

We are IntechOpen, the world's leading publisher of Open Access books Built by scientists, for scientists

6,900

Open access books available

186,000

International authors and editors

200M

Downloads

Our authors are among the

154

Countries delivered to

TOP 1%

most cited scientists

12.2%

Contributors from top 500 universities



WEB OF SCIENCE™

Selection of our books indexed in the Book Citation Index
in Web of Science™ Core Collection (BKCI)

Interested in publishing with us?
Contact book.department@intechopen.com

Numbers displayed above are based on latest data collected.
For more information visit www.intechopen.com



Diagnosis of Acute Myeloid Leukaemia

Anca Bacărea

*University of Medicine and Pharmacy Tg Mures
Romania*

1. Introduction

Acute myeloid leukaemia (AML) is a clonal, malignant disease of hematopoietic tissue characterized by accumulation of abnormal cells, mainly leukaemic blasts in bone marrow and impaired production of normal hematopoietic cells. Leukaemia was discovered in 1845, roughly at the same time by two doctors, Rudolph Virchow, a young Berlin pathologist and a Scottish pathologist, John Hughes Bennett. The term leukaemia was first used by Rudolph Virchow to describe the blood appearance of his female patient after she died. She was a 50-year-old cook, admitted to hospital, complaining of fatigue, frequent nosebleeds and swelling of the legs and abdomen. They were the first who began to understand what exactly goes wrong in this unusual disease.

The aim of this chapter is to present a step by step approach in diagnosing acute myeloid leukaemia and also to identify potential diagnostic pitfalls.

2. Signs and symptoms

The clinical course of AML, treated or untreated, is complex, so care for these patients requires the experience of a specialist physician. Signs and symptoms usually seen in AML are associated with complications, meaning signs and symptoms associated with anaemia, thrombocytopenia, and leukopenia and also signs of organ involvement. Without being specific, they reflect the anaemia development, but there is no direct proportionality between the severity of anaemia and the manifestation of these signs and symptoms: fatigue, asthenia, weakness, pallor, dizziness, irritability, dyspnea, tachycardia, palpitations, and general lack of wellness. Petechial, nosebleeds, gum bleeding, conjunctivas haemorrhage, prolonged bleeding from mild skin lesions, these all reflect the thrombocytopenia and are common early manifestations of the disease. Bleeding of the gastrointestinal tract, genital-urinary, lung or central nervous system (CNS) may occur infrequently.

According to Hu et al. the frequencies of the most important presenting features in AML are presented below in Table 1 (Hu et al., 2011).

Blood transfusions may be necessary but can – in the case of hyperleukocytosis - also lead to a rapid increase in blood viscosity and compromise blood flow. In addition, coagulation abnormalities, including disseminated intravascular coagulation, increase the risk of local haemorrhage. The use of platelet transfusion is recommended, especially since the number of platelets may be overestimated due to the presence of fragments of blasts that are wrongly considered by the automated haematology analyzers. Acute promyelocytic

leukaemia is most commonly associated with intravascular coagulation and bleeding (Tallman & Kwaan, 2004). Platelets interact with normal peripheral blood (PB) cells via soluble mediators of adhesion molecules and these, once released, may affect hematopoietic stem and progenitor cells. Recently the interactions between platelets and AML cells has been characterized in detail (Foss & Bruserud, 2008): blasts and platelets can affect each other’s functions, drugs used to treat AML can alter some platelet functions, systemic levels of cytokines are increased during chemotherapy, including cytokines known to affect platelet activation and blasts, platelet secretion of growth factors is clearly detected in peripheral blood of persons with stem cell autografts.

Acute Myeloid Leukaemia		
Initial symptom	Younger Group (age < 60) %	Elderly Group (age ≥ 60) %
Hypodynamia	57.8	68.3
Pale face	60.3	55.5
Fever	40.5	33.5
Dizziness	14.7	10.4
Hemorrhagic dermatologic mucosa	15.5	14.0
WBC infiltration	6.9	12.2
Myalgias	4.3	3.0
White cell count (10 ⁹ /L)		
< 4	24.1	40.2
4 - 10	16.4	9.8
> 10	59.5	50.0
Haemoglobin (g/L) ²		
Abnormal	93.1	95.7
Normal	6.9	4.3
Platelets (10 ⁹ /L)		
≤10	29.3	21.3
>10	70.7	78.7
Bone marrow cellularity		
Severely hypercellular	53.4	30.5
Moderately hypercellular	21.6	34.8
Normocellular	13.8	20.7
Hypocellular	11.2	14.0

Table 1. The frequencies of the most important presenting features in AML, according to Hu et al.

Infections remain a major cause of morbidity and mortality associated with therapy in both adults and children with AML. Pustules or other skin infections and various skin lesions are the most common minor infections encountered. More serious infections like sinusitis, pneumonia, pyelonephritis and meningitis occur rarely in the beginning. After starting chemotherapy, with aggravation of neutropenia and monocytopenia, serious infections occur more frequently with various bacterial, fungal or viral agents. Progressive decline in immune function makes aged patients with AML theoretically more susceptible

to nosocomial infection than younger ones. However, a study in this regard indicated that there is no significant difference in the overall incidence of infections, such as febrile episodes, the pattern of nosocomial infection sites, the average duration of antimicrobial therapy and overall survival (Fanci et al., 2008). Gram-negative bacteria were more common in patients with severe sepsis (Hämäläinen et al., 2008). A case was reported in the literature of AML with marked hyponatremia and impaired consciousness probably due to treatment with linezolid, but sodium supplementation restored the natremia. Viridans streptococci in children with AML are a major cause of infections and pneumonia in cases with neutropenia. Viridans streptococci sepsis developed at different times after chemotherapy was initiated and patients were febrile for a median of 15 days. 33% of the 172 children with AML included in this study had hypotension, 28% had acute respiratory distress syndrome and 17% had fungal infections (Okamoto et al., 2003). Neutropenic enterocolitis and acute appendicitis are also complications that occur in children with severe or prolonged neutropenia, and may endanger their lives (Alioglu et al., 2007). Hepatosplenic fungal infections are important infectious complications in adults with AML being diagnosed with computerized tomography and high levels of alkaline phosphatase. Mortality related to these infections is low if treatment is appropriate (Masood & Sallah, 2005).

Fever is present at diagnosis in approximately 40-50% of the patients. Anorexia and weight reduction are also common, percentages of 25% being reported (Burns et al., 1981).

Splenomegaly and hepatomegaly are seen in approximately one third of patients, especially in those with a monocytic or monoblastic morphologic subtype. Adenopathy is rare, the exception being the monocytic variant of AML where a frequency of more than 30% can be found (Burns et al., 1981; Hu et al., 2011).

2.1 Specific organ involvement

Blast cells are circulating and infiltrating various tissues. Occasionally, a biopsy or autopsy reveals infiltration with leukaemic cells at different levels. They cause disruption to the affected structures. Extramedullary involvement is more frequent in monocytic and myelomonocytic leukaemia. Recently it was demonstrated that haematopoietic progenitors and leukaemic cells are retained in the bone marrow (BM) microenvironment through chemokine receptors, such as CXCR4. A prospective study evaluated by flow cytometry the prognostic involvement of CXCR4 in AML. The study showed that low expression of CXCR4 on leukaemic cells is correlated with a better prognosis than high expression (Spoo et al., 2007). Different sites may be involved (Liesveld & Lichtman, 2006):

Skin involvement. Skin injury prior to BM and blood involvement is rare and can be of three types: nonspecific lesions (maculae, papules, vesicles, pyoderma gangrenosum, vasculitis, neutrophilic dermatitis, erythema multiform or nodosa), skin leukaemia and granulocytic sarcomas (myeloid sarcomas), being the result of skin infiltration by blastic cells. The most common sites of infiltration are the scalp, trunk and extremities.

Sensory organ involvement. Sensory organ involvement is very rare, however, infiltration of retina, choroids, iris and optic nerve may occur. Otitis external and internal bleeding, infiltration of the mastoid with VII nerve damage may be other signs of disease presentation.

Gastrointestinal tract involvement. May be affected at any level, but functional disorders are rare. Involvement of the oral cavity, colon and anal canal most often lead to symptoms. Involvement of the oral cavity often means the patient goes to the dentist. Infiltration of

gums, periodontal abscess can cause prolonged bleeding following extractions. Enterocolitis may be a way of disease presentation or can occur during treatment. Fever, abdominal pain, bloody diarrhoea or ileus may be present and sometimes mimic appendicitis. Isolated gastrointestinal tract involvement is rare. Proctitis usually occurs in the monocytic variant of leukaemia and is a difficult problem to solve during the period with severe granulocytopenia.

Respiratory tract involvement. Infiltrates may lead to laryngeal obstruction, functional disorders, severe symptoms and radiological changes in the case of parenchymal, alveolar or pleural infiltrates.

Heart involvement. Cardiac involvement is common, but rarely causes symptoms. Pericardial infiltrates, ventricular transmural endocarditis can occasionally cause severe cardiac arrhythmias or even death. Infiltrations of the excitoconductor system and myocardial infarction were also cited.

Urogenital tract involvement. The kidneys are infiltrated with leukaemic cells in a large number of cases, but functional disorders are rare. Bleeding into the collector is common. Cases have been cited with vulvar, prostatic and testicular penetration.

Osteoarticular system involvement. Its involvement is accompanied by various degrees of bone and joint pain. Bone necrosis may also occur. Pseudo-gout arthritis (calcium pyrophosphate dehydrate) or gout arthritis (uric acid) is sometimes responsible for synovitis.

Central nervous system involvement (CNS). CNS involvement is rare, although meningeal infiltration is seen in the monocytic type of AML. An association between CNS involvement and diabetes insipidus has been reported in AML with monosomy 7 and inv16 (Castagnola et al., 1995).

Granulocytic sarcomas. Also known as sarcomas or chloromas, myeloid sarcomas are tumours composed of myeloblasts, monoblasts or megakaryocytes. These tumours can occur as extramedullary masses without evidence of leukaemia in BM or peripheral blood (nonleukaemic myeloid sarcomas) or in combination with leukaemia. When they appear as isolated lesions they are usually chloromas and considered extranodal lymphoma, because of the biopsy appearance similar to lymphoid cells. When myeloid sarcoma is the first manifestation of AML, the involvement of BM and blood appears after a few months. Theoretically myeloid sarcomas can have any location: skin, orbit, paranasal sinuses, bone, chest wall, breast, gastrointestinal tract, respiratory, genital-urinary, central nervous system, peripheral nervous system or lymph node (Hernández et al., 2002; Liesveld & Lichtman, 2006; Pațiu et al., 2008). Abnormalities involving chromosome 8 are the most common cytogenetic abnormalities in nonleukaemic sarcomas (Tsimberidou et al., 2003). Initially, these tumours were termed chloromas because of the green colour due to the presence of myeloperoxidase in myeloid leukaemic cells. Patients with AML with t(8;21) have a propensity to develop extramedullary leukaemia with poor outcomes after treatment.

2.2 Neonatal and childhood AML

A study conducted between May 1988 and June 2000 that included 698 children with AML tried to find the relationship between the age of onset of the disease, clinical characteristics and evolution. AML onset was observed at a very young age and is accompanied by intermediate risk cytogenetics (high incidence of 11q23 translocations). French-American-British (FAB) distribution is also based on age: types M5 and M7 are more common at

younger ages and types M0, M2, M3 more common in older children. In terms of clinical diagnosis, CNS involvement and digestive tract involvement is more common in very young children. Very young children develop severe diarrhoea, nausea and vomiting after chemotherapy (Webb et al., 2001). A recent study shows the impact of the undifferentiated form of AML-M0 on disease progression in children with AML with and without Down syndrome (DS), analyzing two clinical trials (Children's Cancer Group Clinical Trials AML). The main issues pursued were morphology and cytogenetics. Children with AML-M0 without DS had a lower number of leukocytes than patients with non-M0 AML and a higher incidence of del5, non constitutive trisomy 21 and hypoploidy. The analysis of AML in children without DS showed no differences between cases and non-M0 M0. Also there was no difference in evolution between children with DS and M0 and those with DS and non-M0 AML (Barbaric et al., 2007).

Four AML related syndromes are described in newborns:

- Transient myeloproliferative disease that may be present at birth or immediately after in about 10% of children with DS. The syndrome is followed shortly by acute leukaemia, usually myeloid (less common lymphoblastic).
- Transient leukaemia. 25% of children with DS and transient leukaemia develop AML - M7 in the first 4 years of life.
- Congenital Leukaemia.
- Neonatal leukaemia. Children who develop leukaemia during the first weeks of life are often pale, with insufficient increase in weight, diarrhoea and lethargy. The presence of cytogenetic abnormalities involving chromosome 11 has an extremely unfavourable prognosis.

The last two syndromes can occur in children without DS, but 10 times less frequently than in those with DS. Leukocytosis, bone marrow and blood infiltration with blasts, hepatosplenomegaly, thrombocytopenia, anaemia, purpura and skin infiltrates are common manifestations. Unfortunately, these children do not survive more than a few weeks or months. The disease can be highlighted during the prenatal period because cytogenetic abnormalities appear and mark the leukaemic clone. Monocytic differentiation of leukaemia and t(4;11) are common features. A case was even reported of transplacental transmission of acute monocytic leukaemia (Liesveld & Lichtman, 2006).

2.3 Elderly AML

AML in the elderly is a biologically distinct clinical entity. AML is generally a disease of old age, because the diagnosis is usually made in the decade of 60-70 years. The unfavourable course of the disease is due to biological characteristics at this age and various associated comorbidities. In the United States the elderly population is the fastest growing segment, the average age at diagnosis of AML being 67 years (Melchert, 2006). Some data indicate that the disease develops from haematopoietic precursors that are in an early stage of maturation and may thus involve more than one haematopoietic line. This could explain the clinical and biological behaviour of the disease and prolonged neutropenia after chemotherapy. In addition, a large number of blasts express drug resistance glycoprotein - MDR1 and the incidence of unfavourable cytogenetics is high (7-, 5-). These factors, rather than age itself, are responsible for the unfavourable evolution of the disease. Compared to younger ages AML, AML in the elderly often derives from a previous haematological disease or after treatment for another malignancy. The morphological signs of dysplasia are frequently

observed (Ferrara & Pinto, 2007; Hiddemann et al., 1999). Many of these patients cannot cope with intense chemotherapy and its complications. The acute toxicity of chemotherapy is greater in patients with chronic heart, lung, liver or kidney disease. For example, age-related reduction of left ventricular ejection fraction limits the use of anthracyclines or mitoxantrone. Cardiotoxicity can occur at any time during mitoxantrone therapy and the risk increases with cumulative dose. Congestive heart failure, potentially fatal, may occur either during therapy with mitoxantrone or months to years after termination of therapy. The risk of symptomatic congestive heart failure was estimated to be 2.6% for patients receiving up to a cumulative dose of 140 mg/m². Elderly patients also have reduced regenerative capacity of BM, even if the cytoreduction treatment was successful. Their inability to tolerate long periods of pancytopenia, malnutrition and toxicity of aminoglycosides or amphotericin are major barriers to successful treatment (Rathnasabapathy & Lancet, 2003).

3. Laboratory investigations

3.1 Complete Blood Count (CBC)

BM infiltration by leukaemic cells is almost invariably accompanied by anaemia and thrombocytopenia, absolute neutrophil count being low or normal depending on the total number of leukocytes.

Although CBC is a routine investigation, it has not lost its relevance in the diagnosis of haematological diseases and hence in AML. CBC helps to highlight the three major complications in AML: infections (due to neutropenia), anaemia (low value of haemoglobin, low red blood cells count) and bleeding (due to thrombocytopenia).

The first clue for the diagnosis of AML is an anomalous result of the total number of leukocytes. Between 5-20% of patients may present with a very large number of cells ($> 100 \times 10^9/L$). Although leukocytosis is a frequent feature, AML may also present with a normal leukocyte count and only a low number of platelets and erythrocytes, or even leukopenia (aleukaemic forms of AML).

The blast cells may be counted as lymphocytes or monocytes by the automated haematology analyzers and frequently not counted at all. Another important issue is that the analyzers cannot differentiate between myeloblasts and lymphoblasts. Eosinophilia and basophilia may be present in some subtypes of AML.

CBC is used after the diagnosis to monitor disease progression and also has prognostic impact. It is known that the increased number of leukocytes ($> 30000/\text{microL}$ or number of blasts $> 15000/\text{microL}$) and a very low number of platelets ($< 30000/\text{microL}$) are factors of poor prognosis in AML.

3.1.1 Hyperleukocytosis and leukostasis

Leukaemic cells are considerably less deformable than mature myeloid cells. With the increasing number of blasts in PB, leukocytosis (total leukocyte count $> 10000/\text{microL}$) or hyperleukocytosis (total leukocyte count $> 100000/\text{microL}$) appears and microcirculation is threatened by the formation of caps from these rigid cells. Local hypoxemia may be exacerbated by increased metabolic activity of blasts and by the production of various cytokines. These events lead to impaired endothelial integrity and haemorrhage occurring in the existing fund of hypoxia. 5% of patients with AML develop signs and symptoms due

hyperleukocytosis. Circulation of the central nervous system and of the lungs is the most susceptible to the effect of leukostasis. Cerebral haemorrhage due to vascular occlusion is the most aggressive manifestation.

3.1.2 Hypoplastic leukaemia

10% of AML patients have pancytopenia, often with no blasts in peripheral blood, without hepato-splenomegaly. Three quarters of these patients are men aged over 50 years. A BM biopsy shows a hypocellular aspect, but blasts present in a ratio of 15-90%. Hypoplastic leukaemia must be distinguished from aplastic anaemia and hypoplastic myelodysplastic syndrome. Diagnosis is made on the presence of $\geq 20\%$ blasts in the hypocellular marrow. A history of toxic exposure (chemicals, alcohol or chemotherapy for another malignancy) was demonstrated in approximately 20% of these cases (Gladson & Naeim, 1986).

3.1.3 Oligoblastic leukaemia

In 10% of cases, usually in patients aged over 50 years, AML manifests with anaemia and thrombocytopenia, white blood cell count is low, normal or increased. The proportion of blasts present in peripheral blood varies from 0-19% and between 3-20% in the BM. These cases are classified either as oligoblastic myeloid leukaemia or myelodysplastic syndrome, especially refractory anaemia with blasts excess. The disease has high morbidity and mortality through infections and bleedings.

3.1.4 Red blood cell count

Anaemia is almost always present in AML, because of inadequate production of RBC in the BM and shortened lifespan. Anisocytosis and poikilocytosis are variously reflected in erythrocyte indices and Price Jones curve. A vicious chain develops when bleedings occur, but the BM is not able to produce new erythrocytes. The reticulocyte number is usually low.

3.1.5 Platelet count

The platelet count is usually low, with different degrees of thrombocytopenia. In rare cases the platelet number can be normal. The mechanisms of thrombocytopenia are inadequate production of platelets in the BM and shortened lifespan. The platelets are usually big in size as shown by increased medium platelet volume on CBC.

3.2 Blood smear

Diagnosis and classification of AML is becoming increasingly complex. Current classifications refer to morphological features, immunophenotype and genetics in order to classify the different subtypes of leukaemia. Still, a competent and rigorous microscopic examination remains essential for diagnosis of AML.

Presumptive diagnosis of AML can be made by examining the peripheral smear, where leukaemic blasts are circulating in peripheral blood, but definitive diagnosis is made by examination of the aspirate or biopsy of BM. Classic May-Grunwald-Giemsa staining of peripheral blood and BM are used. Currently the diagnosis of AML is based on the evidence of 20% blasts in BM. In some cases, if the condition of patient does not allow the puncture of BM or biopsy and if there is evidence of 20% blasts in peripheral blood, the diagnosis can be made. On the other hand, we must not forget that some patients do not have blasts in their blood, so we could erroneously conclude it is not leukaemia. In such cases, if there is a

suspicion of haematologic malignancy (anaemia, thrombocytopenia) the examination of BM is obligatory.

In the past 30 years the classification of AML has been done after the FAB system (French-American-British Cooperative Group classifications of AML), based on morphological and cytochemical criteria and includes eight types of AML: M0-M7.

- M0 (AML with minimal differentiation)
- M1 (AML without maturation)
- M2 (AML with maturation granulocyte)
- M3 (promyelocytic) or acute promyelocytic leukaemia
- M4 (acute myelomonocytic leukaemia)
- M4Eo (with BM eosinophilia)
- M5 monoblastic acute leukaemia (M5a) or acute monocytic leukaemia (M5b)
- M6 (acute erythroid leukaemia) that includes erythroleukemia (M6a) and very rarely pure erythroblast leukaemia (M6b)
- M7 (acute megakaryoblastic leukaemia)

Blast morphology is considered of three types based on the cytoplasmic content in azurophilic granules: type I myeloblasts with no cytoplasmic granules, type II myeloblasts with less than 20 azurophilic granules and type III myeloblasts with more than 20 azurophilic granules in their cytoplasm. Type II and III may also contain Auer rods (Naeim & Rao 2008). The percentage of Auer rods recognized by Wright-Giemsa (WG) staining was 20.8%, but three times higher by peroxidase staining techniques (Jain et al., 1987). In peripheral blood a variable number of blasts are present and not related with the number of myeloblasts in the BM. Sometimes the BM is highly infiltrated, even if we have few blasts in the blood. Usually, blast morphology in the peripheral blood is in concordance with the BM, although sometimes differences may occur (differential diagnosis with acute lymphoblastic leukaemia, some lymphomas). So, both attentive examination of blood smear and BM are needed.

Red blood cells morphology is variously affected, with large and small erythrocytes (anisocytosis) and different shapes especially if the leukaemia developed from a myelodysplastic syndrome (ovalocytes, tear drop erythrocytes). Erythroblasts and stippled erythrocytes may also be present.

Thrombocytes may be giant or with granulation abnormalities (usually hypogranulated).

Different dysplastic changes may be present if AML has undergone transformation from myelodysplastic syndrome: hyper/hypo granulation or hyper/hypo segmentation of granulocytes.

3.3 Bone marrow examination

Currently, the diagnosis of acute myeloid leukaemia is based on the presence of a minimum of 20% blasts in the BM.

By the term blasts we understand myeloblasts, promonoblasts, monoblasts, megakarioblasts or promyelocytes. According to the World Health Organization (WHO) 2008, an exception from the 20% rule is possible, if there is evidence of AML with recurrent abnormalities: AML with t(8;21)(q22;q22), inv(16)(p13.1q22) or t(16;16)(p13.1;q22) and APL with t(15;17)(q22;q12) are considered as acute leukaemia regardless of blast count in the blood or BM, but in contrast to the previous edition, for AML with t(9;11)(p22;q23) or other 11q23 abnormalities, as well as for all other subgroups (except the rare instance of some cases of

erythroleukemia) blasts of 20% or more of white blood cells in peripheral blood (PB) or of all nucleated BM cells is required for the diagnosis of AML.

The former FAB morphologic entities are now included as acute myeloid leukaemia not otherwise specified:

AML with minimal differentiation (FAB M0)

Medium-sized blasts with no signs of differentiation, with fine nuclear chromatin and agranular cytoplasm. Sometimes blasts are small, resembling lymphoblasts. The BM is usually hypercellular and survival is poor.

AML without maturation (FAB M1)

In the BM we usually find above 90% myeloblasts from nonerytroid cells with few signs of differentiation. Blast may have azurophilic granules and/or Auer rods, but most are agranular blasts. Sometimes blasts look like lymphoblasts and BM is typically hypercellular. The literature cites cases of AML - M1 with mirror cells (although they are most commonly found in acute lymphoblastic leukaemia) and even with Auer rods (Casasnovas et al., 2003).

AML with maturation (FAB M2)

This category represents 30-45% of AML. It is also the most frequent AML in children. We find 20% or more myeloblasts in the blood or BM and 10% or more neutrophils in various stages of maturation (promyelocytes, myelocytes and metamyelocytes). Monocytes represent less than 20% of BM cells. Myeloblasts can be with or without azurophilic granules and Auer rods. Abnormal nuclear segmentation of neutrophils and increased number of eosinophilic precursors are frequent. The BM is usually hypercellular. In some cases the immature cells have abundant cytoplasm and basophilia, with a variable number of granules, sometimes indistinguishably, sometimes coalescent, making difficult the difference between M1 and M2.

Acute promyelocytic leukaemia (FAB M3)

In the classic form the predominant cells are abnormal promyelocytes with many primary granules. Auer rods are frequent and often occur in bundles. In the microgranular version (M3v), leukaemic cells have monocytic aspect with cleaved nuclei and abundant cytoplasm with indistinguishable granules.

Acute myelomonocytic leukaemia (FAB M4)

This category accounts for between 15-25% of AML. Some patients have a history of chronic myelomonocytic leukaemia. It is characterized by the proliferation of neutrophilic and monocytic precursors, 20% or more myeloblasts, monoblasts and promonocytes being needed in the BM nucleated cells to distinguish between chronic myelomonocytic leukaemia and AML, and $5 \times 10^9/L$ or more blood monocytes.

Monoblasts are large size, with round nuclei, abundant cytoplasm and prominent nucleoli, and sometimes have fine azurophilic granules. There is the eosinophilic variant (M4Eo), in which eosinophils are increased in number (>5%) and this variant is associated with chromosome 16 abnormalities.

Monoblastic acute leukaemia (FAB M5a) or acute monocytic leukaemia (FAB M5b)

This is characterized by a percentage exceeding 80% of leukaemia cells of monocytic type: monoblasts, promonocytes and monocytes. The two differ in the relative proportions of

monoblasts and promonocytes. If most cells are monoblasts, it is M5a type (usually over 80%), and if most cells are promonocytes, it is M5b type.

Monoblastic acute leukaemia is characterized by large basophilic monoblasts, with abundant cytoplasm, with formation of pseudopods, round nuclei with one or more prominent nucleoli. Rarely Auer rods are observed. BM is hypercellular with an increased number of monoblasts.

Monocytic acute leukaemia is characterized by the presence of promonocytes with irregular nuclei, with moderate basophilic cytoplasm and azurophilic granules. The erythrophagocytosis phenomenon can be seen.

From a clinical point of view, M4 and M5 subtypes are accompanied with signs of medullary and extramedullary involvement: fever, fatigue, haemorrhage, gingival hyperplasia, hepato-splenomegaly, lymphadenopathy and involvement of the nervous system. Because the involvement of the central nervous system is frequent, the examination of cerebrospinal fluid is recommended, even if no clinical signs of involvement are present.

Acute erythroid leukaemia (FAB M6)

This includes erythroleukemia (M6a) and very rarely pure erythroblast leukaemia (M6b). The two types are characterized by the presence of a predominant erythroid population and in the case of M6a by the presence of an important myeloid component. M6 may be present de novo or evolve from a myelodysplastic syndrome. Occasionally, some cases of chronic myeloid leukaemia may develop into M6. Pancytopenia is a common feature.

Over 50% of nucleated cells of the MO are abnormal erythroblast. Displastic changes in erythroblasts may be important: giant forms, multinucleated, cytoplasmic vacuolation and megaloblastoid change.

Erythroleukemia (M6a) is characterized by 50% or more erythroid precursors from nucleated cells in the BM, 20% or more myeloblasts from non erythroid population in the BM, displastic erythroid precursors, with megaloblastoid nuclei and multinucleated erythroid cells. Dysplasia is also seen on the megakaryocytic line. Myeloblasts are of medium size, occasionally with Auer rods. Ringed sideroblasts can be present and the BM is usually hypercellular. This morphologic type represents the majority of acute erythroid leukaemias. Pure erythroblast leukaemia (M6b) is characterized by medium and large sized erythroblast with round nuclei, fine chromatin, one or more nucleoli, intense basophilic cytoplasm and occasionally coalescent vacuoles.

Acute megakaryoblastic leukaemia (FAB M7)

This represents 3-5% of AML, blast cells appertaining to the megakaryocytic line. It is characterized by cytopenia, displastic changes of neutrophils and platelets.

Megakarioblasts are of medium to large size, with incised or round nuclei and with one or more nucleoli. Cytoplasm is basophilic, agranular with pseudopods. In some cases lymphoblast-like morphology (increased nuclear/cytoplasmic ratio) has been reported. We can frequently see in blood micromegakaryocytes circulating, fragments of megakaryocytes, large and displastic platelets and hypogranulated neutrophils. BM is often fibrous and BM puncture may be white (blinded). It presents with two peaks according to age: in children 1-3 years old related with Down syndrome and in adults. According to 2008 WHO classification, myelodysplastic syndrome and AML related to Down syndrome are biologically identical and considered as myeloid leukaemia associated with Down syndrome.

Acute basophilic leukaemia

This is a form of AML with primary differentiation to basophils. It is a rare, representing 1% of AML. It is accompanied by secondary signs of hyperhistaminemia, circulating blasts, organomegalia and BM failure. Morphologically it is characterized by medium-sized blasts with high nuclear/cytoplasmic ratio, round, oval, bilobate nucleus with one or more nucleoli, moderate basophilic cytoplasm containing a variable number of basophilic granules, red cell dysplasia and hypercellular BM.

Acute panmyelosis with myelofibrosis

This condition can occur at any age, de novo or after treatment with alkylating agents and/or radiation. There is an acute proliferation associated with fibrosis of BM. It is characterized by pancytopenia, marked anisocytosis, dysplastic change of myeloid line, hypercellular BM on the osteomedullary biopsy, varying degrees of hyperplasia of erythroid granulocytic, megakaryocytic precursors in BM, increased number of megakaryocytes with dysplastic changes and a marked increase in the number of reticulin fibres in BM.

There are even some overlapping features with M7 subtype, the distinction is that in M7 the predominant population of blasts is of megakaryocytic origin and in acute panmyelosis with myelofibrosis it is of non-megakaryocytic origin. The prognosis is unfavourable.

3.3.1 Particular morphological forms of acute myeloid leukaemia*Acute myeloid leukaemia with cup-like morphology*

Various authors have attempted to characterize the morphology of AML with this special morphological appearance, raising questions as to whether this is a new disease entity or an artificial phenomenon (Barbaric et al., 2007; Benderra et al., 2005). Investigating the 'cup-like' morphology of 266 randomly selected patients with AML and association with haematological, immunological and prognostic parameters, it was found that this morphology was present in 21% of cases, was associated with the female sex, increased numbers of leukocytes and blast, normal karyotype, low expression of CD34 and HLA-DR. With regard to FLT3 mutations, NPM1 were found in 84.9% of cases, compared to 58.1% in cases without this morphology. Response to treatment and survival were not influenced in this study. Electronic microscopy showed that the cups contain lots of organelles. This particular form does not appear as a distinct category in any classification. It is sometimes difficult to do the differential diagnosis with acute promyelocytic leukaemia, the microgranular variant, in which neoplastic cells with prominent, bilobed nuclei can partially resemble blasts with cup-like nuclei. Immunophenotyping cannot identify the difference because both acute myeloid leukaemia with cup-like morphology and acute promyelocytic leukaemia are CD34- and HLA-DR-, with strong myeloperoxidase reaction.

3.4 Biochemistry

No specific biochemical pattern characterizes AML. Usually high activity of serum lactate dehydrogenase (LDH) is present. LDH is a biochemical marker reflecting tumour load and anaerobic glycolysis. When tissues are shifted from aerobic to the anaerobic glycolysis, LDH activity increases to accelerate the conversion of pyruvate to lactate, with the release of energy. At the molecular level, hypoxia induces expression of vascular-endothelial growth factor (VEGF) and fibroblasts growth factor (bFGF), and thus angiogenesis. Enhancing

angiogenesis is a phenomenon which was observed in AML. Studies have shown that the activity of serum LDH and not the concentrations of two growth factors (VEGF, bFGF) may be used as a parameter predictor for BM angiogenesis in AML (Teng et al., 2006). Another value of this marker is the prediction of tumour lysis syndrome (TLS), which usually occurs in patients with hyperleukocytosis. Despite the prophylactic use of allopurinol, morbidity and mortality related to tumour lysis syndrome (TLS) still occurs in some patients with AML. The criteria for tumour lysis syndrome are serum creatinine level over 1.4 mg/dL (normal range 0.5 to 1.4 mg/dL) and an increase of at least one of the following parameters: potassium > 5 mEq/L (normal range 3.7 to 5.0 mEq/L), uric acid > 7.5 mg/dL (normal range 3.0 to 7.0 mg/dL), phosphate > 5 mg/dL (normal range 2.4 to 4.1 mg/dL) and calcium < 8 mg/dL (normal range 8.4 to 10.2 mg/dL). TLS can be a life-threatening complication in patients during induction therapy in AML. Characteristic laboratory changes may occur spontaneously before initiation of induction therapy due to catabolism and to increased turnover of leukaemic cells, but is most commonly induced by intensive chemotherapy. Yet few studies have focused upon TLS in AML, so the incidence and development of TLS in these patients are not well defined. A study that included 772 patients with AML treated with allopurinol and intense hydration showed that 17% of patients developed TLS. Multivariate analysis showed that pretreatment levels of LDH above the normal range, creatinine over 1.4 mg/dL, uric acid over 7.5 mg/dL and WBC count $25 \times 10^9/L$, were independent prognostic factors for TLS (Montesinos et al., 2008). In children with AML, life-threatening pulmonary complications were cited in combination with TLS and mimic systemic inflammatory response syndrome (SIRS). Severe SIRS is more common in association with monocytic and myelomonocytic AML (M4, M4Eo, M5), especially in M4Eo. A mild or moderate increase of uric acid plasma level is frequent, especially in monocytic and myelo-monocytic AML.

Changes of ions concentrations (sodium, potassium, calcium, hydrogen) are mild or moderate and infrequent. Hypokalemia is the most frequent finding at presentation, related to renal tubular dysfunction, and artifactual increase of potassium is associated in vitro in patients with hyperleukocytosis. Hypocalcaemia can appear as a result of multiple mechanisms, as direct skeletal invasion by malignant cells, ectopic parathyroid hormone (PTH) production or bone-resorbing cytokines. Hypophosphataemia as a result of leukaemic cell up-take, also can occur. Hyponatremia and lactic acidosis as presenting features of AML are rare. Hyponatremia is proposed to be due to inappropriate production of antidiuretic hormone by the leukaemic cells. There has been no well defined cause for lactic acidosis due to leukaemia per se, but probable explanations are due to anaerobic glycolysis by leukaemic cells and due to increased blast count with its attendant leukostasis (Udayakumar et al., 2006).

Various abnormalities of coagulation are met in AML: decrease in α_2 antiplasmin, antithrombin III and fibrinogen. Especially in promyelocytic acute leukaemia, there is a high risk for disseminated intravascular coagulation, because of procoagulants released from the cytoplasmic granules.

3.5 Cytochemical stains

Cytochemical stains with full analysis of blood and careful morphological examination of peripheral smear and BM help to classify most cases of AML. Research into signs of dysplasia is important work and it is hard to quantify cell dysplasia when the line is poorly represented (Braham-Jmili et al., 2006).

Cytochemical stains that characterize each morphological subtype are the following:

M0 (AML with minimal differentiation)

- Myeloperoxidase staining is negative (MPO)
- Sudan Black staining is negative (SBB)
- Naphthol chloroacetate esterase staining is negative (<3% positive blasts)
- Alpha naphthyl acetate and butyrate esterase staining are negative
- Periodic acid Schiff (PAS) staining is negative
- This subtype can only be diagnosed using flow cytometry

M1 (AML without maturation)

- 3% or more of the blasts positive for MPO and SSB
- PAS is usually negative

M2 (AML with maturation granulocyte)

- A large number of blasts are MPO positive
- PAS is usually negative

M3 (promyelocytic) or acute promyelocytic leukaemia

- Blasts are MPO and chloroacetate esterase positive
- The hypogranular variant behave similarly regarding the cytochemical stains

M4 (acute myelomonocytic leukaemia)

- MPO positive in at least 3% of blasts
- Monoblasts, promonocytes and monocytes are typically nonspecific esterase (NSE) positive

Monoblastic M5 acute leukaemia (M5a) or acute leukaemia monocytic (M5b)

- Typically NSE is strongly positive
- MPO is negative, but the MPO may occasionally be positive in M5b
- Lysozyme is positive

M6 (erythroid acute leukaemia)

- Red cell precursors are PAS positive
- Blasts are MPO, SSB negative, but may be positive for NSE

M7 (acute megakaryoblastic leukaemia) (23)

- Stains are negative for MPO and SSB
- Blasts can be PAS and NSE positive
- This subtype can only be diagnosed using flow cytometry

Acute basophilic leukaemia (26)

- Blasts are acid phosphatase positive
- MPO, SBB, NSE are negative

Acute panmyelosis with myelofibrosis

- In some cases blasts may be MPO positive

Granulocytic sarcoma

- Tumour cells may express myeloid associated molecules in the biopsies, such as MPO, NSE or lysozyme.

3.6 Immunophenotyping

Flow cytometry is a technique used for counting, examining and sorting microscopic particles suspended in fluid. It also allows multiparametric analysis of the physical and/or chemical characteristics of a single cell passing through an optical and/or electronic detection device. Immunophenotyping is an essential technique for the diagnosis,

classification, staging and monitoring of leukaemia. In the last 10 years, expanding monoclonal antibodies (MoAb) and fluorochemicals allow differentiation of normal cell populations, of leukaemic cells, defining the state of maturation and recognition of aberrant phenotypes.

Despite recommendations for standardization for multiparametric flow cytometry (Bene et al., 1995; Rothe & Schmitz, 1996; Stewart et al., 1997; Bain et al., 2002), the number, specificity and combination of reagents used for diagnosis and classification of acute leukaemia in different laboratories are varied. A study showed that using combinations of four MoAb from a minimum panel of 13 MoAb and CD45/sideward scatter gating strategy, achieved the correct classification in 97.2% of cases of acute leukaemia (155 patients), of which 79 were AML (Ratei et al., 2007).

To monitor minimal residual disease (MRD), application of five-colour flow cytometry is more appropriate, enhancing sensitivity and precision of the method (Bacărea et al., 2007; Voskova et al., 2007). Another study also demonstrated that multiparametric flow cytometry in five colours is useful for the detection of leukaemia associated phenotypes in BM of patients with de novo AML and detection of MRD. Another study showed that the six-colour cytometry allowed for the identification of leukaemia associated phenotypes that are not expressed in normal BM or postchemotherapy and can be used successfully to monitor the MRD. The practical relevance of the multicolour approach is the ability to detect patients at high risk of relapse (Olaru et al., 2008).

Immunophenotyping of acute leukaemia cells after density gradient separation is currently the gold standard, but the destruction of red blood cells after whole blood lysis and direct marking is a widespread and used procedure. In addition, data show that for both methods, the mean expression of antigens being tested was similar: CD4, CD7, CD11b, CD11c, CD13, CD14, CD15, CD33, CD34, CD65s, glycophorin A, HLA-DR (Schwonzen et al., 2007). For manual counting, blasts represent the percentage of total nucleated cells. For flow-cytometric studies, the lysis step for removing erythrocytes, removes a variable number of red cell precursors. So, the obtained values determined by flow cytometry are a percentage of all analyzed cells or all nonerythroid cells. These differences also affect the use of flow cytometry to assess erythroleukemia, the erythroid/myeloid type, where the criteria require more than 50% red cell precursors of the total population of nucleated cells and above 20% myeloblasts from the nonerythroid population. Using cell separation with Ficoll also leads to alteration of cell proportions and is strongly discouraged. On the other hand, blasts can be difficult to recognize on morphological examination, or are destroyed during preparation of blood or BM smears. So it is prudent to perform both immunophenotyping and morphological blast count (Craig & Foon, 2008).

Usually, the expression of an antigen is considered positive if 20% or more blasts react with a specific antibody. Blast cells can be distinguished from myeloid precursors through the expression of immature markers CD34, CD117 and lack of maturity markers CD11b, CD15, CD16. Some blasts are negative for CD34 and CD117, and are difficult to distinguish from more mature cells. For example, it is difficult to distinguish mature monocytes from CD34 negative monoblasts. Therefore, even if it is tempting, it is preferable not to make the selection of blasts according to CD34. CD117 antigen is expressed on the blasts, but also on mast cells. Mature myeloid cells when hypogranulated may fall below on the side scatter and may fall into the blasts window on CD45/side blasts scatter plot.

The advantages of flow cytometry are given by the possibility of quick analysis of several thousand cells, multiparametric analysis. It also allows the assessment of aberrant markers and mixed phenotypes and investigation of MRD. Disadvantages are the costs (an expensive device and antibodies), the panels that can change, problems of interpretation and the fact that the technique does not allow diagnosis of acute leukaemia, which is cytological.

To standardize the work in specialized laboratories it is recommended an initial assessment of the line and then a secondary assessment. In the attempt to define the optimal number of markers to determine the immunophenotype in acute leukaemia with a sensitivity of 95%, some recommended markers for AML are: myeloperoxidase (MPO), CD33, CD13, CD14, CD15, CD117, CD34 (Lee et al., 2006). Other authors recommend wider panels with specific antibodies: CD13, CD14, CD15, CD33, CD64, CD117, CD36, MPO and antigens associated with haematopoietic cell maturation (CD34, CD38, TdT) and myeloid antigens (CD16, CD66). In addition, it is recommended to use other auxiliary markers in determining non-specific antigens: CD7, CD19 and CD56 are very useful to monitor residual disease (Woźniak & Kopec-Szlezak, 2008).

AML is regarded as a stem cell disease. In AML CD34 + leukaemic stem cells are recognized as CD38-. This CD34 + CD38- population survives chemotherapy and is most likely the cause of residual disease (MRD - with poor prognosis), which will then lead to relapse. Thus, by showing CD34 + CD38- malignant cells after chemotherapy, detection of MRD at stem cell level is possible (van Rhenen et al., 2007).

Based on antigen positivity we can establish different immunological profiles:

- Myeloblastic – CD13, CD33, CD117, CD15, HLA-DR usually positive
- Myelomonocytic – CD11, CD13, CD33, CD14, HLA-DR usually positive
- Erythroblastic – Glycophorin, spectrin, carbonic anhydrase I, HLA-DR usually positive
- Promyelocytic – CD11, CD13, CD33, CD15 usually positive
- Monocytic – CD11, CD13, CD33, CD14, HLA-DR usually positive
- Megakaryoblastic – CD34, CD41, CD42, CD61, von Willebrand factor

For practical reasons it is necessary that FAB classification and immunological profile correspond.

M0 (AML with minimal differentiation)

- CD 34 and HLA-DR usually positive, but CD38 is negative in most cases
- Myeloid associated antigens often positive – CD13, CD33, CD117
- About half of the cases express TdT and/or CD7
- Monocytic markers are usually negative
- Occasionally the blasts may aberrantly express CD10, CD19, CD2, CD56
- Lack of lymphoid antigen expression: cyCD3 for T line, cyCD79 and cyCD22 for B line

M1 (AML without maturation)

- Myeloid associated antigens often positive – CD13, CD33 and CD117
- CD34, HLA-DR, cyMPO are often positive

M2 (AML with maturation granulocyte)

- Myeloid associated antigens often positive – CD13, CD33 and CD117
- CD34, HLA-DR, cyMPO are often positive
- Occasionally the blasts may aberrantly express CD56, CD19
- Monocytic markers are usually negative

M3 (promyelocytic) or acute promyelocytic leukaemia

- Leukaemic promyelocytes express strongly for MPO and SSB, and also for CD9, CD13, CD33

- CD34, HLA-DR are negative
- Sometimes it is difficult to make a differential diagnosis between acute promyelocytic leukaemia, the hypogranular variant and acute myeloid leukaemia with cup-like morphology, because it is also characterized by the immunophenotype: CD34-, HLA-DR-. Also, CD7 is usually negative and myeloid markers are often positive (CD13, CD33, CD117, myeloperoxidase).

M4 (acute myelomonocytic leukaemia)

- Myeloid antigens CD13, CD33 are often positive
- Partial expression of CD34, MPO, CD11c, CD36, CD64, CD117, HLA-DR
- Aberrant expression of CD2, CD7, CD56
- CD14 may have partial expression or sometimes may be negative

M5 (monoblastic acute leukaemia - M5a or acute monocytic leukaemia - M5b)

- Monocytic markers are usually positive: CD11c, CD36, CD64, CD14
- HLA-DR is positive
- A small proportion of blasts express CD13, CD33, CD117, MPO (weak)
- CD34 is usually negative
- Aberrant expression of CD56
- High levels of CD64 expression distinguish AML subtype - M5, but low expression of CD64 by itself does not distinguish between subtypes of AML M4 and M5. Some authors consider the association of CD68 and CD11b useful to differentiate M5a and M5b FAB subtypes, given that CD68 and CD11b expression are much higher in M5a than in M5b (Pagano et al., 2005).
- When immunophenotyping cannot be done successfully (inadequate smears, white puncture) immunohistochemistry can identify the monocytoid component. The usefulness of CD163 (scavenger for haemoglobin molecule present on monocytes/macrophages) is well established (Garcia et al., 2008).

M6 (erythroid acute leukaemia)

- Erythroid precursors are usually positive: glycophorin, CD71
- CD34, HLA-DR are negative
- Myeloid, monocytic markers are negative

M7 (acute megakaryoblastic leukaemia)

- Platelet glycoproteins are positive both on the surface and intracytoplasmatic - CD41, CD42, CD62
- Sometimes megakaryoblasts may express CD36, CD7
- HLA-DR is often negative

Acute basophilic leukaemia

- Some myeloid markers may be positive - CD13, CD33
- CD34, HLA-DR are usually positive

Acute panmyelosis with myelofibrosis

- CD34 and myeloid antigens CD13, CD33, CD117, MPO are often positive
- A small proportion of blasts express platelets associated antigens

Granulocytic sarcoma

- Sarcomas are a mixture of immature and mature myeloid cells. The marker's presence is based on the balance between the two.

Phenotype in myeloid leukaemia associated with Down syndrome

- Usually Down syndrome is associated with megakaryoblastic acute leukaemia, being CD41, CD42, CD62 positive.

Different studies have tried to correlate immunophenotype with cytogenetic profile and clinical manifestations, showing that karyotype abnormalities and clinical manifestations are closely related to abnormal antigen expression in AML (Plesa et al., 2008; Thalhammer-Scherrer et al., 2002; Zheng et al., 2008):

- Co-expression of CD19 was found in subtypes M0, M1 and M2.
- The expression of CD14 is associated with subtypes M4, M4Eo, M5b, accompanied by poor outcome, low complete remission rate and shorter survival.
- Expression of CD7 was found in subtypes M0, M1, M2, M4 and most frequently in M5a.
- Expressions of CD22, CD56, TDT were correlated with the presence of abnormal karyotype.
- t(8;21) was present in M2 and strongly associated with expression CD15/CD19/CD34/CD56.
- In the M3, although lymphoid markers were detected in a considerable number of cases, they were not highlighted in any patient with t(15;17).
- In M4, CD2 and CD34 expression was associated with abnormal karyotype. CD2 expression was higher in the M4Eo version, but had no correlation with inv(16). Other studies indicate the presence of CD2 in M4Eo and M3variant.
- In M5 there was a higher expression of CD14 and CD56.
- The expressions of CD4, CD7, CD14, CD56, TDT were correlated with clinical features: increased numbers of leukocytes, platelets and patient age.
- The few studies investigating AML-M7 confirm the high heterogeneity of this subtype. Cytogenetic abnormalities in adults are frequently those of secondary leukaemia and few of them have a history and morphology with dishematopoiesis. In children, besides the famous Down syndrome (DS) associated M7, t(1;21) is characterized by young age of onset, female sex, tumour presentation and low percentage of blasts in BM, sometimes without megakaryoblastic marrow involvement, but always with dismegakaryopoiesis associated with micromegakaryocytes. It appears that these children generally respond well to intensive chemotherapy (Duchayne et al., 2003).

3.6.1 Flow cytometry and minimal residual disease (BMR)

It is known that flow cytometry can be used not only for diagnosis of AML, but also to monitor the BMR. Two highly sensitive methods, multiparametric flow cytometry and real-time quantitative PCR (RQ-PCR), are widely used to monitor the BMR and disease management. Multiparametric flow cytometry is particularly useful for investigating the early clearance of blasts, and blast count after consolidation therapy. Later, BMR levels quantified by RQ-PCR in cases of AML with fusion gene had the highest prognostic power, the sensitivity of RQ-PCR being between 10^{-4} - 10^{-7} . Both methods are able to detect early disease relapse. Multiparametric flow cytometry may be used for most patients, however, to be successfully applied, two concepts have emerged which should be carefully weighed up: to include only those leukaemia associated phenotypes that are absent in normal BM, respectively do not consider cases with less aberrant immunophenotypes for MRD monitoring. In most cases the phenotype at diagnosis is the same at relapse. But, this may be true for only a part of the leukaemic cells and the intensity of expression and aberrantly expressed antigens may change (Kern et al., 2008):

- Lymphoid antigen expression (e.g. CD33+/CD2+/CD34+, CD34+/CD13+/CD19+)
- Antigenic overexpression

- (e.g. HLA-DR++/CD33++/CD34++, CD64++/CD4++/CD45++)
- Lack of antigens (e.g. HLA-DR-/CD33+/CD34+)
- Asynchronous antigen expression (e.g. CD15+/CD33+/CD34+, CD65+/CD33+/CD34+)

3.7 Secondary acute myeloid leukaemia

Secondary AML is a poorly defined term that usually refers to the AML that develops after a history of myelodysplastic syndrome (MDS), myeloproliferative neoplasm or myelodysplastic/myeloproliferative neoplasm (MDS/MPN). The 2008 WHO classification defined the cases with a history of MDS or MDS/MPN and have evolved to AML, or cases that have a myelodysplasia-related cytogenetic abnormality, or at least 50% of cells in two or more myeloid lineages that are dysplastic as myelodysplasia-related changes. Some cases previously assigned to the subcategory of AML not otherwise specified as acute erythroid leukaemia or acute megakaryoblastic leukaemia may be reclassified as AML with myelodysplasia-related changes (Vardiman et al., 2009). Secondary AML may occur after chemotherapy with alkylating agents or topoisomerase II inhibitors, after radiation or exposure to environmental carcinogens. The 2008 WHO classification classifies cases after use of alkylating agents or topoisomerase II inhibitors as therapy-related myeloid neoplasms. The question is whether secondary AML itself is associated with poor prognosis or whether this is due to association with some morphological and biological characteristics. Dysplasia in de novo AML is related to unfavourable prognosis, but has no prognostic relevance under intensive therapy. Since there is no correlation between cytogenetic risk subgroups and dysplasia, cytogenetics continues to have proven impact in both de novo AML and secondary AML. Cytogenetic abnormalities spectrum in secondary AML is similar to de novo AML, but the frequency of unfavourable cytogenetic abnormalities associated with high risk and intermediate risk (complex karyotype, trisomy 8, monosomy 7 and others) is higher in secondary AML. Survival of patients with therapy-induced AML is shorter than those with de novo AML within the same cytogenetic risk group. Genetic and molecular differences that determine the phenotype and prognosis of secondary AML still require several additional studies (Larson, 2007).

3.8 Acute leukaemias of ambiguous lineage

According to WHO 2008, the classification encompasses the following entities:

- Acute undifferentiated leukaemia
- Mixed phenotype acute leukaemia with t(9;22)(q34;q11.2); *BCR-ABL1*
- Mixed phenotype acute leukaemia with t(v;11q23); *MLL* rearranged
- Mixed phenotype acute leukaemia, B-myeloid, NOS
- Mixed phenotype acute leukaemia, T-myeloid, NOS
- Provisional entity: natural killer (NK) cell lymphoblastic leukaemia/lymphoma:

This is a rare subtype of acute leukaemia, which is much debated. Although the nature of NK cells is questionable, is a variant of leukaemia with distinct morphological features and immunophenotype (blasts express CD56, CD2, CD7 and are negative for B or myeloid antigens). The cases previously classified as 'blastic natural killer cell leukaemia/lymphoma' are now 'myeloid related blastic plasmacytoid dendritic neoplasm' (Vardiman et al., 2009).

The requirements for assigning more than one lineage to a single blast population in mixed phenotype acute leukaemia (MPAL) are presented in Table 2.

For myeloid lineage	Myeloperoxidase (flow cytometry, immunohistochemistry or cytochemistry) or monocytic differentiation (at least two of the following: nonspecific esterase, CD11c, CD14, CD64, lysozyme)
For T lineage	Cytoplasmic CD3 (flow cytometry with antibodies to CD3 epsilon chain; immunohistochemistry using polyclonal anti-CD3 antibody may detect CD3 zeta chain which is not T cell-specific) or surface CD3 (rare in mixed phenotype acute leukaemia)
For B lineage (multiple antigens required)	Strong CD19 with at least one of the following strongly expressed: CD79a, cytoplasmic CD22, CD10 or weak CD19 with at least two of the following strongly expressed: CD79a, cytoplasmic CD22, CD10

Table 2. The requirements for assigning more than one lineage to a single blast population in mixed phenotype acute leukaemia (MPAL).

The former European Group of Immunological Markers for Leukaemia (EGIL) scoring system to evaluate biphenotypic acute leukaemia (BAL) had limitations because of over-diagnosis of BAL, plus it ignored the cytogenetic data. Because of this, well defined genetic abnormalities could be classified as BAL. The new classification includes cytogenetics in the evaluation of MPAL. A lot of studies showed that when applying the 2008 WHO classification the number of MPAL decreased (BAL became ALL with aberrant myeloid markers or AML with aberrant lymphoid markers). The pitfall still remains the over-diagnosis of MPAL, because of misinterpretation of immunological studies (e.g. immunophenotyping for MPO). Regarding MPO, it is preferable, if possible, to have both immunophenotyping and cytochemistry to consider it positive. Care must be taken, for example, not to consider as MPAL the patients with t(9;22) in blast crisis with former chronic myeloid leukaemia (CML). Cases of BCR-ABL1 positive and MLL positive acute leukaemias may meet the criteria for MPAL (Vardiman et al., 2009).

3.9 Cytogenetics

Compared with the 2001 WHO classification, the number of recognized recurrent genetic abnormalities has grown. The current 2008 WHO classification recognizes the importance of recurrent genetic abnormalities, which are crucial for correct diagnosis and treatment of AML:

- AML with t(8;21)(q22;q22); *RUNX1-RUNX1T1*
- AML with inv(16)(p13.1q22) or t(16;16)(p13.1;q22); *CBFB-MYH11*
- APL with t(15;17)(q22;q12); *PML-RARA*
- AML with t(9;11)(p22;q23); *MLLT3-MLL*
- AML with t(6;9)(p23;q34); *DEK-NUP214*
- AML with inv(3)(q21q26.2) or t(3;3)(q21;q26.2); *RPN1-EVI1*
- AML (megakaryoblastic) with t(1;22)(p13;q13); *RBM15-MKL1*
- Provisional entity: AML with mutated *NPM1*
- Provisional entity: AML with mutated *CEBPA*

The detection of recurrent genetic abnormalities requires cytogenetics - karyotyping, fluorescence in situ hybridization (FISH) and molecular analysis - reverse transcriptase polymerase chain reaction (RT-PCR).

The new classification is helpful for clinicians because data can provide more prognostic significance. Cytogenetics currently provides the most important prognostic information

both at diagnosis and at relapse. Given the progress made in recent years on understanding disease pathogenesis, given the profile of the genes, new therapeutic targets will develop, with the hope that this new agents potentially will improve the disease (Avivi & Rowe, 2005). Cytogenetic abnormalities have a frequency of 85% in de novo AML and 95-100% in secondary AML, consistent abnormalities being classified as specific (constant) and nonspecific (random). They can be balanced (translocations or chromosomal rearrangements) and unbalanced (chromosome loss or acquisitions). The specific, balanced abnormalities are present with a higher frequency in a given morphological FAB subtype. There are evidences for more than 80 balanced chromosomal rearrangements: [t(8:21) in AML2, inv16 in AML4 eosinophilic variant, t(9:11) in AML5, t(11:19) in AML4]. Constant unbalanced abnormalities (-7, -5) appear in all morphological subtypes. Some of these abnormalities are good prognostic factors [t(8; 21) (Q22, Q22 - fusion AML1-ETO), t(15; 17) (Q22, Q12 ~ 21 - fusion PML-RARA), inv (16)(p13q22) / t (16; 16) (p13; Q22 - CBFB-MYH11 fusion)], and others poor prognostic factors (5 -, 7 -, 5q-, 7q-, trisomy 8, trisomy 11, t (6, 9) or combinations). AML with t(8;21)(q22;q22); *RUNX1-RUNX1T1* is a common leukaemia usually associated with AML with maturation morphology and sometimes with myelomonocytic morphology. Auer rods are frequent. Eosinophilia and basophilia are common features. Displastic changes and association with myeloid sarcomas may also been seen. AML with inv(16)(p13.1q22) or t(16;16)(p13.1;q22); *CBFB-MYH11* may be associated with other cytogenetic abnormalities like trisomy 21, 8, loss or deletion of Y chromosome. It is associated with BM eosinophilia and lymphadenopathy. APL is one variant of AML associated with t(15;17). It is the retinoic acid receptor α gene (*RAR α*) that is affected. In acute promyelocytic leukaemia, the variant *RARA* translocations with other partner genes should be considered separately, because of different features and different responses to treatment. Generating chimerical fusion proteins from chromosomal translocations results in blocking cell differentiation and contributes to the biological characteristics of different subtypes of leukaemia, representing the primary event in the pathogenesis of AML. In recent years it has become clear that other mutations have a role in pathogenesis:

- Mutations of genes encoding transcription factors involved in haematopoiesis (often in AML1-M0, *CEPBA* - common in M1, M2)
- Mutations of genes that encode components of the signal translation pathways, mutations in the tyrosine kinase receptor (*FLT3* gene - confers proliferative advantage)
- Mutations in genes that encode nucleophosmin (*NPM1* - nucleocytoplasmatic protein involved in regulating gene expression - 35% of cases of AML) (Dohner et al., 2005; Falini et al., 2005; Schnittger et al., 2005)

Extensive studies have proposed a system of risk stratification based on cytogenetics in AML patients who fall into three risk categories: favourable, intermediate and poor. The information obtained from diagnosis is used to further stratify therapy. For patients with abnormal karyotype before treatment, cytogenetic analysis has been recommended to document complete remission (CR), based on data showing that the persistence of even a single metaphase with an abnormality present at diagnosis leads to significantly higher incidence of relapse (Cheson et al., 2003). Because multilineage dysplasia is not associated with independent prognostic significance when cytogenetics is taken into account, the 2008 WHO classification named this group 'AML with myelodysplasia-related changes'. The cytogenetic abnormalities sufficient for diagnosis of AML with myelodysplasia-related changes when 20% or more PB or BM blasts are present are shown in Table 3:

Complex karyotype	
Unbalanced abnormalities	Balanced abnormalities
-7 or del(7q)	t(11;16)(q23;p13.3)
-5 or	t(3;21)(q26.2;q22.1)
i(17q) or t(17p)	t(1;3)(p36.3;q21.1)
-13 or del(13q)	t(2;11)(p21;q23)
del (11q)	t(5;12)(q33;p12)
del (12p) or t(12p)	t(5;7)(q33;q11.2)
del(9q)	t(5;17)(q33;p13)
Idic(X)(q13)	t(5;10)(q33;q21)
	t(3;5)(q25;q34)

Table 3. Cytogenetic abnormalities sufficient for diagnosis of AML with myelodysplasia-related changes

Even if we have patients with therapy-related AML or with myelodysplasia-related changes, it is better to classify them according to their cytogenetic abnormalities. Still, because the outcome in patients with therapy related AML is worse than in those with de novo AML, it is important to correctly classify the therapy related AML, because it could bring important pathogenetic information and as it well known that not all patients taking such treatment develop AML (Vardiman at al., 2009).

As is known, patients with AML with normal karyotype are the largest group and are classified as intermediate risk. They should be analyzed for *FLT3*, *NPM1* and *CEBPA* mutations, and, if present, the abnormality should be noted in the diagnosis. *FLT3* gene encodes a member of the class III receptor tyrosine - kinase, which is expressed on the surface of haematopoietic progenitors from BM, with a role in the survival and differentiation of pluripotent stem cells. *FLT3* - ITD encodes a protein that causes abnormal activation and stimulates autophosphorylation of the receptor, activating the pathway below. Results of studies show the *FLT3*-ITD as a strongly independent negative prognostic factor influencing remission duration and survival in the group with normal karyotype, located in the intermediate cytogenetic risk group. Mutation is found in 28-33% of cases. Additional mutations that occur in the signal transduction molecules (receptor tyrosine kinase - c-kit and *FLT3*, *NRAS* and *KRAS*) are required to generate the disease. *FLT3* is overexpressed in most cases of AML and is mutated in approximately 35% of cases of AML. These mutations lead to activation of *FLT3* with activation of anti-apoptotic pathways. In addition, it activates MAPK (mitogen activated protein kinase), AKT and Stat5 (signalling molecules) leading to activation of Pim-1 (proto-oncogene which encodes a cytoplasmic serine - threonine kinase) and overexpression of Bcl-XL (protein inhibiting cell death and inhibiting caspase activation, thereby inhibiting apoptosis). Simultaneous blockage of both caspase pathways predict poor response to chemotherapy and is prognostic for decreased overall patient survival (Schimmer et al., 2003).

Nucleophosmin mutations have been reported in 46-62% of cases of AML with normal karyotype, as the most frequent gene alteration in this group of AML cytogenetics. *NPM1* mutations have been associated with pre-treatment characteristics such as female sex, higher percentage of blasts in MO, elevated levels of lactate dehydrogenase (LDH), increased number of leukocytes, platelets and low or absent expression of CD34 marker.

Approximately 40% of patients with NPM1 mutations also harbour FLT3-ITDs, which together with the tyrosine kinase domain mutations (FLT3-TKD), are twice as common in NPM1 positive patients as those with wild-type NPM1. CEBPA mutations occur with similar frequency in patients with and without NPM1 mutations. Many studies have shown that NPM1 mutation is associated with clinical outcome. Cytoplasmic localization of nucleophosmin is a favourable prognostic factor for achieving CR (Schnittger et al., 2005).

CEBPA mutations (enhancer binding protein - the gene encodes a myeloid transcription factor and plays an important role in normal granulopoiesis) were detected in 15-20% of cases of AML with normal karyotype. These cases, compared to wild-type mutation, have a higher percentage of blasts in peripheral blood and decreased numbers of platelets, but lymph and extramedullary involvement is much rarer and less likely to carry FLT3-ITD, FLT3-TKD and MLL-PTD. Regarding MLL, although the t(9;11)(p22;q23) is clearly named in the classification, it is recommended that variant *MLL* translocation also be specified in the diagnosis, for example, AML with t(11;19)(q23;p13.3); *MLL-ENL*. MLL-PTD should not be classified in this category (Gaidzik & Döhner, 2008; Marcucci et al., 2008; Mrózek et al., 2007; Vardiman et al., 2009). Cytogenetically normal AML with CEBPA mutations is associated with favourable prognosis. Some recent studies suggest that there is a heterogeneity among mutated CEBPA AML and just the cases with double, biallelic mutations have a favourable outcome (Barjesteh van Waalwijk van Doorn-Khosrovani et al., 2003; Fröhling et al., 2004; Preudhomme et al., 2002; Schlenk et al., 2008). The question of whether the presence of a FLT3-ITD has an impact on prognosis in patients with CEBPA mutations remains open (Renneville et al., 2009; Schlenk et al., 2008).

Down related AML harbour the same molecular abnormality - GATA1 mutation and also other features (clinical, morphological and immunophenotypical) and this was the reason for their separation in the myeloid proliferations related with the Down syndrome category.

4. Differential diagnosis

Regarding the distinction between subtypes of AML, the most important and with consequences for treatment is that between APL and other AML subtypes. APL, especially the hypogranular variant, may look like AML with monocytic differentiation. Leukaemic promonocytes often have Auer rods and are MPO strongly positive. The immunophenotype is different, leukaemic promonocytes being negative for CD34, HLA-DR and monocytic markers. AML with multilineage dysplasia must be distinguished from refractory anaemia with blasts excess (RAEB). The presence of 20% blasts in peripheral blood or BM makes the difference. In order to have the diagnosis of AML with multilineage dysplasia, patients must have 20% or more blasts in the PB or BM and evolve from previously MDS or MDS/MPN, specific myelodysplasia-related cytogenetic abnormalities (see Table 3), or present dysplasia in 50% or more of the cells in two or more myeloid lineages.

The differential diagnosis of acute megakaryoblastic leukaemia includes AML without differentiation, idiopathic myelofibrosis, acute panmyelosis with myelofibrosis and metastases of BM. The presence of Down syndrome, megakarioblasts in peripheral blood, the positivity of CD41, CD42 and CD61 pleads for the diagnosis of acute megakaryoblastic leukaemia. In acute panmyelosis with myelofibrosis, the blasts are of non megakaryocytic origin. Care must be taken in patients with hypoplastic and oligoblastic leukaemia when examining specimens of BM, where the diagnosis is made on the presence of $\geq 20\%$ blasts in the hypocellular marrow.

The difference between AML and ALL is easy to assess using immunophenotyping.

Chronic myeloid leukaemia (CML) in myeloid blast crisis can mimic AML, but the presence of the Philadelphia chromosome, splenomegaly and myeloid cells at all levels of differentiation distinguish CML from AML. Acute basophilic leukaemia is another entity to consider, knowing the characteristic basophilia. Care must be provided for example not to consider as MPAL the patients with t(9;22) in blast crisis with former CML. The 2008 WHO classification shows that there is the atypical CML category, that is *BCR-ABL1*-negative, and it is not a variant of CML, *BCR-ABL1*-positive. On the other hand, cases of *BCR-ABL1*-positive AML have been reported, but because it is difficult to distinguish it from CML in blastic crisis, the 2008 classification does not recognize it (Vardiman et al., 2009).

Leukaemoid reactions and nonleukaemic pancytopenia can be differentiated from AML because the blasts are missing in blood or BM. Sometimes in infections, such as tuberculosis, the proportion of blasts in the marrow may increase, but it does not reach the proportion of blasts required for a diagnosis of AML.

Pseudoleukaemia is a condition usually met after administration of granulocyte colony stimulating factor. Attentive observation of patients clarifies the problem, because in a short time the morphological appearance of BM will normalize. In the beginning it is manifested with severe leukopenia and usually normal thrombocytes.

Agranulocytosis is an acute condition involving severe leukopenia most commonly neutropenia in the circulating blood. The concentration of granulocytes falls below 100 cells/mm³ of blood. When infection and bleeding are present the diagnosis is more complicated. With examination of BM, a history of drug use helps in giving the correct diagnosis.

5. References

- Alioglu, B.; Avci, Z.; Ozcay, F.; Arda, S. & Ozbek, N. (2007). Neutropenic enterocolitis in children with acute leukemia or aplastic anemia. *Int J Hematol*, Vol.86, No.4, pp.364-368, ISSN 1865-3774
- Avivi, I. & Rowe, J.M. (2005). Prognostic factors in acute myeloid leukemia. *Curr Opin Hematol*, Vol.12, No.1, pp. 62-67, ISSN 1531-7048
- Bacărea, V.; Bacărea, A.; Călinici, T.; Mărușteri, M. & Petitot, C. (2007). Evaluarea unui test diagnostic. *Revista Română de Medicină de Laborator*, Vol.8, No.3, pp. 65-70, ISSN 1841-6624
- Bain, B.J.; Barnett, D.; Linch, D.; Matutes, E. & Reilly, J.T. (2002). Revised guideline on immunophenotyping in acute leukaemias and chronic lymphoproliferative disorders. *Clin Lab Haematol*, Vol. 24, no. 1, pp. 1-13, ISSN 1365-2257
- Barbaric, D.; Alonzo, T.A.; Gerbing, R.B.; Meshinchi, S.; Heerema, N.A.; Barnard, D.R.; Lange, B.J.; Woods, W.G.; Arceci, R.J. & Smith, F.O. (2007). Minimally differentiated acute myeloid leukemia (FAB AML-M0) is associated with an adverse outcome in children: a report from the Children's Oncology Group, studies CCG-2891 and CCG-2961. *Blood*, Vol.109, No.6, pp. 2314-2321, ISSN 1528-0020
- Barjesteh van Waalwijk van Doorn-Khosrovani, S.; Erpelinck, C.; Meijer, J.; van Oosterhoud, S.; van Putten, W.L.; Valk, P.J.; Berna Beverloo, H.; Tenen, D.G.; Löwenberg, B. & Delwel, R. (2003). Biallelic mutations in the CEBPA gene and low CEBPA expression levels as prognostic markers in intermediate-risk AML. *Hematol J.*, Vol. 4, No. 1, pp. 31-40, ISSN 1466-4860

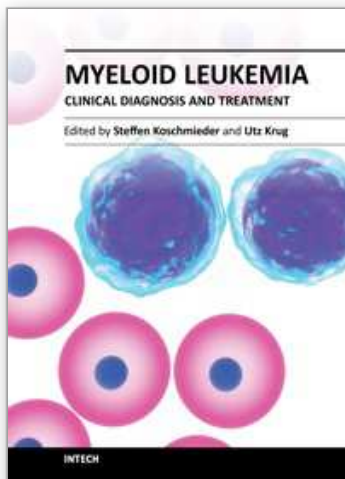
- Benderra, Z.; Faussat, A.M.; Sayada, L.; Perrot, J.Y.; Tang, R.; Chaoui, D.; Morjani, H.; Marzac, C.; Marie, J.P. & Legrand, O. (2005). BCRP, and P-Glycoprotein Activities are Prognostic Factors in Adult Acute Myeloid Leukemia. *Clin. Cancer Res*, Vol.11, No.21, pp. 7764-7772, ISSN 1557-3265
- Bene, M.C.; Castoldi, G.; Knapp, W.; Ludwig, W.D.; Matutes, E.; Orao, A. & van't Veer, M.B. European Group for the Immunological Characterization of Leukemias (EGIL) (1995). Proposals for the immunological classification of acute leukemias. *Leukemia*, Vol. 9, No. 10, pp. 1783-1786, ISSN 1476-5551
- Braham-Jmili, N.; Sendi-Senana, H.; Labiadh, S.; Ben Abdelali, R.; Ben Abdelaziz, A.; Khelif, A.; Saad, A. & Kortas, M. (2006). Haematological characteristics, FAB and WHO classification of 153 cases of myeloid acute leukaemia in Tunisia. *Ann Biol Clin*, Vol.64, No.5, pp. 457-465, ISSN 0003-3898
- Burns, C.P.; Armitage, J.O.; Frey, A.L.; Dick, F.R.; Jordan, J.E. & Woolson, R.F. (1981). Analysis of the presenting features of adult acute leukemia: the French-American-British classification. *Cancer*, Vol. 47, No. 10, pp. 2460-9, ISSN 1097-0142
- Casasnovas, R.O.; Slimane, F.K.; Garand, R.; Faure, G.C.; Campos, L.; Deneys, V.; Bernier, M.; Falkenrodt, A.; Lecalvez, G.; Maynadie', M. & Be'ne', M.C. (2003). Immunological classification of acute myeloblastic leukemias: relevance to patient outcome. *Leukemia*, Vol.17, No.13, pp. 515-527, ISSN 0887-6924
- Castagnola, C.; Morra, E.; Bernasconi, P.; Astori, C.; Santagostino, A. & Bernasconi, C. (1995). Acute myeloid leukemia and diabetes insipidus: Results in five patients. *Acta Haematol*, Vol.93, No.1. pp. 1-4, ISSN 1421-9662
- Cheson, B.D.; Bennett, J.M.; Kopecky, K.J.; Büchner, T.; Willman, C.L.; Estey, E.H.; Schiffer, C.A.; Doehner, H.; Tallman, M.S.; Lister, T.A.; Lo-Coco, F.; Willemze, R.; Biondi, A.; Hiddemann, W.; Larson, R.A.; Löwenberg, B.; Sanz, M.A.; Head, D.R.; Ohno, R. & Bloomfield, C.D. (2003). Revised recommendations of the International Working Group for Diagnosis, Standardization of Response Criteria, Treatment Outcomes, and Reporting Standards for Therapeutic Trials in Acute Myeloid Leukemia. *J Clin Oncol*, Vol.21, No.24, pp. 4642-4649, ISSN 1527-7755
- Craig, F.E. & Foon K.A. (2008). Flow cytometric immunophenotyping for hematologic neoplasms. *Blood*, Vol.111, pp. 3941-3967, prepublished online January 15, ISSN 1528-0020
- Dohner, K.; Schlenk, R.F.; Habdank, M.; Scholl, C.; Rücker, F.G.; Corbacioglu, A.; Bullinger, L.; Fröhling, S. & Döhner, H. (2005). Mutant nucleophosmin (NPM1) predicts favorable prognosis in younger adults with acute myeloid leukemia and normal cytogenetics – interaction with other gene mutation. *Blood*, Vol.106, No.12, pp. 3740-3746, ISSN 1528-0020
- Duchayne, E.; Ferneteau, O.; Pages, M.P.; Sainty, D.; Arnoulet, C.; Dastugue, N.; Garand, R. & Flandrin, G. (2003). Acute megakaryoblastic leukaemia: a national clinical and biological study of 53 adult and childhood cases by the Groupe Français d'Hématologie Cellulaire (GFHC). *Leuk Lymphoma*, Vol.44, No.1, pp. 49-58, ISSN 1029-2403
- Falini, B.; Mecucci, C.; Tiacci, E.; Alcalay, M.; Rosati, R.; Pasqualucci, L.; La Starza, R.; Diverio, D.; Colombo, E.; Santucci, A.; Bigerna, B.; Pacini, R.; Pucciarini, A.; Liso, A.; Vignetti, M.; Fazi, P.; Meani, N.; Pettirossi, V.; Saglio, G.; Mandelli, F.; Lo-Coco, F.; Pelicci, P.-D. & Martelli, M.F. (2005). Cytoplasmic nucleophosmin in acute myelogenous leukemia with normal karyotype. *N Engl J Med*, Vol.352, pp. 254-266, ISSN 0028-4793

- Fanci, R.; Leoni, F. & Longo, G. (2008). Nosocomial infections in acute leukemia: comparison between younger and elderly patients. *New Microbiol*, Vol.31, No.1, pp. 89-96, ISSN 1121-7138
- Ferrara, F. & Pinto, A. (2007). Acute Myeloid Leukemia in the Elderly: Current Therapeutic Results and Perspectives for Clinical Research. *Reviews on Recent Clinical Trials*, Vol.2, No.1, pp. 33-41, ISSN 18761038
- Foss, B. & Bruserud, O. (2008). Platelet functions and clinical effects in acute myelogenous leukaemia. *Thromb Haemost*, Vol.99, No.1, pp. 27-37, ISSN 0340-6245
- Fröhling, S.; Schlenk, R.F.; Stolze, I.; Bihlmayr, J.; Benner, A.; Kreitmeier, S.; Tobis, K.; Döhner, H. & Döhner, K. (2004). CEBPA mutations in younger adults with acute myeloid leukemia and normal cytogenetics: prognostic relevance and analysis of cooperating mutations. *J Clin Oncol.*, Vol. 22, No. 4, pp. 624-633, ISSN 1527-7755
- Gaidzik, V. & Döhner, K. Prognostic implications of gene mutations in acute myeloid leukemia with normal cytogenetics (2008). *Semin Oncol.*, Vol. 35, No. 4, pp. 346-55, ISSN 1532-8708
- Garcia, C.; Gardner, D. & Reichard, K.K. (2008). A Specific Immunohistochemical Marker for Acute Myeloid Leukemia With Monocytic Differentiation. *Applied Immunohistochemistry & Molecular Morphology*, Vol.16, No.5, pp. 417-421, ISSN 1062-3345
- Gladson, C.L. & Naeim, F. (1986) Hypocellular bone marrow with increased blasts. *Am J Hematol*, Vol. 21, No 1, pp. 15-22, ISSN 1096-8652
- Hämäläinen, S.; Kuittinen, T.; Matinlauri, I.; Nousiainen, T.; Koivula, I. & Jantunen, E. (2008). Neutropenic fever and severe sepsis in adult acute myeloid leukemia (AML) patients receiving intensive chemotherapy: Causes and consequences. *Leuk Lymphoma*, Vol.49, No.3, pp. 495-501, ISSN 1029-2403
- Hernández, J.A.; Navarro, J.T.; Rozman, M.; Ribera, J.M.; Rovira, M.; Bosch, M.A.; Fantova, M.J.; Mate, J.L & Millá, F. (2002). Primary myeloid sarcoma of the gynecologic tract: A report of two cases progressing to acute leukemia. *Leuk Lymphoma*, Vol.43, No.11, pp. 2151-2153, ISSN 1029-2403
- Hiddemann, W.; Kern, W.; Schoch, C.; Fonatsch, C.; Heinecke, A.; Woßmann, B. & Büchner, T. (1999). Management of Acute Myeloid Leukemia in Elderly Patients. *Journal of Clinical Oncology*, Vol.17, No.11, pp. 3569-3576, ISSN 1527-7755
- Hu, R.; Wu, Y.; Jiang, X.; Zhang, W. & Xu, L. (2011). Clinical symptoms and chemotherapy completion in elderly patients with newly diagnosed acute leukemia: a retrospective comparison study with a younger cohort. *BMC Cancer*, Vol.11, pp.224, ISSN 1471-2407
- Jain, N.C.; Cox, C. & Bennett, J.M. (1987). Auer rods in the acute myeloid leukemias: frequency and methods of demonstration. *Hematol Oncol.*, Vol.5, No 3, pp. 197-202, ISSN 1099-1069
- Kern, W.; Haferlach, C.; Haferlach, T. & Schnittger, S. (2008). Monitoring of minimal residual disease in acute myeloid leukemia. *Cancer*, Vol.112, pp. 4-16, ISSN 1097-0142
- Larson, R.A. (2007). Is secondary leukemia an independent poor prognostic factor in acute myeloid leukaemia?. *Best Pract Res Clin Haematol*, Vol.20, No.1, pp. 29-37, ISSN 1521-6926
- Lee, S.T.; Kim, H.J. & Kim, S.H. (2006). Defining an Optimal Number of Immunophenotypic Markers for Lineage Assignment of Acute Leukemias Based on the EGIL Scoring System. *Korean J Lab Med.*, Vol.26, No.6, pp. 393-399, ISSN 1598-6535
- Liesveld, J.L. & Lichtman, M.A. (2006). Acute Myelogenous leukemia, In: *Williams Hematology seventh edition*, Strauss, M.; Watt, M.; Edmonson, K.G. & Davis, K., pp. 1183-1236, McGraw-Hill Medical, ISBN 0-07-143591-3, United States of America

- Marcucci, G.; Maharry, K.; Radmacher, M.D.; Mrózek, K.; Vukosavljevic, T.; Paschka, P.; Whitman, S.P.; Langer, C.; Baldus, C.D.; Liu, C.G.; Ruppert, A.S.; Powell, B.L.; Carroll, A.J.; Caligiuri, M.A.; Kolitz, J.E.; Larson, R.A. & Bloomfield, C.D. (2008). Prognostic significance of, and gene and microRNA expression signatures associated with, CEBPA mutations in cytogenetically normal acute myeloid leukemia with high-risk molecular features: a Cancer and Leukemia Group B Study. *J Clin Oncol.*, Vol. 26, No. 31, pp. 5078-87, ISSN 1527-7755
- Masood, A. & Sallah, S. (2005). Chronic disseminated candidiasis in patients with acute leukemia: emphasis on diagnostic definition and treatment. *Leuk Res.*, Vol.29, No.5, pp. 493-501, ISSN 1873-5835
- Melchert, M. (2006). Managing Acute Myeloid Leukemia in the Elderly. *Oncology*, Vol.20, No.13, pp. 1674-1682, ISSN 0890-9091
- Montesinos, P.; Lorenzo, I.; Martín, G.; Sanz, J.; Pérez-Sirvent, M.L.; Martínez, D.; Ortí G.; Algarra, L.; Martínez, J.; Moscardó, F.; de la Rubia, J; Jarque, I.; Sanz, G. & Sanz, M.A. (2008). Tumor lysis syndrome in patients with acute myeloid leukemia: identification of risk factors and development of a predictive model. *Haematologica*, Vol.93, No.1, pp. 67-74, ISSN 1592-8721
- Mrózek, K.; Marcucci, G.; Paschka, P., Whitman, S.P. & Bloomfield, C.D. (2007). Clinical relevance of mutations and gene-expression changes in adult acute myeloid leukemia with normal cytogenetics: are we ready for a prognostically prioritized molecular classification?. *Blood*, Vol. 109, No. 2, pp. 431-448, ISSN
- Naeim, F. & Rao, P.N. (2008). Acute myeloid leukemia, In: *Hematopathology: Morphology, Immunophenotype, Cytogenetics, and Molecular Approaches*, Academic Press, 978-0-12-370607-2, China
- Okamoto, Y.; Ribeiro, R.C.; Srivastava, D.K.; Shenep, J.L.; Pui, C.H. & Razzouk, B.I. (2003). Viridans streptococcal sepsis: Clinical features and complications in childhood acute myeloid leukaemia. *Journal of pediatric hematology/oncology*, Vol.25, No.9, pp.696-703, ISSN 1536-3678
- Olaru, D.; Campos, L. ; Flandrin, P.; Nadal, N. ; Duval, A.; Chautard, S. & Guyotat, D. (2008). Multiparametric analysis of normal and postchemotherapy bone marrow: Implication for detection of leukemia – associated immunophenotypes. *Cytometry Part B (Clinical Cytometry)*, Vol.74B, pp. 17-24, ISSN 1552-4957
- Pagano, L.; Pulsoni, A.; Vignetti, M.; Tosti, M.E.; Falcucci, P.; Fazi, P.; Fianchi, L.; Levis, A.; Bosi, A.; Angelucci, E.; Bregni, M.; Gabbas, A.; Peta, A.; Coser, P.; Ricciuti, F.; Morselli, M.; Caira, M.; Foa, R.; Amadori, S; Mandelli, F. & Leone, G. (2005). Secondary acute myeloid leukaemia: results of conventional treatments. Experience of GIMEMA trials. *Annals of Oncology*, Vol.16, No.2, pp.228-233, ISSN 1569-8041
- Pațiu, M.; Bacărea, A.; Dascălu, A.; Norici, C. & Cucuianu, A. (2008) Sarcom mieloid – prezentare de caz si revizuirea datelor din literatura. *Proceedings of Revista română de medicină de laborator*, 2008 4th RAML Conference pp. 16-17, ISSN 1841-6624, Cluj-Napoca, Romania, 18 – 21 June 2008
- Plesa, C.; Chelghoum, Y. & Plesa, A.; Elhamri, M.; Tigaud, I.; Michallet, M.; Dumontet, C. & Thomas, X (2008). Prognostic value of immunophenotyping in elderly patients with acute myeloid leukemia: a single-institution experience. *Cancer*, Vol.112, No.3, pp. 572-80, ISSN 1097-0142
- Preudhomme, C.; Sagot, C.; Boissel, N.; Cayuela, J.M.; Tigaud, I.; de Botton, S.; Thomas, X.; Raffoux, E.; Lamandin, C.; Castaigne, S.; Fenaux, P. & Dombret, H. ALFA Group. (2002). Favorable prognostic significance of CEBPA mutations in patients with de

- novo acute myeloid leukemia: a study from the Acute Leukemia French Association (ALFA). *Blood*. Vol. 100, No. 8, pp. 2717-2723, ISSN 1528-0020
- Ratei, R.; Karawajew, L.; Lacombe, F.; Jagoda, K.; Del Poeta, G.; JKraan, J.; De Santiago, M.; Kappelmayer, J; Bjo'rkklund, E.; Ludwig, W-D.; Gratama, J.W & Orfao, A. (2007). Discriminant function analysis as decision support system for the diagnosis of acute leukemia with a minimal four color screening panel and multiparameter flow cytometry immunophenotyping. *Leukemia*, Vol.21, No.6, pp. 1204-1211, ISSN 0887-6924
- Rathnasabapathy, R. & Lancet, J.E. (2003). Management of Acute Myelogenous Leukemia in the Elderly. *Cancer Control*, Vol.10, No.6, pp. 469-477, ISSN 1073-2748
- Renneville, A.; Boissel, N.; Gachard, N.; Naguib, D.; Bastard, C.; de Botton, S.; Nibourel, O.; Pautas, C.; Reman, O.; Thomas, X.; Gardin, C.; Terré, C.; Castaigne, S.; Preudhomme, C. & Dombret, H. (2009). The favorable impact of CEBPA mutations in patients with acute myeloid leukemia is only observed in the absence of associated cytogenetic abnormalities and FLT3 internal duplication. *Blood*., Vol. 113, No. 21, pp. 5090-5093, ISSN 1528-0020
- Rothe, G. & Schmitz, G. for the Working Group on Flow Cytometry and Image Analysis. (1996). Consensus protocol for the flow cytometric immunophenotyping of hematopoietic malignancies. *Leukemia*, Vol. 10, No. 5, pp. 877-895, ISSN 1476-5551
- Schimmer, A.D.; Pedersen, I.M.; Kitada, S.; Eksioglu-Demiralp, E.; Minden, M.D.; Pinto, R.; Mah, K.; Andreeff, M.; Kim, Y.; Suk Suh, W. & Reed, J.C. (2003). Functional Blocks in Caspase Activation Pathways Are Common in Leukemia and Predict Patient Response to Induction Chemotherapy. *Cancer Research*, Vol.63, pp. 1242-1248, ISSN 1538-7445
- Schlenk, R.F.; Döhner, K.; Krauter, J.; Fröhling, S.; Corbacioglu, A.; Bullinger, L.; Habdank, M.; Späth, D.; Morgan, M.; Benner, A.; Schlegelberger, B.; Heil, G.; Ganser, A. & Döhner, H. German-Austrian Acute Myeloid Leukemia Study Group. (2008). Mutations and treatment outcome in cytogenetically normal acute myeloid leukemia. *N Engl J Med*. Vol. 358, No. 18, pp. 1909 -1918, ISSN 1533-4406
- Schnittger, S.; Schoch, C.; Kern, W.; Mecucci, C.; Tschulik, C.; Martelli, M.F.; Haferlach, T.; Hiddemann, W. & Falini, B. (2005). Nucleophosmin gene mutations are predictors of favorable prognosis in acute myelogenous leukemia with normal karyotype. *Blood*, Vol.106, No.12, pp.3733-3739, ISSN 1528-0020
- Schwonzen, M.; Diehl, V.; Dellanna, M. & Staib, P. (2007). Immunophenotyping of surface antigens in acute myeloid leukemia by flow cytometry after red blood cell lysis. *Leuk Res*. Vol.31, No1, pp. 113-116, ISSN 0145-2126
- Spoo, A.C.; Lübbert, M.; Werda, W.G. & Burger, J.A. (2007). CXCR4 is a prognostic marker in acute myelogenous leukemia. *Blood*, Vol.109, No.2, pp. 789-91, ISSN 1528-0020
- Stewart, C.C.; Behm, F.G.; Carey, J.L.; Cornbleet, J.; Duque, R.E.; Hudnall, S.D.; Hurtubise, P.E.; Loken, M.; Tubbs, R.R. & Wormsley, S. (1997). US-Canadian consensus recommendations on the immunophenotypic analysis of hematologic neoplasia by flow cytometry: selection of antibody combinations. *Cytometry*, Vol. 30, No. 5, pp. 231-235, ISSN 1097-0320
- Tallman, M.S. & Kwaan, H.C. (2004). Intravascular clotting activation and bleeding in patients with hematologic malignancies. *Rev Clin Exp Hematol*, Vol.8, No.1, pp. E1, ISSN 1127-0020
- Teng, C.L.; Young, J.H.; Hsu S.L.; Chou, G.; Kuo, I.T.; Yu, C.Y. & Hwang, G.Y. (2006). Lactate Dehydrogenase, not Vascular Endothelial Growth Factor or Basic Fibroblast Growth Factor, Positively Correlates to Bone Marrow Vascularity in Acute Myeloid Leukemia. *J Chin Med Assoc*, Vol. 69, No.11, pp. 534-537, ISSN 0143-8042

- Thalhammer-Scherrer, R.; Mitterbauer, G.; Simonitsch, I.; Jaeger, U.; Lechner, K.; Schneider, B.; Fonatsch, C. & Schwarzing, I. (2002). The immunophenotype of 325 adult acute leukemias. Relationship to morphologic and molecular classification and proposal for a minimal screening program highly predictive for lineage discrimination. *Am J Clin Pathol.*, Vol.117, pp. 380-389, ISSN 1943-7722
- Tsimberidou, A.M.; Kantarjian, H.M.; Estey, E.; Cortes, J.E; Verstovsek, S.; Faderl, S.; Thomas, D.A.; Garcia-Manero, G; Ferrajoli, A.; Manning, J.T.; Keating, M.J.; Albitar, M.; O'Brien, S. & Giles, F.J. (2003). Outcome in patients with nonleukaemic granulocytic sarcoma treated with chemotherapy with or without radiotherapy. *Leukemia*. Vol.17, pp. 1100-1103, ISSN 0887-6924
- Udayakumar, N.; Rajendiran, C. & Muthuselvan, R. (2006). A typical presentation of acute myeloid leukemia. *J Cancer Res Ther*, Vol. 2, No. 2, pp. 82-84, ISSN 1998-4138
- van Rhenen, A.; Moshaver, B.; Kelder, A.; Feller, N.; Nieuwint, A.W.; Zweegman, S.; Ossenkoppele, G.J. & Schuurhuis, G.J. (2007). Aberrant marker expression patterns on the CD34+CD38- stem cell compartment in acute myeloid leukemia allows to distinguish the malignant from the normal stem cell compartment both at diagnosis and in remission. *Leukemia*, Vol. 21, No. 8, pp. 1700-7, ISSN 1476-5551
- Vardiman, J.W.; Thiele, J.; Arber, D.A.; Brunning, R.D.; Borowitz, M.J.; Porwit, A.; Lee Harris, N.; Le Beau, M.M.; Hellström-Lindberg, E.; Tefferi A. & Bloomfield, C.D. (2009). The 2008 revision of the World Health Organization (WHO) classification of myeloid neoplasms and acute leukemia: rationale and important changes. *Blood*, Vol.114, No.5, pp. 937-951, ISSN 1528-0020
- Voskova, D.; Schnittger, S.; Schoch, C.; Haferlach, T. & Kern, W. (2007). Use of five-color staining improves the sensitivity of multiparameter flow cytometric assessment of minimal residual disease in patients with acute myeloid leukaemia. *Leuk Lymphoma*, Vol.48, No.1, pp. 80-88, ISSN 1029-2403
- Webb, D.K.H.; Harrison, G.; Stevens, R.F.; Gibson, B.G.; Hann, I.M. & Wheatley, K. (2001). Clinical observations, interventions and therapeutic trials, relationships between age at diagnosis, clinical features and outcome of therapy in children treated in the Medical Research Council AML 10 and 12 trials for acute myeloid leukemia. *Blood*, Vol.98, No.6, pp. 1714-1720, ISSN 1528-0020
- Woźniak, J. & Kopeć-Szlęzak, J. (2008). Standard immunophenotyping of leukemia cells in acute myeloid leukemia (AML). *Centr Eur J Immunol*, Vol.33, No.1, pp. 24-32, ISSN 1644-4124
- Zheng, J.; Wang, X.; Hu, Y.; Yang, J.; Liu, J.; He, Y.; Gong, Q.; Yao, J.; Li, X.; Du, W. & Huang, S. (2008). A correlation study of immunophenotypic, cytogenetic and clinical features of 180 AML patients in China. *Cytometry B Clin Cytom*, Vol.74, No.1, pp. 25-29, ISSN 1552-4957



Myeloid Leukemia - Clinical Diagnosis and Treatment

Edited by Dr Steffen Koschmieder

ISBN 978-953-307-886-1

Hard cover, 296 pages

Publisher InTech

Published online 05, January, 2012

Published in print edition January, 2012

This book comprises a series of chapters from experts in the field of diagnosis and treatment of myeloid leukemias from all over the world, including America, Europe, Africa and Asia. It contains both reviews on clinical aspects of acute (AML) and chronic myeloid leukemias (CML) and original publications covering specific clinical aspects of these important diseases. Covering the specifics of myeloid leukemia epidemiology, diagnosis, risk stratification and management by authors from different parts of the world, this book will be of interest to experienced hematologists as well as physicians in training and students from all around the globe.

How to reference

In order to correctly reference this scholarly work, feel free to copy and paste the following:

Anca Bacărea (2012). Diagnosis of Acute Myeloid Leukaemia, Myeloid Leukemia - Clinical Diagnosis and Treatment, Dr Steffen Koschmieder (Ed.), ISBN: 978-953-307-886-1, InTech, Available from: <http://www.intechopen.com/books/myeloid-leukemia-clinical-diagnosis-and-treatment/diagnosis-of-acute-myeloid-leukaemia>

INTECH
open science | open minds

InTech Europe

University Campus STeP Ri
Slavka Krautzeka 83/A
51000 Rijeka, Croatia
Phone: +385 (51) 770 447
Fax: +385 (51) 686 166
www.intechopen.com

InTech China

Unit 405, Office Block, Hotel Equatorial Shanghai
No.65, Yan An Road (West), Shanghai, 200040, China
中国上海市延安西路65号上海国际贵都大饭店办公楼405单元
Phone: +86-21-62489820
Fax: +86-21-62489821

© 2012 The Author(s). Licensee IntechOpen. This is an open access article distributed under the terms of the [Creative Commons Attribution 3.0 License](https://creativecommons.org/licenses/by/3.0/), which permits unrestricted use, distribution, and reproduction in any medium, provided the original work is properly cited.

IntechOpen

IntechOpen