

We are IntechOpen, the world's leading publisher of Open Access books Built by scientists, for scientists

6,900

Open access books available

185,000

International authors and editors

200M

Downloads

Our authors are among the

154

Countries delivered to

TOP 1%

most cited scientists

12.2%

Contributors from top 500 universities



WEB OF SCIENCE™

Selection of our books indexed in the Book Citation Index
in Web of Science™ Core Collection (BKCI)

Interested in publishing with us?
Contact book.department@intechopen.com

Numbers displayed above are based on latest data collected.
For more information visit www.intechopen.com



Current Endovascular Treatments for Venous Thrombosis

Glenn W. Stambo

*Vascular and Interventional Radiology
St. Josephs Hospital and Medical Center, Tampa
USA*

1. Introduction

Venous disease continues to increase in number of patients throughout the 2000's. With continued use of venous access devices, dialysis and cancer on the increase and overall patient sedentary life style, we will continue to see more and more venous disease in our population. Overall, venous disease is far more prevalent in the population than arterial disease. However, it is less diagnosed than arterial disease due in part too less acute symptomatology. Patients tend to present later in their disease process due to a multitude of factors including lack of debilitating symptoms, non-life threatening presentation and manageable discomfort until later stages.

Symptoms like gradual leg swelling in DVT patients, arm swelling in Dialysis fistulas and facial edema in superior vena cava (SVC) syndrome are slowly progressive until symptoms become debilitating. Even pulmonary emboli can be sub clinical with only non-specific findings like dyspnea and chest discomfort. Coumadin and the other low molecular weight heparin products are used as outpatient therapies in oral or injection preparations. These are adequate therapies for further prevention of clot formation and help resolve clots outside the hospital setting. However, weekly blood draws and side effects of these drugs particularly in the elderly can be significant and are potential reasons for multiple readmissions to the hospitals related to complications from bleeding.

2. Treatment options

The standard treatment for deep venous thrombosis and pulmonary is anti-coagulation embolism. Intravenous heparin is used in the acute hospital setting. Coumadin and the other low molecular weight heparin products are used as outpatient therapies.

For those patients with significant clot burden within peripheral or pulmonary embolism, endovenous therapies can be used if not candidates for anticoagulation. These patients present emergently with significant morbidity. In fact, acute extensive DVT of the lower extremity can cause severe peripheral vascular arterial emergency called Phlegmasia Cereulens Dolans. This disorder needs rapid clot lysis to dissolve the massive clot burden. Thus, only catheter directed thrombolysis could provide this direct form of endovenous therapy. Whether it is acute, semi acute or chronic venous occlusive process, endovenous therapies have become the first line of therapy. If left untreated or inadequately treated with conventional means, patients may develop post thrombotic syndrome.

Various areas may be treated within the venous distribution. The treatable areas include extremity veins, superior venacava, portal vein, inferior venacava, mesenteric veins, renal veins, and pulmonary veins. These cases present in various different clinical scenarios based on acuity and severity of symptoms. Extremity swelling, pain and positive Doppler duplex venous ultrasound are the typical presenting clinical picture. For other venous thromboses, more severe clinical sequela are evident in the setting of portal vein and mesenteric vein thromboses. If not treated quickly, these can present with severe bowel compromise requiring emergent surgery. Computed tomographic angiographic images usually confirm the findings. Massive pulmonary emboli can also present as cardiovascular collapse if not treated emergently. Various scenarios from life threatening entities to outpatient treatments can be approached with endovascular means.

3. Available devices

There are many devices now on the market to treat vascular thromboses and in particular venous thrombolysis. Various types of endovascular devices are now on the market for venous thrombolysis. These include the Unifuse and Speed-Lyser infusion catheters (Angiodynamics, Queensbury, New York), Possis AngioJet Ultra thrombectomy system (Medrad, Minneapolis, Minnesota), EKOS endowave endovascular system (EKOS Corporation, Bothell, WA), Trellis peripheral infusion system (Bacchus Vascular, Santa Clara, CA), Spectranetics Turbo Elite Laser Ablation catheter (Spectranetics, Colorado Springs, CO) and a pure aspiration catheter called the Pronto Extraction catheter (Vascular Solutions, Minneapolis, MN).

There are three different types of catheter systems. One catheter is just used for thrombolytic drug infusion (Speed-Lyser and Uni-Fuse). The second sets of catheter systems are combined devices using both mechanical and pharmacological thrombolysis (EKOS endowave, Possis angiojet, and Trellis thrombectomy) The third set of devices use only mechanical thrombectomy (Possis angiojet, Spectranetics laser ablation and Pronto extraction catheter).

4. Thrombolysis/Infusion catheters

These catheters systems are the original type for thrombolysis. The Uni fuse is a single catheter system with multiple side holes throughout its infusion length. (Fig 1) They infuse drug directly into the clot and allow the drug to act directly on the thrombus intraluminally. The catheters come in various sizes and lengths. The speed lyser catheter is unique short device with only 15 and 20cm lengths. This device is designed to be used during fistulalysis procedures for dialysis patients. Both catheter systems are excellent for clot dissolution due to their ease of use and ability to use any drug combination.

5. Combination mechanical and pharmacological thrombolysis catheters

These devices combine both mechanical dissolution and pharmacological thrombolysis to the clot. The devices include EKOS endowave system, Trellis peripheral infusion system and the Possis Angiojet system. The EKOS system is the newest of the devices. EKOS uses ultrasonic agitation of the clot with drug infusion to speed the clot lysis. This helps clear the large bulky clot typically seen in the venous system. (Fig 2) (Fig 3) The large clot burden in the legs and pulmonary arteries are ideal for this device. Theoretically, there is less drug used and less infusion time resulting in less intensive care monitoring and lessening the cost of the hospital stay. (Fig 4)

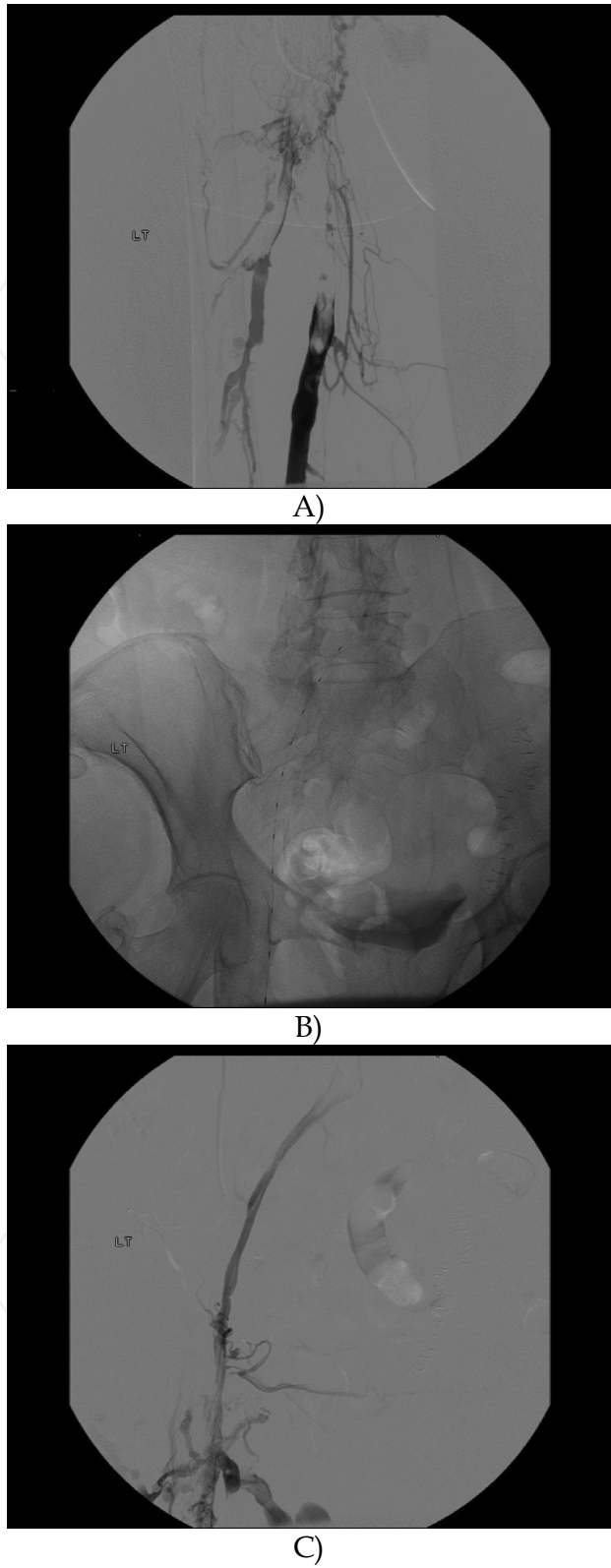


Fig. 1. 64 y/o female with left leg swelling and pain and a positive U/S for DVT A) Extensive DVT Left SFV extending into iliac system B) EKOS Endowave combination thrombolysis catheter in place with TNK infusion overnight C) Widely patent ilio-femoral venous system following thrombolysis

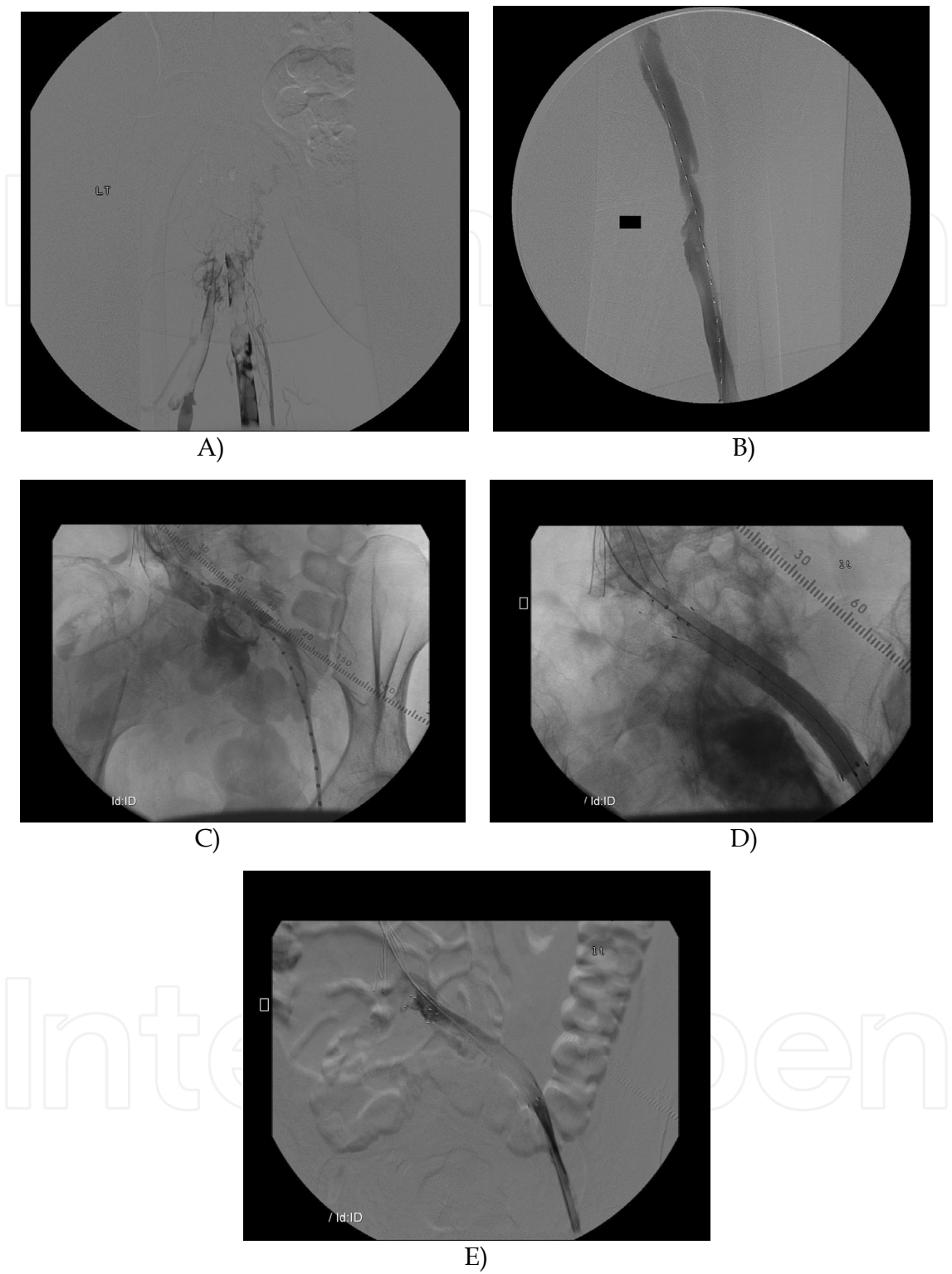
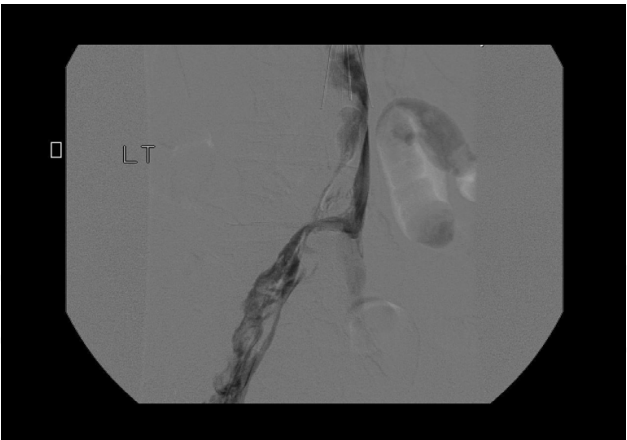
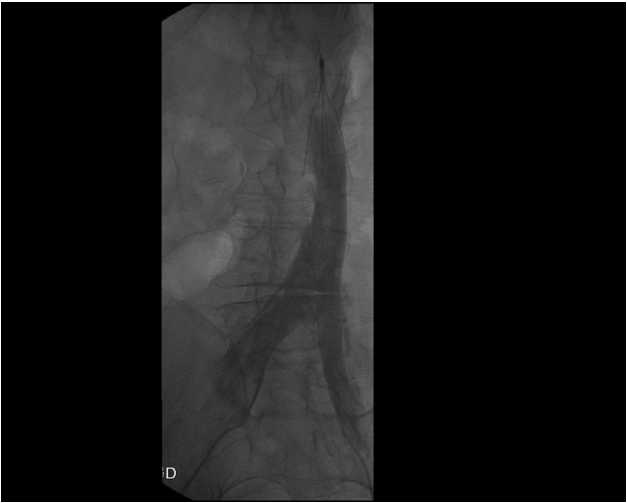

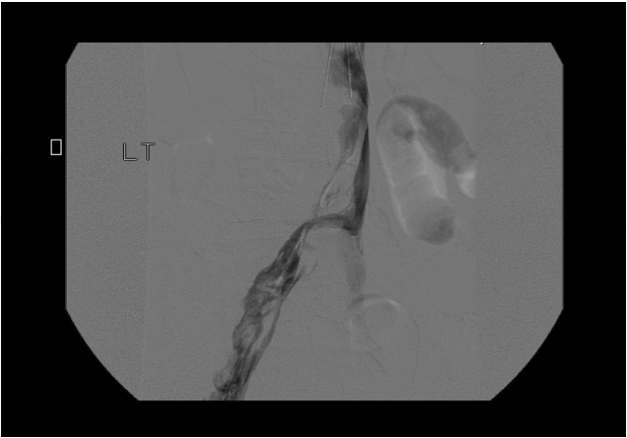Fig. 2. 39 y/o female with May-Thurner Syndrome presents with left leg swelling, pain and + DVT A) Extensive DVT left leg B) Pure thrombolytic therapy performed with Unifuse catheter system and TNK for overnight infusion C) Uncovered irregular stenosis Left iliac vein D) Balloon venoplasty performed with improved appearance but residual stenosis remains E) Iliac venous stent placed now with widely patent venous flow through iliac veins



A)



B)



C)

Fig. 3. 54 y/o male with bilateral leg DVT and ilio-caval DVT
A) Extensive ilio-caval thrombus B) and C) Kissing EKOS catheters placed simultaneously with TNK initiated for overnight infusion now with widely patent iliac veins and venacava on final images

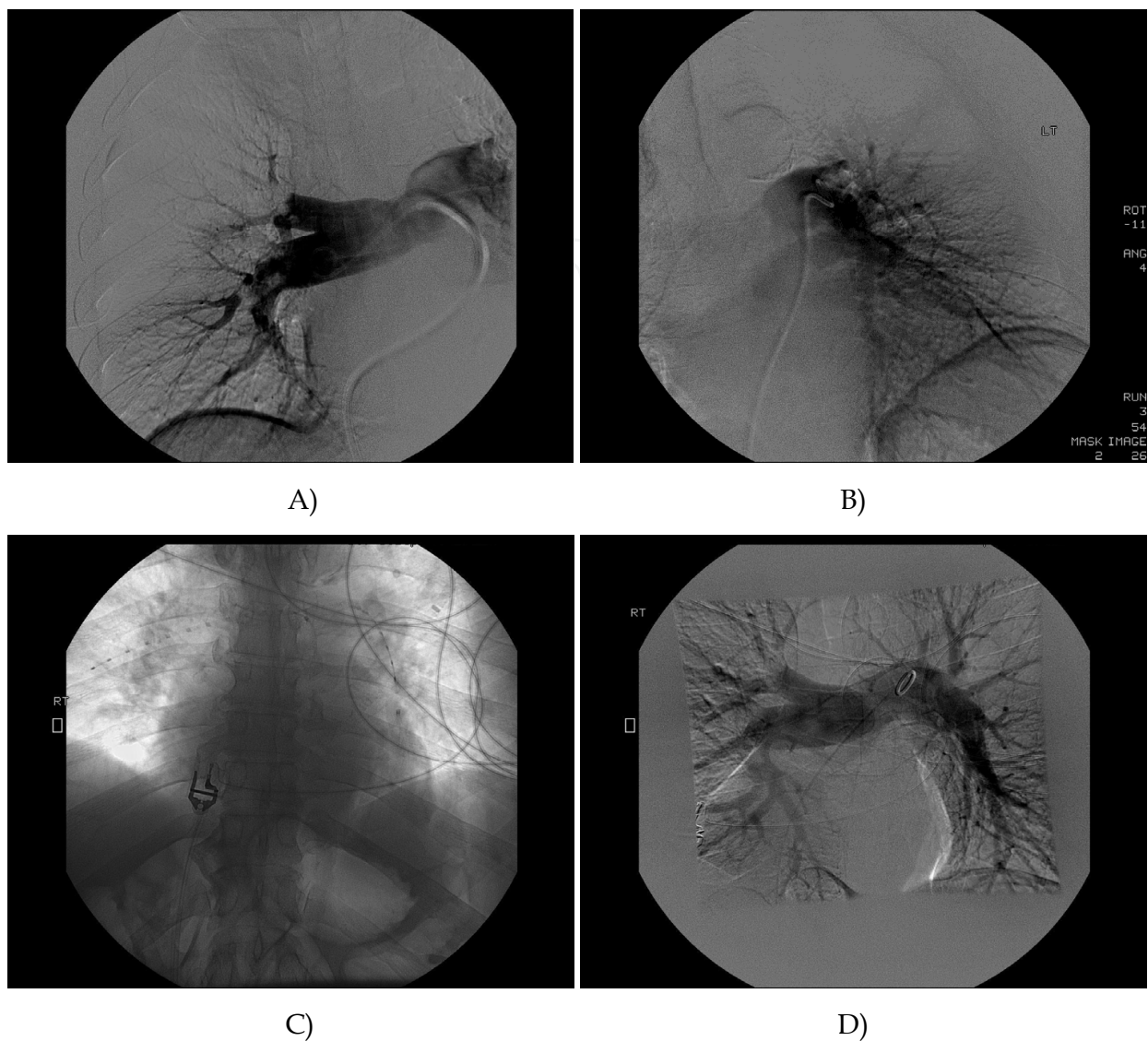
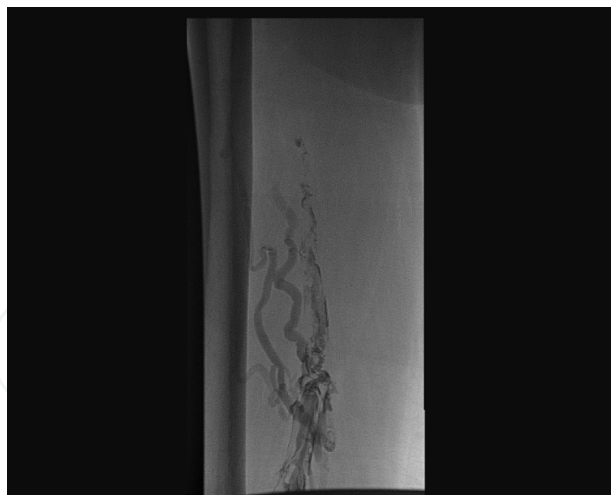

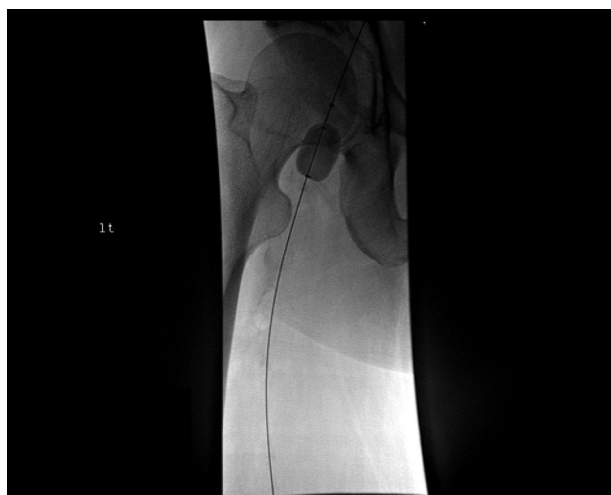Fig. 4. 71 y/o male with cardiopulmonary collapse/shock with bilateral pulmonary embolism A) and B) Bilateral extensive pulmonary embolism C) Bilateral simultaneous EKOS/TNK combination thrombolysis catheters in place D) Widely patent pulmonary arteries following 12 hour infusion

The Trellis device also combines mechanical and pharmacological thrombolysis. This device comes in various lengths and uses balloon occlusion technique to focus on the segmental clot burden. The “whip like” mechanical disruption breaks up the clot allowing the drug to act more effectively. (Fig 5) This is a useful device for isolated clot and can be performed as an outpatient with need for hospital admission.

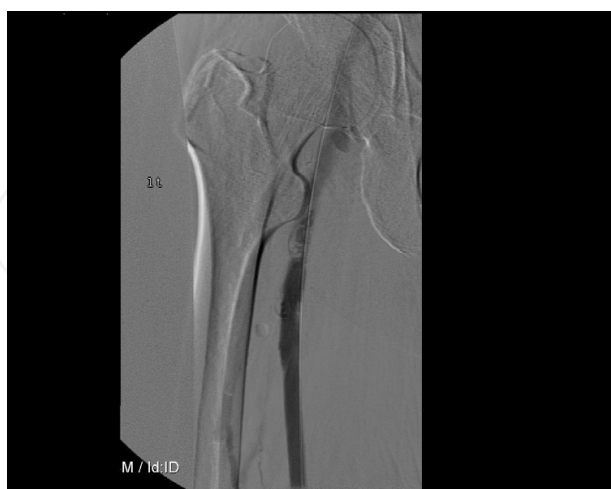The Possis AngioJet system can be both a pure mechanical and combination mechanical and pharmacological thrombolytic system. For combined systems, the Possis catheter is used in a “power pulse spray mode” where the thrombolytic drug is pulse sprayed directly into the clot. It is then allowed to sit in the vessel and dissolve the clot and then is removed by the standard angiojet thrombectomy fashion. This device can be used in many venous distributions with its various lengths and catheter treatment diameters. (Fig 6)



A)



B)



C)

Fig. 5. 59 y/o male with extensive DVT left leg swelling and pain
A) Extensive DVT identified B) Trellis thrombectomy device in SFV with balloon occlusion and mixed mechanical and pharmacological thrombolysis C) Marked improvement following Trellis device

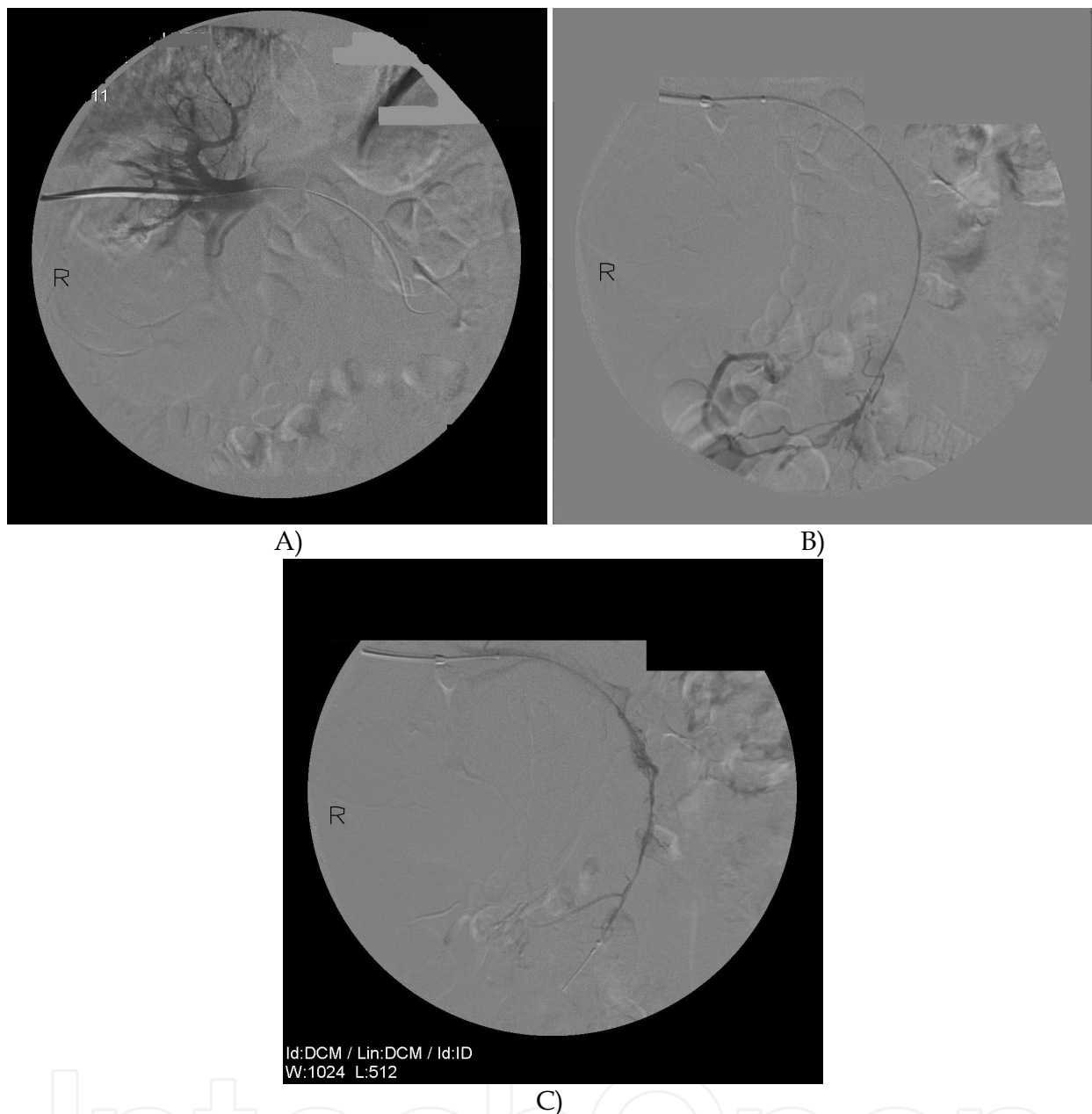


Fig. 6. 61 y/o male with chronic pancreatitis with portal vein thrombosis A) Extensive portal vein thrombosis as seen on this transhepatic portogram B) Power pulse spray possis angiojet and TPA thrombolysis of the portal vein C) Improved patency of portal vein

6. Pure mechanical devices

These devices require no thrombolytic agent to be infused into the vessel. The devices are the Possis angiojet catheter, Spectranectics laser catheter and Pronto extraction catheter. The Possis system uses saline jet through its distal side holes to create a Bernoulli effect thereby removing clot without need for drug therapy. (Fig 7) The Spectranectic device uses laser technology to vaporize the clot and thereby clear the vessel of clot quickly without chance of distal embolic phenomenon. They also come in various sizes for different vessel territories. This device can also be used as an outpatient without need for overnight stay.

The Pronto catheter (Pronto .035 extraction catheter, Vascular Solutions, Inc., Minneapolis, MN) is the newest pure mechanical device. Previously, developed from coronary interventions, it is now made for venous interventions. Pure aspiration catheters with large 8 French end hole-guiding catheters are used for cases with large clot burden such as massive pulmonary embolism and extensive deep venous thrombosis.

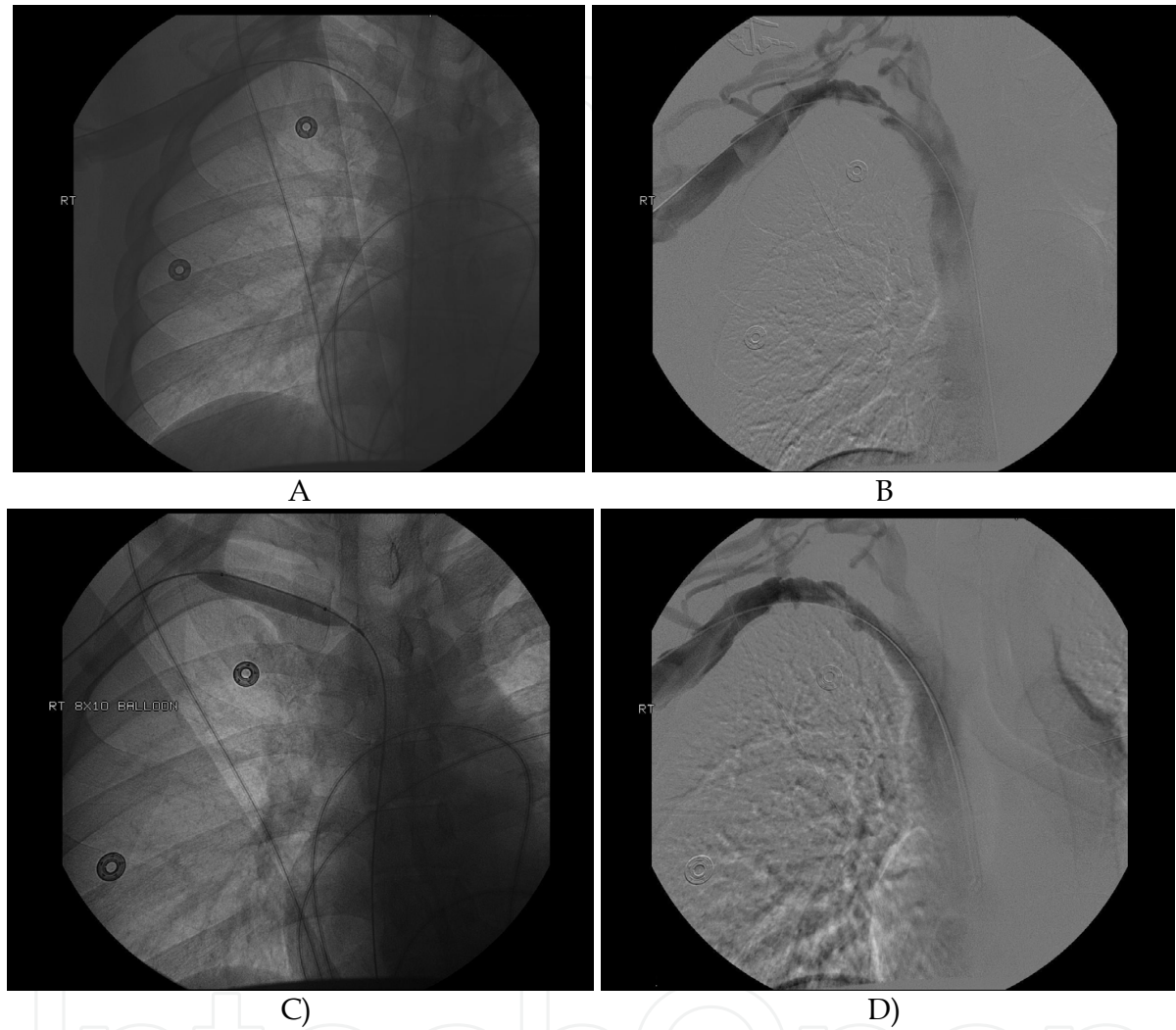


Fig. 7. 31 y/o body building male with dominant right arm swelling and pain c/w Paget Schroetter syndrome A) Possis angiojet pure thrombectomy device cleared clot from subclavian vein B) Uncovered focal irregular stenosis in subclavian vein which is worse with adduction arm motion C) Balloon Venoplasty of right subclavian vein D) Patent right subclavian vein with all degrees of motion the right arm on final images

7. Additional venous interventions

Following mechanical or pharmacological thrombolysis for acute venous thrombolysis, additional endovascular interventions are usually necessary. Whether, there are focal stenoses uncovered following intervention as in Paget Schroetter syndrome, May -Thurner syndrome or fistula anastomoses in dialysis graft, there is typically some element of recoil in the vein, fixed stenosis or some chronic residual thrombus. Further interventions are required involving balloon venoplasty, stent placement or filter placement.

8. Balloon venoplasty

Balloon venoplasty can be performed after the bulky thrombus has been removed uncovering an underlying venous stenosis. This can be treated with venoplasty to improve the diameter of the vessel thus improving its flow. It is the gold standard for venous stenosis in various distributions including subclavian, iliac or venacava corresponding to the various syndromes described previously. Typically, these interventions treat the underlying venous stenosis resulting in venous patency. The more central the venous stenosis, the better the result following venoplasty. Recurrent or residual venous stenosis following balloon venoplasty occurs frequently especially in those patients with chronic central venous catheters. Despite venoplasty, these venous lesions are very difficult to treat and recurrent venous stenosis may require stenting

9. Venous stenting

Stents can be used in any venous distribution from peripheral to central veins. Covered and uncovered metal stents can be used for recurrent stenosis. Central venous stenosis as in the SVC and IVC require the largest available stents. Covered stents and the newest Flair covered stent (CR Bard, Tempe, AZ) are now available for dialysis fistula anastomoses where by a smaller fistula graft enters into the larger native venous outflow resulting in a smooth transition and improve flow dynamics. Venous stenting can also be performed following suboptimal balloon venoplasty result. Venous stenting is not performed on thrombus alone but is used as an adjunct to suboptimal venoplasty and venous thrombolysis.

10. Thrombolytic agents

Activase (TPA) (Genenotech, South San Francisco, CA) and Tenecteplase (TNK) (Genenotech, South San Francisco, CA) are the most common thrombolytic agents currently available. These drugs are fibrinolytic agents which break down fibrin into split products thus allowing clot to lyse within the vascular system. In the veins, both work similarly but TNK seems to lyse clot faster with less bleeding complications due to its exquisite fibrin specificity. Tenecteplase is the newer of the two agents. It has a 14 fold higher fibrin binding specificity than TPA. Due to the larger volume of clot within veins, a larger dose of drug is necessary to lyse the clot burden. This is one of the reasons for combining mechanical with thrombolytic agents. With combination therapy, less drug can be used in these larger capacitance vessels if combined with one of the above-mentioned mechanical devices.

11. Dialysis Interventions

Dialysis fistulas grafts are increasing in number, as renal failure becomes an epidemic. Failure of these grafts is frequent and accounts for most of the morbidity associated with these grafts. Immediate graft malfunction due to surgical causes is quickly identified during placement. Acute thrombosis within these grafts can occur at any time following placement. This is a constant problem for nephrologists due to the nature of hemodialysis itself. Chronic needle punctures within the graft 3-4 times a week results in numerous chances for thrombus formation. Also, heparinization during hemodialysis and then reversing the

coagulation during and after dialysis catheter removal results in thrombosis of the graft. If unable to open the graft within a reasonable time, then other means of vascular access are required. Typically, another central venous dialysis catheter is needed until a new graft is created or the present one is cleaned out.

Interventional doctors are well adapted to lysis of dialysis graft using both pure pharmacological and mechanical thrombectomy. These grafts can be cleared of their thrombus burden in the interventional lab without requiring further surgery. Pure thrombolysis catheters like Speed Lyser delivers drug directly to the clot through multi-side holes via one micro catheter system. The drug is allowed to sit within the graft and dwell for a period of time called "lyse and wait" technique. Over this period of time, the clot is lysed and the graft is cleared of thrombus. TPA is used for this purpose. It can be injected directly into a graft. TPA can be given as a 6mg bolus within the dialysis grafts for this treatment. Following lysis, other interventions may be necessary to alleviate the source of the underlying graft malfunction.

12. Inferior venacava filter placement

Caval thrombosis can be acute or chronic. Filters can be used for the treatment of acute caval thrombosis, prophylaxis of pulmonary embolism and also be the source of caval thrombosis. Both treatment and cause of caval thrombosis makes interruption filters a double-edged sword. Either way, endovenous means are used exclusively for caval thrombosis.


Furthermore, most of the patients undergoing venous thrombolysis receive retrieval Inferior Vena Cava filter before the intervention. This is usually placed at the same setting. This idea is to reduce the risk of an iatrogenic fatal pulmonary embolism during the procedure. This filter can then be removed if indicated up to six months following implantation. Prior to removing the filter, a duplex venous ultrasound of the lower extremities is obtained to document clot resolution.

13. References

- Parikh S, Motarjeme A, McNamara T, Raabe R, Hagspiel K, Benenati J, Sterling K, Comerota A. "Ultrasound-accelerated Thrombolysis for the Treatment of Deep Vein Thrombosis: Initial Clinical Experience". *Journal of Vascular and Interventional Radiology*, 2008; 19(4) 521-528.
- Marchigiano G, Riendeau D, Morse CJ. "Thrombolysis of Acute Deep Vein Thrombosis". *Critical Care Nursing Quarterly*, 2006; 29:312-323.
- Chamsuddin A, Nazzal L, Kang B, Best I, Peters G, Panah S, Martin L, Lewis C, Zeinati C, Ho H, Venbrux A. "Catheter-directed Thrombolysis with the Endowave System in the Treatment of Acute Massive Pulmonary Embolism: A retrospective Multicenter Case Series". *Journal of Vascular and Interventional Radiology*, 2008; 19(3):372-376.
- Comerota AJ, Aldridge SE. Thrombolytic therapy for acute deep vein thrombosis. *Semin Vasc Surg* 1992;5:76-84.
- Plate G, Eklof B, Norgren L, et al. Venous thrombectomy for iliofemoral vein thrombosis – 10-year results of a prospective randomised study. *Eur J Vasc Endovasc Surg* 1997;14:367-374.

- Mewissen MW, Seabrook GR, Meissner MH, et al. Catheter-directed thrombolysis for lower extremity deep venous thrombosis: Report of a national multicenter registry. *Radiology* 1999;211:39-49.
- Comerota AJ, Throm RC, Mathias SD, et al. Catheter-directed thrombolysis for iliofemoral deep venous thrombosis improves health-related quality of life. *J Vasc Surg* 2000;32:130-137.
- Vedantham S, Vesely TM, Sicard GA, et al. Pharmacomechanical thrombolysis and early stent placement for iliofemoral deep vein thrombosis. *J Vasc Interv Radiol* 2004;15:565-574.
- Stambo GW, Montague B. Bilateral EKOS(R) EndoWave(TM) Catheter Thrombolysis of Acute Bilateral Pulmonary Embolism in a Hemodynamically Unstable Patient. *Southern Medical Journal*: May 2010 - Volume 103 - Issue 5 - pp 455-457

IntechOpen



Venous Thrombosis - Principles and Practice

Edited by Dr. Ertugrul Okuyan

ISBN 978-953-307-885-4

Hard cover, 232 pages

Publisher InTech

Published online 05, January, 2012

Published in print edition January, 2012

According to Virchow's triad, venous thrombosis can occur as a result of one or more of three factors: changes in the dynamics of the blood flow, endothelial injury/dysfunction of the blood vessel and hypercoagulability. The blood in the veins is constantly forming microscopic thrombi that are routinely broken down by the body, and significant clotting can occur only when the balance of thrombus formation and resolution is altered. This book is a fresh synthesis of venous thromboembolism care and considers the opinions and studies from different fields of medicine. As venous thrombosis spectrum is wide and can affect many organ systems, from deep veins of the leg to the cerebral venous system, our intent is for this to be a comprehensive, up-to-date and readable book. We tried to present a synthesis of existing material infused with new ideas and perspectives and authors own clinical studies and even case-reports.

How to reference

In order to correctly reference this scholarly work, feel free to copy and paste the following:

Glenn W. Stambo (2012). Current Endovascular Treatments for Venous Thrombosis, Venous Thrombosis - Principles and Practice, Dr. Ertugrul Okuyan (Ed.), ISBN: 978-953-307-885-4, InTech, Available from: <http://www.intechopen.com/books/venous-thrombosis-principles-and-practice/current-endovascular-treatments-for-venous-thrombosis>

INTech
open science | open minds

InTech Europe

University Campus STeP Ri
Slavka Krautzeka 83/A
51000 Rijeka, Croatia
Phone: +385 (51) 770 447
Fax: +385 (51) 686 166
www.intechopen.com

InTech China

Unit 405, Office Block, Hotel Equatorial Shanghai
No.65, Yan An Road (West), Shanghai, 200040, China
中国上海市延安西路65号上海国际贵都大饭店办公楼405单元
Phone: +86-21-62489820
Fax: +86-21-62489821

© 2012 The Author(s). Licensee IntechOpen. This is an open access article distributed under the terms of the [Creative Commons Attribution 3.0 License](https://creativecommons.org/licenses/by/3.0/), which permits unrestricted use, distribution, and reproduction in any medium, provided the original work is properly cited.

IntechOpen

IntechOpen