

We are IntechOpen, the world's leading publisher of Open Access books Built by scientists, for scientists

6,900

Open access books available

185,000

International authors and editors

200M

Downloads

Our authors are among the

154

Countries delivered to

TOP 1%

most cited scientists

12.2%

Contributors from top 500 universities



WEB OF SCIENCE™

Selection of our books indexed in the Book Citation Index
in Web of Science™ Core Collection (BKCI)

Interested in publishing with us?
Contact book.department@intechopen.com

Numbers displayed above are based on latest data collected.
For more information visit www.intechopen.com



Venous Thrombosis in Behcet's Disease

Selda Pelin Kartal Durmazlar

*Department of Dermatology, Ministry of Health Ankara Diskapi
Yildirim Beyazit Education and Research Hospital, Ankara,
Turkey*

1. Introduction

Behcet's Disease (BD) is manifested by a triad of relapsing hypopyon uveitis, aphthous stomatitis and genital ulcers. The disease initially described by a Turkish dermatologist Hulusi Behcet in 1937. The etiology and pathogenesis of Behcet's disease have not been fully clarified yet. However, it is now recognized as a multisystemic, immunoinflammatory disorder involving vessels of all sizes. The disease is most prevalent in the Mediterranean countries, Middle East, and Japan but has a worldwide distribution (Durmazlar et al., 2009; Kartal Durmazlar et al., 2008a).

2. History and diagnosis

The disease, currently known all over the world as "Behcet disease", "Behcet syndrome", "Behcet's triad", "Morbus Behcet" or "Tri-symptom Behcet" was first recognized by Dr. Hulusi Behcet (1889-1948) with a patient in 1924 (Tuzun, 2006; Ustun, 2002; Kartal Durmazlar & Kandi, 2011). This patient, who had been examined because of eye disturbances, recurrent oral and genital ulcers both in Istanbul and Vienna for 40 years, was given several diagnoses. Some doctors thought of tuberculosis or syphilis while some other doctors said a microorganism which was not present in Europe might have caused the disease. Hulusi Behcet, who continued to examine the patient after his loss of vision, thought that the causative agent was a virus. In the next several years he met two more patients with similar to that was seen in the previous patient. Hulusi Behcet thought the symptoms of these three patients were the symptoms of a new disease and reported his ideas on this topic firstly in 1936, in the Journal of Skin and Venereal Diseases (Tuzun, 2006; Ustun, 2002; Kartal Durmazlar & Kandi, 2011; Saylan, 1997). Later, in 1937 he wrote clear examples of symptomatic triad, which are still used as criterias worldwide for diagnosis of Behcet's disease, in Dermatologische Wochenschrift. In the same year at the meeting of the Society of Paris Dermatology he declared that several factors may cause the etiology of the disease, which still can be an acceptable statement. Later he diagnosed further patients and published in German as "Tri-Symptomenkomplex" in 1939, and in English as "Triple symptom complex" in 1940 (Tuzun, 2006; Ustun, 2002; Kartal Durmazlar & Kandi, 2011; Saylan, 1997; Evereklioglu, 2006). In subsequent years, this unique disorder drew the attention, and the term "Behcet syndrome" was first used by Jensen in 1941 (Jensen, 1941). The term "Behcet disease" was first used by Fiegenbaum and Kornblueth in 1946 (Kartal Durmazlar & Kandi, 2011; Fiegenbaum, 1946; Dilsen, 1996; Alpsoy, 2009). On 13 September

1947, international dermatologic societies came together in Zurich and named the disease as “Morbus Behçet”, which honored the first describer of “triple symptom complex” after Zurich Medical Faculty Professor Mischner’s proposal. In fact, several authors before Hulusi Behçet described one or several individual findings of this disorder. Among these physicians, for example, Hippocrates in the fifth century BC reported some individual symptoms attributed to an originally endemic and epidemic disease. But, due to sporadic appearance of the disease in the course of time, the disease became less significant and was forgotten. There were also other physicians who described one or several individual findings of this disorder, for example, Janin (1772), Reis (1906), Blüthe (1908), Gilbert (1920, 1921, 1923), Planner and Remenowsky (1922), Weve (1923), Shigeta (1924), Adamantiades (1930), Dascalopoulos (1932), Whitwell (1934), Nishimura (1936), Blobner (1937) reported several individual findings of this disorder. However, all these papers ascribed the findings either to another disease, such as tuberculosis, syphilis, sepsis or allergy, or to a coincidence and none of them indicated a new or a single syndrome with “classical triad” (Kartal Durmazlar & Kandi, 2011; Alpsoy 2009; Evereklioglu, 2006, 2007a, 2007b, 2007c; Freigenbaum, 1956). The disease is sometimes named as Adamantiades-Behcet’s disease, however, Behcet’s disease should be preferred as suggested by International Associations and Societies of “Behcet” (Mendes et al., 2009).

Several diagnostic criteria have been developed during the years, all have in common the 3 major features of oral ulceration, genital ulceration and eye lesion (16). Today, International Study Group criteria for the diagnosis of Behcet’s disease is used worldwide (Table 1) (International Study Group diagnostic criteria, 1990.).

Recurrent oral ulceration	Minor aphthous, major aphthous, or herpetiform ulceration observed by physician or patient recurring at least three times in one 12-month period Plus any two of the following:
Recurrent genital ulceration	Aphthous ulceration or scarring, observed by physician or patient
Eye lesions	Anterior uveitis, posterior uveitis, cells in the vitreous on slit-lamp examination; or retinal vasculitis observed by ophthalmologist
Skin lesions	Erythema nodosum observed by the physician or patient, pseudofolliculitis, papulopustular lesions; or acneiform nodules observed by physician in post adolescent patients not on corticosteroids treatment
Pathergy	Read by physician at 24-48 hours (The test is performed by introducing a 20-gauge or smaller sterile needle 5 mm obliquely into the patient’s flexor aspect of the avascular forearm skin without injection of saline under sterile conditions. The test is considered positive if there is an indurated erythematous small papule or pustule formation of more than 2 mm in diameter.

*Findings applicable only in the absence of other clinical explanations

Table 1. International Study Group diagnostic criteria, 1990.

As a systemic disease, Behcet’s disease involves visceral organs also such as the gastrointestinal tract, pulmonary, musculoskeletal, and neurological systems (Table 2) (Evereklioglu, 2005).

Manifestations	Characteristics
Articular manifestations	Non-migratory monoarthritis or oligoarthritis, rarely polyarthritis, characterized by non-specific inflammatory-type synovitis. Favors large joints such as the knee (most commonly), ankle, wrist, and elbow as well as proximal interphalangeal and metacarpophalangeal joints. Spinal and sacroiliac involvements are uncommon. <i>Symptoms and signs:</i> arthralgia, tenderness, swelling, limitation of joint movement, warmth, morning stiffness, and redness at the articular site
Audio-vestibular features	Inner ear involvement cochlear and peripheral vestibular disturbances, tinnitus, deafness, dizziness, unilateral or bilateral sensorineural hearing, orthostatic disequilibrium
Thoracic involvement	Aorta and pulmonary artery aneurysms, infarct and hemorrhage, pleural effusion, pulmonary thromboembolism, tracheobronchial ulcerations, pneumonitis, mediastinitis, paranchymal fibrosis, arteriobronchial fistula, cor pulmonale, hilar and mediastinal lymphadenopathy, and lobular perfusion defects. <i>Symptoms:</i> hemoptysis, cough, dyspnea, and pleuritic chest pain
GIS involvement	Ulcerative lesions especially terminal ileum, cecum, occasionally in esophagus and stomach. <i>Symptoms:</i> anorexia, dysphagia, dyspepsia, vomiting, flatulence, vague abdominal discomfort, distention and pain, bloating, and diarrhea. Perforation can occur and malabsorbtion is common
Vascular involvement	Superficial and deep obliterative thrombophlebitis in lower extremity, varices, embolization, infarction, bleeding ulcers. Veins are affected more frequently than arteries. Large vessel thromboses in superior and inferior vena cava with a caput medusa, deep femoral and subclavian veins can occur. Occasionally, aorta, carotid, and popliteal aneurysms, radial artery occlusion, and thromboses of the hepatic (Budd-Chiari syndrome), mesenteric, pulmonary, iliac and renal veins with intracranial hypertension, mesenteric artery aneurysm
Cardiac involvement	Coronary artery disease, myocardial infarction, endocarditis, myocarditis, pericarditis, aortitis, valvular disease (aortic/mitral regurgitation), intracardiac thrombus, endomyocardial fibrosis, arrhythmia
Renal involvement	Microscopic hematuria and proteinuria (microalbuminuria) with normal renal functions, or rapidly progressive anti-neutrophylic antibody-associated vasculitis, cresentic or proliferative glomerulonephritis (focal segmental or sclerosing, diffuse or mesangial), IgA nephritis, renal vein thrombosis, amyloidosis, nephrotic syndrome, renal failure

Genitourinary involvement	Inflammation of the testis, typically epididymitis with painful swelling or uncommonly orchiepididymitis, urethritis, cystitis, voiding dysfunction
CNS involvement	5–10% of patients are affected. Focal or multifocal parenchymal , peripheral or CNS involvement with both motor and sensory manifestations, migraine-like headache (most frequent initial sign), hemiparesis, behavioral changes, stiff neck, pyramidal and extrapyramidal signs, cerebellar ataxia, cerebral vein thrombosis, isolated cerebral sinus thrombosis, cranial nerve palsies, peripheral neuropathy, seizures, benign intracranial hypertension, life-threatening brainstem and spinal cord lesions, aseptic meningitis, chronic meningoencephalitis, multiple sclerosis-like illness, organic confusional syndrome, acute myelitis, aneurysms, stroke, and pseudo-tumor cerebri.
Psychosomatic status	Character disorders, aggressiveness, anxiety, depression, dementia, cognitive deficits, memory disturbances, impairment in acquisition/information storage, personality change, attention deficit, bipolar disorder, and chorea

CNS _ central nervous system; GIS _ gastrointestinal system.

Table 2. Additional Systemic Features of Behcet Disease (From Evereklioglu, 2005).

3. Vascular involvement in Behcet’s disease

Vasculo-Behcet Disease (VBD), which involves the arterial and venous system, is found in 15-38% of patients with BD. Three major manifestations of VBD have been identified: venous occlusion, arterial occlusion and aneurysm formation, with a clear preponderance of the venous lesions compared to arterial involvement. The coexistence of arterial and venous involvement is not frequent and is one of the major causes of morbidity and mortality. Venous involvement, including superficial thrombophlebitis and deep venous thrombosis, is a characteristic manifestation. Thrombosis of superficial and deep vein is more frequent than arterial aneurism and thrombotic occlusions (Kartal Durmazlar et al., 2008a, 2009; Houman et al., 2001; Aksoy et al., 2010). Venous thrombosis appeared to be the major vascular involvement reported in 7 to 33% of cases with BD with a male predominance, and representing 85 to 93% of VBD (Houman et al., 2001). Deep vein thrombosis is seen in about one-fifth of Turkish patients with BD (Gul et al., 1999). Lower extremities is the most frequent site of thromboses but thromboses of other venous sites such as superior and inferior vena cava, coronary, portal, renal and pulmonary veins have been identified (Houman et al., 2001; La Regina et al., 2010). Leg ulcers in BD, which may be caused by vasculitis or deep vein thrombosis, have a chronic recurrent course and are refractory to treatment (Jung et al., 2008; Kartal Durmazlar et al, 2008b; Akgul & Kartal Durmazlar, 2008).

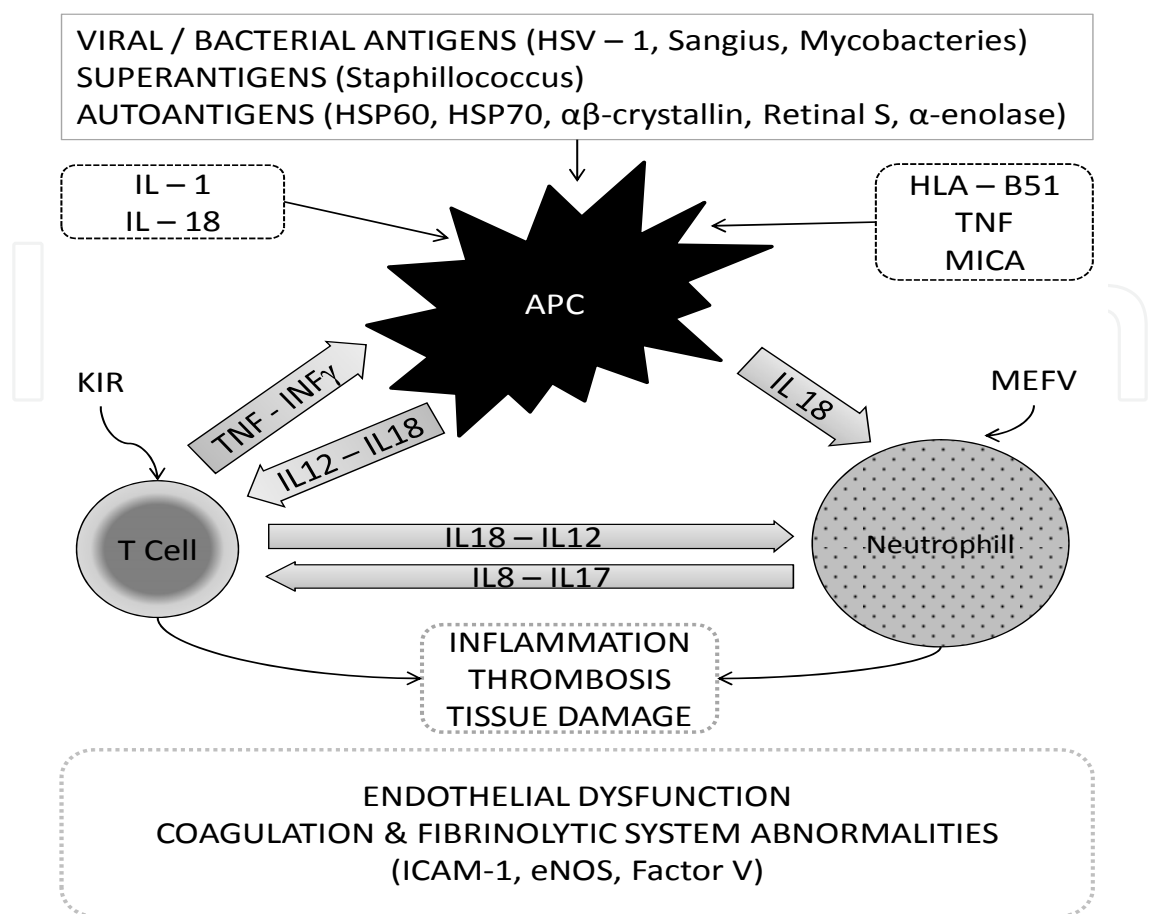
4. Pathogenesis of Behcet’s disease and thrombosis

The main pathology in BD is an inflammatory process of small arteries and veins and thrombosis as a result of vasculitis of the vaso vasorum (Evereklioglu et al., 2002).

Histopathological studies revealed cellular infiltrations consisting of lymphocytes, plasmocytes, monocytes and PMN in varying degrees, depending on the stage of lesion in BD. Since cytokines are involved in the regulation of functions of lymphocytes and phagocytes, they are playing important role in the pathogenesis of the disease (Durmazlar et al, 2009). Chemotactic and phagocytic activity of neutrophils in patients with BD has been reported to be high (19). Increased spontaneous secretion of Tumor necrotizing factor (TNF- α), Interleukin-6 (IL-6) and Interleukin-8 (IL-8) in monocyte cultures obtained from BD patients have been reported (Mege et al., 1993). IL-8 secretion after incubation of human dermal microvascular endothelial cells with serum of BD patients indicates that chemotaxis is an initial process of inflammation. IL-8 upregulates neutrophil chemotaxis as mRNA expression have been reported to be more prominent in patients with active BD than in patients with inactive disease (Evereklioglu, 2005). IL-8, a major chemokine known as neutrophil activating factor, attract and activate leukocytes has been assumed to represent such a notable link between immune system activation and endothelial alterations in BD (Durmazlar et al., 2009; Evereklioglu, 2005; Tursen, 2009). It has been suggested that Th1 type cytokines and chemokines including IL-17, largely produced by activated CD4⁺ and CD8⁺ T cells, are involved in the recruitment of neutrophils to the site of inflammation. Activated neutrophils in BD patients produce significant quantities of IL-12 and IL-18 (Pay et al., 2007).

The pathogenesis of thrombotic events in BD is not fully understood. The primary abnormalities of the coagulation, anticoagulation, or fibrinolytic systems have not been confirmed yet in BD. The main factor responsible for the increased frequency of thrombosis in BD is thought to be endothelial dysfunction caused by vascular inflammation (Evereklioglu, 2005). There is accumulating evidence for inflammation markers as a result of thrombosis. Deep vein thrombosis significantly associates with the male gender and a positive pathergy test (Houman et al., 2001). A number of studies have explored the pathogenesis of thrombophilia in Behcet's disease. Neither deficiency in protein C, in protein S, in factor V Leiden and in antithrombin III nor resistance to activated protein C and anticardiolipin antibody levels seem to be correlated with vascular thrombosis in Behcet's disease (Houman et al., 2001; Espinosa et al., 2002; Hirohata & Kikuchi, 2003). In BD, there is an occlusive inflammatory thrombus formation, strictly adherent to inflamed vessel wall, which is typically not complicated with thromboembolism (Lakhanpal et al., 1985; Kobayashi et al., 2000; Matsumoto et al., 1991). There are increased thrombin generation, fibrinolysis, and thrombomodulin in Behcet's disease, but these abnormalities are not related to thrombosis (Espinosa et al., 2002). These results therefore suggest that thrombophilia in Behcet's disease may be related more to inflammation than to clotting disorder (Hirohata & Kikuchi, 2003). Studies have disclosed the occurrence of antiendothelial cell antibodies, increased E-selectin and myeloperoxidase expression in Behcet's disease (Houman et al., 2001; Espinosa et al., 2002; Hirohata & Kikuchi, 2003). As neutrophils from active Behcet's disease release increased amounts of myeloperoxidase, it is probable that neutrophil activation as well as the expression of antiendothelial cell antibodies may play an important role in the development of endothelial inflammatory damages, leading to thrombophilia (Houman et al., 2001; Espinosa et al., 2002; Hirohata & Kikuchi, 2003). Figure 1 summarizes the immunopathogenesis of Behcet's disease (Pay et al., 2007).

Homocysteine (Hcy) is an intermediary sulphhydryl-containing aminoacid formed during the conversion of methionine to cysteine. Its sulphhydryl group can cause direct endothelial cytotoxicity, inhibition of glutathione peroxidase and nitric oxide, interference with clotting



APC: Antigen presenting cell, MICA: MHC class I related gene, eNOS: Endothial NO synthetase, ICAM-1: intracellular adhesion molecule-1

Fig. 1. Immunopathogenesis of Behcet’s disease (From Pay et al., 2007).

factor, and LDL oxidation (Kartal Durmazlar et al., 2008a, 2009). The association between Hcy levels and endothelial dysfunction and its correlation to the degree of endothelial damage have been shown in patients with BD. Hcy is thought to induce proinflammatory cytokines. Suggested mechanisms of Hcy in promoting such a clotting cascade are the inactivation of protein C, activation of coagulation factor V, and inhibition of thrombomodulin (Kartal Durmazlar et al., 2008a, 2009). The increase in Hcy concentration in patients at risk for vascular disease is expressed as odds ratio and for venous thrombosis, this odds ratio is approximately 1.6. In a study, a change of 1 $\mu\text{mol/l}$ in Hcy concentration was found to correspond to a risk ratio of 1.01 (Willems et al., 2006). A study reported that 5 $\mu\text{mol/l}$ increase of Hcy was associated with a 60% and 27% increased risk of venous thrombosis in retrospective and prospective studies, respectively (Omar et al., 2007). The association between Hcy levels and endothelial dysfunction and its correlation to the degree of endothelial damage has been shown in patients with BD (Ozdemir et al., 2004). Hcy generates superoxide and hydrogen peroxide, both of which have been linked to endothelial damage (Er et al., 2002). Hcy-induced vascular problems are thought to be multifactorial, including direct Hcy damage to the endothelium, enhanced lipid peroxidation and increased platelet aggregation by the effects on the coagulation system (Er et al., 2002; Sarican et al., 2007). Hcy has been shown in vivo and in vitro to promote inflammatory

process such as the adhesion of neutrophils to endothelial cells as well as the release of the inflammatory cytokine IL-8 and monocyte chemoattractant protein-1 (MPC-1) (Koga et al., 2002). Hcy was shown to enhance the cytokine-stimulated expression of endothelial cell adhesion molecules and monocyte and T-cell adhesion to endothelial cells (Koga et al., 2002). Hcy was shown to promote TNF- α mediated induction of vascular cell adhesion molecule-1 (VCAM-1) in endothelial cells (Silverman et al., 2002). Some studies have shown hyperhomocysteinemia as a correctable risk factor for thrombosis in BD (Kartal Durmazlar et al., 2008a, 2009; Omar et al., 2007; Ozdemir et al., 2004; Er et al., 2002; Sarican et al., 2007). In a recent work, thrombogenesis in BD is discussed through the concept of Virchow’s triad of venous thrombosis (La Regina et al., 2010). Based on this concept; abnormal blood flow, abnormal vessel wall, abnormal blood constituents are presented in Table 3.

Blood flow abnormalities	Enhanced erythrocyte aggregation, increased fibrinogen, high blood viscosity Impaired microcirculation Turbulent blood flow at sites of venous varices and arterial aneurysms Arterial and venous occlusion
Abnormal vessel wall	Perivasculitis Endothelial dysfunction Venous varices Aneurysms and pseudoaneurysms
Abnormal blood constituents	Endothelial factors such as vWF, t-PA, thrombomodulin, NO, VEGF, endothelin-1 Procoagulant factors such as factor V Leiden and prothrombin mutations, hyperhomocystenemia, factors VIII, IX, lipoprotein a Factors of fibrinolysis such as PAI-1, t-PA Anticoagulant factors (protein C, S, Z, antithrombin)

vWF: von Willebrand factor, t-PA: tissue plasminogen activator, NO: nitric oxide, VEGF: vascular endothelial growth factor, PAI-1: the type-1 inhibitor of plasminogen activators, t-PA: tissue plasminogen activator

Table 3. Thrombogenesis in Behcet’s Disease according to Virchow’s triad of venous thrombosis (From La Regina et al., 2010).

5. Medical management of Behcet’s disease

The choice of treatment is generally based on the clinical presentation and the site affected. Although the treatment has become much more effective in recent years, BD still associates with severe morbidity and considerable mortality. Therefore, the main aim of the treatment should be the prevention of irreversible organ damage, especially, during the early, active phase of the disease. Male sex and a younger age of onset have been reported to be associated with severe disease, which in case may require aggressive treatment (Alpsoy & Akman, 2009).Recently, a group of experts developed recommendations for the management of BD by combining the current evidence from controlled trials (Hatemi et al., 2008). The European League against Rheumatism (EULAR) recommendations are summarized in Table 4.

Eye disease	<ul style="list-style-type: none">• Affecting the posterior segment: Azathioprine and local and systemic corticosteroids• If refractory eye involvement (retinal vasculitis or macular involvement): Cyclosporine A or infliximab in combination with azathioprine and corticosteroids or IFN-a alone or with corticosteroids
Major vessel disease*	<ul style="list-style-type: none">• Acute deep vein thrombosis: Corticosteroids, azathioprine, cyclophosphamide or cyclosporine A• Thrombosis of the vena cava and Budd–Chiari syndrome: Cyclophosphamide• Pulmonary and peripheral arterial aneurysms: Cyclophosphamide and corticosteroids; surgery• Anticoagulants, antiplatelet and antifibrinolytic agents are not recommended (there are no controlled data on, or evidence of benefit from uncontrolled experience with anticoagulants, antiplatelet or antifibrinolytic agents in the management of deep vein thrombosis pulmonary embolism is rare and there is the risk of major bleeding in case there are concomitant pulmonary aneurysms)
Gastrointestinal involvement**	Sulfasalazine, corticosteroids, azathioprine, TNF-a antagonists or thalidomide; surgery
Articular involvement	Colchicine; IFN-a, azathioprine, TNF-a antagonists in resistant cases
CNS involvement***	<ul style="list-style-type: none">• Parenchymal disease: Corticosteroids, IFN-a, azathioprine, cyclophosphamide, methotrexate, TNF-a antagonists• Dural sinus thrombosis: Corticosteroids• Cyclosporine should be avoided in case of neurological involvement due to neurotoxicity, unless necessary for intraocular inflammation.
Mucocutaneous involvement (oral, genital and skin lesions)	<ul style="list-style-type: none">• Isolated lesions: Topical measures such as corticosteroids preparations, lidocaine gel, chlorhexidine, sucralfate suspension• Acne-like lesions: Topical measures as used in acne vulgaris• Erythema nodosum: Colchicines• Resistant cases: Azathioprine, IFNa and TNFa antagonists may be considered in resistant cases.

CNS: Central nervous system; IFN: Interferon; TNF: Tumour necrosis factor.
* There is no firm evidence to guide the management of major vessel disease in BD
** There is no evidence-based treatment that can be recommended for the management of gastrointestinal involvement of BD
*** There are no controlled data to guide the management of CNS involvement in BD

Table 4. EULAR recommendations for treatment of Behcet’s disease (Hatemi et al., 2008)

6. Conclusion

The pathogenesis of thrombotic events in BD is not fully understood. The primary abnormalities of the coagulation, anticoagulation, or fibrinolytic systems have not been confirmed yet in BD. In this review current knowledge of venous thrombosis in BD are summarized. There is no agreement on the treatment of thrombosis in BD. However, in general immunosuppressive agents such as corticosteroids, azathioprine, cyclophosphamide or cyclosporine are recommended for the treatment of venous thrombosis in BD. There is no enough evidence of benefit with anticoagulants or fibrinolytic agents in the management of thrombosis of BD (La Regina et al., 2010). Further studies are needed to clarify the safety and effectiveness of antithrombotic therapy in BD. However, owing to the complications of established thrombus, it would be reasonable to target different steps of the coagulation cascade for the prophylaxis and treatment of thrombosis in BD.

7. References

- Akgul, A. & Kartal Durmazlar, SP. (2008). Medical treatment of venöz ulcers. *Turkiye Klinikleri Journal of Cardiovasc Surgery-Special Topics*, Vol.1, pp. 31-33
- Aksoy, Y.; Ercan, A.; Dalmizrak, O.; Canpinar, H.; Kartal Durmazlar, SP. & Bayazit, M. (2010). The determination of matrix metalloproteinase 9 activity and gene expression levels in Behcet's disease patients with aneurismal complications. *Clinical Rheumatology*, DOI 10.1007/s10067-010-1559-1563
- Alpsoy, E. & Akman, A., (2009). Behçet's disease: an algorithmic approach to its treatment. *Archives of Dermatological Research*, Vol.301, pp. 693-702
- Alpsoy, E. (2009). Behcet's disease. *Turkderm*, Vol.43, Sup2, pp. 21-23
- Dilsen, N. (1996). History and development of Behçet's disease. *Revue du Rhumatisme English Edition*, Vol.63, pp. 512-519
- Durmazlar, SP.; Bahar Ulkar, G.; Eskioglu, F.; Tatlican, S.; Mert, A. & Akgul, A. (2009). Significance of serum interleukin-8 levels in patients with Behcet's disease: High levels may indicate vascular involvement. *International Journal of Dermatology*, Vol.48, No.3, pp. 259-264
- Er, H.; Evereklioglu, C.; Cumurcu, T.; Türköz, Y.; Ozerol, E.; Sahin, K. & Doganay, S. (2002). Serum homocysteine level is increased and correlated with endothelin-1 and nitric oxide in Behçet's disease. *British Journal of Ophthalmology*, Vol.86, pp. 653-657
- Espinosa, G.; Font, J.; Tassies, D.; Vidaller, A.; Deulofeu, R.; Lopez-Soto, A.; Cervera, R.; Ordinas, A.; Ingelmo, M. & Reverter, JC. (2002). Vascular involvement in Behcet's disease: relation with thrombophilic factors, coagulation activation, and thrombomodulin. *The American Journal of Medicine*, Vol.112, pp. 37-43
- Evereklioglu, C.; Er, H.; Turkoz, Y. & Cekmen, M. (2002). Serum levels of TNF-alpha, sIL-2R, IL-6, and IL-8 are increased and associated with elevated lipid peroxidation in patients with Behcet's disease. *Mediators of Inflammation*, Vol.11, pp. 87-93
- Evereklioglu, C. (2005). Current concepts in the etiology and treatment of Behcet Disease. *Survey of Ophthalmology*, Vol.50, pp. 297-350
- Evereklioglu, C. (2006). Regarding neutrophil and lymphocyte responses to oral Streptococcus in Adamantiades-Behçet's disease. *FEMS Immunology and Medical Microbiology*, Vol.47, pp. 311-314


- Evereklioglu, C. (2007a). The migration pattern, patient selection with diagnostic methodological flaw and confusing naming dilemma in Behçet disease. *European Journal of Echocardiography*, Vol.8, pp. 167-73
- Evereklioglu, C. (2007b). Regarding the naming dilemma of Behçet disease in the 21st century. *Oral Diseases*, Vol.13, pp. 117-121
- Evereklioglu, C. (2007c). The treatment schedule and historical naming process of Behçet disease. *Journal of European Academy of Dermatology and Venereology*, Vol.21, pp. 427-428
- Evereklioglu, C. (2010). Behçet's disease or Adamantiades-Behçet disease? An evidence-based historical survey. *Medical Science Monitor*, Vol.16, pp.: RA136-142
- Figenbaum, A. & Kornblueth, W. (1946). Behçet's disease as manifestation of a chronic septic condition connected with a constitutional disorder. With a report of 4 cases. *Acta Medical Orient*, Vol.5, pp. 139-151
- Freigenbaum, A. (1956). Description of Behçet's syndrome in the Hippocratic third book of endemic diseases. *British Journal of Ophthalmology*, Vol.40, pp. 355-357
- Gul, A.; Aslantas, AB.; Tekinay, T.; Konice, M. & Ozcelik, T. (1999). Procoagulant mutations and venous thrombosis in Behcet's disease. *Rheumatology*, Vol.38, pp. 1298-1299
- Hatemi, G.; Silman, A.; Bang, D.; Bodaghi, B.; Chamberlain, AM.; Gul, A. et al; EULAR Expert Committee. (2008). EULAR recommendations for the management of Behçet disease. *Annals of the Rheumatic Diseases*, Vol.67, pp. 1656-1662.
- Hirohata, S. & Kikuchi H. (2003). Behcet's disease. *Arthritis Research and Therapy*, Vol.5, pp. 139-146
- Houman, MH.; Ben Ghorbel, I.; Khiari Ben Salah, I.; Lamoulou, M.; Ben Ahmed, M. & Miled, M. (2001). Deep vein thrombosis in Behcet's disease. *Clinical and Experimental Rheumatology*, Vol.19, pp. 48-50
- International study group for Behcet's disease. (1990). Criteria for diagnosis of Behcet's disease. *Lancet*, Vol.335, pp. 1078-1080
- Jensen, T. (1941). Sur les ulcerations aphteuses de la muqueuse de la bouche et de la peau genitale combinees avec les symptomes oculaires (=Syndrome Behçet). *Acta Dermatology and Venereology*, Vol.22, pp. 64-79
- Jung, JY.; Kim, DY. & Bang D. (2008). Leg ulcers in Behçet's disease. *British Journal of Dermatology*, Vol.158, pp. 172-203.
- Kartal Durmazlar, SP.; Akgul, A.; Eskioglu, F. (2008a) Homocysteine may involve in the pathogenesis of Behcet's disease by inducing inflammation. *Mediators of Inflammation* 2008: 407972, doi:10.1155/2008/407972
- Kartal Durmazlar, SP.; Akgul, A. & Eskioglu, F. (2008b). Traditional wound care and wound dressings in venous ulcers. *Turkiye Klinikleri Journal of Cardiovasc Surgery-Special Topics*, Vol.1, pp. 59-64
- Kartal Durmazlar, SP.; Akgul, A. & Eskioglu, F. (2009). B vitamin supplementation reduced serum homocysteine and interleukin-6 levels in patients with Behcet's disease with acute venous thrombosis: A prospective controlled study. *Turkiye Klinikleri Journal of Medical Science*, Vol.29, pp. 361-366
- Kartal Durmazlar, SP. & Kandi, B. (2011). Naming dilemma of Behcet's disease. *Journal of Turkish Academy of Dermatology*, Vol.5, No.1, jtad1151r1

- Kobayashi, M.; Ito, M.; Nakagawa, A.; Matsushita, M.; Nishikimi, N.; Sakurai, T. & Nimura, Y. (2000). Neutrophil and endothelial cell activation in the vasa vasorum in vasculo-Behçet's disease. *Histopathology*, Vol.36, pp. 362-371
- Koga, T.; Claycombe, K. & Meydani, M. (2002). Homocysteine increases monocyte and T-cell adhesion to human aortic endothelial cells. *Atherosclerosis*, Vol.161, pp. 365-374
- Lakhanpal, S.; Tani, K.; Lie, JT.; Katoh, K.; Ishigatsubo, Y. & Ohokubo, T. (1985). Pathologic features of Behçet's syndrome: a review of Japanese autopsy registry data. *Human Pathology*, Vol.16, pp. 790-795
- La Regina, M.; Gasparyan, AY.; Orlandini, F. & Prisco, D. (2010). Behçet's disease as a model of venous thrombosis. *Open Cardiovascular Medicine Journal*, Vol.4, pp. 71-77
- Matsumoto, T.; Uekusa, T. & Fukuda, Y. (1991). Vasculo-Behçet's disease. A pathologic study of eight cases. *Human Pathology*, Vol.22, pp. 45-51.
- Mege, JL.; Dilsen, N.; Sanguedolce, V. ; Gul, A.; Bongrand, P.; Roux, H.; Ocal, L.; Inanc, M. & Capo, C. (1993). Over production of monocyte derived tumor necrosis factor alpha, interleukin IL-6, IL-8 and increased neutrophil superoxide generation in Behçet's disease. A comparative study with familial mediterranean fever and healthy subjects. *Journal of Rheumatology*, Vol.20, pp. 1544-1549
- Mendes, D.; Correia, M.; Barbedo, M.; Vaio, T.; Mota, M.; Gonçalves, O. & Valente, J. (2009). Behçet's disease--a contemporary review. *Journal of Autoimmunity*, Vol.32, pp. 178-188
- Omar, S.; Ghorbel, IB.; Feki, H.; Souissi, M.; Feki, M.; Houman, H. & Kaabachi N. (2007). Hyperhomocysteinemia is associated with deep vein thrombosis of the lower extremities in Tunisian patients. *Clinical Biochemistry*, Vol.40, pp. 41-45.
- Ozdemir, R.; Barutcu, I.; Sezgin, AT.; Acikgoz, N.; Ermis, N.; Esen, AM.; Topal, E.; Bariskaner, E. & Ozerol, I. (2004). Vascular endothelial function and plasma homocysteine levels in Behçet's disease. *American Journal of Cardiology*, Vol.94, pp. 522-525
- Pay, S.; Simsek, I.; Erdem, H. & Dinc, A. (2007). Immunopathogenesis of Behçet's disease with special emphasize on the possible role of antigen presenting cells. *Rheumatology International*, Vol.27, pp. 417-424
- Sarican, T.; Ayabakan, H.; Turkmen, S.; Kalaslioglu, V.; Baran, F. & Yenice N. (2007). Homocysteine: an activity marker in Behçet's disease? *Journal of Dermatological Science*, Vol.45, pp. 121-126
- Saylan, T. (1997). Life story of the Dr. Hulusi Behçet. *Yonsei Medical Journal*, Vol.38, pp. 327-332
- Silverman, MD.; Tumuluri, RJ.; Davis, M.; Lopez, G.; Rosenbaum, JT. & Lelkes, PI. (2002). Homocysteine upregulates vascular cell adhesion molecule-1 expression in cultured human aortic endothelial cells and enhances monocyte adhesion. *Arteriosclerosis Thrombosis and Vascular Biology*, Vol.22, pp. 587-592
- Tursen, U. (2009). Activation markers in Behçet's disease. *Turkderm*, Suppl 2, pp. 74-86
- Tuzun, Y. (2006). Hulusi Behçet, MD February 20, 1889 to March 8, 1948. *Clinical Dermatology*, Vol.24, pp. 548-550
- Ustün, C. (2002). A famous Turkish dermatologist, Dr. Hulusi Behçet. *European Journal of Dermatology*, Vol.12, pp. 469-470

Willems, HP.; den Heijer, M.; Gerrits, WB.; Schurgers, LJ.; Havekes, M.; Blom, HJ. & Bos, GM. (2006). Oral anticoagulant treatment with coumarin derivatives does not influence plasma homocysteine concentration. *European Journal of Internal Medicine*, Vol.17, pp. 120-124.

IntechOpen

IntechOpen



Venous Thrombosis - Principles and Practice

Edited by Dr. Ertugrul Okuyan

ISBN 978-953-307-885-4

Hard cover, 232 pages

Publisher InTech

Published online 05, January, 2012

Published in print edition January, 2012

According to Virchow's triad, venous thrombosis can occur as a result of one or more of three factors: changes in the dynamics of the blood flow, endothelial injury/dysfunction of the blood vessel and hypercoagulability. The blood in the veins is constantly forming microscopic thrombi that are routinely broken down by the body, and significant clotting can occur only when the balance of thrombus formation and resolution is altered. This book is a fresh synthesis of venous thromboembolism care and considers the opinions and studies from different fields of medicine. As venous thrombosis spectrum is wide and can affect many organ systems, from deep veins of the leg to the cerebral venous system, our intent is for this to be a comprehensive, up-to-date and readable book. We tried to present a synthesis of existing material infused with new ideas and perspectives and authors own clinical studies and even case-reports.

How to reference

In order to correctly reference this scholarly work, feel free to copy and paste the following:

Selda Pelin Kartal Durmazlar (2012). Venous Thrombosis in Behcet's Disease, Venous Thrombosis - Principles and Practice, Dr. Ertugrul Okuyan (Ed.), ISBN: 978-953-307-885-4, InTech, Available from: <http://www.intechopen.com/books/venous-thrombosis-principles-and-practice/venous-thrombosis-in-behcet-s-disease>

INTeCH
open science | open minds

InTech Europe

University Campus STeP Ri
Slavka Krautzeka 83/A
51000 Rijeka, Croatia
Phone: +385 (51) 770 447
Fax: +385 (51) 686 166
www.intechopen.com

InTech China

Unit 405, Office Block, Hotel Equatorial Shanghai
No.65, Yan An Road (West), Shanghai, 200040, China
中国上海市延安西路65号上海国际贵都大饭店办公楼405单元
Phone: +86-21-62489820
Fax: +86-21-62489821

© 2012 The Author(s). Licensee IntechOpen. This is an open access article distributed under the terms of the [Creative Commons Attribution 3.0 License](https://creativecommons.org/licenses/by/3.0/), which permits unrestricted use, distribution, and reproduction in any medium, provided the original work is properly cited.

IntechOpen

IntechOpen