

# We are IntechOpen, the world's leading publisher of Open Access books Built by scientists, for scientists

6,900

Open access books available

186,000

International authors and editors

200M

Downloads

Our authors are among the

154

Countries delivered to

TOP 1%

most cited scientists

12.2%

Contributors from top 500 universities



WEB OF SCIENCE™

Selection of our books indexed in the Book Citation Index  
in Web of Science™ Core Collection (BKCI)

Interested in publishing with us?  
Contact [book.department@intechopen.com](mailto:book.department@intechopen.com)

Numbers displayed above are based on latest data collected.  
For more information visit [www.intechopen.com](http://www.intechopen.com)



# **The Effects of Sildenafil Citrate on the Liver and Kidneys of Adult Wistar Rats (*Rattus norvegicus*) – A Histological Study**

Andrew Osayame Eweka<sup>1</sup> and Abieyuwa Eweka<sup>2</sup>

<sup>1</sup>*Department of Anatomy, School of Basic Medical Sciences, College of Medical Sciences, University of Benin, Benin City, Edo State,*

<sup>2</sup>*School of Nursing, University of Benin Teaching Hospital, Benin City Edo State, Nigeria*

## **1. Introduction**

Sildenafil citrate is widely used as an effective and safe oral treatment for erectile dysfunction of various etiologies (Goldstein et al., 1998; Cheitlin et al., 1999; Benckekroun et al., 2003). It is a potent and selective inhibitor of phosphodiesterase type 5 enzymes that acts to break down cyclic guanosine monophosphate (cGMP) (Boolell et al., 1996). The medication amplifies the effect of sexual stimulation by retarding the degradation of this enzyme. Sildenafil has been found effective in several subpopulations of men with erectile dysfunction, including sufferers from diabetes (Basu and Ryder, 2004), hypertension (Feldman et al., 1999), spinal cord injuries (Hultling et al., 2000; Deforge et al., 2006), multiple sclerosis (Fowler et al., 2005), depression (Seidman et al., 2001; Rosen et al., 2004; Tignol et al., 2004; Fava et al., 2006), PTSD (Orr et al., 2006), and schizophrenia (Aviv et al., 2004; Gopalakrishnan et al., 2006), men after resection of the prostate or radical prostatectomy (Nandipati et al., 2006), after renal transplant (Sharma et al., 2006), men on dialysis (Dachille et al., 2006), and men aged 65 years and older (Wagner et al., 2001; Carson, 2004).

Psychogenic erectile dysfunction (ED) patients are excellent candidates for sildenafil citrate therapy due to the intact neurovascular pathway. Nevertheless, the drug has been reported to be effective only in about 78% of patients with psychogenic ED (McMahon et al., 2000). It is likely that performance anxiety and sympathetic overtone are the cause of this unresponsiveness to sildenafil citrate during awakening, though data supporting this assumption are lacking (Rosen, 2001). The drug has been found to be effective and well tolerated in men with mild to moderate erectile dysfunction of no clinically identifiable organic cause (Eardley, 2001).

With the presence of PDE5 in choroidal and retinal vessels sildenafil citrate increase choroidal blood flow and cause vasodilation of the retinal vasculature. The most common symptoms are a blue tinge to vision and an increased sensitivity to light (Kerr and Danesh-Meyer, 2009). Adverse effects include headache, visual and retinal disturbances, dizziness and pupil-sparing third nerve palsy (Monastero et al., 2001). There have been reports of non-arteritic anterior ischaemic optic neuropathy and serous macular detachment in users of PDE5 inhibitors; although a causal relationship has not been conclusively shown. Despite

the role of cGMP in the production and drainage of aqueous humor these medications do not appear to alter intraocular pressure and are safe in patients with glaucoma. All PDE5 inhibitors weakly inhibit PDE6 located in rod and cone photoreceptors resulting in mild and transient visual symptoms that correlate with plasma concentrations. Psychophysical tests reveal no effect on visual acuity, visual fields or contrast sensitivity; however, some studies show a mild and reversible impairment of blue-green colour discrimination. PDE5 inhibitors transiently alter retinal function on electroretinogram testing but do not appear to be retinotoxic. Despite the role of cyclic nucleotides in tear production there is no detrimental effect on tear film quality. Based on the available evidence PDE5 inhibitors have a good ocular safety profile (Kerr and Danesh-Meyer, 2009).

It has been reported that sildenafil citrate significantly improves nocturnal penile erections in sildenafil non-responding patients with psychogenic erectile dysfunction (Abdel-Naser et al., 2004). Several pharmacological and physiological properties of sildenafil have been described (Cheitlin et al., 1999; Aviv et al., 2004; Galie et al., 2005; Hooper et al., 2006)

In Nigeria, most individuals often use sildenafil citrate indiscriminately for sexual arousal. There is a growing apprehension that it could be harmful or injurious to the body. Though sildenafil is currently being used to treat erectile dysfunction in patients with multiple sclerosis, Parkinson disease, multisystem atrophy, and spinal cord injury by improving their neurologically related erectile dysfunction, conversely, it has been implicated in a number of neurological problems, such as intracerebral hemorrhage, migraine, seizure, transient global amnesia, nonarteritic anterior ischemic optic neuropathy, macular degeneration, branch retinal artery occlusion, and ocular muscle palsies. Thus, preclinical and very limited clinical data suggest that sildenafil may have therapeutic potential in selected neurological disorders. However, numerous reports are available regarding neurological adverse events ascribed to the drug. Although sildenafil shows some promise as a therapeutic agent in selected neurological disorders, well-designed clinical trials are needed before the agent can be recommended for use in any neurological disorder (Farooq et al., 2008).

The liver is the largest glandular organ of the body, weighing between 1.4-1.6kg. It lies below the diaphragm in the thoracic region of the abdomen. It plays a major role in metabolism and has a number of functions in the body, including glycogen storage, plasma protein synthesis, production of bile; an alkaline compound which aids in digestion, and detoxification of most substances (Gartner and Hiatt, 2000).

The Kidney is a paired organ located in the posterior abdominal wall, whose functions include the removal of waste products from the blood and regulation of the amount of fluid and electrolytes balance in the body. As in humans, the majority of drugs administered are eliminated by a combination of hepatic metabolism and renal excretion (Katzung 1998). The kidney also plays a major role in drug metabolism, but its major importance to drugs is still its excretory functions.

Since the liver and kidneys are involved in the performance of these varied functions they may be susceptible to injury particularly in situation of toxicity. This work is carried out to investigate the histological effects of Sildenafil citrate on the liver and kidneys of adult Wistar rat. Though there are little or no literature report of toxicity of this drug on these two organs, but because they are vital organs in the body it is worthwhile to study its effects on them. Though Daghfous et al., in 2005 reported that sildenafil-induced liver disease.

This study will further corroborate or disprove the toxic effects of Sildenafil citrate in organs other than sex organs, with a view to advising the consumers on the inherent dangers of excessive consumption of the aphrodisiac.

## 2. Materials and methods

Twenty-four (24) adult Wistar rats of both sexes, weighing between 220.5g and 233.8g, with an average weight of 222.3g were randomly assigned into three treatment (n=18) and control (n=6) groups. The rats were obtained and maintained in the Animal holdings of the Department of Anatomy, School of Basic Medical Sciences, University of Benin, Benin city, Nigeria. They were fed with growers' mash obtained from Edo feed and flour mill limited, Ewu, Edo State and given water and feed ad libitum. The rats were acclimatized for 4 weeks before the experiment started.

### 2.1 Sildenafil citrate administration

The rats in the treatment groups (A, B, & C) received respectively, 0.25mg/kg, 0.70mg/kg and 1.43mg/kg body weight of Sildenafil citrate base dissolved in distilled water daily for 6 weeks, through orogastric feeding tube, while that of the control group D, received equal volume of distilled water daily during the period of the experiment. The rats were sacrificed by cervical dislocation on day forty-three of the experiment. The liver and kidneys of the animals in each group were dissected out and quickly fixed in 10% formal saline for general histological studies.

### 2.2 Histological study

The liver and Kidney tissues were dehydrated in an ascending grade of alcohol (ethanol), cleared in xylene and embedded in paraffin wax. Serial sections of 7 microns thick were obtained using a rotatory microtome. The deparaffinised sections were stained routinely with hematoxylin and eosin reagent. Photomicrographs of the specimens were obtained using digital research photographic microscope in the University of Benin research laboratory.

### 2.3 Liver enzyme assay and other metabolic panel

Blood samples were collected from all the rats within different treatment groups through the orbital venous plexuses on the last day of the experiment under chloroform anaesthesia. Blood serum was separated by centrifugation at 3000 rpm for 15 min. Serum was analysed colorimetrically for total protein, albumin, transaminases (aspartate aminotransferase (AST) and alanine aminotransferase (ALT). Blood samples were also collected and analyzed for blood urea nitrogen (BUN) and serum creatinine (Scr) by using the commercial kits (McClatchey, 1994)

### 2.4 Approval

This study was given consent and approval for the methodology and other ethical issues concerning the work by the University of Benin Research Ethics Ccommittee.

### 2.5 Statistical analysis

The results were expressed as mean  $\pm$ SD. Data obtained from liver function test, blood urea nitrogen (BUN) and serum creatinine (Scr) were subjected to statistical analysis using one way analysis of variance (ANOVA) then followed with post hoc test (Least Square Deviation), P value of less than 0.05 was considered significant.

### 3. Results

#### 3.1 Liver tissue

The control sections of the liver showed normal histological features with the hepatic lobules showing irregular hexagonal boundary defined by portal tract and sparse collagenous tissues. The hepatic portal veins, bile ductules and hepatic artery within the portal tract were all visible (Figure 1).

The treatment sections of the liver showed some histological changes that were at variance with those obtained in the control. There were evidence of dilatations of the central veins, which contained lysed red blood cells and cyto-architectural distortions of the hepatocytes and centrilobular haemorrhagic necrosis. There were atrophic and degenerative changes with the group that received 1.43mg/kg body weight of Sildenafil citrate more (Figure 2, 3 & 4).

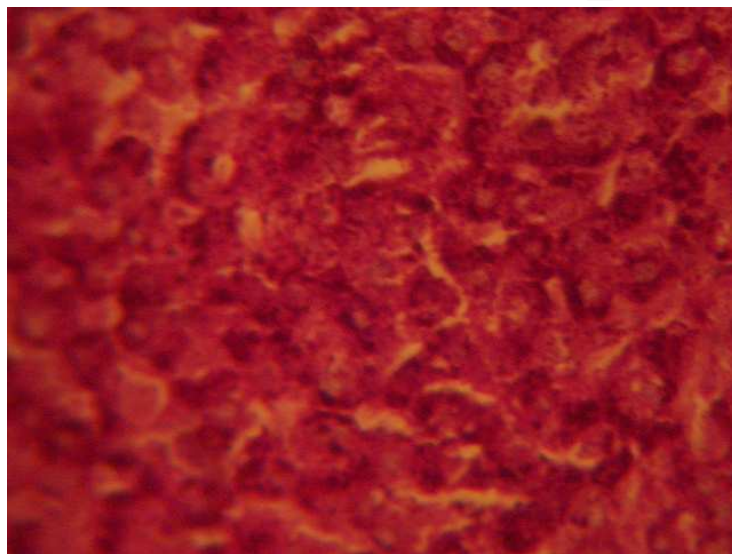


Fig. 1. Control section of the liver. Group 'D' (Mag. X400)

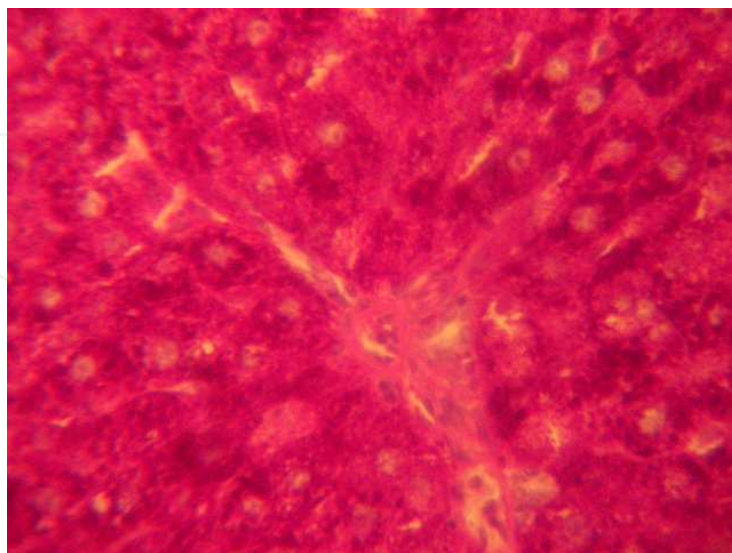


Fig. 2. Photomicrograph of the liver showing in the treatment groups 'A' that received 0.25mg/kg body weight of Sildenafil citrate. It shows portal tract and sparse collagenous tissues. The liver sinusoid and central veins were visible (Mag. x400)



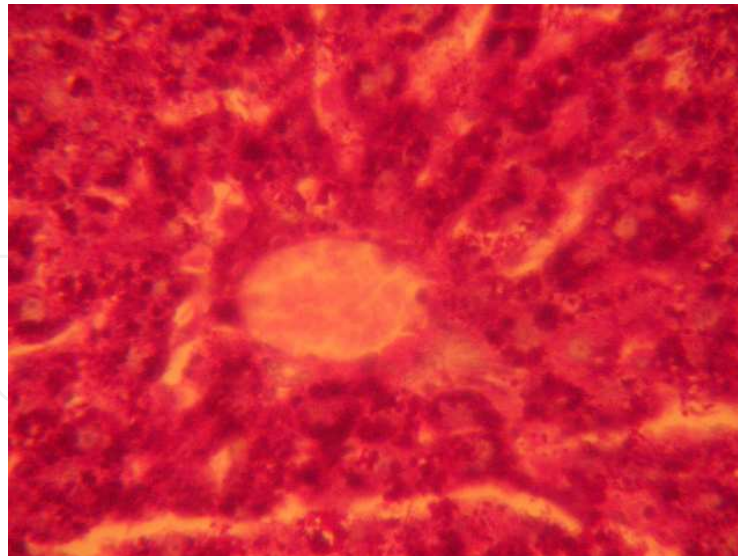


Fig. 3. Photomicrograph of the liver showing in the treatment groups 'B' that received 0.70mg/kg body weight of Sildenafil citrate. There were atrophic and degenerative changes around the hepatocytes and central vein, which was dilated and contained lysed red blood cell (Mag. X400).

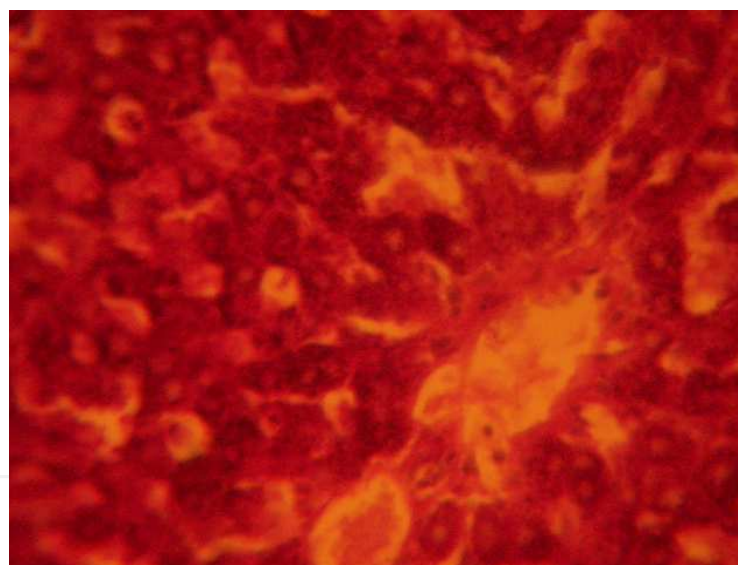


Fig. 4. Photomicrograph of the liver showing in the treatment groups 'C' that received 1.43mg/kg body weight of Sildenafil citrate. There were marked atrophic and degenerative changes around the hepatocytes and lysed red blood cell containing dilated central vein (Mag. X400).

### 3.2 Kidney tissue

The control sections of the kidneys showed normal histological features. The section indicated a detailed cortical parenchyma and the renal corpuscles appeared as dense rounded structures with the glomerulus surrounded by a narrow Bowman's spaces (Figure 5)

The kidneys of the animals in group 'A' treated with 0.25mg/kg of Sildenafil citrate revealed some level of cyto-architectural distortion of the cortical structures as compared to the control (Figure 6)

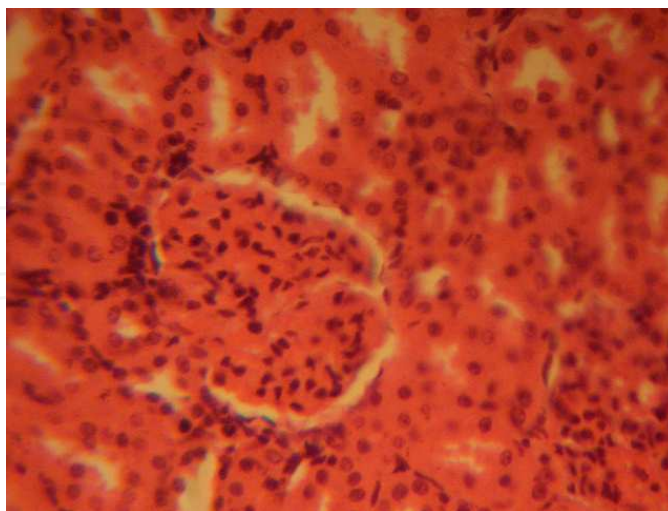


Fig. 5. Control section of the Kidney. Group 'D' (Mag. X400)

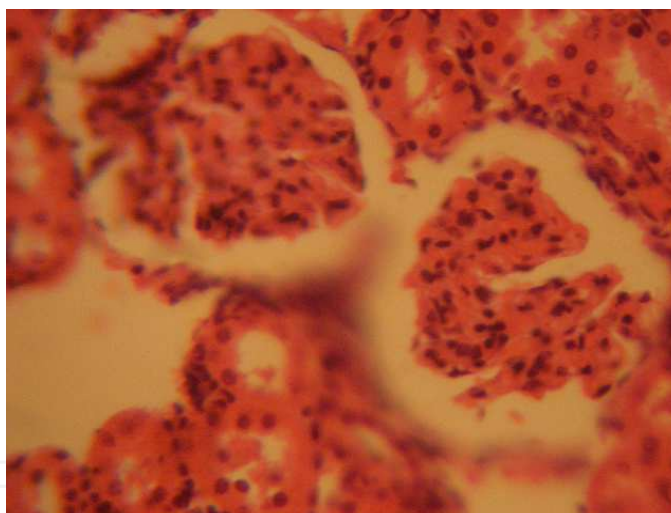


Fig. 6. Photomicrograph of the Kidney showing in the treatment groups 'A' that received 0.25mg/kg body weight of Sildenafil citrate showing some level of cyto-architectural distortion of the cortical structures (Mag. X400)

The kidney sections of animals in group 'B' treated with 0.70mg/kg of Sildenafil citrate revealed mild to moderate distortion of cyto-architecture of the renal cortical structures with mild degenerative and atrophic changes. The kidney sections of animals in group 'C' treated with 1.43mg/kg of Sildenafil citrate revealed marked distortion of cyto-architecture of the renal cortical structures, and degenerative and atrophic changes. There were vacuolations appearing in the stroma and loss of renal corpuscles which were less identified and the Bowman's spaces were sparsely distributed as compared to the control group 'D' (Figure 7)

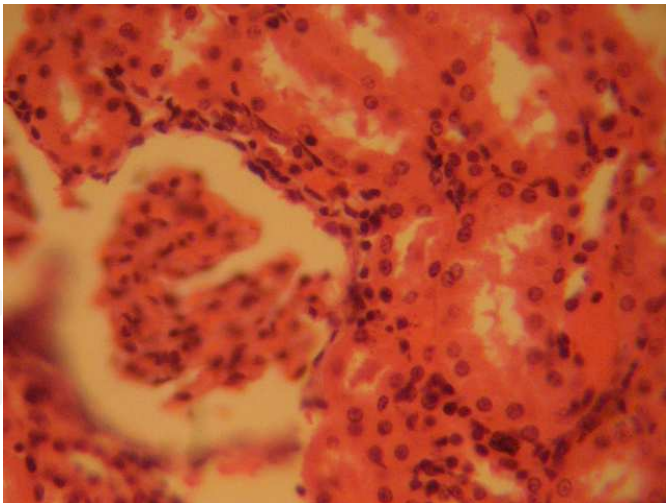


Fig. 7. Photomicrograph of the Kidney showing in the treatment groups ‘B’ that received 0.70mg/kg body weight of Sildenafil citrate mild to moderate distortion of cyto-architecture of the renal cortical structures with mild degenerative and atrophic changes (Mag. X400)

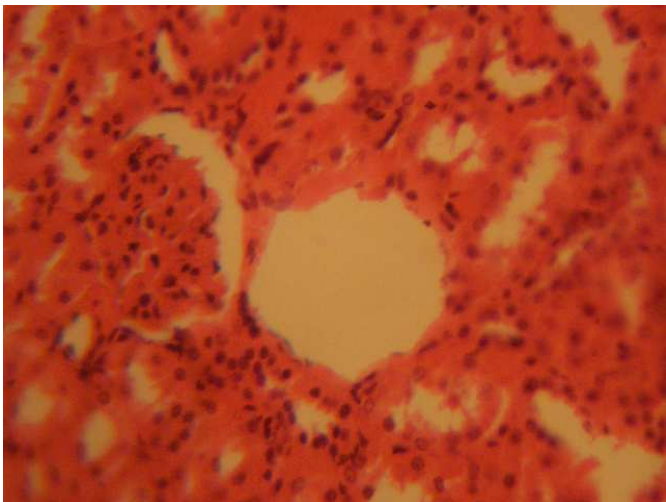


Fig. 8. Photomicrograph of the Kidney showing in the treatment groups ‘B’ that received 1.43mg/kg body weight of Sildenafil citrate marked distortion of cyto-architecture of the renal cortical structures, and degenerative and atrophic changes. There were vacuolations appearing in the stroma and loss of renal corpuscles which were less identified and the Bowman’s spaces were sparsely distributed.

Table 1 below shows the mean and standard deviation of each group for the different components. The table revealed that experimental group C (Exp. C) has the highest mean for components: Total Protein, Albumin, ALT and AST. The Control group had the least mean for all the components.

Table 2 shows the analysis of variance for the four groups for the five components. The results revealed that the difference between the means of the four groups for each component is significant ( $P < 0.0001$ ).

The result of this experiment revealed that Sildenafil citrate consumption caused significant ( $P < 0.05$ ) increase in functional nephrotoxicity indicators such as BUN and Serum creatinin in Sildenafil citrate-treated rats compared with control (Table 3).



	Group	N	Mean	Std. Deviation	Std. Error
Protein (g/dl)	Control	6	4.46	0.59	0.19
	Exp. A	6	5.73	0.21	0.04
	Exp. B	6	6.69	0.37	0.10
	Exp. C	6	7.73	0.42	0.12
	Total	24	6.68	0.98	0.22
Albumin (g/dl)	Control	6	2.83	0.38	0.16
	Exp. A	6	3.45	0.26	0.07
	Exp. B	6	4.31	0.29	0.09
	Exp. C	6	5.23	0.34	0.13
	Total	24	3.66	0.69	0.17
ALT (µmol/l)	Control	6	32.42	0.51	0.26
	Exp. A	6	73.84	11.63	4.34
	Exp. B	6	108.66	27.03	8.60
	Exp. C	6	112.73	29.42	9.71
	Total	24	78.34	35.20	7.84
AST (µmol/l)	Control	6	13.60	0.61	0.28
	Exp. A	6	58.70	8.84	3.16
	Exp. B	6	79.82	29.37	9.90
	Exp. C	6	88.57	32.62	11.72
	Total	24	53.16	35.45	6.84

Table 1. Descriptive statistics, protein and some liver enzymes assay of groups.

	Source of Variation	Sum of Squares	df	Mean Square	F	Sig.
Protein	Between Groups	17.612	3	8.560	91.528	.000
	Within groups	1.978	21	0.096		
	Total	18.282	24			
Albumin	Between Groups	7.749	3	3.471	60.21	.000
	Within groups	1.881	21	0.083		
	Total	8.976	24			
ALT	Between Groups	19421.463	3	9823.571	31.791	.000
	Within groups	5627.238	21	302.135		
	Total	25570.766	24			
AST	Between Groups	13873.376	3	6936.688	23.022	.000
	Within groups	5724.897	21	301.310		
	Total	18.898	24			

P <0.0001

Table 2. Analysis of Variance (ANOVA) of the Four Groups

	BUN (mg/ dl)	Scr (mg/ dl)
Control	14.38±2.5	0.47±0.21
Experimental group A (0.25mg/kg)	28.7±4.63	2.3±0.23
Experimental group B (0.70mg/kg)	55±0.72	3.2±0.99
Experimental group C (1.43mg/kg)	69±0.33	3.8±2.62

Table 3. Effects of Sildenafil citrate consumption on BUN and Scr concentration

4. Discussion

The results of the histological studies revealed that with increasing dose of Sildenafil citrate consumption, there were varying degrees of dilatations of the central vein of the liver which contained lysed red blood cells in the treatment group compared to the control sections of the liver, and as well as varying degree of cyto-architectural distortion and reduction in the number of renal corpuscle in the kidneys of the treated groups compared to the control sections of the kidneys. This suggests that the distortion of the cyto-architecture of the liver could be associated with functional changes that may be detrimental to the health of the rats. The proliferating cells of the liver, which produce red and white blood cells, are normally found between the hepatic cells and the walls of the vessels (Singh, 1997).

As a result of the distortion and dilatation of the hepatocytes and their central vein, the haematopoietic function of the liver may have been highly affected as a result of probable toxic effect of Sildenafil citrate. This was further buttressed by the increase in the liver enzymes obtained in the test group. In addition, total protein and albumin increased in this study the increase in total protein may be due to the fact that Sildenafil citrate was given for a short period of time. The resultant effect is acute toxicity leading to enhanced hepatocellular activity and increase in globulin and albumin components of the protein .However, with prolonged usage, hepatic necrosis is likely to occur with a resultant low albumin levels. There were several diffuse degeneration and necrosis of the tubular epithelial cells in the kidneys of the treated animals. The degenerative and atrophic changes where observed more in the kidneys of rats that received the highest dose (1.43mg/kg) of Sildenafil citrate.

It may be inferred from the present results that higher doses of Sildenafil citrate consumption may have resulted in degenerative and atrophic changes observed in the renal corpuscle. The possible deduction from these results is that secondary metabolites, which are largely responsible for therapeutic or pharmacological activities of medicinal plants (Perry, 1980), may also account for their toxicity when the dosage is abused.

Pathological or accidental cell death is regarded as necrotic and could result from extrinsic insults to the cell as osmotic thermal, toxic and traumatic effect (Farber et al, 1981). Physiological cell death is regarded as apoptotic and organized programmed cell death (PCD) that is mediated by active and intrinsic mechanisms. The process of cellular necrosis involves disruption of membranes, as well as structural and functional integrity. Cellular necrosis is not induced by stimuli intrinsic to the cells as in programmed cell death (PCD), but by an abrupt environmental perturbation and departure from the normal physiological conditions (Farber et al, 1981).

Cellular degeneration has been reported to result in cell death, which is of two types, namely apoptotic and necrotic cell death. These two types differ morphologically and biochemically (Wyllie, 1980). Pathological or accidental cell death is regarded as necrotic and could result

from extrinsic insults to the cell such as osmotic, thermal, toxic and traumatic effects (Wyllie, 1980). Cell death in response to toxins occurs as a controlled event involving a genetic programme in which caspase enzymes are activated (Waters et al., 1994).

As the hepatocytes swell as seen in this study the activities of cellular transporters are approximately modified by up or down regulations as earlier reported in the case of hyponatraemia or hypernatraemia (Johnson, 1995). Ischaemic or pharmacologic disruption of cellular transporters can cause swelling of parenchyma of the liver cells. Sildenafil citrate may have acted as toxins to the hepatocytes, thereby affecting their cellular integrity and causing defect in membrane permeability and cell volume homeostasis.

The actual mechanism by which Sildenafil citrate induced cellular degeneration observed in this experiment needs further investigation. The necrosis observed is probably due to the high concentration of Sildenafil citrate on the liver and kidney; this obviously will affect the normal detoxification, excretory processes and other functions of the liver and kidneys respectively.

The limitation of this study was the duration of study (acute) as opposed to chronic which could have yielded more light on the pathology.

## 5. Conclusion

The results obtained in this study following the administration of 0.25mg/kg, 0.70mg/kg and 1.43mg/kg per day of Sildenafil to adult Wistar rats affected the histology of the liver and kidneys. These results suggest that the functions of the liver and kidney may have been adversely affected. It is recommended that caution should therefore be advocated in the intake of this product and further studies be carried out to examine these findings.


## 6. References

- [1] Abdel-Naser MB, Imam A, Wollina U (2004). Sildenafil citrate significantly improves nocturnal penile erections in sildenafil non-responding patients with psychogenic erectile dysfunction. *Int. J. Impot. Res.* 16, 552–556.
- [2] Aviv A, Shelef A, Weizman A (2004). An open-label trial of sildenafil addition in risperidone-treated male schizophrenia patients with erectile dysfunction. *Journal of Clinical Psychiatry* 65:97–103.
- [3] Basu A, Ryder RE (2004). New treatment options for erectile dysfunction in patients with diabetes mellitus. *Drugs*, 64:2667–2688.
- [4] Benckroun A, Faik M, Benjelloun S (2003). A baseline-controlled, open-label, flexible dose-escalation study to assess the safety and efficacy of sildenafil citrate (Viagra) in patients with erectile dysfunction. *Int. J Impot. Res.* 15(Suppl. 1):S19–S24
- [5] Boolell M, Allen MJ, Ballard SA (1996). Oral sildenafil: an orally active type 5 cyclic GMP specific phosphodiesterase inhibitor for the treatment of penile erectile dysfunction. *Int J Impot Res*; 8: 47–52.
- [6] Carson CC (2004). Erectile dysfunction: evaluation and new treatment options. *Psychosomatic Medicine*, 66:664–671.
- [7] Cheitlin MD, Hutter AM, Brindis RG, Kaul S, Russell RO, Zusman RM (1999). Use of sildenafil (Viagra) in patients with cardiovascular disease. *Circulation*, 99:168–177.
- [8] Cunningham AV, Smith KH (2001). Anterior ischemic optic neuropathy associated with Viagra. *Journal of Neuro-Ophthalmology*, 21, 22–25.
- [9] Dachille G, Pagliarulo V, Ludovico GM (2006). Sexual dysfunction in patients under dialytic treatment. *Minerva Urologica e Nefrologica* 58:195–200.

- [10] Deforge D, Blackmer J, Garritty C (2006). Male erectile dysfunction following spinal cord injury: a systematic review. *Spinal Cord*, 44:465–473.
- [11] Drury RAB, Wallington EA, Cameron R. Carleton's Histological Techniques: 4th ed., Oxford University Press NY. U.S.A. 1967 279-280.
- [12] Eardley I (2001). Efficacy and safety of sildenafil citrate in the treatment of men with mild to moderate erectile dysfunction The British Journal of Psychiatry. 178: 325-330
- [13] Farber JL Chein KR, Mittnacht S (1981). The pathogenesis of Irreversible cell injury in ischemia. *American Journal of Pathology*; 102:271-281.
- [14] Farooq MU, Naravetla B, Moore PW, Majid A, Gupta R, Kassab MY (2008). Role of Sildenafil in Neurological Disorders *Clinical Neuropharmacology*: Vol 31 - Issue 6 - pp 353-362
- [15] Fava M, Nurnberg HG, Seidman SN (2006). Efficacy and safety of sildenafil in men with serotonergic antidepressant-associated erectile dysfunction: results from a randomized, double-blind, placebo-controlled trial. *J. Clin Psych.*, 67:240–246.
- [16] Feldman R, Meuleman EJ, Steers W (1999). Sildenafil citrate (VIAGRA) in the treatment of erectile dysfunction: analysis of two flexible dose-escalation studies. Sildenafil Study Group. *Int. J Clin Pract*, 53(Suppl. 102):10–12.
- [17] Fowler CJ, Miller JR, Sharief MK (2005). A double blind, randomised study of sildenafil citrate for erectile dysfunction in men with multiple sclerosis. *J Neuro. Neurosurg Psych.*, 76:700–705.
- [18] Galie N, Ghofrani HA, Torbicki A, Barst RJ, Rubin LJ, Badesch D, Fleming T, Parpia T, Burgess G, Branzi A, Grimminger F, Kurzyna M, Simonneau G (2005). Sildenafil citrate therapy for pulmonary arterial hypertension. *N Engl J Med* Nov 17; 353:2148-57.
- [19] Gartner LP, Hiatt JL (2000). *Color Atlas of Histology*; 3rd Edi., Lippincott Williams & Wilkins Publishers, A Wolters Kluwer company, pp 294-301.
- [20] Goldstein I, Lue TF, Padma-Nathan H, Rosen RC, Steers WD, Wicker PA (1998). Oral sildenafil in the treatment of erectile dysfunction. *N Engl J Med*; 338: 1397–1404.
- [21] Gopalakrishnan R, Jacob KS, Kuruvilla A (2006). Sildenafil in the treatment of antipsychotic-induced erectile dysfunction: a randomized, double-blind, placebo-controlled, flexible-dose, two-way crossover trial. *American Journal of Psychiatry*, 163:494–499.
- [22] Hoepfer MM, Welte T, Izbicki G, Rosengarten D, Picard E, Kuschner WG, Galiè N, Rubin LJ, Simonneau G (2006). Sildenafil Citrate Therapy for Pulmonary Arterial Hypertension. *N Engl J Med*; 354:1091-1093.
- [23] Hultling C, Giuliano F, Quirk F (2000). Quality of life in patients with spinal cord injury receiving Viagra (sildenafil citrate) for the treatment of erectile dysfunction. *Spinal Cord*, 38:363–370.
- [24] Johnson CE (1995). Effects of fluid imbalances In: *Neurosciences in Medicine*. Conn MP (Ed). New York: JB Lippincott Company; 187-189.
- [25] Katzung BG (1998). *Basic and Clinical Pharmacology* 7th edition, Appleton and Lange, Stamford CT; pp. 372-375
- [26] Kerr NM, Danesh-Meyer HV (2009). Phosphodiesterase inhibitors and the eye. *Clinical & Experimental Ophthalmology*, Volume 37 Issue 5, Pages 514 - 523
- [27] Daghfous R, El Aidli S, Zaiem A, Loueslati MH, Belkahia C (2005). Sildenafil-Associated Hepatotoxicity. *The American Journal of Gastroenterology* 100, 1895–1896; doi:10.1111/j.1572- 0241.41983\_6.x
- [28] Martins LJ, Al-Abdulla NA, Kirsh JR, Sieber FE, Portera-Cailliau C (1998). Neurodegeneration in excitotoxicity, global cerebral ischemia and target



- deprivation: A perspective on the contributions of apoptosis and necrosis. *Brain Res. Bull.* 46(4): 281-309.
- [29] McClatchey KD (1994). *Clinical Laboratory Medicine* London Williams & Wilkins;
- [30] McMahon CG, Samali R, Johnson H (2000). Efficacy, safety and patient acceptance of sildenafil citrate as treatment for erectile dysfunction. *J Urol*; 164: 1192-1196.
- [31] Monatero R, Pipia C, Camarda LKC, Camarda R (2001). Intracerebral haemorrhage associated with sildenafil citrate, *J. Neurol.*, Vol. 248: 2; 141-142.
- [32] Nandipati KC, Raina R, Agarwal A, Zippe CD (2006). Erectile dysfunction following radical retropubic prostatectomy: epidemiology, pathophysiology and pharmacological management. *Drugs & Aging*, 23:101-117.
- [33] Orr G, Weiser M, Polliack M (2006). Effectiveness of sildenafil in treating erectile dysfunction in PTSD patients: a double-blind, placebo-controlled crossover study. *Journal of Clinical Psychopharmacology*, 26:426-430.
- [34] Perry LM (1980). *Medicinal plants of East and South East Asia*, MIT Press, Cambridge Massachusetts.
- [35] Pomeranz HD, Smith KH, Hart WM, Jr, Egan RA (2002). Sildenafil-associated nonarteric anterior ischemic optic neuropathy. *Ophthalmology*, 109, 584-587.
- [36] Pomeranz HD, Bhavsar AR (2005). Nonarteric ischemic optic neuropathy developing soon after use of sildenafil (Viagra): A report of seven new cases. *Journal of Neuro-Ophthalmology*, 25, 9-13.
- [37] Rosen RC (2001). Psychogenic erectile dysfunction. Classification and management. *Urol Clin North Am*; 28: 269-278.
- [38] Rosen RC, Seidman SN, Menza MA (2004). Quality of life, mood, and sexual function: a path analytic model of treatment effects in men with erectile dysfunction and depressive symptoms. *Int J Impot Res*, 16:334-340.
- [39] Seidman SN, Roose SP, Menza MA (2001). Treatment of erectile dysfunction in men with depressive symptoms: results of a placebo-controlled trial with sildenafil citrate. *American Journal of Psychiatry*, 158:1623-1630.
- [40] Sharma RK, Prasad N, Gupta A, Kapoor R (2006). Treatment of erectile dysfunction with sildenafil citrate in renal allograft recipients: a randomized, double-blind, placebo-controlled, crossover trial. *American Journal of Kidney Diseases*, 48:128-133.
- [41] Siesjo BK (1978). Utilization of substrates by brain tissues, (In) *Brain energy metabolism*. John Wiley & Sons, USA. 101-130.
- [42] Singh I (1997). *Textbook of Human Histology with color atlas* 3rd edn. New Delhi: Jaypee Brothers Medical Publishers Ltd; 238-244.
- [43] Tignol J, Furlan PM, Gomez-Beneyto M (2004). Efficacy of sildenafil citrate (Viagra) for the treatment of erectile dysfunction in men in remission from depression. *International Clinical Psychopharmacology*, 19:191-199.
- [44] Wagner G, Montorsi F, Auerbach S, Collins M (2001). Sildenafil citrate (VIAGRA) improves erectile function in elderly patients with erectile dysfunction: a subgroup analysis. *Journal of Gerontology: Biological Sciences and Medical Sciences*, 56:M113-M119.
- [45] Waters CM, Wakinshaw G, Moser B, Mitchell IJ (1994). Death of neurons in the neonatal rodent globus pallidus occurs as a mechanism of apoptosis. *Neuroscience*: 63: 881-894.
- [46] Wyllie AH (1980). Glucocorticoid-induced thymocyte apoptosis is associated with endogenous endonuclease activation. *Nature*: 284:555- 556.



### **Sexual Dysfunctions - Special Issues**

Edited by Dr. Azita Goshtasebi

ISBN 978-953-307-859-5

Hard cover, 128 pages

**Publisher** InTech

**Published online** 22, December, 2011

**Published in print edition** December, 2011

Sexual dysfunctions have recently recognized as one of the major public health problems. This book enhances our scientific understanding of sexual function and dysfunction from different perspectives. It presents evidence-based interventions for sexual dysfunctions in difficult medical situations such as cancer, and gives a valuable overview of recent experimental researches on the topic. Published in collaboration with InTech - Open Access Publisher, this imperative work will be a practical resource for health care providers and researchers who are involved in the study of sexual health.

#### **How to reference**

In order to correctly reference this scholarly work, feel free to copy and paste the following:

Andrew Osayame Eweka and Abieyuwa Eweka (2011). The Effects of Sildenafil Citrate on the Liver and Kidneys of Adult Wistar Rats (*Rattus norvegicus*) – A Histological Study, *Sexual Dysfunctions - Special Issues*, Dr. Azita Goshtasebi (Ed.), ISBN: 978-953-307-859-5, InTech, Available from:  
<http://www.intechopen.com/books/sexual-dysfunctions-special-issues/the-effects-of-sildenafil-citrate-on-the-liver-and-kidneys-of-adult-wistar-rats-rattus-norvegicus-a->

**INTECH**  
open science | open minds

#### **InTech Europe**

University Campus STeP Ri  
Slavka Krautzeka 83/A  
51000 Rijeka, Croatia  
Phone: +385 (51) 770 447  
Fax: +385 (51) 686 166  
[www.intechopen.com](http://www.intechopen.com)

#### **InTech China**

Unit 405, Office Block, Hotel Equatorial Shanghai  
No.65, Yan An Road (West), Shanghai, 200040, China  
中国上海市延安西路65号上海国际贵都大饭店办公楼405单元  
Phone: +86-21-62489820  
Fax: +86-21-62489821

© 2011 The Author(s). Licensee IntechOpen. This is an open access article distributed under the terms of the [Creative Commons Attribution 3.0 License](https://creativecommons.org/licenses/by/3.0/), which permits unrestricted use, distribution, and reproduction in any medium, provided the original work is properly cited.

IntechOpen

IntechOpen