

We are IntechOpen, the world's leading publisher of Open Access books Built by scientists, for scientists

6,900

Open access books available

186,000

International authors and editors

200M

Downloads

Our authors are among the

154

Countries delivered to

TOP 1%

most cited scientists

12.2%

Contributors from top 500 universities



WEB OF SCIENCE™

Selection of our books indexed in the Book Citation Index
in Web of Science™ Core Collection (BKCI)

Interested in publishing with us?
Contact book.department@intechopen.com

Numbers displayed above are based on latest data collected.
For more information visit www.intechopen.com



Clinical Outcome of Aortic Root Replacement With Cryopreserved Aortic Valve Allografts

Aya Saito^{1,2} and Noboru Motomura^{1,2}

¹*Department of Cardiothoracic Surgery, the University of Tokyo*

²*University of Tokyo Tissue Bank
Japan*

1. Introduction

Cryopreserved heart and vascular allografts are major prostheses of choice in cardiac surgery today, used in variety of treatment situations. Right and left ventricular outflow tract reconstruction in congenital heart diseases, cases of infective endocarditis, mitral valve plasty, and aortic aneurysm of infective etiology are the major indications for allograft use. Saphenous vein grafts with small-sized valves have also been reported to be beneficial in particular cases in reconstructing the right ventricular flow to the pulmonary artery for neonates and infants, since these valved vein grafts offer good performance in preserving right ventricular function in small children, thus leading to better clinical outcomes [Murakami, 2002; Tam, 2001].

It has been over 40 years since the first heart valve allograft was performed by Dr. Ross for a case of congenital heart defect [Ross and Somerville, 1966]. Since then, heart valve allografts have entered into clinical use steadily, starting with the use of fresh grafts. Emerging techniques of cryopreservation, including programmed freezing methods and innovation of cryoprotective agents, have enabled long-term graft storage without the loss of morphological and biological benefits, and banking systems have made elective use possible. Tissue Banking system was introduced into Japan in 1997, and gradually became established as the method of choice mainly for congenital heart defects and infective cardiovascular diseases. The University of Tokyo Tissue Bank (UTTB) houses one of the biggest banks in Japan where related clinical investigations and scientific research is also conducted.

In this chapter we describe the allograft processing, the characteristics, and the clinical results of cryopreserved aortic valve allograft that were shipped from UTTB.

2. Tissue processing

2.1 Procurement

The tissues are usually collected in the operating theatre under sterile conditions, in the same manner as in an ordinary surgical procedure. Informed consent is obtained from the donor family in advance by the tissue bank donor coordinators. The procurement team consists of 4-6 surgeons, including cardiovascular surgeons for heart valve procurement and liver transplantation surgeons for venous graft procurement. A small piece of each allograft or adjacent connective tissue is sent for a culture test to rule out any contamination with

microorganisms. A blood specimen of the donor is also obtained in advance or during the procurement for serological study. Following a median sternotomy, the whole heart is excised and the heart valves and superior caval vein are dissected on a side table in the theatre. The descending thoracic aorta, inferior caval vein, and portal vein system, and veins from the lower extremities are also retrieved accordingly. Care is taken to process the tissues obtained from the thoracic cavity, the abdominal cavity, and the femoral region separately to avoid cross-contamination. The dissected tissues are immersed in disinfection medium: RPMI 1640 medium + l-glutamate (GIBCO, Invitrogen Corp., Grand Island, NY, USA) containing cefmetazole (240 µg/ml), lincomycin (120 µg/ml), and vancomycin (50 µg/ml), and polymyxin B (1000 µg/ml). Tissues from the thoracic cavity, abdominal cavity, and lower extremities are separately incubated in this antibiotic solution for 24 to 48 hours at 4°C. Up to December 2000, amphotericin B (5 µg/ml) was added to the disinfection medium at the University of Tokyo Tissue Bank, since at the time the trachea was also recovered from the donor, which was considered to be contaminated with yeast.

2.2 Trimming

After immersion in the antibiotic solution, tissues are trimmed to an appropriate size and shape in a laminar flow cabinet (Figure 1 a,b). A surgeon performs the tissue dissection dressed in a sterile disposable operating theatre gown. Tissues are packed in double-sterile bags (Figures 2a to 2d). Samples for microbiological testing are also taken from each graft at this time. Sediments obtained from filtration of the disinfection solution are also sent for microbiological testing. The tissues that are positive for microbes at trimming are excluded from clinical use.

2.3 Cryopreservation

The tissues are cryopreserved in RPMI 1640 containing 10% dimethyl sulfoxide (Me₂SO) in a final volume of 100 ml, including the tissue graft. The doubly packed tissues are cooled at a rate of -1°C/min down to -40°C, and then at a rate of -5°C/min to -80°C, using a programmable freezer (Profreeze, Nippon Freezer Co., Ltd, Tokyo, Japan). The grafts are then stored in vapor-phase liquid nitrogen at -180°C until used. Ketheesan et al demonstrated that a freezing rate of -1°C/min best maintained the viability of cells [Ketheesan et al, 1996], and this is the standard method of cryopreservation regimen today. As for the duration of graft storage, we keep the grafts for a maximum of 5 years, because of possible damage to the packages.

2.4 Thawing and clinical use

Grafts are rapidly thawed in a 37°C sterile saline bath and rinsed by sequential dilution using 1000 ml lactate Ringer solution (Lactec G®) to completely remove Me₂SO, because Me₂SO can cause tissue damage at normal body temperature. A small piece of thawed tissue is submitted for microbiological and pathological tests for the final check of quality control of the graft.

3. Characteristics of the heart valve allografts

3.1 Immunogenicity

In the past 40 years heart valve allografting, cryopreservation techniques (programmed freezing methods, innovation of cryoprotective agent, etc.) have improved significantly, and

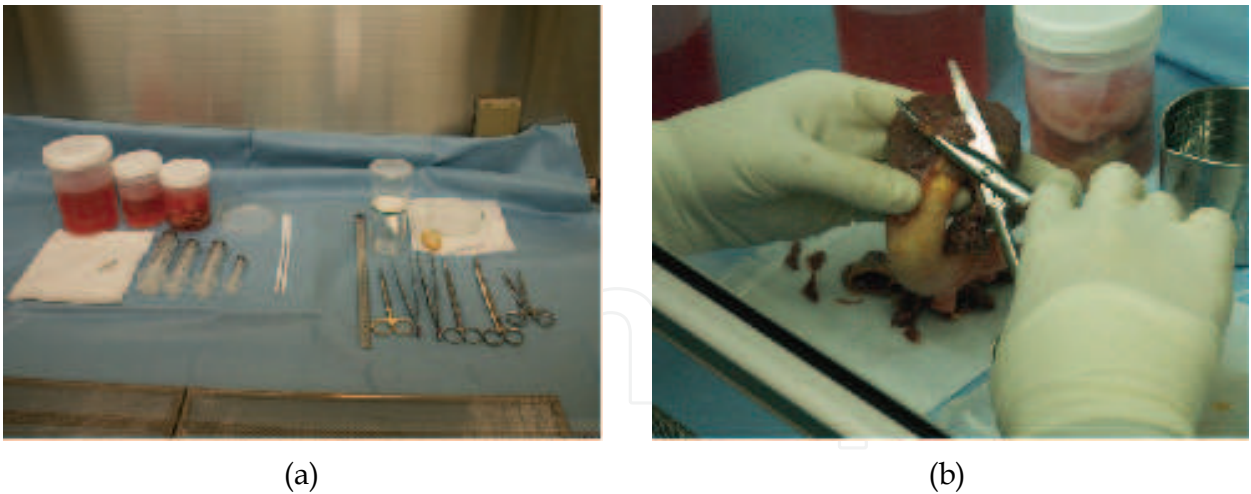


Fig. 1. (a) Tissues trimming is performed in a laminar flow chart; (b) Muscle skirt is trimmed to 4mm thick and 20mm long


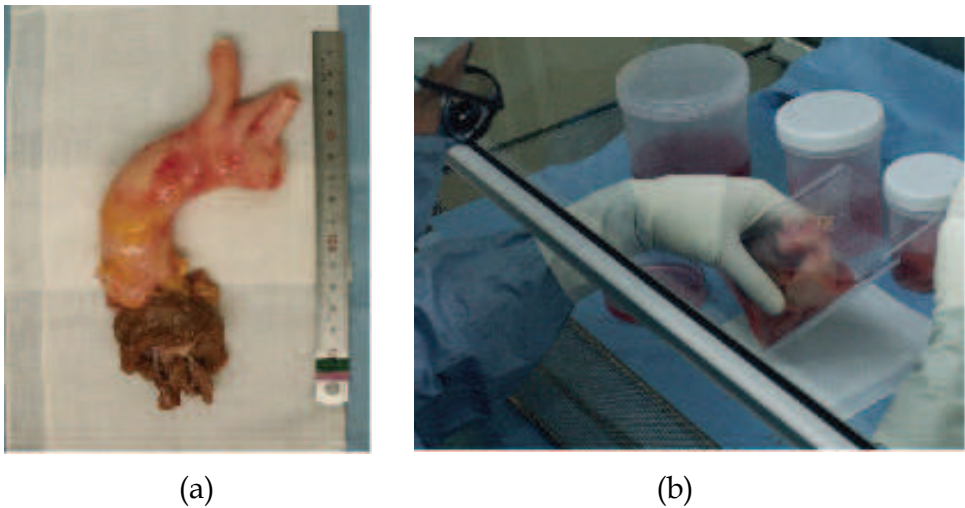


Fig. 2. (a) Allograft after trimming; (b) The graft is immersed in medium containing cryoprotectant (first package); (c) First and second packages are sealed tight with a heat sealer; (d) Final view of the package

progress in techniques and establishment of tissue banking systems have enabled long-term graft storage. With more frequent use of allografts, questions related to the extent of the allografts' antigenicity and the influence of the cryopreservation method on immunogenicity of the allografts has become a matter of discussion [Hoekstra et al., 1996].

Results of clinical investigations and animal experimentation have shown that both fresh and cryopreserved valve allografts have a certain, albeit, low degree of immunogenicity. Such studies date back to the 1990s and continue up to the present. Fischlein et al. reported that allograft valves caused immunological reaction after implantation by monitoring the circulation mononuclear cell in the recipients' peripheral blood; the immunological reaction was reversible without immunosuppressive treatment [Fischlein, 1995]. The authors concluded that aortic valve allografts were able to induce an immune response in the recipient that was related to early graft destruction and failure. In further studies using a rat transplantation model, it appeared that cryopreservation diminished but did not eliminate the immunogenicity of the allograft [Oei, 2001]. O'Brien et al presented data showing a donor-specific immune response after aortic valve allografting in the rat [Zhao, 1994], also confirmed in a clinical study [Hogan et al, 1996]. Graft rejection was also observed in infant cases receiving heart valve allografts [Rajani et al, 1998]. In several studies, mixed lymphocyte reaction (MLR) results showed recipient alloreactivity in rats [Rajani et al, 1998; Ketheesan et al, 1996; Oei et al, 2001; Saito et al, 2006]. The impact of cryopreservation manipulation on the alteration in the graft's allogenicity is still under investigation, and it is worth noting that two previous studies [Ketheesan et al, 1996; Oei et al, 2001] have concluded that cryopreservation decreases the immunogenicity of allografts. However, our analyses have shown that there was no difference in immunogenicity before and after cryopreservation [Saito et al, 2006]. This discrepancy in the results may arise from the difference in the conduits used (valved conduits vs non-valved aortic grafts), or the experimental methodology, or may be related to the method of measurement, i.e., whether antigen non-specific T cell response induced by concanavalin A stimulation was used [Ketheesan et al, 1996; Oei et al, 2001], or antigen-specific T cell response to donor antigen was employed using a third alloantigen [Saito et al, 2006].

Histological investigation was the major method of estimating the allogenicity of the cryopreserved allografts compared with fresh grafts [Legare et al, 2000; Moustapha et al, 1997; O'Brien et al, 1987; Oei et al, 2002], and our experimental results also added some data on the alteration of allogenicity in cryopreserved tissues from a molecular perspective [Saito et al, 2006]. Consistent with the results of T cell responses, our investigation of graft revealed that cryopreservation did not modify the graft's immunogenicity. Real-time PCR studies showed that the gene expression of TNF α , IFN γ , and iNOS (as a downstream effector of IFN γ pathway) in response to cryopreservation. In other words, cryopreservation did not modify graft allogenicity. Consistent with our results, Solanes et al recently reported that the cryopreservation method maintained immunogenicity of porcine arterial allografts [Solanes et al, 2005].

Cellular viability of grafts is important in that it preserves the long term viability of grafts [O'Brien et al, 1987], and numerous studies have addressed the status of endothelial cell viability in cryopreserved heart valves and vascular allografts [Oei et al, 2002]. The importance of preserving endothelial cell viability after cryopreservation is a matter of controversy, since there are two opposite interpretations; one being that graft endothelial cell viability is decreased after cryopreservation and also after transplantation because of depletion of donor cellular population [Armiger, 1995; Mitchell et al, 1995; Neves et al, 1997;

Niwaya et al, 1995; O'Brien et al, 1987; Redwood and Tennant, 2001], and the other that graft cell viability is maintained to a certain degree even after cryopreservation, from morphological, metabolic, and chromosomal perspectives [Fischlein et al, 1995; Lang et al, 1994; Oei et al, 2001]. Duration of warm ischemic time (i.e., the period from cardiac arrest of the donor and retrieval of the heart valve tissues to insertion in medium with antibiotic cocktail at 4°C), differences in the graft preparation method, and the antibiotic treatment regimen, may influence the outcome. In our animal experiments [Saito et al, 2006], eNOS gene expression level was measured in fresh and cryopreserved aortic allografts, which were processed in the same manner, including warm ischemic time and antibiotic treatment for a precise comparison. Levels of eNOS gene expression were similar in fresh and cryopreserved grafts, suggesting that endothelial cell viability is well-preserved at the molecular level after cryopreservation at the molecular level. Endothelial cells are also recognized as MHC class II antigen-presenting cells and may induce T-cell mediated immune responses after allotransplantation [Fischlein et al, 1995; Le Bas-Bernardet et al, 2004; Mitchell and Lichtman, 2004; Ono et al, 1998].

3.2 Resistance against infection

Invasive infective endocarditis of the aortic root is a critical and challenging post-operative complication that needs to be treated, especially when it forms an abscess at the juxtavalvular structure that can perforate to other neighboring cardiac structures. Short-term mortality rates due to this complication are reported to be 5% to 39% [Anguera et al, 2006; Cabell et al, 2005; Chu, 2004; Hasbun, 2003; Motomura et al, 2002; Kilian et al, 2010; Perrotta et al, 2010]. Gram positive cocci such as *Staphylococcus aureus* are frequently isolated, and among these *Methicillin-resistant Staphylococcus aureus* (MRSA) bacteremia is associated with significantly higher mortality rates than other infections. Surgical treatment at the appropriate time is crucial, including complete resection of the infected area and substitution of the defect with valvular prostheses. The choice of valve prosthesis is a key issues for a better prognosis. As regards the choice of substitutes, a heart valve allograft is considered superior to the other prosthesis like mechanical valves and bioprosthetic valves. Since the 1990s, several retrospective studies have shown that possible superiority of the valve allograft use for severe infective endocarditis and prosthetic valve endocarditis cases from the clinical results [Grinda et al, 2005; Haydock et al, 1992; Leyh et al, 2004; Sabik et al, 2002; Vogt et al, 1997; Yankah et al, 2005]; however, there is no final consensus of an allografts' potential of antimicrobial capacity due to the absence of randomized controlled studies and scientific evidence supporting this mechanism [Eichinger et al, 2002; Rowe et al, 1999], and the presence of opposing opinions [El-Hamamsy et al, 2010; Klieverik et al, 2009]. Further information was contributed in 2008 by our group to strongly support the allografts' property to overcome infection from a scientific point of view; the key substance conferring the antibacterial property was found to be indoleamine 2,3-dioxygenase (IDO) [Narui et al, 2009; Saito et al, 2008].

IDO is a IFN- γ induced, rate-limiting enzyme of the L-tryptophan (Trp) -L-kynurenine (Kyn) pathway [Mellor and Munn, 2004; Munn et al, 1998]. IDO is an important factor in induction of immunological tolerance by suppressing T cell proliferation through Trp degradation, and by producing toxic Trp metabolites that have anti-bacterial properties [Bauer et al, 2005; Bozza 2005; Silva 2002]. A possible mechanism linking antimicrobial activity and possible immune tolerance of allografts is the contribution of IDO. Our study was based on an aortic transplantation model using inbred rats. Aortic allografts, isografts,

and control grafts were analyzed to determine the extent of IFN γ , TNF α , and IDO gene expression by quantitative RT-PCR. Also, Trp metabolite production in the graft was measured by liquid chromatography/tandem mass spectrometry analysis. The bacteriostatic effect of each graft and Trp metabolite production was determined by a MRSA proliferation assay. These experiments showed significant gene expression of IFN γ , TNF α , and IDO in the allografts but not in the isografts and MRSA growth was suppressed when incubated with allografts but not with isografts (Figure 3A). Among Trp metabolites, the bacteriostatic effect against MRSA was remarkable with 3-hydroxykynurenine (3-HK) (Figure 3B), and 3-HK was actually isolated from allografts but not from the isografts. It may be concluded that the allograft anti-infection property arises as a consequence of the biological reaction following allotransplantation, which is not expected to occur with

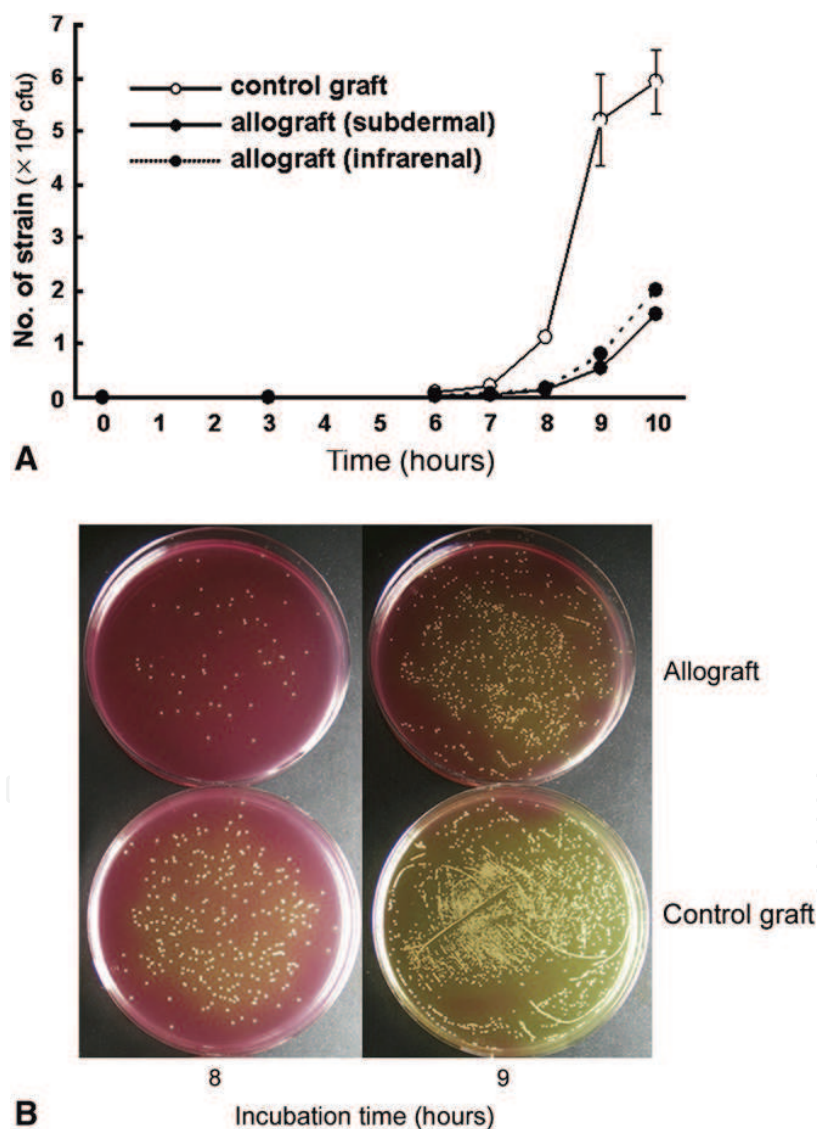


Fig. 3. A) Antimicrobial activity of the allografts against MRSA growth in vitro. MRSA proliferated remarkably when cultured with control grafts, whereas allografts showed MRSA growth suppression. B) MRSA proliferation was visualized on the mannitol salt agar. (Saito et al., 2008)

artificial biomaterial or mechanical prosthesis. Because of this, the allograft heart valve will still be a prime material of choice in surgical procedures related to infective endocarditis.

3.3 Allograft calcification

Although durability of allografts is generally as good as that of bioprosthetic valves, they tend to fail sooner in young recipients, especially neonates and infants than in adults, because of progressive calcification and degeneration [Baskett et al, 1996; O'Brien et al, 2001]. The precise mechanism regarding allograft calcification especially in the younger patients is still not fully understood; however, some studies have been reported [Mennander et al, 1991; Religa et al, 2003; Shioi et al, 2002; Tintut et al, 2000].

Factors related to calcium metabolism in the young (e.g., hyperphosphatemia) are thought to be a possible mechanism promoting allograft calcification. Graft calcification in young rats was inhibited by restriction of dietary inorganic phosphate (Pi) or by blocking of Pi transport via the sodium-phosphate cotransporter by phosphonoformic acid (unpublished data).

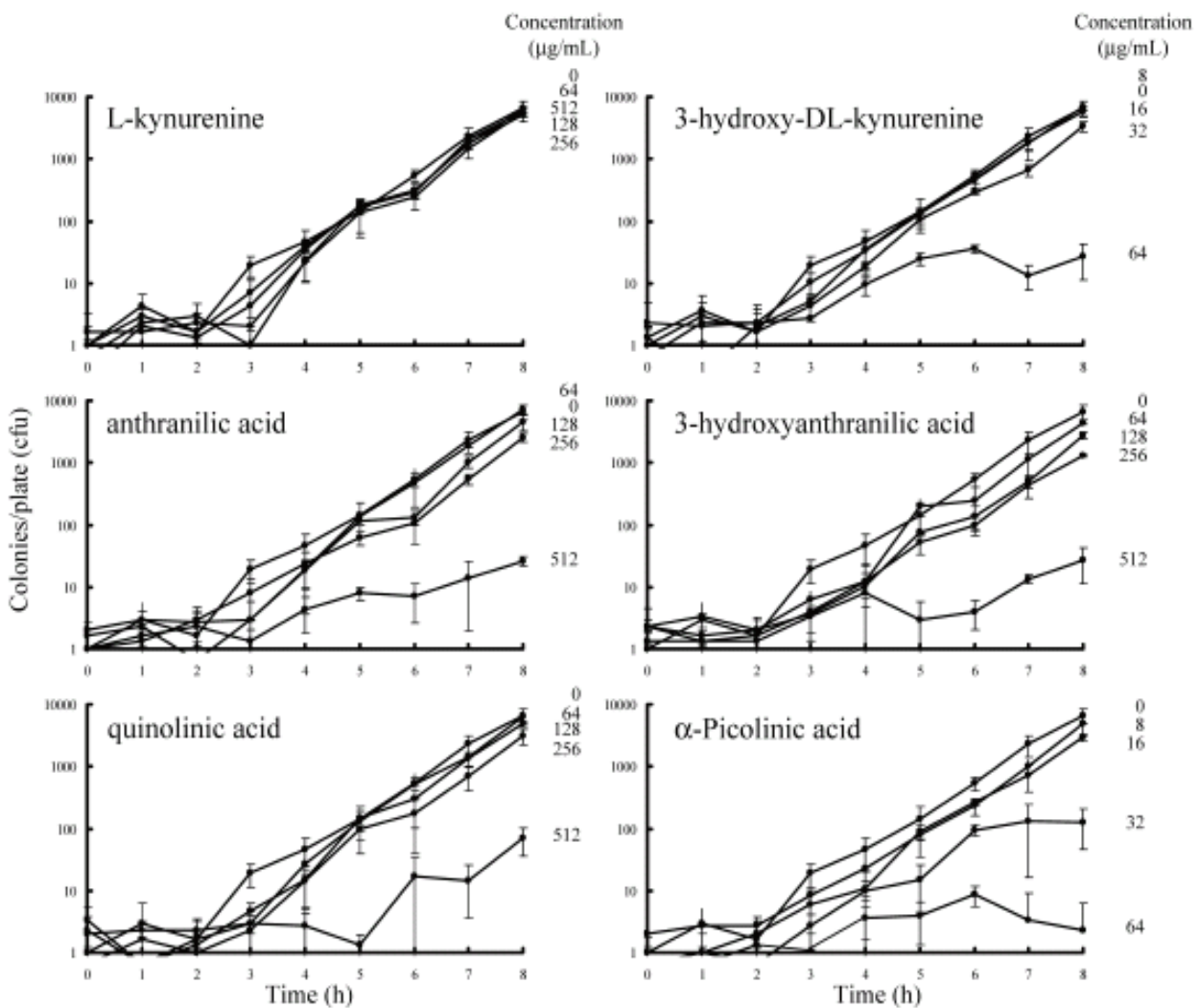


Fig. 4. MRSA Growth Curves with or without Tryptophan Metabolites at Various Concentrations (Narui et al., 2009)

4. Clinical experience from UTTB case series

Heart valve allografts have proven to be useful in the management of aortic valve and aortic root pathology. It has been more than 40 years since an aortic valve allograft was first inserted. Although they are not the only device available for valve replacement, they provide superior clinical outcome compared with the other types of devices such as prosthetic valves (mechanical and bioprosthetic valves) when they are used for infective endocarditis. The purpose of this section is to present the clinical performance of cryopreserved aortic valve allografts, which were provided by the University of Tokyo Tissue Bank (UTTB).

4.1 Patients and methods

Between December 1998 and September 2010, 60 aortic valve allografts were provided from UTTB for aortic root reconstruction. All the patients' characteristics were evaluated preoperatively (age, gender, indication for allograft transplantation and aortic allografts') profiles, and short- and long-term outcomes were analyzed. Recipients and the allografts were matched by size; blood-type or gender match were not mandatory. Follow-up data including the survival, performance status, graft function, and cause of deaths or graft loss were collected by follow-up with the surgeons in charge at 1, 3, 6, and 12 months after the surgery, followed by yearly updates.

The end points of the analysis of graft survival were repeat graft replacement for any reason, reoperation on the graft, or death of the patient with the graft in place. Long-term survival, freedom from recurrence of infection, reoperation, and cardiac death were assessed by Kaplan-Meier method using statistical analysis computer software, SAS ver. 5 (SAS Institute Inc., Cary NC, USA). Patients who survived more than 30 days after the procedure were included in the calculation for long-term analysis.

4.2 Results

A total of 60 patients received allograft transplantation during the observation period. Follow-up ranged from 2 days to 144.6 months (mean, 35.5 months). Mean age at time of operation was 52+/-16 years (range, 9 months – 74 years), and the majority of the patients were between 40 and 70 years of age. Most of the patients (48, 80%) were male. The majority of patients were diagnosed with active infective endocarditis (56/60, 93.3%) including 42 prosthetic valve endocarditis (29 mechanical prostheses, 10 bioprostheses, 2 homografts, and 1 autograft), and 14 cases of native valve endocarditis. Forty-five cases (75%) presented with advanced infection with aortic annular abscess formation or extensive destruction of the aortic root structure. Microorganisms were isolated from 43 cases by preoperative blood culture, most of them being *Staphylococcus spp.* or *Streptococcus spp.*, and MRSA was isolated from 6 of the 43 cases (14.0%). All the cases received antibiotic regimen prior to the surgery, however, urgent decision making was required to decide on surgery in most cases because of their hemodynamic instability and arrhythmia resulting from sudden onset of valvular disorders (in most cases, acute regurgitation), large amounts of vegetation on the valve leaflets, and progression of prosthetic valve dehiscence from the annulus. Four cases received allografts for non-infective reason; 2 cases for aortic root pseudoaneurysm after aortic root replacement, 1 for prosthetic valve dehiscence from the annulus because of Behcet's disease, and 1 for congenital aortic stenosis after balloon valvuloplasty. Fifty-four cases (90%) were the repeat surgery of the aortic root. Almost all cases were considered very high risk for surgical intervention (Figure 5 a,b).

Surgical techniques especially for proximal anastomosis at the aortic root have changed overtime; circumferential interrupted proximal suture technique in early days, intermittent continuous suture anastomoses with 6 to 8 stitches in the next era, and interrupted suture at the posterior anastomosis line and intermittent continuous suture in the anterior side of the proximal anastomosis line recently. The method of coronary artery reconstruction was carried out by direct reimplantation of the coronary buttons or interposition between the coronary ostium and allograft wall using the aortic arch branches of the allografts especially in repeat cases (Figure 5c) [Ohtsuka et al, 2001]. Coronary artery bypass grafting was added, if necessary. Short-term outcome showed a 30-day operative mortality of 11.7% (7/60), and the causes of death were uncontrolled infection in 3 cases, low output syndrome in 2 cases, multisystem organ failure (MOF) in 1 case, and bleeding in 1 case. Long-term results showed that the 1-year, 5-year, and 10-year survival rates were 88%, 61% and 53%, respectively (Figure 6a). Freedom from recurrent infection was 94%, 91%, and 91%, respectively (Figure 6c), and freedom from reoperation rates were 92%, 69%, and 55%,

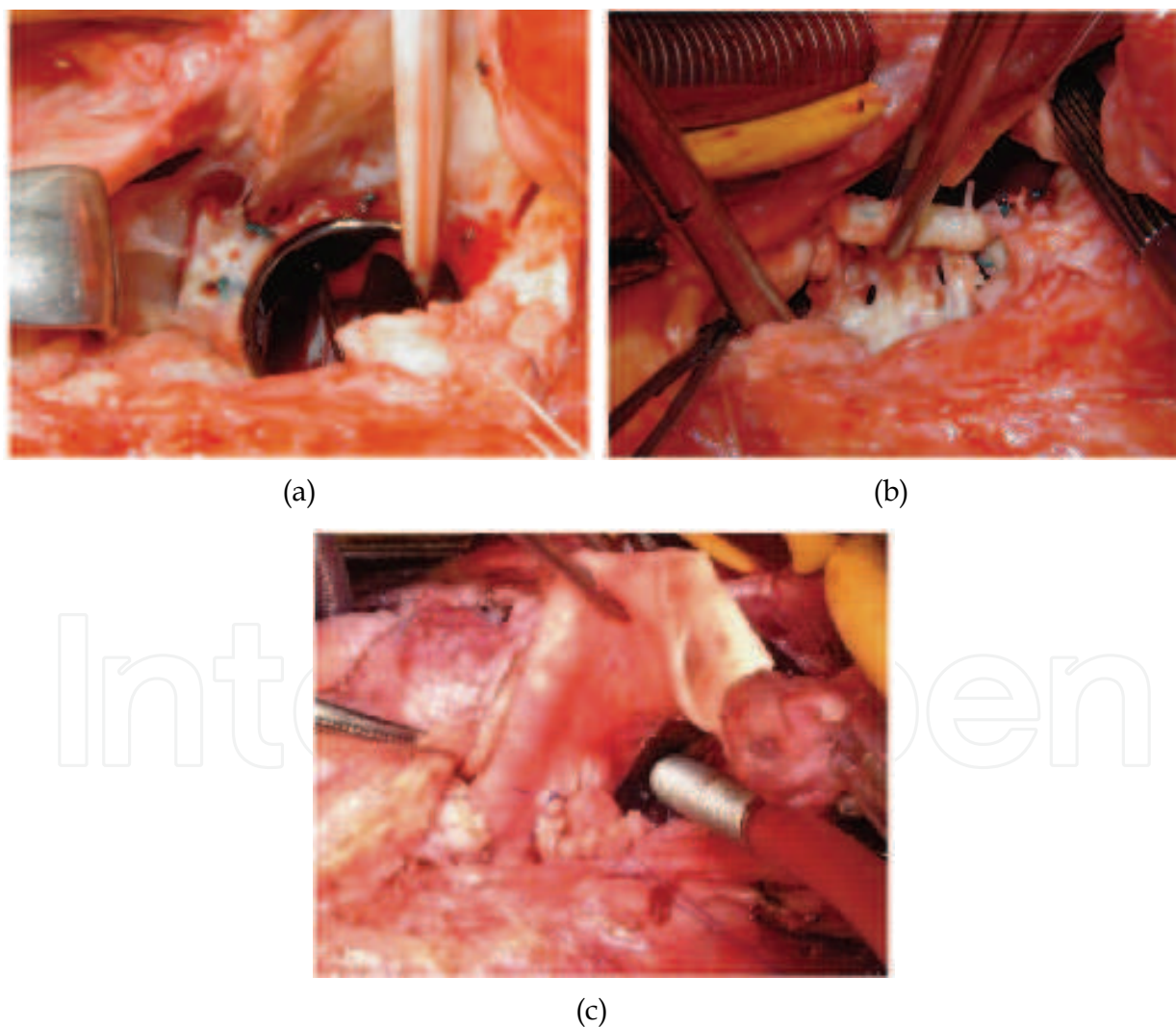


Fig. 5. (a) Annular abscess at the aortic root; (b) Prosthetic valve is detached from the annulus due to the infection; (c) Reconstruction of the aortic root with coronary artery reconstruction using a piece of arterial allograft

respectively (Figure 6d). The longest surviving graft has lasted 144.6 months. The causes of allograft loss were: uncontrolled infection in 4 cases, heart failure arising from aortic insufficiency in 3 cases, bleeding in 1 case, and MOF in 1 case. The other 6 cases were lost due to non-cardiac reasons. The major indications for reoperation were pseudoaneurysm at the anastomosis sites (either proximal or distal anastomosis line), allograft aortic valve insufficiency due to perforation of the non-coronary cusp [Saito et al, 2003], and bleeding at the proximal anastomosis.

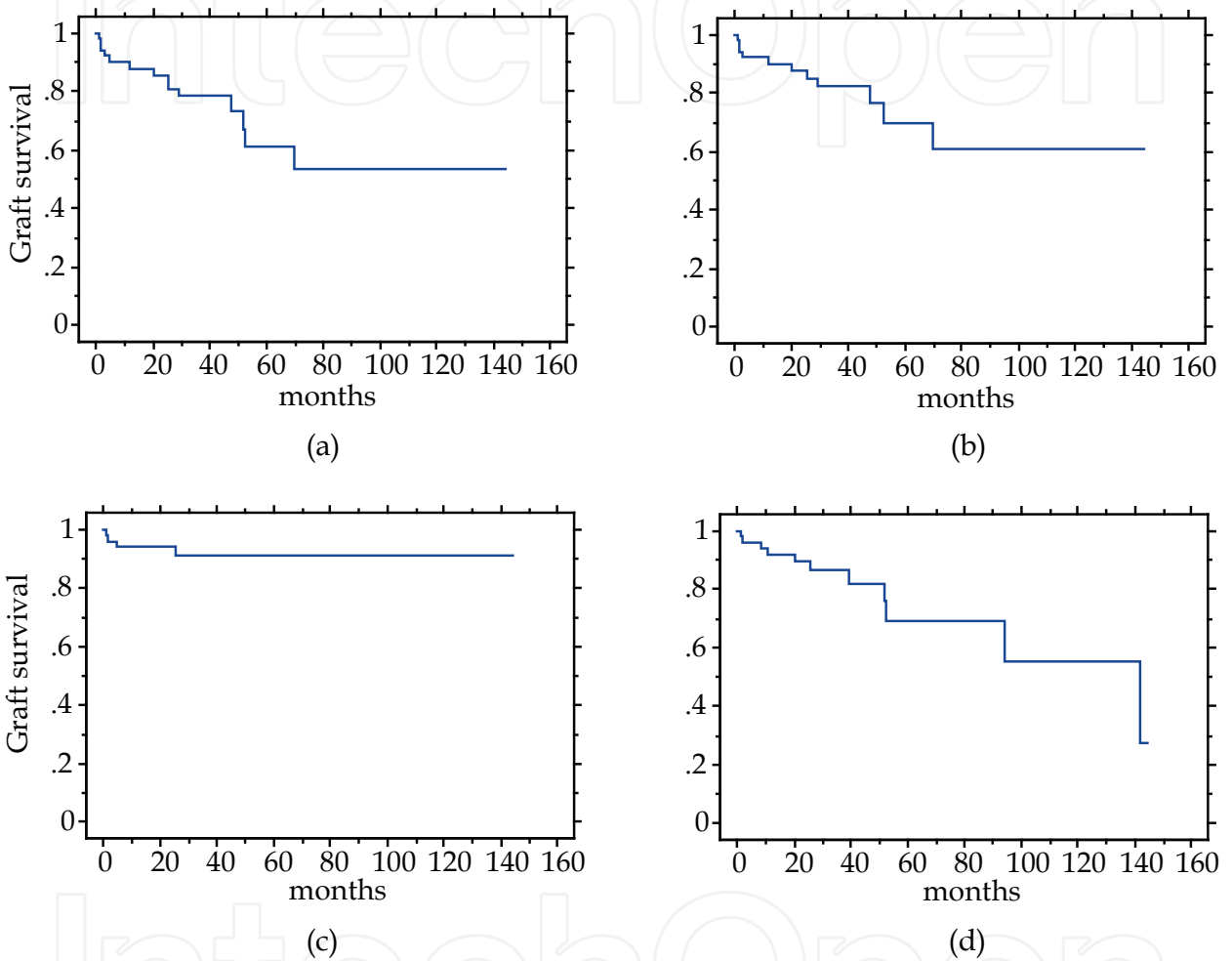


Fig. 6. (a) Cumulative survival after aortic root replacement with allograft (conditional survival); (b) Freedom from cardiac death; (c) Freedom from recurrence of infection; (d) Freedom from reoperation

5. Conclusions

The aortic root replacement with heart valve allograft was carried out successfully in patients with extensive infective lesions around the aortic root for whom the estimated operative mortality was very high. The allografts' nature of anti-infection property was thought to be beneficial in those critical infective disease, and long-term prognosis was satisfactory once the infection was controlled by surgery. Pseudoaneurysm formation at the anastomosis line appeared to be the major issue to overcome in order to improve the operative outcome.

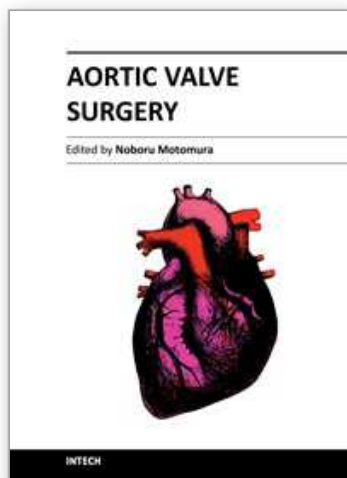
6. References

- Anguera, Miro, San Roman, de Alarcon, Anguita, Almirante, Evangelista, Cabell, Vilacosta, Ripoll, Munoz, Navas, Gonzalez-Juanatey, Sarria, Garcia-Bolao, Farinas, Rufi, Miralles, Pare, Fowler, Mestres, de Lazzari, Guma, del Rio, Corey. 2006. Periannular complications in infective endocarditis involving prosthetic aortic valves. *Am J Cardiol*, 98.9.1261-1268
- Armiger. 1995. Viability studies of human valves prepared for use as allografts. *Ann Thorac Surg*, 60.2 Suppl. S118-120; discussion S120-111
- Baskett, Ross, Nanton, Murphy. 1996. Factors in the early failure of cryopreserved homograft pulmonary valves in children: preserved immunogenicity? *J Thorac Cardiovasc Surg*, 112.5.1170-1178; discussion 1178-1179
- Bauer, Jiga, Chuang, Randazzo, Opelz, Terness. 2005. Studying the immunosuppressive role of indoleamine 2,3-dioxygenase: tryptophan metabolites suppress rat allogeneic T-cell responses in vitro and in vivo. *Transpl Int*, 18.1.95-100
- Bozza, Fallarino, Pitzurra, Zelante, Montagnoli, Bellocchio, Mosci, Vacca, Puccetti, Romani. 2005. A crucial role for tryptophan catabolism at the host/*Candida albicans* interface. *J Immunol*, 174.5.2910-2918
- Cabell, Abrutyn, Fowler, Hoen, Miro, Corey, Olaison, Pappas, Anstrom, Stafford, Eykyn, Habib, Mestres, Wang. 2005. Use of surgery in patients with native valve infective endocarditis: results from the International Collaboration on Endocarditis Merged Database. *Am Heart J*, 150.5.1092-1098
- Chu, Cabell, Benjamin, Kuniholm, Fowler, Engemann, Sexton, Corey, Wang. 2004. Early predictors of in-hospital death in infective endocarditis. *Circulation*, 109.14.1745-1749
- Eichinger, Goppel, Mandler, Mattes, Lankes, Botzenhardt, Bauernschmitt, Lange. 2002. In-vivo bacterial adherence to intracardiac prosthetic materials: a new experimental model. *J Heart Valve Dis*, 11.3.438-446
- El-Hamamsy, Eryigit, Stevens, Sarang, George, Clark, Melina, Takkenberg, Yacoub. Long-term outcomes after autograft versus homograft aortic root replacement in adults with aortic valve disease: a randomised controlled trial. *Lancet*, 376.9740.524-531
- Fischlein, Schutz, Haushofer, Frey, Uhlig, Detter, Reichart. 1995. Immunologic reaction and viability of cryopreserved homografts. *Ann Thorac Surg*, 60.2 Suppl. S122-125; discussion S125-126
- Grinda, Mainardi, D'Attellis, Bricourt, Berrebi, Fabiani, Deloche. 2005. Cryopreserved aortic viable homograft for active aortic endocarditis. *Ann Thorac Surg*, 79.3.767-771
- Hasbun, Vikram, Barakat, Buenconsejo, Quagliarello. 2003. Complicated left-sided native valve endocarditis in adults: risk classification for mortality. *Jama*, 289.15.1933-1940
- Haydock, Barratt-Boyes, Macedo, Kirklin, Blackstone. 1992. Aortic valve replacement for active infectious endocarditis in 108 patients. A comparison of freehand allograft valves with mechanical prostheses and bioprostheses. *J Thorac Cardiovasc Surg*, 103.1.130-139
- Hoekstra, Knoop, Vaessen, Wassenaar, Jutte, Bos, Bogers, Weimar. 1996. Donor-specific cellular immune response against human cardiac valve allografts. *J Thorac Cardiovasc Surg*, 112.2.281-286

- Hogan, Duplock, Green, Smith, Gall, Frazer, O'Brien. 1996. Human aortic valve allografts elicit a donor-specific immune response. *J Thorac Cardiovasc Surg*, 112.5.1260-1266; discussion 1266-1267
- Ketheesan, Kearney, Ingham. 1996. The effect of cryopreservation on the immunogenicity of allogeneic cardiac valves. *Cryobiology*, 33.1.41-53
- Kilian, Fries, Kowert, Vogt, Kreuzer, Reichart. Homograft implantation for aortic valve replacement since 15 years: results and follow-up. *Heart Surg Forum*, 13.4.E238-242
- Klieverik, Yacoub, Edwards, Bekkers, Roos-Hesselink, Kappetein, Takkenberg, Bogers. 2009. Surgical treatment of active native aortic valve endocarditis with allografts and mechanical prostheses. *Ann Thorac Surg*, 88.6.1814-1821
- Lang, Giordano, Cardon-Cardo, Summers, Staiano-Coico, Hajjar. 1994. Biochemical and cellular characterization of cardiac valve tissue after cryopreservation or antibiotic preservation. *J Thorac Cardiovasc Surg*, 108.1.63-67
- Le Bas-Bernardet, Coupel, Chauveau, Soullillou, Charreau. 2004. Vascular endothelial cells evade apoptosis triggered by human leukocyte antigen-DR ligation mediated by allospecific antibodies. *Transplantation*, 78.12.1729-1739
- Legare, Lee, Ross. 2000. Cryopreservation of rat aortic valves results in increased structural failure. *Circulation*, 102.19 Suppl 3.III75-78
- Leyh, Knobloch, Hagl, Ruhparwar, Fischer, Kofidis, Haverich. 2004. Replacement of the aortic root for acute prosthetic valve endocarditis: prosthetic composite versus aortic allograft root replacement. *J Thorac Cardiovasc Surg*, 127.5.1416-1420
- Mellor, Munn. 2004. IDO expression by dendritic cells: tolerance and tryptophan catabolism. *Nat Rev Immunol*, 4.10.762-774
- Mennander, Tiisala, Halttunen, Yilmaz, Paavonen, Hayry. 1991. Chronic rejection in rat aortic allografts. An experimental model for transplant arteriosclerosis. *Arterioscler Thromb*, 11.3.671-680
- Mitchell, Jonas, Schoen. 1995. Structure-function correlations in cryopreserved allograft cardiac valves. *Ann Thorac Surg*, 60.2 Suppl.S108-112; discussion S113
- Mitchell, Lichtman. 2004. The link between IFN-gamma and allograft arteriopathy: is the answer NO? *J Clin Invest*, 114.6.762-764
- Motomura, Takamoto, Murakawa, Yoneda, Shibusawa, Maeda, Suematsu, Murakami, Nakajima, Kotsuka. 2002. Short-term result of aortic valve replacement with cryopreserved homograft valve in the University of Tokyo Tissue Bank. *Artif Organs*, 26.5.449-452
- Moustapha, Ross, Bittira, Van-Velzen, McAlister, Lannon, Lee. 1997. Aortic valve grafts in the rat: evidence for rejection. *J Thorac Cardiovasc Surg*, 114.6.891-902
- Munn, Zhou, Attwood, Bondarev, Conway, Marshall, Brown, Mellor. 1998. Prevention of allogeneic fetal rejection by tryptophan catabolism. *Science*, 281.5380.1191-1193
- Murakami, Takamoto, Takaoka, Kobayashi, Maeda, Takayama, Motomura, Murakawa, Ono. 2002. Saphenous vein homograft containing a valve as a right ventricle-pulmonary artery conduit in the modified Norwood operation. *J Thorac Cardiovasc Surg*, 124.5.1041-1042
- Narui, Noguchi, Saito, Kakimi, Motomura, Kubo, Takamoto, Sasatsu. 2009. Anti-infectious activity of tryptophan metabolites in the L-tryptophan-L-kynurenine pathway. *Biol Pharm Bull*, 32.1.41-44

- Neves, Gulbenkian, Ramos, Martins, Caldas, Mascarenhas, Guerreiro, Matoso-Ferreira, Santos, Monteiro, Melo. 1997. Mechanisms underlying degeneration of cryopreserved vascular homografts. *J Thorac Cardiovasc Surg*, 113.6.1014-1021
- Niwaya, Sakaguchi, Kawachi, Kitamura. 1995. Effect of warm ischemia and cryopreservation on cell viability of human allograft valves. *Ann Thorac Surg*, 60.2 Suppl.S114-117
- O'Brien, Harrocks, Stafford, Gardner, Pohlner, Tesar, Stephens. 2001. The homograft aortic valve: a 29-year, 99.3% follow up of 1,022 valve replacements. *J Heart Valve Dis*, 10.3.334-344; discussion 335
- O'Brien, Stafford, Gardner, Pohlner, McGiffin. 1987. A comparison of aortic valve replacement with viable cryopreserved and fresh allograft valves, with a note on chromosomal studies. *J Thorac Cardiovasc Surg*, 94.6.812-823
- Oei, Stegmann, Vaessen, Marquet, Weimar, Bogers. 2001. Immunological aspects of fresh and cryopreserved aortic valve transplantation in rats. *Ann Thorac Surg*, 71.5 Suppl.S379-384
- Oei, Stegmann, van der Ham, Zondervan, Vaessen, Baan, Weimar, Bogers. 2002. The presence of immune stimulatory cells in fresh and cryopreserved donor aortic and pulmonary valve allografts. *J Heart Valve Dis*, 11.3.315-324; discussion 325
- Ohtsuka, Takamoto, Ono, Motomura. 2001. Aortic root replacement and coronary interposition using a cryopreserved allograft and its branch. *Eur J Cardiothorac Surg*, 20.3.631-632
- Ono, Nakajima, Lee, Hirata, Kobayashi, Kawauchi, Kotsuka, Takamoto, Furuse. 1998. Influence of cryopreservation on human vascular endothelial cell immunogenicity. *Transplant Proc*, 30.7.3915-3916
- Perrotta, Aljassim, Jeppsson, Bech-Hanssen, Svensson. Survival and quality of life after aortic root replacement with homografts in acute endocarditis. *Ann Thorac Surg*, 90.6.1862-1867
- Rajani, Mee, Ratliff. 1998. Evidence for rejection of homograft cardiac valves in infants. *J Thorac Cardiovasc Surg*, 115.1.111-117
- Redwood, Tennant. 2001. Cellular survival in rat vein-to-artery grafts. Extensive depletion of donor cells. *Cell Tissue Res*, 306.2.251-256
- Religa, Bojakowski, Gaciong, Thyberg, Hedin. 2003. Arteriosclerosis in rat aortic allografts: dynamics of cell growth, apoptosis and expression of extracellular matrix proteins. *Mol Cell Biochem*, 249.1-2.75-83
- Ross, Somerville. 1966. Correction of pulmonary atresia with a homograft aortic valve. *Lancet*, 2.7479.1446-1447
- Rowe, Impellizzeri, Vaynblat, Lawson, Kim, Sierra, Homel, Acinapura, Cunningham, Burack. 1999. Studies in thoracic aortic graft infections: the development of a porcine model and a comparison of collagen-impregnated dacron grafts and cryopreserved allografts. *J Thorac Cardiovasc Surg*, 118.5.857-865
- Sabik, Lytle, Blackstone, Marullo, Pettersson, Cosgrove. 2002. Aortic root replacement with cryopreserved allograft for prosthetic valve endocarditis. *Ann Thorac Surg*, 74.3.650-659; discussion 659
- Saito, Motomura, Kakimi, Narui, Noguchi, Sasatsu, Kubo, Koezuka, Takai, Ueha, Takamoto. 2008. Vascular allografts are resistant to methicillin-resistant *Staphylococcus aureus*

- through indoleamine 2,3-dioxygenase in a murine model. *J Thorac Cardiovasc Surg*, 136.1.159-167
- Saito, Motomura, Kakimi, Ono, Takai, Sumida, Takamoto. 2006. Cryopreservation does not alter the allogenicity and development of vasculopathy in post-transplant rat aortas. *Cryobiology*, 52.2.251-260
- Saito, Ohtsuka, Motomura, Kotsuka, Takamoto, Takazawa. 2003. Early valvular obliteration of cryopreserved aortic valve allograft. *Jpn J Thorac Cardiovasc Surg*, 51.8.384-386
- Shioi, Katagi, Okuno, Mori, Jono, Koyama, Nishizawa. 2002. Induction of bone-type alkaline phosphatase in human vascular smooth muscle cells: roles of tumor necrosis factor- α and oncostatin M derived from macrophages. *Circ Res*, 91.1.9-16
- Silva, Rodrigues, Santoro, Reis, Alvarez-Leite, Gazzinelli. 2002. Expression of indoleamine 2,3-dioxygenase, tryptophan degradation, and kynurenine formation during in vivo infection with *Toxoplasma gondii*: induction by endogenous gamma interferon and requirement of interferon regulatory factor 1. *Infect Immun*, 70.2.859-868
- Solanes, Rigol, Khabiri, Castella, Ramirez, Roque, Agusti, Roig, Perez-Villa, Segales, Pomar, Engel, Massaguer, Martorell, Rodriguez, Sanz, Heras. 2005. Effects of cryopreservation on the immunogenicity of porcine arterial allografts in early stages of transplant vasculopathy. *Cryobiology*, 51.2.130-141
- Tam, Murphy, Parks, Raviele, Vincent, Strieper, Cuadrado. 2001. Saphenous vein homograft: a superior conduit for the systemic arterial shunt in the Norwood operation. *Ann Thorac Surg*, 71.5.1537-1540
- Tintut, Patel, Parhami, Demer. 2000. Tumor necrosis factor- α promotes in vitro calcification of vascular cells via the cAMP pathway. *Circulation*, 102.21.2636-2642
- Vogt, von Segesser, Jenni, Niederhauser, Genoni, Kunzli, Schneider, Turina. 1997. Emergency surgery for acute infective aortic valve endocarditis: performance of cryopreserved homografts and mode of failure. *Eur J Cardiothorac Surg*, 11.1.53-61
- Yankah, Pasic, Klose, Siniawski, Weng, Hetzer. 2005. Homograft reconstruction of the aortic root for endocarditis with periannular abscess: a 17-year study. *Eur J Cardiothorac Surg*, 28.1.69-75
- Zhao, Green, Frazer, Hogan, O'Brien. 1994. Donor-specific immune response after aortic valve allografting in the rat. *Ann Thorac Surg*, 57.5.1158-1163



Aortic Valve Surgery

Edited by Prof. Noboru Motomura

ISBN 978-953-307-600-3

Hard cover, 246 pages

Publisher InTech

Published online 22, December, 2011

Published in print edition December, 2011

The aortic valve is located at the center of the heart. It is the core of cardiac anatomy and aortic valve surgery has led the field of cardiac surgery. This book describes all aspects of aortic valve surgery and it will help clarify daily questions regarding the clinical practice in aortic valve surgery, as well as induce inspiration and new insights into this field.

How to reference

In order to correctly reference this scholarly work, feel free to copy and paste the following:

Aya Saito and Noboru Motomura (2011). Clinical Outcome of Aortic Root Replacement With Cryopreserved Aortic Valve Allografts, Aortic Valve Surgery, Prof. Noboru Motomura (Ed.), ISBN: 978-953-307-600-3, InTech, Available from: <http://www.intechopen.com/books/aortic-valve-surgery/clinical-outcome-of-aortic-root-replacement-with-cryopreserved-aortic-valve-allografts>

INTech
open science | open minds

InTech Europe

University Campus STeP Ri
Slavka Krautzeka 83/A
51000 Rijeka, Croatia
Phone: +385 (51) 770 447
Fax: +385 (51) 686 166
www.intechopen.com

InTech China

Unit 405, Office Block, Hotel Equatorial Shanghai
No.65, Yan An Road (West), Shanghai, 200040, China
中国上海市延安西路65号上海国际贵都大饭店办公楼405单元
Phone: +86-21-62489820
Fax: +86-21-62489821

© 2011 The Author(s). Licensee IntechOpen. This is an open access article distributed under the terms of the [Creative Commons Attribution 3.0 License](https://creativecommons.org/licenses/by/3.0/), which permits unrestricted use, distribution, and reproduction in any medium, provided the original work is properly cited.

IntechOpen

IntechOpen