

We are IntechOpen, the world's leading publisher of Open Access books Built by scientists, for scientists

6,900

Open access books available

186,000

International authors and editors

200M

Downloads

Our authors are among the

154

Countries delivered to

TOP 1%

most cited scientists

12.2%

Contributors from top 500 universities



WEB OF SCIENCE™

Selection of our books indexed in the Book Citation Index
in Web of Science™ Core Collection (BKCI)

Interested in publishing with us?
Contact book.department@intechopen.com

Numbers displayed above are based on latest data collected.
For more information visit www.intechopen.com



Evaluation of Tinnitus in the Emergency Department

Kerry J. Welsh¹, Audrey R. Nath¹ and Matthew R. Lewin²

¹University of Texas Health Science Center at Houston

²California Academy of Sciences
USA

1. Introduction

Tinnitus is defined as the perception of abnormal noise by the patient in the absence of an external acoustic source. It may be described as a ringing, whistling, buzzing, roaring, or clicking sound, although any type of sound may be reported. Tinnitus may be unilateral or bilateral, and can be described as occurring within the head or as a distant sound ¹. It may occur constantly or intermittently. Tinnitus severity may vary considerably, ranging from a minor annoyance for the patient to distressing enough for certain patients to consider suicide ².

Tinnitus appears to be a very common symptom, with a reported prevalence ranging from 10 - 25 % ^{3,4}. Of the 35 - 50 million adults with this symptom, approximately 12 million visit a physician; 2 - 3 million of these patients are severely impacted by tinnitus ⁵. Furthermore, these patients often have numerous associated comorbidities including anxiety, depression, and reduced general health ⁶⁻⁹. Tinnitus occurs more frequently in Caucasians, men, and older age groups ¹⁰. Other reported risk factors include exposure to loud noise, hearing loss, smoking, and hypertension ^{11,12}. Tinnitus has also been reported in approximately 36% of children, but often goes undocumented due to the infrequency of their spontaneously reporting it ¹³.

Numerous hypotheses have been developed for the pathophysiology of tinnitus; however, a precise mechanism has not been established ¹⁴. Tinnitus may arise from any abnormality of the neural pathway from the cochlear neural axis to the auditory cortex. Proposed etiologies include damage to hair cells with accompanying excess stimulation of auditory nerves, increased activity in the auditory complex, and excessively active auditory nerves ^{3,15}. Multiple mechanisms likely account for tinnitus because of the complexity of the hearing pathways, and thus this symptom is non-specific.

Several classification types have been used to describe tinnitus. One such method classifies tinnitus as objective or subjective. Objective tinnitus indicates that the sound may be heard by the physician by auscultation with a stethoscope over the head and neck adjacent to the patient's ear ³. Subjective tinnitus is considerably more common, and is only perceived by the patient. This chapter will review the differential diagnosis of objective and subjective tinnitus as well as the evaluation and management of these patients.

2. Objective tinnitus

Objective tinnitus, occasionally referred to as somatosounds, is audible to the physician by use of a stethoscope or Doppler ¹⁵. The tinnitus is often characterized by the patient as a clicking or pulsing sound. The cause is often due to a vascular abnormality, which may be arterial or venous in etiology ¹. Additional causes include neurologic lesions or eustachian tube dysfunction ¹⁵.

2.1 Vascular causes

i. Arterial sources. Arteriovenous shunts include both arteriovenous malformations and arteriovenous fistulas, and represent an important cause of tinnitus that is essential to recognize in the emergency department ¹. Congenital arteriovenous malformations are generally asymptomatic and are uncommon causes of tinnitus, whereas acquired arteriovenous shunts are more likely to be symptomatic. Approximately 10 -15 % of intracranial arteriovenous fistula are dural, but are more often responsible for tinnitus than neck or cerebral arteriovenous shunts ¹⁶. Dural arteriovenous fistulas likely arise due to dural venous sinus thrombosis that is most often due to trauma, but may also be secondary to infections, neoplasms, or surgery ¹⁷. Mortality from hemorrhage of a dural arteriovenous fistula ranges from 10 - 20% ¹⁷; thus, appropriate diagnosis by emergency physicians is essential.

A second significant cause of acquired arteriovenous shunt that may cause tinnitus is a paraganglioma in the temporal bone, classified as either a glomus jugulare or glomus tympanicum tumor ¹⁵. Such tumors often cause the patient to perceive a constant blowing sound. Additional symptoms that may occur as the tumor enlarges include hearing loss, and deficits in cranial nerves VII - XII. These tumors are occasionally visualized as a vascular mass behind the tympanic membrane ¹⁵.

Rarely, tinnitus may be caused by dissecting aneurysms of the of the internal auditory canal or the vertebral artery ¹⁷. Additional symptoms that may occur are pain, Horner's syndrome, cranial nerve deficits, subarachnoid hemorrhage, and transient ischemic attacks. Vasculopathies that predispose individuals to this condition include Marfan syndrome, osteogenesis imperfecta, and fibromuscular dysplasia ¹⁷.

Tinnitus may occasionally be the presenting symptom of atherosclerosis in the carotid artery ^{17,18}. The source of the somatosounds is stenosis in regions of the carotid artery that result in blood flow turbulence. Associated risk factors are those typical for atherosclerosis and include older age, smoking, diabetes, hyperlipidemia, and hypertension. Carotid bruits have been reported in patients with this source of tinnitus ¹⁸. Tinnitus may also result from arterial bruits in other vessels in the temporal bone including branches of the external carotid, basilar, vertebral arteries, and vascular abnormalities located in the auditory canal ^{15,19}. These patients generally lack other otologic symptoms such as vertigo, hearing loss, otalgia, and symptoms of aural fullness ¹⁵.

ii. Venous sources. Tinnitus may also arise from venous sources. A venous origin of tinnitus may be differentiated from an arterial source by application of pressure on the ipsilateral jugular vein; this maneuver results in cessation of the tinnitus from venous sources ¹⁷.

The most important etiology of venous causes of tinnitus is pseudotumor cerebri, also called idiopathic intracranial hypertension. Pseudotumor cerebri classically occurs in young, obese, women. Pulsatile tinnitus in one series was reported to occur in 60% of patients;

accompanying symptoms include headache, visual disturbances, and retrobulbar pain ²⁰. Indeed, the combination of headache with pulsatile tinnitus is fairly specific for the diagnosis of pseudotumor cerebri ²⁰⁻²². The most common signs on physical exam include papilledema, loss of visual fields, and cranial nerve VI palsy. Occasionally, pseudotumor cerebri has been reported in the absence of papilledema ²²⁻²⁴. Untreated pseudotumor cerebri may lead to permanent vision loss ²⁵.

Venous hums are another source of tinnitus. They may be heard in patients with hypertension, which may be systemic or intracranial ¹⁵. Another cause of venous hum tinnitus is a dehiscent jugular bulb, an aberrantly high location of the jugular bulb that extends into the middle ear space ¹⁵. Dehiscent jugular bulb tinnitus results in a low-pitched, soft hum that decreases with activity, movement of the head, or application of jugular vein pressure. Hearing loss has been reported secondary to a dehiscent jugular bulb ²⁶. A dehiscent jugular bulb may be visualized behind the tympanic membrane, and must be differentiated from a glomus tumor ¹⁵.

2.2 Non-vascular causes

Palatal myoclonus and stapedia muscle spasm are two neurologic disorders that may cause objective tinnitus. Palatal myoclonus is caused by inappropriate contractions of the superior constrictor muscles, the salpingopharyngeus, the tensor veli palatini, and the levator veli palatini muscles ²⁷. The muscular contractions occur 10 - 240 times per minute, and occur intermittently; the objective tinnitus results from abrupt closure of the eustachian tube ²⁸. This condition may occur in any age group, and may be accompanied by temporomandibular joint pain or occipital headaches; other reported symptoms include hearing loss, alteration of sounds, and the sensation of aural pressure ¹⁵. The diagnosis can be confirmed by viewing palatal myoclonic jerks or by listening with a Toynbee tube. This condition may occur secondary to other neurologic disorders such as cerebrovascular disease, central nervous system tumors, and multiple sclerosis ²⁷.

Stapedial muscle spasm is an idiopathic condition that is described as a rumbling sensation in the ear ¹⁵. It is often exacerbated by other noises such as speech. The diagnosis is made by visualizing contractions of the tympanic membrane that coincide with the sensation experienced by the patient. Stapedial muscle spasm is considered a benign, self-limited condition ¹⁵.

Finally, dysfunction of the eustachian tube may result in objective tinnitus ¹⁵. This type of tinnitus is often described as a roaring sound that coincides with breathing. Patients may additionally report autophony and reverberation. The symptoms typically improve with lying down and recur after rising. It may be diagnosed by visualizing a fluttering of the tympanic membrane when the patient strongly inhales through the nose. This condition typically develops after a large weight loss of any type ¹⁵.

3. Subjective tinnitus

Subjective tinnitus refers to the perception of a sound that is not audible to the examiner. Patients describe the perceived sounds as a ringing, buzzing or clicking ²⁹. The causes for subjective tinnitus generally stem from hearing loss from damage to the auditory pathway anywhere from the external auditory canal to the auditory nerve.

External causes for subjective tinnitus include cerumen impaction as well as cerumen removal procedures ³⁰, otitis externa ³¹ and temporomandibular disorders ³². The presence of

swelling in the external auditory canal may amplify tinnitus and must be ruled out with a thorough examination of the ears.

Within the middle ear, diseases of the ossicles may result in conductive hearing loss that results in a subjective tinnitus³³. Patients with otosclerosis may describe a hearing loss which appears to improve in noisy environments. Otosclerosis may present in young or middle-aged adults and may be inherited in an autosomal dominant manner³⁴.

Damage to cochlear hair cells encompasses some of the most common causes of subjective tinnitus. Noise-induced hearing loss involves damage to cochlear hair cell from exposure to loud sounds in the environment, ranging from close proximity to explosions to overuse of headphones playing music at a high volume, and the severity of the tinnitus has been found to be associated with the degree of hearing loss³⁵. These noise-induced insults may occur in children and young adults. In contrast, age-related hearing loss involves degeneration of cochlear hair cells, especially those in the higher frequency ranges, and may result in tinnitus corresponding to the frequencies of lost hearing³⁶.

Other components of the cochlea may be affected in addition to the hair cells that can result in hearing loss and subjective tinnitus. In Ménière's disease, there is an excessive accumulation of endolymph in the membranous labyrinth of the cochlea that leads to episodes of tinnitus, vertigo and progressive hearing loss³⁷. Tinnitus in these subjects may vary over time, and reported handicap resulting from tinnitus has been found to associate with the stage of Ménière's disease³⁸.

Compression of the auditory nerve itself may result in increased firing of afferent neurons to the auditory cortex, leading to a gradual or abrupt onset of subjective tinnitus. Tumors within the internal auditory canal may lead to tinnitus and hearing loss^{39,40}. Vestibular schwannomas, or acoustic neuromas, arise from the Schwann cells surrounding the eighth cranial nerve, resulting in both hearing loss and tinnitus as well as vertigo and disturbances in balance⁴¹. Patients with a strong suspicion for acoustic neuroma should undergo contrast-enhanced imaging to both make a diagnosis as well as to monitor the growth of the tumor, which tends to be slow⁴². The surgical resection of acoustic neuromas may also result in hearing loss and tinnitus from direct damage to the auditory nerve⁴³.

Involvement of the cerebral cortex and brainstem through tumors and infarctions may result in subjective tinnitus. Tumors of the inferior colliculus⁴⁴ and within the cerebellopontine angle⁴⁵ may cause tinnitus with auditory symptoms. Infarctions of the inferior colliculus⁴⁶, cerebellum⁴⁷, and the basal ganglia, thalamus and pons of the cerebral cortex⁴⁸ have been associated with subjective tinnitus.

There are a number of systemic illnesses that are known to cause subjective tinnitus. Anemia may result in a cerebral hypoxia that can cause symptoms of tinnitus, vertigo and headache, as in the setting of cancer-related anemia⁴⁹. Hyperlipidemia may cause or worsen tinnitus, and lowering blood cholesterol levels has been found to improve subjective tinnitus⁵⁰. Patients with low thyroid function may report some degree of hearing loss with tinnitus⁵¹. Multiple sclerosis may manifest with hearing impairment with tinnitus^{52,53}. Syphilis may manifest in otologic symptoms in both early and late stages of the disease. The presence of otosyphilis may be characterized by hearing loss or hyperacusis with tinnitus along with vestibular disturbances⁵⁴.

Medications from nearly every major category may result in ototoxicity and tinnitus. The use of salicylates, such as aspirin, may result in damage to the cochlea spiral ganglion neurons⁵⁵ and changes in cochlear NMDA receptor currents⁵⁶. Aminoglycoside antibiotics, such as gentamicin, are well known to cause hearing loss and vestibular damage⁵⁷. Loop

diuretics, such as furosemide, may result in transient or permanent ototoxicity, and these effects may be minimized by delivery with slow infusion rather than bolus injection or using divided oral doses ⁵⁸. Additionally, many chemotherapeutic agents ⁵⁹, heavy metals ^{60,61} and anti-malarial drugs ^{62,63} may contribute to hearing loss and tinnitus.

Finally, psychiatric stressors may worsen the handicap resulting from subjective tinnitus. Depression ⁶⁴ and fibromyalgia ⁶⁵ have been found to associate with and exacerbate chronic tinnitus. It should be noted that subjective tinnitus generally differs from auditory hallucinations observed in psychotic disorders by the nature of the perceived sound; tinnitus generally manifests as a more simple ringing or humming, whereas auditory hallucinations tend to involve more complex sounds or speech ⁶⁶.

4. Diagnostic evaluation of tinnitus

The main goal of the evaluation of tinnitus in the emergency department is to identify life-threatening causes, preserve hearing, identify causes that are treatable, and provide the appropriate referral and symptomatic treatment. The initial evaluation of tinnitus begins with a complete history, including the onset, location, characteristics, associated symptoms, pattern, alleviating/exacerbating factors, past medical history and surgeries, and medication use. The onset of tinnitus should be characterized as sudden versus gradual. A sudden onset of tinnitus is concerning, and may indicate a vascular or traumatic etiology. Questions regarding the pattern of tinnitus should attempt to differentiate pulsatile from continuous or episodic tinnitus. Pulsatile tinnitus is frequently due to a vascular source whereas Ménière's disease tends to be episodic. Specific associated symptoms to inquire about include hearing loss, vertigo, and aural fullness. The impact of patient positioning on the tinnitus should be asked; specifically, eustachian tube dysfunction is often alleviated by lying down. A past medical history of hyperlipidemia or diabetes may indicate carotid artery atherosclerosis, whereas a thyroid disorder or anemia may suggest a high output cause. Finally, a number of medications are known to cause tinnitus.

A thorough head and neck exam should be performed on all patients presenting with tinnitus. A search for an objective source of tinnitus should be performed by auscultation of the auricular region, the mastoid, and the carotid arteries. Objective tinnitus secondary to a venous etiology is identified by disappearance of the sound when the ipsilateral jugular vein is compressed. Careful otoscopy should be performed to evaluate for middle-ear infection, cerumen impaction, a dehiscent jugular bulb, or glomus tumor. The oral cavity should be examined for contractions of the palatal muscles. The cranial nerves should be evaluated for evidence of hearing loss or brainstem dysfunction. Finally, a fundoscopic exam should be performed to look for papilledema in suspected cases of pseudotumor cerebri.

Diagnostic testing should be guided by the results of the history and physical examination. A complete blood count and thyroid function tests may reveal conditions that cause increased cardiac output and cerebral blood flow that can result in tinnitus. Contrast enhanced computed tomography (CT) should be performed on patients with a tympanic mass visible on otoscopy, which may reveal jugular bulb abnormalities, glomus tumors, and vascular abnormalities. CT or MR angiography may be needed to diagnose dissecting aneurysms and arteriovenous fistulas. Carotid ultrasonography may confirm suspected carotid atherosclerotic artery disease. A lumbar puncture should be performed in patients who are being considered for a diagnosis of pseudotumor cerebri. The suggested approach to patients with tinnitus is depicted in Figures 1 and 2.

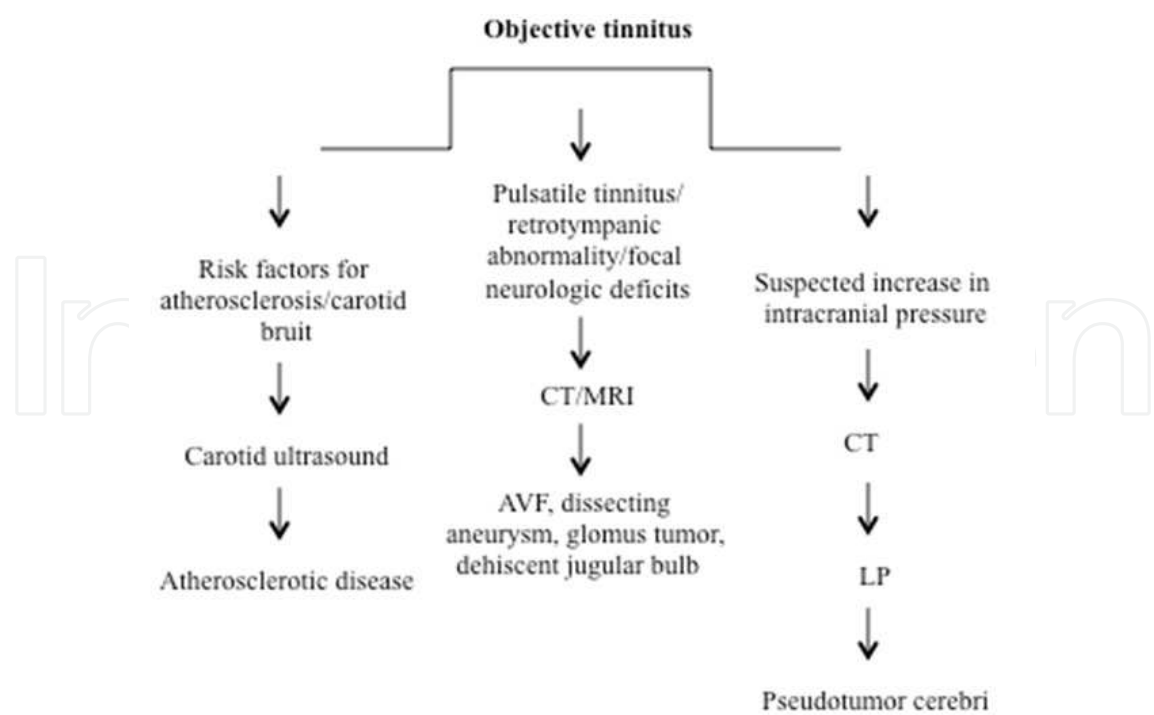


Fig. 1. Suggested approach to objective tinnitus in the emergency department.

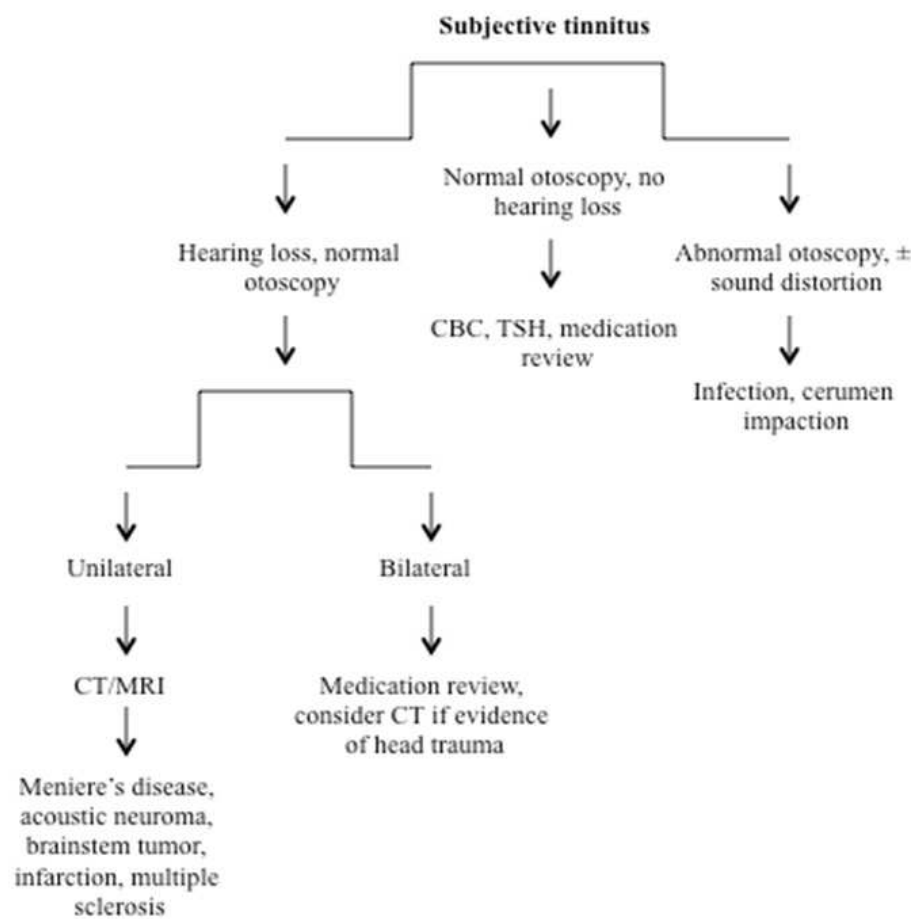


Fig. 2. Suggested approach to subjective tinnitus in the emergency department.

5. Management

The management of tinnitus first involves treating identified underlying causes. Tinnitus secondary to ototoxic medications may resolve after discontinuing the medication. Patients with arteriovenous fistula or dehiscent jugular bulb may be treated with vessel ligation or embolization. Those with glomus tumors can be referred for surgical resection or angiographic embolization. Carotid endarterectomy may benefit patients with tinnitus secondary to carotid artery atherosclerosis if the carotid artery stenosis is greater than 60%⁶⁷⁻⁶⁹. Patients with benign venous hums or arterial bruits may simply need reassurance, but may be referred for surgical ligation of the vessel if the tinnitus causes significant reduction in quality of life.

Patients with pseudotumor cerebri require intense follow-up with neurology and ophthalmology⁷⁰. While lumbar punctures provide temporary relief, the benefit is short-term due to the rapid reformation of CSF and is not recommended as the primary therapy because of potential complications. Medical management involves treatment with carbonic anhydrase inhibitors, specifically acetazolamide at starting at doses of 500 mg twice daily⁷¹. Loop diuretics such as furosemide (20 - 40 mg/day in adults) are an adjunctive therapy⁷². Weight reduction also improves symptoms and is a critical component of management⁷³⁻⁷⁵. Patients with palatal myoclonus or eustachian tube dysfunction should be referred to an otolaryngologist for management. Injection of botulinum toxin into the palate has been successful for patients with tinnitus secondary to palatal muscle myoclonus⁷⁶. Eustachian tube dysfunction may be managed by treatment with mucosal irritants such as tetracycline to the nose that cause disruption of the orifice of the eustachian tube¹⁵; alternatively, the nasopharyngeal orifice may be surgically closed⁷⁷ or silicone plugs placed through the middle ear⁷⁸.

Unfortunately, there are very few effective treatments specifically for tinnitus. Gabapentin resulted in a significant improvement in tinnitus annoyance scores for patients with tinnitus secondary to trauma⁷⁹, but does not appear to be effective in relieving idiopathic tinnitus^{79,80}. Alprazolam was reported to decrease the loudness of tinnitus in one trial⁸¹, whereas a more recent study failed to find an effect on tinnitus loudness or the Tinnitus Handicap Inventory⁸². Clinical trials of the tricyclic antidepressant nortriptyline significantly reduced tinnitus, depression, and the resulting disability^{83,84}. However, caution should be used with prescribing these drugs in the emergency department due to the dangers of overdose in suicidal patients.

Many experimental therapies warrant consideration in patients with tinnitus unresponsive to medications. The use of repetitive transcranial magnetic stimulation (rTMS) to stimulate regions in and around temporal auditory cortex has had some success in cases of chronic tinnitus⁸⁵⁻⁸⁷. Finally, behavioral based therapies such as tinnitus retraining therapy, masking devices, and biofeedback therapy have reported success^{10,88}; consideration should be given to referring patients to providers who can provide these interventions.

6. References

- [1] Liyanage SH, Singh A, Savundra P, Kalan A. Pulsatile tinnitus. *The Journal of laryngology and otology*. 2006 Feb;120(2):93-7.
- [2] Lewis JE, Stephens SD, McKenna L. Tinnitus and suicide. *Clinical otolaryngology and allied sciences*. 1994 Feb;19(1):50-4.


- [3] Crummer RW, Hassan GA. Diagnostic approach to tinnitus. *American family physician*. 2004 Jan 1;69(1):120-6.
- [4] Shargorodsky J, Curhan GC, Farwell WR. Prevalence and characteristics of tinnitus among US adults. *The American journal of medicine*. 2010 Aug;123(8):711-8.
- [5] Adams PF, Hendershot GE, Marano MA. Current estimates from the National Health Interview Survey, 1996. *Vital and health statistics Series 10, Data from the National Health Survey*. 1999 Oct(200):1-203.
- [6] Crocetti A, Forti S, Ambrosetti U, Bo LD. Questionnaires to evaluate anxiety and depressive levels in tinnitus patients. *Otolaryngology--head and neck surgery : official journal of American Academy of Otolaryngology-Head and Neck Surgery*. 2009 Mar;140(3):403-5.
- [7] Folmer RL, Griest SE, Meikle MB, Martin WH. Tinnitus severity, loudness, and depression. *Otolaryngology--head and neck surgery : official journal of American Academy of Otolaryngology-Head and Neck Surgery*. 1999 Jul;121(1):48-51.
- [8] Schleuning AJ, 2nd. Management of the patient with tinnitus. *The Medical clinics of North America*. 1991 Nov;75(6):1225-37.
- [9] Tyler RS, Baker LJ. Difficulties experienced by tinnitus sufferers. *The Journal of speech and hearing disorders*. 1983 May;48(2):150-4.
- [10] Lockwood AH, Salvi RJ, Burkard RF. Tinnitus. *The New England journal of medicine*. 2002 Sep 19;347(12):904-10.
- [11] Axelsson A, Ringdahl A. Tinnitus--a study of its prevalence and characteristics. *British journal of audiology*. 1989 Feb;23(1):53-62.
- [12] Nondahl DM, Cruickshanks KJ, Wiley TL, Klein R, Klein BE, Tweed TS. Prevalence and 5-year incidence of tinnitus among older adults: the epidemiology of hearing loss study. *Journal of the American Academy of Audiology*. 2002 Jun;13(6):323-31.
- [13] Shetye A, Kennedy V. Tinnitus in children: an uncommon symptom? *Archives of disease in childhood*. 2010 Aug;95(8):645-8.
- [14] Seidman MD, Standring RT, Dornhoffer JL. Tinnitus: current understanding and contemporary management. *Current opinion in otolaryngology & head and neck surgery*. 2010 Oct;18(5):363-8.
- [15] Fortune DS, Haynes DS, Hall JW, 3rd. Tinnitus. Current evaluation and management. *The Medical clinics of North America*. 1999 Jan;83(1):153-62, x.
- [16] Madani G, Connor SE. Imaging in pulsatile tinnitus. *Clinical radiology*. 2009 Mar;64(3):319-28.
- [17] Sismanis A. Pulsatile tinnitus. *Otolaryngologic clinics of North America*. 2003 Apr;36(2):389-402, viii.
- [18] Sismanis A, Stamm MA, Sobel M. Objective tinnitus in patients with atherosclerotic carotid artery disease. *The American journal of otology*. 1994 May;15(3):404-7.
- [19] Herzog JA, Bailey S, Meyer J. Vascular loops of the internal auditory canal: a diagnostic dilemma. *The American journal of otology*. 1997 Jan;18(1):26-31.
- [20] Wall M, George D. Idiopathic intracranial hypertension. A prospective study of 50 patients. *Brain : a journal of neurology*. 1991 Feb;114 (Pt 1A):155-80.
- [21] Rudnick E, Sismanis A. Pulsatile tinnitus and spontaneous cerebrospinal fluid rhinorrhea: indicators of benign intracranial hypertension syndrome. *Otology & neurotology : official publication of the American Otological Society, American*

- Neurotology Society [and] European Academy of Otolaryngology and Neurotology. 2005 Mar;26(2):166-8.
- [22] Wang SJ, Silberstein SD, Patterson S, Young WB. Idiopathic intracranial hypertension without papilledema: a case-control study in a headache center. *Neurology*. 1998 Jul;51(1):245-9.
- [23] Mathew NT, Ravishankar K, Sanin LC. Coexistence of migraine and idiopathic intracranial hypertension without papilledema. *Neurology*. 1996 May;46(5):1226-30.
- [24] Quattrone A, Bono F, Fera F, Lavano A. Isolated unilateral abducens palsy in idiopathic intracranial hypertension without papilledema. *European journal of neurology : the official journal of the European Federation of Neurological Societies*. 2006 Jun;13(6):670-1.
- [25] Corbett JJ, Savino PJ, Thompson HS, et al. Visual loss in pseudotumor cerebri. Follow-up of 57 patients from five to 41 years and a profile of 14 patients with permanent severe visual loss. *Archives of neurology*. 1982 Aug;39(8):461-74.
- [26] Hauptert MS, Madgy DN, Belenky WM, Becker JW. Unilateral conductive hearing loss secondary to a high jugular bulb in a pediatric patient. *Ear, nose, & throat journal*. 1997 Jul;76(7):468-9.
- [27] Seidman MD, Arenberg JG, Shirwany NA. Palatal myoclonus as a cause of objective tinnitus: a report of six cases and a review of the literature. *Ear, nose, & throat journal*. 1999 Apr;78(4):292-4, 6-7.
- [28] Slack RW, Soucek SO, Wong K. Sonotubometry in the investigation of objective tinnitus and palatal myoclonus: a demonstration of eustachian tube opening. *The Journal of laryngology and otology*. 1986 May;100(5):529-31.
- [29] Hall III JW, Haynes DS. Audiologic assessment and consultation of the tinnitus patient. *Semin Hear*. 2001;22:37-50.
- [30] Folmer RL, Shi BY. Chronic tinnitus resulting from cerumen removal procedures. *Int Tinnitus J*. 2004;10(1):42-6.
- [31] Kurnatowski P, Filipiak J. Otitis externa: the analysis of relationship between particular signs/symptoms and species and genera of identified microorganisms. *Wiad Parazytol*. 2008;54(1):37-41.
- [32] Bernhardt O, Mundt T, Welk A, et al. Signs and symptoms of temporomandibular disorders and the incidence of tinnitus. *J Oral Rehabil*. 2011 Apr 23.
- [33] Deggouj N, Castelein S, Gerard JM, Decat M, Gersdorff M. Tinnitus and otosclerosis. *B-ENT*. 2009;5(4):241-4.
- [34] Ealy M, Smith RJ. Otosclerosis. *Adv Otorhinolaryngol*. 2011;70:122-9.
- [35] Mazurek B, Olze H, Haupt H, Szczepek AJ. The more the worse: the grade of noise-induced hearing loss associates with the severity of tinnitus. *Int J Environ Res Public Health*. 2010 Aug;7(8):3071-9.
- [36] Nicolas-Puel C, Faulconbridge RL, Guitton M, Puel JL, Mondain M, Uziel A. Characteristics of tinnitus and etiology of associated hearing loss: a study of 123 patients. *Int Tinnitus J*. 2002;8(1):37-44.
- [37] Semaan MT, Megerian CA. Meniere's disease: a challenging and relentless disorder. *Otolaryngol Clin North Am*. 2011 Apr;44(2):383-403, ix.
- [38] Sanchez RI, Perez Garrigues H, Rodriguez Rivera V. Clinical characteristics of tinnitus in Meniere's disease. *Acta Otorrinolaringol Esp*. 2010;61(5):327-31.

- [39] Ishikawa T, Kawamata T, Kawashima A, et al. Meningioma of the internal auditory canal with rapidly progressive hearing loss: case report. *Neurol Med Chir (Tokyo)*. 2011;51(3):233-5.
- [40] Wuertenberger CJ, Rosahl SK. Vertigo and tinnitus caused by vascular compression of the vestibulocochlear nerve, not intracanalicular vestibular schwannoma: review and case presentation. *Skull Base*. 2009 Nov;19(6):417-24.
- [41] Agrawal Y, Clark JH, Limb CJ, Niparko JK, Francis HW. Predictors of vestibular schwannoma growth and clinical implications. *Otol Neurotol*. 2010 Jul;31(5):807-12.
- [42] Sriskandan N, Connor SE. The role of radiology in the diagnosis and management of vestibular schwannoma. *Clin Radiol*. 2011 Apr;66(4):357-65.
- [43] Cope TE, Baguley DM, Moore BC. Tinnitus Loudness in Quiet and Noise After Resection of Vestibular Schwannoma. *Otol Neurotol*. 2011 Jan 8.
- [44] Missori P, Delfini R, Cantore G. Tinnitus and hearing loss in pineal region tumours. *Acta Neurochir (Wien)*. 1995;135(3-4):154-8.
- [45] Hodges TR, Karikari IO, Nimjee SM, Tibaleka J, Cummings TJ, Friedman AH. Calcifying Pseudoneoplasm of the Cerebellopontine Angle: Case Report. *Neurosurgery*. 2011 Mar 15.
- [46] Choi SY, Song JJ, Hwang JM, Kim JS. Tinnitus in fourth nerve palsy: an indicator for an intra-axial lesion. *J Neuroophthalmol*. 2010 Dec;30(4):325-7.
- [47] Martines F, Dispenza F, Gagliardo C, Martines E, Bentivegna D. Sudden sensorineural hearing loss as prodromal symptom of anterior inferior cerebellar artery infarction. *ORL J Otorhinolaryngol Relat Spec*. 2011;73(3):137-40.
- [48] Sugiura S, Uchida Y, Nakashima T, Yoshioka M, Ando F, Shimokata H. Tinnitus and brain MRI findings in Japanese elderly. *Acta Otolaryngol*. 2008 May;128(5):525-9.
- [49] Cunningham RS. Anemia in the oncology patient: cognitive function and cancer. *Cancer Nurs*. 2003 Dec;26(6 Suppl):38S-42S.
- [50] Olzowy B, Canis M, Hempel JM, Mazurek B, Suckfull M. Effect of atorvastatin on progression of sensorineural hearing loss and tinnitus in the elderly: results of a prospective, randomized, double-blind clinical trial. *Otol Neurotol*. 2007 Jun;28(4):455-8.
- [51] Bhatia PL, Gupta OP, Agrawal MK, Mishr SK. Audiological and vestibular function tests in hypothyroidism. *Laryngoscope*. 1977 Dec;87(12):2082-9.
- [52] Nishida H, Tanaka Y, Okada M, Inoue Y. Evoked otoacoustic emissions and electrocochleography in a patient with multiple sclerosis. *Ann Otol Rhinol Laryngol*. 1995 Jun;104(6):456-62.
- [53] Rodriguez-Casero MV, Mandelstam S, Kornberg AJ, Berkowitz RG. Acute tinnitus and hearing loss as the initial symptom of multiple sclerosis in a child. *Int J Pediatr Otorhinolaryngol*. 2005 Jan;69(1):123-6.
- [54] Yimtae K, Srirompotong S, Lertsukprasert K. Otosyphilis: a review of 85 cases. *Otolaryngol Head Neck Surg*. 2007 Jan;136(1):67-71.
- [55] Wei L, Ding D, Salvi R. Salicylate-induced degeneration of cochlea spiral ganglion neurons-apoptosis signaling. *Neuroscience*. 2010 Jun 16;168(1):288-99.
- [56] Puel JL. Cochlear NMDA receptor blockade prevents salicylate-induced tinnitus. *B-ENT*. 2007;3 Suppl 7:19-22.
- [57] Xie J, Talaska AE, Schacht J. New developments in aminoglycoside therapy and ototoxicity. *Hear Res*. 2011 May 27.

- [58] Rybak LP. Pathophysiology of furosemide ototoxicity. *J Otolaryngol.* 1982 Apr;11(2):127-33.
- [59] Dille MF, Konrad-Martin D, Gallun F, et al. Tinnitus onset rates from chemotherapeutic agents and ototoxic antibiotics: results of a large prospective study. *J Am Acad Audiol.* 2010 Jun;21(6):409-17.
- [60] Arda HN, Tuncel U, Akdogan O, Ozluoglu LN. The role of zinc in the treatment of tinnitus. *Otol Neurotol.* 2003 Jan;24(1):86-9.
- [61] Kim SJ, Jeong HJ, Myung NY, et al. The protective mechanism of antioxidants in cadmium-induced ototoxicity in vitro and in vivo. *Environ Health Perspect.* 2008 Jul;116(7):854-62.
- [62] Ralli M, Lobarinas E, Fetoni AR, Stolzberg D, Paludetti G, Salvi R. Comparison of salicylate- and quinine-induced tinnitus in rats: development, time course, and evaluation of audiologic correlates. *Otol Neurotol.* 2010 Jul;31(5):823-31.
- [63] Bortoli R, Santiago M. Chloroquine ototoxicity. *Clin Rheumatol.* 2007 Nov;26(11):1809-10.
- [64] Langguth B, Landgrebe M, Kleinjung T, Sand GP, Hajak G. Tinnitus and depression. *World J Biol Psychiatry.* 2011 May 13.
- [65] Waylonis GW, Heck W. Fibromyalgia syndrome. New associations. *Am J Phys Med Rehabil.* 1992 Dec;71(6):343-8.
- [66] Shergill SS, Brammer MJ, Fukuda R, Williams SC, Murray RM, McGuire PK. Engagement of brain areas implicated in processing inner speech in people with auditory hallucinations. *Br J Psychiatry.* 2003 Jun;182:525-31.
- [67] Endarterectomy for asymptomatic carotid artery stenosis. Executive Committee for the Asymptomatic Carotid Atherosclerosis Study. *JAMA : the journal of the American Medical Association.* 1995 May 10;273(18):1421-8.
- [68] Halliday A, Mansfield A, Marro J, et al. Prevention of disabling and fatal strokes by successful carotid endarterectomy in patients without recent neurological symptoms: randomised controlled trial. *Lancet.* 2004 May 8;363(9420):1491-502.
- [69] Hobson RW, 2nd, Weiss DG, Fields WS, et al. Efficacy of carotid endarterectomy for asymptomatic carotid stenosis. The Veterans Affairs Cooperative Study Group. *The New England journal of medicine.* 1993 Jan 28;328(4):221-7.
- [70] Wall M. Sensory visual testing in idiopathic intracranial hypertension: measures sensitive to change. *Neurology.* 1990 Dec;40(12):1859-64.
- [71] Kesler A, Hadayer A, Goldhammer Y, Almog Y, Korczyn AD. Idiopathic intracranial hypertension: risk of recurrences. *Neurology.* 2004 Nov 9;63(9):1737-9.
- [72] Lee AG, Anderson R, Kardon RH, Wall M. Presumed "sulfa allergy" in patients with intracranial hypertension treated with acetazolamide or furosemide: cross-reactivity, myth or reality? *American journal of ophthalmology.* 2004 Jul;138(1):114-8.
- [73] Newborg B. Pseudotumor cerebri treated by rice reduction diet. *Archives of internal medicine.* 1974 May;133(5):802-7.
- [74] Kupersmith MJ, Gamell L, Turbin R, Peck V, Spiegel P, Wall M. Effects of weight loss on the course of idiopathic intracranial hypertension in women. *Neurology.* 1998 Apr;50(4):1094-8.

- [75] Johnson LN, Krohel GB, Madsen RW, March GA, Jr. The role of weight loss and acetazolamide in the treatment of idiopathic intracranial hypertension (pseudotumor cerebri). *Ophthalmology*. 1998 Dec;105(12):2313-7.
- [76] Bryce GE, Morrison MD. Botulinum toxin treatment of essential palatal myoclonus tinnitus. *The Journal of otolaryngology*. 1998 Aug;27(4):213-6.
- [77] Orlandi RR, Shelton C. Endoscopic closure of the eustachian tube. *American journal of rhinology*. 2004 Nov-Dec;18(6):363-5.
- [78] Sato T, Kawase T, Yano H, Suetake M, Kobayashi T. Trans-tympanic silicone plug insertion for chronic patulous Eustachian tube. *Acta oto-laryngologica*. 2005 Nov;125(11):1158-63.
- [79] Bauer CA, Brozoski TJ. Effect of gabapentin on the sensation and impact of tinnitus. *The Laryngoscope*. 2006 May;116(5):675-81.
- [80] Piccirillo JF, Finnell J, Vlahiotis A, Chole RA, Spitznagel E, Jr. Relief of idiopathic subjective tinnitus: is gabapentin effective? *Archives of otolaryngology--head & neck surgery*. 2007 Apr;133(4):390-7.
- [81] Johnson RM, Brummett R, Schleuning A. Use of alprazolam for relief of tinnitus. A double-blind study. *Archives of otolaryngology--head & neck surgery*. 1993 Aug;119(8):842-5.
- [82] Jalali MM, Kousha A, Naghavi SE, Soleimani R, Banan R. The effects of alprazolam on tinnitus: a cross-over randomized clinical trial. *Medical science monitor : international medical journal of experimental and clinical research*. 2009 Nov;15(11):PI55-60.
- [83] Sullivan M, Katon W, Russo J, Dobie R, Sakai C. A randomized trial of nortriptyline for severe chronic tinnitus. Effects on depression, disability, and tinnitus symptoms. *Archives of internal medicine*. 1993 Oct 11;153(19):2251-9.
- [84] Dobie RA, Sakai CS, Sullivan MD, Katon WJ, Russo J. Antidepressant treatment of tinnitus patients: report of a randomized clinical trial and clinical prediction of benefit. *The American journal of otology*. 1993 Jan;14(1):18-23.
- [85] De Ridder D. Should rTMS for tinnitus be performed left-sided, ipsilaterally or contralaterally, and is it a treatment or merely investigational? *Eur J Neurol*. 2010 Jul;17(7):891-2.
- [86] Meeus OM, De Ridder D, Van de Heyning PH. Transcranial magnetic stimulation (TMS) in tinnitus patients. *B-ENT*. 2009;5(2):89-100.
- [87] Khedr EM, Rothwell JC, El-Atar A. One-year follow up of patients with chronic tinnitus treated with left temporoparietal rTMS. *Eur J Neurol*. 2009 Mar;16(3):404-8.
- [88] Andersson G, Lyttkens L. A meta-analytic review of psychological treatments for tinnitus. *British journal of audiology*. 1999 Aug;33(4):201-10.



Up to Date on Tinnitus

Edited by Prof. Fayeze Bahmad

ISBN 978-953-307-655-3

Hard cover, 186 pages

Publisher InTech

Published online 22, December, 2011

Published in print edition December, 2011

Up to Date on Tinnitus encompasses both theoretical background on the different forms of tinnitus and a detailed knowledge on state-of-the-art treatment for tinnitus, written for clinicians by clinicians and researchers. Realizing the complexity of tinnitus has highlighted the importance of interdisciplinary research. Therefore, all the authors contributing to the this book were chosen from many specialties of medicine including surgery, psychology, and neuroscience, and came from diverse areas of expertise, such as Neurology, Otolaryngology, Psychiatry, Clinical and Experimental Psychology and Dentistry.

How to reference

In order to correctly reference this scholarly work, feel free to copy and paste the following:

Kerry J. Welsh, Audrey R. Nath and Matthew R. Lewin (2011). Evaluation of Tinnitus in the Emergency Department, Up to Date on Tinnitus, Prof. Fayeze Bahmad (Ed.), ISBN: 978-953-307-655-3, InTech, Available from: <http://www.intechopen.com/books/up-to-date-on-tinnitus/evaluation-of-tinnitus-in-the-emergency-department>

INTech
open science | open minds

InTech Europe

University Campus STeP Ri
Slavka Krautzeka 83/A
51000 Rijeka, Croatia
Phone: +385 (51) 770 447
Fax: +385 (51) 686 166
www.intechopen.com

InTech China

Unit 405, Office Block, Hotel Equatorial Shanghai
No.65, Yan An Road (West), Shanghai, 200040, China
中国上海市延安西路65号上海国际贵都大饭店办公楼405单元
Phone: +86-21-62489820
Fax: +86-21-62489821

© 2011 The Author(s). Licensee IntechOpen. This is an open access article distributed under the terms of the [Creative Commons Attribution 3.0 License](https://creativecommons.org/licenses/by/3.0/), which permits unrestricted use, distribution, and reproduction in any medium, provided the original work is properly cited.

IntechOpen

IntechOpen