

# We are IntechOpen, the world's leading publisher of Open Access books Built by scientists, for scientists

6,900

Open access books available

185,000

International authors and editors

200M

Downloads

Our authors are among the

154

Countries delivered to

TOP 1%

most cited scientists

12.2%

Contributors from top 500 universities



WEB OF SCIENCE™

Selection of our books indexed in the Book Citation Index  
in Web of Science™ Core Collection (BKCI)

Interested in publishing with us?  
Contact [book.department@intechopen.com](mailto:book.department@intechopen.com)

Numbers displayed above are based on latest data collected.  
For more information visit [www.intechopen.com](http://www.intechopen.com)



# Posterior Ankle and Hindfoot Arthroscopy

Masato Takao  
Teikyo University  
Japan

## 1. Introduction

Hindfoot pain can be caused by any part of the posterior ankle anatomy with bony and soft tissue, including os trigonum, large posterior talar process, tenosynovitis of the flexor hallucis longus tendon, osteochondral lesions of the talus, subtalar arthritis and arthrosis, prominent calcaneus posterior process and free bodies, such as synovial chondromatosis. Because these structures are deeply situated and difficult to palpate, there remain diagnostic difficulties. Posterior ankle and hindfoot arthroscopy gives excellent access to such a posterior ankle compartment<sup>1</sup>, and it is regarded as the ideal diagnostic tool for accurate diagnosis of the hindfoot disorders. Furthermore, it is also regarded as an effective tool especially for the athletes who expect to return to their initial athletic activities with a shorter recovery time.

The arthroscopic approach to the posterior ankle was first described by Parisien and Vangsness in 1985 as a subtalar arthroscopy<sup>2</sup>. In 2000, van Dijk advanced an epoch-making technique, a two portal endoscopic approach, which makes it possible to obtain broad field of vision and working space<sup>1</sup>. Recently, posterior ankle and hindfoot arthroscopy utilizing a two portal endoscopic approach has been developed and widely used for diagnosis and treatment of hindfoot disorders. In this part, the author describes the posterior ankle and hindfoot arthroscopy utilizing a two portal endoscopic approach.

## 2. Basics and clinical applications

### 2.1 Indications

The indications of hindfoot endoscopy are posterior ankle joint pathologies including osteochondral lesions of the posterior talus, loose bodies, ossicles, posttraumatic calcification or avulsion fragment; posterior subtalar joint pathologies including osteophyte, loose bodies, osteoarthritis or intraosseous talar ganglion; periarticular pathologies including posterior ankle impingement syndrome, deltoid ligament avulsion, tenosynovitis or intratendinous ganglion of the flexor hallucis longus, tenosynovitis or partial rupture of the peroneal tendon and posterior tibial tendon, retrocalcaneal bursitis and entrapment of the tibial nerve within the tarsal tunnel<sup>3</sup>.

### 2.2 Set-up and normal anatomy

#### 2.2.1 Set-up

Hindfoot endoscopy was performed under spinal lumbar anesthesia. The patient was placed in a prone position on an operating table (Figure 1).

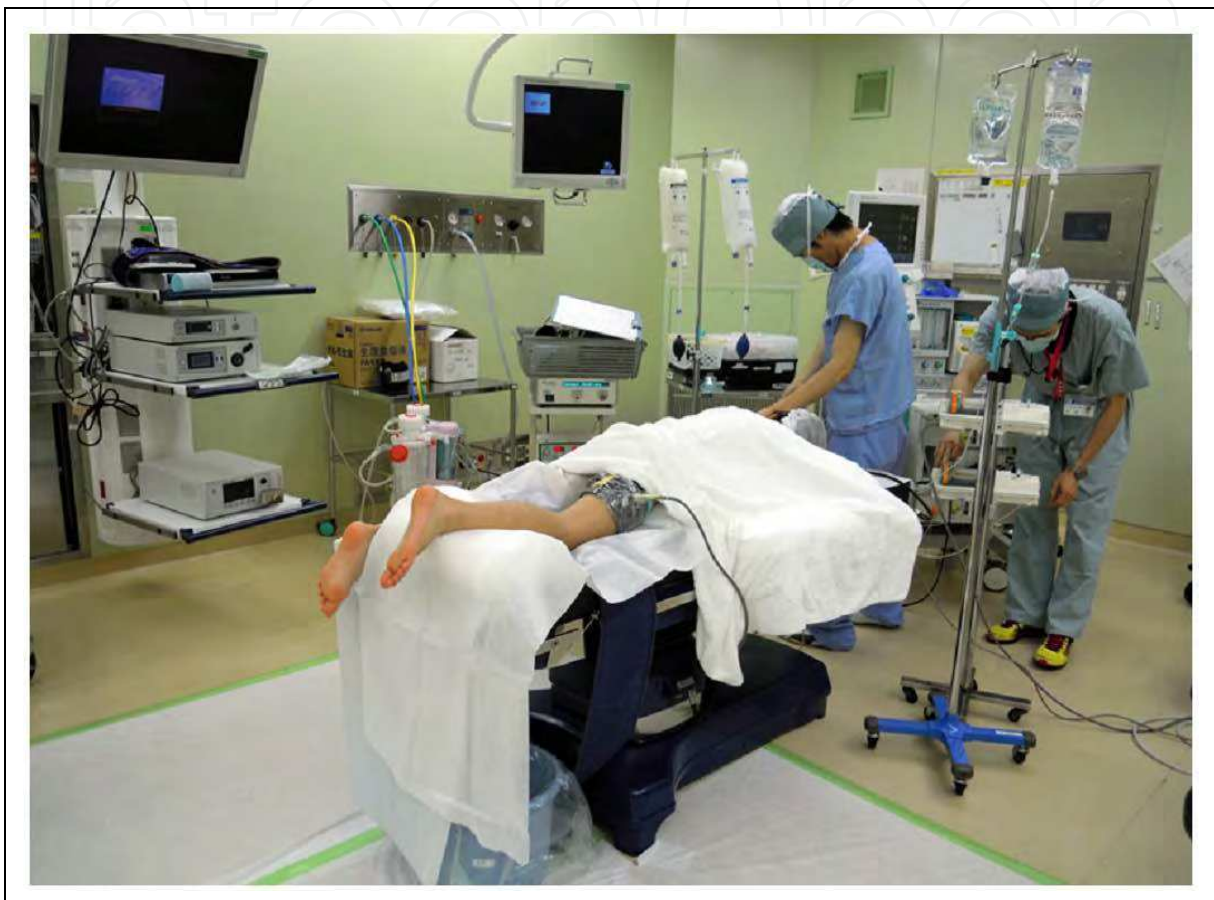


Fig. 1. Position of the patient.

A small support was placed under the lower leg. A pneumotourniquet is inflated to a pressure of 300 mm Hg. An arthroscope 4.0 mm in diameter with a 30 degree angle and the irrigation of saline with a pressure of 50 to 80 mmHg is used. Although any distraction device may not be needed in most cases, the bandage distraction technique<sup>4</sup> with a force of 78.4 Newtons (Figure 2) is beneficial in cases where it is needed to be widen the posterior talocrural joint (Figure 3).

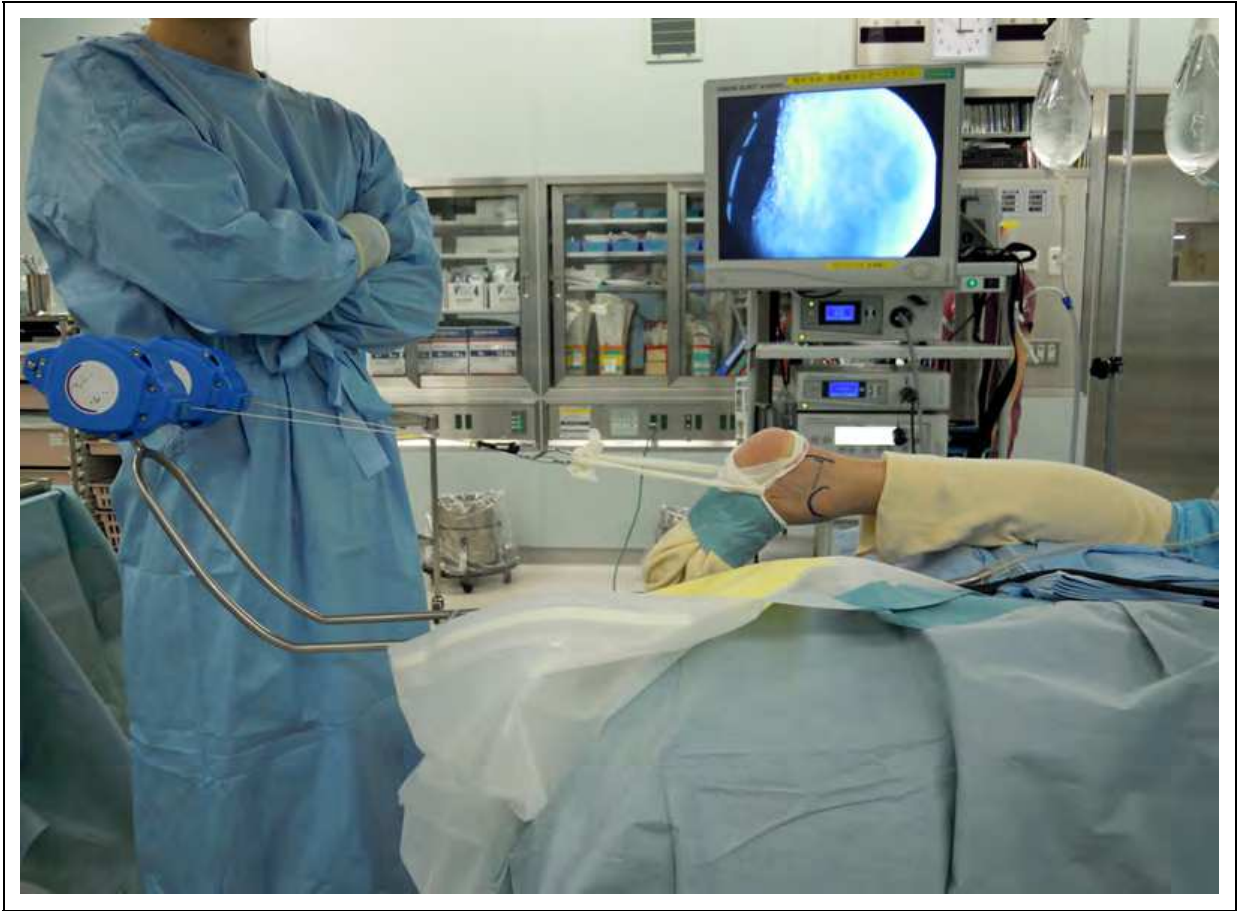

Fig. 2. Bandage distraction technique.

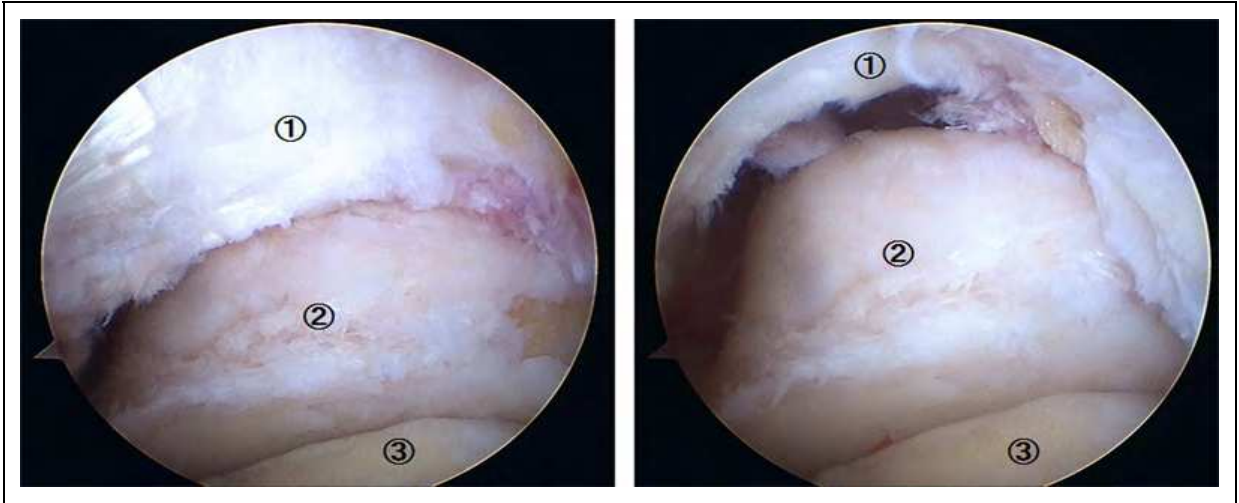


Fig. 3. Arthroscopic view of the posterior talocrural joint before distraction (left) and after distraction (right).  
1. Tibia; 2. Talus; 3. Calcaneus



### 2.2.2 Making the portal and the working space

A line was drawn from the tip of the lateral malleolus to the Achilles tendon, parallel to the sole of the foot. The posterolateral and posteromedial portals were made just above this line and 3 mm medial and lateral of the Achilles tendon using a pneumotourniquet inflated to a pressure of 300 mm Hg (Figure 4).

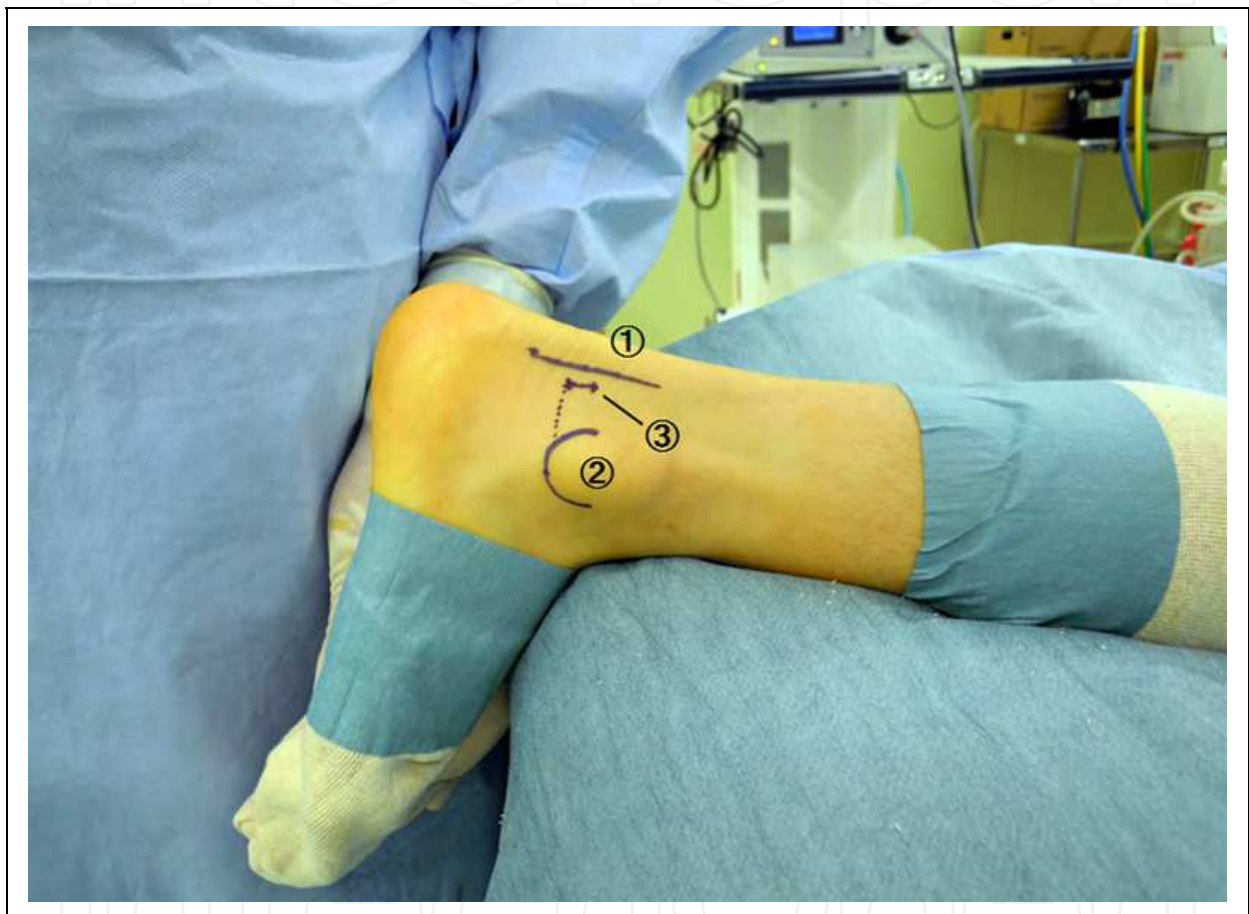

Fig. 4. Posterolateral portal.

1. Achilles tendon; 2. Lateral malleolus; 3. Posterolateral portal

If the portals are close to the Achilles tendon it may lead to tenosynovitis of the Achilles tendon. On the other hand, if the portals are too far from the Achilles tendon, it is difficult to watch the field fully. The deep layer is split by mosquito clamp via a posterolateral portal that is directed to the first web or second toe through the 1 cm vertical skin incision (Figure 5). When the tip of the clamp touches the bone, it is exchanged for a 4.5 mm arthroscope shaft with the blunt trocar to direct to the first web or second toe (Figure 6).

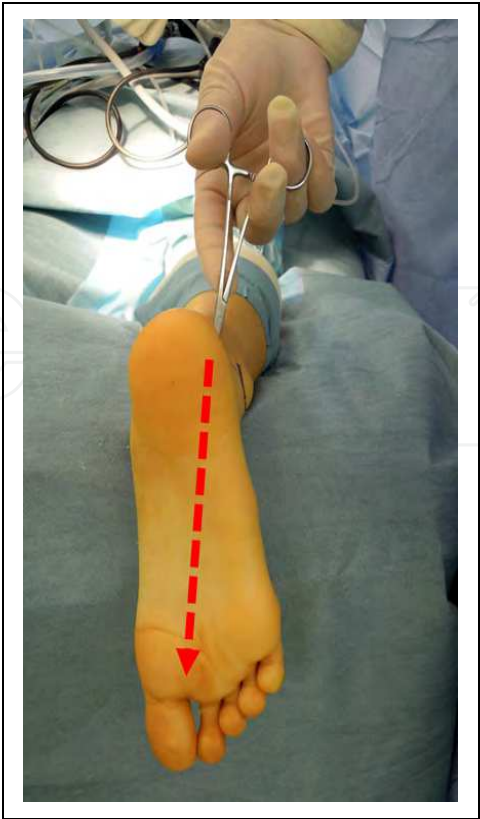


Fig. 5. Split of the deep layer by mosquito clamp directing to the first web.

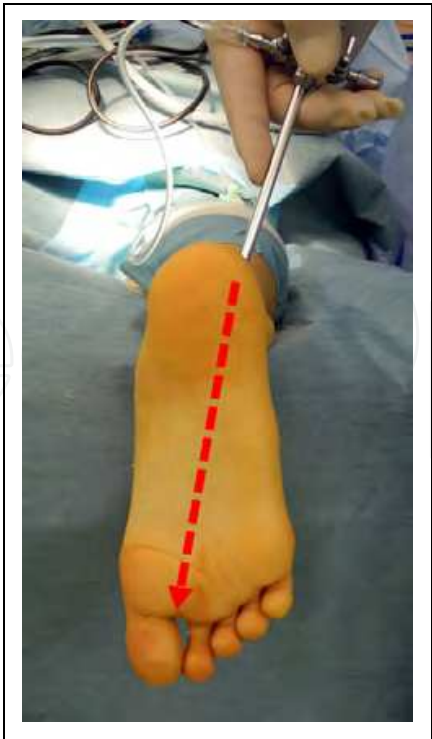


Fig. 6. Insert an arthroscope shaft with the blunt trocar directing to the first web.

The trocar is exchanged to an arthroscope 4.0 mm in diameter with a 30 degree angle. Next, a mosquito clamp is introduced via a posteromedial portal. A mosquito clamp touches the shaft of the arthroscope and the deep layer around the arthroscope is split. A 4.0 to 5.0 mm motorized shaver (full radius shaver) is inserted through the posteromedial portal in order to make the working space (Figure 7).

For bringing the shaver into the field of vision of the arthroscopy, it is helpful that the tip of the shaver touches the shaft of the arthroscope and slide distally (Figure 8).

Adipose tissue and the posterior joint capsule are removed by motorized shaver. First of all, the surgeon must show the FHL tendon (Figure 9). The neurovascular bundle lies medial to the FHL tendon, so the surgeon should perform the arthroscopic surgery laterally to the FHL tendon (Figure 10).

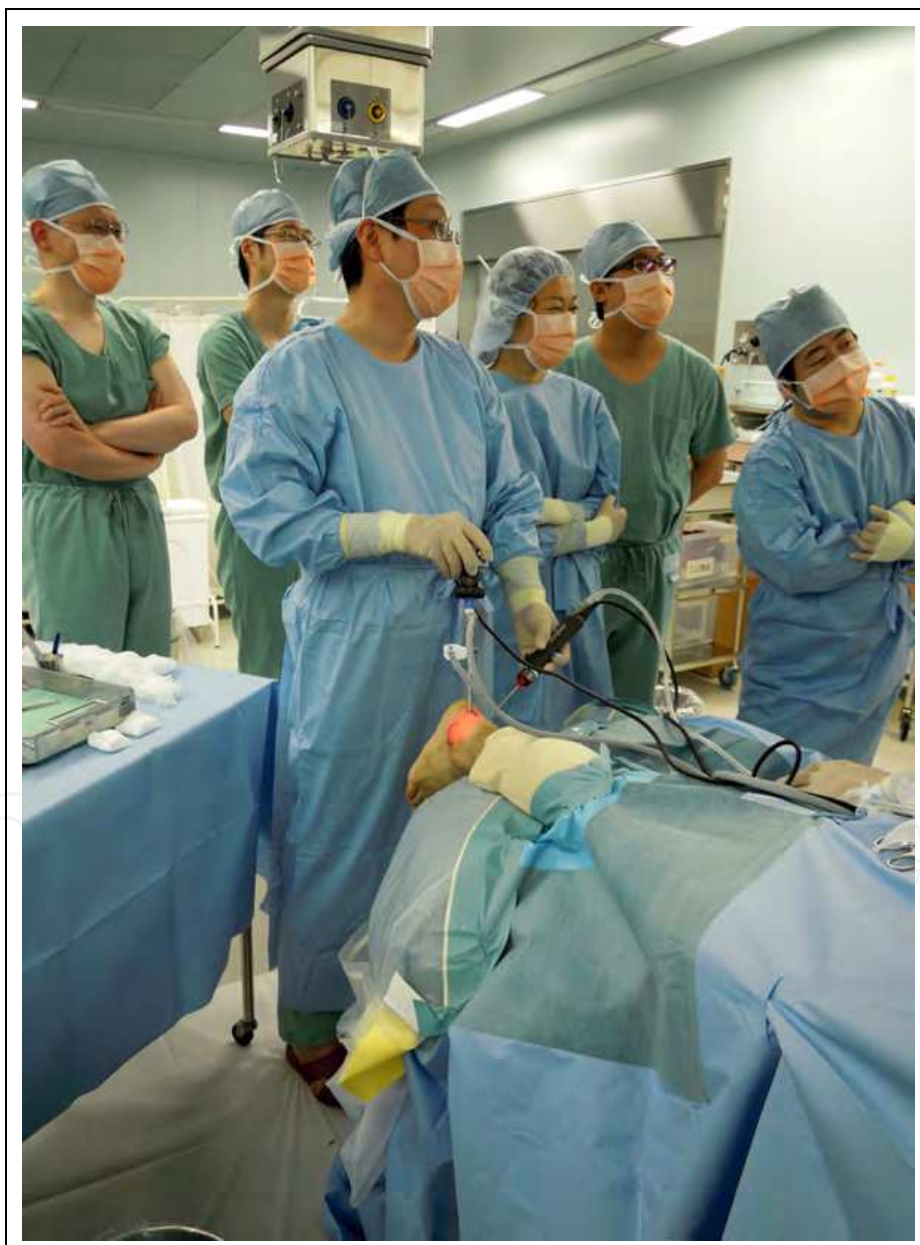

Fig. 7. Hindfoot endoscopy.

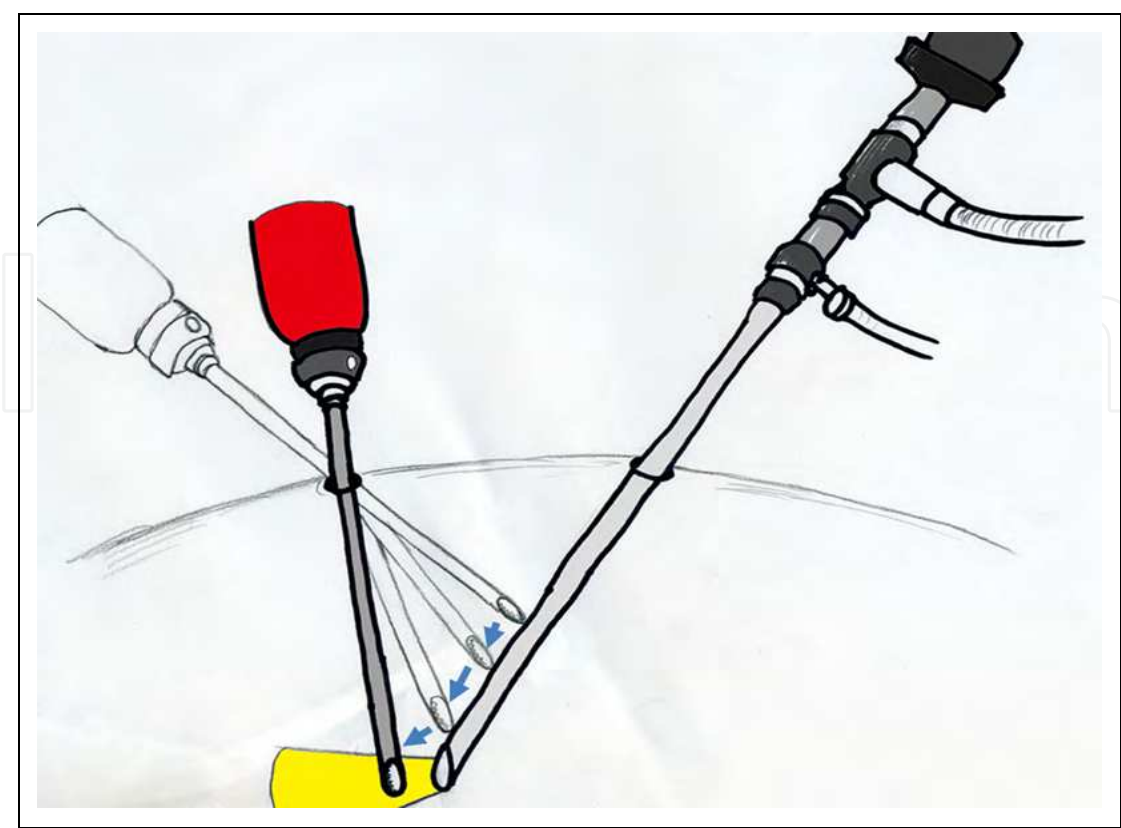


Fig. 8. Introducing the shaver into the field of vision of the arthroscopy.

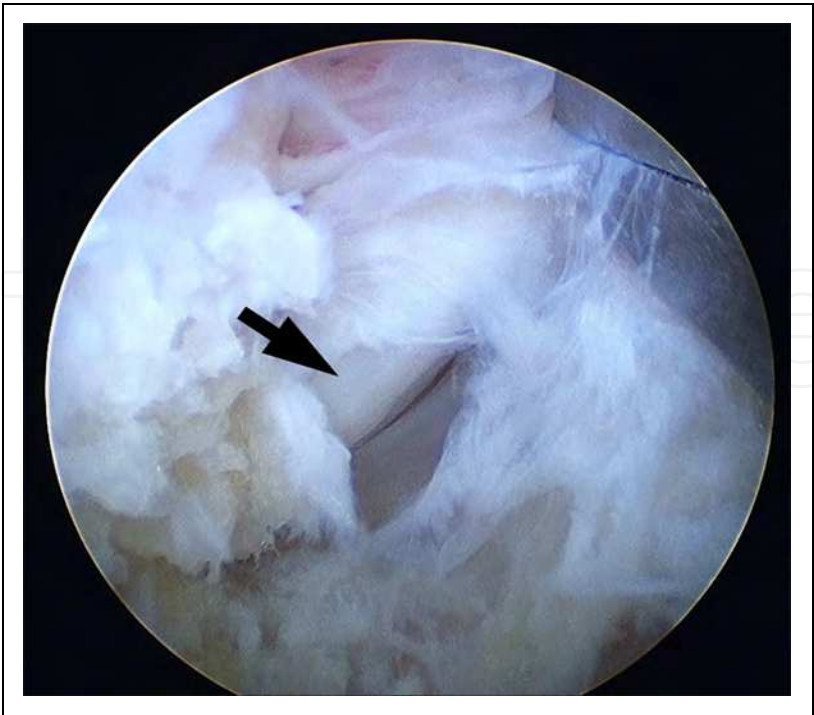


Fig. 9. Flexor hallucis longus tendon (arrow).



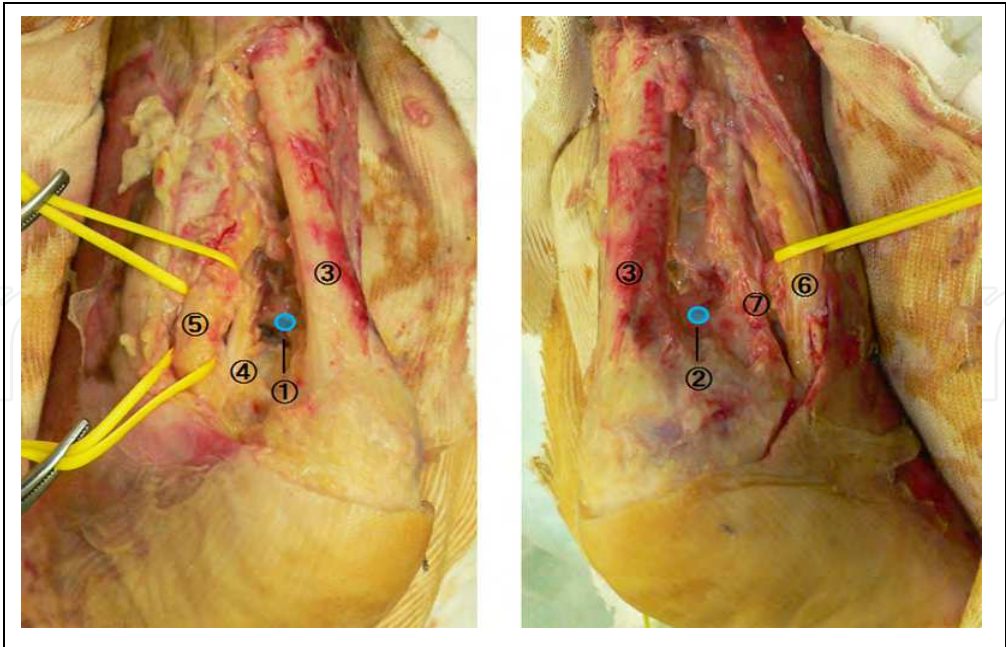


Fig. 10. Anatomic dissection of the posterior ankle around the posteromedial portal (left) and the posterolateral portal (right).

1. Posteromedial portal; 2. Posterolateral portal; 3. Achilles tendon; 4. Flexor hallucis longus tendon; 5. Tibian nerve and posterior tibial artery; 6. Sural nerve; 7. Peroneal tendon

**2.2.3 Normal anatomy**

Normal structures which can be observed via posterior two portals are shown in Figure 11<sup>5</sup>.

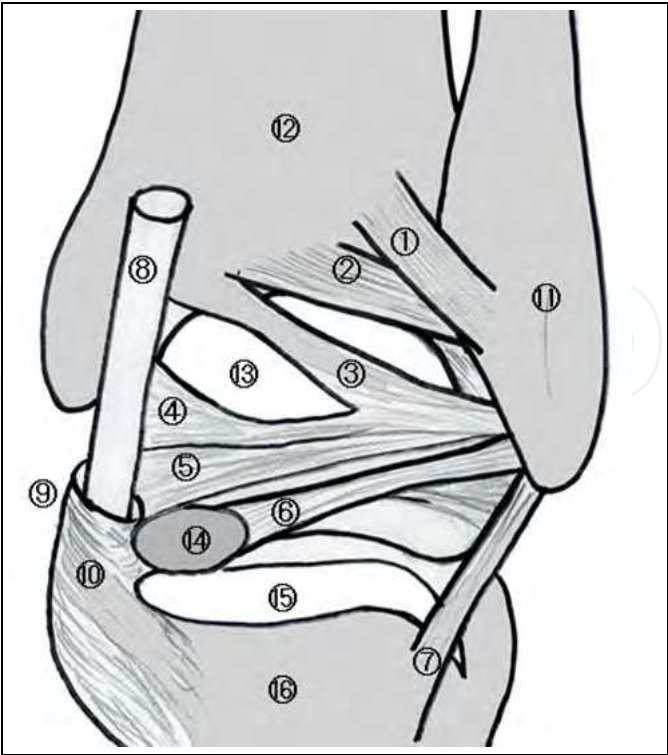


Fig. 11. Normal anatomy of the posterior ankle.

1. Superficial component of the posterior tibiofibular ligament; 2. Deep component of the posterior tibiofibular ligament or transvers ligament; 3. Tibial insertion of the posterior intermalleolar ligament; 4. Tibial malleolar insertion of the posterior intermalleolar ligament; 5. Talar insertion of the posterior intermalleolar ligament; 6. Posterior talofibular ligament; 7. Calcaneofibular ligament; 8. Flexor hallucis longus (FHL) tendon; 9. Entrance of the tarsal tunnel; 10. FHL retinaculum; 11. Lateral malleolus; 12. Tibia; 13. Posterior talar dome; 14. Posterolateral talar process; 15. Subtalar joint; 16. Calcaneus

## 2.3 Clinical applications

### 2.3.1 Posterior ankle impingement syndrome

Posterior ankle impingement syndrome (PAIS) is generally considered to be the clinical disorder characterized by posterior ankle pain in forced plantar flexion<sup>6</sup>. The etiology of this syndrome is varied and may involve any part of the posterior ankle anatomy, including bony and soft tissue structures. Among them, os trigonum and large posterior talar process are frequent (Figure 12).

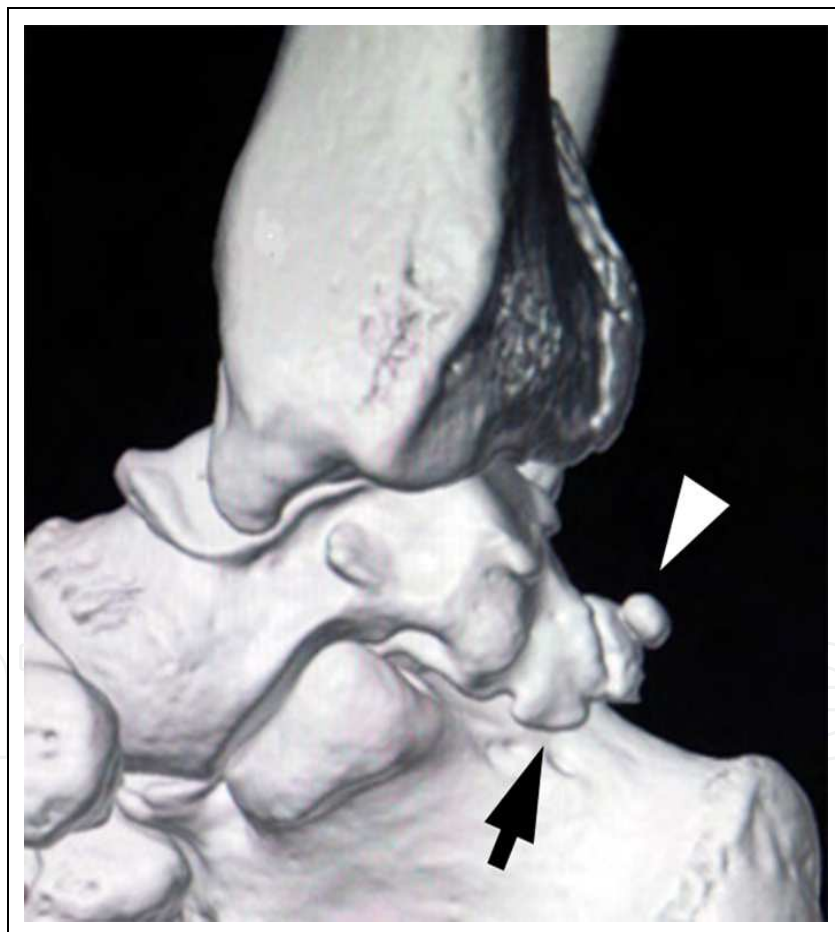


Fig. 12. Three dimensional computed tomogram of the hindfoot.

An arrow shows a large posterolateral process of the talus and an arrow head shows an os trigonum.

According to the author's experiences gained in approximately 200 cases, it should be noted that hindfoot endoscopies have shown that large posterolateral talar processes compress a

FHL tendon in most cases (Figure 13) and in some cases constrict the FHL tendon at the posteromedial part of the fibro-osseous tunnel leading to tenosynovitis of the FHL (Figure 14).

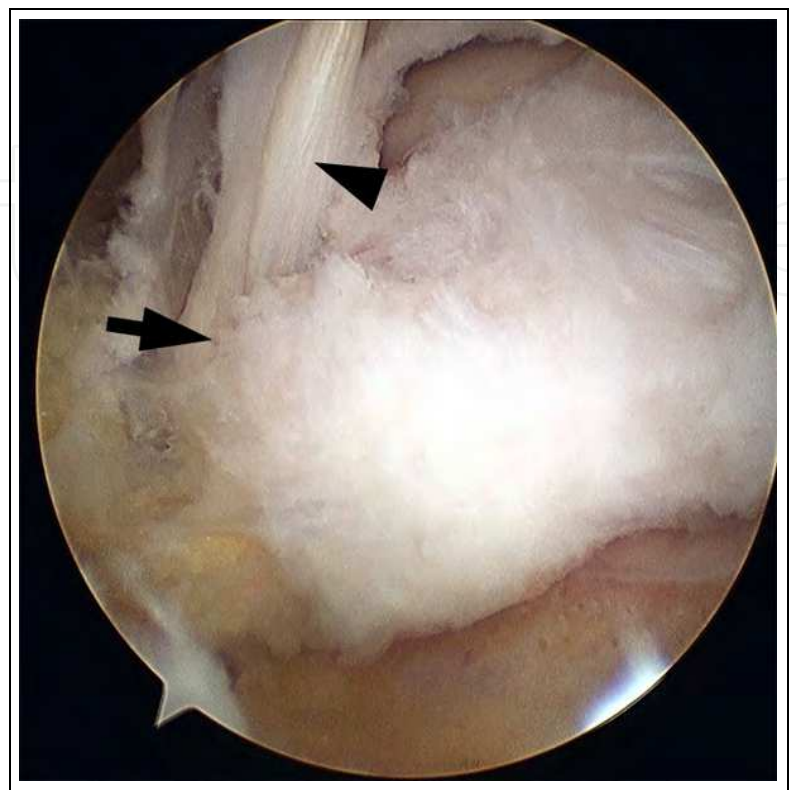


Fig. 13. Flexor hallucis longus tendon (arrow head) compressed by large posterolateral talar process (arrow).

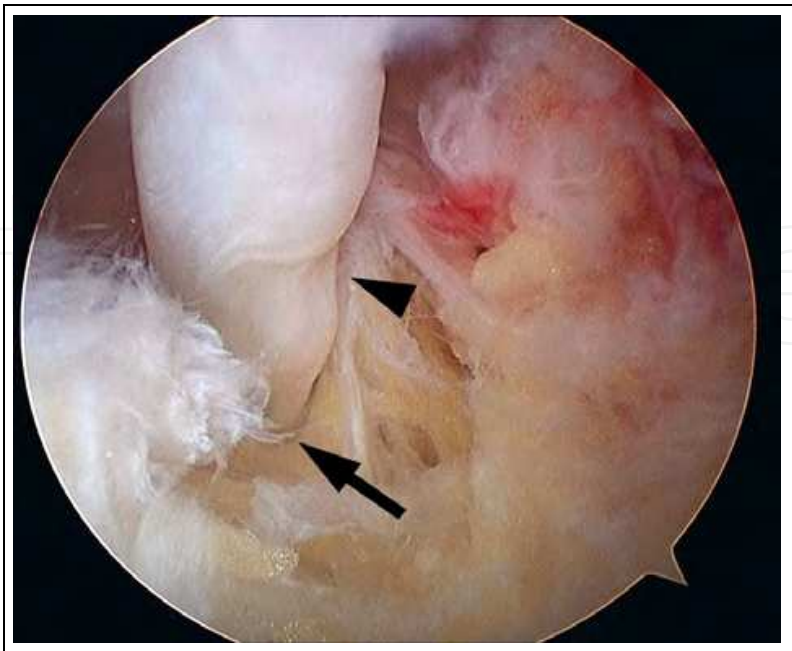


Fig. 14. Constriction of the flexor hallucis longus tendon (arrow head) at the posteromedial part of the fibro-osseous tunnel (cut, arrow).

Care should be taken as it is difficult for diagnosis of tenosynovitis of the FHL with preoperative imaging<sup>7</sup>, especially in the early stage cases. For treating this disorder, operative release of the FHL is recommended when disabling symptoms persist despite non-operative treatment<sup>8-12</sup>, and hindfoot endoscopic surgery is beneficial, especially for athletes who expect to return to their initial athletic activities with a shorter recovery time. After removing the hypertrophic synovium over the FHL tendon with forceps, the hypertrophic flexor retinaculum, which lays at the insertion of the tarsal tunnel and/or abnormal bony structures, were removed with curved forceps and motorized shaver for decompression of the constricted FHL tendon (Figure 15).

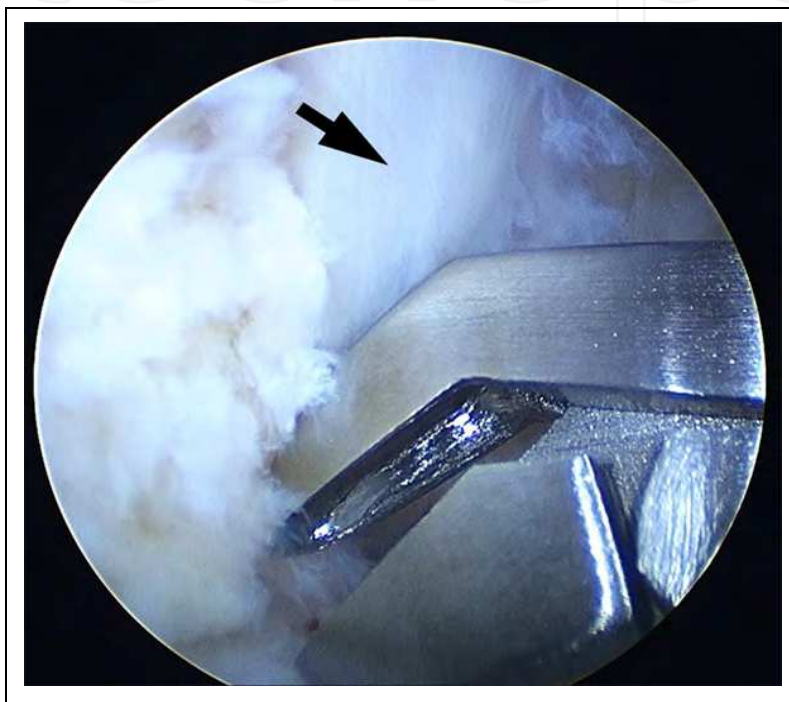


Fig. 15. Decompression of the flexor hallucis longus tendon (arrow) with curved forceps.

After surgery, the ankle was immobilized with an elastic bandage for two days. One day after the surgery, an active range of motion was allowed, and a passive range of motion was allowed two weeks after the surgery. Full weight bearing was allowed at 2 days after the surgery. Athletic activity was allowed if the patients feel no pain and no limitation of range of motion of their affected foot. They will return to the full athletic activity at four to seven weeks after surgery.

### 2.3.2 Osteoarthritis of the subtalar joint

Recently, arthroscopic subtalar arthrodesis has been reported as an alternative to traditional open methods for intractable hindfoot disorders, such as subtalar arthritis after fracture of the calcaneus or talus, primary arthritis, talocalcaneal coalition or inflammatory arthritis<sup>13-17</sup>, because of its advantages, including minimizing invasion to the soft tissue around the hindfoot and preserving blood supply to the talus. Although the lateral approach using anterolateral and posterolateral portals in the supine or lateral decubitus position was initially introduced for arthroscopic subtalar arthrodesis<sup>18, 19</sup>, the recent trend is the use of



the posterior two portals with patients in the prone position, permitting surgeons to access the posterior subtalar joint easily, as compared to the lateral approach<sup>13, 17</sup>. Accompanying techniques, such as the use of a third accessory portal<sup>14, 15, 17</sup> or bone substitute for grafting<sup>13, 15</sup>, have been reported to result in successful prognosis without complications. The author recommends arthroscopic subtalar arthrodesis via a posterior approach using two portals accompanied by grafting of autologous cancellous bone, which is harvested by means of a tube harvester and grafted thorough these arthroscopic portals.

First, the shaver is inserted through the posteromedial portal and the soft tissue is removed until the FHL tendon is identified by arthroscopic visualization. If tenosynovitis is present around the FHL tendon, release of the flexor retinaculum and synovectomy are performed. After identification of the FHL tendon, the soft tissue overlying the posterior facet of the subtalar joint is removed from the lateral field of the FHL tendon. Next, the articular cartilage of the posterior facet of the subtalar joint is removed using a small chisel and a shaver until subchondral bone is exposed (Figure 16).

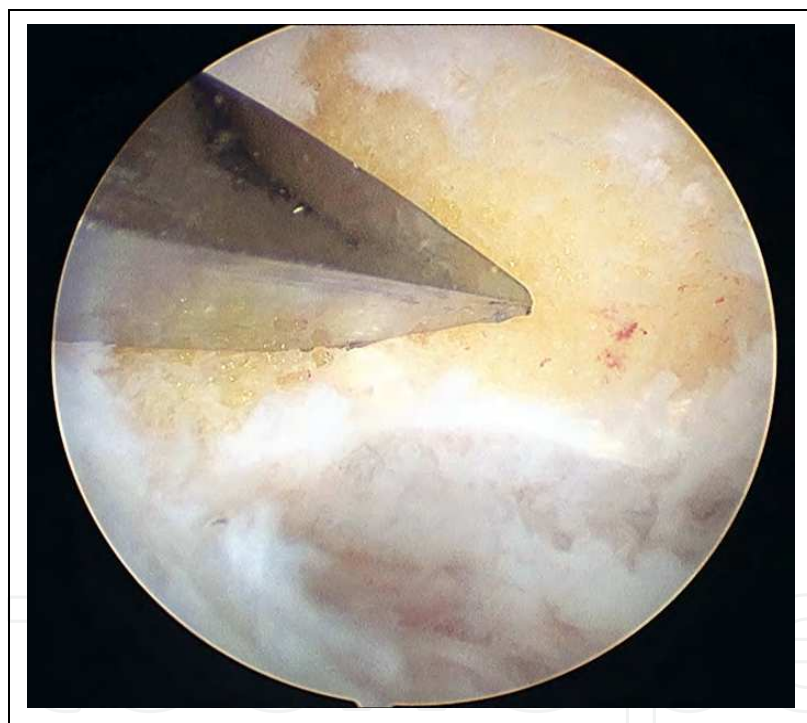

Fig. 16. Debridement of the subtalar joint with a small chisel.

After curettage of the anterior region of the posterior facet is confirmed arthroscopically, temporary fixation is performed using guide wires with the hindfoot in a neutral position. Subsequently, cancellous autograft bone is harvested from the ipsilateral iliac crest by using a tube harvester (OATS system, Arthrex, Naples, Florida) (Figure 17).

Two or three rigid cancellous bone plugs harvested through an approximately 1.5-cm skin incision are cut by a blade into small bone columns (Figure 18) so that autologous bone grafting is easily performed via arthroscopic portals.

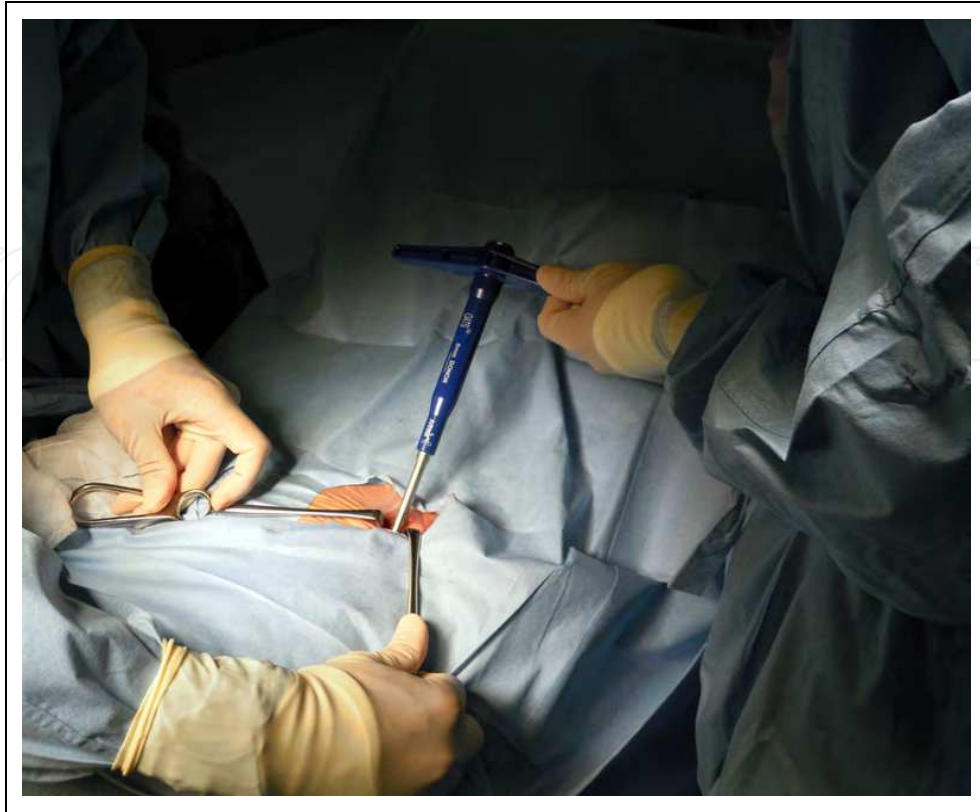

Fig. 17. Harvesting cancellous bone from the ipsilateral iliac crest using a tube harvester.

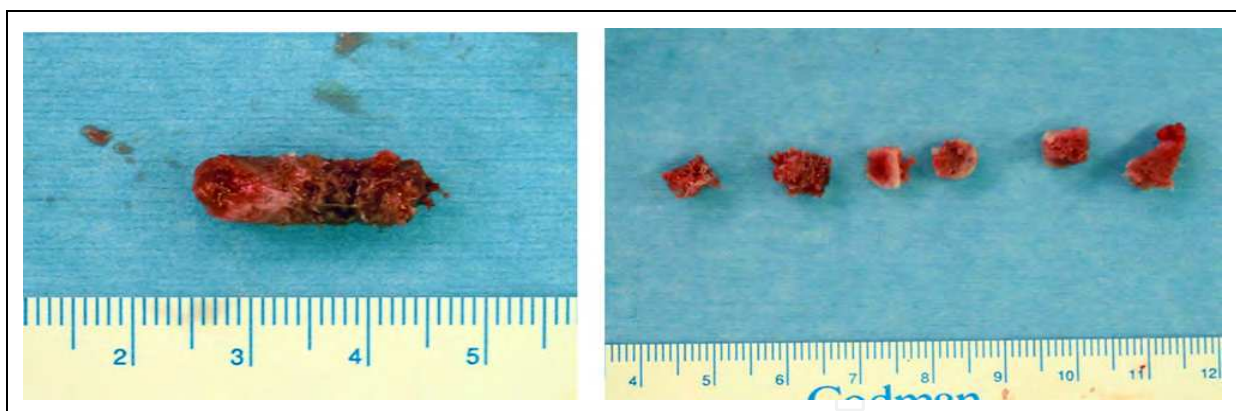


Fig. 18. Harvested cancellous bone plug (left) is cut into small bone columns (right).

Under arthroscopic visualization, two guide wires of the headless cannulated screws (Acutrak plus, Acumed, Hillsboro, Oregon) are inserted from the plantar of the heel to the talus body through the posterior facet of the subtalar joint and was followed by the overdrilling (Figure 19).

After autologous bone is grafted to the void after curettage of the posterior facet of the subtalar joint via portals (Fugure 20), the headless cannulated screws with a diameter of 6.5 mm are inserted (Figure 21).

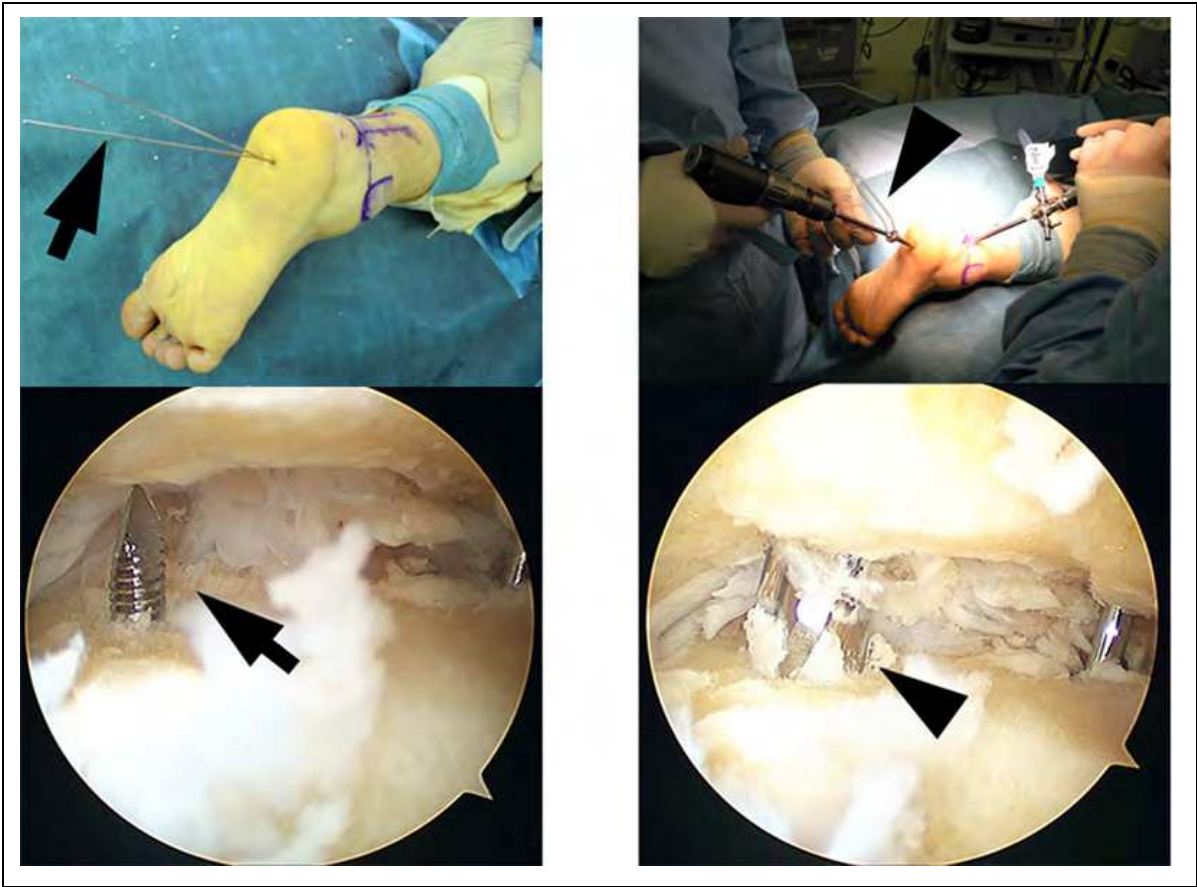


Fig. 19. Inserted guide wire through the subtalar joint (left, arrow) followed by the over drilling (right, arrowhead).

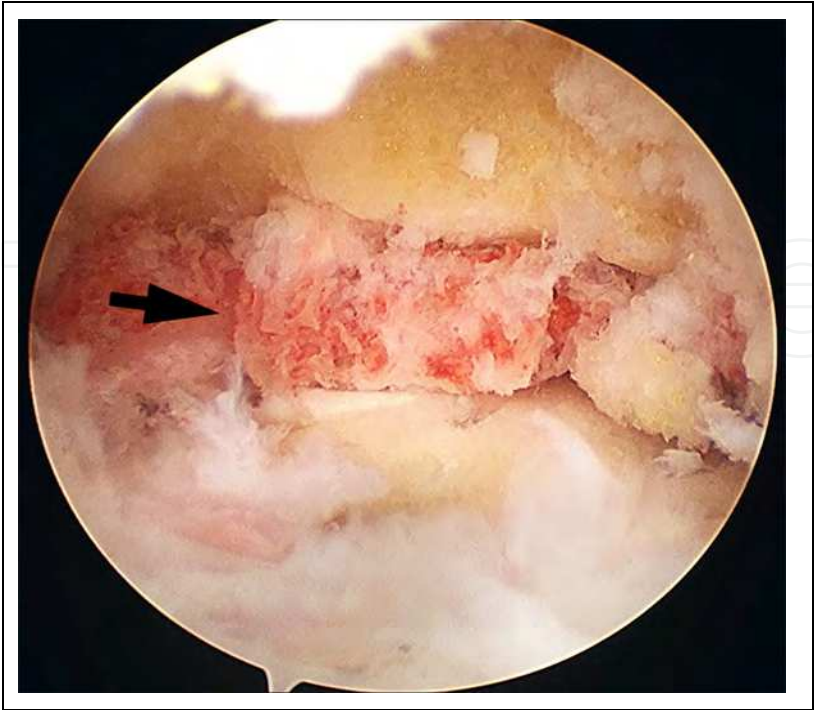


Fig. 20. Grafted cancellous bone on the subtalar joint (arrow).



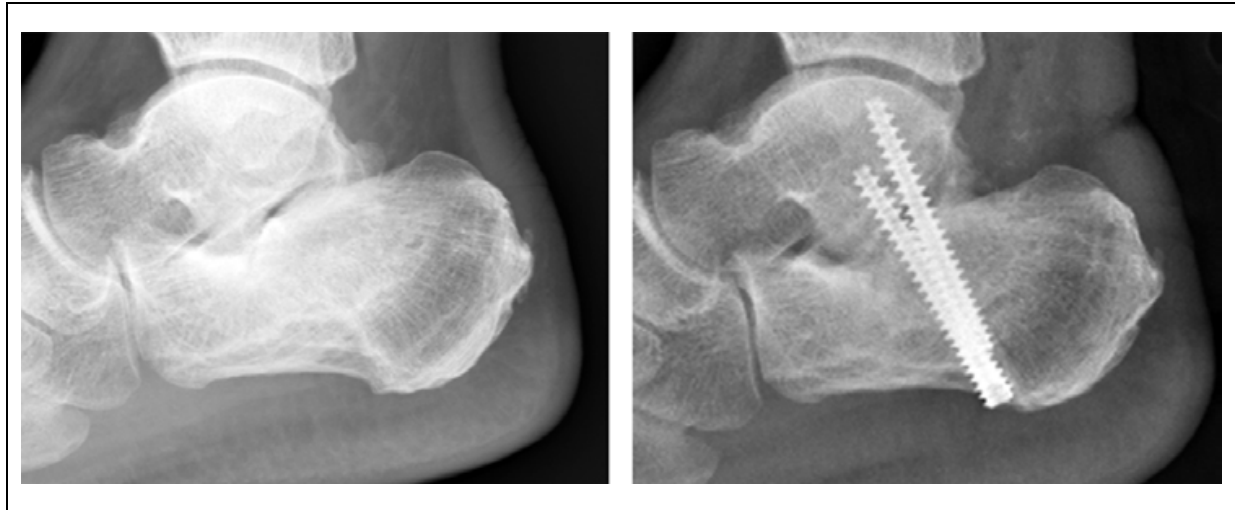

Fig. 21. Lateral view of the standard X-ray of the ankle before surgery (left) and after surgery (right).

After surgery, operated feet are not placed in casts, and active range-of-motion exercise of the talocrural joint is allowed the next day. Partial weight-bearing is allowed six weeks after surgery and full weight-bearing is permitted after a bridging callus is confirmed between posterior facets by radiological investigation.

### 3. Conclusion


Since 1997, the author has performed about 300 hindfoot endoscopic procedures utilizing posterior two portals without any complications. The patients complained of less pain after surgery and recovered earlier than those who underwent open surgery. The author believes that hindfoot endoscopic surgery, performed by an experienced arthroscopist who has enough knowledge for local anatomy and become skillful in this art, is safe and reliable method for posterior ankle disorders.

### 4. References

- [1] Van Dijk, CN.; Scholten, PE. & Krips, R. (2000). A 2-portal endoscopic approach for diagnosis and treatment of posterior ankle pathology. *Arthroscopy*, Vol.16, pp. 871-876.
- [2] Parisien, JS. & Vangsness, T. (1985). Arthroscopy of the subtalar joint: An experimental approach. *Arthroscopy*, Vol.1, pp. 53-57.
- [3] Van Dijk, CN. (2006). Hindfoot endoscopy for posterior ankle pain. *Instr Course Lect*, Vol.55, pp. 545-554.
- [4] Takao, M; Ochi, M; Shu, N; Naito, K; Matsusaki, M; Tobita, M & Kawasaki, K. (1999). Bandage distraction technique for ankle arthroscopy. *Foot Ankle Int*, Vol. 20, pp. 389-91.
- [5] Golano, P; Vega, J; de Leeuw, PA; Malagelada, F; Manzanares, MC; Gotzens V & van Fijk, CN. (2010). Anatomy of the ankle ligaments: a pictorial essay. *Knee Surg Sports Traumatol Arthrosc*, Vol. 18, pp. 557-569.



- [6] Maquirriain, J. (2005). Posterior ankle impingement syndrome. *J Am Acad Orthop Surg*, Vol. 13, pp. 365-371.
- [7] Link, SC; Erickson, SJ & Timins ME. (1993). MR imaging of the ankle and foot: normal structures and anatomic variants that may simulate disease. *Am J Roentgenol*, Vol. 161, pp. 607-612.
- [8] Cowell, HR; Elener, V & Lawhon SM. (1982). Bilateral tendinitis of the flexor hallucis longus in a ballet dancer. *J Pediatr*, Vol. 2, pp. 582-586.
- [9] Hamilton, HG. (1982). Stenosing tenosynovitis of the flexor hallucis longus tendon and posterior impingement upon the os trigonum in ballet dancers. *Foot Ankle*, Vol. 3, pp. 74-80.
- [10] Lereim, P. (1985). Trigger toe in classical-ballet dancers. *Arch Orthop Trauma Surg*, Vol. 104, pp. 325-326.
- [11] Lynch, T & Pupp GR. (1990). Stenosing tenosynovitis of the flexor hallucis longus at the ankle joint. *J Foot Surg*, Vol. 29, pp. 345-348.
- [12] McCarroll, JR; Ritter, MA & Becker, TE. (1983). Triggering of the great toe. A case report. *Clin Orthop*, Vol. 175, pp. 184-185.
- [13] Amendola, A; Leun-Bae, L; Charles, LS & Jin-Soo, S. (2007). Technique and early experience with posterior arthroscopic subtalar arthrodesis. *Foot Ankle Int*, Vol. 28, pp. 298-302.
- [14] Beimers, L; Leeuw, PAJ & Van Dijk, CN. (2009). A 3-portal approach for arthroscopic subtalar arthrodesis. *Knee Surg Sports Traumatol Arthrosc*, Vol. 17, pp. 830-834.
- [15] Lee, KB; Saltzman CL; Suh, JS; Wasserman, L & Amendola, A. (2008). A posterior 3-portal arthroscopic approach for isolated subtalar arthrodesis. *Arthroscopy*, Vol. 24, pp. 1306-1310.
- [16] Lee, KB; Park, CH; Seon, JK & Kim, MS. (2010). Arthroscopic subtalar arthrodesis using a posterior 2-portal approach in the prone position. *Arthroscopy*, Vol. 26, pp. 230-238.
- [17] Perez Carro, L; Golano, P & Vega, J. (2007). Arthroscopic subtalar arthrodesis: the posterior approach in the prone position. *Arthroscopy*, Vol. 23, pp. e 1-4.
- [18] Glanzmann, MC & Sanhueza-Hernandez, R. (2007). Arthroscopic subtalar arthrodesis for symptomatic osteoarthritis of the hindfoot: a prospective study of 41 cases. *Foot Ankle Int*, Vol. 28, pp. 2-7.
- [19] Tasto, JP. (2003). Arthroscopic subtalar arthritis. *Tech Foot Ankle Surg*, Vol. 2, pp. 122-128.



## **Modern Arthroscopy**

Edited by Dr Jason L. Dragoo

ISBN 978-953-307-771-0

Hard cover, 302 pages

**Publisher** InTech

**Published online** 09, December, 2011

**Published in print edition** December, 2011

Modern Arthroscopy will assist practitioners to stay current in the rapidly changing field of arthroscopic surgery. The chapters in this book were written by a panel of international experts in the various disciplines of arthroscopy. The goals of this text are to present the classical techniques and teachings in the fields of Orthopaedics and Dentistry, but also to include new, cutting-edge applications of arthroscopy, such as temporomandibular arthroscopy and extra-articular arthroscopy of the knee, just to name a few. We hope Modern Arthroscopy becomes a core reference for your arthroscopic surgery practice.

### **How to reference**

In order to correctly reference this scholarly work, feel free to copy and paste the following:

Masato Takao (2011). Posterior Ankle and Hindfoot Arthroscopy, Modern Arthroscopy, Dr Jason L. Dragoo (Ed.), ISBN: 978-953-307-771-0, InTech, Available from: <http://www.intechopen.com/books/modern-arthroscopy/posterior-ankle-and-hindfoot-arthroscopy>

**INTECH**  
open science | open minds

### **InTech Europe**

University Campus STeP Ri  
Slavka Krautzeka 83/A  
51000 Rijeka, Croatia  
Phone: +385 (51) 770 447  
Fax: +385 (51) 686 166  
[www.intechopen.com](http://www.intechopen.com)

### **InTech China**

Unit 405, Office Block, Hotel Equatorial Shanghai  
No.65, Yan An Road (West), Shanghai, 200040, China  
中国上海市延安西路65号上海国际贵都大饭店办公楼405单元  
Phone: +86-21-62489820  
Fax: +86-21-62489821

© 2011 The Author(s). Licensee IntechOpen. This is an open access article distributed under the terms of the [Creative Commons Attribution 3.0 License](https://creativecommons.org/licenses/by/3.0/), which permits unrestricted use, distribution, and reproduction in any medium, provided the original work is properly cited.

IntechOpen

IntechOpen