

We are IntechOpen, the world's leading publisher of Open Access books Built by scientists, for scientists

6,900

Open access books available

186,000

International authors and editors

200M

Downloads

Our authors are among the

154

Countries delivered to

TOP 1%

most cited scientists

12.2%

Contributors from top 500 universities



WEB OF SCIENCE™

Selection of our books indexed in the Book Citation Index
in Web of Science™ Core Collection (BKCI)

Interested in publishing with us?
Contact book.department@intechopen.com

Numbers displayed above are based on latest data collected.
For more information visit www.intechopen.com



Extraarticular Arthroscopy of the Knee

Shinichi Maeno¹, Daijo Hashimoto², Toshiro Otani³, Ko Masumoto⁴,
Itsuki Yuzawa⁵, Kengo Harato⁶ and Seiji Saito¹

¹*Department of Orthopedic Surgery, Shioya Hospital of International
University of Health and Welfare, Tochigi,*

²*Department of Surgery, Josai Hospital, Tochigi,*

³*Keio University Faculty of Nursing and Medical Care, Tokyo,*

⁴*Masumoto Clinic, Tokyo,*

⁵*Department of Orthopedic Surgery, Terada Hospital, Tokyo,*

⁶*Department of Orthopedic Surgery, Kawasaki Municipal Kawasaki Hospital
Japan*

1. Introduction

Indication of the intraarticular arthroscopy, which was originally developed in knee surgery, has been expanded dramatically in accordance with the development of the instruments, including electric coagulator or pressure and flow-control pump. It is widely used not only in the major joints such as knee, shoulder, and hip, but also in the small joints, in hand and foot. It is also applied to outside the joint cavities, such as in the bursae (Verdonk et al., 1988; Klein, 1996; Bradley & Dillingham, 1998; Ogilvie-Harris & Gilbert, 2000), bone marrow of femur or tibia (Roberts et al., 2000,2001; Kwak et al., 2009), and around the tendon sheath (van Dijk et al., 1997, 1998; Steenstra & van Dijk, 2006; Lui, 2007). We describe herein extra-articular arthroscopy using a lifting hanger.

2. Indication

Possible indications for the extraarticular procedures around the knee are; lateral release for painful bipartite patella, excessive lateral pressure syndrome, and recurrent dislocation of the patella (Maeno et al., 2008,2010), bursectomy for prepatellar bursa, and medial patellofemoral ligament (MPFL) reconstruction. It can be expanded to any other extraarticular works around the knee.

3. Instruments

A conventional arthroscopy setup is used. Either a hanger or a coil shaped lifter is needed. The hanger is shaped in a semi-circular, similar to those used in infantile gasless laparoscopic surgery (Takasago Medical Industry, Tokyo, Japan). The coil-shaped lifter is created from an endotracheal tube stylet (Muranaka Medical Instruments, Osaka, Japan). The tip end is bent manually to form a spiral shape, creating a coil about 5 cm in diameter, with about 3 loops (Fig 1).

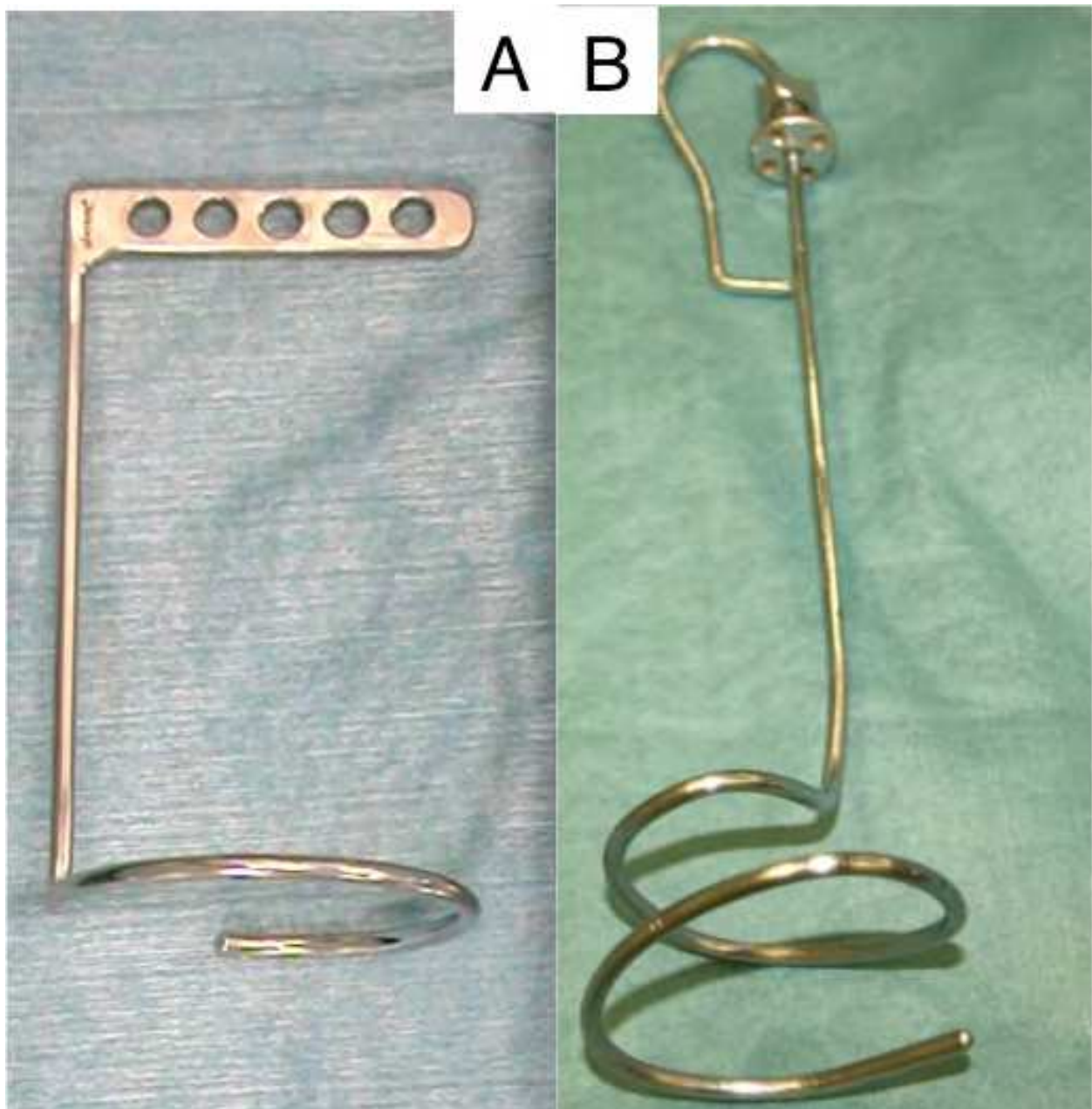


Fig. 1. A: Semi-circular hanger, B: Coil shaped lifter

4. Methods

Routine diagnostic intraarticular arthroscopy is performed from anterolateral (AL) portal. In cases of lateral release procedures, a 1 cm superolateral (SL) portal is made with care not to penetrate the joint. The subcutaneous space is then developed to establish the working space. The lifting hanger is applied. Through the superolateral portal, the ring-shaped end is inserted into the subcutaneous space, and rolled up until the end of the hanger buries under the skin (Fig.2).

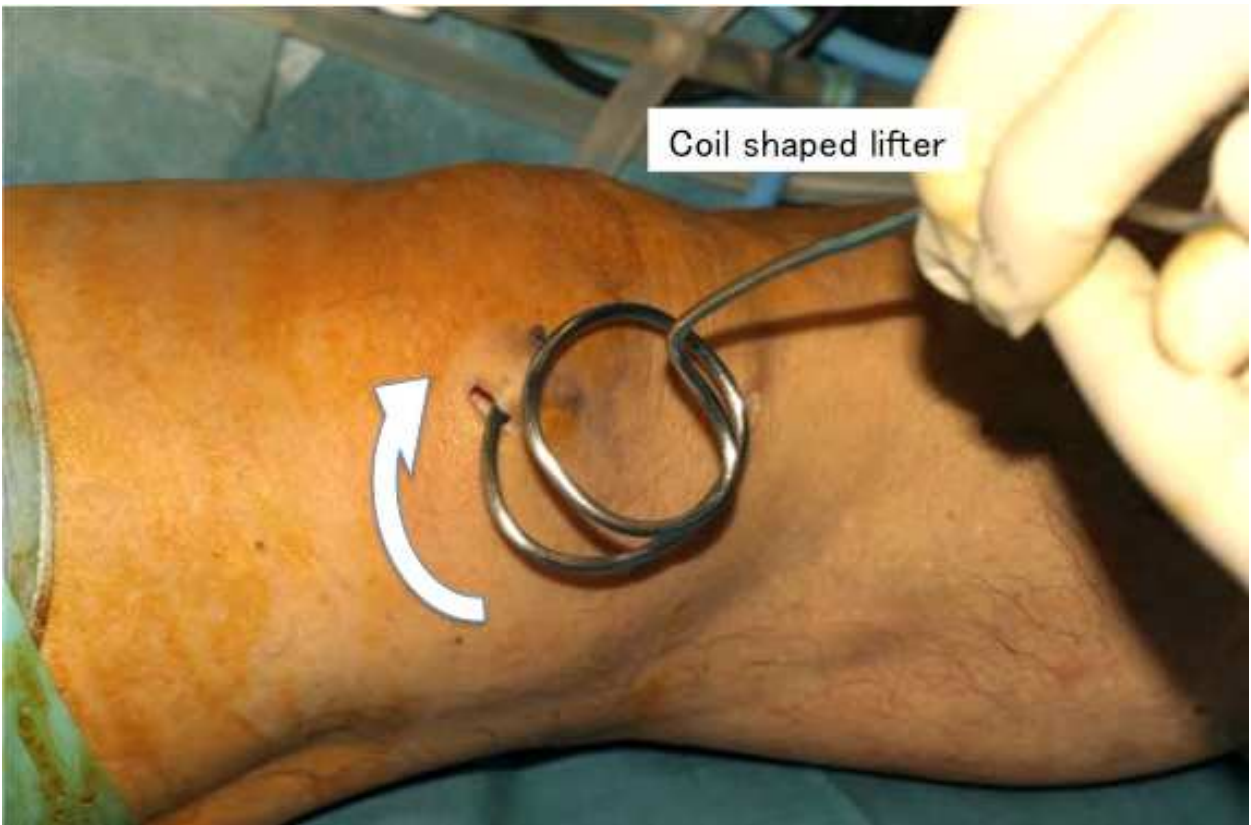

Fig. 2. Coil shaped lifter is inserted into the subcutaneous space

Once pulling the lifter, the working space is established. Care must be taken to avoid inserting the end of the hanger into the underlying muscle. Dry arthroscopy can be performed in the subcutaneous working space created by the lifter (Fig.3,4). Lastly, the hanger is removed by turning it in the opposite direction.

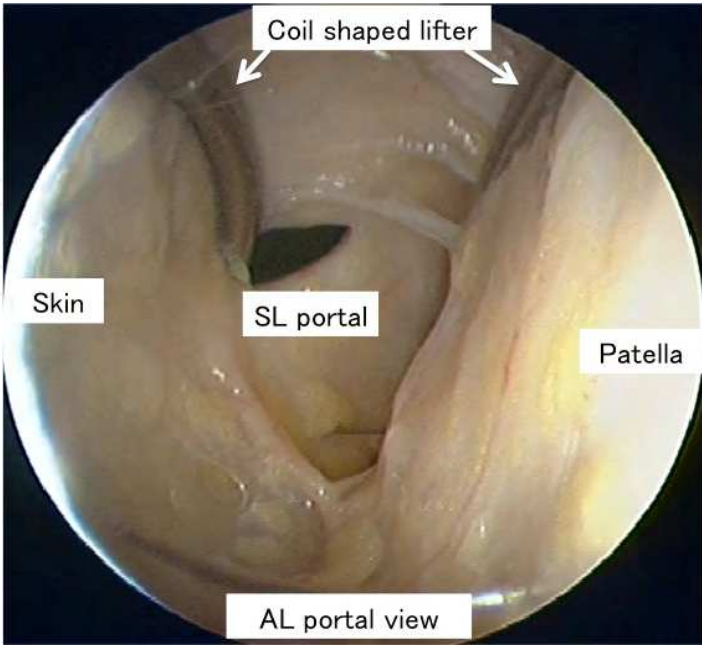


Fig. 3. Subcutaneous space created by the lifter.

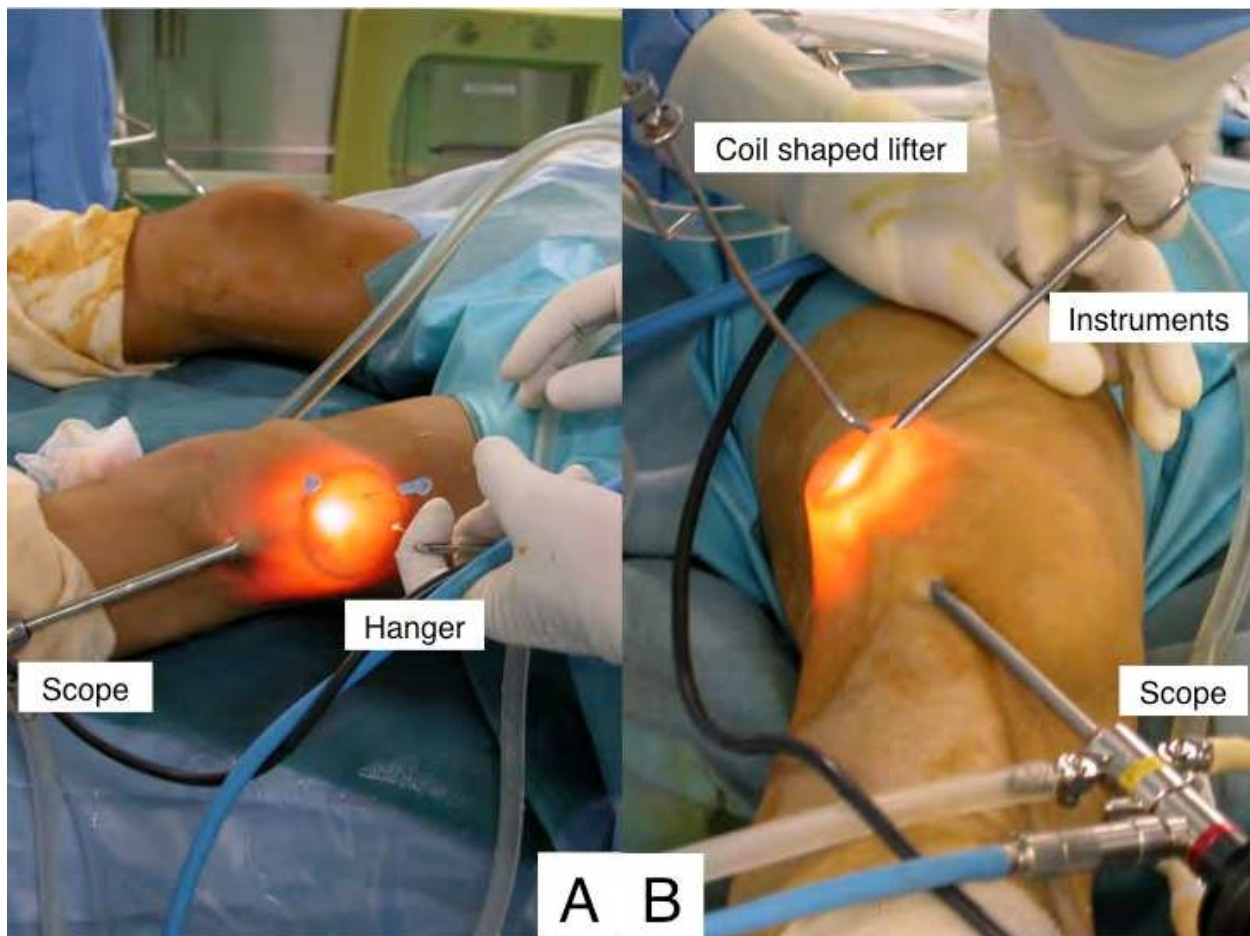


Fig. 4. Operational field during surgery. A) The hanger lifts up the skin, affording the operator a view from outside the joint. B) Likewise, coil shaped lifter is creating the space. Instruments (scissors) are introduced to the operative field. In these situations, the arthroscope is introduced from the AL portal and the hanger lifts the skin from the superolateral portal.

4.1 Lateral release

In the lateral release procedure, a subcutaneous cavity from the AL portal up to the SL portal is needed. In cases of bipartite patella, careful probing to examine instability of the fragment, the status of articular cartilage underneath the patella, and the extent of the affected area to be treated is important. Viewing the lesion from inside the joint, firstly we pierce the lesion with 23-gauge needles at the proximal and distal edges of the lesion, to ensure the extent of release. It often involves not only the lateral retinaculum but also vastus lateralis muscle. We try to release only the attachment of the vastus lateralis muscle and lateral retinaculum to the fragment.

Basically the arthroscope is in the AL viewing portal. Under a magnified arthroscopic view, careful release should be performed, including the vastus lateralis muscle and lateral retinaculum, with a No. 11 blade through the SL portal. The release should be between the needle markers with a knife and arthroscopic scissor cutters. A 1-cm portal is sufficient to introduce both the lifter and an arthroscope, or the lifter and instruments, as the portal is stretched by the lifter. Authors prefer to debride the released edge of the vastus lateralis

muscle with a 4.5-mm shaver to create a gap between the muscle and fragment, which decreases the risk of the muscle scarring back down to the fragment (Fig.5).

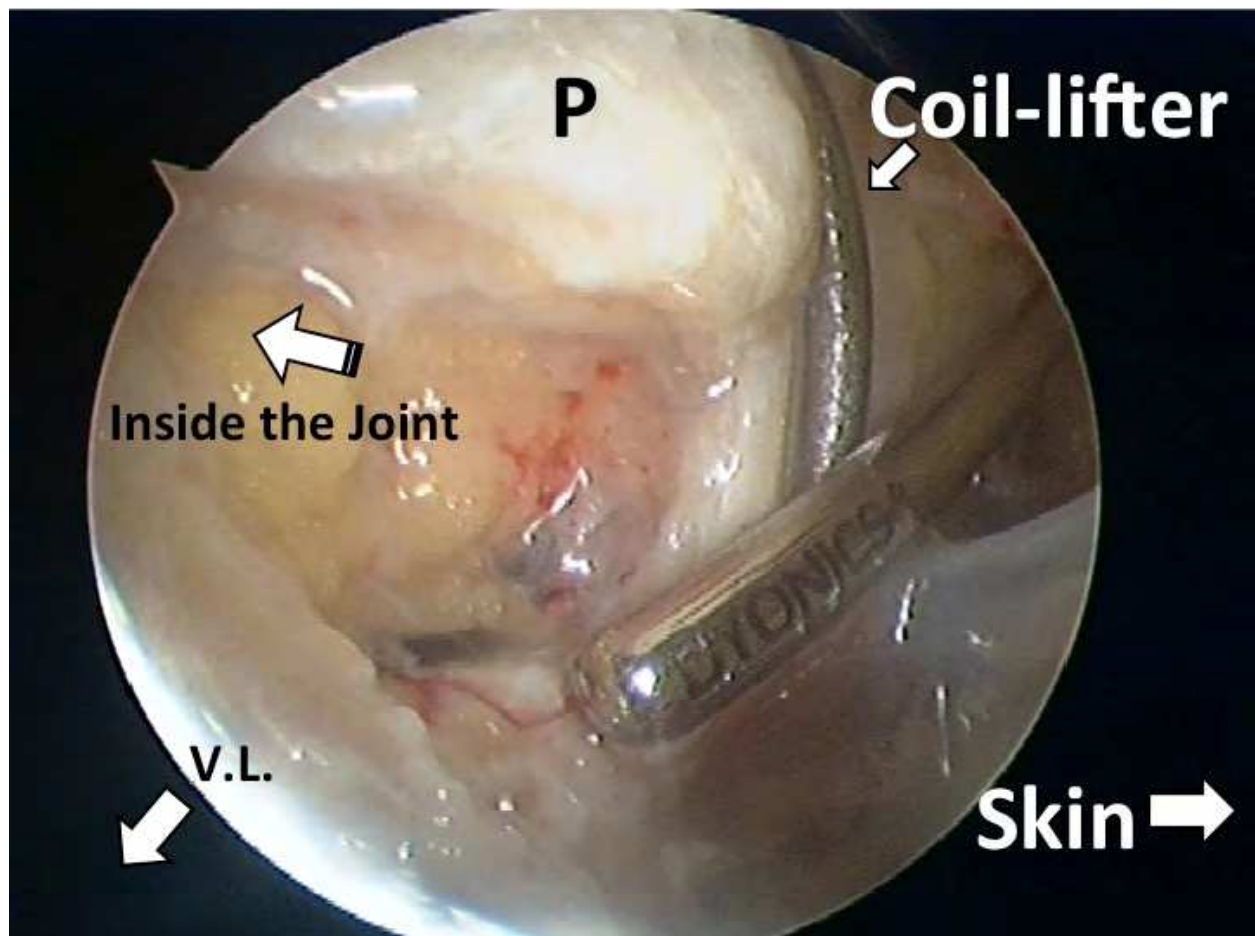


Fig. 5. SL portal view. A 4.5 mm shaver is used in order to create a gap between muscle and fragment. VL, vastus lateralis muscle; P, patella.

It should ideally be done from outside the joint with care not to penetrate the joint, so that the joint capsule can be maintained intact to help minimize the postoperative leakage of the joint fluid.

4.2 Medial patellofemoral ligament reconstruction

While numbers of MPFL reconstructions are reported, this procedure allows doing under a minimum incision. Authors' preferred method is as follows; a 1 cm incision at the superomedial corner of the patella is made. An oblique bone tunnel through the patella is drilled with a guide pin and overdrilling method. This tunnel should be obliquely routed from the superomedial corner of the patella to the anterior center of the patella, trying to recreate the original fan-shaped attachment of the MPFL (Steensen et al., 2004). The lifting hanger is introduced into the prepatellar space, to be able to perform extraarticular dry arthroscopy. The harvested semitendinosus tendon is introduced to this space through the bone tunnel, pulled using a passing pin (Fig.6).

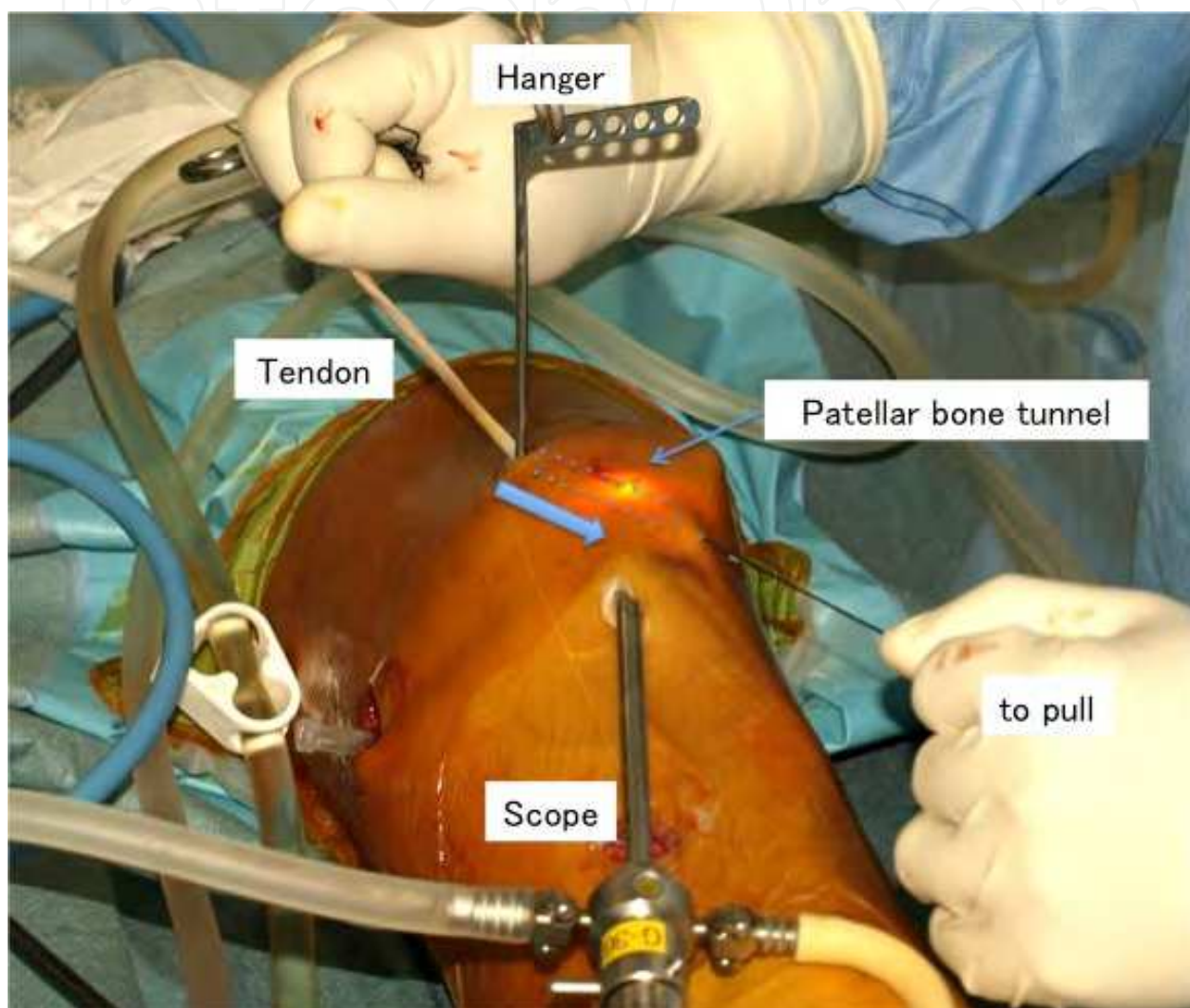


Fig. 6. Watching the drilled hole on anterior surface of the patella through the scope, absorbable sutures (No. 2 Vicryl®) connected to semitendinosus tendon is introduced by pulling through the passing pin.

The suture is caught using a grasper punch from the superomedial portal, and the tendon is drawn out to the superomedial portal, along with the existing end of the tendon (Fig.7).

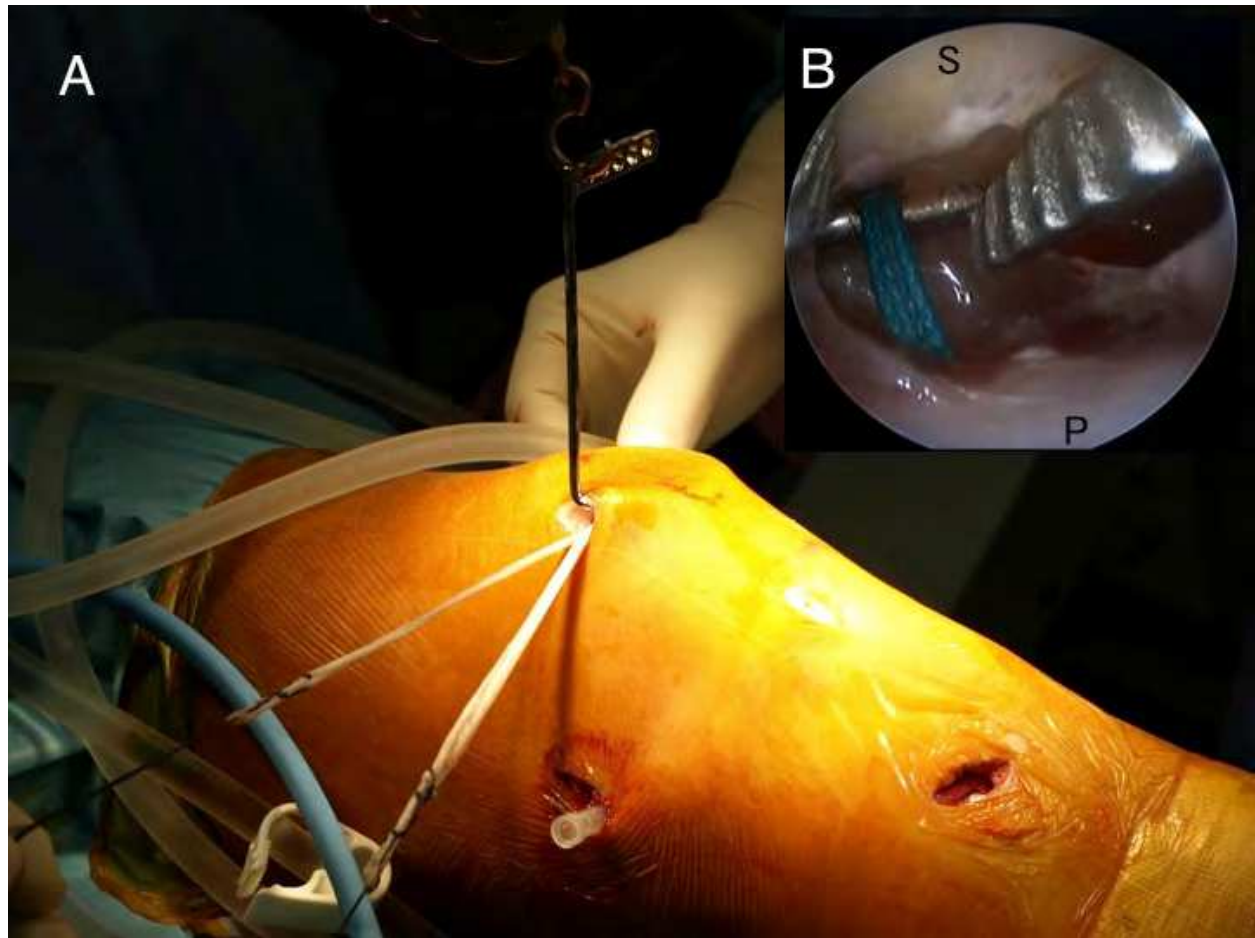


Fig. 7. A) The tendon passing through the bone tunnel is drawn out to the superomedial portal, which also exists at the other end of the tendon. B) Arthroscopic view between the patella and skin during the operation. In this situation, a hanger, an arthroscope, and forceps are introduced from the same superomedial portal. The forceps are about to grip the sutures connecting the ligament. P, patella; S, subcutaneous tissue.

Using a tendon passer, both tendon ends lead to the femoral fixation site, which is just distal to the adductor tubercle and posterosuperior to the medial epicondyle (Nomura, 2003).

An interference screw is used to fix the ligament.

4.3 Bursectomy

Among numbers of bursae existed around the knee, the most problematic bursitis would happen in the prepatellar bursa. The incision should be at the superior and the inferior end of the bursa, with care not to cut the infrapatellar branch of the saphenous nerve. Authors prefer using dye solution prior to resection to help determine the extent of the bursal tissue, as it does not always look like typical bursa. Under dry arthroscopy in the bursa created by the lifter, bursectomy can be performed using a shaver or an electric coagulator.

Putting a drainage tube should also be considered depending on the cases.

5. Case presentation

A 10-year-old boy (football player) suffered bilateral anterior knee pain and consulted a nearby clinic in 2005, but only underwent observational studies. Radiography showed a normal patellar shape on the left, but the lateral edge of the patella seemed deficient on the right. Pain worsened to the point where he could no longer continue playing football. Bilateral bipartite patellae was diagnosed at 12 years old in 2007, and he was introduced to our hospital in October 2007.

Radiography in our hospital revealed bilateral bipartite patellae (Saupe classification, type II) (Saupe, 1943), and showed marked tenderness on the anterolateral aspect of the knees, at the site of dissociated bony fragments (Fig. 8).

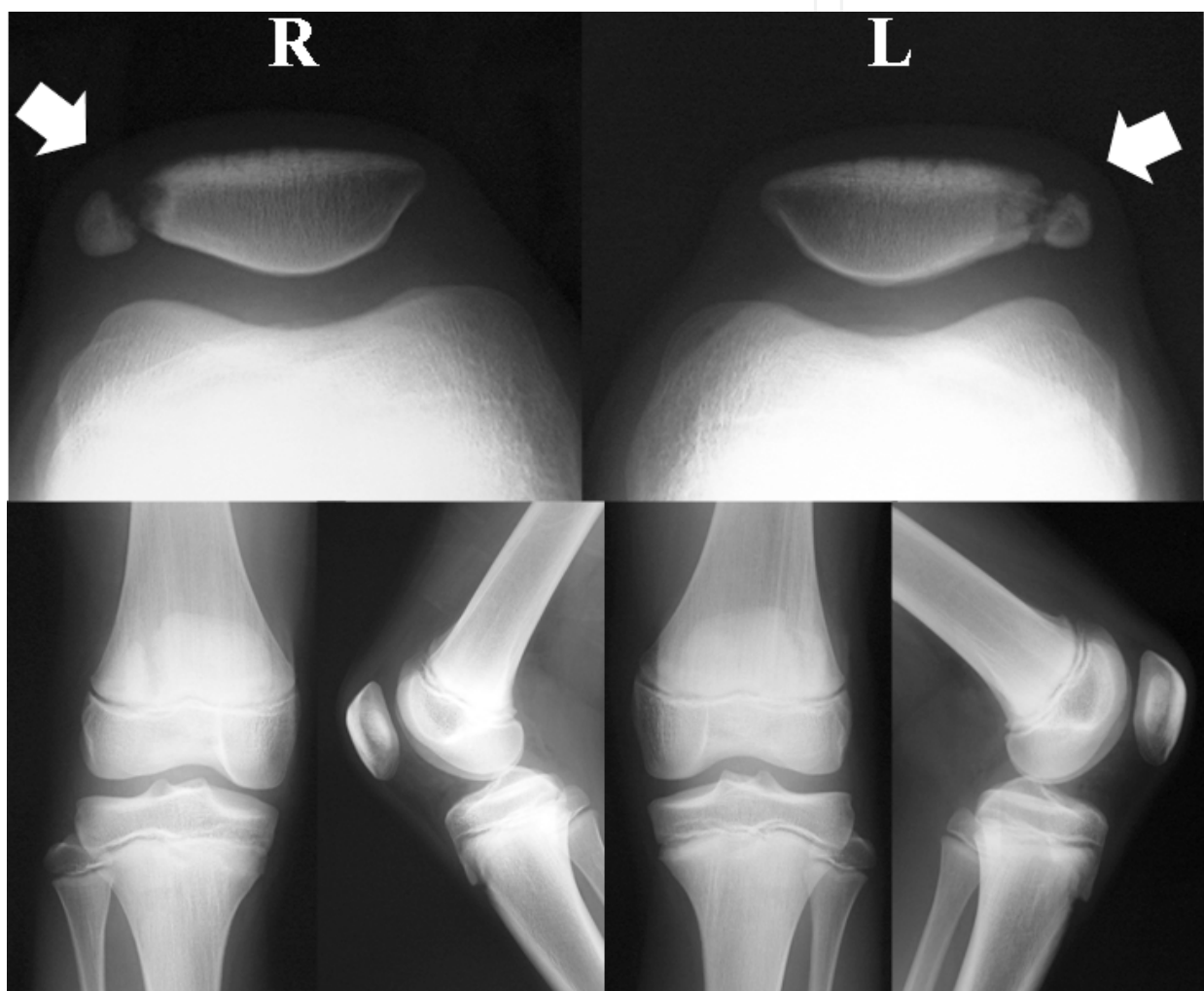


Fig. 8. Plain radiography in Case 1. Left figures show the right knee, right figures show the left knee.

Magnetic resonance imaging (MRI) showed signal hyperintensity at the dissociated fragment and fibrous connected site on T2-weighted fat-suppression images.

Lateral retinacular release accompanied by the release of vastus lateralis muscle insertion from the bony fragment were performed on both knees arthroscopically under both intra- and extra-articular views using the hanger lifting procedure in November 2007, at 13 years old. At first, conventional arthroscopy was performed to check the cartilage status. The

surface of the cartilage looked almost intact on dissociated sites. We determined the range to release from the shape of the patella from inside the joint, using pierce-marks of 23-G needles for marking. The subcutaneous space was then widely developed. A semi-circular hanger was then applied through the SL access portal by placing the ring-shaped end of the hanger, with the other end of the hanger retracted by hand. Watching the patella and lateral retinaculum from outside the joint, lateral release was able to be performed. The width of release could be checked from both inside and outside the joint (Fig.9).

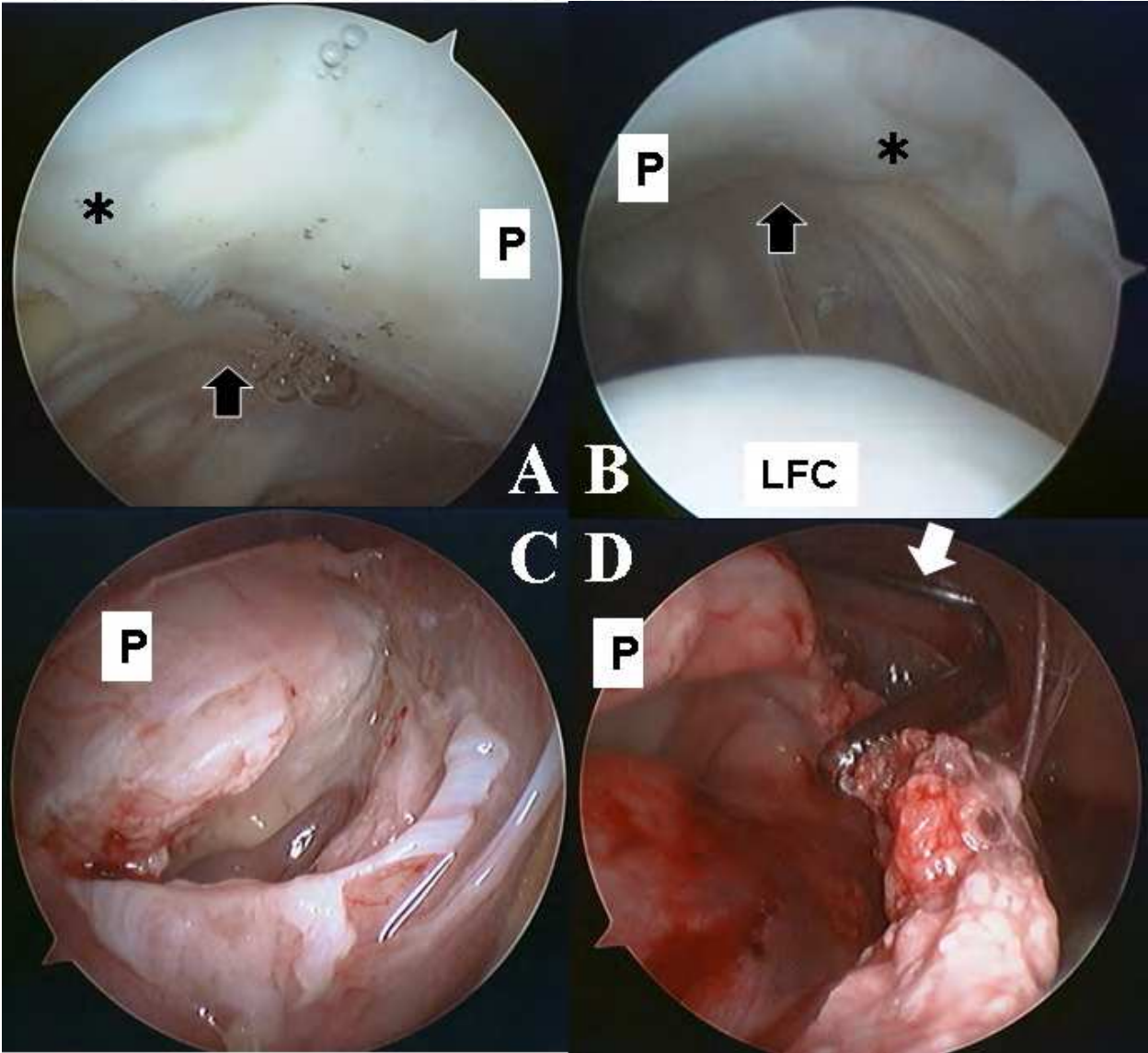


Fig. 9. Arthroscopic view from inside and outside the joint. A, C) Right knee. B, D) Left knee. A) View from inside the right knee joint, using the AL portal. Black arrow indicates the bipartite patella. No marked cartilage damage was evident. B) View from inside the left knee joint, using the AL portal. C) View from outside the right knee joint, using the SL portal. Lateral release of bipartite patella is successfully completed. The lateral femoral condyle can be seen from outside the joint. D) Lateral release performed under a view from outside the joint. A shaver is introduced from the SL portal. The camera is from the AL portal. The lifting hanger is also seen (white arrow). P, patella. *Bipartite patellae.

The patient began range-of-motion exercises from postoperative day 1, and was able to walk from postoperative day 2. Symptom resolved within 1 month, and radiography showed bone union by 2 months postoperatively in the left knee, and by 4 months in the right knee. Even the inclined bony fragment of the right knee was corrected during the course (Fig. 10).

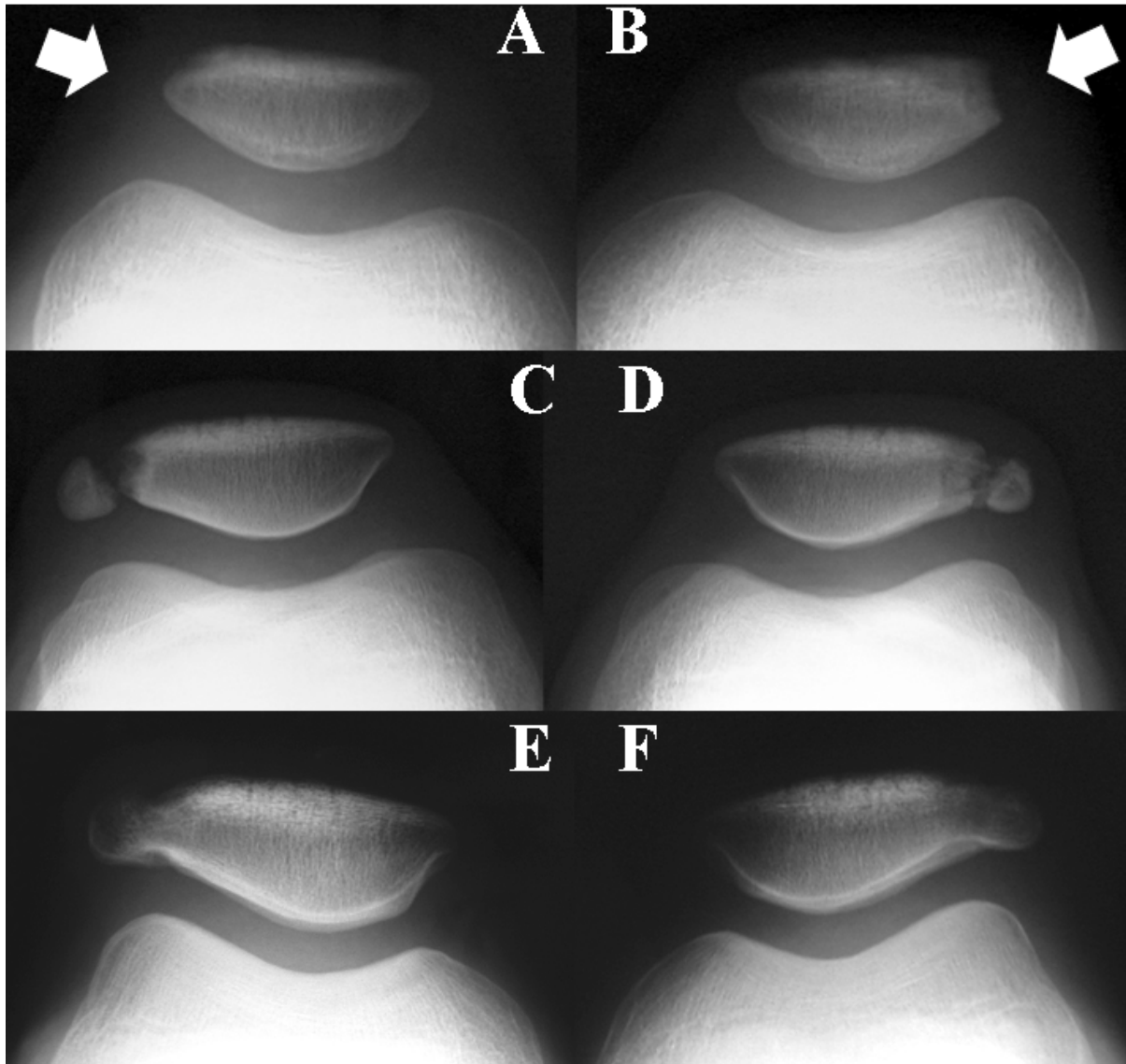


Fig. 10. Radiography of Case 1 along with time course. A, C, E) Right knee. B, D, F) Left knee. A, B) Radiography at the time of initial complaint of pain in both knees at 11 years old. The shape of the right patella seemed normal (A), but the lateral edge of the left knee seemed deficient (B). C, D) Preoperative radiography at 12 years old. Both knees displayed bipartite patella (Saupe classification, type II). E) Right knee at 4 months postoperatively. F) Left knee at 2 months postoperatively. Bone union seemed complete.

6. Discussion

Hanger lifting procedures have been developed for abdominal operations during laparoscopic surgery, to avoid the risks inherent in conventional pneumoperitoneum (Hashimoto et al., 1993, 1995, Nagai et al., 1995). The hanger we used was designed for

abdominal operations in children (Yokomori et al., 1998), but is also suitable for knee surgery because the diameter is close to that of the patella. Instead of lifting the abdominal wall, we lifted the anterior skin of the knee to achieve extra-articular arthroscopy. The most characteristic feature of this method is the provision of an extra-articular view, which seems effective for these procedures. Views can be obtained from both inside and outside the joint arthroscopically without water. Further, with regard to vastus lateralis release, the benefit of this technique is the ability to keep the joint capsule intact, which is not possible with a conventional intra-articular arthroscopic approach. In terms of MPFL reconstruction, the creation of patellar bone tunnel and tendon passage can be made under arthroscopic view. Both intra- and extra-articular arthroscopic views seem indispensable for precise performance of those methods.

The only substantial complication is interstitial edema and subcutaneous adhesion due to developing subcutaneous space. Thus, early mobilization with compression dressing seems necessary.

7. Acknowledgement


The authors thank Drs. Yasuyuki Fukui, Makoto Nishiyama, Masayuki Ishikawa, Nobuyuki Fujita, and Soraya Nishimura, Mita Hospital, International University of Health and Welfare, for their excellent technical assistance.

8. References

- Bradley DM, Dillingham MF (1998). Bursoscopy of the trochanteric bursa. *Arthroscopy*, Vol.14, No.8, pp.884-887.
- Hashimoto D, Nayeem SA, Kajiwarra S, Hoshino T (1993). Abdominal wall lifting with subcutaneous wiring: An experience of 50 cases of laparoscopic cholecystectomy without pneumoperitoneum. *Surg Today*, Vol.23, No.9, pp.786-790.
- Klein W (1996). Endoscopy of the deep infrapatellar bursa. *Arthroscopy* Vol.12, No.1, pp. 127-131..
- Kwak JH, Sim JA, Yang SH, Kim SJ, Lee BK, Ki YC (2009). The use of medulloscopy for localized intramedullary lesions: Review of 5 cases. *Arthroscopy*, Vol.25, No.12, pp.1500-1504.
- Lui TH (2007). Arthroscopically assisted Z-lengthening of extensor hallucis longus tendon. *Arch Orthop Trauma Surg*, Vol.127, No.9, pp.855-857.
- Maeno S, Hashimoto D, Otani T, Masumoto K, Matsumoto H (2008). Hanger-lifting procedure in knee arthroscopy. *Arthroscopy*, Vol.24, No.12, pp.1426-1429.
- Maeno S, Hashimoto D, Otani T, Masumoto K, Fukui Y, Nishiyama M, Ishikawa M, Fujita N, Kanagawa H (2010). Medial patellofemoral ligament reconstruction with hanger lifting procedure, *Knee Surg Sports Traumatol Arthrosc*, Vol.18, No.2, pp.157-160.
- Maeno S, Hashimoto D, Otani T, Masumoto K, Hui C (2010). The "coiling-up procedure": a novel technique for extra-articular arthroscopy. *Arthroscopy*, Vol.26, No.11, pp.1551-1555.
- Nomura E, Inoue M (2003). Surgical technique and rationale for medial patellofemoral ligament reconstruction for recurrent patellar dislocation. *Arthroscopy*, Vol.19, No.5, pp.E47

- Nagai H, Kondo Y, Yasuda T, Kasahara K, Kanazawa K (1993). An abdominal wall-lift method of laparoscopic cholecystectomy without peritoneal insufflation. *Surg Laparosc Endosc* Vol.3, No.3, pp.175-179.
- Ogilvie-Harris DJ, Gilbert M (2000). Endoscopic bursal resection: The olecranon bursa and prepatellar bursa. *Arthroscopy* Vol.16, No.3, pp.249-253.
- Roberts CS, Statton JO, Walker JA, Seligson D, Hempel D (2000). Medulloscopy of the tibia: Initial report of a new technique. *Arthroscopy* Vol.16, No.8, pp.865-868.
- Roberts CS, Walker JA, Statton J, Seligson D (2001). Medulloscopy for sepsis or nonunion: Early clinical experience with the tibia and femur. *Arthroscopy* Vol.17, No.9, pp.E39.
- Saupe H (1943). Primäre Knochenmarkseilerung der Kniescheibe. *Dtsche Z Chir* Vol. 258, pp.386.
- Steensen RN, Dopirak RM, McDonald WG (2004). The anatomy and isometry of the medial patellofemoral ligament. Implications for reconstruction. *Am J Sports Med* Vol.32, pp.1509-1513.
- Steenstra F, van Dijk CN (2006). Achilles tendoscopy. *Foot Ankle Clin* Vol.11, No.2, pp.429-438, viii.
- van Dijk CN, Kort N, Scholten PE (1997). Tendoscopy of the posterior tibial tendon. *Arthroscopy* Vol.13, No.6, pp.692-698.
- van Dijk CN, Kort N (1998). Tendoscopy of the peroneal tendons. *Arthroscopy* Vol.14, No.5, pp.471-478.
- Verdonk R, Van Meirhaeghe J, Van Houcke H, Verjans P, De Groof E, Van Lerbeirghe J, Claessens H (1988). Shoulder bursoscopy. *Acta Orthop Belg* Vol.54, No.2, pp.233-236.
- Yokomori K, Terawaki K, Kamii Y, Obana K, Hashizume K, Hoshino T, Hashimoto D (1998). New technique applicable to pediatric laparoscopic surgery: Abdominal wall "area lifting" with subcutaneous wiring. *J Pediatr Surg* Vol.33, No.11, pp.1589-1592.

IntechOpen



Modern Arthroscopy

Edited by Dr Jason L. Dragoo

ISBN 978-953-307-771-0

Hard cover, 302 pages

Publisher InTech

Published online 09, December, 2011

Published in print edition December, 2011

Modern Arthroscopy will assist practitioners to stay current in the rapidly changing field of arthroscopic surgery. The chapters in this book were written by a panel of international experts in the various disciplines of arthroscopy. The goals of this text are to present the classical techniques and teachings in the fields of Orthopaedics and Dentistry, but also to include new, cutting-edge applications of arthroscopy, such as temporomandibular arthroscopy and extra-articular arthroscopy of the knee, just to name a few. We hope Modern Arthroscopy becomes a core reference for your arthroscopic surgery practice.

How to reference

In order to correctly reference this scholarly work, feel free to copy and paste the following:

Shinichi Maeno, Daijo Hashimoto, Toshiro Otani, Ko Masumoto, Itsuki Yuzawa, Kengo Harato and Seiji Saito (2011). Extraarticular Arthroscopy of the Knee, Modern Arthroscopy, Dr Jason L. Dragoo (Ed.), ISBN: 978-953-307-771-0, InTech, Available from: <http://www.intechopen.com/books/modern-arthroscopy/extraarticular-arthroscopy-of-the-knee>

INTech
open science | open minds

InTech Europe

University Campus STeP Ri
Slavka Krautzeka 83/A
51000 Rijeka, Croatia
Phone: +385 (51) 770 447
Fax: +385 (51) 686 166
www.intechopen.com

InTech China

Unit 405, Office Block, Hotel Equatorial Shanghai
No.65, Yan An Road (West), Shanghai, 200040, China
中国上海市延安西路65号上海国际贵都大饭店办公楼405单元
Phone: +86-21-62489820
Fax: +86-21-62489821

© 2011 The Author(s). Licensee IntechOpen. This is an open access article distributed under the terms of the [Creative Commons Attribution 3.0 License](https://creativecommons.org/licenses/by/3.0/), which permits unrestricted use, distribution, and reproduction in any medium, provided the original work is properly cited.

IntechOpen

IntechOpen