

We are IntechOpen, the world's leading publisher of Open Access books Built by scientists, for scientists

6,900

Open access books available

185,000

International authors and editors

200M

Downloads

Our authors are among the

154

Countries delivered to

TOP 1%

most cited scientists

12.2%

Contributors from top 500 universities



WEB OF SCIENCE™

Selection of our books indexed in the Book Citation Index
in Web of Science™ Core Collection (BKCI)

Interested in publishing with us?
Contact book.department@intechopen.com

Numbers displayed above are based on latest data collected.
For more information visit www.intechopen.com



Anesthesia for Arthroscopic Shoulder Surgery

Diego Benítez and Luis M. Torres

*Department of Anesthesia, University Hospital Puerta del Mar,
Cátedra del Dolor Fundación Grunenthal-Universidad de Cádiz
Spain*

1. Introduction

Arthroscopic shoulder surgery is a minimally invasive technique that effectively treats certain diseases and injuries of the shoulder joint. Indeed, new lesions and surgical techniques for their treatment have also been discovered by using this approach.

Controlling post-operative pain in shoulder surgery facilitates early mobilization and fast functional recovery, allowing pain-free muscle contraction. Tissue injury due to the surgical intervention results in the release of many chemical mediators that activate and increase the excitability of nociceptors, producing intra- and post-operative hyperalgesia. Local anesthesia can be used more frequently for less aggressive surgical techniques, particularly in limb surgery, both for intra-operative and post-operative pain.

It is essential to be familiar with the anatomy of the region to be anesthetized in order to minimize the potential risks and recognize them when they occur. The upper limb is innervated by the arms of the cervical spinal nerves (C5-C8) and part of the ventral branch of T1, although anatomical variations may exist. All these sensory, motor and vegetative nerve fibers form an "anastomotic complex of fibers", known as the brachial plexus.

The block of the brachial plexus was first developed in 1884, when Halstead injected cocaine into the exposed roots of the brachial plexus (1). However, it was not until 1911 that Hirschel and Kulenkampff described the percutaneous brachial plexus block first developing the axillary technique and then, the supraclavicular route (2,3). In 1919, Mulley developed a technique aimed at preventing pneumothorax by employing interscalenic approach to the brachial plexus (4). The modern interscalenic approach was perfected by Winnie, using the transverse processes of the 6th cervical vertebra (5) as a reference for needle insertion.

Anesthetic options for shoulder arthroscopic surgery include: general anesthesia, regional anesthesia with or without sedation, and a combination of both general and regional anaesthesia. Regional anesthesia offers many advantages over general anesthesia for arthroscopic shoulder surgery. The most notable advantage is the ability to control perioperative pain by proximally blocking the brachial plexus (supraclavicular approaches). The "Preemptive" analgesia afforded by the blockade and the excellent analgesic conditions can overtake the need for intraoperative opioid administration. The patients' perception of pain-free surgery represents a further advantage of this approach. Together, this facilitates earlier hospital discharge with the attendant reduction in the economic cost of the procedure (6,7).

Relaxing the shoulder muscles is essential for successful surgery. We have observed that the muscle relaxation obtained following the interscalene blockage are superior to those observed with general anesthesia, without the need for tracheal intubation and mechanical ventilation due to neuromuscular blockade. Also, there is a decrease in perioperative bleeding associated with regional blockade in shoulder surgery (8). Mechanical ventilation increases intrathoracic pressure and as a consequence, the venous pressure in the upper limbs. This increase in pressure augments venous blood loss, which can be avoided if the patient is breathing spontaneously. In addition, the sympathetic blockade produced by regional blocking, combined with the semi-recumbent position of the patient, decreases venous pressure and bleeding. Hemodynamic stability itself favors regional anesthesia, decreasing mean arterial pressure and bleeding. Moreover, supraclavicular nerve blockage techniques without the need for general anesthesia decrease the possibility of aspiration of stomach contents, making them particularly attractive for emergency surgery.

The total time required does not differ greatly between the different anesthetic techniques, despite the obvious advantages associated with particular approaches. In fact, proximal brachial plexus block, performed by an expert, requires less time than the induction of general anesthesia, especially considering the shorter recovery time associated with regional anesthesia. In addition, the associated latency period can be used to position the patient and prepare the surgical area. The availability of a room for to perform specific preparation before the patient enters the operating theatre also optimizes resources and anesthesia times. Other notable advantages of regional versus general anesthesia include decreased post-operative complications, earlier discharge from the post-operative recovery room, the need for less apparatus, fewer nursing requirements and reduced hospital readmissions (9,10). Together, these advantages make such techniques the better choice for the majority of surgical procedures of the shoulder. The development of modern neurolocalization techniques, such as the use of ultrasound with peripheral nerve blockade, has improved the efficacy and safety of blind techniques, avoiding paresthesia and nerve stimulation, enabling real-time imaging of neural structures.

2. Anatomy of the proximal nerve structures in the upper extremity

As indicated, the brachial plexus is formed by the anterior branches of spinal nerves C5-T1. The union of these fibers is highly variable among individuals and can even be asymmetrical in certain individuals, often also involving fibers C4 and T2. Nevertheless, the organization observed in up to 70% of cadavers involves 3 main trunks: the anterior branch of C5 fusing with that of C6 to form the upper primary trunk; the anterior branch of C7 forms the average primary trunk; and the anterior branch of C8 and T1 join to form the lower primary trunk.

Each of these primary trunks divides into an anterior and posterior branch. The three posterior branches unite to give rise to the posterior cord (the origin of the axillary nerve), circumflex and radial, which is the terminal portion. The anterior branches of the middle and upper primary trunks merge to form the lateral cord, which later gives rise to the musculocutaneous nerve and the lateral portion of the median nerve. The anterior branch of the inferior primary trunk gives rise to the medial cord, which will ultimately separate into the ulnar nerve, medial antebrachial cutaneous nerve and medial cutaneous nerve. The latter two, along with the intercostobrachial nerve, collect sensitivity from the medial arm. The median nerve also receives a portion of the medial cord (Figure 1)

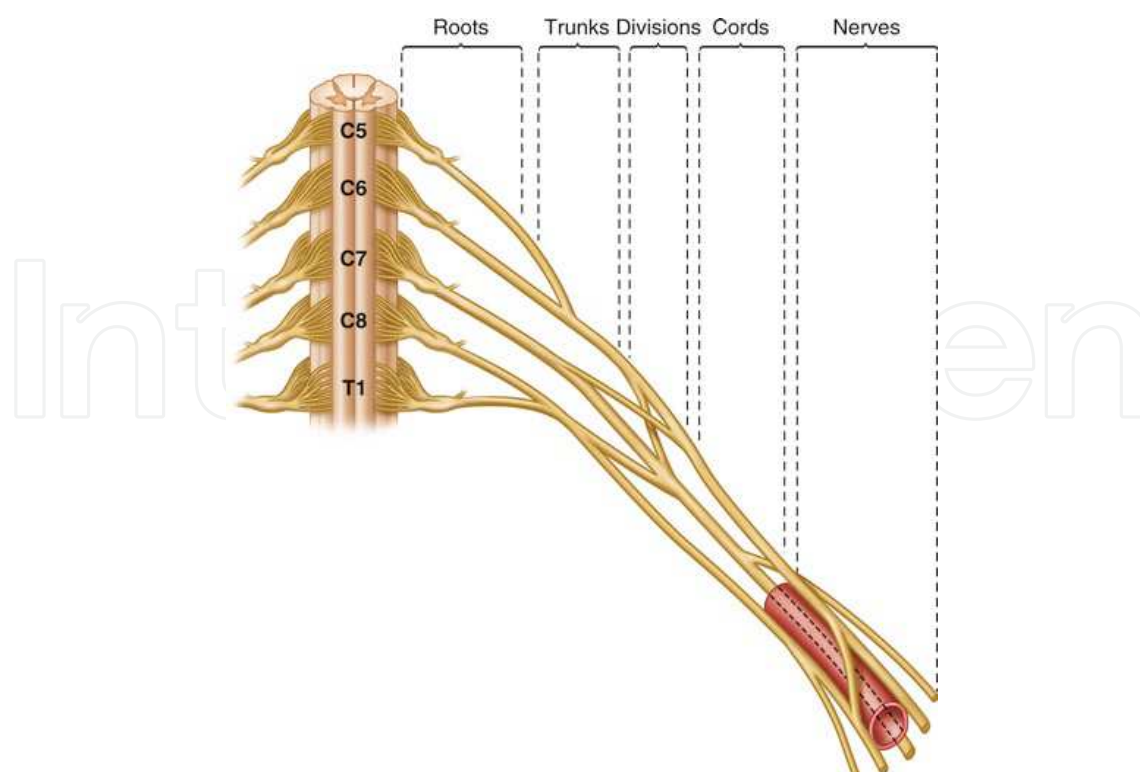


Fig. 1. Schematic representation of the structures of the left brachial plexus.

Situated at the upper surface of the spinous process of the cervical vertebra. From here they run out and down between the anterior and middle scalene muscles to reach the lateral base of the neck, close to the subclavian artery but is above the pleural dome. They then appear within the costoclavicular axillary canal, closely associated with the vascular bundle.

In the interscalene space, the middle and upper primary trunks are more superficial than the lower trunk. The supraclavicular part of the plexus undergoes its first division in the costoclavicular space, forming a group of clustered secondary trunks lateral and superficial to the subclavian artery, and above the first rib and pleural dome. At the infraclavicular level, the plexus forms a series of bundles or cords (lateral, medial and posterior) around the axillary artery. Distally the terminal branches are individualized, forming the median, ulnar and brachial cutaneous nerves, the medial forearm and the intercostobrachial nerve in the humeral canal. The musculocutaneous nerve and the radial nerve run outside the humeral canal.

3. Preoperative study

Anesthesia visit should be used to carry out both a global study of the surgical-anesthetic risk, and to reduce the patient's anxiety before surgery. Indeed, the treatment of post-operative pain begins in this pre-operative period, with apprehension and anxiety increasing when patients are poorly informed as to the upcoming procedures. In examining the personal background of the patient, it is important to note any previous surgical interventions, particularly those in the cervical and thoracic region.

upper airway should be explored in detail, from the mouth to the base of the neck, noting and missing teeth or dentures that might make ventilation and endotracheal intubation more difficult. Observe whether the patient has a short neck or an increased cervical diameter, which determines the location of skin reference points for locking and positioning if an

ultrasound transducer is employed. It may be difficult to maintain good ventilation in obese patients and to use the neurostimulator to find the brachial plexus in the different supraclavicular approaches. The preanesthesia visit is a good time to perform this exploration. Chronic lung disease may be a relative contraindication to performing a bilateral interscalene block, since phrenic nerve block exacerbates the poor respiratory function in such patients. In such cases additional studies may be necessary, such as chest RX and basic tests of respiratory function (*e.g.*, spirometry).

We explore the contralateral arm to see determine whether the patient has a clear vein network channel for peripheral venous administration, or whether an alternative route of administration will be required. While the patient must fully informed of the technique they are to undergo, if told "a needle will be inserted into your neck" their levels anxiety are likely to rise. However, a correct explanation of the technique, starting at the pre-operative visit and continuing up to and during the procedure, along with adequate sedation, will significantly increase the patient's satisfaction with the technique, as well as their confidence in the anesthesiologist.

A blood analysis including blood counts and basic clotting biochemistry must be performed, particularly for more invasive surgical procedures such as prosthetic glenohumeral joint or proximal humerus fractures. Arthroscopic procedures themselves do not involve bleeding. A severe impairment of clotting is an absolute contraindication for performing the regional block technique, although it can be partially permissive if taking into account the benefit/risk in those patient at the limits of normality, and particularly when ultrasound-guided block is performed by an expert. We also investigate factors or conditions that potentially increase the risk of post-operative nausea and vomiting in the patient, which may require prophylactic drugs or adaptation of the anesthetic technique.

the patient must be informed of the pain they may experience after the surgical procedure, as well as of the various analgesic strategies available. of and understand the information provided during the pre-anesthesia visit, including the possible associated complications and setbacks, and they must provide informed consent for the anesthetic techniques that may be employed.

4. General considerations during surgery

Whether in the operating theatre or in an alternative location approved to perform the peripheral nerve block, access is required to a peripheral vein in the arm contralateral to the surgery at least. Where premedication with benzodiazepines or other hypnotics is required, it is desirable to provide the patient with a supplementary source of oxygen in the form of a low flow nasal cannula or face mask (11). Shoulder As shoulder arthroscopy does not involve a large degree of fluid loss, a small venous line will suffice (a 20G needle should be adequate). However, fluid deficits due to pre-operative fasting should be calculated.

Basic patient monitoring principles should be applied, including circulatory parameters such as heart rate and non-invasive blood pressure, partial oxygen saturation, continuous electrocardiogram leads II (for better evaluation of rhythm disturbances) and V5 (for better assessment of ST segment changes and repolarization). In cases where the patient receives mechanical ventilation or spontaneous ventilation through a supraglottic airway device, FiO_2 and fractional exhaled CO_2 should be continuously monitored, along with basic ventilation parameters (tidal volume, respiratory rate, index I:E, airway pressure and PEEP if applicable). The patient's temperature should also be controlled systematically, given the considerable loss of heat that can occur during surgery.

position of the patient during arthroscopic examination is fundamental and poor positioning will affect the surgeon's movements, dexterity and maneuverability of the instruments, and traction vector placement. The position of the patient will depend on the type of surgery, the personal preferences of the surgeon and the specific workplace in question. Correct initial placement of the patient avoids subsequent postural adjustments during surgery, which can increase both surgical and recovery times.

5. Lateral decubitus

Proposed This method was first proposed by Wiley and Older (12), whereby the patient is positioned with a lateral tilt, leaving the arm exposed. No traction should be used, and the position of flexion and adduction of the arm should allow easy penetration of the shoulder joint.

In order to obtain greater diastasis of the joint, Andrews and Carson (13) positioned the arm at about 70° of abduction and 15° of flexion, with adequate longitudinal tension, although this may lead to overstretching the neurovascular structures (Figure 1). Different drivelines can be applied to the upper limb but the weight applied to traction should under no circumstances exceed 4-6 kg. Moreover, as the drive can induce ischemic stroke, traction for more than 2 hours should be avoided. Paulos (14) reported 30% transitional neuroapraxia after shoulder arthroscopy. Before traction, the upper limb should be slightly rotated internally at the elbow to reduce the tension on glenohumeral ligaments, thereby augmenting the joint space. In preparing the operating room is important to place the anesthesia machine beside the surgical bed to provide the surgeon with sufficient room to move and operate (Table 1).

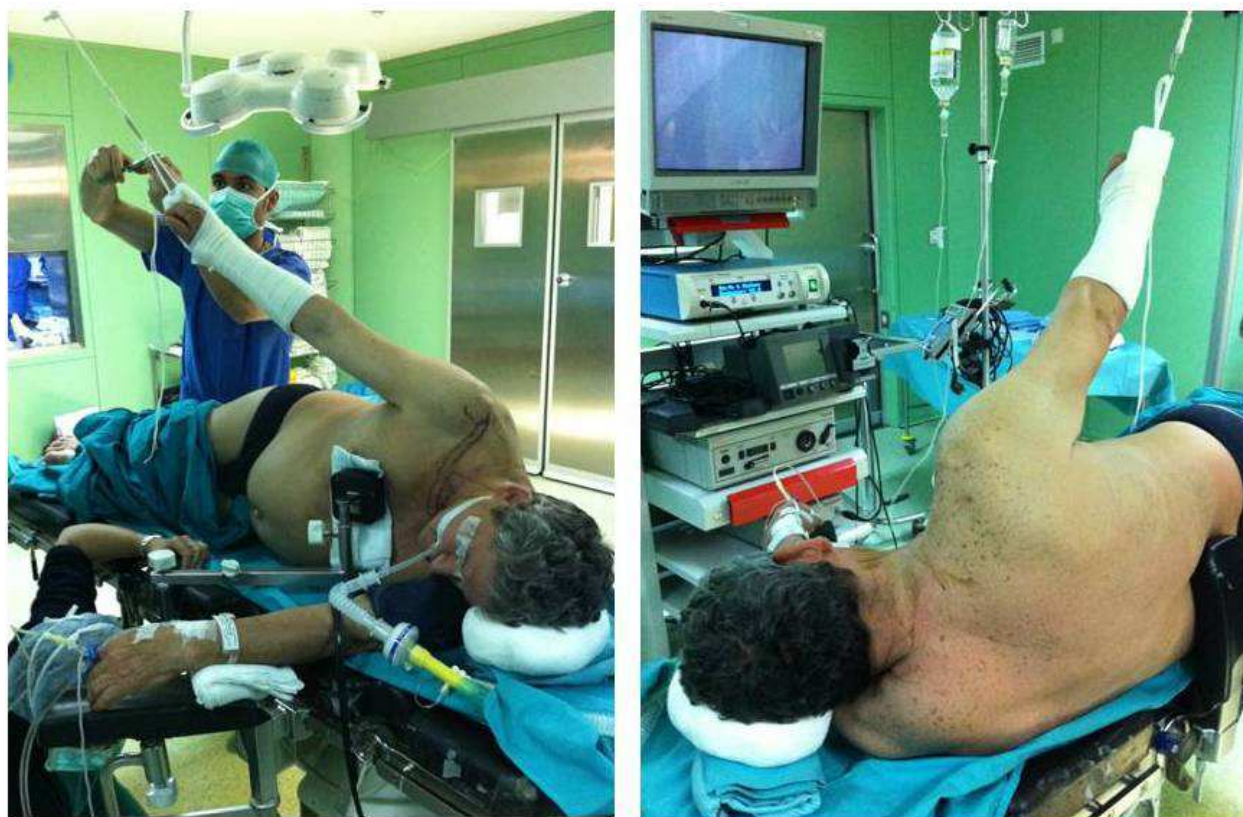

Fig. 1. Lateral decubitus position.

Lateral benefits	Disadvantages
Better view of the joint space with traction device	Difficulty of penetrating the joint due to the slope
More space for front and rear access	The conversion of arthroscopy to open surgery is uncomfortable
	Risk of excessive traction on the brachial plexus
	Poorly tolerated with only local anesthesia

Table 1. Patient position

6. Sedestación beach chair position

Described This was described in 1988 by Skyhar, whereby the patient sits on the operating table with the help of specially designed brackets, with the trunk flexed 60-80° to the horizontal. The hemithorax on the affected side must be free in the dorsal region to situate the posterior shoulder portal. The head and neck are supported by a specific device, with the head in slight flexion and extension, avoiding extreme rotation that could have a detrimental effect by overdistingending the brachial plexus (Figure 2). This position also reduces the risk of brachial plexus injuries when compared with the lateral position, and it is better tolerated with only local anesthesia (Table 2).

Advantages	Disadvantages
Better tolerated with local anesthesia	Poor display without pulling the joint and the axillary recess
Reduced patient installation time	Difficulty moving the lens if the position is not maintained
Upper limb mobility	Increased associated risk of hypotension
No need for traction	
Reduce Reduced risk of neuroapraxia	
Facilitates eventual conversion to open surgery	

Table 2. Characteristics of the Beach Chair Position

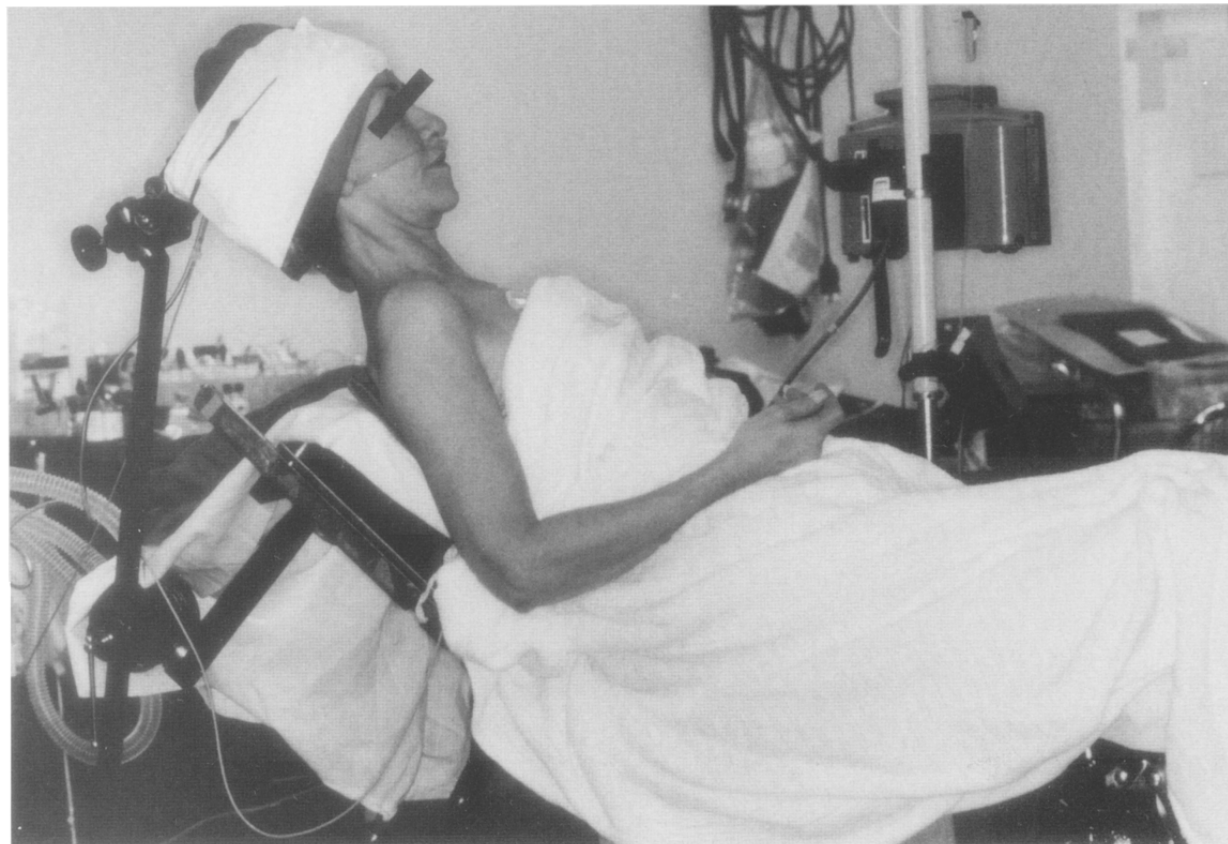

Fig. 2. Representation of the Beach chair position

Maintaining normothermia and preventing heat loss by the patient during surgery is essential due to the large amount of fluid infused into the joint. Hypothermia slows patient recovery. Indeed, shivering increases tissue oxygen demand and decreases cardiac output, thereby hindering proper oxygen and nutrient exchange to tissues, leading to acidosis. After surgery, the material that covers the patient is usually wet and cool, which also makes the patient cool. Using waterproof materials is effective, as is good continued aspiration of the instilled fluid. Furthermore, mechanical ventilation lowers the temperature by using a cold gas. Fluid heating systems and convection heating elements are usually effective in this kind of surgery for prophylaxis of hypothermia.

The interscalene and supraclavicular approaches to the brachial plexus (above the clavicle or proximal), have proven effective and safe for anesthesia and post-operative analgesia in arthroscopic shoulder surgery. Recently, a new safe and effective approach to arthroscopic shoulder surgery was advocated, blocking the suprascapular nerve and axillary nerve, although this is a preliminary study (15). The parascalene approach is also thought to offer safe and effective anesthesia for these procedures, as well as a unique benefits in the treatment of acute postoperative pain (16).

The intercostobrachial nerve comes from the thoracic nerve roots T1-T2 and it is responsible for the sensitivity of the anteromedial aspect of the arm. Since some techniques do not block the supraclavicular nerve, this is achieved with a subcutaneous wheel and 3-5 ml of local axillary anesthetic, superficial to the area of palpation of the axillary artery (Figure 3).

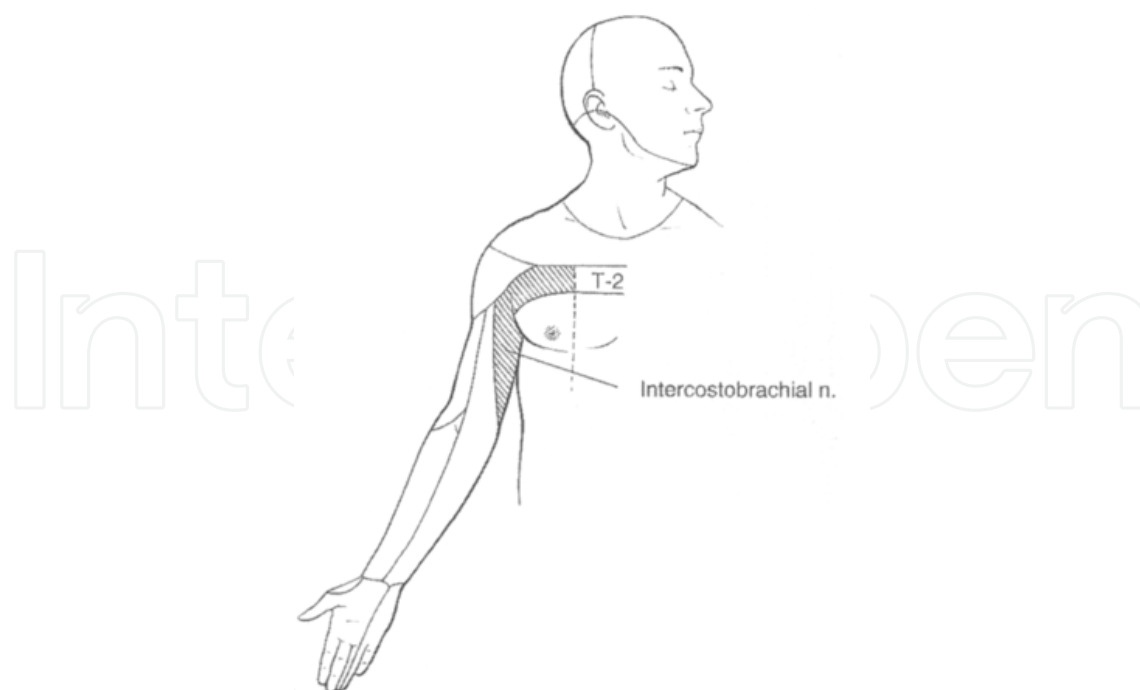


Fig. 3. Schematic representation of the sensitive area of the intercostobrachialis nerve.

7. Interscalenic approach to the brachial plexus

In blocking the brachial plexus in the proximal interscalene space, the anesthesia is applied to the roots or nerve trunks to achieve a metameric distribution of the anesthesia. The plexus is formed by the anterior divisions of the C5 to T1 nerves, with regular contributions from C4 and T2. When the nerve roots exit through the intervertebral foramina, they head down towards the first rib surrounded by a fascia or aponeurotic sheath. This sheath extends into the upper arm by forming partitions, which hinders the diffusion of the anesthetic. Just before you reach the first rib (interscalene space), the roots above are fused together to give three trunks, referred to as the superior (C5-C6), middle (C7) and lower (C8-T1) in a craniocaudal direction. Both the plexus and the scalene muscles are located within a limited anatomical region defined by the outer edge of the sternocleidomastoid muscle, the upper edge of the middle third clavicular and anterior border of the trapezius muscle. This area is located external to the jugular vein, which must be born in mind to avoid puncture.

In the interscalene groove, roots that form the brachial plexus begin to coalesce to give rise to the upper, middle and bottom trunk. At this site, the brachial plexus is located at an approximate distance of about 1 cm from the skin and therefore, it is advisable to use high-frequency (10-15 MHz) and low penetration (3 - 4 cm) probes for exploration.

8. Classic cross-cutting approach

To perform the block, the patient is placed in a supine position with the head rotated slightly to the side contralateral to the blockade. In the classical approach we use a probe situated transversely direction, putting it in the midline of the neck and starting at the level of the cricoid cartilage (Figure 4).

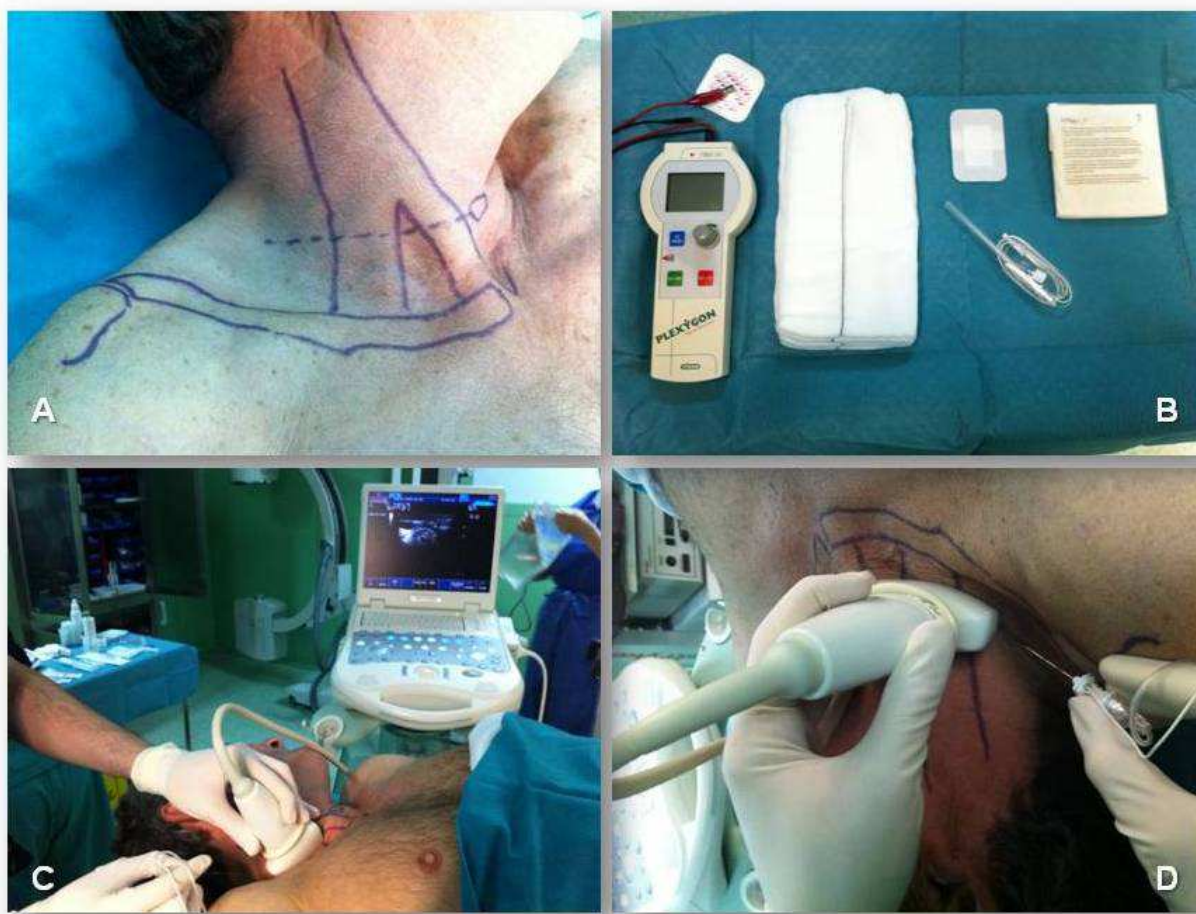

Fig. 4. A. Representation of the most relevant references in the neck skin to the perform an interscalene block. B. Material for blockade by neurostimulation. C. Plexus Neurolocalization by ultrasound. D. Plexus approach using ultrasound with needle insertion "flat" from the side.

In the resulting image and for educational purposes, three areas can be identified when using this approach. A superficial area (located in the upper area of the ultrasound screen) occupied mainly by muscle structures, most of them more shallow than the sternocleidomastoid muscle. A middle zone located immediately under the muscle plane described above in which the tracheal lumen and cricoid cartilage lie, and lateral to the tracheal lumen the homogeneous texture of the thyroid lobe can be observed (Figure 5a), together with two vascular structures: a) the most inner and rounded one going up to the pulsating carotid artery; and b) the outer triangular one that readily collapses on applying pressure with the scanning probe corresponds to the internal jugular vein (Figure 5b). A deep zone (located in the lower area of the ultrasound screen) the lower limit of which marks the vertebral transverse process, which at this level corresponds to C6. Once these structures have been identified, the probe can be moved laterally and by maintaining the same angle, interscalene scan plane is reached (Figure 5c).

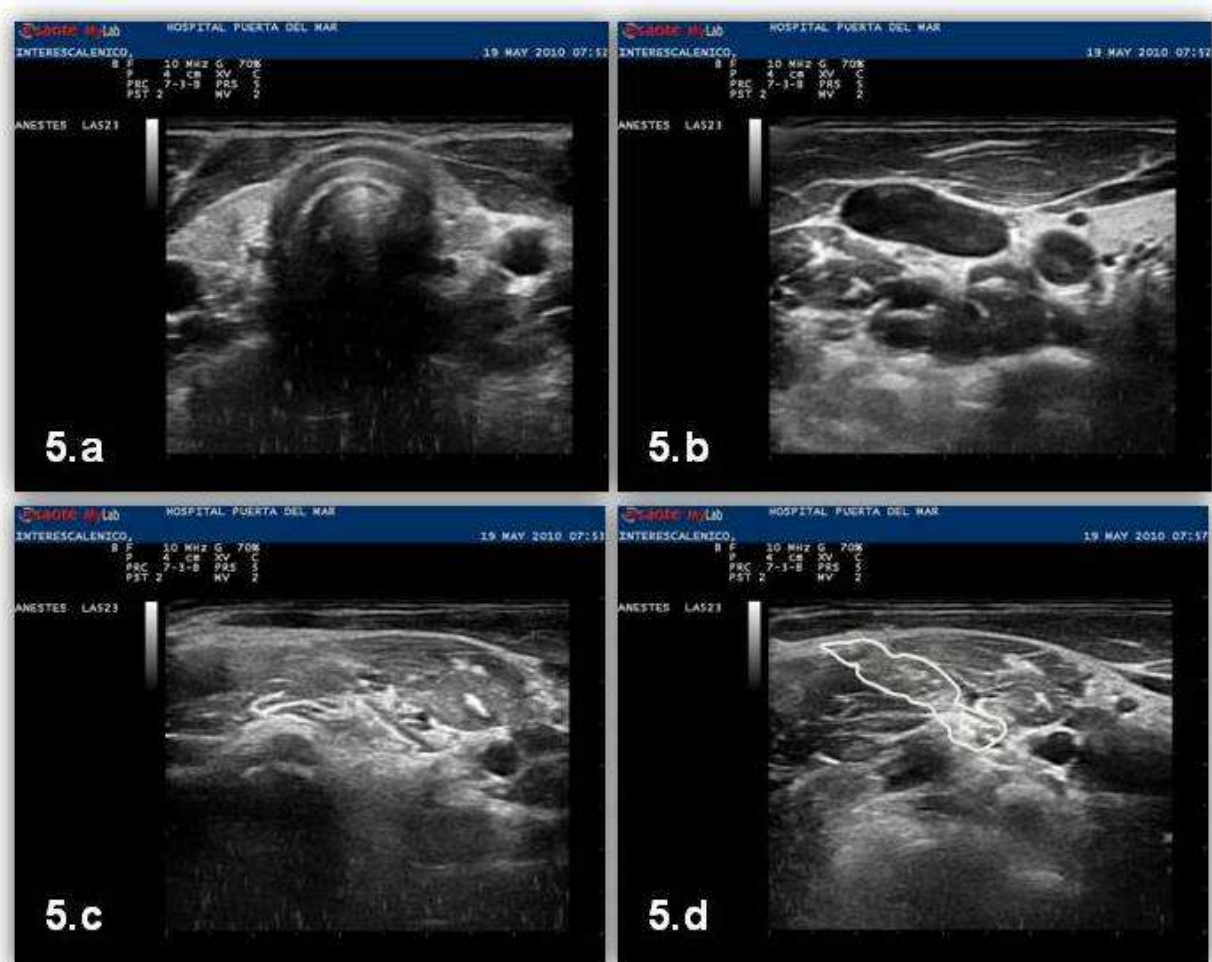


Fig. 5. Cervical screening ultrasound images left of the cricoid cartilage (C6), from medial to lateral. Figure 5b, the interscalene space can be seen just after the deposit of the local anesthetic (area designated).

Medium zone. Beneath the sternocleidomastoid muscle, the anterior scalene (located more medially) and middle scalene (located more laterally) muscles can be seen, and between the two muscles the roots of interscalene brachial plexus groove are located. Their images appear as oval or round, hypoechoic (dark image), hyperechoic rim (white) and often with a dot inside (Figure 5c).

Inferior zone. Located immediately under the scalene muscles, the longus colli can be identified lateral to the vertebral artery a round, hypoechoic and pulsating image crossing medially to laterally. It is important to differentiate the nervous structures (well rounded and hypoechoic but not pulsating) that are often in line but below them in the picture. If in doubt, the scan mode used color Doppler to show the pulsatile flow of the artery, which is not seen if the nerve roots are being explored.

9. "Alternative" cross-cutting approach

In an alternative approach described by Jack Vander Beek, the ultrasound scan is performed in the caudocraneal sense instead of the medio-lateral sweep of the "classic" technique. This approach is especially useful in patients with previous anatomical changes in the neck (surgery, radiotherapy, lean muscle bellies, etc.). Whichever approach is chosen, it is advisable to make subtle and rapid caudocraneal movements that will help visualize the nerve roots. It is advisable to define the scalene and focus on finding the nerves.

10. Implementation of the blockade

Having identified the brachial plexus in the interscalene space, the needle is inserted lateral to the transducer (flat) and with a local anesthetic bolus (remember the plexus is located about 1 cm from the skin), the needle is advanced while directly visualization the plane with the transducer until it enters the interscalene groove and is located adjacent to a nerve root. It is preferable to situate the needle at the deepest roots so that when we start to infuse the local anesthetic, it pushes us toward superficial plexus, improving the success rate. After gentle aspiration, we proceed to inject the local anesthetic, confirming the spread of local anesthetic into the interscalene groove by direct visualisation.

11. Indications

- Primarily for analgesia and anesthesia of shoulder and proximal arm.
- In cases of long-term surgery or intention analgesia, it may be appropriate to implant a catheter.

12. Complications

- Perimedulla Dissemination: which would produce a spinal block and require ventilation support. This can be prevented by aspiration prior to injection and checking there is no CSF fluid.
- Systemic toxicity: direct intravascular injection (perform test prior to aspiration) or by absorption of the anesthetic.
- Vasovagal syncope: due to a Bezold-Jarisch reaction (hypotension and bradycardia, possibly with extreme apnea). Cervical sympathetic blockage occurs and venous return becomes difficult due to the surgical position (sitting). It usually occurs 30-60 min after blockade. Treat with ephedrine or atropine if needed, and vascular fluid filling.
- Ipsilateral phrenic nerve palsy: is constant in the interscalene block. Translate a cephalic spread over C6.
- Changes in phonation, hoarseness if recurrent involvement (rare), superior laryngeal nerve block anesthesia of hemipharynx (more common). If phonation disturbance persists, consider anatomical nerve involvement and monitoring.
- Horner's syndrome: produced by affecting the stellate ganglion. If it persists, suspect anatomical node involvement such as hematoma.
- Pneumothorax.
- Delayed neurological dysfunction: usually transient.

Other considerations and peculiarities:

- Do not hold bilateral blocks in patients with respiratory disease.
- It is not entirely clear whether alterations can be made in hemostasis.
- May require superficial Superficial cervical plexus block may be required (sensitive innervations of the skin over the shoulder on top and above). This can be achieved by infiltrating 5-10 ml of anesthetic in a fan at the posterior lateral edge of the sternocleidomastoid muscle from the midpoint of an imaginary line between the mastoid and the clavicle.

13. Supraclavicular approach of brachial plexus

The supraclavicular fossa is limited by the outer edge of the sternocleidomastoid muscle, the middle third clavicular and the anterior border of trapezius. When the trunks of the brachial plexus abandon the interscalene space, they form 6 divisions, 3 above and 3 below. The brachial plexus is directed from the corresponding interscalene space to the axilla, passing over the 1st rib between the attachments of the anterior and middle scalene muscles, and below the collarbone. When the plexus lies between the first rib and the clavicle, it remains surrounded by a fascial sheath, maintaining a close relationship to the subclavian artery, although extending above and remaining external to it. The subclavian vein is located above the 1st rib and enters into the anterior scalene muscle.

For ultrasound imaging of the brachial plexus, the supraclavicular ultrasound probe should be placed in the supraclavicular fossa, parallel to the clavicle and the edge, touching its inside while at an angle to the chest. This represents the "guide" to locate the subclavian artery. It is desirable that this approach is made at a level that includes the artery in the center of the image, clearly positioned on the first rib, leaving the farthest edge of the pleura on each side. In that way, the nerves will be situated in a superior position external to the artery. It is sometimes possible to observe a cross-section of the subclavian vein, which appears as a hypoechoic round structure that does not pulsate, with internal strings of images that correspond to valvular structures. Anatomically, it is situated before the insertion of anterior scalenus muscle, and thus medial to the muscle in the image, and in most cases it is obscured by the clavicle.

14. Performing the technique

To achieve the supraclavicular block, the patient is placed in a prone position with the head turned slightly to the side contralateral to the blockade and with their arm parallel against their body. The probe is placed just above the collarbone, parallel to it, and the map obtained is the oblique coronal plane, that offers a cross section of the subclavian artery. In At this site, the brachial plexus is located approximately 1 cm from the skin and therefore, it is advisable to use high-frequency (10-15 MHz) and low penetration (3-4 cm) probes for exploration (Figure 6).

The needle is inserted through the lateral end of the probe, moving at an angle of about 20° to the skin and parallel to the transducer. After inserting the needle tip into the plexus and gentle aspirating, the local anesthetic solution is slowly injected. A sign of good distribution of the local anesthesia is the peripheral displacement of the divisions/trunks that form the plexus at this level, and the strengthening of their hyperechoic rim. It is recommended that the needle be replaced if the local anesthetic is distributed asymmetrically.

an even distribution of the local anesthetic will produce blockade in all the territories dependent on the brachial plexus nerve in > 80% of cases. To achieve uniform distribution of the anesthetic, a slow injection is paramount, along with high resolution ultrasound to directly observe its distribution.

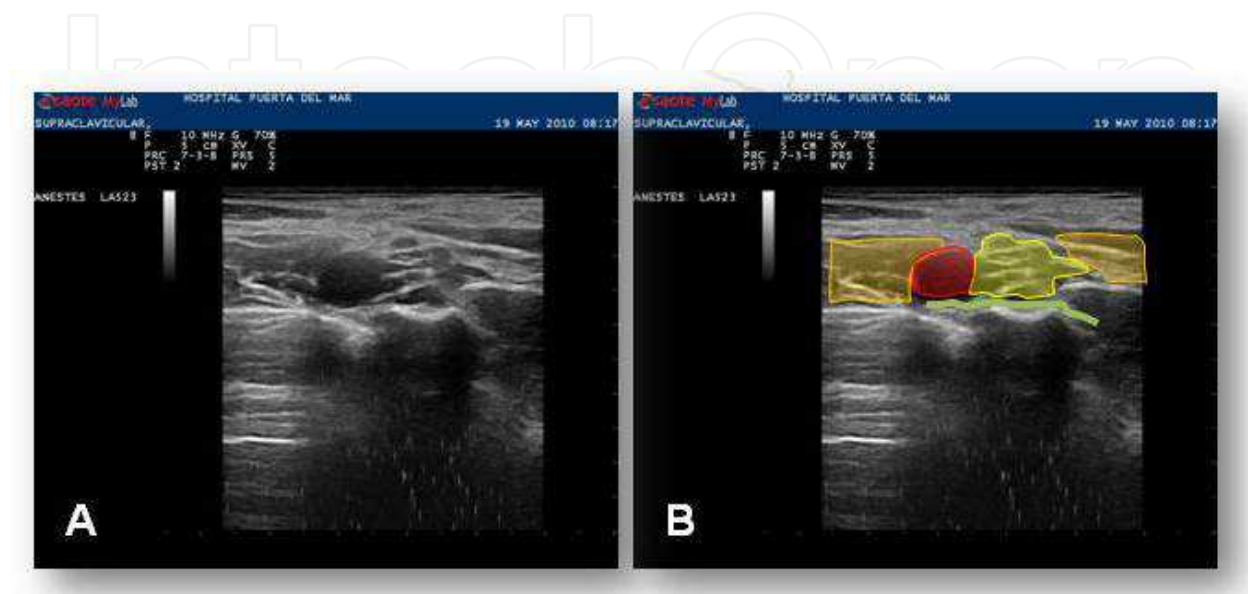


Fig. 6. A. Ultrasound anatomy of the supraclavicular brachial plexus. B. Schematic representation of the scalene muscles (orange), subclavian artery (red), first rib (white) and brachial plexus (Yellow)

The Brachial plexus blockage via the supraclavicular approach has some notable advantages:

- In the supraclavicular block, a single, uniformly distributes injection of local anesthetic may achieve a total blockage of all forearm and arm nerve territories, including the medial cutaneous nerves of the arm, the musculocutaneous forearm nerves and the axillary nerve.
- Compared with infraclavicular blockage, supraclavicular access is more effective in terms of radial blockade of the territory using a single puncture technique.

15. Complications

- Pneumothorax: classically described as late onset, although direct visualization of the pleura during blockade should reduce this potential complication.
- Systemic toxicity: direct intravascular injection (test by prior aspiration) or by absorption of the anesthetic.
- subclavian Subclaviar arterial puncture.
- ipsilateral Ipsilateral phrenic nerve palsy.
- Changes in phonation: hoarseness if the recurrent nerve is involvement (rare).
- Horner's syndrome: due to blocking the stellate ganglion.

- delayed Delayed neurological dysfunction: usually transient.

Other considerations and peculiarities:

- Given the possible occurrence of pneumothorax in the hours after the blockade, this may not be a good option for outpatient surgery.
- Contraindicated for use in patients with respiratory disease, contralateral recurrent paralysis and impaired hemostasis.
- It may be necessary to perform a concomitant intercostobrachial nerve block if there is prolonged use of a tourniquet. This nerve root emerges from D2-D3 and it is responsible for part of the sensitivity in the inside of the arm, lying over the artery in the subcutaneous tissue of the axilla.

16. Postoperative analgesic management

Proper management of acute post-operative pain after arthroscopic shoulder surgery enables patients to be discharged earlier, reducing the rate of rehospitalization, and facilitating early rehabilitation and recovery. Optimal pain control also includes evaluating the patient's physical and psychological situation, altered as a result of the surgery. As indicated, pain management should commence in the pre-operative period, while the use of neuromodulator drugs, such as gabapentin/pregabalin, can reduce post-operative pain and the need for analgesics after arthroscopic surgery for ruptured rotator cuff (17). In the intra-operative period, pain can be controlled by administering the appropriate analgesic anesthetic technique, both in terms of the type of approach and the local anesthetics used, as well as the intra-articular drugs administered (18). Post-operative management includes oral/IV analgesics, heated iv fluid and if necessary, the use of narcotics or continuous perineural infusion techniques (19).


Multiple studies have compared different therapeutic strategies have often been compared, including single dose perineural infiltration and continuous infusion techniques (20), technical perineural analgesia versus intravenous patient controlled analgesia, perineural versus intra-articular analgesia (21,22), etc. The pPain is usually worst during the first 48h and it is influenced by many factors apart from the surgery (23). In our experience, paracetamol administration in association with continuous intravenous infusion of NSAIDs scheduled during the first 48h successfully reduces post-operative pain, without provoking any serious side effects. Open shoulder surgery or failure in the regional block can require post-operative treatment with morphine by patient-controlled analgesia (PCA). The control and monitoring of these patients by the acute in-patient Pain Unit, or through telephone follow-up for out-patients, is very important to ensure adequate pain control and to optimize the needs of these patients. Different protocols can be used to adapt the therapy to the patient's specific characteristics, and to diagnose and treat the different potential side effects.

Particular attention should be paid to patient ventilation, which can be compromised by previous handling of the airways or by diffusion of the liquid infused into the neck joint if the lateral decubitus position was used. Check the temperature of the patient as it may fall, ensure that the patient is maintained warm and that warm fluids are infused. It is possible that post-operative nausea and vomiting may occur, especially when the blockade is associated with general anesthesia. Although rare, we can not forget the possibility of delayed onset neurotoxicity or cardiotoxicity, especially in elderly patients.

17. References

- [1] Crile GW: Anesthesia of nerve roots with cocaine. *Cleve Med J*, 1897; 2: 355.
- [2] Hirschel G: Die Anaesthesierung des Plexus Brachialis fuer die Operationen der oberen Extremitaet. *Muenchen Med Wochenschr*, 1911; 58: 1555.
- [3] Kulenkampff D: Die Anaesthesierung des Plexus Brachialis. *Zentralbl Chir*, 1911; 38: 1337.
- [4] Barash P: *Die Anesthesia*. Philadelphia Lippincott, 1989: page 13.
- [5] Winnie A: *Plexus Anesthesia; Vol 1: Perivascular techniques of brachial plexus blocks*. Philadelphia, WB Saunders Co, 1984.
- [6] Salcedo E, Shay P, Berrigan M: The pre-emptive analgesic effect of interscalene block prior to shoulder surgery (scientific poster). *Reg Anesth* 1996;21:107.
- [7] Seltzer J, Greek R, Maurer P: The preemptive analgesic effect of regional anesthesia for shoulder surgery. *Anesthesiology* 1993;79:A815.
- [8] D'Alessio J, Rosenblum M, Shea K: A retrospective comparison of interscalene block and general anesthesia for ambulatory surgery shoulder arthroscopy. *Reg Anesth* 1995;20:62-68
- [9] Maurer P, Greek R, Torjman M: Is regional anesthesia more time efficient than general anesthesia for shoulder surgery. *Anesthesiology* 1993; 79:A897
- [10] Greenberg C, Brown A: Cost containment--Utilization of techniques, personnel, equipment and supplies, in White P (ed): *Ambulatory Anesthesia and Surgery*, London, UK, Saunders, 1997, pp 635-647.
- [11] Glenn M. et al. Cerebral Oxygen desaturation events assessed by near-infrared spectroscopy during shoulder arthroscopy in the beach chair and lateral decubitus position. *Anest. Analg.* 2010; 111, 2: 496-505.
- [12] Wiley AM, Older MW. Shoulder arthroscopy: Investigations with a fiberoptic instrument. *Am J Sports Med* 1980; 8:31
- [13] Andrews JR, Carson WG, Ortega K. Arthroscopy of the shoulder: Technique and normal anatomy. *Am J Sports Med* 1984;12:1.
- [14] Paulos LE, Franklin JL. Arthroscopy Shoulder Decompression: Development and application: a five years of experience. *Am J Sports Med*, 1990; 18: 235.
- [15] Checcucci G. et al. A new technique for regional anesthesia for arthroscopy shoulder surgery based on a suprascapular nerve block and an axillary nerve block: an evaluation of the first results. *Arthroscopy* 2008; 24: 689-696.
- [16] Reig R, Sole J, Raully E. Bloqueo paraescalénico para cirugía artroscópica de hombro. *Rev. Esp. Anesthesiol. Reanim.* 2004; 51: 247-252.
- [17] Yu S, Kim T: Can gabapentine help reduce postoperative pain in arthroscopic rotator cuff repair? A prospective, randomized, double-blind study. *Arthroscopy* 2010; 26:106-11.
- [18] Ballieul RJ, et al. The peri-operative use of intra-articular local anesthetics: a review. *Acta Anaesthesiol Belg* 2009;60:101-8.
- [19] Ruiz-Suarez M, Barber FA: Postoperative pain control after shoulder arthroscopy. *Orthopedics* 2008; 31: 1130-5.
- [20] Young S, Cawley P: Postoperative pain management for arthroscopic shoulder surgery: interscalene block versus patient-controlled infusion of 0.25% bupivacaine. *Am J Orthop* 2006; 35: 231-4.

- [21] Contreras-Dominguez V, et al. Eficacia del bloqueo interescalénico continuo en comparación a la analgesia intra-articular para el tratamiento del dolor postoperatorio en acromioplastias artroscópicas. *Rev Esp Anesthesiol Reanim* 2008;55: 475-480.
- [22] Ciccone W. et al. Assesment of pain relief provided by interescalene regional block and infusion pump after arthroscopic shoulder surgery. *Arthroscopy*, 2008;l 24: 14-19, .
- [23] Anthony R. Brown. Regional anesthesia for shoulder surgery. *Techniques in Regional Anesthesia and Pain Management*, 1999; 3:64-78.



Modern Arthroscopy

Edited by Dr Jason L. Dragoo

ISBN 978-953-307-771-0

Hard cover, 302 pages

Publisher InTech

Published online 09, December, 2011

Published in print edition December, 2011

Modern Arthroscopy will assist practitioners to stay current in the rapidly changing field of arthroscopic surgery. The chapters in this book were written by a panel of international experts in the various disciplines of arthroscopy. The goals of this text are to present the classical techniques and teachings in the fields of Orthopaedics and Dentistry, but also to include new, cutting-edge applications of arthroscopy, such as temporomandibular arthroscopy and extra-articular arthroscopy of the knee, just to name a few. We hope Modern Arthroscopy becomes a core reference for your arthroscopic surgery practice.

How to reference

In order to correctly reference this scholarly work, feel free to copy and paste the following:

Diego Benítez and Luis M. Torres (2011). Anesthesia for Arthroscopic Shoulder Surgery, Modern Arthroscopy, Dr Jason L. Dragoo (Ed.), ISBN: 978-953-307-771-0, InTech, Available from:
<http://www.intechopen.com/books/modern-arthroscopy/anesthesia-for-arthroscopic-shoulder-surgery>

INTech
open science | open minds

InTech Europe

University Campus STeP Ri
Slavka Krautzeka 83/A
51000 Rijeka, Croatia
Phone: +385 (51) 770 447
Fax: +385 (51) 686 166
www.intechopen.com

InTech China

Unit 405, Office Block, Hotel Equatorial Shanghai
No.65, Yan An Road (West), Shanghai, 200040, China
中国上海市延安西路65号上海国际贵都大饭店办公楼405单元
Phone: +86-21-62489820
Fax: +86-21-62489821

© 2011 The Author(s). Licensee IntechOpen. This is an open access article distributed under the terms of the [Creative Commons Attribution 3.0 License](https://creativecommons.org/licenses/by/3.0/), which permits unrestricted use, distribution, and reproduction in any medium, provided the original work is properly cited.

IntechOpen

IntechOpen