

We are IntechOpen, the world's leading publisher of Open Access books Built by scientists, for scientists

6,900

Open access books available

186,000

International authors and editors

200M

Downloads

Our authors are among the

154

Countries delivered to

TOP 1%

most cited scientists

12.2%

Contributors from top 500 universities



WEB OF SCIENCE™

Selection of our books indexed in the Book Citation Index
in Web of Science™ Core Collection (BKCI)

Interested in publishing with us?
Contact book.department@intechopen.com

Numbers displayed above are based on latest data collected.
For more information visit www.intechopen.com



Extraintestinal Manifestations of Ulcerative Colitis

Brian Huang, Lola Y. Kwan and David Q. Shih
Cedars Sinai Medical Center, Inflammatory Bowel and Immunobiology Institute (IB)
 USA

1. Introduction

Inflammatory bowel disease (IBD) consists predominantly of ulcerative colitis (UC) and Crohn's disease (CD), which are clinically distinguished by intestinal localization, local features of inflammation, a profile of complications, and familial aggregation. UC is characterized by recurring episodes of continuous inflammation limited to the mucosal layer of the colon and rectum, and approximately 42% of UC patients have extraintestinal complications (Ozdil et al., 2004). This chapter highlights key features of each involved organ system including association, diagnosis, and treatment options.

2. Extraintestinal manifestations of Ulcerative Colitis

The extraintestinal manifestations (EIMs) of UC can affect any organ system ranging from more common ones including the skin and hepatobiliary systems, to less common ones including the cardiovascular and renal systems (Das, 1999). Studies have shown that the development of one EIM can increase the risk of developing additional complications (Monsen et al., 1990).

2.1 Skin and mucocutaneous complications

The skin is one of the most commonly affected organ systems in IBD patients. The two most common skin disorders associated with UC, erythema nodosum (EN) and pyoderma gangrenosum (PG), are reactive due to an immunologic response to UC. Non immunologic causes can also occur secondary to nutritional deficiencies and medication side effects. (Das, 1999; Timani & Mutasim, 2008). Skin disorders seen in UC caused by malnutrition include diseases such as pellagra and cheilitis. Aphthae are the most common complication of the oral mucosa, while fissures and fistulae are most common in the perianal mucosa. [FIGURES 1 AND 2] (Areias & Garcia E Silva, 1987). Standard medications used to treat UC include steroids and immunosuppressants which can cause skin disorders such as cushingoid features and drug eruptions (Timani & Mutasim, 2008). Other disorders, such as Sweet's syndrome and psoriasis have been associated with UC (Timani & Mutasim, 2008).

2.1.1 Erythema Nodosum

EN affects about 3% of patients with UC (Areias & Garcia E Silva, 1987; Evans & Pardi, 2007; Mir-Madjlessi et al., 1985; Timani & Mutasim, 2008). Lesions affect females with UC more

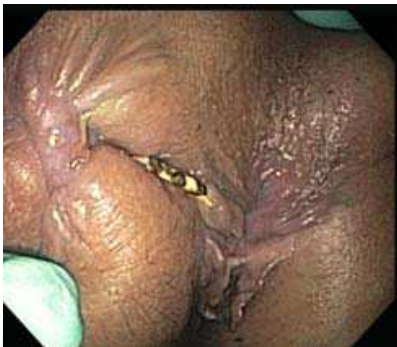

Fig. 1. Fistula with a seton

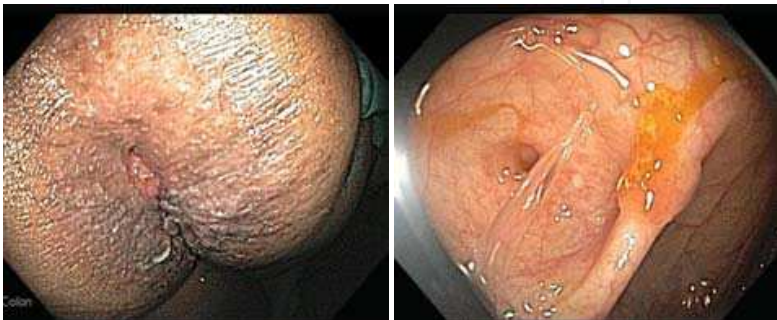


Fig. 2. UC patient with peri-anal fistula (left). Endoscopic view of fistula (right)

frequently than men and EN rarely precedes the initial diagnosis of UC (Trost & McDonnell, 2005; Weinstein et al., 2005). Typical EN lesions present as painful, raised subcutaneous lesions located on extensor surfaces of the extremities (Evans & Pardi, 2007; Timani & Mutasim, 2008). However, UC patients almost always have EN lesions on the anterior surface of the legs [FIGURE 3] (Mir-Madjlessi, Taylor et al., 1985). The skin nodules are non-ulcerating and resemble a bruise on the skin (Timani & Mutasim, 2008). Unlike PG, EN lesions mirror UC disease activity and worsen with colonic flares (Timani & Mutasim, 2008). The average lag time between initial UC diagnosis and appearance of EN is 5 years (Mir-Madjlessi, Taylor et al., 1985).

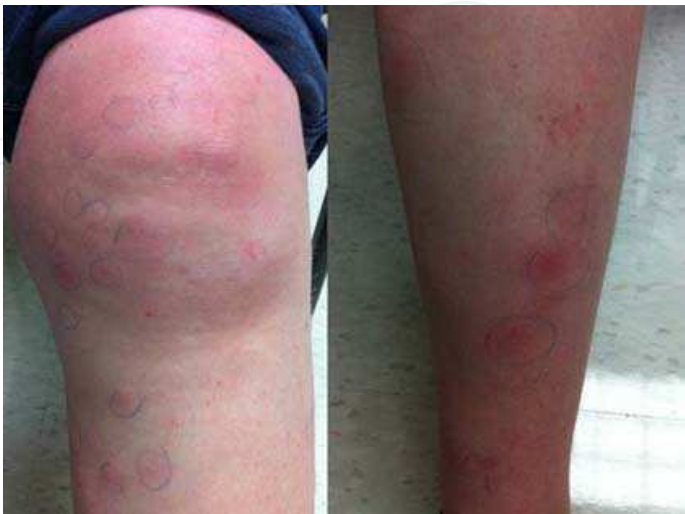

Fig. 3. EN affecting the lower extremities in a UC patient

As EN lesions and UC disease activity usually parallel each other, treatment of the underlying UC usually controls the EN lesions. Most lesions are self-limiting, thus a conservative approach to therapy is often practiced, such as leg elevation, rest, non-steroidal anti-inflammatory drugs (NSAIDs), and potassium iodide (Horio et al., 1981; Marshall & Irvine, 1997; Schulz & Whiting, 1976). In situations where lesions occur during quiescent phases of UC, treatment with oral steroids is effective. Studies have shown that time to remission in patients with EN is approximately 5 weeks which is significantly shorter than that seen in PG (Timani & Mutasim, 2008; Tromm et al., 2001).

2.1.2 Pyoderma Gangrenosum

The incidence of PG in patients with UC varies between 1.4 and 5% (Areias & Garcia E Silva, 1987; McCallum & Kinmont, 1968). PG is more commonly seen in patients with UC as opposed to CD, and as with EN, there is a slight female predilection (Bernstein et al., 2001b; Greenstein et al., 1976). PG was initially described in 1930 as necrotic ulcers with expanding borders of erythema (Newell & Malkinson, 1982). The onset of noninfectious pustules and nodules eventually expand outwards to develop painful shallow and deep ulcers (Callen, 1998; Farhi & Wallach, 2008). PG usually occurs on the legs, but can also appear anywhere on the skin [FIGURE 4]. Pathergy, a phenomenon in which skin lesions develop secondary to local trauma, has been reported in approximately 30% of cases of PG (Blitz & Rudikoff, 2001; Callen, 1998). The average lag time between initial UC diagnosis and appearance of PG is 10 years (Mir-Madjlessi, Taylor et al., 1985). Diagnosis of PG is usually clinical, but skin biopsy may be necessary for confirmation. PG is classified as a type of neutrophilic dermatosis in which the inflammatory infiltrate seen on microscopic examination shows dense dermal neutrophilic infiltrates without any evidence of infection (Cohen, 2009; Timani & Mutasim, 2008). Unlike EN, there is no temporal relationship between onset of UC flares and the course of PG lesions (Thornton et al., 1980).

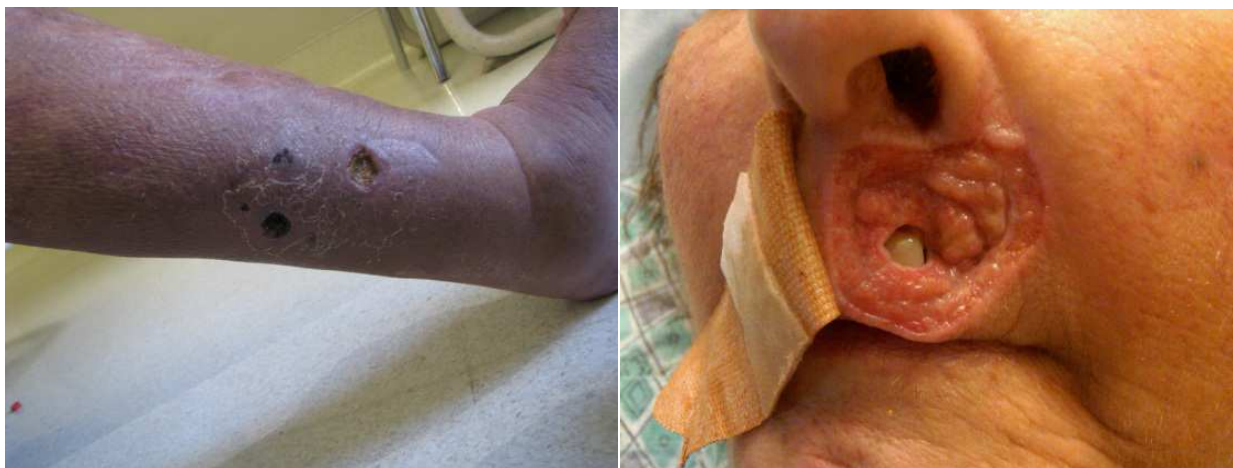

Fig. 4. PG affecting the lower extremity (left) and face (right)

In general, the PG lesions are more severe and refractory to therapy than EN. Treatment of the underlying UC activity does not always resolve the PG lesions and about 30% of patients require additional treatment (Mir-Madjlessi, Taylor et al., 1985). The mainstay of treating PG has been a combination of topical, intralesional, and systemic medications, but no specific therapy has proven to be universally effective (Cohen, 2009; Timani & Mutasim, 2008). Treatments with the best clinical evidence include systemic corticosteroids and

cyclosporine as maintenance therapy (Wollina, 2002), assuming there is no concurrent infection. Initial doses of oral prednisone have ranged from 0.5 to 2 mg/kg/day and initial cyclosporine doses have ranged from 2 to 5 mg/kg/day (Timani & Mutasim, 2008; Wollina, 2002). Maintaining target trough serum levels of 150-350 ng/ml for cyclosporine has shown to be effective in improving PG lesions (Cohen, 2009; Curley et al., 1985; Matis et al., 1992; Turner et al., 2010). In small lesions, intralesional steroid injections can be considered (Timani & Mutasim, 2008). Other agents including azathioprine, cyclophosphamide, methotrexate, high dose intravenous immunoglobulin, mycophenolate mofetil, minocycline, plasmapheresis, and hyperbaric oxygen treatment have been employed with variable efficacy (Cohen, 2009; Timani & Mutasim, 2008; Tutrone et al., 2007; Wasserteil et al., 1992). Biologics including infliximab and adalimumab have also been reported to improve PG lesions (Alkhouiri et al., 2009; Brooklyn et al., 2006). Additionally, optical treatments such as steroids, tacrolimus, benzoyl peroxide, and hydrogen peroxide have shown positive results (Callen & Jackson, 2007). To avoid pathergy, unnecessary surgical interventions should be avoided. However, surgery can be considered if medical therapies are not successful. Proper timing of the surgery with immunosuppressants is essential for optimal long term wound stabilization (Rozen et al., 2001; Wittekindt et al., 2007; Wollina, 2002).

2.1.3 Sweet's syndrome

Sweet's syndrome (SS), also known as acute febrile neutrophilic dermatosis, has a female predilection and classically affects women between the ages of 30 and 50 years (Timani & Mutasim, 2008). Although the pathogenesis is unclear, Sweet's syndrome usually develops as a response to some type of underlying systemic disease, such as infection, malignancy, medications, or IBD (Vij et al., 2010). In fact, studies have shown that patients with SS have underlying disease in 50% of cases and an underlying malignancy in 20% of cases (Kemmett & Hunter, 1990; Souissi et al., 2007). UC and CD are the most common systemic diseases associated with SS (Timani & Mutasim, 2008). SS is characterized by an acute onset of fever, leukocytosis, and tender, erythematous plaques that can occur on the extremities, face, neck, and trunk (Burrall, 1999; Kemmett & Hunter, 1990; Souissi, Benmously et al., 2007). When these lesions occur on the lower extremities, they often resemble EN and skin biopsy may be necessary to differentiate the two disease processes (Guhl & Garcia-Diez, 2008). These lesions are burning-like and non-pruritic in quality. Other associated symptoms include, but are not limited to arthralgia, headache, fatigue, and other constitutional symptoms. Other organ systems such as the eye, kidney, liver, and pancreas can be involved as well (Cohen et al., 1988). As is also seen with PG, skin biopsy reveals neutrophilic infiltrates in the reticular dermis upon histopathological examination (Kemmett & Hunter, 1990; Timani & Mutasim, 2008). The onset of symptoms from SS usually occur after the initial diagnosis of UC (Darvay, 1996).

The mainstay of treatment for SS is steroids and multiple studies have shown dramatic improvement with a 6 week course of systemic corticosteroid therapy (Cohen, Talpaz et al., 1988; Souissi, Benmously et al., 2007). Topical or intralesional steroids are effective for localized disease (Timani & Mutasim, 2008). Recurrence is common and has been reported to affect approximately 1/3 of patients (Kemmett & Hunter, 1990). Untreated lesions have been reported to heal after variable periods of time, but can be associated with scarring (Kemmett & Hunter, 1990; Timani & Mutasim, 2008). Other alternative first line treatments include potassium iodide and colchicine. Second line agents including indomethacin and clofazimine have been used with successful results, but are not as effective as corticosteroids, potassium iodide, and colchicine (Cohen, 2009; Cohen & Kurzrock, 2002).

2.1.4 Mucocutaneous manifestations

Aphthous Stomatitis. About 4.3% of UC patients experience recurrent aphthous stomatitis and symptom onset often parallels UC disease activity (Areias & Garcia E Silva, 1987; Timani & Mutasim, 2008). Minor aphthous ulcers are small, round, painful, and heal within 2 weeks without scarring, while major recurrent ulcers are larger, can last for 6 weeks, and frequently scar [FIGURE 5] (Ship, 1996; Timani & Mutasim, 2008). A study showed that a majority of patients with multiple aphthous ulcers had underlying IBD (Letsinger et al., 2005). The pathogenesis of aphthous stomatitis and UC is still unclear; studies have not been successful in proving that these ulcers are secondary to vitamin deficiencies as the lesions did not improve with vitamin therapy (Basu & Asquith, 1980). Treatment options include treating the underlying UC, symptomatic relief with steroid elixirs, and systemic treatment with steroids and immunosuppressants (Basu & Asquith, 1980; Timani & Mutasim, 2008).

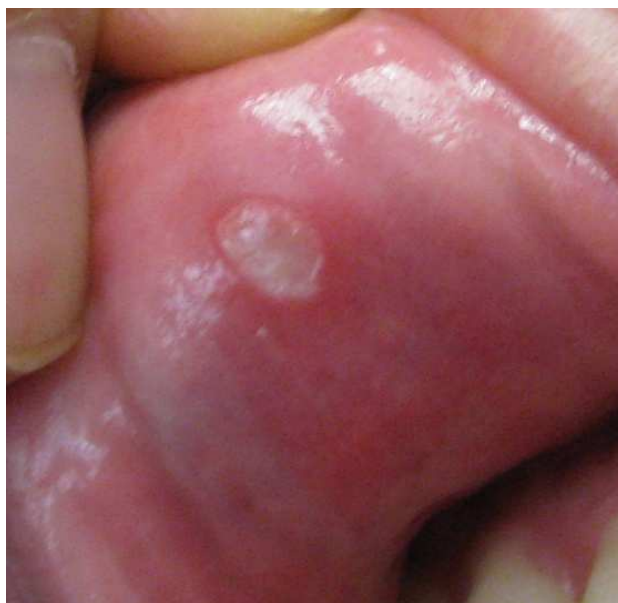

Fig. 5. Aphthous stomatitis in a UC patient

Pyostomatitis Vegetans. Pyostomatitis vegetans, a rare disorder of the oral mucosa, has been shown to be a specific marker for IBD, especially UC (Storwick et al., 1994; Timani & Mutasim, 2008). Lesions are hyperplastic folds of the mucosa with small abscesses and erosions and often manifest before the diagnosis of UC (Hansen et al., 1983).

Pyostomatitis vegetans is usually resistant to treatments such as topical steroids, antibiotic mouthwashes, or hydrogen peroxide. Systemic steroids and immunosuppressants have been employed with variable success, but were not always successful in maintaining remission (Timani & Mutasim, 2008). In one case report, topical fluocinonide gel resulted in temporary state of remission, but total colectomy was necessary to achieve complete remission (Calobrisi et al., 1995).

2.1.5 Miscellaneous skin disorders

Studies report an increased risk of psoriasis with UC. In one study, of 88 patients with UC, 5.7% had psoriasis, compared to 1.5% in the control group, suggesting some type of genetic relationship between the two (Yates et al., 1982). Another study found an association between UC and hidradenitis suppurativa [FIGURE 6].

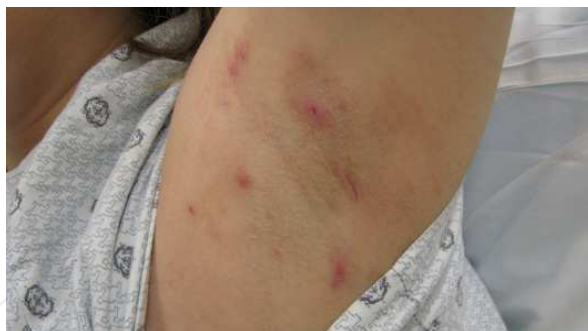

Fig. 6. UC patient with hidradenitis suppurativa

2.2 Hepatopancreatobiliary complications

There are multiple types of hepatic, biliary, and pancreatic complications associated with UC. Pancreatic complications are less common than hepatobiliary complications, but will be discussed in this section as well given its anatomic location.

2.2.1 Primary Sclerosing Cholangitis (PSC)

PSC is a chronic cholestatic liver disease that is caused by progressive inflammatory destruction of intra- and extra-hepatic bile ducts, which leads to multifocal biliary strictures, resulting in liver cirrhosis and failure. PSC is believed to be the result of a combination of genetic and immunological factors, resulting in immune dysfunction and improper targeting of the biliary system by lymphocytes and autoantibodies (Bergquist et al., 2008; Karlsen et al., 2007; Saarinen et al., 2000). Multiple autoantibodies including ANA, RF and atypical p-ANCA have been described in UC and PSC patients (Chapman et al., 2010; Terjung & Spengler, 2009). Atypical p-ANCA is detected by indirect immunofluorescence staining on ethanol fixed neutrophils in a perinuclear or nuclear pattern whereas classical ANCA targets myeloperoxidase and proteinase 3 in a perinuclear pattern (Terjung et al., 1998). Atypical p-ANCA is detectable in approximately 70% of PSC patients with or without UC and is also described in autoimmune hepatitis in patients with IBD (Duerr et al., 1991; Saxon et al., 1990; Terjung & Spengler, 2009). Atypical p-ANCA recognizes both beta isoform 5 in human neutrophils and bacterial cell division protein FtsZ, which is highly conserved across bacterial microflora in the gut (Terjung et al., 2010). This evidence supports the theory of a combined pathogenesis of PSC or autoimmune hepatitis in UC. It is proposed that an altered immune response to bacterial antigen in the gut lumen results in a "leaky gut" and stimulation of pattern recognition receptors (cross-recognition between bacterial antigen in the gut and host components, such as beta isoform 5 in neutrophils) which gives rise to autoimmunity phenomenon. (Terjung & Spengler, 2009).

PSC typically affects young to middle aged males (male to female ratio of 2:1) and while only 5% of patients with UC will develop PSC, about 70% to 80% of cases of PSC occur in patients with UC (Charatcharoenwitthaya & Lindor, 2006; Lundqvist & Broome, 1997). The onset of PSC can precede or follow the onset of UC, and may not be related to UC disease activity (Larsen et al., 2010). An isolated alkaline phosphatase level may be the only finding during the early stages of the disease, but PSC usually manifests with chronic intermittent obstructive jaundice. As the disease progresses, serum bilirubin will rise (Lee & Kaplan, 1995). In the latter course of the disease, the prothrombin time will be prolonged and serum albumin level will decrease, signaling progression to hepatic failure. Other symptoms such as right upper quadrant abdominal pain, pruritus, fatigue, fever, and weight loss are

variably present. However, PSC should be suspected in asymptomatic patients with an isolated elevation of serum alkaline phosphatase (Larsen, Bendtzen et al., 2010). Symptomatic patients manifest with icterus, jaundice, hepatomegaly and splenomegaly (Chapman, Fevery et al., 2010; Farrant et al., 1991; Wiesner et al., 1989).

Pericholangitis, described by studies as PSC of the small bile ducts, is another complication of UC. A study of 107 patients with UC showed that 35% patients had "small duct" PSC compared to 17% with "large duct" PSC, but histologic examinations were indistinguishable from each other (Wee & Ludwig, 1985). These findings imply that rather than being separate disorders, PSC and pericholangitis merely affect different areas of the same disease process. Pericholangitis (or small-duct PSC) is now referred to patients with biochemical and histologic characteristics of PSC, but with normal appearing cholangiograms (Wee & Ludwig, 1985). Small-duct PSC is more often associated with Crohn's disease whereas large-duct PSC (classical PSC) is more often associated with UC (Bjornsson et al., 2008; Loftus, 1997; Rasmussen et al., 1997). Compared to large-duct PSC, small-duct PSC has a relatively favorable prognosis with longer transplant-free survival. Approximately 25% of patients with small-duct PSC progress to large-duct PSC, but usually does not develop into cholangiocarcinoma unless it progresses to large-duct PSC (Bjornsson, Olsson et al., 2008).

The gold standard for diagnosis is endoscopic retrograde cholangiopancreatography (ERCP) and typical radiographic findings include multifocal strictures and dilatation of the intra- and/or extra-hepatic biliary tracts, producing a "beaded pattern" (Lee & Kaplan, 1995; Maccarty et al., 1983). Recently, magnetic resonance cholangiopancreatography (MRCP) has emerged as a non-invasive alternative in diagnosing suspected PSC (Chapman, Fevery et al., 2010). ERCP may be more preferable over MRCP in diagnosing early stage PSC having a specificity and sensitivity near 100% (Angulo et al., 2000; Berstad et al., 2006; Moff et al., 2006). However, ERCP does carry potential for significant risks and complications (Larsen, Bendtzen et al., 2010). Hence, there has been an increased use of MRCP as an initial diagnostic tool, followed by ERCP as needed. If the diagnosis is in doubt, liver biopsy can assist in the confirmation of diagnosis as well as staging of disease (Charatcharoenwitthaya & Lindor, 2006). However, the classic pathognomonic finding of "onion-skin lesions" or periductal concentric fibrosis is rarely seen (Chapman, Fevery et al., 2010). Liver biopsy can be essential in the diagnosis of small-duct PSC, but is not required for the diagnosis of large-duct PSC (Burak et al., 2003; Chapman, Fevery et al., 2010).

Multiple studies show that using ursodeoxycholic acid (UDCA) at moderate to high dosages has been shown to improve liver histology and liver biochemistry (Smith & Befeler, 2007). Even though UDCA has not been demonstrated to improve either symptoms or mortality, it has been shown to reduce the incidence of colonic dysplasia, colorectal carcinoma and cholangiocarcinoma (Pardi et al., 2003). Focus should be on starting these patients early enough to delay progression to cirrhosis, cholangiocarcinoma, and death. This is especially important as UDCA is not as effective in patients with end stage PSC. During treatment with UDCA, stenosis of bile ducts may occur and endoscopic intervention with dilatation has been showed to be effective (Stiehl, 2004). At the present time, liver transplantation is the only effective treatment especially for end-stage PSC or PSC with cholangiocarcinoma (Chapman, Fevery et al., 2010; Navaneethan & Shen, 2010). Orthotopic liver transplantation is the established treatment in PSC with 85% to 90% of 5-year survival rate (Gow & Chapman, 2000). However, 20 to 25% of transplanted patients develop recurrent PSC 5 to 10 years after transplant (Alabraba et al., 2009; Campsen et al., 2008; Graziadei et al., 1999; Navaneethan & Shen, 2010).

2.2.2 Malignancies

PSC has been shown to be complicated by malignancies including cholangiocarcinoma (CCA), bile duct carcinoma, gall bladder carcinoma, and hepatocellular carcinoma. Studies have shown that patients with UC and PSC are more prone to develop cholangiocarcinoma, colorectal cancer, gallbladder cancer and hepatocellular carcinoma (Broome et al., 1995; Florin et al., 2004; Kitiyakara & Chapman, 2008). Typically CCA presents as an intraductal tumor, and at times can be quite difficult to differentiate from a benign PSC stricture [FIGURE 7]. Evidence supporting diagnosis of CCA include high levels of CA 19-9, cross sectional liver imaging with long, confluent strictures and ERCP with brush biopsy of strictures, in addition to overall clinical presentation (Chapman, Fevery et al., 2010; Charatchoenwittaya et al., 2008; Levy et al., 2005). The relative risk of bile duct carcinoma in UC patients is 31.3 compared to the general population and the prognosis is quite poor with a mean survival of less than one year. PSC and pericholangitis are common pre-existing lesions in UC patients with bile duct carcinoma (Mir-Madjlessi et al., 1987). A case report recommended that in patients with UC and PSC with abnormal gallbladders, liver biopsy and cholecystectomy should be performed (Dorudi et al., 1991). Another case report documented an association between fibrolamellar hepatocellular carcinoma and UC complicated by PSC (Snook et al., 1989).

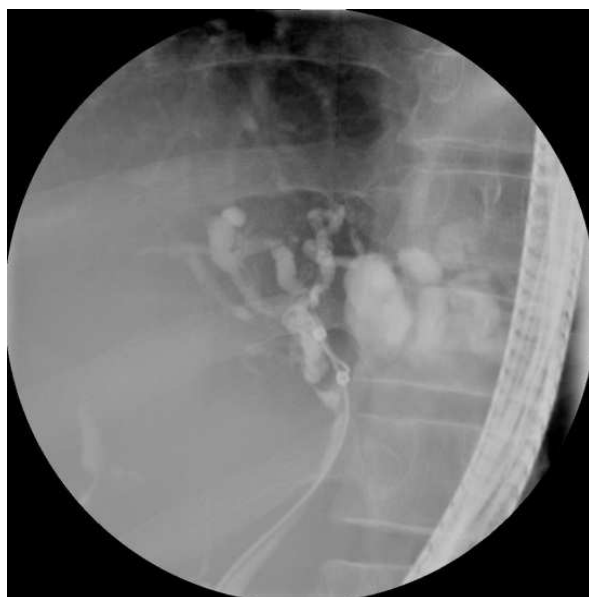

Fig. 7. ERCP of a UC patient with PSC showing high grade strictures within the right and left hepatic ducts with secondary pronounced intrahepatic ductal dilatation

2.2.3 Primary Biliary Cirrhosis (PBC)

PBC is autoimmune in nature with the unique presence of anti-mitochondrial antibodies (AMA) on laboratory testing. Studies have reported that in patients with UC, there is a 30 fold risk of primary biliary cirrhosis compared to the general population (Koulentaki et al., 1999). UC patients with PBC, as compared to patients without UC, are younger and more likely to be male. The mainstay treatment of PBC includes cholestyramine to relieve itching by reducing the amount of bile acid in the blood, UDCA to increase bile flow to reduce inflammation in bile ducts, fat soluble vitamins for nutritional supplementation, and ERCP for bile drainage. Ultimately, advanced PBC with liver failure and portal hypertension requires liver transplantation.

2.2.4 Autoimmune Hepatitis (AIH)

Autoimmune chronic active hepatitis (CAH) has been observed in UC patients with and without PSC (Rabinovitz et al., 1992; Snook, Kelly et al., 1989). In addition to laboratory tests showing the presence of autoantibodies, such ANA and anti-smooth muscle muscle antibody (ASMA) and abnormal liver function tests, liver biopsy may be necessary to confirm the diagnosis (Alvarez et al., 1999). In patients with both UC and autoimmune hepatitis, up to 42% have abnormal cholangiographic findings indicating the coexistence or overlap of PSC (Perdigoto et al., 1992). UC patients with both AIH and PSC respond relatively poorly to immunosuppression and progress more rapidly to cirrhosis. Autoimmune CAH responds to steroids, but in the presence of PSC, dual therapy with steroids and azathioprine is indicated (Perdigoto, Carpenter et al., 1992; Rabinovitz, Demetris et al., 1992). Thus, in patients with UC complicated by autoimmune CAH, cholangiography is necessary to rule out PSC to dictate further therapy.

2.2.5 Other hepatic complications

Fatty liver or hepatic steatosis can be observed in UC patients and appears to correlate with disease severity or duration and may contribute to abnormal liver function tests (Riegler et al., 1998). The ultrasound findings of fatty liver show hepatomegaly and a dysechogenic pattern (De Fazio et al., 1992). Causes of fatty liver include malnutrition, protein loss, and steroid use. Patients are usually asymptomatic and treatment is geared towards treatment of the underlying UC and improving nutritional status (Navaneethan & Shen, 2010).

Hepatic amyloidosis is an extremely rare complication of UC (0.07% vs. 0.9% in CD) and control of gut inflammation can reduce amyloid deposition severity (Greenstein et al., 1992; Navaneethan & Shen, 2010; Wester et al., 2001). Because of the rarity and asymptomatic nature of this complication, the need for liver biopsy remains unclear and should be made on a case-by-case basis.

Hepatic and/or splenic abscesses are rare complications of IBD and even more rare in UC. They are diagnosed by ultrasound or CT scan showing non-enhancing hypodense lesions in the liver and/or spleen. Clinical suspicion of hepatosplenic abscesses should be considered in febrile patients with IBD whose presentations are inconsistent with IBD exacerbation. The treatments of hepatosplenic abscesses include drainage, broad-spectrum antibiotics, and treatment of underlying IBD with sulfasalazine and/or steroids. The pathogenesis of hepatosplenic abscess in UC is unclear at this time with possible mechanisms including infectious and immunologic etiologies (Navaneethan & Shen, 2010).

2.2.6 Portal vein thrombosis

Portal vein thrombosis is considered an EIM of UC and is thought to be secondary to coagulation abnormalities caused by chronic bowel inflammation. Ulceration of the mucosa barrier can increase the chance of gut microbial translocation and thus portal vein thrombosis (Navaneethan & Shen, 2010). Portal vein thrombosis has also been observed in UC patients who were status post proctocolectomy (Navaneethan & Shen, 2010).

2.2.7 Pancreatic complications

Patients with UC have increased chances of developing both acute and chronic pancreatitis (Keljo & Sugerman, 1997). Causes include idiopathic, gallstones, PSC, and medication side effects from drugs such as 5-ASA, mesalamine, corticosteroids, azathioprine, and 6-mercaptopurine. Medication induced pancreatitis does not lead to chronic pancreatitis and

treatment involves cessation of the insulting drug (Bank & Wright, 1984). On the other hand, the etiology of chronic pancreatitis is unknown. Chronic pancreatitis with UC is usually painless, but is associated with pancreatic duct strictures and severe pancreatic exocrine insufficiency (Pena et al., 2000).

Autoimmune pancreatitis (AIP) is a less common complication of UC compared to drug-induced or gallstone pancreatitis (Navaneethan & Shen, 2010). It affects elderly individuals and can present with obstructive jaundice. Steroids have become the standard treatment of AIP for obstructive jaundice, abdominal pain, and prevention of future episodes of pancreatitis (Finkelberg et al., 2006; Kamisawa et al., 2009). Failure to respond to steroids raises the possibility of pancreatic cancer and warrants further work up for malignancy.

2.3 Musculoskeletal complications

Musculoskeletal complications are quite common and affect approximately 25% of all IBD patients (Bourikas & Papadakis, 2009; Danese et al., 2005). The musculoskeletal involvement of UC patients can be divided into the following categories:

1. Arthritis: peripheral arthritis, axial arthritis including ankylosing spondylitis (AS) and sacroiliitis
2. Periarticular inflammation: enthesitis, tendonitis, dactylitis, clubbing, periostitis, myositis, fibromyalgia, and granulomatous lesions of the joint and bone
3. Metabolic bone disorders: osteoporosis, osteopenia, osteonecrosis
4. Localized myopathy: orbital myositis, gastrocnemius myalgia syndrome, polymyositis, dermatomyositis
5. Impaired growth: seen in children and adolescents

2.3.1 Arthritis

Peripheral Arthritis: Arthritis, located peripherally or axially, can precede, occur concurrently, or follow the diagnosis of UC (Bourikas & Papadakis, 2009). The type of articular involvement in UC is inflammatory and is associated with pain, heat, swelling, and decreased joint mobility. Similar to rheumatoid arthritis (RA), the pain and stiffness of arthritis in UC is worse in the morning and improves with physical activity. However, unlike RA arthritis, UC arthritis is typically seronegative, non-deforming, and non-erosive. The peripheral arthropathy seen with UC can be classified into two types: Type 1 and Type 2 (Atzeni et al., 2009; Bourikas & Papadakis, 2009; Brakenhoff et al., 2010; Jose & Heyman, 2008).

Type 1 is pauci-articular, asymmetrical in distribution, and typically affects less than 5 large joints, such as the knees, elbows, and ankles. The risk of developing peripheral arthritis is higher in UC patients and increases with colonic involvement (Bourikas & Papadakis, 2009; Jose & Heyman, 2008). The risk of developing type 1 peripheral arthritis is also increased with the presence of other EIMs, such as EN, PG, abscesses, stomatitis, and uveitis (Jose & Heyman, 2008). With the exception of small joints or type 2 polyarticular arthritis, the arthritis usually correlates with UC disease activity (Atzeni, Ardizzone et al., 2009). This type of arthritis is sometimes referred to as colitic arthritis, affects up to 20% of UC patients, and usually presents as an acute self-limiting episode that lasts less than 10 weeks with a median of 5 weeks (Bourikas & Papadakis, 2009; Das, 1999; Jose & Heyman, 2008). However, about 20% to 40% will experience recurrent episodes of arthritis.

Type 2 arthropathy is typically polyarticular, involving 5 or more joints including the small joints of the hands, and most commonly affects the MCP joints of the hands. This type of polyarticular arthritis with IBD is associated with uveitis, but not with other EIMs of IBD.

Unlike type 1 arthritis, symptoms of type 2 arthritis are independent of bowel disease activity and can persist for months to years with a median of 3 years (Bourikas & Papadakis, 2009; Jose & Heyman, 2008). Genetic factors implicated in the association between peripheral arthritis and UC include: HLA-B27, HLA-B35, HLA-DR, and HLA-B44 (Brakenhoff, Van Der Heijde et al., 2010).

Axial Arthritis: Axial arthritis, referred as type 3 arthritis, includes both AS and isolated sacroiliitis. This axial type of arthropathy occurs less frequently than peripheral arthritis, and as with type 2 arthropathy, does not parallel the underlying IBD in clinical course (Bourikas & Papadakis, 2009; Brakenhoff, Van Der Heijde et al., 2010; Jose & Heyman, 2008). In fact, studies have shown that axial arthropathy often precedes UC diagnosis by several years (Bourikas & Papadakis, 2009). In fact, studies have shown that AS occurs in approximately 5% to 10% of patients with IBD and patients are typically young and HLA-B27 positive [FIGURES 8 AND 9]. Presentation involves a severe onset of back pain with morning stiffness that is exacerbated by activity. Spondyloarthritis commonly coincides with periarticular involvement including synovitis, dactylitis, enthesitis, plantar fasciitis, and chest wall pain (Bourikas & Papadakis, 2009). Sacroiliitis seen with UC is often asymptomatic, but can manifest as pelvic pain that improves with movement and sacroiliac joint pain worsened with pelvic brim pressure [FIGURE 10] (Atzeni, Ardizzone et al., 2009).

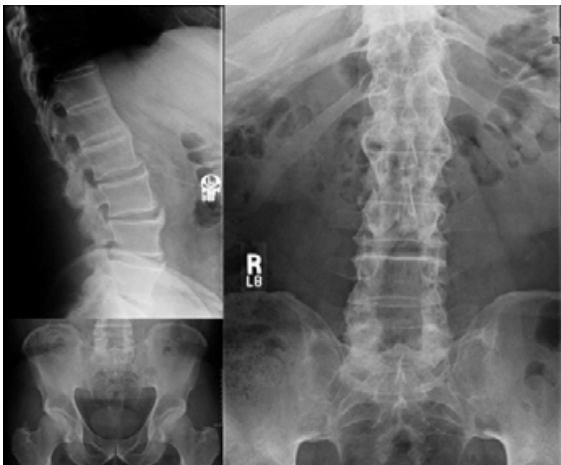


Fig. 8. X-Rays of a UC patient with AS

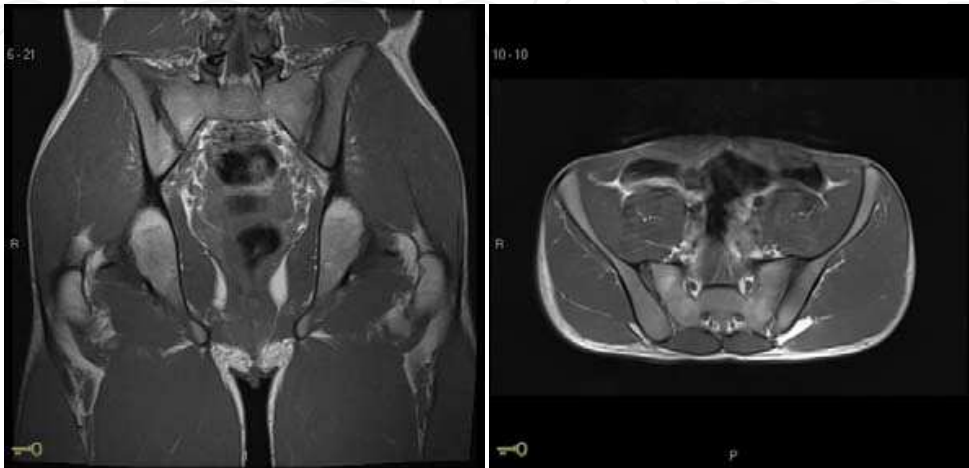


Fig. 9. MRI images (Sagittal, left and coronal, right) showing AS in a young patient with UC

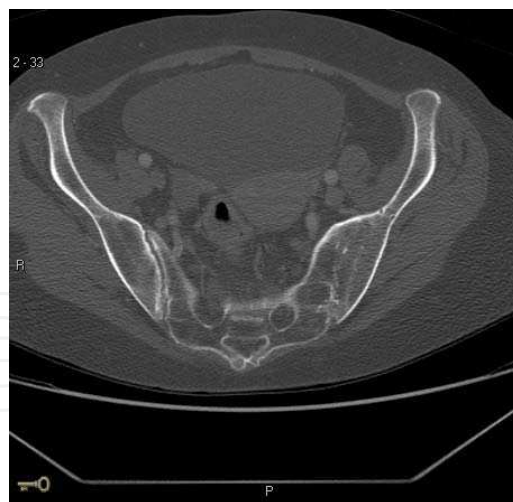

Fig. 10. MRI showing right sided SI and fused left sided joint space

Treatment: The treatment of UC-associated arthropathies is extrapolated from other forms of arthritis (Atzeni, Ardizzone et al., 2009). As with other types of UC EIMs, treatment of the underlying disorder with medical and/or surgical interventions can improve the peripheral arthritis seen with UC (Danese, Semeraro et al., 2005; Jose & Heyman, 2008). Symptomatic treatments include rest, physical therapy, and intra-articular steroid treatments. A short course of celecoxib (COX-2 inhibitor) for 2 weeks has been safely used to treat arthritis in UC (Sandborn et al., 2006). Patients failing to improve should be considered for second-line therapy, including sulfasalazine and immunomodulators (Danese, Semeraro et al., 2005). In patients with active colonic inflammation and peripheral arthritis, biologic agents such as infliximab should be considered (Atzeni, Ardizzone et al., 2009).

In contrast to peripheral arthritis which generally responds to treatment of the colitis, medical and surgical therapy of the underlying bowel disease does not affect the disease course of axial arthropathy. Traditionally, mainstay treatments of AS included intensive physical therapy plus disease-modifying drugs such as sulfasalazine and methotrexate (Atzeni, Ardizzone et al., 2009). However, recent studies have shown that TNF-alpha inhibitor agents such as infliximab are effective in treating AS, IBD, and IBD-associated peripheral and axial arthritis (Atzeni, Ardizzone et al., 2009; Bourikas & Papadakis, 2009; Danese, Semeraro et al., 2005).

2.3.2 Periarticular Inflammation

Periarticular inflammation including enthesitis, tendonitis, clubbing, dactylitis, periostitis, fibromyalgia, and granulomatous lesions of the joints and bones, have been described in UC patients in the presence and absence of arthritis (Bourikas & Papadakis, 2009; Salvarani et al., 2000). These types of periarticular involvement usually do not alter inflammatory markers, but can severely compromise quality of life.

2.3.3 Metabolic bone disorders

Bone disorders such as osteoporosis, osteopenia, and osteonecrosis are associated with UC and this relationship is intensified with concomitant steroid use (Jose & Heyman, 2008). Some studies have shown that in IBD patients, the prevalence rate of osteoporosis can range from 2% to 30% and as high as 40% to 50% for osteopenia (Danese, Semeraro et al., 2005). However, there is still controversy on the exact relationship between UC and osteoporosis.

While one study found approximately 25% of UC patients to have decreased bone mineral density (BMD), another group in Norway found that unlike CD patients, UC patients had relatively normal body compositions without significantly decreased body mass index (BMI) or BMD (Jahnsen et al., 1997; Jahnsen et al., 2003; Vestergaard, 2004).

The exact pathogenesis between UC and metabolic bone disorders is not entirely clear, but suggested causes include nutritional deficiency, malabsorption of calcium and vitamin D, steroid use, immobility, and elevated inflammatory cytokines (Danese, Semeraro et al., 2005). Consequently, calcium and vitamin D levels should be checked in UC patients taking steroids. Attempts to minimize steroid dosage and/or duration, substituting steroids with steroid-sparing immunomodulators, or supplementation with bisphosphonates or calcitonin can prevent bone loss and reduce morbidity in these patients (Jose & Heyman, 2008).

Osteonecrosis, also known as aseptic or avascular necrosis, is characterized by bone tissue death secondary to poor vascular supply. Believed to be the result of ischemia of the juxta-articular bone, osteonecrosis has been described in both children and adults with IBD with a prevalence of <1% of all IBD patients and up to 4% of patients taking steroids (Jose & Heyman, 2008; Madsen & Andersen, 1994). Osteonecrosis is a serious complication of UC that should be diagnosed early by magnetic resonance imaging and/or bone scan to prevent serious complications (Madsen & Andersen, 1994). Treatment includes medical management with calcium, vitamin D, bisphosphonates, hydrochlorothiazide, or anti-hypertensive to reduce bone edema. Surgical options include core-decompression biopsy, arthroplasty, or joint replacement (Jose & Heyman, 2008).

2.3.4 Localized myopathy

Muscle involvement is a rare EIM and UC patients are less affected than CD (Bourikas & Papadakis, 2009). The myopathy seen in UC patients can be a direct result of the underlying autoimmune disorder or a side effect of the IBD therapy. In most patients, diagnosis of IBD usually precedes the development of myopathy symptoms. Myopathy disorders that have been associated with UC include orbital myositis, gastrocnemius myalgia syndrome, polymyositis, and dermatomyositis (Bourikas & Papadakis, 2009). Orbital myositis in UC patients is rare and only a handful of cases have been reported (Macarez et al., 2005). It presents as acute orbital pain, diplopia, eyelid swelling, exophthalmos, and conjunctival injection. Diagnosis is made by CT or MRI that can show proptosis and extra-ocular muscle swelling. A case report documented successful results with a short course of systemic steroids and long-term mesalamine therapy (Macarez, Bazin et al., 2005). Gastrocnemius myalgia syndrome usually presents as calf tenderness and is less commonly reported in UC compared to CD. Polymyositis and dermatomyositis in UC patients usually present with proximal muscle weakness (Bourikas & Papadakis, 2009). Diagnostic work up should include CPK, ESR, muscle/skin biopsy, and EMG. Mainstay treatment of the various types of myositis should always include glucocorticoids. TNF-alpha blockers may be required for orbital myositis and azathioprine for polymyositis and dermatomyositis (Bourikas & Papadakis, 2009). A case report of an elderly woman with UC and polymyositis who was treated with corticosteroids and 5-ASA had marked improvement of her muscle weakness (Chugh et al., 1993).

2.3.5 Impaired growth

About 33% of patients with IBD develop symptoms during childhood and adolescence (Ballinger et al., 2001). Of this young population, approximately 28% of UC patients have

evidence of growth impairment and delay with onset of bowel symptoms (Berger et al., 1975; Stawarski et al., 2006). The underlying UC causes of this chronic under-nutrition include poor oral intake from fear of colitis exacerbation, malabsorption from inflammation, and hypoalbuminemia secondary to protein-losing enteropathies (Jose & Heyman, 2008). There is evidence that inflammatory cytokines such as IL-6 and TNF-alpha account for the chronic inflammation that impairs linear growth and thus development (Ballinger, Camacho-Hubner et al., 2001). Studies have also shown that high dose daily steroid therapy is associated with diminished type 1 collagen production, which is also important for linear growth. Interestingly, low dose and alternate-day steroid regimens have less dramatic impacts on growth velocity and should be considered as treatment regimens for UC (Berger, Gribetz et al., 1975). Height, weight, puberty staging, and bone age should be regularly checked in young UC patients to prevent poor development. Optimal management of these young patients involves a balance between selecting an appropriate regimen that adequately treats the UC while minimally compromising normal growth and development. Ideally, keeping the underlying bowel disease in remission, especially during puberty, can improve the chance of reaching full growth potential. Calorie supplementation and enteral nutrition should be utilized to meet individualized nutritional goals. (Ballinger, Camacho-Hubner et al., 2001). Surgical interventions eradicating medically refractory disease activity have had more success in reversing growth retardation than high dose steroids, assuming that there was not a significant preexisting delay (Berger, Gribetz et al., 1975).

2.4 Ocular complications

Ocular complications associated with UC were first described in 1925 in two patients with corneal inflammation and conjunctivitis (Crohn, 1925). A large study of 465 UC patients showed that 17 patients (3.6%) had ocular involvement. Of these 17 patients, 7 patients had episcleritis and 5 had iritis or anterior uveitis (Billson et al., 1967). Two patients had blepharo-keratitis and there were single cases of interstitial keratitis, choroiditis, and dacryocystitis reported in this study. Episcleritis, uveitis and conjunctivitis are the most frequent eye manifestations of IBD. Females are affected more frequently than males and eye manifestations were found to be well correlated with UC flares (Billson, De Dombal et al., 1967). Another study reported a higher incidence with 10 out of 78 UC patients (12.8%) having ocular complications (Ozdemir et al., 2000).

2.4.1 Episcleritis

The episclera is the connective tissue between the conjunctiva and sclera. Episcleritis is thus defined as an inflammation of the episclera and its adjacent tissues. The inflammation is usually segmental and bilateral in distribution and associated with eye discomfort, irritation, redness, and tearing [FIGURE 11]. However, there is usually no visual impairment or purulent discharge. Episcleritis responds well to topical steroids (Billson, De Dombal et al., 1967).

2.4.2 Uveitis

The uvea is the middle layer of the eye and is situated between the retina and sclera. It includes the iris, ciliary body, and the choroid of the eye. Uveitis refers to an inflammation of the uvea. Multiple studies and case reports have demonstrated that UC can be associated not only with anterior uveitis, but also posterior, peripheral, or even pan-uveitis (Ozdemir et al., 2000). Symptoms of uveitis include photophobia, blurred vision, pain, and conjunctival

injection. Anterior uveitis or iritis is distinguished from other causes of red eye by slit lamp examination and leukocytes seen in the anterior chamber is diagnostic of anterior uveitis. Posterior uveitis can be diagnosed by one of two ways: either by direct visualization of the active chorioretinal inflammation and/or by detecting leukocytes in the vitreous humor by slit lamp or indirect ophthalmoscope. Uveitis usually responds to topical steroid treatment. Severe cases of iritis should be treated with mydriatics to dilate pupils to prevent synechia, in which there is adhesion of the iris to the cornea or lens. It has been speculated that primary treatment of the UC with systemic steroids could account for the relatively low incidence of uveitis in patients with UC (Billson, De Dombal et al., 1967).

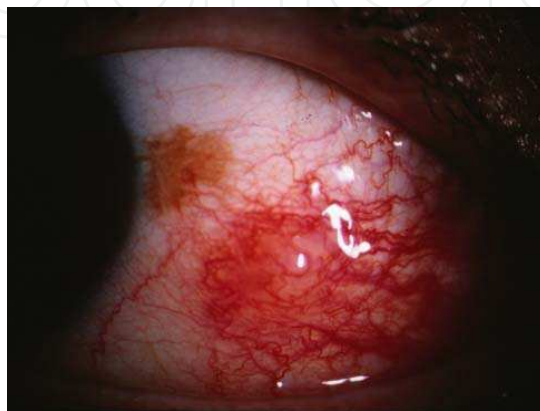

Fig. 11. UC Patient with episcleritis

2.4.3 Scleritis

UC has been associated with different types of anterior scleritis: diffuse, nodular, and posterior scleritis (Ozdemir et al., 2000). Symptoms of scleritis include deep eye pain with radiation to eyebrows, cheeks and temples, eye redness, tearing, photophobia and blurred vision. Severe cases can ultimately lead to blindness. Initial treatments include NSAIDs; oral steroids or immunosuppressants may be necessary for advanced disease. Necrotizing scleritis, the most severe form of scleritis, causes severe inflammation and pain in part of or the entire sclera. This serious disorder is associated with RA, but has also been reported in UC (Lyne & Pitkeathley, 1968). A case report documented a case of severe necrotizing scleritis in a patient with UC that was surgically treated with an amniotic membrane graft and successfully preserved the patient's vision (Lazzaro, 2010).

2.4.4 Optic neuritis

Optic neuritis is inflammation of optic nerve and studies have shown that optic neuritis can be the sole ocular manifestation of UC (Sedwick et al., 1984). Patients with UC who develop rapid and progressive reduction in vision should be suspected to have optic neuritis. Untreated optic neuritis can lead to permanent loss of vision and treatment of optic neuritis typically includes systemic steroid (Nakamura et al., 2005).

One of the key inflammatory mediators of UC includes the cytokine tumor necrosis-alpha (TNF- α). As such, anti-TNF- α therapies are often used to treat patients with UC and are generally well tolerated (Rutgeerts et al., 2005). However, there have been reports of the development of demyelinating disease such as optic neuritis in patients receiving anti-TNF- α therapy (Nash & Florin, 2005). A study of 15 patients who presented with optic neuritis following TNF- α antagonist therapy showed that 9 of these patients experienced full

recovery, 2 had partial resolution, and 4 patients continued to be symptomatic (Simsek et al., 2007). It is recommended that patients on anti-TNF- α therapy should be monitored for signs and symptoms of optic neuritis and if symptomatic, should have the medication discontinued.

2.4.5 Other ocular complications

Other ocular complications include marginal keratitis and corneal ulcers, cataracts, recurrent conjunctivitis, blepharitis, retinal vasculitis, retinal vein occlusion, and neuroretinitis (Billson, De Dombal et al., 1967).

In summary, routine eye examinations are recommended for UC patients. Early diagnosis and treatment of ocular involvement can prevent serious and potentially irreversible complications of UC.

2.5 Hematologic and vascular complications

Hematological complications that are associated with UC include (Gomollon & Gisbert, 2009; Imagawa, 1999; Wilson et al., 2004):

1. Anemia of various causes: iron deficiency anemia (IDA), anemia of chronic disease (ACD), folic acid or B12 deficiency, megaloblastic anemia, autoimmune hemolytic anemia, or anemia secondary to marrow-suppressing medications.
2. Granulocytopenia, thrombocytopenia
3. Idiopathic thrombocytopenic purpura
4. Neoplastic (rare): myelodysplastic syndrome, acute or chronic leukemia

In IBD, the prevalence of anemia ranges from 8.8% to 73.7% and the major types of anemia are IDA and ACD (Giannini & Martes, 2006).

2.5.1 Iron deficiency anemia

In addition to biochemical values (serum iron, total iron binding capacity, transferrin, ferritin), new indices of iron metabolism (for example soluble transferrin receptors or sTfR, sTfR-ferritin index, hepcidin, ferritin: transferrin receptor ratio, reticulocyte hemoglobin content or percentage of hypochromic red blood cells) may help with the assessment of IDA and ACD in IBD (Stein et al., 2010; Zhu et al., 2010). Traditionally, IDA is treated with oral iron supplementation. However in patients with UC, not only can oral iron cause more GI side effects, but it is also poorly absorbed in the gut secondary to mucosal inflammation and altered distribution. As a result, the strong oxidizing properties of the unabsorbed iron inside the gut lumen can exacerbate the UC (Zhu, Kaneshiro et al., 2010). Hence, parenteral iron therapy and erythropoietin have been advocated in the treatment of IDA in UC patients (Gomollon & Gisbert, 2009; Stein, Hartmann et al., 2010; Wilson, Reyes et al., 2004; Zhu, Kaneshiro et al., 2010).

2.5.2 Anemia of Chronic Disease

ACD, seen in patients with acute or chronic inflammation, is the second most common anemia in both the general and IBD population (Weiss & Goodnough, 2005). The pathogenesis of ACD is immune driven by cytokines and cells of the reticuloendothelial system. Erythropoiesis is decreased secondary to the chronic inflammation and corresponding anti-inflammatory treatments for IBD (Zhu, Kaneshiro et al., 2010). In UC, recombinant human erythropoietin is recommended for ACD and IDA if parenteral iron therapy is ineffective (Stein, Hartmann et al., 2010; Weiss & Goodnough, 2005; Zhu, Kaneshiro et al., 2010).

2.5.3 Autoimmune Hemolytic Anemia

The association of autoimmune hemolytic anemia (AIHA) with UC is rare, occurring in less than 1% of cases. However, AIHA should be suspected in patients with anemia, painless jaundice, and unconjugated hyperbilirubinemia (Gumaste et al., 1989; Valderrama Rojas et al., 2003). The diagnosis of AIHA includes a positive direct Coombs test that detects IgG or complement absorbed onto red blood cells. However, studies have shown that approximately 1.82% of UC patients without signs of hemolysis can have a positive direct Coombs test (Valderrama Rojas, Rodriguez Gorostiza et al., 2003). Systemic steroids are the first line of therapy, produce remission in 21% to 50% of cases, and should be continued for 3 weeks before being considered ineffective (Gumaste, Greenstein et al., 1989; Veloso et al., 1991). For cases unresponsive to steroids, immunosuppressive therapy with agents such as cyclophosphamide or azathioprine and surgical intervention including splenectomy should be considered. A case report describes a patient with UC and AIHA in which immunosuppression with steroids and azathioprine was not successful in achieving remission. Ultimately, splenectomy was performed and the patient went into remission allowing her immunosuppressants to be discontinued (Wodzinski & Lawrence, 1985). If the hemolysis is not responding to the aforementioned treatments, colectomy or total proctocolectomy are advisable and effective (Gumaste, Greenstein et al., 1989)(Sharma 2002). Thrombocytopenia with AIHA is known as Evan's syndrome. A case report describes an association of Evan's syndrome with UC that responded to immunosuppressive therapy (Ucci et al., 2003).

2.5.4 Other hematologic complications

Agranulocytosis and thrombocytopenia have been reported to be associated with UC. This can be secondary to medication side effects: for example, sulfasalazine has been shown to cause agranulocytosis and mesalamine has been showed to cause thrombocytopenia (Farrell et al., 1999; Roddie et al., 1995). Immune-mediated neutropenia and thrombocytopenia have also been reported in UC (Kim et al., 1995). Idiopathic thrombocytopenic purpura (ITP), documented by various case reports to occur in patients with UC, is autoimmune in nature and treatment is similar to that of AIHA with steroids, splenectomy, and if necessary, colectomy (Mizuta et al., 2003; Yoshida et al., 1996).

Various hematologic malignancies have been reported as UC complications and include: acute promyelocytic leukemia, acute myelogenous leukemia, chronic granulocytic leukemia, and myelodysplastic syndrome (Braverman & Bogoch, 1978; Fabry et al., 1980; Hebbar et al., 1997; Rosen & Teplitz, 1965). However, the pathogenesis of the association remains unclear (Fabry, Sachar et al., 1980; Hebbar, Kozlowski et al., 1997; Rosen & Teplitz, 1965; Suzuki et al., 1995).

2.5.5 Vascular complications

Venous thromboembolism (VTE) such as deep vein thrombosis (DVT) and pulmonary embolism (PE) are known complications of UC (Braverman & Bogoch, 1978). This is attributable to the hypercoagulable state associated with UC with patients often having active disease at time of VTE (Koutroubakis, 2005). Treatment is similar to that of patients without IBD. Arterial thrombosis is a rare complication of UC and sites of thrombosis involving radial, brachial and common carotid arterial thrombosis have been reported (Braverman & Bogoch, 1978; Mikroulis et al., 1999; Nogami et al., 2007). The pathogenesis of arterial thrombosis is related to increased fibrinogen levels, increased platelet counts, and decreased anti-thrombin III levels (Mikroulis, Antypas et al., 1999). Treatment with antithrombotic therapy can often worsen the UC and in patients who fail antithrombotic or

anticoagulation therapies, colectomy is often necessary (Mikroulis, Antypas et al., 1999; Nogami, Iiai et al., 2007).

UC has been reported to be associated with several vasculitides including: Takayasu's arteritis and giant cell arteritis (Jacob et al., 1990; Kawashima et al., 1999; Shibata et al., 2002). Takayasu's arteritis is a granulomatous arteritis involving the aorta and its branches. Involvement of the common carotid artery will show typical tenderness of carotid artery, an early but pathognomonic symptom of Takayasu's arteritis. MRI is helpful for the early diagnosis of Takayasu's arteritis (Kawashima, Koike et al., 1999). Giant cell arteritis is granulomatous arteritis involving medium and large-sized arteries. Giant cell arteritis, also known as temporal arteritis and cranial arteritis, usually presents with headache, blurred vision, and sometimes sensorineural deafness (Jacob, Ledingham et al., 1990). Biopsy of temporal artery is needed for definitive diagnosis of temporal arteritis. Both Takayasu's arteritis and Giant cell arteritis respond to steroids (Jacob, Ledingham et al., 1990; Kawashima, Koike et al., 1999; Shibata, Funayama et al., 2002). Early diagnosis is important as delayed treatment can lead to permanent loss of vision.

2.6 Renal and genitourinary tract complications

A significant number of UC patients can develop complications involving the kidney and genitourinary tract. These complications include urolithiasis, chronic renal disease, ureteral obstruction, fistulas, and renal cell carcinoma.

2.6.1 Urolithiasis

Kidney stones, usually composed of either calcium oxalate or uric acid, are more prevalent in UC patients than in the general population (Caudarella et al., 1993). UC patients, especially those who have undergone surgery, have been shown to have decreased urinary volume, pH, magnesium, and excretion of citrate, all of which are significant risk factors for renal stone formation. Dehydration from diarrhea during UC flares further increases one's chance of developing nephrolithiasis.

2.6.2 Chronic renal disease

A statistically significant increased risk for renal disease is found in UC but not in CD patients (Bernstein et al., 2005). Reported chronic renal diseases associated with UC include: glomerulonephritis, immunoglobulin A nephropathy, nephrotic syndrome, idiopathic interstitial nephritis, drug-induced nephritis by mesalamine, NSAID induced nephropathy, type AA renal amyloidosis, or secondary amyloidosis (Basili et al., 2002; Skhiri et al., 1998; rStokke et al., 1976; Tokuyama et al., 2010). Kidney biopsy is indicated in order to confirm the diagnosis.

Nephrotic syndrome as a complication of UC has been reported to be related to an underlying complement and immune disorder and usually responds favorably to steroid treatment. A case report documents rapid improvement in renal function after colectomy (Stokke, Teisberg et al., 1976). UC patients found to have micro- or macro-hematuria should receive a renal biopsy for possible immunoglobulin A nephropathy (Trimarchi et al., 2001). Many of these diagnoses can end in renal failure and may ultimately require hemodialysis.

2.6.3 Ureteral obstruction

Ureteral involvement has been reported to occur in 3-6% of IBD cases (Ruffolo et al., 2004).

Ureteral obstruction in UC can be caused by kidney stone or retroperitoneal inflammation and fibrosis. Intravenous pyelography (IVP) is used to diagnose non-calculous ureteral obstruction and is found in 14% of UC patients (Fleckenstein et al., 1977). These patients are initially asymptomatic, but chronic obstruction and lead to pyelonephritis, hydronephrosis, hypertension, and eventual loss of kidney function. Because occult ureteral stenosis without gastrointestinal symptoms may be present, the possibility of IBD should be raised in patients who present with isolated ureteral stenosis (Kruglik et al., 1977). Initial management focuses on medical treatment of UC, but nephrostomy tubes or ureteral stents are indicated to relieve any obstructions.

2.6.4 Renal Cell Carcinoma

Renal cell carcinoma (RCC), although relatively uncommon, has been documented to occur in UC patients. While the association is unclear, possible etiologies include genetic predisposition or immunosuppression from medications. Treatment usually requires surgical intervention including nephrectomy (Satsangi et al., 1996).

2.7 Neurological complications

Both central and peripheral neurological disorders have been reported to occur in patients with UC. These include strokes, cerebral sinus thrombosis, cerebral vasculitis, acute disseminated encephalomyelitis, multiple sclerosis, peripheral neuropathies, and many other disorders (Jose & Heyman, 2008). Neurological complications of UC can be differentiated into three major categories: cerebrovascular disease, cerebral vasculitis, and immune mediated neuropathy. (Pandian et al., 2004)

2.7.1 Cerebrovascular disease

Compared to venous thrombotic events such as DVT and pulmonary emboli, thrombotic events occurring in the CNS are relatively rare occurring in up to 7.5% of cases (Nudelman et al., 2010). Cerebral sinus thrombosis typically presents with headache, convulsions, hemiparesis, and/or other neurologic signs and diagnosis is made by MRI angiogram (Tsujikawa et al., 2000). Because untreated cerebral sinus thrombosis can result in fatal cerebral edema and herniation, rapid diagnosis and treatment aimed to reduce intracranial pressure with a combination of steroids, diuretics, anticoagulants, and antithrombotic therapy is essential (Nudelman, Rosen et al., 2010; Tsujikawa, Urabe et al., 2000).

Cerebral arterial thrombosis is also a rare complication of UC, but has been described in young patients without any other significant risk factors of cerebral vascular accidents such as hyperlipidemia, cardiac arrhythmia, or carotid artery disease (Katsanos & Tsianos, 2002). Unfortunately, due to the rarity of cases, there are no official guidelines on the treatment of strokes in patients with IBD. Case reports have documented that arterial thrombotic events in UC patients is often associated with severe pan-colonic disease and generally carries a poor prognosis (Novotny et al., 1992). Colectomy may be necessary in these patients.

2.7.2 Cerebral vasculitis

Cerebral vasculitis is another complication of UC and can manifest as seizures and severe headaches (Masaki et al., 1997; Nomoto et al., 2006). Diagnosis is typically made with MRI

digital subtraction angiogram that shows a “beaded” appearance with multiple areas of irregularities of the intracerebral arteries. Treatment is similar to that of systemic vasculitis and usually involves steroids and/or immunosuppressants (Nelson et al., 1986; Nomoto, Nagao et al., 2006).

2.7.3 Immune mediated neuropathy

An association between UC and multiple sclerosis (MS) has been found both within families and within individuals (Hoffmann & Kruis, 2004). MS affects UC more than CD patients and the prevalence of MS in IBD patients is about 3.7 times more than seen in the average (Kimura et al., 2000). There are clearly common factors between IBD and MS, but more research is necessary to establish specific relationships between the two disorders (Pandian, Pawar et al., 2004). Management of these patients including diagnosis and treatment is generally similar to patients without UC (Pandian, Pawar et al., 2004).

Other rare neurological complications of UC that have been reported include: acute disseminated encephalomyelitis, optic neuritis, sensorineural hearing loss, myelopathy, peripheral polyneuropathy, Guillain-Barre syndrome, and myasthenia gravis (Gondim et al., 2005; Kanra et al., 2002; Krystallis et al., 2010; Lossos et al., 1995; Scheid & Teich, 2007; Tan, 1974; Yesilova et al., 2006). Many of these complications are autoimmune in nature and respond to steroids and/or immunosuppressive therapy.

2.8 Pulmonary complications

A variety of pulmonary complications associated with UC have been well documented and reported in medical and scientific literature. Virtually any part of the respiratory system can be involved and the pulmonary complications can be classified into airway, parenchymal, vascular, thromboembolic, and pleural disease.

2.8.1 Airway disease

Almost any part of the airway ranging from the trachea to the bronchi and bronchioles, can be associated with UC with the most common complications involving the bronchi (Higenbottam et al., 1980). Bronchial involvement may present as a chronic persistent cough with mucopurulent production suggesting chronic bronchitis or bronchiectasis (Gibb et al., 1987). In general, these symptoms do not respond to antibiotics, but do respond to inhaled steroids (Higenbottam, Cochrane et al., 1980). Studies have shown that in UC patients, colonic and pulmonary flares often parallel each other, suggesting a common embryonic origin of the colonic and pulmonary epithelium (Higenbottam, Cochrane et al., 1980; Wilcox et al., 1987). Furthermore, the histopathology of sclerosing cholangitis, another EIM of UC, has been shown to be quite similar to that of the airway inflammation associated with UC (Janssen et al., 2006).

Tracheal involvement can present as cough, hoarseness, dyspnea or even stridor due to inflammation and stenosis in subglottic or upper tracheal area. Depending on the severity of the inflammation and degree of respiratory compromise, systemic steroids and sometimes endotracheal intubation may be indicated (Janssen, Bierig et al., 2006; Rickli et al., 1994).

Less frequently seen in UC patients is bronchiole and small airways inflammation manifested as constrictive bronchiolitis or bronchiolitis obliterans with organizing pneumonia (BOOP) (Ward et al., 1999). Constrictive bronchiolitis is defined as concentric fibrosis in the bronchiolar submucosal layer with continuous external circular scarring

(Epler, 2007). BOOP is an inflammatory disease involving the terminal bronchiole and alveoli (lung parenchyma), and has been reported to be associated with UC. Symptoms seen with small airway involvement include cough, sputum production, wheezing, dyspnea, fever, flu-like symptoms, and pleuritic chest pain. These symptoms can manifest acutely or in chronic fashion and systemic steroids are indicated in the treatment of small airway inflammation.

Diagnosis

1. Routine laboratory tests: Sputum culture can rule out a respiratory infection. Observing peripheral eosinophilia on complete blood count can help differentiate inflammation from infection. Chest X-ray may show diffuse narrowing of the trachea in tracheal stenosis, thickening of the bronchial wall in bronchiectasis, or ground glass opacities in BOOP (Epler, 2001; Gibb, Dhillon et al., 1987; Janssen, Bierig et al., 2006).
2. Pulmonary function tests: An obstructive pattern is usually seen in large airway inflammation while a restrictive pattern is usually seen in small airway or parenchymal inflammation. Patients with inflammation affecting various parts of the airway and parenchyma can have mixed patterns on pulmonary function tests (Gibb, Dhillon et al., 1987). In patients with upper airway obstruction, flow-volume loops will show flattening of the inspiratory and expiratory limbs (Janssen, Bierig et al., 2006). A low lung diffusing capacity for carbon monoxide (DLco) can help to diagnose small airway inflammation such as BOOP or parenchymal disease such as interstitial lung disease.
3. CT scan: CT scans, especially High Resolution CT (HRCT) scans are more sensitive than plain chest films in differentiating between the pulmonary complications of UC. Irregular narrowing of the trachea or main bronchi can be seen in large airway involvement, thickened bronchial walls and dilated airways with mucoid impaction can be seen with bronchial involvement, and bilateral consolidation and peripheral (pleural-based) ground glass opacities are observed in BOOP (Epler, 2001; Garg et al., 1993; Spira et al., 1998; Wilcox, Miller et al., 1987).
4. Bronchoscopy: Bronchial epithelial biopsy can help diagnose tracheal stenosis with extensive inflammation with granulation tissue, basal reserve cell hyperplasia, thickening of the basement membrane, and submucosal inflammation (Gibb, Dhillon et al., 1987; Janssen, Bierig et al., 2006).
5. Surgery: Open lung biopsy or video-assisted thoracoscopic (VATS) procedure with biopsy may be needed to establish a diagnosis of BOOP or interstitial lung disease (Epler, 2001).

2.8.2 Lung parenchymal disease

BOOP, a disorder with both airway and parenchymal involvement, has been discussed under the airway disease section. Interstitial lung disease as a pulmonary complication of UC is extremely rare and is usually steroid-responsive, but cases of mortality have been reported (Marten et al., 2005). In a case report, a patient with UC was described to present with dyspnea and fatigue, but unlike BOOP, cough or fever was absent. Physical examination revealed inspiratory crackles and chest x-ray revealed reticular densities in the mid- to lower lung field bilaterally. CT scan revealed honeycombing and ground glass opacification with traction bronchiectasis and bronchiolectasis in similar lung field. Pulmonary function test revealed restriction pattern with reduced DLco and the patient ultimately developed respiratory failure requiring mechanical ventilation and passed away

from acute right ventricular failure (Marten, Fend et al., 2005). Pulmonary infiltrates with eosinophilia (PIE syndrome) is a recognized pulmonary complication of UC and has been documented to occur in patients receiving and not receiving sulfasalazine/mesalamine therapy (Camus et al., 1993; Saltzman et al., 2001). Typical chest x-ray appearance of PIE is peripheral homogenous nonsegmental air-space infiltrate or a "reverse pulmonary edema" pattern (Saltzman, Rossoff et al., 2001). The patient presents with dry cough, wheezing, fever, night sweat, and malaise. Peripheral blood and bronchoalveolar lavage can demonstrate eosinophilia. Systemic steroid treatment causes prompt and sustained resolution of clinical and radiographic abnormalities (Saltzman, Rossoff et al., 2001). Necrobiotic nodules (sterile abscesses) are rare pulmonary complications of UC. Patients usually present with high fever and constitutional symptoms. The lesions show PMNs and fibrin with necrosis, a similar pattern seen in PG, a dermatologic complication of IBD (Camus, Piard et al., 1993; Warwick et al., 2009). Chest X-ray can show multiple cavitory and non-cavitory nodules. In 2 case reports, therapy with steroids with or without cyclophosphamide successfully produced remission without relapse (Camus, Piard et al., 1993).

2.8.3 Vascular disease

Pulmonary vasculitis is a rare complication of UC (Black et al., 2007; Forrest & Shearman, 1975; Hilling et al., 1994; Isenberg et al., 1968). Patients can present with fever, dyspnea, or cough with blood-tinged sputum (Forrest & Shearman, 1975; Hilling, Robertson et al., 1994). Other vascular diseases associated with UC include Wegener granulomatosis, Churg-Strauss syndrome, and microscopic polyangiitis (Black, Mendoza et al., 2007). Nodular lung lesions can be seen in pulmonary vasculitis and Wegener's granulomatosis and are usually responsive to systemic steroids (Black, Mendoza et al., 2007; Forrest & Shearman, 1975; Hilling, Robertson et al., 1994; Isenberg, Goldstein et al., 1968; Stebbing et al., 1999).

2.8.4 Vascular thromboembolic disease

The incidence of VTE is about 3 to 4 times higher for patients with IBD in comparison with controlled age-matched groups (Bernstein et al., 2001a; Miehsler et al., 2004; Stebbing, Askin et al., 1999). The age-adjusted incidence ratios of UC compared to age-matched population was 2.8 for DVT and 3.6 for pulmonary embolism (PE) (Bernstein, Blanchard et al., 2001). IBD patients have increased risk factors for thromboembolism secondary to the underlying disease process or its associated complications including dehydration, inactivity, hospitalization, surgery, and central venous catheterization. However, up to 1/3 of VTE events occur in patients while the underlying disease process is quiescent, suggesting that there are additional risk factors unrelated to disease activity or accompanying therapies (Stebbing, Askin et al., 1999; Tsiolakidou & Koutroubakis, 2008). The following genetic factors have been suggested to increase the incidence of VTE in IBD patients: factor V Leiden, factor II (prothrombin, G20210A), methylenetetrahydrofolate reductase gene mutation (MTHFR, 6777T), plasminogen activator inhibitor type 1 (PAI-1) gene mutation and factor XIII (val34leu) (Tsiolakidou & Koutroubakis, 2008). The symptoms, diagnosis and treatment of DVT and PE in UC are similar to patients without IBD.

2.8.5 Pleural disease

Pleural and pericardial complications of IBD in the form of serositis, pleural effusions, pleuritis, pericarditis, pleuro-pericarditis or myo-pericarditis are uncommon (Tsiolakidou &

Koutroubakis, 2008). When they do occur, they are usually diagnosed in young male patients with UC (Camus, Piard et al., 1993; Stebbing, Askin et al., 1999). The pleural effusion is almost always unilateral and exudative in nature. The symptoms and diagnosis of serositis are similar to other patients without UC and the treatment of serositis includes steroid and NSAIDs such as aspirin and Indocin (Stebbing, Askin et al., 1999).

2.9 Cardiac complications

In general, cardiovascular involvement with UC is uncommon, but complications such as intracavitary thrombosis, endocarditis, myocarditis, pericarditis, coronary artery disease, arrhythmias, and heart failure have been described in case reports (Katsanos & Tsianos, 2002).

2.9.1 Thrombosis

Intracavitary thrombosis, diagnosed by echocardiogram, has been reported to occur in the right atrium and left ventricle of UC patients (Saleh, 2010; Sasvary et al., 1996). Early diagnosis and treatment is essential as RA thrombus can lead to PE and LV thrombus can lead to systemic embolism.

2.9.2 Endocarditis

In UC patients, endocarditis can occur as a result of bacteremia, prolonged total parenteral nutrition (TPN) usage, or immunosuppression (Katsanos & Tsianos, 2002). Responsible organisms include streptococcus bovis, enterococcus faecium, and candida albicans (Christakis et al., 2007; Moshkowitz et al., 1992). Other complications that have been reported of endocarditis in UC patients include cerebral infarction and mitral valve leaflet aneurysm for which surgical intervention is indicated (Katsanos & Tsianos, 2002; Tomomasa et al., 1993).

2.9.3 Myocardial Involvement

Although relatively rare, myocardial involvement in UC patients compared with the general population has an incidence ratio of 2.6 (Sorensen & Fonager, 1997). A majority of cases in UC patients with myocardial involvement is complicated by pericarditis or pleural effusion. Prolonged corticosteroid use has been implicated in the cause of hypertrophic cardiomyopathy and mesalamine has been reported to cause myocarditis and perimyocarditis (Katsanos & Tsianos, 2002).

Case reports of acute myocardial infarction have been documented to occur during flares (Efremidis et al., 1999). The pathogenesis behind this ischemia is presumed to be reversible vasoconstriction of varying severity decreasing blood flow to myocardial tissue (Katsanos & Tsianos, 2002).

2.9.4 Pericarditis

The most commonly reported cardiac complication of UC is pericarditis which can be caused by drugs (5-aminosalicylic acid, mesalamine, azathioprine), pericardio-colonic fistulas, or idiopathic mechanisms (Katsanos & Tsianos, 2002). Both acute and chronic pericarditis with and without cardiac tamponade have been reported (Cappell & Turkieh, 2008; Dubowitz & Gorard, 2001). Drug induced pericarditis typically resolves after omission of the offending drug and treatment with NSAIDs is effective. Cardiac tamponade is a rare,

but life threatening complication of UC that can be diagnosed by echocardiogram or cardiac catheterization. Treatment includes emergent pericardiocentesis and pericardiectomy is indicated for recurrent pericardial effusion and chronic constrictive pericarditis (Cappell & Turkieh, 2008; Rezaie et al., 2010).

2.9.5 Valvular Involvement

Valvular involvement in UC is relatively common and can manifest as endocardium and aortic root involvement. Aortic and mitral valve involvement may require surgical replacement, but generally carries with good outcomes and prognosis (Katsanos & Tsianos, 2002).

2.9.6 Arrhythmias

Various types of cardiac arrhythmia have been reported to occur in UC, including Wenckebach, complete heart block, atrial fibrillation, supraventricular tachycardia, ventricular tachyarrhythmia, and mesalamine related sinus bradycardia (Katsanos & Tsianos, 2002). A permanent pacemaker is indicated for complete heart block (Maeder, 1996). Hypomagnesemia is frequently seen in UC due to ongoing fecal losses and this can lead to ventricular tachycardia. Treatment with magnesium infusion is effective (Levine et al., 1982). Interestingly, in patients with no prior cardiac history or electrolyte balance, QT intervals were found to be significantly higher in UC than CD, suggesting an increased risk of dangerous arrhythmias (Curione et al., 2010).

2.9.7 Heart failure

Heart failure in UC can be acute (acute myocardial infarction, myocarditis, cardiac tamponade, valvular deterioration) or chronic (myocardium or valvular involvement, heart muscle atrophy with TPN and prolonged steroid use) (Katsanos & Tsianos, 2002). Aortic valve insufficiency can cause heart failure and cardiogenic shock (Lidon & Ariza, 1993). Sudden cardiac arrest in UC patients can be secondary to acute myocardial infarction, cardiogenic shock, or ventricular arrhythmias (Katsanos & Tsianos, 2002).

3. Conclusion

UC is a systemic disease, since its clinical manifestations can affect not only the bowel, but can also involve almost any organ including the skin, eyes, liver, musculoskeletal cardiovascular, hematologic, and renal systems (Table 1). These EIM can influence both morbidity and mortality. Most of the patients with IBD associated EIMs have extensive colitis and family history of the disease. With the exception of PSC, AS, PG, and type 2 arthritis, extraintestinal complications tend to follow the clinical course of IBD. Awareness and understanding of the disease manifestations extrinsic to the gastrointestinal tract are essential in the management of IBD patients.

4. Acknowledgment

The authors thank Cindy Ting for critical reading of this manuscript. Dr. Jamil Laith (Cedars-Sinai Medical Center) for providing Figure 7. Drs. Dmitry Karayev and Thomas J. Learch for providing Figures 8-10. Gary Holland and Yen Tran (Jules Stein Eye Institute, UCLA) for providing Figure 11.

Common Manifestations					
Organ System	Features	CD or UC	IBD Activity Correlation		
Dermatologic	Erythema nodosum	Painful, raised subcutaneous lesions on extensor surfaces	Both	Yes	Conse rest, N Treatr
	Pyoderma gangrenosum	Early: noninfectious pustules and nodules Late: Painful ulcers that can be shallow or deep	Both	No	Cortic Cyclo Biolog Hyper Surge Glucoc
	Aphthous stomatitis	Small, round, painful ulcers in oral mucosa	Both	Yes	Immu Treatr Glucoc
	Pyostomatitis vegetans	Hyperplastic folds of oral mucosa with small abscesses and erosions	Both, but especially UC	Yes, occurs prior to flares	immu succes Colec remis
Hepatopancreatobiliary					
	Primary Sclerosing Cholangitis	Progressive inflammatory destruction of bile ducts Chronic intermittent obstructive jaundice Abdominal pain, pruritus, fatigue, fever, weight loss	Both, but more common in UC	No	Ursod Endos stent p Liver
	Primary Biliary Cirrhosis	Progressive cholestatic liver disease Pruritus, jaundice, skin pigmentation, fatigue, abominal pain	Both	Chronic disease progression	Chole Ursod ERCP

Common Manifestations					
Organ System	Features	CD or UC	IBD Activity Correlation		
Autoimmune Hepatitis	Acute/chronic hepatitis or cirrhosis Fever, right upper quadrant pain, jaundice	Both	No		Glucose Azathioprine Liver
Pancreatitis	Abdominal pain, nausea/vomiting Acute and chronic: idiopathic, gallstones, PSC, medication induced Autoimmune: obstructive jaundice	Both	Controversial		Treatment Autoimmune
Musculoskeletal					
Basic Features: Clinical or Histologic					
Peripheral arthritis	Pain, heat, swelling, decreased mobility in affected joint. Non-deforming, non-erosive Worse in AM, improves with activity Type 1: acute, pauci-articular (<5 joints), asymmetrical, self-limiting Type 2: poly-articular (≥ 5 joints), migratory arthritis, chronic with relapsing/remitting course	Both, more common in CD	Type 1: Yes Type 2: No		Type 1 Type 2 immunosuppressants Both: symptomatic therapy
Axial Arthritis (Sacroiliitis and Ankylosing Spondylitis)	Back pain Back stiffness in morning or after rest	Both	No		Intensification Glucose methotrexate
Osteoporosis	Bone pain Increased fracture risk	Both, more severe in CD than UC	Indirectly related to nutrition, absorption, and treatment		Symptomatic Medication bisphosphonates Surgery
Polymyositis/Dermatomyositis	Muscle pain/weakness Elevated serum CPK	Both	No		Glucose 5-ASA

Common Manifestations					
Organ System		Features	CD or UC	IBD Activity Correlation	
Ocular	Orbital Myositis	Sudden orbital pain Periorbital/eyelid edema Diplopia Exophthalmos Conjunctival injection	Rare in both	No	Glucocorticoids
	Gastrocnemius Myalgia Syndrome	Calf tenderness	Both, more common in CD	No	Glucocorticoids
	Episcleritis	Acute onset of injection, irritation of eye Vision typically not affected	Both	Yes	Topical steroids Treatments
	Uveitis	Photophobia, blurred vision, pain, conjunctival injection	Both	Unpredictable, but can parallel luminal IBD activity	Topical steroids Mydriatics Infliximab
	Scleritis	Deep eye pain with radiation to eyebrows, cheeks, temples Eye redness, tearing, photophobia, blurred vision Blindness	Both	May precede or follow IBD diagnosis	Oral steroids NSAIDs Immunosuppressants Surgery

Less Common Manifestations

Organ System	Features	CD or UC	IBD Activity Correlation	Therapy
Hematologic				
Iron deficiency anemia	UC: more often secondary to blood loss CD: more often secondary to poor absorption	Both, more common in UC	Yes	Iron (parenteral if on therapy) Erythropoietin
Anemia of chronic disease	Secondary to inflammatory cytokines and/or low erythropoietin	Both, more common in CD	Yes	Erythropoietin
Megaloblastic anemia	From folic acid or B12 deficiency	Both, more common in CD (ileal disease/resection)	Yes	Intranasal B12 Folic Acid
Autoimmune hemolytic anemia (AIHA)	Anemia, painless jaundice, unconjugated hyperbilirubinemia	Both, more common in UC	Controversial	Steroids Splenectomy Immunosuppressants Collective
Idiopathic Thrombocytopenic Purpura (ITP)	Petechiae, purpura, epistaxis	Both, more common in UC	No	Steroids Immunosuppressants Splenectomy Collective
Evan's Syndrome	ITP + AIHA Autoantibodies to platelets and RBCs	Both, more common in UC	No	Treatment of both
Vascular				
Venous Thromboembolism	Deep vein thrombosis Pulmonary embolism	Both	Yes	Similar to primary for pathogenesis

Renal

Organ System	Features	CD or UC	IBD Activity Correlation	Therapeutic Approach
Renal	Arterial Thrombosis	Both	Yes	Antithrombotic therapy Collective management
	Urolithiasis	Both	No	Narcotic analgesics Lithotripsy Surgery
	Chronic Renal Disease	UC	Variable	Hemodialysis renal transplant
Neurological	Cerebrovascular Disease (Cerebral sinus/arterial thrombosis)	Both	No	Sinus stenting reduction of hypercoagulability anticoagulation Arterial revascularization guidelines
	Cerebral Vasculitis	Both	unclear	Steroids Immunosuppressants Anticoagulation
	Immune Mediated Neuropathy (Multiple Sclerosis)	Both	unclear	Steroids Immunosuppressants

Less Common Manifestations

Organ System	Features	CD or UC	IBD Activity Correlation	Therapy
Pulmonary				
Upper Airway Disease (Epiglottitis, Laryngotracheitis, Subglottic, or Tracheal stenosis)	Cough, hoarseness, dysphonia, dyspnea, stridor	Both	No	Inhaled Steroids Laser obstruction
Large Airway Disease (Chronic bronchitis, Bronchiectasis)	Cough, mucopurulent sputum production	Both	No	Inhaled Steroids Low dose
Small Airway Disease (Constrictive bronchiolitis)	Cough, sputum, dyspnea, wheezing, fever	Both	No	Inhaled Steroids Low dose
	Concentric fibrosis in bronchiolar submucosal layers with continuous external circular scarring inflammation in terminal bronchiole			
Small Airway and Lung Parenchymal Disease (BOOP)	Dry cough, dyspnea, fever, wheezing, pleuritic chest pain, flu-like symptoms	Both, more common in UC	No	High dose Steroids
Interstitial Lung Disease	Dyspnea, fatigue	Both	No	Oral steroids immunosuppressants
Pulmonary infiltrates with eosinophilia (PIE)	Dry cough, wheezing, fever, chest tightness, night sweats, malaise Eosinophilia in blood and bronchoalveolar lavage	Both	No	Oral steroids
Lung necrobiotic nodules (Sterile abscesses)	High fever, constitutional symptoms PMNs and fibrin with necrosis, absence of giant cells, vasculitis, or capillaritis	Both, more common in UC	No	Oral steroids cyclophosphamide

Less Common Manifestations

Organ System	Features	CD or UC	IBD Activity Correlation	Therapy
Pulmonary Vasculitis	Fever, dyspnea, cough, blood-tinged sputum Nodular density on lung biopsy	Both	No	Oral steroids
Pleural Effusion/Pleuritis	Dyspnea, pleuritic chest pain Unilateral and exudative effusion	Both	No	Steroids NSAIDs Therapy
Cardiac				
Intracavitary Thrombosis	RA Thrombosis: pulmonary embolism LV Thrombosis: cerebrovascular event	Both	No	Anticoagulants
Infectious endocarditis	Septicemia, related to TPN catheters and immunosuppressive therapy	Both, more common in CD	No	Antibiotics Valvular surgery
Myocarditis (idiopathic, drug induced, selenium deficiency)	Asymptomatic Chest pain, dyspnea	Both, more common in UC	No	Withhold NSAIDs Treat with Selenium
Myocardial Infarction	Angina, chest pain, diaphoresis Usual pathophysiologic mechanisms and risk factors Ischemia secondary to reversible vasoconstriction	Both	Yes	Steroids Treat with NSAIDs Treat with aspirin
Pericarditis	Pleuritic chest pain, fever, dyspnea, cough	Both	No	Omission of NSAIDs Pericardial tamponade Pericardial biopsy

Less Common Manifestations					
Table 1. Extraintestinal Manifestations of IBD	Organ System	Features	CD or UC	IBD Activity Correlation	Tr
	Valvular Involvement (from endocarditis or aortitis)	Aortic regurgitation, mitral regurgitation, tricuspid regurgitation, mitral valve aneurysm	Both	No	Tr Va ca
	Cardiac Arrhythmia	Various types including Wenckebach, complete heart block, atrial fibrillation, SVT, etc.	Both	No	Tr M Pe he
	Heart Failure	Acute: AMI, myocarditis, tamponade, valvular deterioration Chronic: myocardium or valvular involvement, myocardial atrophy due to prolonged TPN or steroid use	Both	No	Tr
	Cardiac Related Sudden Death	Sudden AMI, cardiogenic shock, cardiac tamponade, or arrhythmia	Both	No	Tr

5. References

- Alabraba, E., P. Nightingale, et al. (2009). A re-evaluation of the risk factors for the recurrence of primary sclerosing cholangitis in liver allografts. *Liver Transpl* 15(3): 330-340.
- Alkhoury, N., V. Hupertz, et al. (2009). Adalimumab treatment for peristomal pyoderma gangrenosum associated with Crohn's disease. *Inflamm Bowel Dis* 15(6): 803-806.
- Alvarez, F., P. A. Berg, et al. (1999). International Autoimmune Hepatitis Group Report: review of criteria for diagnosis of autoimmune hepatitis. *J Hepatol* 31(5): 929-938.
- Angulo, P., D. H. Pearce, et al. (2000). Magnetic resonance cholangiography in patients with biliary disease: its role in primary sclerosing cholangitis. *J Hepatol* 33(4): 520-527.
- Areias, E.&L. Garcia e Silva (1987). [Cutaneous manifestations of ulcerative colitis]. *Med Cutan Ibero Lat Am* 15(3): 185-197.
- Atzeni, F., S. Ardizzone, et al. (2009). Combined therapeutic approach: inflammatory bowel diseases and peripheral or axial arthritis. *World J Gastroenterol* 15(20): 2469-2471.
- Ballinger, A. B., C. Camacho-Hubner, et al. (2001). Growth failure and intestinal inflammation. *QJM* 94(3): 121-125.
- Bank, L.&J. P. Wright (1984). 6-Mercaptopurine-related pancreatitis in 2 patients with inflammatory bowel disease. *Dig Dis Sci* 29(4): 357-359.
- Basili, E., M. Cazo, et al. (2002). [Secondary amyloidosis complicating ulcerative colitis]. *Gastroenterol Clin Biol* 26(5): 529-531.
- Basu, M. K.&P. Asquith (1980). Oral manifestations of inflammatory bowel disease. *Clin Gastroenterol* 9(2): 307-321.
- Berger, M., D. Gribetz, et al. (1975). Growth retardation in children with ulcerative colitis: the effect of medical and surgical therapy. *Pediatrics* 55(4): 459-467.
- Bergquist, A., S. M. Montgomery, et al. (2008). Increased risk of primary sclerosing cholangitis and ulcerative colitis in first-degree relatives of patients with primary sclerosing cholangitis. *Clin Gastroenterol Hepatol* 6(8): 939-943.
- Bernstein, C. N., J. F. Blanchard, et al. (2001a). The incidence of deep venous thrombosis and pulmonary embolism among patients with inflammatory bowel disease: a population-based cohort study. *Thromb Haemost* 85(3): 430-434.
- Bernstein, C. N., J. F. Blanchard, et al. (2001b). The prevalence of extraintestinal diseases in inflammatory bowel disease: a population-based study. *Am J Gastroenterol* 96(4): 1116-1122.
- Bernstein, C. N., A. Wajda, et al. (2005). The clustering of other chronic inflammatory diseases in inflammatory bowel disease: a population-based study. *Gastroenterology* 129(3): 827-836.
- Berstad, A. E., L. Aabakken, et al. (2006). Diagnostic accuracy of magnetic resonance and endoscopic retrograde cholangiography in primary sclerosing cholangitis. *Clin Gastroenterol Hepatol* 4(4): 514-520.
- Billson, F. A., F. T. De Dombal, et al. (1967). Ocular complications of ulcerative colitis. *Gut* 8(2): 102-106.
- Bjornsson, E., R. Olsson, et al. (2008). The natural history of small-duct primary sclerosing cholangitis. *Gastroenterology* 134(4): 975-980.
- Black, H., M. Mendoza, et al. (2007). Thoracic manifestations of inflammatory bowel disease. *Chest* 131(2): 524-532.
- Blitz, N. M.&D. Rudikoff (2001). Pyoderma gangrenosum. *Mt Sinai J Med* 68(4-5): 287-297.
- Bourikas, L. A.&K. A. Papadakis (2009). Musculoskeletal manifestations of inflammatory bowel disease. *Inflamm Bowel Dis* 15(12): 1915-1924.

- Brakenhoff, L. K., D. M. van der Heijde, et al. (2010). The joint-gut axis in inflammatory bowel diseases. *J Crohns Colitis* 4(3): 257-268.
- Braverman, D. & A. Bogoch (1978). Arterial thrombosis in ulcerative colitis. *Am J Dig Dis* 23(12): 1148-1150.
- Brooklyn, T. N., M. G. Dunnill, et al. (2006). Infliximab for the treatment of pyoderma gangrenosum: a randomised, double blind, placebo controlled trial. *Gut* 55(4): 505-509.
- Broome, U., R. Lofberg, et al. (1995). Primary sclerosing cholangitis and ulcerative colitis: evidence for increased neoplastic potential. *Hepatology* 22(5): 1404-1408.
- Burak, K. W., P. Angulo, et al. (2003). Is there a role for liver biopsy in primary sclerosing cholangitis? *Am J Gastroenterol* 98(5): 1155-1158.
- Burrall, B. (1999). Sweet's syndrome (acute febrile neutrophilic dermatosis). *Dermatol Online J* 5(1): 8.
- Callen, J. P. (1998). Pyoderma gangrenosum. *Lancet* 351(9102): 581-585.
- Callen, J. P. & J. M. Jackson (2007). Pyoderma gangrenosum: an update. *Rheum Dis Clin North Am* 33(4): 787-802, vi.
- Calobrisi, S. D., D. F. Mutasim, et al. (1995). Pyostomatitis vegetans associated with ulcerative colitis. Temporary clearance with fluocinonide gel and complete remission after colectomy. *Oral Surg Oral Med Oral Pathol Oral Radiol Endod* 79(4): 452-454.
- Campsen, J., M. A. Zimmerman, et al. (2008). Clinically recurrent primary sclerosing cholangitis following liver transplantation: a time course. *Liver Transpl* 14(2): 181-185.
- Camus, P., F. Piard, et al. (1993). The lung in inflammatory bowel disease. *Medicine (Baltimore)* 72(3): 151-183.
- Cappell, M. S. & A. Turkieh (2008). Chronic pericarditis and pericardial tamponade associated with ulcerative colitis. *Dig Dis Sci* 53(1): 149-154.
- Caudarella, R., E. Rizzoli, et al. (1993). Renal stone formation in patients with inflammatory bowel disease. *Scanning Microsc* 7(1): 371-379; discussion 379-380.
- Chapman, R., J. Fevery, et al. (2010). Diagnosis and management of primary sclerosing cholangitis. *Hepatology* 51(2): 660-678.
- Charatcharoenwitthaya, P., F. B. Enders, et al. (2008). Utility of serum tumor markers, imaging, and biliary cytology for detecting cholangiocarcinoma in primary sclerosing cholangitis. *Hepatology* 48(4): 1106-1117.
- Charatcharoenwitthaya, P. & K. D. Lindor (2006). Primary sclerosing cholangitis: diagnosis and management. *Curr Gastroenterol Rep* 8(1): 75-82.
- Christakis, G. B., S. P. Perlorentzou, et al. (2007). Bacteremia caused by *Pantoea agglomerans* and *Enterococcus faecalis* in a patient with colon cancer. *J BUON* 12(2): 287-290.
- Chugh, S., J. B. Dilawari, et al. (1993). Polymyositis associated with ulcerative colitis. *Gut* 34(4): 567-569.
- Cohen, P. R. (2009). Neutrophilic dermatoses: a review of current treatment options. *Am J Clin Dermatol* 10(5): 301-312.
- Cohen, P. R. & R. Kurzrock (2002). Sweet's syndrome: a review of current treatment options. *Am J Clin Dermatol* 3(2): 117-131.
- Cohen, P. R., M. Talpaz, et al. (1988). Malignancy-associated Sweet's syndrome: review of the world literature. *J Clin Oncol* 6(12): 1887-1897.
- Curione, M., A. Aratari, et al. (2010). A study on QT interval in patients affected with inflammatory bowel disease without cardiac involvement. *Intern Emerg Med* 5(4): 307-310.

- Curley, R. K., A. W. Macfarlane, et al. (1985). Pyoderma gangrenosum treated with cyclosporin A. *Br J Dermatol* 113(5): 601-604.
- Danese, S., S. Semeraro, et al. (2005). Extraintestinal manifestations in inflammatory bowel disease. *World J Gastroenterol* 11(46): 7227-7236.
- Darvay, A. (1996). Sweet's syndrome preceding inflammatory bowel disease. *Clin Exp Dermatol* 21(2): 175.
- Das, K. M. (1999). Relationship of extraintestinal involvements in inflammatory bowel disease: new insights into autoimmune pathogenesis. *Dig Dis Sci* 44(1): 1-13.
- de Fazio, C., G. Torgano, et al. (1992). Detection of liver involvement in inflammatory bowel disease by abdominal ultrasound scan. *Int J Clin Lab Res* 21(4): 314-317.
- Dorudi, S., R. W. Chapman, et al. (1991). Carcinoma of the gallbladder in ulcerative colitis and primary sclerosing cholangitis. Report of two cases. *Dis Colon Rectum* 34(9): 827-828.
- Dubowitz, M. & D. A. Gorard (2001). Cardiomyopathy and pericardial tamponade in ulcerative colitis. *Eur J Gastroenterol Hepatol* 13(10): 1255-1258.
- Duerr, R. H., S. R. Targan, et al. (1991). Anti-neutrophil cytoplasmic antibodies in ulcerative colitis. Comparison with other colitides/diarrheal illnesses. *Gastroenterology* 100(6): 1590-1596.
- Efremidis, M., E. Prappa, et al. (1999). Acute myocardial infarction in a young patient during an exacerbation of ulcerative colitis. *Int J Cardiol* 70(2): 211-212.
- Epler, G. R. (2001). Bronchiolitis obliterans organizing pneumonia. *Arch Intern Med* 161(2): 158-164.
- Epler, G. R. (2007). Constrictive bronchiolitis obliterans: the fibrotic airway disorder. *Expert Rev Respir Med* 1(1): 139-147.
- Evans, P. E. & D. S. Pardi (2007). Extraintestinal manifestations of inflammatory bowel disease: focus on the musculoskeletal, dermatologic, and ocular manifestations. *MedGenMed* 9(1): 55.
- Fabry, T. L., D. B. Sachar, et al. (1980). Acute myelogenous leukemia in patients with ulcerative colitis. *J Clin Gastroenterol* 2(3): 225-227.
- Farhi, D. & D. Wallach (2008). The neutrophilic dermatoses. *Dermatol Nurs* 20(4): 274-276, 279-282.
- Farrant, J. M., K. M. Hayllar, et al. (1991). Natural history and prognostic variables in primary sclerosing cholangitis. *Gastroenterology* 100(6): 1710-1717.
- Farrell, R. J., M. A. Peppercorn, et al. (1999). Mesalamine-associated thrombocytopenia. *Am J Gastroenterol* 94(8): 2304-2306.
- Finkelberg, D. L., D. Sahani, et al. (2006). Autoimmune pancreatitis. *N Engl J Med* 355(25): 2670-2676.
- Fleckenstein, P., L. Knudsen, et al. (1977). Obstructive uropathy in chronic inflammatory bowel disease. *Scand J Gastroenterol* 12(5): 519-523.
- Florin, T. H., N. Pandeya, et al. (2004). Epidemiology of appendicectomy in primary sclerosing cholangitis and ulcerative colitis: its influence on the clinical behaviour of these diseases. *Gut* 53(7): 973-979.
- Forrest, J. A. & D. J. Shearman (1975). Pulmonary vasculitis and ulcerative colitis. *Am J Dig Dis* 20(5): 482-486.
- Garg, K., D. A. Lynch, et al. (1993). Inflammatory airways disease in ulcerative colitis: CT and high-resolution CT features. *J Thorac Imaging* 8(2): 159-163.
- Giannini, S. & C. Martes (2006). Anemia in inflammatory bowel disease. *Minerva Gastroenterol Dietol* 52(3): 275-291.

- Gibb, W. R., D. P. Dhillon, et al. (1987). Bronchiectasis with ulcerative colitis and myelopathy. *Thorax* 42(2): 155-156.
- Gomollon, F. & J. P. Gisbert (2009). Anemia and inflammatory bowel diseases. *World J Gastroenterol* 15(37): 4659-4665.
- Gondim, F. A., T. H. Brannagan, 3rd, et al. (2005). Peripheral neuropathy in patients with inflammatory bowel disease. *Brain* 128(Pt 4): 867-879.
- Gow, P. J. & R. W. Chapman (2000). Liver transplantation for primary sclerosing cholangitis. *Liver* 20(2): 97-103.
- Graziadei, I. W., R. H. Wiesner, et al. (1999). Recurrence of primary sclerosing cholangitis following liver transplantation. *Hepatology* 29(4): 1050-1056.
- Greenstein, A. J., H. D. Janowitz, et al. (1976). The extra-intestinal complications of Crohn's disease and ulcerative colitis: a study of 700 patients. *Medicine (Baltimore)* 55(5): 401-412.
- Greenstein, A. J., D. B. Sachar, et al. (1992). Amyloidosis and inflammatory bowel disease. A 50-year experience with 25 patients. *Medicine (Baltimore)* 71(5): 261-270.
- Guhl, G. & A. Garcia-Diez (2008). Subcutaneous sweet syndrome. *Dermatol Clin* 26(4): 541-551, viii-ix.
- Gumaste, V., A. J. Greenstein, et al. (1989). Coombs-positive autoimmune hemolytic anemia in ulcerative colitis. *Dig Dis Sci* 34(9): 1457-1461.
- Hansen, L. S., S. Silverman, Jr., et al. (1983). The differential diagnosis of pyostomatitis vegetans and its relation to bowel disease. *Oral Surg Oral Med Oral Pathol* 55(4): 363-373.
- Hebbbar, M., D. Kozlowski, et al. (1997). Association between myelodysplastic syndromes and inflammatory bowel diseases. Report of seven new cases and review of the literature. *Leukemia* 11(12): 2188-2191.
- Higenbottam, T., G. M. Cochrane, et al. (1980). Bronchial disease in ulcerative colitis. *Thorax* 35(8): 581-585.
- Hilling, G. A., D. A. Robertson, et al. (1994). Unusual pulmonary complication of ulcerative colitis with a rapid response to corticosteroids: case report. *Gut* 35(6): 847-848.
- Hoffmann, R. M. & W. Kruis (2004). Rare extraintestinal manifestations of inflammatory bowel disease. *Inflamm Bowel Dis* 10(2): 140-147.
- Horio, T., S. Imamura, et al. (1981). Potassium iodide in the treatment of erythema nodosum and nodular vasculitis. *Arch Dermatol* 117(1): 29-31.
- Imagawa, M. (1999). [Extra-intestinal complications of ulcerative colitis: hematologic complication]. *Nippon Rinsho* 57(11): 2556-2561.
- Isenberg, J. I., H. Goldstein, et al. (1968). Pulmonary vasculitis--an uncommon complication of ulcerative colitis. Report of a case. *N Engl J Med* 279(25): 1376-1377.
- Jacob, A., J. G. Ledingham, et al. (1990). Ulcerative colitis and giant cell arteritis associated with sensorineural deafness. *J Laryngol Otol* 104(11): 889-890.
- Jahnsen, J., J. A. Falch, et al. (1997). Bone mineral density is reduced in patients with Crohn's disease but not in patients with ulcerative colitis: a population based study. *Gut* 40(3): 313-319.
- Jahnsen, J., J. A. Falch, et al. (2003). Body composition in patients with inflammatory bowel disease: a population-based study. *Am J Gastroenterol* 98(7): 1556-1562.
- Janssen, W. J., L. N. Bierig, et al. (2006). Stridor in a 47-year-old man with inflammatory bowel disease. *Chest* 129(4): 1100-1106.
- Jose, F. A. & M. B. Heyman (2008). Extraintestinal manifestations of inflammatory bowel disease. *J Pediatr Gastroenterol Nutr* 46(2): 124-133.

- Kamisawa, T., T. Shimosegawa, et al. (2009). Standard steroid treatment for autoimmune pancreatitis. *Gut* 58(11): 1504-1507.
- Kanra, G., A. Kara, et al. (2002). Sensorineural hearing loss as an extra-intestinal manifestation of ulcerative colitis in an adolescent girl with pyoderma gangrenosum. *Eur J Pediatr* 161(4): 216-218.
- Karlsen, T. H., E. Schrumpf, et al. (2007). Genetic epidemiology of primary sclerosing cholangitis. *World J Gastroenterol* 13(41): 5421-5431.
- katsanos, K. H.&E. V. Tsianos (2002). The heart in inflammatory bowel disease. *Annals of Gastroenterology* 15(2): 124-133.
- Kawashima, M., R. Koike, et al. (1999). [A case of Takayasu's arteritis with ulcerative colitis diagnosed by carotodynia and MRI findings]. *Nihon Rinsho Meneki Gakkai Kaishi* 22(5): 317-323.
- Keljo, D. J.&K. S. Sugerman (1997). Pancreatitis in patients with inflammatory bowel disease. *J Pediatr Gastroenterol Nutr* 25(1): 108-112.
- Kemmett, D.&J. A. Hunter (1990). Sweet's syndrome: a clinicopathologic review of twenty-nine cases. *J Am Acad Dermatol* 23(3 Pt 1): 503-507.
- Kimura, K., S. F. Hunter, et al. (2000). Concurrence of inflammatory bowel disease and multiple sclerosis. *Mayo Clin Proc* 75(8): 802-806.
- Kitiyakara, T.&R. W. Chapman (2008). Chemoprevention and screening in primary sclerosing cholangitis. *Postgrad Med J* 84(991): 228-237.
- Koulentaki, M., I. E. Koutroubakis, et al. (1999). Ulcerative colitis associated with primary biliary cirrhosis. *Dig Dis Sci* 44(10): 1953-1956.
- Koutroubakis, I. E. (2005). Therapy insight: Vascular complications in patients with inflammatory bowel disease. *Nat Clin Pract Gastroenterol Hepatol* 2(6): 266-272.
- Kruglik, G. D., H. L. Neiman, et al. (1977). Urological complications of regional enteritis. *Gastrointest Radiol* 1(4): 375-378.
- Krystallis, C. S., D. K. Kamberoglou, et al. (2010). Guillain-Barre syndrome during a relapse of ulcerative colitis: a case report. *Inflamm Bowel Dis* 16(4): 555-556.
- Larsen, S., K. Bendtzen, et al. (2010). Extraintestinal manifestations of inflammatory bowel disease: epidemiology, diagnosis, and management. *Ann Med* 42(2): 97-114.
- Lazzaro, D. R. (2010). Repair of necrotizing scleritis in ulcerative colitis with processed pericardium and a Prokera amniotic membrane graft. *Eye Contact Lens* 36(1): 60-61.
- Lee, Y. M.&M. M. Kaplan (1995). Primary sclerosing cholangitis. *N Engl J Med* 332(14): 924-933.
- Letsinger, J. A., M. A. McCarty, et al. (2005). Complex aphthosis: a large case series with evaluation algorithm and therapeutic ladder from topicals to thalidomide. *J Am Acad Dermatol* 52(3 Pt 1): 500-508.
- Levine, S. R., T. J. Crowley, et al. (1982). Hypomagnesemia and ventricular tachycardia: a complication of ulcerative colitis and parenteral hyperalimentation in a nondigitalized noncardiac patient. *Chest* 81(2): 244-247.
- Levy, C., J. Lymp, et al. (2005). The value of serum CA 19-9 in predicting cholangiocarcinomas in patients with primary sclerosing cholangitis. *Dig Dis Sci* 50(9): 1734-1740.
- Lidon, R. M.&A. Ariza (1993). [Heart failure, changes in heart rhythm, and cardiogenic shock in a 46-year-old patient]. *Med Clin (Barc)* 101(20): 789-794.
- Loftus, E. V., Sandborn WJ, Lindor KD, et al. (1997). Interactions between chronic liver disease and inflammatory bowel disease. *Inflamm Bowel Dis* 3: 288-302.
- Lossos, A., Y. River, et al. (1995). Neurologic aspects of inflammatory bowel disease. *Neurology* 45(3 Pt 1): 416-421.


- Lundqvist, K.&U. Broome (1997). Differences in colonic disease activity in patients with ulcerative colitis with and without primary sclerosing cholangitis: a case control study. *Dis Colon Rectum* 40(4): 451-456.
- Lyne, A. J.&D. A. Pitkeathley (1968). Episcleritis and scleritis. Association with connective tissue disease. *Arch Ophthalmol* 80(2): 171-176.
- Macarez, R., S. Bazin, et al. (2005). [Orbital myositis associated with ulcerative colitis]. *J Fr Ophthalmol* 28(6): 610-613.
- MacCarty, R. L., N. F. LaRusso, et al. (1983). Primary sclerosing cholangitis: findings on cholangiography and pancreatography. *Radiology* 149(1): 39-44.
- Madsen, P. V.&G. Andersen (1994). Multifocal osteonecrosis related to steroid treatment in a patient with ulcerative colitis. *Gut* 35(1): 132-134.
- Maeder, H. U. (1996). The complete heart-block--an extraintestinal manifestation of ulcerative colitis. *Z Gastroenterol* 34(1): 27-29.
- Marshall, J. K.&E. J. Irvine (1997). Successful therapy of refractory erythema nodosum associated with Crohn's disease using potassium iodide. *Can J Gastroenterol* 11(6): 501-502.
- Marten, K., F. Fend, et al. (2005). Case report: Fatal acute exacerbation of usual interstitial pneumonia in ulcerative colitis. *Br J Radiol* 78(932): 762-766.
- Masaki, T., T. Muto, et al. (1997). Unusual cerebral complication associated with ulcerative colitis. *J Gastroenterol* 32(2): 251-254.
- Matis, W. L., C. N. Ellis, et al. (1992). Treatment of pyoderma gangrenosum with cyclosporine. *Arch Dermatol* 128(8): 1060-1064.
- McCallum, D. I.&P. D. Kinmont (1968). Dermatological manifestations of crohn's disease. *Br J Dermatol* 80(1): 1-8.
- Miehlsler, W., W. Reinisch, et al. (2004). Is inflammatory bowel disease an independent and disease specific risk factor for thromboembolism? *Gut* 53(4): 542-548.
- Mikroulis, D. A., G. D. Antypas, et al. (1999). Arterial Thrombosis in Ulcerative Colitis: Case Report. *Int J Angiol* 8(1): 62-64.
- Mir-Madjlessi, S. H., R. G. Farmer, et al. (1987). Bile duct carcinoma in patients with ulcerative colitis. Relationship to sclerosing cholangitis: report of six cases and review of the literature. *Dig Dis Sci* 32(2): 145-154.
- Mir-Madjlessi, S. H., J. S. Taylor, et al. (1985). Clinical course and evolution of erythema nodosum and pyoderma gangrenosum in chronic ulcerative colitis: a study of 42 patients. *Am J Gastroenterol* 80(8): 615-620.
- Mizuta, Y., H. Isomoto, et al. (2003). Immune thrombocytopenic purpura in patients with ulcerative colitis. *J Gastroenterol* 38(9): 884-890.
- Moff, S. L., I. R. Kamel, et al. (2006). Diagnosis of primary sclerosing cholangitis: a blinded comparative study using magnetic resonance cholangiography and endoscopic retrograde cholangiography. *Gastrointest Endosc* 64(2): 219-223.
- Monsen, U., J. Sorstad, et al. (1990). Extracolonic diagnoses in ulcerative colitis: an epidemiological study. *Am J Gastroenterol* 85(6): 711-716.
- Moshkowitz, M., N. Arber, et al. (1992). Streptococcus bovis endocarditis as a presenting manifestation of idiopathic ulcerative colitis. *Postgrad Med J* 68(805): 930-931.
- Nakamura, M., A. Kanamori, et al. (2005). Alternate total ophthalmoplegia and optic neuropathy associated with ulcerative colitis. *Eye (Lond)* 19(2): 235-237.
- Nash, P. T.&T. H. Florin (2005). Tumour necrosis factor inhibitors. *Med J Aust* 183(4): 205-208.

- Navaneethan, U.&B. Shen (2010). Hepatopancreatobiliary manifestations and complications associated with inflammatory bowel disease. *Inflamm Bowel Dis* 16(9): 1598-1619.
- Nelson, J., M. M. Barron, et al. (1986). Cerebral vasculitis and ulcerative colitis. *Neurology* 36(5): 719-721.
- Newell, L. M.&F. D. Malkinson (1982). Pyoderma (ecthyma) gangrenosum by Brunsting, Goeckerman and O'Leary, October 1930. Commentary: Pyoderma gangrenosum. *Arch Dermatol* 118(10): 743-773.
- Nogami, H., T. Iiai, et al. (2007). Common carotid arterial thrombosis associated with ulcerative colitis. *World J Gastroenterol* 13(11): 1755-1757.
- Nomoto, T., T. Nagao, et al. (2006). Cerebral arteriopathy with extracranial artery involvement in a patient with ulcerative colitis. *J Neurol Sci* 243(1-2): 87-89.
- Novotny, D. A., R. J. Rubin, et al. (1992). Arterial thromboembolic complications of inflammatory bowel disease. Report of three cases. *Dis Colon Rectum* 35(2): 193-196.
- Nudelman, R. J., D. G. Rosen, et al. (2010). Cerebral sinus thrombosis: a fatal neurological complication of ulcerative colitis. *Patholog Res Int* 2010: 132754.
- Ozdil, S., F. Akyuz, et al. (2004). Ulcerative colitis: analyses of 116 cases (do extraintestinal manifestations effect the time to catch remission?). *Hepatogastroenterology* 51(57): 768-770.
- Pandian, J. D., G. Pawar, et al. (2004). Multiple sclerosis in a patient with chronic ulcerative colitis. *Neurol India* 52(2): 282-283.
- Pardi, D. S., E. V. Loftus, Jr., et al. (2003). Ursodeoxycholic acid as a chemopreventive agent in patients with ulcerative colitis and primary sclerosing cholangitis. *Gastroenterology* 124(4): 889-893.
- Pena, E., V. F. Moreira, et al. (2000). [Idiopathic chronic pancreatitis (with diffuse stenosis of Wirsung's duct) in ulcerative colitis]. *Gastroenterol Hepatol* 23(8): 389-391.
- Perdigoto, R., H. A. Carpenter, et al. (1992). Frequency and significance of chronic ulcerative colitis in severe corticosteroid-treated autoimmune hepatitis. *J Hepatol* 14(2-3): 325-331.
- Rabinovitz, M., A. J. Demetris, et al. (1992). Simultaneous occurrence of primary sclerosing cholangitis and autoimmune chronic active hepatitis in a patient with ulcerative colitis. *Dig Dis Sci* 37(10): 1606-1611.
- Rasmussen, H. H., J. F. Fallingborg, et al. (1997). Hepatobiliary dysfunction and primary sclerosing cholangitis in patients with Crohn's disease. *Scand J Gastroenterol* 32(6): 604-610.
- Rezaie, A., K. Wong, et al. (2010). Pericardial tamponade in a patient with inactive ulcerative colitis. *Case Report Med* 2010: 352417.
- Rickli, H., C. Fretz, et al. (1994). Severe inflammatory upper airway stenosis in ulcerative colitis. *Eur Respir J* 7(10): 1899-1902.
- Riegler, G., R. D'Inca, et al. (1998). Hepatobiliary alterations in patients with inflammatory bowel disease: a multicenter study. Caprilli & Gruppo Italiano Studio Colon-Retto. *Scand J Gastroenterol* 33(1): 93-98.
- Roddie, P., H. Dorrance, et al. (1995). Treatment of sulphasalazine-induced agranulocytosis with granulocyte macrophage-colony stimulating factor. *Aliment Pharmacol Ther* 9(6): 711-712.
- Rosen, R. B.&R. L. Teplitz (1965). Chronic Granulocytic Leukemia Complicated by Ulcerative Colitis: Elevated Leukocyte Alkaline Phosphatase and Possible Modifier Gene Deletion. *Blood* 26: 148-156.

- Rozen, S. M., M. Y. Nahabedian, et al. (2001). Management strategies for pyoderma gangrenosum: case studies and review of literature. *Ann Plast Surg* 47(3): 310-315.
- Ruffolo, C., I. Angriman, et al. (2004). Minimally invasive management of Crohn's disease complicated by ureteral stenosis. *Surg Laparosc Endosc Percutan Tech* 14(5): 292-294.
- Rutgeerts, P., W. J. Sandborn, et al. (2005). Infliximab for induction and maintenance therapy for ulcerative colitis. *N Engl J Med* 353(23): 2462-2476.
- Saarinen, S., O. Olerup, et al. (2000). Increased frequency of autoimmune diseases in patients with primary sclerosing cholangitis. *Am J Gastroenterol* 95(11): 3195-3199.
- Saleh, T. (2010). Left Ventricular Thrombosis in Ulcerative Colitis. *Case Rep Gastroenterol* 4(2): 220-223.
- Saltzman, K., L. J. Rossoff, et al. (2001). Mesalamine-induced unilateral eosinophilic pneumonia. *AJR Am J Roentgenol* 177(1): 257.
- Salvarani, C., G. Fornaciari, et al. (2000). Musculoskeletal manifestations in inflammatory bowel disease. *Eur J Intern Med* 11(4): 210-214.
- Sandborn, W. J., W. F. Stenson, et al. (2006). Safety of celecoxib in patients with ulcerative colitis in remission: a randomized, placebo-controlled, pilot study. *Clin Gastroenterol Hepatol* 4(2): 203-211.
- Sasvary, F., J. Murin, et al. (1996). [Intracavitary thrombosis--unusual complications in ulcerative colitis]. *Bratisl Lek Listy* 97(11): 669-672.
- Satsangi, J., J. Marshall, et al. (1996). Ulcerative colitis complicated by renal cell carcinoma: a series of three patients. *Gut* 38(1): 148-150.
- Saxon, A., F. Shanahan, et al. (1990). A distinct subset of antineutrophil cytoplasmic antibodies is associated with inflammatory bowel disease. *J Allergy Clin Immunol* 86(2): 202-210.
- Scheid, R.&N. Teich (2007). Neurologic manifestations of ulcerative colitis. *Eur J Neurol* 14(5): 483-493.
- Schulz, E. J.&D. A. Whiting (1976). Treatment of erythema nodosum and nodular vasculitis with potassium iodide. *Br J Dermatol* 94(1): 75-78.
- Sedwick, L. A., T. G. Klingele, et al. (1984). Optic neuritis in inflammatory bowel disease. *J Clin Neuroophthalmol* 4(1): 3-6.
- Shibata, C., Y. Funayama, et al. (2002). Takayasu's arteritis after total proctocolectomy for ulcerative colitis: report of a case. *Dis Colon Rectum* 45(3): 422-424.
- Ship, J. A. (1996). Recurrent aphthous stomatitis. An update. *Oral Surg Oral Med Oral Pathol Oral Radiol Endod* 81(2): 141-147.
- Simsek, I., H. Erdem, et al. (2007). Optic neuritis occurring with anti-tumour necrosis factor alpha therapy. *Ann Rheum Dis* 66(9): 1255-1258.
- Skhiri, H., B. Knebelmann, et al. (1998). Nephrotic syndrome associated with inflammatory bowel disease treated by mesalazine. *Nephron* 79(2): 236.
- Smith, T.&A. S. Befeler (2007). High-dose ursodeoxycholic acid for the treatment of primary sclerosing cholangitis. *Curr Gastroenterol Rep* 9(1): 54-59.
- Snook, J. A., P. Kelly, et al. (1989). Fibrolamellar hepatocellular carcinoma complicating ulcerative colitis with primary sclerosing cholangitis. *Gut* 30(2): 243-245.
- Sorensen, H. T.&K. M. Fonager (1997). Myocarditis and inflammatory bowel disease. A 16-year Danish nationwide cohort study. *Dan Med Bull* 44(4): 442-444.
- Souissi, A., R. Benmously, et al. (2007). [Sweet's syndrome: a propos of 8 cases]. *Tunis Med* 85(1): 49-53.
- Spira, A., R. Grossman, et al. (1998). Large airway disease associated with inflammatory bowel disease. *Chest* 113(6): 1723-1726.

- Stawarski, A., B. Iwanczak, et al. (2006). [Intestinal complications and extraintestinal manifestations in children with inflammatory bowel disease]. *Pol Merkur Lekarski* 20(115): 22-25.
- Stebbing, J., F. Askin, et al. (1999). Pulmonary manifestations of ulcerative colitis mimicking Wegener's granulomatosis. *J Rheumatol* 26(7): 1617-1621.
- Stein, J., F. Hartmann, et al. (2010). Diagnosis and management of iron deficiency anemia in patients with IBD. *Nat Rev Gastroenterol Hepatol* 7(11): 599-610.
- Stiehl, A. (2004). [Primary sclerosing cholangitis]. *Internist (Berl)* 45(1): 27-32.
- Stokke, K. T., P. A. Teisberg, et al. (1976). Nephrotic syndrome in ulcerative colitis. *Scand J Gastroenterol* 11(6): 571-576.
- Storwick, G. S., M. B. Prihoda, et al. (1994). Pyodermatitis-pyostomatitis vegetans: a specific marker for inflammatory bowel disease. *J Am Acad Dermatol* 31(2 Pt 2): 336-341.
- Suzuki, Y., K. Nakase, et al. (1995). [Acute promyelocytic leukemia following ulcerative colitis]. *Rinsho Ketsueki* 36(7): 707-709.
- Tan, R. S. (1974). Ulcerative colitis, myasthenia gravis, atypical lichen planus, alopecia areata, vitiligo. *Proc R Soc Med* 67(3): 195-196.
- Terjung, B., V. Herzog, et al. (1998). Atypical antineutrophil cytoplasmic antibodies with perinuclear fluorescence in chronic inflammatory bowel diseases and hepatobiliary disorders colocalize with nuclear lamina proteins. *Hepatology* 28(2): 332-340.
- Terjung, B., J. Sohne, et al. (2010). p-ANCA in autoimmune liver disorders recognise human beta-tubulin isotype 5 and cross-react with microbial protein FtsZ. *Gut* 59(6): 808-816.
- Terjung, B. & U. Spengler (2009). Atypical p-ANCA in PSC and AIH: a hint toward a leaky gut? *Clin Rev Allergy Immunol* 36(1): 40-51.
- Thornton, J. R., R. H. Teague, et al. (1980). Pyoderma gangrenosum and ulcerative colitis. *Gut* 21(3): 247-248.
- Timani, S. & D. F. Mutasim (2008). Skin manifestations of inflammatory bowel disease. *Clin Dermatol* 26(3): 265-273.
- Tokuyama, H., S. Wakino, et al. (2010). Acute interstitial nephritis associated with ulcerative colitis. *Clin Exp Nephrol* 14(5): 483-486.
- Tomomasa, T., K. Itoh, et al. (1993). An infant with ulcerative colitis complicated by endocarditis and cerebral infarction. *J Pediatr Gastroenterol Nutr* 17(3): 323-325.
- Trimarchi, H. M., A. Iotti, et al. (2001). Immunoglobulin A nephropathy and ulcerative colitis. A focus on their pathogenesis. *Am J Nephrol* 21(5): 400-405.
- Tromm, A., D. May, et al. (2001). Cutaneous manifestations in inflammatory bowel disease. *Z Gastroenterol* 39(2): 137-144.
- Trost, L. B. & J. K. McDonnell (2005). Important cutaneous manifestations of inflammatory bowel disease. *Postgrad Med J* 81(959): 580-585.
- Tsiolakidou, G. & I. E. Koutroubakis (2008). Thrombosis and inflammatory bowel disease-the role of genetic risk factors. *World J Gastroenterol* 14(28): 4440-4444.
- Tsujikawa, T., M. Urabe, et al. (2000). Haemorrhagic cerebral sinus thrombosis associated with ulcerative colitis: a case report of successful treatment by anticoagulant therapy. *J Gastroenterol Hepatol* 15(6): 688-692.
- Turner, R. B., J. J. Emer, et al. (2010). Rapid resolution of pyoderma gangrenosum after treatment with intravenous cyclosporine. *J Am Acad Dermatol* 63(3): e72-74.
- Tutrone, W. D., K. Green, et al. (2007). Pyoderma gangrenosum: dermatologic application of hyperbaric oxygen therapy. *J Drugs Dermatol* 6(12): 1214-1219.
- Ucci, G., P. Ferrando, et al. (2003). A case of Evans' syndrome in a patient with ulcerative colitis. *Dig Liver Dis* 35(6): 439-441.

- Valderrama Rojas, M., F. J. Rodriguez Gorostiza, et al. (2003). [Autoimmune hemolytic anemia: a rare complication of ulcerative colitis]. *An Med Interna* 20(2): 78-80.
- Veloso, F. T., J. Fraga, et al. (1991). Autoimmune hemolytic anemia in ulcerative colitis. A case report with review of the literature. *J Clin Gastroenterol* 13(4): 445-447.
- Vestergaard, P. (2004). Prevalence and pathogenesis of osteoporosis in patients with inflammatory bowel disease. *Minerva Med* 95(6): 469-480.
- Vij, A., G. M. Modi, et al. (2010). Chronic, recurrent neutrophilic dermatosis: a case report. *Dermatol Online J* 16(10): 1.
- Ward, H., K. L. Fisher, et al. (1999). Constrictive bronchiolitis and ulcerative colitis. *Can Respir J* 6(2): 197-200.
- Warwick, G., T. Leecy, et al. (2009). Pulmonary necrobiotic nodules: a rare extraintestinal manifestation of Crohn's disease. *Eur Respir Rev* 18(111): 47-50.
- Wasserteil, V., S. Bruce, et al. (1992). Pyoderma gangrenosum treated with hyperbaric oxygen therapy. *Int J Dermatol* 31(8): 594-596.
- Wee, A.&J. Ludwig (1985). Pericholangitis in chronic ulcerative colitis: primary sclerosing cholangitis of the small bile ducts? *Ann Intern Med* 102(5): 581-587.
- Weinstein, M., D. Turner, et al. (2005). Erythema nodosum as a presentation of inflammatory bowel disease. *CMAJ* 173(2): 145-146.
- Weiss, G.&L. T. Goodnough (2005). Anemia of chronic disease. *N Engl J Med* 352(10): 1011-1023.
- Wester, A. L., M. H. Vatn, et al. (2001). Secondary amyloidosis in inflammatory bowel disease: a study of 18 patients admitted to Rikshospitalet University Hospital, Oslo, from 1962 to 1998. *Inflamm Bowel Dis* 7(4): 295-300.
- Wiesner, R. H., P. M. Grambsch, et al. (1989). Primary sclerosing cholangitis: natural history, prognostic factors and survival analysis. *Hepatology* 10(4): 430-436.
- Wilcox, P., R. Miller, et al. (1987). Airway involvement in ulcerative colitis. *Chest* 92(1): 18-22.
- Wilson, A., E. Reyes, et al. (2004). Prevalence and outcomes of anemia in inflammatory bowel disease: a systematic review of the literature. *Am J Med* 116 Suppl 7A: 44S-49S.
- Wittekindt, C., J. C. Luers, et al. (2007). Pyoderma gangrenosum in the head and neck. *Arch Otolaryngol Head Neck Surg* 133(1): 83-85.
- Wodzinski, M. A.&A. C. Lawrence (1985). Severe Coombs positive autoimmune haemolytic anaemia associated with ulcerative colitis. *Postgrad Med J* 61(713): 261-262.
- Wollina, U. (2002). Clinical management of pyoderma gangrenosum. *Am J Clin Dermatol* 3(3): 149-158.
- Yates, V. M., G. Watkinson, et al. (1982). Further evidence for an association between psoriasis, Crohn's disease and ulcerative colitis. *Br J Dermatol* 106(3): 323-330.
- Yesilova, Z., I. Naharci, et al. (2006). Motor axonal polyneuropathy in the course of ulcerative colitis: a case report. *Turk J Gastroenterol* 17(1): 58-61.
- Yoshida, E. M., H. Chaun, et al. (1996). Immune thrombocytopenic purpura in three patients with preexisting ulcerative colitis. *Am J Gastroenterol* 91(6): 1232-1235.
- Zhu, A., M. Kaneshiro, et al. (2010). Evaluation and treatment of iron deficiency anemia: a gastroenterological perspective. *Dig Dis Sci* 55(3): 548-559.



Ulcerative Colitis - Epidemiology, Pathogenesis and Complications

Edited by Dr Mortimer O'Connor

ISBN 978-953-307-880-9

Hard cover, 280 pages

Publisher InTech

Published online 14, December, 2011

Published in print edition December, 2011

This book is intended to act as an up-to-date reference point and knowledge developer for all readers interested in the area of gastroenterology and in particular, Ulcerative Colitis. All authors of the chapters are experts in their fields of publication, and deserve individual credit and praise for their contributions to the world of Ulcerative Colitis. We hope that you will find this publication informative, stimulating, and a reference point for the area of Ulcerative colitis as we move forward in our understanding of the field of medicine.

How to reference

In order to correctly reference this scholarly work, feel free to copy and paste the following:

Brian Huang, Lola Y. Kwan and David Q. Shih (2011). Extraintestinal Manifestations of Ulcerative Colitis, Ulcerative Colitis - Epidemiology, Pathogenesis and Complications, Dr Mortimer O'Connor (Ed.), ISBN: 978-953-307-880-9, InTech, Available from: <http://www.intechopen.com/books/ulcerative-colitis-epidemiology-pathogenesis-and-complications/extraintestinal-manifestations-of-ulcerative-colitis>

INTECH
open science | open minds

InTech Europe

University Campus STeP Ri
Slavka Krautzeka 83/A
51000 Rijeka, Croatia
Phone: +385 (51) 770 447
Fax: +385 (51) 686 166
www.intechopen.com

InTech China

Unit 405, Office Block, Hotel Equatorial Shanghai
No.65, Yan An Road (West), Shanghai, 200040, China
中国上海市延安西路65号上海国际贵都大饭店办公楼405单元
Phone: +86-21-62489820
Fax: +86-21-62489821

© 2011 The Author(s). Licensee IntechOpen. This is an open access article distributed under the terms of the [Creative Commons Attribution 3.0 License](https://creativecommons.org/licenses/by/3.0/), which permits unrestricted use, distribution, and reproduction in any medium, provided the original work is properly cited.

IntechOpen

IntechOpen