

We are IntechOpen, the world's leading publisher of Open Access books Built by scientists, for scientists

6,900

Open access books available

185,000

International authors and editors

200M

Downloads

Our authors are among the

154

Countries delivered to

TOP 1%

most cited scientists

12.2%

Contributors from top 500 universities



WEB OF SCIENCE™

Selection of our books indexed in the Book Citation Index
in Web of Science™ Core Collection (BKCI)

Interested in publishing with us?
Contact book.department@intechopen.com

Numbers displayed above are based on latest data collected.
For more information visit www.intechopen.com



Non-Herpetic Acute Limbic Encephalitis: A New Subgroup of Limbic Encephalitis?

Hiroshi Shoji¹, Noriyuki Kimura², Toshihide Kumamoto²,
Takashi Ichiyama³ and Yukitoshi Takahashi⁴

¹*Division of Neurology, St. Mary Hospital, Fukuoka 830-8543,*

²*Department of Internal Medicine III, Faculty of Medicine,
Oita University, Oita,*

³*Department of Pediatrics, Yamaguchi University Graduate
School of Medicine, Yamaguchi,*

⁴*National Epilepsy Center, Shizuoka Institute of Epilepsy
and Neurological Disorders, Shizuoka
Japan*

1. Introduction

Non-herpetic acute limbic encephalitis (NHALE) was found at 1994 during the survey of herpes simplex encephalitis (HSE) in the Kyushu district, Japan. NHALE is characterized by a lack of evidence of the herpes simplex virus (HSV) genome or HSV antibody, non-paraneoplastic limbic encephalitis, and magnetic resonance imaging (MRI) abnormalities in bilateral medial temporal lobes such as the hippocampi and amygdalae (Kusuhara et al., 1994; Kaji et al., 1996; Shoji et al., 2004). Etiologies of NHALE consist of various causes, including viral origins, autoimmune disorders, and several anti-neural antibodies. Since Urgent Conference on Non-Herpetic Limbic Encephalitis, at Ichikawa City, Japan, November 2002, many cases have been accumulated as viral related acute limbic encephalitis, autoantibody-mediated acute limbic encephalitis, paraneoplastic limbic encephalitis or encephalopathy (Yuasa et al, 2003). Cerebrospinal fluid (CSF) shows a mild pleocytosis with increase of pressure, mild increase of protein, and sometimes, a lack of the pleocytosis. The CSF level of interferon- γ (IFN- γ) is unchanged with an increase of interleukin (IL)-6 (Asaoka et al., 2004; Ichiyama et al., 2008a). Among them, NHALE patient group with the onset symptoms of abnormal behavior and incoherence, and the detection of anti-glutamate receptor (GluR ϵ 2 NR2B) antibodies is gaining attention (Nemoto et al., 2005; Hayashi et al. 2005; Takahashi et al., 2007). This NHALE type is indicated to form a new subgroup of acute limbic encephalitis or encephalopathy. GluR ϵ 2 is a subunit of the N-methyl-D-aspartate (NMDA) glutamate receptor. NHALE overlaps clinically to anti-NMDA receptor (NR1+2A) encephalitis, but the NMDA encephalitis is usually associated with ovarian teratoma (Dalmau et al., 2007; Iizuka et al., 2008).

In this review, two NHALE patients with positive anti-GluR ϵ 2 antibody are briefly described, and the pathogenesis of NHALE, clinical features, differential diagnosis, prognosis, and sequelae are discussed.

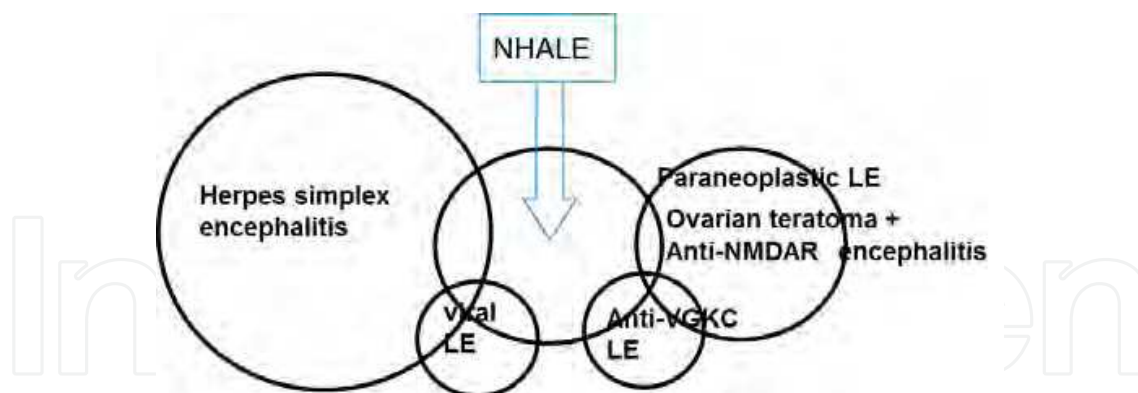


Fig. 1. Possible relationships of NHALE and related disorders.

NHALE=non-herpetic acute limbic encephalitis, NMDAR=N-methyl-D-aspartate receptor
VGKC =voltage-gated potassium channel, LE=limbic encephalitis

2. Case presentation

Here, we present two representative patients with NHALE who were evaluated at A rehabilitation hospital 3 months to 2 years after the onset (Noto et al., 2008; Shoji et al., 2009).

Patient 1: A 50 year-old man was restless and became talkative with a fever and palpitation in the end of July 200x. Several days later, he was admitted with collapsed state to a nearby hospital. On admission, he showed a fever of 38.4°C, coma state, and generalized myoclonus without nuchal stiffness, then paroxysmal atrial fibrillation, status epileptics, and needed an artificial respirator for 3 months. The CSF exhibited no abnormalities in the cell count, protein and glucose contents, and polymerase chain reaction (PCR) for HSV and human herpesvirus (HHV)-6 was negative. The serum antibodies were negative for herpesvirus groups (HSV, HHV-6, varicella-zoster virus and cytomegalovirus). The MRI revealed hyperintensity lesions bilaterally in the hippocampi, amygdalae and claustrum. His CSF at the 5th illness day was positive for anti-GluR2 IgG and IgM antibodies. Acyclovir (ACV) administration, thereafter methylprednisolone pulse therapy was performed with sodium valproate and clonazepam. Amnestic syndrome and partial seizure remained. Three months after the onset he was transferred to A rehabilitation hospital which was near to his home town. Neuropsychological tests such as the Wechsler adult intelligence scale-revised (Japanese edition, WAIS-R), Wechsler memory scale-revised (Japanese edition, WMS-R), and functional independence measure (FIM) were conducted to assess the sequelae for 2 years after the onset. WMS-R showed severe impairment of recent memory with normal total WAIS IQ and FIM points. The MRI at the recovery stage showed bilateral atrophic changes in the hippocampi and amygdalae with hyperintensity lesions in the rectus gyri (Fig 2a). Thereafter, he moved to an another rehabilitation hospital. At 2 years after the onset, moderate amnestic syndrome and focal seizure remained, and he is still unable to return to his previous job.

Patient 2: A 36 year-old man had diarrhea for several days, and he then developed a fever of 40°C for one week, but he did not stop his job of rescue party. Convulsive seizures and delirium appeared, and he was admitted to a nearby hospital. His consciousness level was stupor state without nuchal stiffness and pathologic reflexes. The CSF contained 6 mononuclear cells per mm³ and protein content of 46 mg/dl, and HSV PCR was negative in

the CSF. Serum enzyme immunosorbent assay (EIA) tests for herpesvirus groups, rubella, measles and mumps were all negative. His CSF showed positive for anti-GluR ϵ 2 IgG and IgM antibodies. Electroencephalogram (EEG) revealed periodic lateralized epileptiform discharges (PLEDs). The MRI exhibited hyperintensity lesions in the bilaterally medial temporal lobes including hippocampi and amygdalae. Patient 2 was diagnosed as having NHALE with positive anti-GluR ϵ 2 antibodies. Anticonvulsant drugs and ACV were administered, but he developed status epileptics, and put on a respirator, and methylprednisolone pulse and immunoglobulin therapies were conducted. Three months after the onset, he was transferred to A rehabilitation hospital. He showed a fever of 37°C, attention impairment, nystagmus, myoclonus at the left face and upper extremity, and weakness and atrophy of the both legs as a disuse syndrome. MRI revealed bilaterally atrophy of the hippocampi and amygdalae with hyperintensity lesions (Fig.2b). WAIS-R showed 69 of total IQ, and 44/126 at FIM. Intensive rehabilitation was performed, and 6 months later he was discharged with improvement of scores of WAIS-R, WMS-R and FIM. At 2 years after the onset, mild dysarthria, attention impairment, and gait disturbance have remained, and he is now trying to return to his previous job.

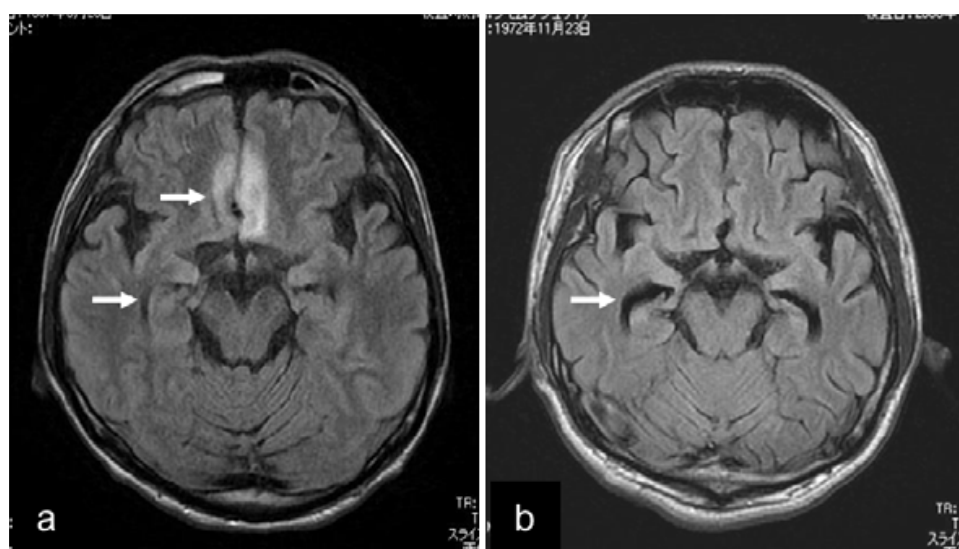


Fig. 2. a,b: MRIs of Patients 1 & 2 with NHALE at the recovery stage; a: an axial fluid attenuated inversion recovery (FLAIR) MRI of Patient 1 reveals hyperintensity lesions in the rectus gyri, and mild dilatation of the inferior horn. b: an axial FLAIR MRI of Patient 2 shows moderate dilatation of the inferior horn.

3. Pathogenesis

In the CSF cytokines of NHALE patients, the IFN- γ value is not elevated with an increase of IL-6 (Asaoka et al., 2004; Ichiyama et al., 2008a; Fig.3). CSF IFN- γ levels were elevated in the central nervous system (CNS) disorders due to direct viral invasion, such as viral meningitis and HSE (Matsubara et al., 2000; Ichiyama et al., 2005; Ichiyama et al., 2008a), but not in immune-mediated CNS disorders, such as acute disseminated encephalomyelitis, influenza-associated encephalopathy, and acute encephalopathy following prolonged febrile seizures, and hemolytic uremic syndrome with encephalopathy (Ichiyama et al., 2002; Ichiyama et al., 2004; Ichiyama et al., 2008b; Shiraishi et al., 2008). IFN- γ , which is produced by NK cells,

CD8+ and Th1 type CD4+ T lymphocytes, plays an important role in host defense against viral infection, and inhibits viral replication (Samuel., 1991). Therefore, IFN- γ elevating in the CSF may exert an inhibitory effect against viruses invading the CNS. With respect to CSF IFN- γ levels, we suggest that the main pathogenesis of NHALE is not caused by the direct invasion of virus into the CNS.

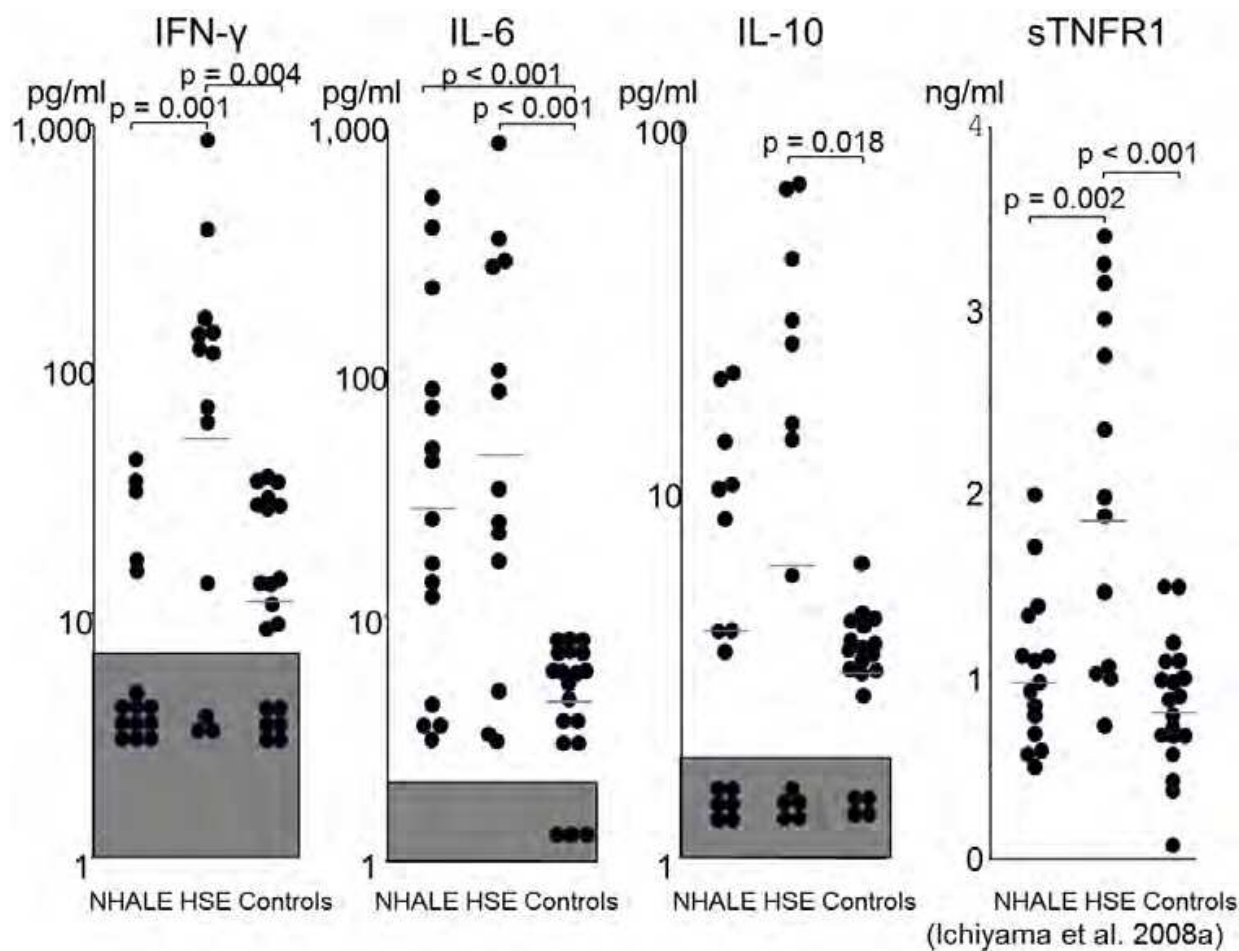


Fig. 3. The CSF concentrations of IFN- γ , IL-6, IL-10, and sTNFR1 in patients with NHALE, HSE, and controls. Horizontal lines indicate geometric means. Shaded areas indicate values below the detection limits. IFN- γ =interferon- γ , IL=interleukin, sTNFR1=soluble tumor necrosis factor receptor-1

In a major subgroup of NHALE patients presenting psychiatric symptoms such as abnormal behavior or incoherence, a subunit of NMDA glutamate receptor antibody (GluR ϵ 2 NR2B) was detected in the sera and CSF. In Japan, many similar cases have been accumulated (Nemoto et al., 2005; Hayashi et al., 2005; Noto et al., 2008). Patients 1 & 2 here described are regarded as anti-GluR ϵ 2 positive NHALE. Mochizuki et al. (2006) reported an autopsy case of NHALE with positive Anti-GluR ϵ 2 NR2B antibody, and a few autopsy cases followed (Okamoto et al., 2008; Maki et al., 2008). Thus, this NHALE type should be regarded as belonging to a new subgroup of acute limbic encephalitis. Anti-NMDA type GluR antibodies categorized into NMDA glutamate receptor complex antibodies {GluR ζ 1 (NR1) + GluR ϵ 1 (NR2A) or GluR ϵ 2 (NR2B)} and antibodies to each subunits composing of the complex antibodies. Antibodies to GluR ϵ 2 (NR2B) subunit are antibodies to a whole

molecules of GluR ϵ 2 (NR2B) subunit (Takahashi et al., 2008, Fig.4). Takahashi et al. (2008) reported 60% positive rate of Anti-GluR ϵ 2 antibodies in the serum of NHALE patients from the acute to convalescent stage, whereas these Anti-GluR ϵ 2 antibodies in the CSF of NHALE patients were detected in 50% at the acute stage, and 40% at the recovery stage; anti-GluR ϵ 2 antibodies is indicated to invade from serum to CNS with injury of the blood-brain barrier, and may involve the pathogenesis of acute limbic encephalitis or encephalopathy (Takahashi et al., 2007; 2010). Ichiyama et al. (2009) reported that high matrix metalloproteinase-9/tissue inhibitor of metalloproteinase 1 (MMP-9/TIMP-1) ratio which indicates to injure the blood-brain barrier continues from the acute to convalescent stages (Fig. 5).

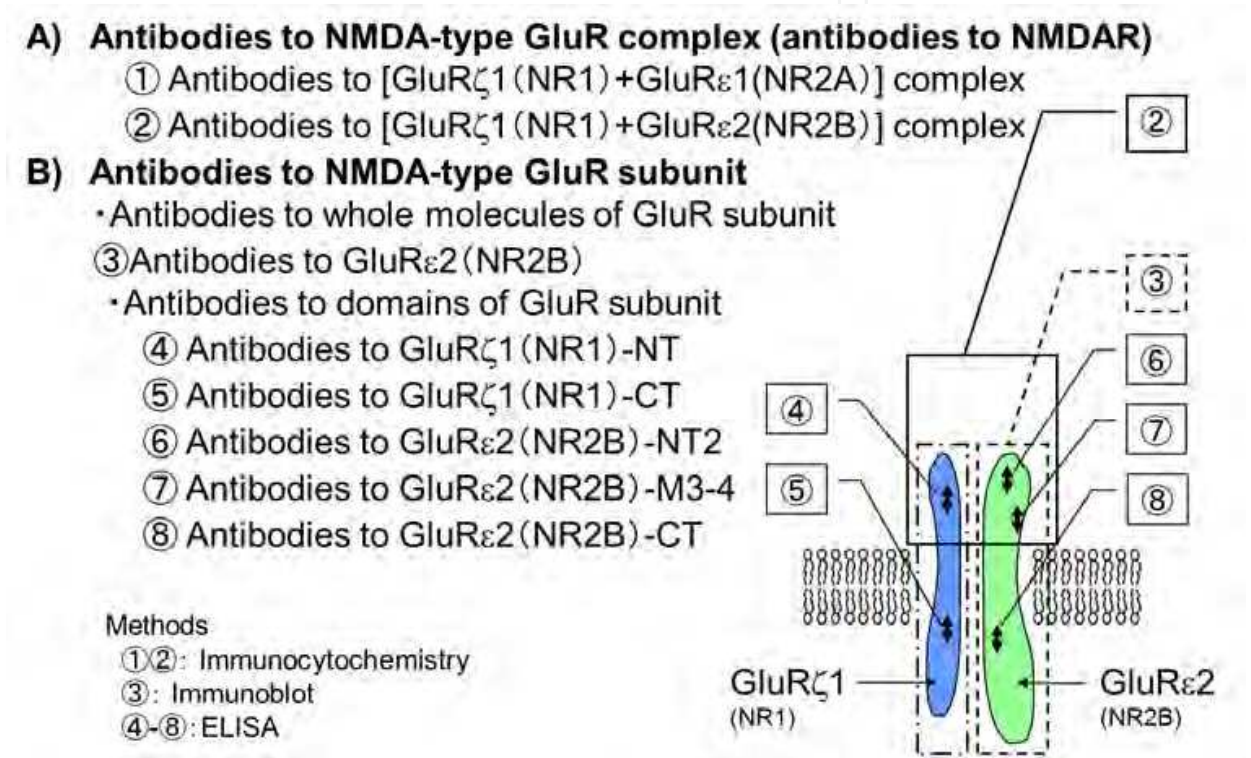


Fig. 4. Antibodies to NMDA-type GluR complex and each domain of GluR subunits. Antibodies to NMDA-type GluR complex (antibodies to NMDAR) were examined using HEK cells transfected by expression plasmid of GluR ζ 1 (NR1) + GluR ϵ 1 (NR2A) or GluR ϵ 2 (NR2B) (Dalmau et al., 2007). Antibodies against whole molecules of GluR ϵ 2 were examined by immunoblot (Takahashi Y et al., 2003). Antibodies against each domain of GluR ϵ 2 (NR2B) and GluR ζ 1 (NR1) were examined by ELISA with synthesized peptides. NMDA=N-methyl-D-aspartate, GluR= glutamate receptor

On the other hand, the anti-GluR ϵ 2 antibodies are also detected in Rasmussen encephalitis, acute encephalitis with refractory repetitive partial seizures (AERRPS), mild encephalopathy with a reversible splenial lesion (MERS), or HSE (Takahashi et al., 2003; 2005; Sakuma et al., 2009; Kai et al., 2009). Anti-GluR ϵ 2 antibody encephalitis may form a wider spectrum of encephalitis and encephalopathy. The antibody reacts cross to anti-NMDA-type GluR complex antibodies, and the clinical significance and specificity to NHALE of anti-GluR ϵ 2 antibodies is not established. In near future, the specificity, or further pathological mechanism of GluR ϵ 2 NR2B for NHALE should be investigated.

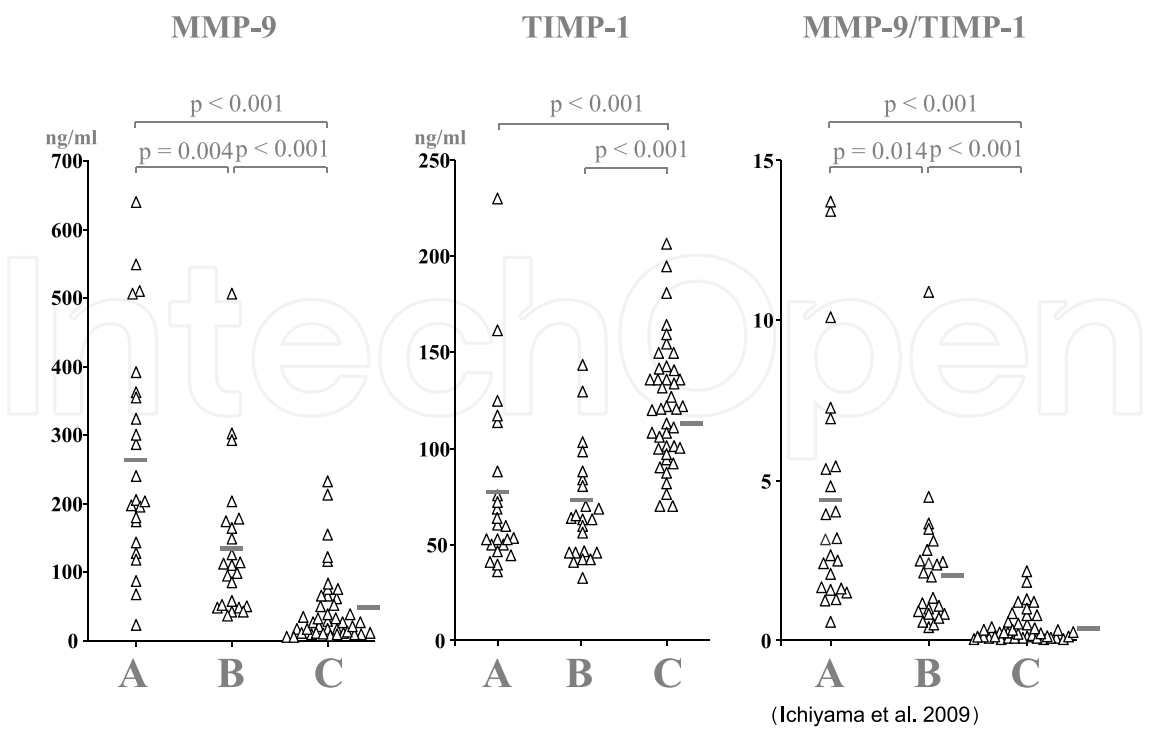


Fig. 5. Serum concentrations of MMP-9 and TIMP-1 and the ratio of MMP-9/TIMP-1 in patients with NHALE and in controls. The high ratio of MMP-9/TIMP-1 continues from the acute to convalescent stages. A: Patients with NHALE in the acute stage, B: patients with NHALE in the convalescent stage, and C: controls. The horizontal lines indicate median values. MMP-9=matrix metalloproteinase-9 , TIMP-1=tissue inhibitor of metalloproteinase 1

4. Clinical characteristics

4.1 Clinical findings

Incidence rate is 4.7 persons per million person-year. Mean onset ages of NHALE show 44.8 years in male and 31.6 years in female, respectively (Wada-Isoe et al., 2008). In response to the limbic system disorder, various symptoms such as changeable disorientation, memory impairment, catalepsy, schizophrenic-like delusions, anger, hallucinations, convulsive seizures, autonomic seizures, pulse rate or respiratory abnormalities, and hyponatremia can appear (Yuasa, 2003). Our Patients 1 & 2 showed restlessness, palpitation and delirious state as initial symptoms. In the acute stage of NHALE, schizophrenic-like symptoms consisting of abnormal behavior, incoherence, delusions, and hallucination are frequently observed, and then convulsive seizures, status epileptics, and autonomic seizures are follows. Meningeal irritation signs appear mildly. Takahashi et al. (2008) analyzed 53 cases of non-paraneoplastic non-herpetic acute limbic encephalitis compared with 16 negative anti-GluR ϵ 2 antibody cases; abnormal behavior, delusions, and hallucination are more frequently observed including autonomic seizures, pyramidal and extrapyramidal signs, and cerebellar symptoms. Status epileptics appeared at 56.5% of the adult cases, and the other complexes partial seizures without convulsive seizure are also described. Prognostic outcome is comparative favorable, and several limited autopsy cases have been reported (Mochizuki et al., 2006). As the complications of NHALE, hypertrophic pachymeningitis or Vogt-Koyanagi-Harada disease has been reported (Usui et al., 2007; Masuda et al., 2009).

4.2 Laboratory findings

PCR and antibody tests including sensitive enzyme-linked immunosorbent assay for herpesvirus groups result in all negative. However, in the serum tests of the adults or elderly patients we may sometimes encounter carrier having HSV positive antibody (Shoji et al., 2004).

CSF shows a mild pleocytosis with increase of pressure, mild increase of protein, and sometimes, a lack of the pleocytosis. The CSF level of IFN- γ is unchanged with an increase of IL-6 (Asaoka et al., 2004; Ichiyama et al., 2008a). Ichiyama et al. (2008a) reported the comparison of CSF cytokines between NHALE and HSE; increases of IFN- γ , IL-6, IL-10, and sTNFR were observed in HSE, whereas only increase of IL-6 was found in NHALE. Brain MRI exhibits often bilateral abnormalities in the limbic areas; abnormal signals distribute in the bilateral hippocampi, amygdalae, rectus, cingulate gyri, and insula. Diffusion weighted images (DWI) is most sensitive to detect the lesions, and the hyperintensity lesions decreased by apparent diffusion coefficient (ADC) (Fig.6). Brain CT is difficult to detect the medial temporal lesions. Also, it should be evaluated that the hyperintensity lesions are apt to appear by DWI as similar lesions after status epilepticus. At the acute stage the inferior horn narrowing is often observed by MRI or CT probably reflecting the brain edema, and at the recovery stage the inferior horn is dilated suggesting the brain atrophy. ^{99m}Tc -ECD using easy z-score imaging system (eZIS) analysis single photon emission CT (SPECT) may reveal wider hypo- or hyper-perfusion lesions than the corresponding MRI lesions in the limbic areas (Fig. 7). Moreover, the hyperintensity lesions on DWI may show relatively increased regional cerebral blood flow (rCBF) on eZIS analysis. EEG reveals whole moderate slowness, and PLEDs or periodic synchronous discharges (PSD) are observed at approximately 20-30% for the acute stage.

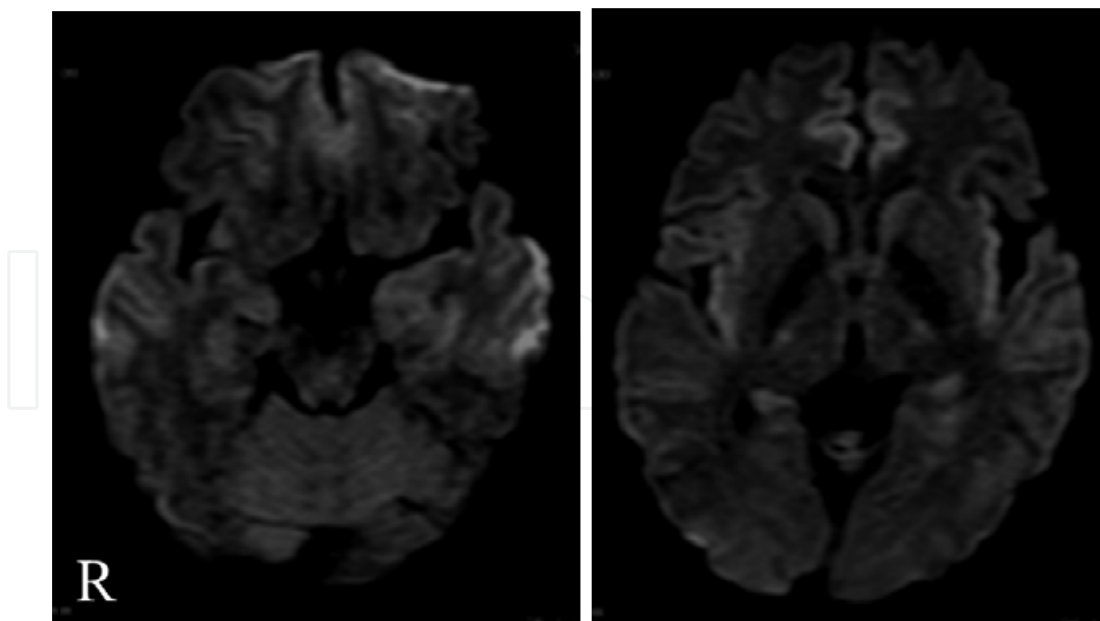


Fig. 6. MRIs of patient with NHALE at the acute stage.

Diffusion-weighted MR images showed hyperintensity lesions in the bilateral medial temporal lobes, cingulate gyri, and insulas.

NHALE=non-herpetic acute limbic encephalitis

4.3 Treatment

There is no standard therapy for NHALE. Most treatment approaches have employed some form of nonspecific immunosuppressant therapy similar to that used for other encephalitis/encephalopathy and autoimmune diseases, including corticosteroid, intravenous immunoglobulin (IVIg), plasmapheresis, or a combination of these therapies. High-dose intravenous steroids are widely accepted as first-line therapy. Most of the data describing treatment for NHALE are derived from case reports and small series. To date, there have been no randomized, controlled trials for the treatment of NHALE. On the other hand, ACV therapy is usually conducted at the acute stage due to difficulty to exclude HSE.

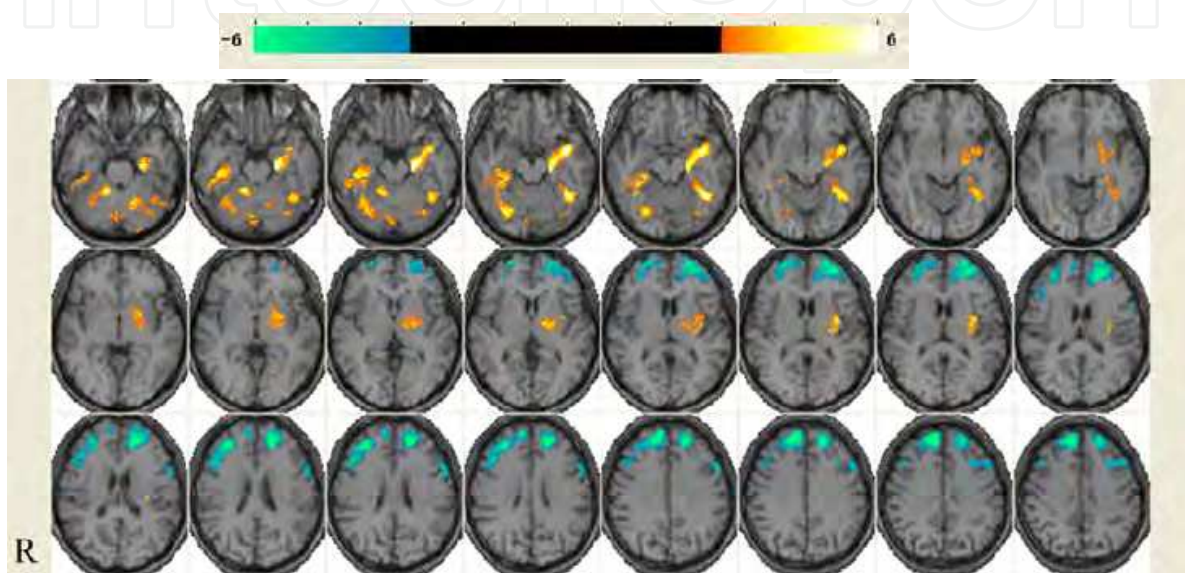


Fig. 7. eZIS images in (axial view) patients with NHALE at acute stage.

The eZIS analysis detected a significantly increased rCBF in the bilateral medial temporal lobes, left insula, and left putamen, and a significantly decreased rCBF in the bilateral frontal lobes. The color images represent the statistical significance (Z-score) of the increase (red) or decrease (blue) in rCBF.

eZIS = easy z-score imaging system, NHALE = non-herpetic acute limbic encephalitis, rCBF = regional cerebral blood flow

4.4 Differential diagnosis

Differential diagnosis with HSE is important in the choice of anti-viral drug starting or immunological therapy. HSE presents a fever, meningeal irritation signs, consciousness impairment, convulsive seizures, and memory impairment, while NHALE shows the onset symptoms with abnormal behavior or talk, and meningeal signs appear mildly. Neuroimaging of HSE often involves predominantly unilateral temporal lobe, but NHALE tends to localize bilateral medial temporal lobes. The CSF findings of NHALE are apt to reveal mild changes. Differentiation between NHALE and NMDAR encephalitis at the initial stage may be difficult, because 25% of NMDAR encephalitis exhibits localized limbic encephalitis form (Iizuka et al., 2008). Therefore, particularly in juvenile female patients with acute encephalitis, ovarian teratoma should be checked rapidly (Kamei S., 2004, 2008). On the other hand, anti-voltage-gated potassium channel (VGKC) antibody limbic encephalitis

shows often encephalopathy type with hyponatremia, and overlaps Morvan syndrome with neuromyotonia. Hashimoto encephalopathy should be noticed to present limbic encephalopathy type, although this encephalopathy usually shows whole encephalitis type.

5. Sequelae

As sequelae, memory impairment, and personality or emotional changes have been most frequently described. Regards with the sequelae of our Patients 1 & 2 at 2 years after the onset, Patient 1 shows prominent impairment for recent memory with intact intelligence and immediate memory. Another Patient 2 presents memory and intelligence impairments, involuntary movement, and paresis in both legs as disuse syndrome. They are still unable to return their previous jobs.

Next, we analyzed the sequelae evaluated in questionnaires from 19 cases of NHALE and 13 cases of anti- NMDAR encephalitis, which was registered for an encephalitis research group of Japanese Ministry of Health & Welfare (Shoji et al., 2010). The Barthel score contains activity of daily living (ADL 0-20), epilepsy (0-4), psychosis (0-2), intelligence (0-4), memory impairment (0-2), and motor function (0-3) were assessed at 3 months and 1 year after the onset. Average ages of the NHALE and anti-NMDAR encephalitis groups were mean ± SD=37.5 ± 17.5 and 29.4 ± 3.2 years, respectively. Male and female ratio was all women in the NMDAR encephalitis. The statistical significance was evaluated using the Wilcoxon test. P values less than 0.10 were considered significant, because of the small case study for both groups.

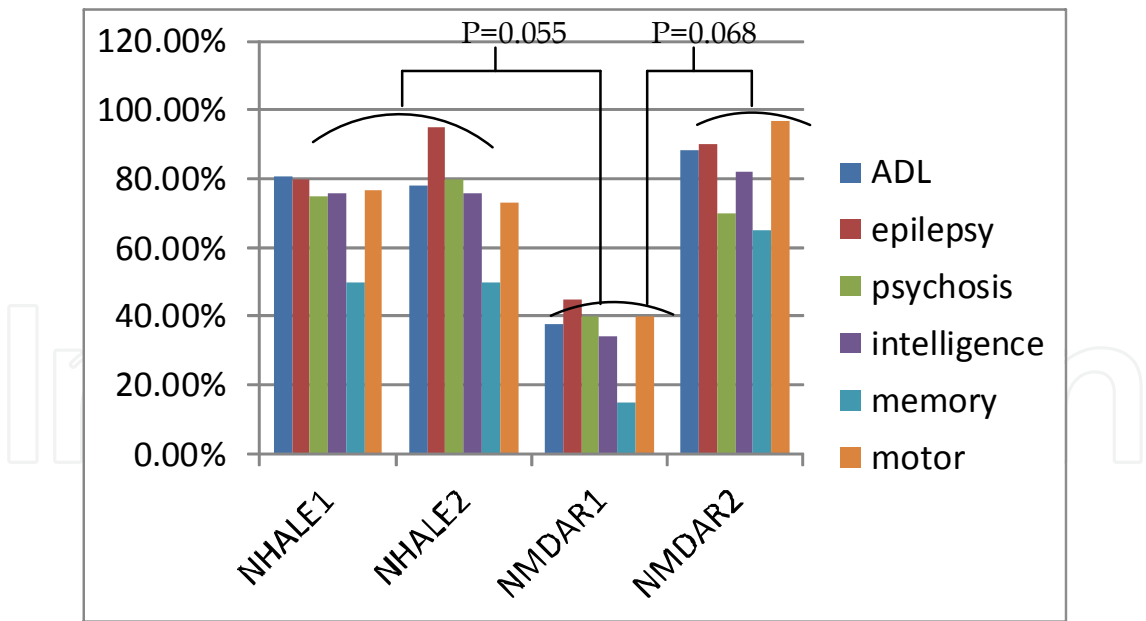


Fig. 8. The comparison of sequelae between NHALE and anti-NMDAR encephalitis (average/full score%).
NHALE1= non-herpetic acute limbic encephalitis; 3 months after the onset, NHALE2=1 year after the onset, NMDAR1=anti- N-methyl-D-asparate receptor encephalitis; 3 months after the onset, NMDAR2=1 year after the onset, ADL=activity of daily living.

In the comparison between NHALE and NMDAR groups at 3 months after onset, in NHALE group memory impairment most frequently involved, while in NMDAR group ADL, intelligence and memory impairments severely disturbed (Fig. 8, $p=0.055$ by Wilcoxon test). These results may suggest that NHALE has a localized limbic lesion with comparative good prognosis, and NMDAR may represent whole brain encephalitis. However, the comparison between 3 months and 1 year after onset in both groups showed significant improvement in NMDAR than NHALE group ($p=0.068$ by Wilcoxon test).

Prognostic outcome of NHALE is relatively favorable compared with HSE. However, many patients with NHALE are unable to return to their jobs because of memory impairments, and personality or emotional changes. Further collaborative investigation for the sequelae of NHALE and related disorders are expected.

6. Conclusion

Etiologies of NHALE consist of various causes, including viral origins, collagen disorders, and several anti-neural antibodies. Among them, anti- GluR ϵ 2 NR2B antibodies were detected. This NHALE type is indicated to form a new subgroup of acute limbic encephalitis or encephalopathy. The NHALE type may be characterized by the onset of abnormal behavior or incoherence, positive anti-GluR ϵ 2 NR2B antibodies, a lack of evidence of the HSV genome or HSV antibody, non-paraneoplastic limbic encephalitis, and MRI abnormalities predominantly in bilateral limbic systems, including hippocampi and amygdalae. CSF shows a mild pleocytosis, and sometimes, a lack of the pleocytosis. The CSF level of IFN- γ is not elevated with an increase of IL-6. The CSF cytokines' profile suggests that the main pathogenesis of NHALE is not caused by the direct invasion of virus into the CNS.


Prognostic outcome is relatively favorable, and differential diagnosis with HSE is important in the choice of anti-viral drug starting or immunological therapy. Furthermore, the specificity and pathological role of GluR ϵ 2 NR2B antibodies for NHALE should be investigated.

7. References

- Asaoka, K.; Shoji, H., Nishizaka, S., Ayabe, M., Abe, T., Ohhori, N., Ichiyama, T. & Eizuru, Y. (2004). Non-herpetic acute limbic encephalitis. *Intern Med* 43. 42-48.
- Dalmau, J.; Turzen. E., Wu, H.Y., Masjuan, J., Voloschin, A., Baehring, J.M., Shimazaki, H., Koide, R., King, D., Mason, W., Sansing, L.H., Dichter, M.A., Rosenfeld, M.R. & D.R. (2007). Paraneoplastic anti-N-methyl-D-aspartate receptor encephalitis associated with ovarian teratoma. *Ann Neurol* 61. 25-36.
- Hayashi, Y.; Matsuyama, Z., Takahashi, Y., Wakida, K., Hashizume, T., Kimura, A., Hozumi, I., Murase, M. & Inuzuka, T. (2005) . A case of non-herpetic acute encephalitis with autoantibodies for ionotropic glutamate receptor delta2 and epsilon2. *Rinshou Shinkeigaku* 45. 657-662.
- Ichiyama, T.; Shoji, H., Kato, M., Sawaishi, Y., Ozawa, H., Matsubara, T. & Furukawa, S. (2002) . Cerebrospinal fluid levels of cytokines and soluble tumor necrosis factor receptor in acute disseminated encephalomyelitis. *Eur J Pediatr* 161. 133-137.

- Ichiyama, T.; Morishima, T., Isumi, H., Matsufuji, H., Matubara, T. & Furukawa, S. (2004). Analysis of cytokine levels and NF- κ B activation in peripheral blood mononuclear cells in influenza virus-associated encephalopathy. *Cytokine* 27. 31-37.
- Ichiyama, T.; Maeba, S., Suenaga, N., Saito, K., Matsubara, T. & Furukawa, S. (2005). Analysis of cytokine levels in cerebrospinal fluid in mumps meningitis: comparison with echovirus type 30 meningitis. *Cytokine* 30. 243-247.
- Ichiyama, T.; Shoji, H., Takahashi, Y., Matsushige, T., Kajimoto, M., Inuzuka, T. & Furukawa, S. (2008a). Cerebrospinal fluid levels of cytokines in non-herpetic acute limbic encephalitis: comparison with herpes simplex encephalitis. *Cytokine* 44.149-153.
- Ichiyama, T.; Suenaga, N., Kajimoto, M., Tohyama, J., Isumi, H., Kubota, M. & Mori, M. & Furukawa, S. (2008b). Serum and CSF levels of cytokines in acute encephalopathy following prolonged febrile seizures. *Brain Dev* 30. 47-52.
- Ichiyama, T.; Takahashi, Y., Matsushige, T., Kajimoto, M., Fukunaga, S. & Furukawa, S. (2009). Serum matrix metalloproteinase-9 and tissue inhibitor of metalloproteinase-1 levels in non-herpetic acute limbic encephalitis. *J Neurol* 256. 1846-1850.
- Iizuka, T.; Sakai, F., Ide, T., Monzen, T., Yoshii, S., Iigaya, M., Suzuki, K., Lynch, D.R., Suzuki, N., Hata, T. & Dalmau, J. (2008). Anti-NMDA receptor encephalitis in Japan: long-term outcome without tumor removal. *Neurology* 70. 504-511.
- Iizuka, T. (2008). Pathophysiology of anti-NMDAR antibody positive limbic encephalitis. *Clin Neurosci* 26. 516-522.
- Kai, T.; Wada-Isoe, K., Nakashima, K. & Takahashi, Y. (2009). Clinically mild encephalitis/encephalopathy with a reversible splenial lesion(MERS) with anti-glutamate receptor antibody. A case report. *Shinkeinaika* 71. 397-401.
- Kaji, M.; Kusuhara, T., Ayabe, M., Hino, H., Shoji, H. & Nagao, T. (1996). Survey of herpes simplex virus infections of the central nervous system, including acute disseminated encephalomyelitis, in the Kyushu and Okinawa regions of Japan. *Mult Scler* 2. 83-87.
- Kamei, S. (2004). Acute juvenile female non-herpetic encephalitis. *Adv neurol Sci* 48. 827-836.
- Kamei, S.; Kuzuhara, S., Ishihara, M., Morita, A., Taira, N., Togo, M., Matsui, M., Ogawa, M., Hisanaga, K., Mizutani, T. & Kuno, S. (2009). Nationwide survey of acute juvenile female non-herpetic encephalitis in Japan: relationship to anti-N-methyl-D-aspartate receptor encephalitis. *Intern Med* 48. 673-679.
- Kusuhara, T.; Shoji, H., Kaji, M., Ayabe, M. & Hino, H. (1994). Non-herpetic acute limbic encephalitis. *Rinshou Shinkeigaku* 34. 1083-1088.
- Maki, T.; Kokubo, Y., Nishida, S., Suzuki, H. & Kuzuhara, S. (2008). An autopsy case with non-herpetic acute limbic encephalitis (NHALE). *Neuropathology* 28. 521-525.
- Masuda, T., Kimura, N., Ishibashi, M., Ito, M., Takahashi, Y. & Kumamoto, T. (2009). A case of Vogt-Koyanagi-Harada disease associated with non-herpetic acute limbic encephalitis with autoantibodies against glutamate receptor epsilon2 in the cerebrospinal fluid. *Rinshou Shinkeigaku* 49. 483-487.
- Matsubara, T.; Matsuoka, T., Katayama, K., Yoshitomi, T., Nishikawa, M., Ichiyama, T. & Furukawa, S. (2000) Mononuclear cells and cytokines in the cerebrospinal fluid of echovirus 30 meningitis patients. *Scand J Infect Dis* 32. 471-474.
- Mochizuki, Y.; Mizutani, T., Isozaki, E., Ohtake, T. & Takahashi, Y. (2006). Acute limbic encephalitis: a new entity? *Neurosci Lett* 394. 5-8.

- Nemoto, H.; Takahashi, Y. & Yuasa, T. (2005). Autoantibody mediated acute reversible Limbic encephalitis (AMED-ARLE). *Neuroinfection* 1. 44-46.
- Noto, Y.; Mori, S., Kawakami, O., Yamada, K. & Takahashi, Y. (2008). A patient with non-herpetic limbic encephalitis followed-up using MRI. *Shinkeinaika* 68. 378-382.
- Okamoto, K.; Yamazaki, T., Banno, H., Sobue, G., Yoshida, M. & Takatama, M. (2008). Neuropathological studies of patients with possible non-herpetic acute limbic encephalitis and so-called acute juvenile female non-herpetic encephalitis. *Intern Med* 47. 231-236.
- Sakuma, H.; (2009). Acute encephalitis with refractory, repetitive partial seizures. *Brain Dev* 31. 510-514.
- Samuel, C.E.; (1991). Antiviral actions of interferon. Interferon-regulated cellular proteins and their surprisingly selective antiviral activities. *Virology* 183. 1-11.
- Shiraishi, M.; Ichiyama, T., Matsushige, T., Iwaki, T., Iyoda, K., Fukuda, K., Makata, H., Matsubara, T. & Furukawa, S. (2008) Soluble tumor necrosis factor receptor 1 and tissue inhibitor of metalloproteinase-1 in hemolytic uremic syndrome with encephalopathy. *J Neuroimmunol* 196. 147-152.
- Shoji, H.; Asaoka, K., Ayabe, M., Ichiyama, T. & Sakai, K. (2004). Non-herpetic acute limbic encephalitis: a new subgroup of limbic encephalitis? *Intern Med* 43. 348.
- Shoji, H.; Hazama, K., Tanaka, R., Koike, F., Nakahara, K., Utsunomia, H., Tabata, E., Eriguchi, M. & Takahashi, Y. (2009). A study of sequelae in non-herpetic acute limbic encephalitis. *Bulletin of the Fukuoka School of Rehabilitation Sciences & Fukuoka School of Nursing International University of Health & Welfare* 6. 7-12.
- Shoji, H.; Tamekazu, T., Kaneko, M., Muraoka, N., Koike, F., Tabata, E. & Takahashi, Y. (2010). A study of sequelae in non-herpetic acute limbic encephalitis and related disorders. *Bulletin of the Fukuoka School of Rehabilitation Sciences & Fukuoka School of Nursing International University of Health & Welfare* 6. 7-12.
- Takahashi, Y., Mori, H., Mishima, M., Watanabe, M., Fujiwara, T., Shimomura, J., Aiba, H., Miyajima, T., Saito Y, Nezu A, Nishida H, Imai K, Sakaguchi, N. & Kondo N. (2003). Autoantibodies to NMDA receptor in patients with chronic forms of epilepsy partialis continua. *Neurology* 61.891-896.
- Takahashi Y., Mori, H., Mishima, M., Watanabe, M., Kondo, N., Watanabe, M., Kondo, N., Shimomura, J., Kubota, Y., Matsuda, K., Fukushima, K., Shiroma, N., Akasaka, N., Nishida, H., Imamura, A., Watanabe, H., Sugiyama, N., Ikezawa, M. & Fujiwara, T. (2005):Autoantibodies and cell-mediated autoimmunity to NMDA-type GluR ϵ 2 in patients with Rasmussen's encephalitis and chronic progressive epilepsy partialis continua. *Epilepsia* 46 (Suppl 5). 152-158.
- Takahashi, Y., Yamasaki, E., Kubota, Y., Nishimura, S., Tsunogae, H., Ikeda, H., Takahashi, H., Mine, J., Otani, S. & Fujiwara, T. (2007). Autoantibodies against glutamate receptors in patients with encephalitis. *Rinshou Shinkeigaku* 47. 848-851.
- Takahashi, Y., Mogami, Y., Takayama, R., Ikeda, H. & Imai, K. (2010). Antibodies to glutamate receptorin limbic encephalitis. *Brain Nerve* 62. 827-837.
- Usui, T., Nishizawa, E. & Tei, H. (2007). Nonherpetic acute limbic encephalitis with hypertrophic pachymeningitis. A case report. *Shinkeinaika* 66. 464-468.
- Wada-Isoe, K., Kusumi, M., Kai, T., Awaki, E., Shimoda, M., Yano, H., Suzuki, K., Nakayasu, H., Oota, K., Kowa, H. & Nakashima, K. (2008). Epidemiological study of acute encephalitis in Tottori Prefecture, Japan. *Eur J Neurol* 15. 1075-1079.



Pathogenesis of Encephalitis

Edited by Dr. Daisuke Hayasaka

ISBN 978-953-307-741-3

Hard cover, 344 pages

Publisher InTech

Published online 09, December, 2011

Published in print edition December, 2011

Many infectious agents, such as viruses, bacteria, and parasites, can cause inflammation of the central nervous system (CNS). Encephalitis is an inflammation of the brain parenchyma, which may result in a more advanced and serious disease meningoencephalitis. To establish accurate diagnosis and develop effective vaccines and drugs to overcome this disease, it is important to understand and elucidate the mechanism of its pathogenesis. This book, which is divided into four sections, provides comprehensive commentaries on encephalitis. The first section (6 chapters) covers diagnosis and clinical symptoms of encephalitis with some neurological disorders. The second section (5 chapters) reviews some virus infections with the outlines of inflammatory and chemokine responses. The third section (7 chapters) deals with the non-viral causative agents of encephalitis. The last section (4 chapters) discusses the experimental model of encephalitis. The different chapters of this book provide valuable and important information not only to the researchers, but also to the physician and health care workers.

How to reference

In order to correctly reference this scholarly work, feel free to copy and paste the following:

Hiroshi Shoji, Noriyuki Kimura, Toshihide Kumamoto, Takashi Ichiyama and Yukitoshi Takahashi (2011). Non-Herpetic Acute Limbic Encephalitis: A New Subgroup of Limbic Encephalitis?, Pathogenesis of Encephalitis, Dr. Daisuke Hayasaka (Ed.), ISBN: 978-953-307-741-3, InTech, Available from:
<http://www.intechopen.com/books/pathogenesis-of-encephalitis/non-herpetic-acute-limbic-encephalitis-a-new-subgroup-of-limbic-encephalitis->

INTech
open science | open minds

InTech Europe

University Campus STeP Ri
Slavka Krautzeka 83/A
51000 Rijeka, Croatia
Phone: +385 (51) 770 447
Fax: +385 (51) 686 166
www.intechopen.com

InTech China

Unit 405, Office Block, Hotel Equatorial Shanghai
No.65, Yan An Road (West), Shanghai, 200040, China
中国上海市延安西路65号上海国际贵都大饭店办公楼405单元
Phone: +86-21-62489820
Fax: +86-21-62489821

© 2011 The Author(s). Licensee IntechOpen. This is an open access article distributed under the terms of the [Creative Commons Attribution 3.0 License](https://creativecommons.org/licenses/by/3.0/), which permits unrestricted use, distribution, and reproduction in any medium, provided the original work is properly cited.

IntechOpen

IntechOpen