

We are IntechOpen, the world's leading publisher of Open Access books Built by scientists, for scientists

6,900

Open access books available

186,000

International authors and editors

200M

Downloads

Our authors are among the

154

Countries delivered to

TOP 1%

most cited scientists

12.2%

Contributors from top 500 universities



WEB OF SCIENCE™

Selection of our books indexed in the Book Citation Index
in Web of Science™ Core Collection (BKCI)

Interested in publishing with us?
Contact book.department@intechopen.com

Numbers displayed above are based on latest data collected.
For more information visit www.intechopen.com



Rasmussen's Encephalitis: An Overview

Mayowa Owolabi
University of Ibadan
Nigeria

1. Introduction

Epilepsia partialis continua (EPC) resulting from localized encephalitis was first described by Kozhevnikov and Brun in 1895 in patients suffering from Russian spring-summer encephalitis. (Bien et al., 2005b) In 1958, Rasmussen described a syndrome of focal seizures due to chronic localized encephalitis in three cases. The heterogeneity of this syndrome was demonstrated by Oguni in a description of 48 cases in 1991 among which 80% had focal motor seizures of which 50% were continuous. (Oguni et al., 1991) The syndrome occurred predominantly in children who had hemiparesis and cortical signs. (Oguni et al., 1991) Even though a diagnostic criteria has been proposed (Bien et al., 2005b), the aetio-pathogenesis remains unresolved.

Rasmussen's encephalitis (RE) is a rare neurological disease of childhood characterized by unilateral hemispheric atrophy, focal intractable seizures, and progressive neurological deficits. The affected brain tissue shows a chronic inflammatory histopathology and an autoimmune reaction is suspected. Therapeutic strategies include anticonvulsants, immunomodulation and surgery. (Bien et al., 2005b) This review covers the natural history, aetiopathogenesis, clinical features, diagnosis, and treatment of RE.

2. RE by Theodore Rasmussen

Rasmussen et al presented a clinico-pathologic report of three children suffering from a chronic illness, producing focal seizures and gradually producing severe damage to one cerebral hemisphere. (Rasmussen et al., 1958) Occasional specimens of scarred, atrophic brain removed for the treatment of focal cerebral seizures at the Montreal Neurological Institute showed striking perivascular collections of round cells, particularly in less severely damaged areas of the specimens. Rasmussen observed that in the past this perivascular cuffing was attributed to the effect on the brain of recurring seizures. He inferred, however, that this was a rather unsatisfactory explanation since the great majority of surgical specimens removed from patients with equally frequent focal seizures did not show this change. (Rasmussen et al., 1958) He suggested that this microscopic picture may indicate the presence of an unsuspected, more or less localized, chronic encephalitis that had smoldered along over a period of years. (Rasmussen et al., 1958)

He opined that suggestions for therapy in the active phase of the disease, when it might be possible to prevent destruction of brain tissue, must await determination of etiologic factors. (Rasmussen et al., 1958)

Rasmussen speculated regarding the ability of some dormant viruses in the nervous system to be pertinent to the problem. He reasoned that localization of the lesions and their character are more consistent with viral encephalitis than with postinfectious perivenous encephalitis or with allergic encephalitis. He concluded that the histological appearance in each instance suggested chronic focal encephalitis of unknown cause which manifested with focal epilepsy. (Rasmussen et al., 1958)

3. Aetio-pathogenesis and pathology of RE

RE is a rare disease that should be envisaged as sporadic, since there is no evidence for a genetic component. There is, at present, no conclusive evidence why and how RE starts.

3.1 Is RE an epileptic encephalopathy?

In analogy to other conditions of childhood epilepsies with progressive neurological deterioration, it has been suggested that in RE, the epileptic activity itself may contribute to the functional decline. (Bien et al., 2005b) This is because focal motor deficit usually follows the onset of epilepsy and its severity seems to mirror the intensity of the seizure activity (Bien et al., 2005b; Chinchilla et al., 1994). Steroids given early in the course of the disease are able to reduce the severity of the deficit, when seizure activity is brought under control. The response to steroids may suggest that an inflammatory process underlies the manifestation with seizures and neurological deficit. Because for any inflammatory process, the immune effector cells or antibodies originate from the blood stream, the encephalitis is expected to be bilateral. Thus focal epilepsy has been postulated as the reason for the unilaterality of the encephalitis. (Bien et al., 2005b) It has been suggested that focal seizures may damage the blood brain barrier allowing autoantibodies to cross the it thus causing unilateral brain damage. (Bien et al., 2005b)

However, while seizures may lead to reversible Todd's palsy probably due to neuronal exhaustion, there is no conclusive evidence yet that seizures on their own cause or precede encephalitis. (Rasmussen et al., 1958) Rasmussen reiterated that the great majority of surgical specimens removed from patients with equally frequent focal seizures did not show features of focal encephalitis. (Rasmussen et al., 1958) Furthermore, unilaterality is not a constant finding in RE, and the progressive atrophy and epileptiform processes may progressively involve the other hemisphere. (Bien et al., 2005b) The fact that the seizure is originally focal could not be the basis for focal encephalitis. Rather focal seizures could be a manifestation of focal encephalitis. The effect cannot precede the cause. Therefore asymmetry of the pathogenic process may be responsible for focal seizures and focal neurological deficits. This is corroborated by reports of cases with hemiparesis and focal encephalitis preceding seizures. (Korn-Lubetzki et al., 2004)

The factors responsible for the asymmetry remain unravelled. Nevertheless, the evidence for immunologic mechanisms is growing although the antigenic stimulus remains obscure.

3.2 Role of CD-8 cells

Unilateral encephalitis, an intriguing feature of RE, distinguishes it from any other inflammatory disease of the CNS. Histopathological findings in RE comprise lymphocytic infiltrates, microglial nodules, neuronal and astrocytic loss, and gliosis of the affected hemisphere. (Farrell et al., 1992; Robitaille, 1991) Destruction of neurons and astrocytes by

cytotoxic CD8 T cells has been proposed as a pathogenic mechanism underlying RE. (Schwab et al., 2009)

Active brain inflammatory lesions contain large numbers of T lymphocytes, which are recruited early within the lesions suggesting that a T cell dependent immune response contributes to the onset and evolution of the disease (Farrell et al., 1992; Schwab et al., 2009). Moreover, the histopathological observation of granzyme B-containing CD8+ T cells in direct apposition to MHC class I positive neurons raised the hypothesis of a CD8+ T cells-mediated neuronal attack as a key pathogenetic mechanism underlying RE. (Bien et al., 2005b; Bien et al., 2002a; Bien et al., 2002c; Bien et al., 2005a; Schwab et al., 2009) Apart from neuronal cell death, CD8 cells may also be responsible for the degeneration of astrocytes found in RE lesions. (Bauer et al., 2002; Bauer et al., 2007)

The antigens of these brain-infiltrating lymphocytes are still unknown. It is not even clear yet, whether the CNS-directed T-cell response (TCR) is focused towards particular antigens. Experimentally, this could be proven by demonstrating that individual clones are expanded in the tissue. (Bien et al., 2005b)

In a longitudinal analysis of TCR in RE, severe perturbations of the TCR repertoire were found in brain infiltrates from all specimens, while clonal expansions, as evidenced by peripheral blood analysis, belonged to the CD8+ T-cell subset. In line with previous findings, histochemical analysis of the brain lesions showed Vb specific T cells containing the cytotoxic molecule granzyme B and lying in close appositions to NeuN+ neurons and GFAP+ astrocytes. (Bauer et al., 2002; Bauer et al., 2007; Bien et al., 2002b; Bien et al., 2002a; Bien et al., 2005a) Analysis of corresponding CNS/blood specimens revealed overlapping but also CNS-restricted expansions of certain TCR clonotypes suggesting expansions of T cells within the target organ itself. (Bauer et al., 2002; Bauer et al., 2007; Bien et al., 2002b; Bien et al., 2002a; Bien et al., 2005a)

Longitudinal analysis of peripheral blood samples demonstrated dominance but also longitudinal persistence of specific CD8 T-cell clones over time. The Vb/Jb usage, length of the CDR3, and biochemical characteristics of the CDR3 amino acids suggested high similarities putatively related to common driving antigen(s) without shared clones. In conclusion, the data strongly support the hypothesis of an antigen-driven MHC class-I restricted, CD8+ T cell-mediated attack against neurons and astrocytes in the CNS dominating the pathogenesis in RE in contrast to a random attraction of cells as part of a secondary immune response. (Schwab et al., 2009)

This process may persist for at least 1 to 2 years. (Schwab et al., 2009) The long-term persistence (or re-occurrence) of putatively pathogenic T-cell clones despite therapy (or even immunoablation) may indicate an ongoing exposure of the immune system to the antigenic trigger. This trigger (autoantigen or virus) could very well reside within the CNS. The finding of identical TCR clones between the CNS and peripheral blood compartment in patients with matching CNS-blood samples is in line with this assumption. However, because this was a small-scale study, further research is required to validate the hypothesis.

3.3 Glu-R3 autoantibodies

Autoantibodies against glutamate receptors (GluR3 and NR2B), first reported in Rasmussen encephalitis, have been observed in other focal epilepsies, central nervous system ischemic infarcts, transient ischemic attacks, sporadic olivopontocerebellar atrophy, systemic lupus erythematosus, and paraneoplastic encephalopathies. (Pleasure, 2008)

Furthermore, the hypothesis of RE as a primarily antibody-driven attack against neuronal structures [e.g. the glutamate receptor GluR3 could not be confirmed in larger cohorts (Bien et al., 2005b). Thus the detection of glutamate receptor autoantibodies is not useful in the evaluation of Rasmussen encephalitis. (Pleasure, 2008)

This does not exclude that other humoral mechanisms may contribute to the pathogenesis of RE. Future antibody research in RE will probably concentrate on detecting possibly pathogenic antibodies other than glutamate receptor antibodies. (Bien et al., 2005b; Pleasure, 2008)

3.4 Pathological features

The precise nature and sequence of the pathogenetically relevant processes remain controversial. It is unclear if a uniform process exists in all stages of the disease in all RE patients. (Bien et al., 2005b; Pleasure, 2008)

The histopathological properties of RE have been described in several studies. (Bien et al., 2005b; Bien et al., 2002b; Bien et al., 2002c) Using standard histochemical staining techniques, four stages corresponding to disease duration have been proposed. **Group 1** (earliest phase) is characterized by inflammation with numerous microglial nodules, with or without neuronophagia, perivascular round cells and glial scarring. **Group 2** reveals several microglial nodules, cuffs of perivascular round cells, and at least one gyral segment of complete necrosis. **Group 3** shows neuronal loss and gliosis with moderately abundant perivascular round cells and few microglial nodules. Finally, **group 4** (last phase) displays no or few microglial nodules, neuronal loss and mild perivascular inflammation, combined with various degrees of gliosis and glial scarring. (Bien et al., 2005b; Bien et al., 2002b; Bien et al., 2002c; Robitaille, 1991)

The round cell infiltrates in RE brains consist almost exclusively of T lymphocytes. Using a quantitative histopathological immunohistochemical approach, it has been demonstrated that densities of T cells, microglial nodules and activated astrocytes are inversely correlated with disease duration. Furthermore, the immunohistochemical observations showed that the majority of the T cells are CD8+ containing GrB+ granules. A proportion of them laid in apposition to neurons. These neurons were positive for MHC class I. A few neurons were found to die by apoptosis. These findings were interpreted as evidence for a cytotoxic T cell reaction against neurons. (Bien et al., 2005b; Bien et al., 2002b; Bien et al., 2002c; Robitaille, 1991)

Another diagnostically relevant observation was that <5% of the CD68+HLADR + cells had macrophage morphology (the remainder had microglial morphology). In addition, CD20+ cells (B cells) and CD138+ cells (plasma cells) are extremely rare and signs of immunoglobulin deposits or activated complement were not found. (Bien et al., 2005b; Bien et al., 2002b; Bien et al., 2002c)

A viral aetiology was already suggested by Rasmussen based on the constituents of the immune reaction in the brains such as lymphocyte infiltration and microglial nodules (Rasmussen et al., 1958). The similarities of RE and Russian spring summer meningoencephalitis, which is caused by a flavivirus, further supported this hypothesis. (Bien et al., 2005b) However, so far all attempts to identify a pathogenic viral agent have been contradictory and inconclusive. Bien Inclusion bodies suggestive of a viral infection have not been observed in RE. (Bien et al., 2005b)

Available data continue to suggest a T cell-led immune basis to the pathogenesis of RE. However, the antigenic basis is still obscure. Serial examinations in the early phase of the disease might be important in identifying this group of patients, so that more detailed study

of possible etiologic factors might be made before the fire has burned out and only the scarred evidence of earlier damage remains. (Rasmussen et al., 1958)

4. Clinical features

4.1 Natural history and evolution

Although reported cohorts of individuals with RE are not large, three stages have been proposed. (Bien et al., 2005b; Bien et al., 2002c; Bien et al., 2002d). The average age at presentation is 6 years of age. (Bien et al., 2005b; Bien et al., 2002c; Oguni et al., 1991) In about two-thirds of patients, RE may commence in some patients with a non-specific '**prodromal stage**' manifesting with a relatively low seizure frequency and rarely mild hemiparesis with a median duration of 7.1 months (range: 0 months to 8.1 years). (Bien et al., 2005b; Bien et al., 2002c; Bien et al., 2002d; Oguni et al., 1991)

All patients enter an '**acute stage**' of the disease characterized by frequent seizures, mostly simple partial motor seizures often in the form of *epilepsia partialis continua* (EPC). The neurological deterioration becomes manifest by progressive hemiparesis, hemianopia, cognitive deterioration and, if the dominant hemisphere is affected, aphasia. (Bien et al., 2005b; Bien et al., 2002c; Oguni et al., 1991) The median duration of this stage is 8 months (range 4–8 months). (Bien et al., 2005b; Bien et al., 2002c; Oguni et al., 1991)

The final stage is the '**residual stage**' with permanent and stable neurological deficits and still many seizures, although less frequent than in the acute stage. At this stage, not all the patients are hemiplegic. (Bien et al., 2005b; Bien et al., 2002c; Oguni et al., 1991)

The wide time ranges for the duration of the disease stages indicate the high variability of severity and speed of the destructive process in different patients. For clinical monitoring of the progression, hemiparesis is the most useful marker as this feature is most consistently found, and it allows quantitative evaluation, even in children. (Bien et al., 2005b; Bien et al., 2002c; Oguni et al., 1991) Assessment of degree of hemiparesis is best done in periods with low frequency of seizures, because it can be increased by additional transient postictal paresis in cases with motor seizures. In addition, periodic assessment of neuropsychological performance is recommended in order to detect cognitive decline, especially in cases without overt hemiparesis, such as those of temporal lobe origin. (Bien et al., 2005b; Hennessy et al., 2001)

Monitoring can also be done using the hemispheric ratio on neuroimages.

4.2 Characteristics of the seizures in RE

Epilepsy in RE patients is characterized by the polymorphism of seizures in a given patient; the frequent occurrence of EPC; and the medical intractability of seizures, particularly of EPC. (Bien et al., 2005b) The different semiologies of seizures, often noted on longitudinal evaluation of patient records, is best explained as a 'march (of the epileptic focus) across the hemisphere'. (Oguni et al., 1991) Supportive findings have been made by serial neuroimaging studies. However, apart from the rare cases of bilateral RE, all seizures originate in one hemisphere. (Bien et al., 2005b)

Simple partial motor seizures involving one side of the body are the most common (77% of cases), followed by secondarily generalized tonic clonic seizures (42%), complex partial seizures (19% with automatisms and 31% with subsequent unilateral motor involvement), postural seizures probably originating in the supplementary motor region (24%) and somatosensory seizures (21%) (Oguni et al., 1991). EPC has been reported to occur in 56–92%

of patients at some time during their disease course EPC was originally described in Russian adults suffering from Russian springsummer encephalitis and has subsequently caused extensive discussions regarding its nature and origin. EPC is most commonly viewed as cortical and epileptic.

4.3 Possible variants of RE

In contrast to the classical features mentioned above, certain clinical variants of RE exist.

4.3.1 RE with delayed seizure onset

Patients with progressive hemiparesis and biopsy evidence of RE followed by unilaterally generated seizures only after several months have been reported. (Korn-Lubetzki et al., 2004).

4.3.2 RE with movement disorder

Unilateral basal ganglia involvement (usually the caudate nucleus) has been reported to present with features of hemidystonia and hemiathetosis in addition to EPC. (Bhatjiwale et al., 1998; Bien et al., 2005b)

4.3.3 Localised form

Mild and non-progressive phenotypes of the disease have been reported with childhood or late-onset chronic focal encephalitis, dominated by partial seizures with mild focal motor deficit and choreo-dystonic movements. (Gambardella et al., 2008)

4.3.4 Bilateral cases

The term 'bilateral RE' should be reserved for cases with inflammatory lesions in both hemispheres. Although several clinical and electrophysiological features have suggested bilateral cerebral involvement in many cases (e.g. secondary spread of focal seizures to the contralateral side, interictal epileptiform abnormalities on the contralateral side, or mild contralateral atrophy). (Andermann et al., 2006; Bien et al., 2005b; Hart, 2004) True bilateral RE is very rare.

There is no evidence for an inherent tendency of RE to spread to the contralateral side after longstanding disease. Furthermore with over 10 years follow-up: no case of RE initially cured by surgery from the epilepsy point of view exhibited delayed relapse on the contralateral side, even when the affected hemisphere was not removed but purely disconnected. (Bien et al., 2005b; Delalande et al., 2004)

4.3.5 Late-onset RE

Although RE is generally considered as a childhood disease, adolescent and adult patients have been described and may account for about 10% of all RE cases. (Bien et al., 2005b) The oldest patient reported so far was 58-years-old. (Hunter et al., 2006)

While adult-onset Rasmussen's syndrome may mimic the early-onset form, symptoms often progress more slowly and the neurological defect is more variable. They appear to have a more protracted and milder clinical course with less residual functional deficits and lower degrees of hemiatrophy and more frequent occipital lobe seizure onset (Bien et al., 2005b; Hart et al., 1997), but identical histopathological as well as clinical, electrophysiological and neuroimaging findings. (Bien et al., 2005b)

Some atypical features may be noted such as bilateral hemispheric involvement or a picture of temporal lobe epilepsy or the presence of movement disorders at the beginning of the disease. Surgical hemispheric disconnection that appears the most effective treatment in children to improve seizure control is not indicated in adults for evident functional reasons. Based on recent pathogenic concepts, different medical treatments may be proposed. Large multicentre controlled studies are mandatory to define a clear medical therapeutic strategy in these cases of adult-onset. (Jaillon-Riviere et al., 2007)

4.3.6 RE with unilateral brainstem encephalitis

The case of an adult woman with Rasmussen encephalitis with brainstem involvement responsive to immunosuppression is reported. (Quesada et al., 2007)

4.3.7 RE with neurological comorbidity

Cases with double cranial pathology (RE plus low grade tumour, cortical dysplasia, tuberous sclerosis, vascular abnormalities or old ischaemic lesions) have been described. (Bien et al., 2005b; Hart et al., 1998) In the Montreal series, about 10% of cases had double pathology. (Bien et al., 2005b; Hart et al., 1998) The diagnosis of dual pathology was suspected based on MRI findings and confirmed by histopathology (biopsy or resective epilepsy surgery).

5. Investigations

5.1 EEG features

As early as 4 months after disease onset, EEG shows polymorphic delta waves over the affected hemisphere, mainly in a temporal and central location (Figure 1). (Bien et al., 2005b; Hart et al., 1998; Owolabi et al., 2008) This may be accompanied by epileptiform abnormalities, which may evolve into (subclinical) ictal EEG patterns. During the disease course, in most cases, contralateral asynchronous slow waves and epileptiform discharges occur. However, ictal patterns are rarely recorded from contralateral electrodes. As in other conditions, EPC in RE is not always accompanied by rhythmic EEG discharges on surface EEG. (Bien et al., 2005b)

Thus EEG may contribute to the tentative diagnosis of RE already in early disease stages. The following unihemispheric findings strongly suggest RE: impairment of background activity and sleep spindles; focal slow activity; multifocal ictal discharges; and subclinical ictal discharges. In cases with the secure diagnosis of RE, the documentation of an independent contralateral seizure onset may raise the suspicion of bilateral disease. (Bien et al., 2005b)

5.2 Radiological features

5.2.1 CT and MRI

Rarely, CT and MRI may be normal on very early scans. (Bien et al., 2005b; Bien et al., 2002c; Bien et al., 2002d) Within the first 4 months after disease onset, the majority of patients exhibit unilateral enlargement of the inner and outer CSF compartments, most accentuated in the insular and periinsular regions, with increased cortical or subcortical (or both) T2 (and FLAIR) signal (Figures 2 and 3). In addition, in most cases, there is atrophy of the ipsilateral head of the caudate nucleus.

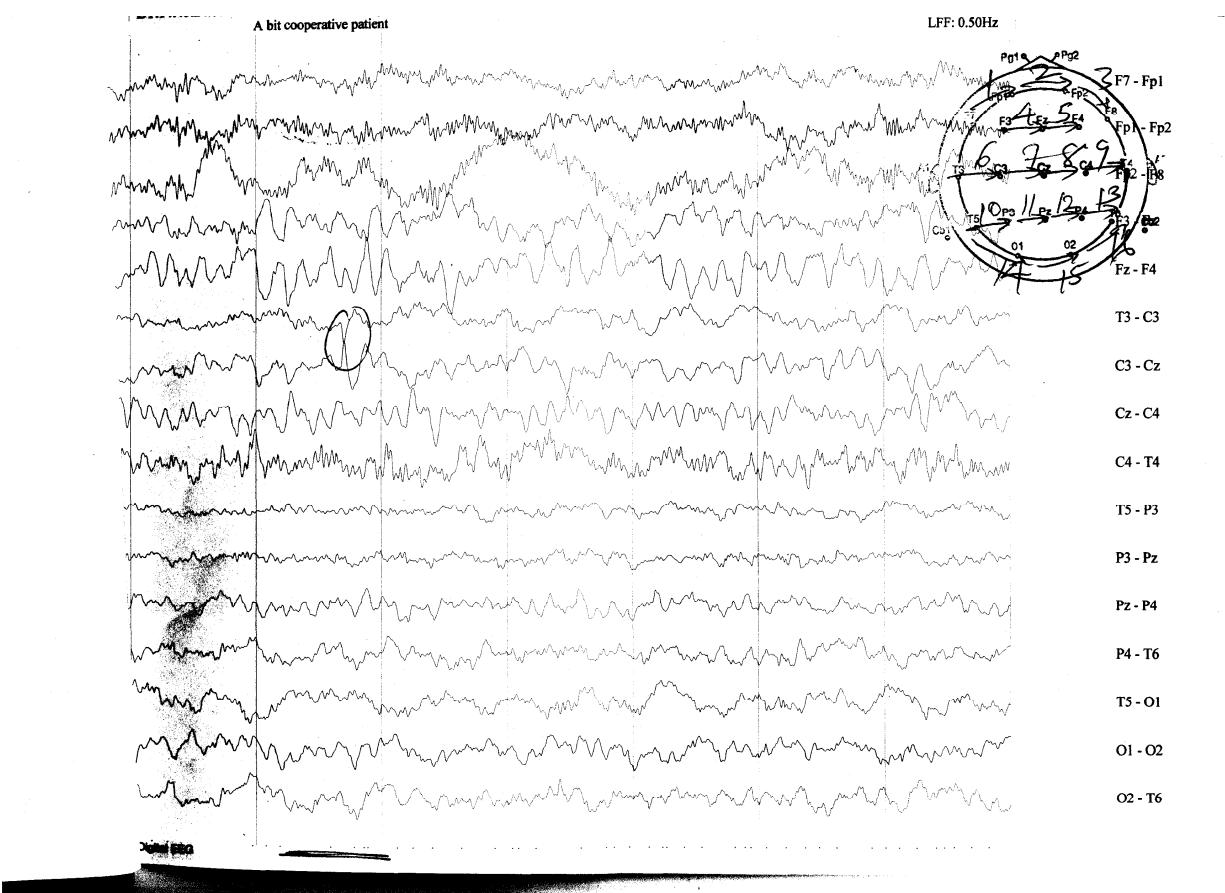


Fig. 1. EEG features in a young girl with RE (Owolabi et al., 2008)
Theta and delta waves on the left hemisphere with epileptiform sharp and slow wave complexes and phase reversal pattern. These features predominated in the temporo-central region. No evidence of secondary generalization.

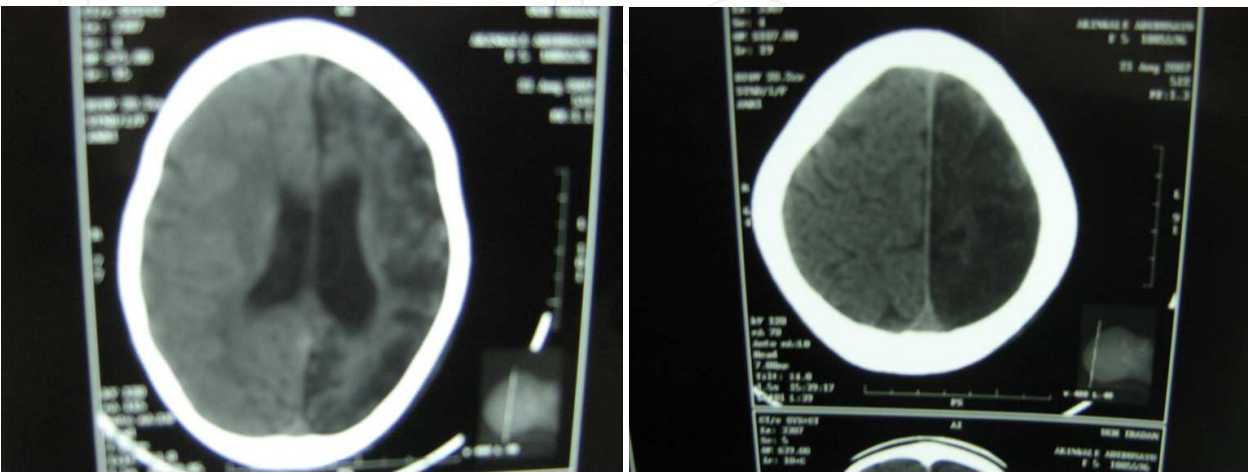


Fig. 2. Cranial CT scan
Isolated left hemispheric atrophy with non-enhancing hypodense lesions.

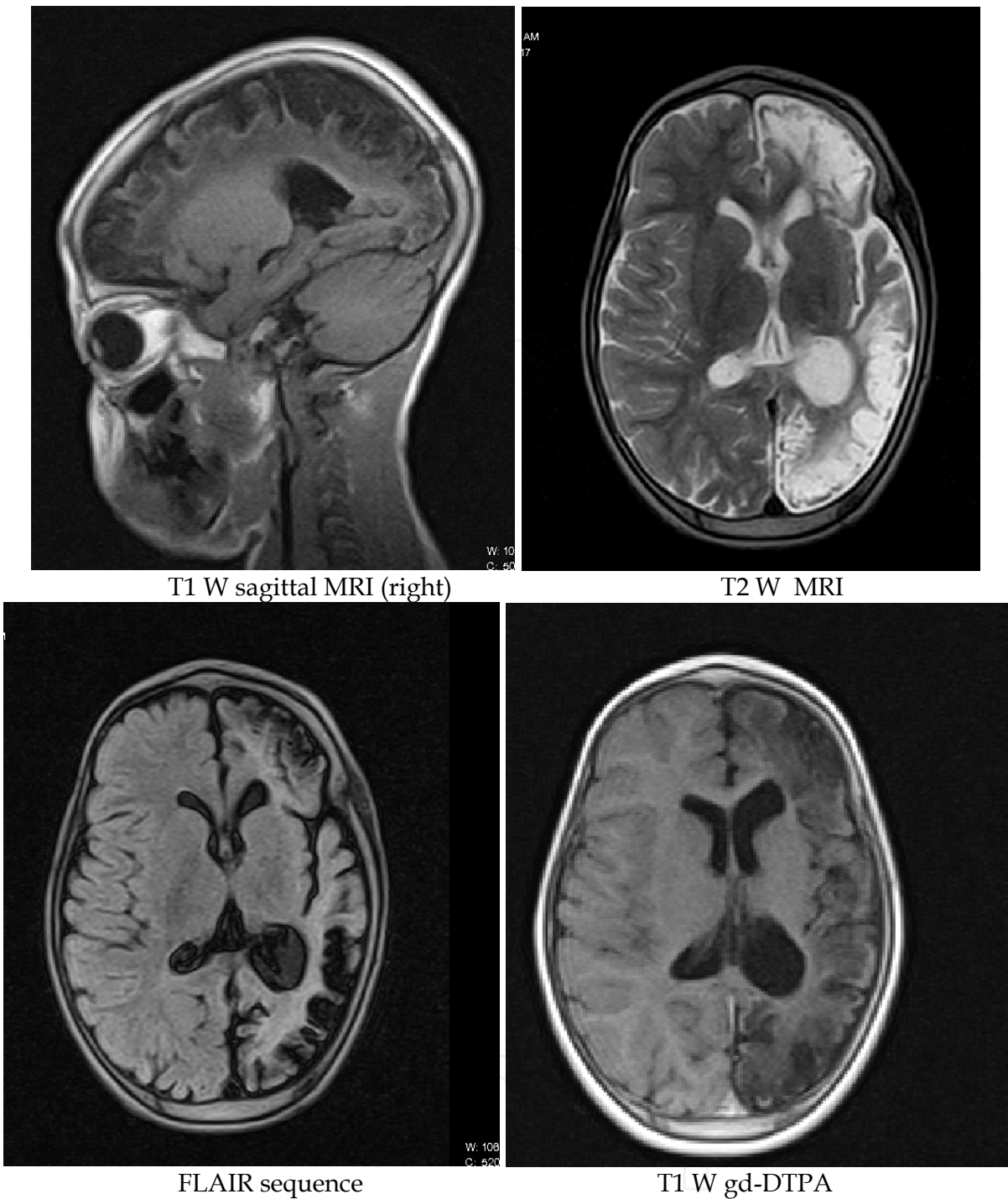


Fig. 3. Brain MRI T1W and T2W transverse and sagittal images as well as FLAIR transverse and coronal images were obtained. The images show left unilateral cerebral atrophy worse at the frontal occipital and perisinsular regions. There is associated ipsilateral dilatation of the lateral ventricle and widening of the cerebral sulci. The T2W images show diffuse increased signal intensity in the cortical and subcortical white matter which are of decreased signal on T1W images. The FLAIR images also show increased signal changes in the frontal and occipital white matter on the left. The right cerebral hemisphere, brainstem and cerebellum are all within normal limits. The post gadolinium images show no evidence of enhancement.

A few patients transiently show focal cortical swelling on early scans. Subsequently, a spread of signal changes and atrophy within the affected hemispheres is observed.

In areas with increased MRI signal, the intensity of inflammation as measured by number of T cells, microglial nodules and GFAP+ astrocytes is increased compared with more chronically affected areas with advanced atrophy and no more signal increase.(Bien et al., 2005b; Bien et al., 2002c; Bien et al., 2002d) Using a quantitative approach (calculation of the 'hemispheric ratio', i.e. the ratio affected/unaffected hemisphere on planimetry of axial and coronal slices including the Sylvian fissure) to assess the temporal evolution of hemiatrophy, most of the tissue loss occurs during the first 12 months after onset of the acute disease stage.(Bien et al., 2005b; Bien et al., 2002c; Bien et al., 2002d) However, it may, in some cases, go on for several years.(Bien et al., 2005b; Bien et al., 2002c; Bien et al., 2002d)

In a series of immunotreated RE patients, volumetric assessment of serial MRIs during early disease stages revealed a median tissue loss of 29.9 cm³ per year in the affected and of 6.8 cm³ in the unaffected hemispheres.(Larionov et al., 2005) Gadolinium enhancement is very rare in RE.(Bien et al., 2005b; Bien et al., 2002c)

5.2.2 PET studies

PET studies, almost exclusively performed using the tracer fluorodeoxyglucose (FDG), show abnormalities confined to the affected hemisphere. In most cases, large areas of hypometabolism are observed; in the remainder (mostly 'ictal' studies in patients with ongoing EPC), additional areas of focal hypermetabolism are found.(Bien et al., 2005b) FDG-PET changes in early stages (disease duration up to 1 year) are confined to frontotemporal areas. In later stages, abnormalities also affect posterior cortical regions. (Bien et al., 2005b)

One case study suggested that FDG-PET-hypermetabolism correlates with ongoing electrical seizure activity whereas methionin- PET-hypermetabolism indicates areas of inflammation, but this needs to be confirmed in larger patients group.(Bien et al., 2005b) It has been proposed that PET might guide brain biopsy in cases with inconclusive or normal MRI findings, especially in early stages.

5.2.3 Single photon emission computed tomography (SPECT)

With interictal and ictal SPECT, the same type of results and conclusions have been reached as with PET (Bien et al., 2005b)

5.2.4 Magnetic resonance spectroscopy (MRS)

Magnetic resonance spectroscopy (MRS) studies consistently showed decreased N-acetyl-aspartate (NAA) levels and increased (or normal) choline (cho) peaks resulting in a decreased NAA/cho-ratio suggestive of neuronal loss or dysfunction.(Bien et al., 2005b) Partly observed increased lactate peaks seemed to be associated with the presence of EPC. The present studies do not provide evidence for RE-specific MRS abnormalities.

In conclusion, PET, SPECT and MRS techniques are not suitable for defining the inflammatory nature of the condition. They may, however, help in confirming the unihemispheric nature in suspected early RE findings. (Bien et al., 2005b) Simultaneous *fMRI* and EEG recording may be useful in planning surgery. (Cuspinada Bravo et al., 2010)

5.3 Laboratory features

No laboratory test is available to positively support the diagnosis of RE. The largest series of CSF tests has been reported by the Montreal group. In about half of the examinations, cell counts and protein levels were in the normal range. In the remainder, elevated cell counts (16–70 cells/ml, predominantly lymphocytes), and increased protein content (50–100 mg/dl) or a first or midzone elevation of the colloidal gold curve were observed. In only 15% of the abnormal CSF tests, were all three parameters were abnormal. (Bien et al., 2005b) Oligoclonal bands are an inconsistent finding ranging from 0 to 67% in some small series. (Bien et al., 2005b)

GluR3 antibodies in serum (and CSF alike) do not discriminate between RE and noninflammatory epilepsy. (Bien et al., 2005b) Moreover, the presence or absence of GluR3 antibodies does not allow specific pathogenic clues in a given patient and should not be used to select or exclude a specific treatment.

Therefore, CSF standard tests are not suitable to exclude or confirm the diagnosis of RE. Serological CSF tests are usually applied to rule out a CNS infection by known neurotropic agents.

5.4 Brain biopsy

Brain biopsy is not required in all RE cases because other criteria can be sufficient to diagnose the condition. In 'burnt out' cases, brain biopsy may give nonspecific results and not lead to initiation of immunomodulatory treatment. (Bien et al., 2005b) In cases not fulfilling the noninvasive diagnostic criteria as well as in less common RE forms, brain biopsy can contribute considerably to diagnostic certainty. (Bien et al., 2005b)

However, false negative results may be obtained in a small stereotactic needle biopsy because normal and abnormal tissue elements may be located in very close apposition. (Bien et al., 2005b) Therefore, if there are no contraindications, an open biopsy comprising meninges, grey and white matter is preferable. If, in suspicious cases, histology does not clearly show lymphocytic inflammation and microglial (nodular) activation, evaluation of serial sections may be necessary. Biopsy should be taken from a non-eloquent area where there is increased T2/FLAIR signal on MRI or abnormal findings in PET or SPECT. (Bien et al., 2005b)

A gradient of inflammatory intensity from frontotemporal to occipital areas, especially in early cases, has been observed. Therefore, frontal or temporal biopsies are generally preferable. Cases with predominant parietal or occipital involvement, however, exist. (Bien et al., 2005b)

True histopathological differential diagnoses to RE are not as numerous as sometimes assumed. Chronic viral encephalitides, paraneoplastic encephalitis and nonparaneoplastic limbic encephalitis (Bien et al., 2005b) need to be considered. If the results of brain biopsy are inconclusive, further clinical and MRI follow-up studies (e.g. every 6 months) are required to clarify the nature of the disease.

6. Diagnostic criteria

A diagnostic criteria is proposed by the European Consensus statement (Table 1). RE can be diagnosed if either all three criteria of Part A or two out of three criteria of Part B are present. (Bien et al., 2005b)

RE can be diagnosed if either all three criteria of Part A or two out of three criteria of Part B are present. Check first for the features of Part A. Then, if these are not fulfilled, of Part B. In addition: If no biopsy is performed, MRI with administration of gadolinium and cranial CT needs to be performed to document the absence of gadolinium enhancement and calcifications to exclude the differential diagnosis of a unihemispheric vasculitis .

Part A:

- 1. Clinical Focal seizures (with or without Epilepsia partialis continua) and Unilateral cortical deficit(s)
- 2. EEG Unihemispheric slowing with or without epileptiform activity and Unilateral seizure onset
- 3. MRI Unihemispheric focal cortical atrophy and at least one of the following:
 - Grey or white matter T2/FLAIR hyperintense signal
 - Hyperintense signal or atrophy of the ipsilateral caudate head

Part B:

- 1. Clinical Epilepsia partialis continua or Progressive* unilateral cortical deficit(s)
 - 2. MRI Progressive* unihemispheric focal cortical atrophy
 - 3. Histopathology T cell dominated encephalitis with activated microglial cells (typically, but not necessarily forming nodules) and reactive astrogliosis. Numerous parenchymal macrophages, B cells or plasma cells or viral inclusion bodies exclude the diagnosis of RE.
- *‘Progressive’ means that at least two sequential clinical examinations or MRI studies are required to meet the respective criteria. To indicate clinical progression, each of these examinations must document a neurological deficit, and this must increase over time. To indicate progressive hemiatrophy, each of these MRIs must show hemiatrophy, and this must increase over time.

Table 1. European Consensus Diagnostic Criteria for RE (2005)(Bien et al., 2005b)

7. Differential diagnoses

Differential diagnoses include unihemispheric epileptic syndromes, inflammatory diseases, metabolic or degenerative disorders. Unihemispherical epileptic syndromes include cortical dysplasia, hemimegalencephaly, tuberous sclerosis, Sturge-Weber-syndrome, stroke, and hemiconvulsion-hemiplegia-epilepsy-syndrome. (Bien et al., 2005b)

Inflammatory diseases such as cerebral vasculitis in systemic connective tissue disease and unihemispheric cerebral vasculitis usually present with typical serological features, calcification on brain CT and gadolinium enhancement on MRI. Subacute sclerosing panencephalitis presents with period discharges on EEG.

Epilepsia partialis continua (EPC) due to metabolic disorders such as DM and hepatic encephalopathy can be diagnosed with blood tests. Metabolic or degenerative progressive neurological diseases such as MELAS and other can be diagnosed by mitochondrial DNA genetic testing for mutations and muscle biopsy.

8. Treatment

The goals of treatment are to reduce inflammation, control seizures and reverse functional deficits (motor, sensory, cognitive, etc). Pharmacologic, immunotherapeutic, surgical and

rehabilitative techniques are used to achieve these goals. Rarity of the condition makes it difficult to conduct RCTs to compare treatment options.

8.1 Pharmacological control of seizures

Classical AEDs are more effective in the control of complex partial seizures and secondarily generalized seizures than EPC. (Bien et al., 2009a) No anticonvulsive mono- or combination-therapy has been described to be superior to other regimens. There is no evidence that the new AEDs have higher efficacy than older AEDs. However, their improved tolerability and reduced potential for pharmacokinetic interactions may be of particular importance if long-term immune-treatment is applied. (Bien et al., 2009a)

Enzyme-inducing drugs reduce blood-levels of corticosteroids and tacrolimus; enzyme-inhibiting drugs, on the other hand, confer the risk of tacrolimus intoxication and encephalopathy. Substances with high albumin bound fraction may be difficult to keep at a constant blood level if in parallel with plasma exchange. As a general rule, number and dose of AEDs should be kept as low as possible, i.e., one should try to abolish secondarily generalized tonic clonic and, possibly, complex partial seizures; EPC, however, is almost never suppressed by AEDs and it provides little benefit to the patients if one tries to suppress this focal motor status epilepticus. In cases of localised EPC, botulinum toxin has been successfully injected. (Bien et al., 2009a) Epilepsy surgery and immunotherapy are also helpful in seizure control.

8.2 Immunotherapy

Immunotherapeutic interventions include corticosteroids, immunoglobulin, plasmapheresis, interferon, rituximab, and tacrolimus.

8.2.1 Corticosteroids

Prednisolone/prednisone started at high doses and slowly tapered down have been reported to have beneficial effects on seizures and neurological functions in several series, particularly when started early in the course of the disease. (Bien et al., 2009a) However, serious side effects partly necessitating steroid withdrawal have been noticed. These include fluid retention/Cushing's syndrome in all patients and, in single cases, psychosis, behavioural abnormalities, septicaemia, osteoporosis, hypertension and candidiasis. (Bien et al., 2009a) Therefore, for long-term steroid therapy, it has been recommended to start with boluses of intravenous methylprednisolone (e.g. 400 mg/m²/day) or, in children, 20 mg/kg/day and then to introduce 1–2 mg/kg/day oral prednisolone or prednisone. This dose should be slowly reduced, ideally to a dose below the threshold of Cushing's syndrome. Short-term steroid bolus administration (dosing as above) has been found to be effective in blocking status epilepticus. (Bien et al., 2009a)

8.2.2 Intravenous Immunoglobulin (IVIG)

Good effects of IVIG on seizures and neurological functions were reported in some case studies and series where IVIG is recommended as the first-line immunotherapy. Furthermore, favourable responses of adult cases have led to the proposal IVIG as first-line treatment especially in late-onset cases. (Bien et al., 2009a) The recommended dosing scheme is to start with three to five consecutive infusions of 0.4 g/kg/day and to proceed with a monthly dose of 0.4–2.0 g/kg distributed over 1–5 consecutive days. Side effects of IVIG treatment are rare.

8.2.3 IVIG plus steroid

In case of insufficient effect of IVIG, a combination of 0.4 g/kg/month IVIG plus corticosteroids (dosing as above) is recommended. (Bien et al., 2009a)

8.2.4 Plasma exchange/plasmapheresis

Plasma exchange cycles have been performed at a frequency of three to six single volume exchanges on consecutive or alternate days, repeated every 2 to 8 weeks. Selective periodic immuno-adsorption with protein A has been used as a long-term management with positive results in adolescent-adult onset patients. Both measures improved neurological function and seizure frequency in some patients during the weeks following the intervention that could be reinstituted by repeat treatment. However there is very limited experience with long term treatment in RE. (Bien et al., 2009a) Long-term immunotherapy is usually ineffective against seizures.

8.2.5 Tacrolimus

Tacrolimus is a T cell inhibiting immunosuppressant. In a small controlled trial, the tacrolimus patients had a superior outcome regarding neurological function and progression rate of cerebral hemiatrophy on MRI, but no better seizure outcome. Their cognitive outcome was good. (Bien et al., 2004; Bien et al., 2009a) The results of a randomized prospective trial, comparing tacrolimus and IVIG are still being awaited. (Bien et al., 2004; Bien et al., 2009a)

8.2.6 IFN-alpha

Report of seizure control with the use of intraventricular interferon-alpha has been made. (Bien et al., 2009a; Dabbagh et al., 1997) However it is an invasive measure and further trials are required to verify its efficacy and determine its role in RE therapy.

8.2.7 Rituximab

Rituximab is a chimeric monoclonal antibody against the protein CD20. Although CD20+ cells (B cells) are extremely rare, rituximab may in single cases be a viable treatment alternative; a formal trial is underway. (Bien et al., 2005b)

8.3 Surgical treatment

Surgical treatment is indicated in medically-refractory seizures. Options include anatomic hemispherectomy, functional hemispherectomy, perisylvian hemispherotomy, trans-sylvian hemispherotomy and central/vertical hemispherotomy. (Bien et al., 2005b; Bien et al., 2009b; Bien et al., 2009a; Terra-Bustamante et al., 2009) However, only hemispherectomy (anatomical or functional) is effective in RE. (Bien et al., 2005b; Bien et al., 2009b; Bien et al., 2009a; Terra-Bustamante et al., 2009)

The basic principle of the modern techniques is to replace resection by disconnection.

Presurgical evaluation for hemispherectomy should be performed in all patients with pharmacoresistant and handicapping seizures due to RE. Some special considerations during this presurgical assessment arise from the fact that RE represents the rare case of an epilepsy due to acquired hemispheric brain damage. In RE, patients with disease onset >4 years of age (when secondary language transfer is no longer highly likely) need to be

investigated with particular scrutiny to predict the post-HE functioning. (Bien et al., 2005b; Bien et al., 2009b; Bien et al., 2009a; Terra-Bustamante et al., 2009)

The following steps are recommended in the pre-op work-up of RE patients: brain MRI and video-EEG-monitoring for registration of interictal and ictal activity and prediction of postoperative functional outcome by assessment of the actual language, motor, visual function (visual field) and language dominance lateralization, usually by means of Wada testing. (Bien et al., 2005b; Bien et al., 2009b; Bien et al., 2009a; Terra-Bustamante et al., 2009) However, it is imperative to determine cerebral dominance by Wada test prior to surgery. (Bien et al., 2005b; Bien et al., 2009b; Bien et al., 2009a; Terra-Bustamante et al., 2009) Language functional MRI alone has not been shown to be sufficient due to limited comparability of the two hemispheres as well as the restricted ability of the patients to follow instructions. (Bien et al., 2005b; Bien et al., 2009b; Bien et al., 2009a; Terra-Bustamante et al., 2009)

8.4 Rehabilitation

Depending on the type of neurological deficits, different modalities of rehabilitation are employed to improve the health-related quality of life of the patient. This includes physiotherapy, vocational therapy, occupational therapy, speech and language therapy, and cognitive rehabilitation. Botulinum toxin A is useful in the management of localized refractory EPC.

8.5 Choice of therapy for individual patients

Anti-seizure effect of anti-epilepsy drugs is usually limited to secondarily generalized seizures and complex partial seizures whereas EPC is usually refractory. (Bien et al., 2005b; Bien et al., 2009a) Hemispherectomy in one of its modern variants offers a very high chance of seizure freedom, however at the price of irreversible loss of functions located in the affected hemisphere. (Bien et al., 2005b; Bien et al., 2009a; Terra-Bustamante et al., 2009) In a proportion of patients, long-term immunotherapy is able to prevent or slow down hemispheric tissue loss and the associated functional decline. It does, however, mostly not improve the epilepsy. Whereas for many patients unequivocal treatment proposals can be readily made, a dilemma may emerge in those with severe epilepsy but still preserved hemispheric function. (Bien et al., 2005b; Bien et al., 2009a; Terra-Bustamante et al., 2009)

In the European consensus statement on RE, a therapeutic protocol (Bien et al., 2005b; Bien et al., 2009a) for any patient with the diagnosis of RE has been suggested.

8.5.1 Mild or absent epilepsy, with progressed functional deficit

A low dose AED therapy will usually suffice in these cases. If complete seizure freedom cannot be achieved but is a major goal of the patient, surgery can be offered. (Bien et al., 2005b; Bien et al., 2009a)

8.5.2 Handicapping epilepsy, and no findings predicting a relevant post-op deterioration

Here, surgery is clearly the treatment of choice. The patient and his family needs to be informed about the general risks of the procedure. (Bien et al., 2005b; Bien et al., 2009a; Terra-Bustamante et al., 2009)

8.5.3 Mild or absent epilepsy with limited neurological deficit

If the patient is still in the acute disease stage, i.e., has recently experienced a functional decline, this is certainly the ideal situation for long-term immunotherapy. The epilepsy is no or only a minor problem, and the functional decline may be stopped or at least slowed down by the immunotherapy. If, however, the patient is already in the residual stage (i.e., no functional decline within the previous 6 months or so), initiation of immunotherapy is no longer recommended. (Bien et al., 2005b; Bien et al., 2009a)

8.5.4 Handicapping epilepsy, but prediction of significant functional deterioration after surgery

This is certainly the most problematic situation. (Bien et al., 2005b; Bien et al., 2009b; Bien et al., 2009a; Terra-Bustamante et al., 2009) Early institution of long-term immunotherapy is recommended to prevent functional decline. If seizures remain severe and disabling, additional “short-term/intense” immunotherapy should be tried (e.g., an i.v. pulse of several days of methylprednisolone at 20 mg/(kg day) in children or 500–1000 mg/day in adults, or plasma exchange, or IVIG). If no satisfying effect is achieved, this add-on immunotherapy should be discontinued, and the option of HE should be considered as discussed above. (Bien et al., 2005b; Bien et al., 2009a)

The severity of each of the expected deficits after surgery should be weighed in relation to the severity of epilepsy. (Bien et al., 2005b; Bien et al., 2009a; Terra-Bustamante et al., 2009; Terra-Bustamante et al., 2007) This requires extensive and in-depth discussions with the patient and his family. Whereas the prediction of postoperative aphasia in a still communicable child (RE of the language dominant hemisphere) will usually preclude surgery, the perspective of a fixed dense hemiparesis with preserved walking abilities may be an acceptable price for seizure freedom. This is particularly clear in cases, in which continuous or near-continuous motor seizures impair hand and leg function anyway. (Bien et al., 2005b; Bien et al., 2009a; Terra-Bustamante et al., 2009; Terra-Bustamante et al., 2007)

Regardless of the affected side, the probably least relevant consequence of surgery is hemianopia, which is usually well compensated in everyday life. In conclusion, especially in patients with impairing seizures and affection of the non-dominant hemisphere, surgery will often emerge as the superior long-term option compared to ongoing conservative treatment. (Bien et al., 2005b; Bien et al., 2009a; Terra-Bustamante et al., 2009; Terra-Bustamante et al., 2007)

9. Conclusions and future prospects

Rasmussen’s encephalitis (RE) is a very rare disease of the brain, usually in children, characterized by focal seizures, ipsilateral cortical deficits and hemiparesis, as well as hemiatrophy of the contralateral cerebral hemisphere. Even though the European Consensus criteria has been proposed for its diagnosis, the aetio-pathogenesis remains enigmatic.

The affected brain tissue shows a chronic T-cell mediated inflammatory histopathology and an autoimmune reaction is suspected. Four groups of histopathological changes have been described with variable densities of microglial nodules, gyral necrosis, neuronal loss, glial scarring and gliosis. Following the natural history of the disease, three stages have been

proposed: the *prodromal stage* with a relatively low seizure frequency and mild hemiparesis; the *acute stage* with frequent seizures, and the *residual stage*. Focal epilepsy can be demonstrated by EEG while neuroimaging by CT scan or MRI demonstrates cerebral hemiatrophy.

Anti-epileptic drugs have limited efficacy particularly in the control of EPC. Several immunomodulatory therapies have been tried. However being an orphan disease, no randomized clinical trials have demonstrated the long-term outcome of steroids, tacrolimus, plasmapheresis and immunoglobulin therapy. Whereas epileptic surgery is effective for seizure control, it is at the price of inducing severe neurological deficit.

It is hoped that in the nearest future early diagnosis and extensive study of new cases in the prodromal phase may help unravel the antigenic stimulus for the T-cell-mediated response as well as the basis for the unilaterality of hemispheric damage. This may lead to specific immunotherapeutic techniques which can then be tested in multicenter randomized control trials.

Better understanding of epilepsy therapeutics with combination of new and older antiepileptic drugs may result in better seizure control. (Owolabi et al., 2008) However, successes of non-surgical approaches have to be proven in the context of the natural evolution of the disease to a non-progressive phase. The decision to undergo surgery has to be individualized and predicated on the full information about the risks and benefits for the index patient. Novel and holistic approach to rehabilitation may result in improved quality of life for RE patients who can then march on to achieve their goals in life despite the fire of inflammation in the brain.

10. References

- Andermann,F., and Farrell,K. (2006). Early onset Rasmussen's syndrome: a malignant, often bilateral form of the disorder. *Epilepsy Res.* 70 Suppl 1, S259-S262.
- Bauer,J., Bien,C.G., and Lassmann,H. (2002). Rasmussen's encephalitis: a role for autoimmune cytotoxic T lymphocytes. *Curr. Opin. Neurol* 15, 197-200.
- Bauer,J., Elger,C.E., Hans,V.H., Schramm,J., Urbach,H., Lassmann,H., and Bien,C.G. (2007). Astrocytes are a specific immunological target in Rasmussen's encephalitis. *Ann. Neurol* 62, 67-80.
- Bhatjiwale,M.G., Polkey,C., Cox,T.C., Dean,A., and Deasy,N. (1998). Rasmussen's encephalitis: neuroimaging findings in 21 patients with a closer look at the basal ganglia. *Pediatr. Neurosurg.* 29, 142-148.
- Bien,C.G., and Bauer,J. (2005a). T-cells in human encephalitis 22. *Neuromolecular. Med* 7, 243-253.
- Bien,C.G., Bauer,J., Deckwerth,T.L., Wiendl,H., Deckert,M., Wiestler,O.D., Schramm,J., Elger,C.E., and Lassmann,H. (2002a). Destruction of neurons by cytotoxic T cells: a new pathogenic mechanism in Rasmussen's encephalitis. *Ann. Neurol* 51, 311-318.
- Bien,C.G., Elger,C.E., and Wiendl,H. (2002b). Advances in pathogenic concepts and therapeutic agents in Rasmussen's encephalitis. *Expert. Opin. Investig. Drugs* 11, 981-989.


- Bien, C.G., Gleissner, U., Sassen, R., Widman, G., Urbach, H., and Elger, C.E. (2004). An open study of tacrolimus therapy in Rasmussen encephalitis 33. *Neurology* 62, 2106-2109.
- Bien, C.G., Granata, T., Antozzi, C., Cross, J.H., Dulac, O., Kurthen, M., Lassmann, H., Mantegazza, R., Villemure, J.G., Spreafico, R., and Elger, C.E. (2005b). Pathogenesis, diagnosis and treatment of Rasmussen encephalitis: a European consensus statement 28. *Brain* 128, 454-471.
- Bien, C.G., and Schramm, J. (2009a). Treatment of Rasmussen encephalitis half a century after its initial description: promising prospects and a dilemma. *Epilepsy Res* 86, 101-112.
- Bien, C.G., Szinay, M., Wagner, J., Clusmann, H., Becker, A.J., and Urbach, H. (2009b). Characteristics and surgical outcomes of patients with refractory magnetic resonance imaging-negative epilepsies. *Arch. Neurol.* 66, 1491-1499.
- Bien, C.G., Urbach, H., Deckert, M., Schramm, J., Wiestler, O.D., Lassmann, H., and Elger, C.E. (2002c). Diagnosis and staging of Rasmussen's encephalitis by serial MRI and histopathology. *Neurology* 58, 250-257.
- Bien, C.G., Widman, G., Urbach, H., Sassen, R., Kuczaty, S., Wiestler, O.D., Schramm, J., and Elger, C.E. (2002d). The natural history of Rasmussen's encephalitis. *Brain* 125, 1751-1759.
- Chinchilla, D., Dulac, O., Robain, O., Plouin, P., Ponsot, G., Pinel, J.F., and Graber, D. (1994). Reappraisal of Rasmussen's syndrome with special emphasis on treatment with high doses of steroids. *J Neurol Neurosurg. Psychiatry* 57, 1325-1333.
- Cuspidada Bravo, E.R., Iturria, Y., Praderes, J.C., Melie, L., Valdes, P.A., Virues, T., Machado, C., and Valdes, U.L. (2010). Noninvasive multimodal neuroimaging for Rasmussen encephalopathy surgery: simultaneous EEG-fMRI recording. *Clin EEG. Neurosci.* 41, 159-165.
- Dabbagh, O., Gascon, G., Crowell, J., and Bamoggadam, F. (1997). Intraventricular interferon-alpha stops seizures in Rasmussen's encephalitis: a case report. *Epilepsia* 38, 1045-1049.
- Delalande, O., Fohlen, M., Bulteau, C., and Jalin, C. (2004). [Surgery for intractable focal epilepsy in children]. *Rev. Neurol (Paris)* 160 Spec No 1, 5S195-5S202.
- Farrell, M.A., DeRosa, M.J., Curran, J.G., Secor, D.L., Cornford, M.E., Comair, Y.G., Peacock, W.J., Shields, W.D., and Vinters, H.V. (1992). Neuropathologic findings in cortical resections (including hemispherectomies) performed for the treatment of intractable childhood epilepsy. *Acta Neuropathol.* 83, 246-259.
- Gambardella, A., Andermann, F., Shorvon, S., Le, P.E., and Aguglia, U. (2008). Limited chronic focal encephalitis: another variant of Rasmussen syndrome? *Neurology* 70, 374-377.
- Hart, Y. (2004). Rasmussen's encephalitis. *Epileptic. Disord.* 6, 133-144.
- Hart, Y.M., Andermann, F., Fish, D.R., Dubeau, F., Robitaille, Y., Rasmussen, T., Berkovic, S., Marino, R., Yakoubian, E.M., Spillane, K., and Scaravilli, F. (1997). Chronic encephalitis and epilepsy in adults and adolescents: a variant of Rasmussen's syndrome? *Neurology* 48, 418-424.

- Hart,Y.M., Andermann,F., Robitaille,Y., Laxer,K.D., Rasmussen,T., and Davis,R. (1998). Double pathology in Rasmussen's syndrome: a window on the etiology? *Neurology* 50, 731-735.
- Hennessy,M.J., Koutroumanidis,M., Dean,A.F., Jarosz,J., Elwes,R.D., Binnie,C.D., and Polkey,C.E. (2001). Chronic encephalitis and temporal lobe epilepsy: a variant of Rasmussen's syndrome? *Neurology* 56, 678-681.
- Hunter,G.R., Donat,J., Pryse-Phillips,W., Harder,S., and Robinson,C.A. (2006). Rasmussen's encephalitis in a 58-year-old female: still a variant? *Can. J Neurol Sci.* 33, 302-305.
- Jaillon-Riviere,V., Dupont,S., Bertran,F., De,L.S., V, Beuvon,F., Baulac,M., and Defer,G. (2007). [Late onset Rasmussen's syndrome: clinical and therapeutic characteristics]. *Rev. Neurol (Paris)* 163, 573-580.
- Korn-Lubetzki,I., Bien,C.G., Bauer,J., Gomori,M., Wiendl,H., Trajo,L., Ovadia,H., Wilken, B., Hans,V.H., Elger,C.E., Hurvitz,H., and Steiner,I. (2004). Rasmussen encephalitis with active inflammation and delayed seizures onset 37. *Neurology* 62, 984-986.
- Larionov,S., Konig,R., Urbach,H., Sassen,R., Elger,C.E., and Bien,C.G. (2005). MRI brain volumetry in Rasmussen encephalitis: the fate of affected and "unaffected" hemispheres 27. *Neurology* 64, 885-887.
- Oguni,H., Andermann,F., and Rasmussen,T.B. (1991). The natural history of the syndrome of chronic encephalitis and epilepsy: a study of the MRI series of fortyeight cases. In *Chronic encephalitis and epilepsy. Rasmussen's syndrome.*, F.Andermann, ed. (Boston: Butterworth-Heinemann) pp. 7-35.
- Owolabi,M.O., Ogbale,G., and Lagunju,I. (2008). Conservative management of Rasmussen's encephalitis in a Nigerian girl. *Journal of Pediatric Neurology* 6, 389-394.
- Pleasure,D. (2008). Diagnostic and pathogenic significance of glutamate receptor autoantibodies. *Arch. Neurol.* 65, 589-592.
- Quesada,C.M., Urbach,H., Elger,C.E., and Bien,C.G. (2007). Rasmussen encephalitis with ipsilateral brain stem involvement in an adult patient 10. *J Neurol Neurosurg. Psychiatry* 78, 200-201.
- Rasmussen,T., Olszewski,J., and LLOYDSMITH,D. (1958). Focal seizures due to chronic localized encephalitis. *Neurology* 8, 435-445.
- Robitaille,Y. (1991). Neuropathologic aspects of chronic encephalitis. In *Chronic encephalitis and epilepsy. Rasmussen's syndrome*, F.Andermann, ed. (Boston: Butterworth-Heinemann) pp. 79-110.
- Schwab,N., Bien,C.G., Waschbisch,A., Becker,A., Vince,G.H., Dornmair,K., and Wiendl,H. (2009). CD8+ T-cell clones dominate brain infiltrates in Rasmussen encephalitis and persist in the periphery. *Brain* 132, 1236-1246.
- Terra-Bustamante,V.C., Inuzuka,L.M., Fernandes,R.M., Escorsi-Rosset,S., Wichert-Ana, L., Alexandre,V., Jr., Bianchin,M.M., Araujo,D., Santos,A.C., Oliveira dos, S.R., Machado,H.R., and Sakamoto,A.C. (2007). Outcome of hemispheric surgeries for refractory epilepsy in pediatric patients 11. *Childs Nerv. Syst.* 23, 321-326.

Terra-Bustamante,V.C., Machado,H.R., dos Santos,O.R., Serafini,L.N., Souza-Oliveira,C., Escorsi-Rosset, S., Yacubian, E. M., Naffah-Mazzacoratti, M. G., Scorza, C. A., Cavalleiro, E.A., Scorza,F.A., and Sakamoto,A.C. (2009). Rasmussen encephalitis: long-term outcome after surgery. Childs Nerv. Syst. 25, 583-589.

IntechOpen

IntechOpen



Pathogenesis of Encephalitis

Edited by Dr. Daisuke Hayasaka

ISBN 978-953-307-741-3

Hard cover, 344 pages

Publisher InTech

Published online 09, December, 2011

Published in print edition December, 2011

Many infectious agents, such as viruses, bacteria, and parasites, can cause inflammation of the central nervous system (CNS). Encephalitis is an inflammation of the brain parenchyma, which may result in a more advanced and serious disease meningoencephalitis. To establish accurate diagnosis and develop effective vaccines and drugs to overcome this disease, it is important to understand and elucidate the mechanism of its pathogenesis. This book, which is divided into four sections, provides comprehensive commentaries on encephalitis. The first section (6 chapters) covers diagnosis and clinical symptoms of encephalitis with some neurological disorders. The second section (5 chapters) reviews some virus infections with the outlines of inflammatory and chemokine responses. The third section (7 chapters) deals with the non-viral causative agents of encephalitis. The last section (4 chapters) discusses the experimental model of encephalitis. The different chapters of this book provide valuable and important information not only to the researchers, but also to the physician and health care workers.

How to reference

In order to correctly reference this scholarly work, feel free to copy and paste the following:

Mayowa Owolabi (2011). Rasmussen's Encephalitis: An Overview, Pathogenesis of Encephalitis, Dr. Daisuke Hayasaka (Ed.), ISBN: 978-953-307-741-3, InTech, Available from:

<http://www.intechopen.com/books/pathogenesis-of-encephalitis/rasmussen-s-encephalitis-an-overview>

INTECH
open science | open minds

InTech Europe

University Campus STeP Ri
Slavka Krautzeka 83/A
51000 Rijeka, Croatia
Phone: +385 (51) 770 447
Fax: +385 (51) 686 166
www.intechopen.com

InTech China

Unit 405, Office Block, Hotel Equatorial Shanghai
No.65, Yan An Road (West), Shanghai, 200040, China
中国上海市延安西路65号上海国际贵都大饭店办公楼405单元
Phone: +86-21-62489820
Fax: +86-21-62489821

© 2011 The Author(s). Licensee IntechOpen. This is an open access article distributed under the terms of the [Creative Commons Attribution 3.0 License](https://creativecommons.org/licenses/by/3.0/), which permits unrestricted use, distribution, and reproduction in any medium, provided the original work is properly cited.

IntechOpen

IntechOpen