

We are IntechOpen, the world's leading publisher of Open Access books Built by scientists, for scientists

6,900

Open access books available

186,000

International authors and editors

200M

Downloads

Our authors are among the

154

Countries delivered to

TOP 1%

most cited scientists

12.2%

Contributors from top 500 universities



WEB OF SCIENCE™

Selection of our books indexed in the Book Citation Index
in Web of Science™ Core Collection (BKCI)

Interested in publishing with us?
Contact book.department@intechopen.com

Numbers displayed above are based on latest data collected.
For more information visit www.intechopen.com



Haemolytic-Uraemic Syndrome: Neurologic Symptoms, Neuroimaging and Neurocognitive Outcome

Ana Roche Martínez¹, Pilar Póo Argüelles¹, Marta Maristany Cucurella¹,
Antonio Jiménez Llor², Juan A Camacho² and Jaume Campistol Plana¹

*Neurology (1) and Nephrology (2) Departments of Sant Joan de Déu
Children's Hospital of Barcelona, Barcelona University (U.B.)
Spain*

1. Introduction

Haemolytic-Uraemic Syndrome (HUS) was first described in 1955 by Gasser (Pérez del Campo et al., 2000) and defined as a multi-systemic syndrome, due to the association of microangiopathic haemolytic anemia, thrombopenia and multiorganic aggression. HUS affects mainly kidneys and leads to acute renal failure with high levels of urea and creatinin; it often involves digestive and central nervous systems. Central nervous system (CNS) lesions, typically at the basal ganglia, may also affect cortico-subcortical areas and in so doing determines motor and neurocognitive outcome, and modify the patients' quality of life.

Incidence of HUS varies among continents, highly influenced by migration movements, and it is estimated to be around 18/100,000 in children younger than 5 years old. Some countries, like Argentina and South Africa, are considered "endemic", with a steady and relatively high incidence of HUS during all the seasons of the year; other areas, such as Canada, most of the European countries, and the west coast of the USA, are said to be "epidemic", with sporadic cases and a lower incidence of HUS compared to Latin America and Africa during most of the year, but with self-limited relapses during summertime (Exeni, 2001).

HUS etiology is diverse and physiopathologic mechanisms are not yet well known, but infective microorganisms are frequently involved, especially *Escherichia coli*, serotype O15:H7; this bacteria is able to produce a toxic protein (vero-toxin -VT- or Shiga-toxin -Stx), which "recognizes" the endothelial cells and provokes an endothelial lesion (Scheiring, 2010). Other bacteria seem to be involved in different cases of HUS, like *Salmonella enteritidis* and *Streptococcus pneumoniae* (De Loos et al., 2002; Prestidge & Wong, 2009). Mutations in genes coding for different components of the complement system seem to be a risk factor for HUS (Skerka et al., 2009). However, the etiologic agent remains unidentified in most patients.

Clinical presentation in the acute phase includes acute renal failure (100% of patients), often high blood pressure (HBP) due to a volume surcharge (35-40% of patients), and neurological

symptoms such as irritability, drowsiness, seizures, cortical blindness, hemiparesis or coma, in up to 35-50% of patients (Montoliu, 1989). These symptoms may be a consequence of different disturbances: metabolic distress (hyponatremia, hyperglycemia, acidosis, fluid imbalance), HBP itself, or CNS microangiopathy. Pancreatic failure and heart involvement are less frequent during the acute phase of HUS (2% of patients).

HUS treatment is based on hydro-electrolytic management: peripheral and central venous pressure must be monitored and cardiac function must be closely controlled; renal function control is especially important, as well as caloric intake adjustment. Neurologic evaluation at the acute phase and during follow-up is crucial to diagnose CNS damage and prevent medium- and long-term sequelae.

No complementary tests have yet been developed to help the clinician in establishing a medium- or long-term prognosis in patients with HUS presenting with neurologic symptoms. Although during the 1980s some authors observed a good clinical outcome in patients with microangiopathic lesions (Steinborn et al., 2004), few references have reported long-term follow-up in these patients. Over the last 20 years, some cases of posterior reversible leuko-encephalopathy syndrome of subacute onset (presenting with drowsiness, lethargy, visual disturbance or seizures) have been described in the context of HUS, sometimes not even associated with HBP (Bennett et al., 2003; Gómez-Lado et al., 2007; Kitamura et al., 2010).

Prognosis factors previously described in different series of patients (Cimolai et al., 1992; Roche et al. 2008), including patient age, acute gastroenteritis symptoms, etiologic agent, seizures at onset, CNS images at the acute phase and neurofunctional tests performance, are reviewed below; clinical course during follow-up and long-term outcome of HUS patients with neurological symptoms are also analyzed.

2. Material and methods

Over the last 30 years (1981-2011), a series of 64 patients (29 boys and 35 girls) have presented with HUS in our hospital. Clinical charts of children with neurological symptoms during the acute phase were reviewed, including:

- Clinical data: age at onset, male/female gender, clinical presentation as infectious disease (acute gastroenteritis); “D+” nomenclature is internationally accepted to define acute gastroenteritis history, not regarding infectious agent identification. “D-” is used if acute gastrointestinal infection history was not present.
- Laboratory tests (data not shown but available upon request).
- Infectious agent: *Escherichia coli*, *Salmonella enteritidis*, *Streptococcus pneumoniae*, etc.
- Neurological symptoms: seizures, drowsiness, irritability, visual disturbances and paresia.
- Electrophysiological findings in video-electroencephalogram (video-EEG), visual evoked potentials (VEP) and brainstem evoked auditory response (BEAR), during the acute phase and along follow-up.
- Brain perfusion: Medium brain artery (MBA) Doppler ultrasound (US).
- Eye funduscopy at the acute phase and during follow-up.
- Neuroimaging: transfontanelar US, brain computerized tomography (CT), brain magnetic resonance imaging (MRI) at the acute phase and during follow-up.
- Non-neurological complications: pancreatitis, heart dysfunction....

- Medium- and long-term outcome (2-18 years).
Neurologic evaluation was performed by a pediatric neurologist when abnormalities at the initial neurological examination or complementary tests were identified.
Neurological sequelae were considered “medium-term” when they were present between 4 weeks and 12 months after clinical onset; complications were considered “long-term” when they persisted for more than 1 year after admission.
Neurocognitive evaluation was performed when medium or long term sequelae were identified. In these patients, physiotherapy and neurocognitive intervention were started as soon as possible after hospital discharge and continued during the school years.

- Pathology data of the exitus are also summarized.
Follow-up was maintained until clinical normalization or at least 2 years after admission.

3. Results

The following tables summarize the patients’ characteristics (sex, age at onset), causative agent, clinical presentation, diagnostic tests and clinical course of the 25 patients with HUS and neurological symptoms at onset.
Median age at presentation was 2 years 8 months (range 7 months-7 years old).
As shown in Table 1, sex distribution in HUS patients with neurologic symptoms reveals a higher proportion of girls (64%), with a boy/girl rate of 1:1.7; the rate among patients without neurologic symptoms was 1:1.2, slightly more frequent in girls.
Recent history of acute gastroenteritis (D+) was present in 24/25 patients with HUS and neurological symptoms at onset, although etiologic agent was only found in blood in 4/25 (two *Salmonella enteritidis* and two *E. coli*). One of these patients presented *E coli* both in blood and urine, and another had *Salmonella* in blood and *E. coli* in urine; *E. coli* was also present in urine in another patient.
The most frequent neurologic sign at onset was drowsiness alone (40%) or together with irritability (16%), while irritability alone was present in 10%.

Patient	Age at onset	Sex M / F#	Acute Gastro enteritis ¹	Agent	Dialysis	Acute neurologic presentation
1	1yr 3mo	M	D+	Unknown	no	Accidental traumatic epidural hematoma
2	2yr 3mo	F	D+	Unknown	yes	Drowsiness
3	8mo	F	D+	Salmonella	yes	Drowsiness. GTCS. Hyponatremia
4	7mo	F	D+	Unknown	yes	Drowsiness → cardiac arrest → myoclonias. Plain EEG within 15 hours
5	4yr 6mo	F	D+	Unknown	yes	GTCS. HBP. Hypoglycemia
6	1yr 2mo	M	D-	Unknown	yes	GTCS
7	3yr 4mo	M	D+	Unknown	no	Drowsiness
8	3yr	F	D+	Unknown	yes	HBP. Brain edema. Irritability and drowsiness
9	2yr 2mo	M	D+	Unknown	yes	Neurologic depression. Myoclonic seizures

10	4yr 6mo	M	D+	Salmonella <i>E.coli</i> (urine)	yes	Consciousness decrease. Irritability
11	1yr 10mo	F	D+	Unknown	yes	Consciousness decrease. Myosis. Pyramidal signs
12	1yr 6mo	F	D+	Unknown	yes	Drowsiness, pyramidal signs
13	2yr 2mo	M	D+	Unknown	no	Irritability-drowsiness
14	6yr	F	D+	<i>E.Coli</i> (urine and blood)	yes	Drowsiness
15	1yr 2mo	M	D+	Unknown	yes	GTCS
16	3yr 8mo	F	D+	Unknown	yes	Drowsiness, irritability
17	1yr 8mo	F	D+	Unknown	yes	Drowsiness. Loss of consciousness
18	2yr 2mo	F	D+	Unknown	yes	GTCS. Anisocoria
19	3yr 1mo	F	D+	<i>E.Coli</i> (urine)	yes	Drowsiness
20	7yr 4mo	F	D+	Unknown	yes	Drowsiness
21*	3yr	F	D+	E.Coli	yes	Stupor. Consciousness decrease. Slow ocular movements
22	3yr 11mo	M	D+	Unknown	yes	Irritability, agitation, drowsiness, orolingual dystonia.
23	4 yr	F	D+	Unknown	yes	Drowsiness
24	12 mo	F	D+	Unknown	yes	GTCS
25	12 mo	M	D+	Unknown	yes	GTCS

GTCS: generalized tonic-clonic seizure; HBP: high blood pressure;#M:male /F:female;*Trip to Argentina a few days before acute gastroenteritis

Table 1. Acute neurologic presentation on HUS context.

Nine patients suffered seizures at onset (generalized tonic-clonic, tonic or myoclonic seizures), which stands for 14% of all HUS patients and 36% of neurologic HUS patients. All nine patients survived without important long term sequelae. However, patients presenting seizure recurrence (patient 6) or myoclonic seizures during the acute phase (patient 9) developed medium term sequelae.

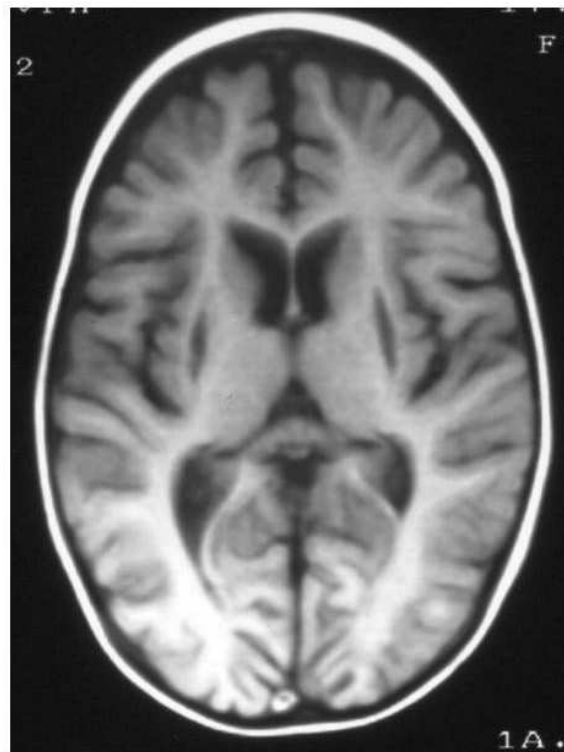
One patient presented orolingual dystonia shortly after clinical onset with irritability and drowsiness; no other patients showed abnormal movements at the acute phase or during follow up.

Eleven children had some neurological complementary test performed: eye funduscopy showed fovea erythrosis in patient 4 (exitus), and patient 21 presented delayed and disorganized VEP with normal BEAR. Video EEG was abnormal for all the patients who underwent it (5/9), with slow background activity; transfontanellar US, BMA Doppler US brain CT and MRI (both in the acute phase and during follow-up) findings are summarized in Table 2.

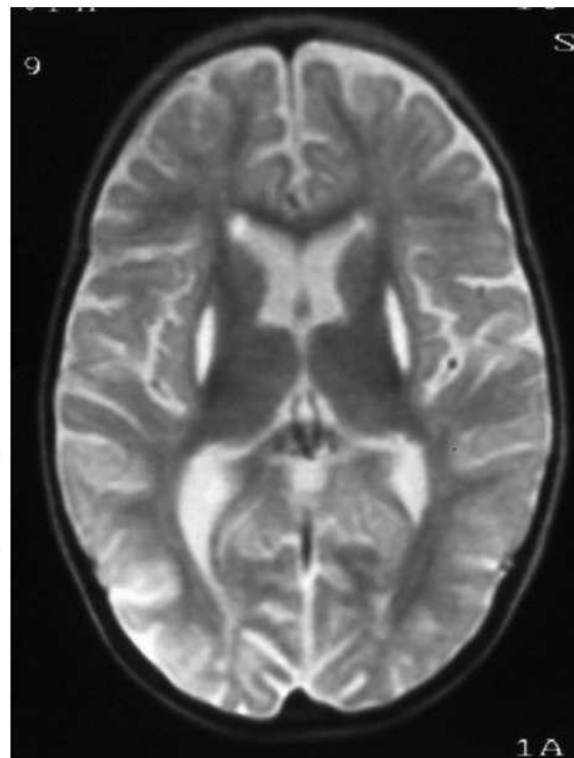
Brain MRI findings of patients 6 (Figures 1 and 2) and 21 (Figures 3 and 4) are consistent with vasculitic lesions due to diffuse hypoxic-ischemic aggression, with cortico-subcortical and basal ganglia distribution. Despite these findings, which were persistent along follow-up, both patients presented a favorable course without important long-term sequelae.

Patient	EEG	Brain ultrasound	Brain CT	Brain MRI acute phase	Brain MRI control
4	Plain EEG 15 hours after onset	Normal at the acute phase. Absence of supra-tentorial pulse 15h after onset	Not performed	Not performed	Not performed
6	Bilateral hemispheric abnormalities	Not performed	Not performed	Cortico-subcortical atrophy. Putamen necrosis	Putamen necrosis
11	Combination θ , α and β waves, without paroxysmal activity	Normal	Normal	Not performed	Not performed
15	Diffuse slow background. Left temporal paroxysms	Prominent sulci	Not performed	Not performed	Not performed
17	Paradoxal reactivity with slow background and slow high voltage waves in both hemispheres, no paroxysms	Not performed	Not performed	Not performed	Not performed
21	Not performed	Bilateral hemispheric abnormalities, of left predominance	Multiple cortico-subcortical hypointense images, consistent with brain edema	Basal ganglia necrosis and cortico-subcortical atrophy, consistent with vasculitis	Basal ganglia necrosis and cortico-subcortical atrophy also affecting cerebellum
22	Not performed	Normal brain medium artery Doppler ultrasound	Not performed	Normal diffusion brain MRI	Not performed
24	Not performed	Not performed	Not performed	Normal	Not performed
25	Not performed	Not performed	Normal	Not performed	Not performed

Table 2. Results of the pathologic tests in patients with HUS and neurologic symptoms at the acute phase and MRI control.



A



B

Fig. 1. Brain MRI of patient n. 6, six days after clinical onset.

T1 (A) and T2 (B) axial sequences, consistent with cortico-subcortical atrophy. Symmetrical areas of putamen necrosis.

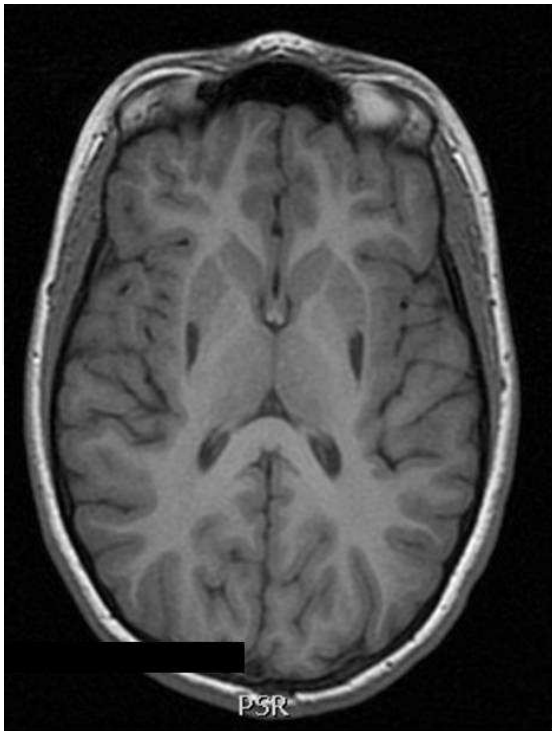


Figure 2.A

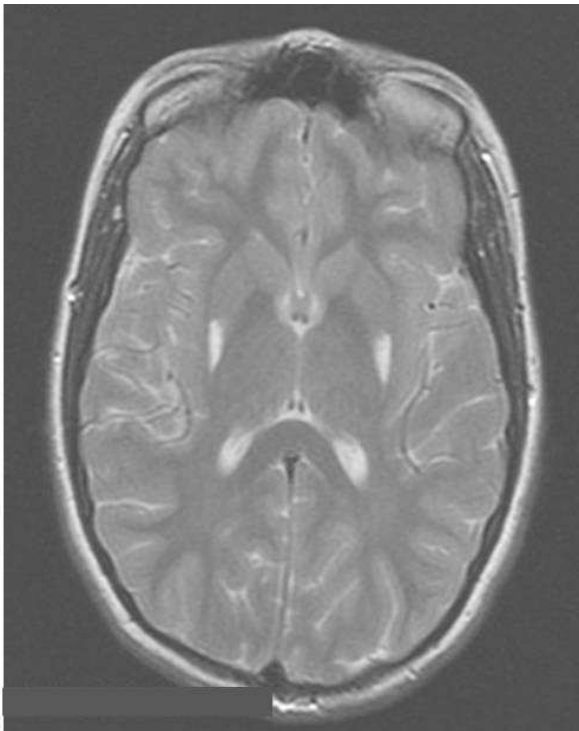


Figure 2.B

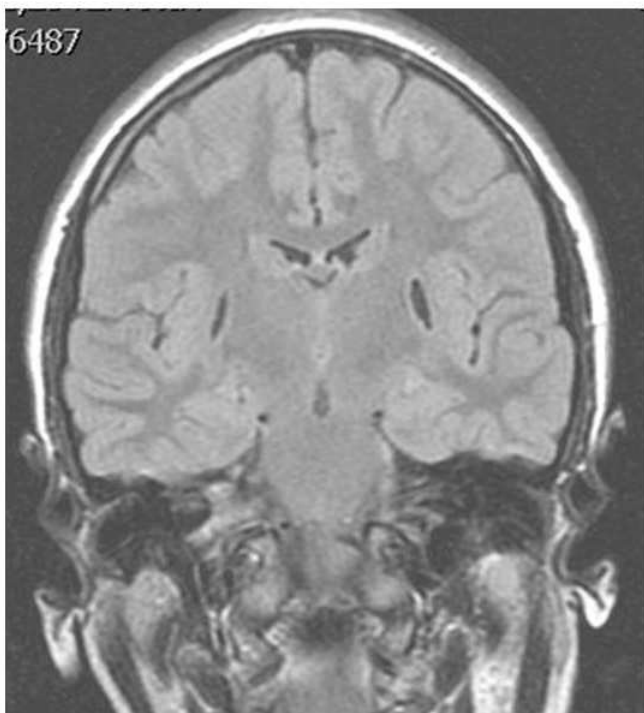


Figure 2.C

Fig. 2. Brain MRI of patient n. 6, fifteen years after clinical presentation. Axial T1 (A) and FLAIR (B), and coronal T2 (C) sequences. The bilateral putamen necrotic areas remain unchanged compared to the previous study.

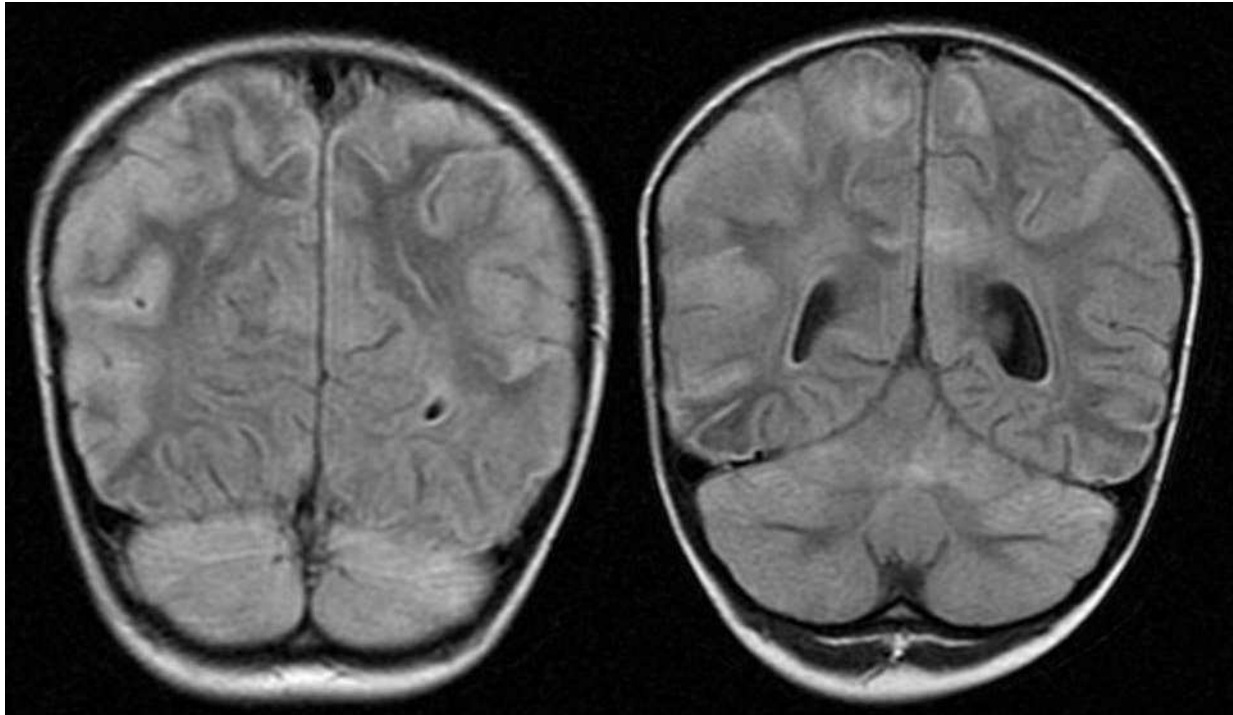


Figure 3.A

Figure 3.B

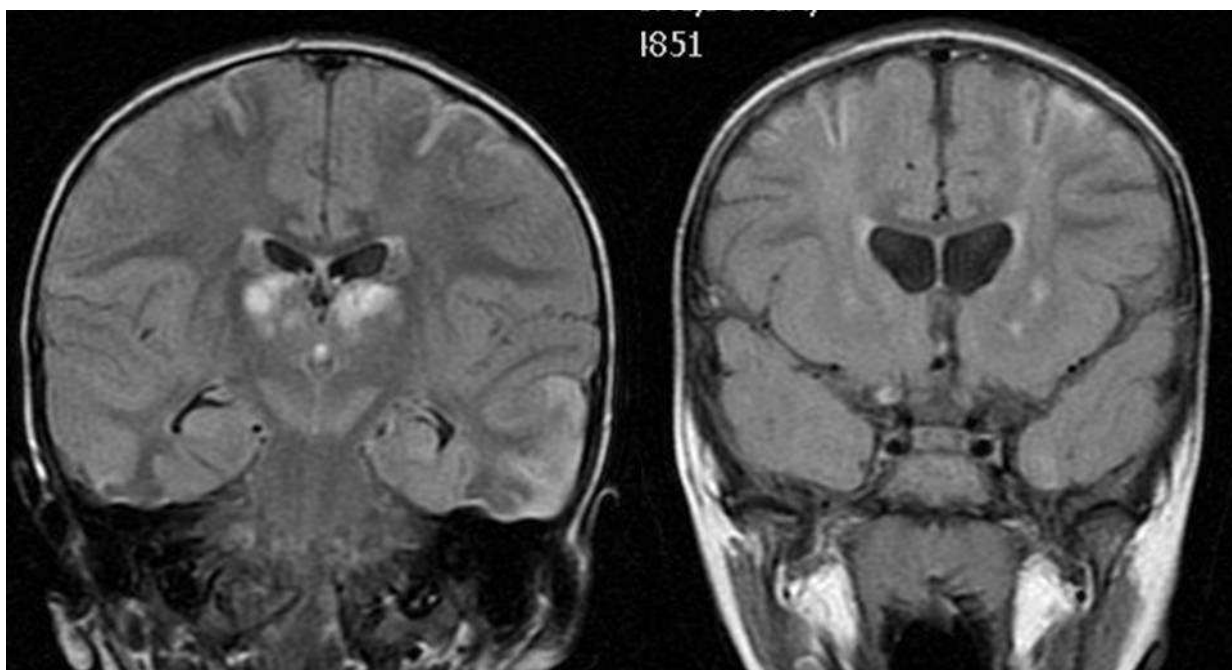


Figure 3.C

Figure 3.D

Fig. 3. Brain MRI of patient n. 21, six days after clinical onset. Coronal FLAIR (A, B, C and D) sequences. Prominence of the convexity sulci and increased ventricular size, consistent with cortico-subcortical atrophy. Bilateral hyperintense areas at the basal ganglia. Multiple cortico-subcortical supratentorial hyperintensities, more subtle at the cerebellar lobes, suggestive of ischemic lesions.

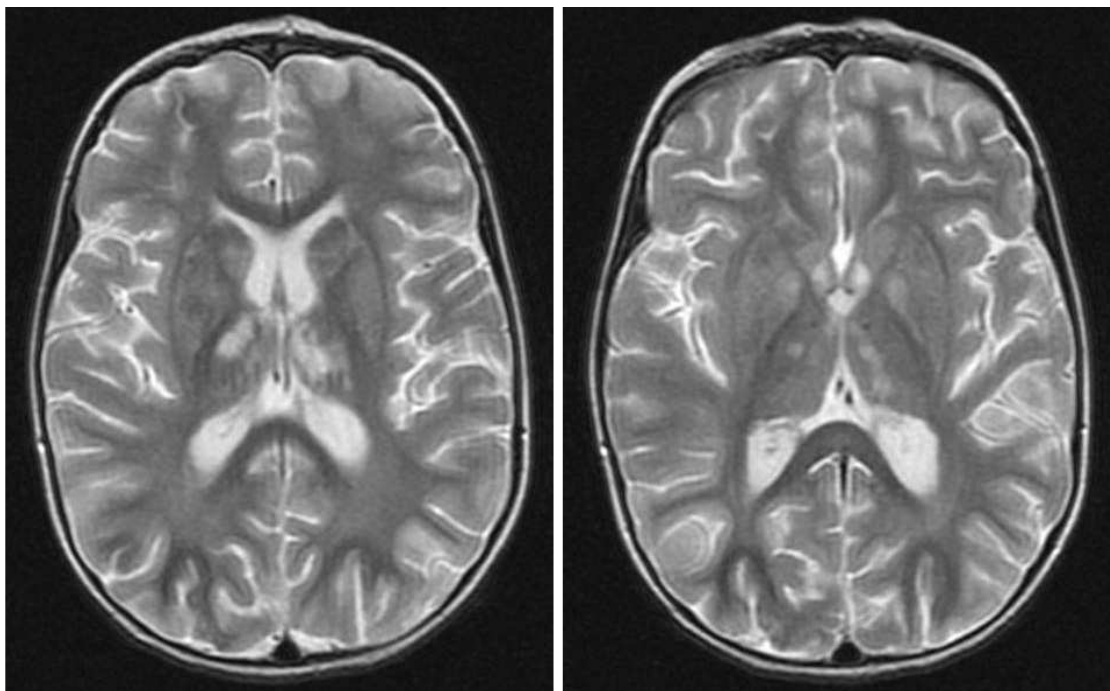


Figure 3.E

Figure 3.F

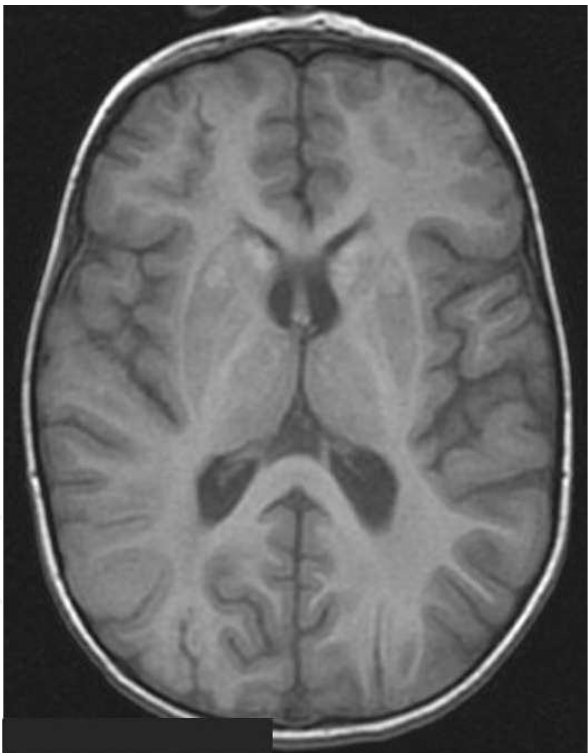


Figure 3.G

Fig. 3. Brain MRI of patient n. 21, six days after clinical onset. Axial T2 FS (E, F) and T1 (G) sequences. Prominence of the convexity sulci and increased ventricular size, consistent with cortico-subcortical atrophy. Bilateral hyperintense areas at the basal ganglia. Multiple cortico-subcortical supratentorial hyperintensities, milder at the cerebellar lobes, suggestive of ischemic lesions.

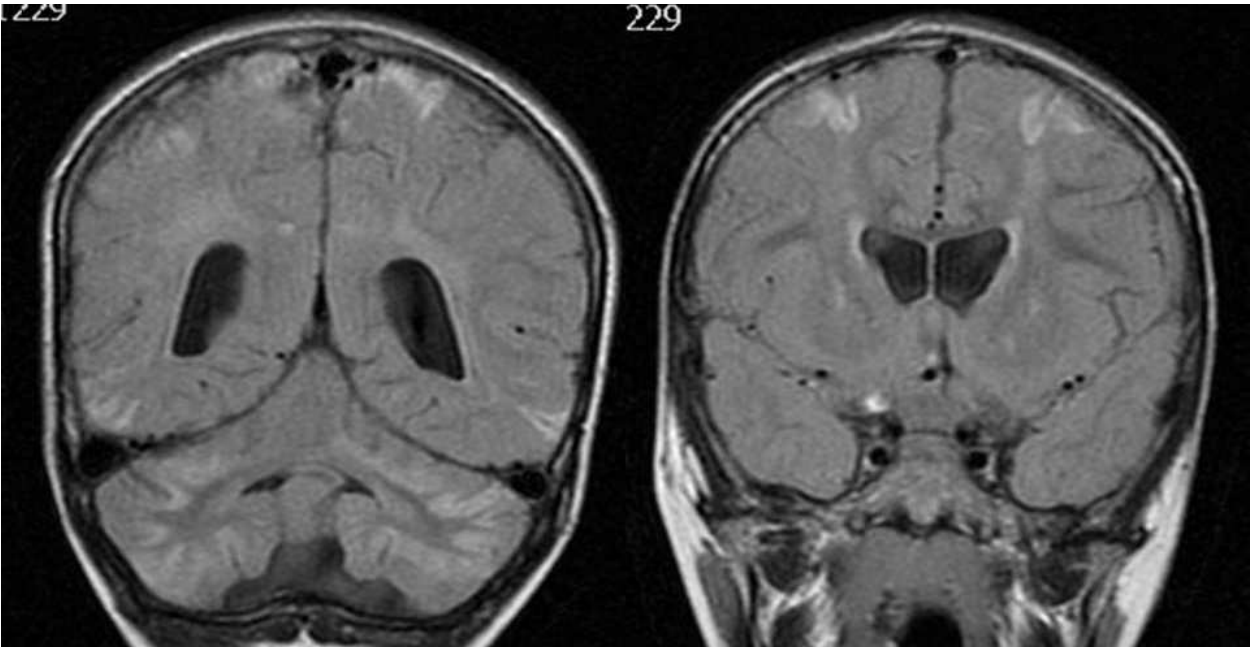


Figure 4.A

Figure 4.B

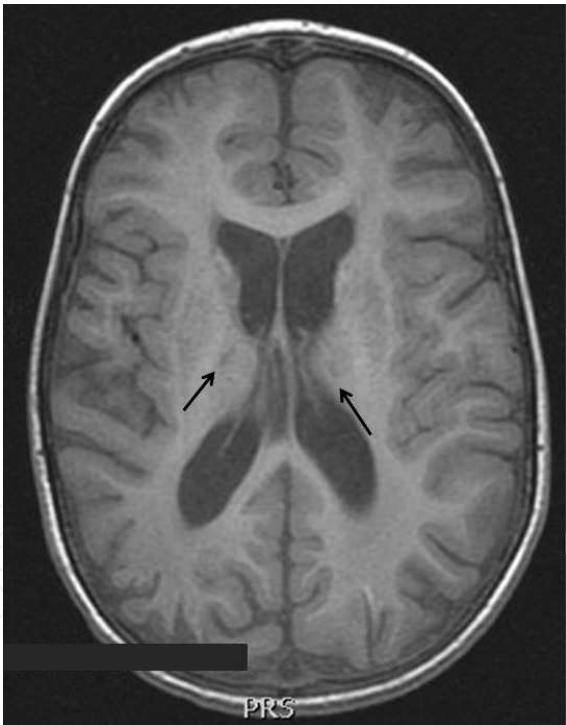


Figure 4.C

Fig. 4. Brain MRI of patient n. 21, 6 months after clinical onset. Coronal FLAIR sequences (Figures A and B). Increased ventricular size, bilateral hyperintense areas at the basal ganglia and multiple cortico-subcortical supratentorial hyperintense images, milder at cerebellar lobes, suggestive of subacute ischemic lesions, with laminar cortical necrosis. Axial T1 sequence (C) showing basal ganglia necrosis (arrows) and cortico-subcortical atrophy.

Patient	Diagnostic Test	Medium-term outcome	Long-term outcome
1	No	Normal	Normal
2	No	Normal	Normal
3	No	Normal	Normal
4	Transfontanellar ultrasound* Pathology	Exitus in the acute phase	Exitus in the acute phase
5	No	Normal	Normal
6	EEG* Brain MRI* Renal biopsy. Heart Doppler and EKG	Left hemiplegia Hypertensive retinopathy Renal function worsening Hypertrophic cardiomyopathy	Asymptomatic
7	No	Normal	Normal
8	Eye funduscopy	Normal	Normal
9	VEP. ERG. EEG* Brain MRI*. SPECT*	Cognitive and language delay and epilepsy due to cortical dysplasia.	Consistent with his base line neurodevelopment
10	No	Normal	Normal
11	EEG* Brain CT	Slight cognitive delay	Outside follow-up, described as normal
12	No	Normal	Normal
13	No	Normal	Normal
14	No	Normal	Normal
15	Transfontanellar ultrasound EEG*	Learning disability	Normal
16	No	Normal	Normal
17	EEG*	Normal	Normal
18	No	Normal	Normal
19	No	Acute pancreatitis	Normal
20	No	Normal	Normal
21	Brain CT*. Brain MRI* EEG*. VEP*. PEAT	Visual impairment	Slight visual impairment Slightly unstructured EEG
22	Diffusion MRI*. EEG Lumbar puncture Brain medium artery Doppler ultrasound	Visual impairment Cognitive impairment	Normal
23	No	normal	normal
24	Brain MRI	normal	normal
25	Brain CT	normal	normal

Table 3. Diagnostic tests, medium- and long-term outcome of patients with neurologic symptoms at the acute phase; (*) abnormal test.

Five of the 25 patients with neurologic symptoms at the acute phase showed one or more medium-term neurological deficits (Table 3): 1/5 hemiparesia, 4/5 mild cognitive dysfunction and 2/5 visuo-perception and construction deficits, which almost normalized during long-term follow up. Nineteen of the 25 presented normal neurological examination at hospital discharge, and one year later.

Patient 4 died within the first 15 hours after admission, after a rapidly progressive neurologic deterioration and respiratory arrest. He presented lower limb myoclonias after life rescue. Thorax x-ray revealed right inferior lobe (RIL) pneumonia. Abdomen and transfontanellar US were normal. Pathology studies confirmed RIL pneumonia, severe segmentary glomerular and tubular nephropathy, acute pancreatitis, lung and heart interstitial inflammation, diffuse alveolar damage, intracapillary thrombi in lungs and kidneys, brain cortical necrosis with edema and cerebellar granular necrosis. *Streptococcus pneumoniae* was not identified. This represents a mortality of 1.5% of the HUS patients and 4% of the patients with HUS and neurologic symptoms at onset.

4. Comments

HUS is a multisystemic entity; its incidence in Europe has been sporadic in the past, although recent migration movements have facilitated a relapse of cases in several countries. In general, older patients tend to show milder neurologic symptoms at onset, like drowsiness or irritability, while younger patients, especially under 18 months, tend to present seizures during the acute phase.

Physiopathology is not yet well understood, but experimental and in vivo studies (Ren et al., 1999; Carter, 1986; Cimolai, 1896) have proved that *Escherichia coli* VT induces thrombopenia through consuming, kidnapping, aggregation and platelet dysfunction mechanisms; plasminogen inhibitor activity is also enhanced, and therefore fibrinolysis is inhibited. Released factors such as TNF, IL, FvW monomers, free radicals, thromboxane, etc., provoke endothelial lesions and vasculitic events in several organs, especially kidneys, digestive system and brain (Seth et al., 1896; Miller & Kin, 1987; Montoliu, 1989; Hahn et al., 1989; Erikson et al., 2001; Steinborn et al., 2004; Rivero et al., 2004). VT receptors are present in various troncoencephalic nuclei, the amygdala and the hippocampus, and in the posterior root neurons of the ganglia. This suggests VT may induce primary neuronal damage as well as a vasculitic lesion (Hahn et al., 1989; Hamano et al., 1993; Rivero et al., 2004). This probably happens also at the basal ganglia, especially at putamen nucleae, the most frequent localization of CNS lesions (Nakamura et al., 2003). The vasculitic damage (due to the diffuse hypoxic-ischemic aggression) observed in our patients was mainly localized at cortico-subcortical areas and the basal ganglia, as described in previous reports (Ren et al., 1999; Akasaka et al., 1999; Garel et al., 2004). Clinical course of patients with these lesions was favorable, and MRI lesions became smaller on follow-up controls. Brain MRI sequenced controls of patients 6 and 21 reinforce the hypothesis of vasculitic lesion as the main cause of tissue damage, although direct neuronal toxicity could not be disclosed (Hahn et al., 1989). In contrast with previous reports (Theobald et al., 2001), basal ganglia necrosis has not proved to be a bad prognosis factor in our series: our patients did not present extrapyramidal signs, as other authors have reported (Di Mario et al., 1987; Barnett et al., 1995).

Unfavorable neurologic outcome was formerly correlated with seizures at onset of symptoms and plasmapheresis (unnecessary for our patients) at diagnosis (Cimolai et al.,

1986). The nine patients who presented seizures at onset survived without long-term sequelae, whereas the only exitus presented initial drowsiness and rapidly progressive neurologic deterioration, without seizures (myoclonias happened after resuscitation maneuvers). This was the only patient with neurologic symptoms, acute pancreatitis, endocarditis and RIL pneumonia; *Streptococcus pneumoniae* was not detected (De Loos et al., 2002; Prestidge & Wong, 2009). Neurologic evaluation and follow-up of patients with CNS symptoms allowed early detection of subtle vision dysfunction, visual perception deficit, and mild cognitive disabilities.

Incidence of neurologic symptoms in acute phase of HUS in this group (39%) was similar to former descriptive studies (Sheth et al., 1986; Hahn et al., 1989; Garel et al., 2004; Steinborn et al., 2004); orolingual dystonia was previously observed, but cortical blindness, hallucinations (Cimolai et al., 1896) and cerebellar mutism/anarthria (Mewasingh et al., 2003) were not observed in our group. A slightly higher prevalence in girls was identified (boy/girl rate 1:1.2), as reported by other authors (Cimolai et al., 1986; Rivero et al., 2004; Zambrano et al., 2005); this rate is increased to 1:1,7 when regarding the neurologic patients, perhaps related to specific auto-immune characteristics.

It was previously reported that HUS patients with partial seizures tend to present epilepsy or abnormal movements after HUS recovery (Dhuna et al., 1992; Hue et al., 1992; Koehl et al., 2010). However, none of our patients developed abnormal movements during medium- and long-term follow-up, and seizures or EEG abnormalities at the acute phase did not determine a poor outcome (only the patient with previously diagnosed cortical dysplasia presented focal seizures).

SHU mortality has decreased in recent years, from 25% in the 1980s to 2% in more recent publications (Rivero et al., 2004). Despite this low mortality rate, a small percentage of patients with neurological symptoms at the acute stage subsequently present neurological sequelae. In our series of 25 children with neurological symptoms, one patient died and 5 had medium-term neurological complications (hemiparesia, cognitive delay or visual perception deficit). The rates of medium-term neurologic morbidity (20%) and mortality (4%) were similar to those of other authors (Hahn et al., 1989; Erikson et al., 2001). Only in one patient after 3 years of follow-up were there persistent minor neurological sequelae (slight cognitive, visual perception and visual construction impairments), with gradual improvement despite the absence of significant changes on MRI and visual evoked potentials monitoring. Although neurocognitive impairment is not frequently reported in HUS (Roche et al., 2008), neuropsychological evaluation and follow-up of these children, especially when basal ganglia (mainly putamen) and cortico-subcortical regions are damaged at the initial brain MRI, helps to identify neurocognitive disabilities. Even if they are not severe, a good neurofunctional diagnosis and rehabilitation can help patients with their school performance and day-to-day life.

5. Conclusions

In summary, HUS is not yet completely understood from a physiological point of view. The most common neurological manifestations in the acute phase are drowsiness, stupor, irritability and convulsions. Neurological morbidity is important: it affects 20% of children with acute neurological presentation (8% of all patients with HUS). Seizures at presentation were not a risk factor for poor outcome in our series. Electrophysiological abnormalities at the acute phase tend to normalize; when they persist, clinical expression

is very subtle. Importantly, brain lesions may persist during follow-up despite clinical recovery. No clear correlation can be established between MRI findings and long-term clinical outcome. Neurocognitive evaluation of children with neurological impairment in the context of SHU should be part of the medium- and long-term follow-up in these patients.

6. References


- Akasaka N, Hayakawa H, Okugawa T, Kasahara T, Ishikawa N, Tojo M et al. Serial cerebral computed tomography and magnetic resonance imaging in a case of hemolytic uremic syndrome with the complication of the central nervous system due to *Escherichia coli* O157:H7. *No To Hattatsu* 1999;31:565-70
- Barnett ND, Kaplan AM, Bernes SM & Cohen ML. Hemolytic uremic syndrome with particular involvement of basal ganglia and favorable outcome. *Pediatr Neurol* 1995;12:155-58
- Bennett B, Booth T & Quan A. Late onset seizures, hemiparesis and blindness in hemolytic uremic syndrome *Clin Nephrol* 2003;59:196-200
- Cimolai N & Carter JE. Bacterial genotype and neurological complications of *Escherichia coli* O157:H7-associated haemolytic uraemic syndrome. *Acta Paediatr* 1986;87:593-94
- Cimolai N, Morrison BJ & Carter JE. Risk factors for the CNS manifestations of gastroenteritis associated HUS. *Pediatrics* 1992;90:616-21
- De Loos F, Huijben K, van der Kar NCAJ, Monnens LAH, van den Heuvel LPWJ, Groener JEM et al. Hemolytic uremic syndrome attributable to *Streptococcus pneumoniae* infection: a novel cause for secondary protein n-glycan abnormalities. *Clinical Chemistry* 2002 48;781-84
- Dhuna A, Pascual-Leone A, Talwar D & Torres F. EEG and seizures in children with hemolytic-uremic syndrome. *Epilepsia* 1992;33:482-86
- DiMario FJ Jr, Brönte-Stewart H, Sherbotie J & Turner ME. Lacunar infarction of the basal ganglia as a complication of hemolytic-uremic syndrome. MRI and clinical correlations. *Clin Pediatr (Phila)* 1987;26:586-89
- Exeni R. Aspectos Clínicos del Síndrome Hemolítico Urémico.
<http://www.medwave.cl/congresos/2nefro2001>
- Erikson KJ, Boyd SG & Tasker RC. Acute neurology and neurophysiology of haemolytic-uraemic syndrome. *Arch Dis Child* 2001;84:434-35
- Garel L, Vázquez E & Lucaya J. Clinical quiz. *Pediatr Radiol* 2004;34:92-93
- Gómez-Lado C, Martínón-Torres F, Álvarez-Moreno, Eiris-Puñal J, Carreira-Sande N, Rodríguez-Núñez A & Castro-Gago M. Leucoencefalopatía posterior reversible: una complicación infrecuente en el curso del síndrome hemolítico urémico. *Rev Neurol* 2007;44:475-78
- Hahn JS, Havens PL, Higgings JJ, O'Rourke PP, Estroff JA & Strand R. Neurological complications of hemolytic-uremic syndrome. *J Child Neurol* 1989;4:108-13
- Hamano S, Nakanishi Y, Nara T, Seki T, Ohtani T, Oishi T et al. Neurological manifestations of hemorrhagic colitis in the outbreak of *Escherichia coli* O157:H7 infection in Japan. *Acta Paediatr* 1993;825:454-58

- Hue V, Leclerc F, Martinot A, Vallee L & Saunier P. Striatal involvement with abnormal movements in hemolytic-uremic syndrome. *Arch Fr Pediatr* 1992;49:369-71
- Kitamura M, Furusu A, Hirose M, Nishino T, Obata Y, Uramatsu T & Kohno S. A case of reversible posterior leukoencephalopathy syndrome in a patient on peritoneal dialysis. *Clin Exp Nephrol* 2010;14:633-36
- Koehl B, Boyer O, Biebuyck-Gougé N, Kossorotoff M, Frémeaux-Bacchi V, Boddaert N & Niaudet P. Neurological involvement in a child with atypical hemolytic uremic syndrome. *Pediatr Nephrol* 2010;25:2539-42
- Miller K, Kin Y. Hemolytic Uremic Syndrome. In: Holliday AA, Martin Barrat J & Vernier RK. *Pediatric nephrology*, 2nd ed. Baltimore, USA: Williams and Wilkins, 1987: 482-89
- Mewasingh LD, Kadhim H, Christophe C, Christiaens FJ & Dan B. Nonsurgical cerebellar mutism (anarthria) in two children. *Pediatr Neurol* 2003;28:59-63
- Montoliu J. Microangiopatía trombótica. Síndrome urémico-hemolítico y púrpura trombótica trombocitopénica. *MTA Medicina Interna* 1989;7:517-46
- Nakamura H, Takaba H, Inoue T, Saku Y, Saito F, Ibayashi S & Fujishima M. MRI findings of hemolytic uremic syndrome with encephalopathy: widespread symmetrical distribution. *J Neuroimaging* 2003;13:75-78
- Pérez del Campo Y, Espinosa López DM., Florín Yrabien J, Levy ON, Alvarez Arias CZ & Infante Velázquez E. Síndrome hemolítico urémico: Aspectos epidemiológicos y patogénicos. *Rev Cubana Pediatr* 2000;3:203-13
- Prestidge C & Wong W. Ten years of pneumococcal-associated haemolytic uraemic syndrome in New Zealand children. *J Paediatr Child Health* 2009;45:731-5
- Ren J, Utsunomiya I, Taguchi K, Ariga T, Tai T, Ihara Y & Miyatake T. Localization of verotoxin receptors in nervous system. *Brain Research* 1999;825:183-88
- Rivero MA, Padola NL, Etcheverría AI & Parma AE. Escherichia coli enterohemorrágica y síndrome hemolítico urémico en Argentina. *Medicina (Buenos Aires)* 2004;64:352-56
- Roche Martínez A, Póo P, Maristany-Cucurella M, Jiménez-Llort A, Camacho JA & Campistol J. Neurologic presentation in haemolytic-uraemic syndrome. *Rev Neurol* 2008 16-31;47:191-96
- Scheiring J, Rosales A & Zimmerhackl LB. Clinical practice. Today's understanding of the haemolytic uraemic syndrome. *Eur J Pediatr* 2010;169:7-13
- Skerka C, Jazsi M, Zipfel PF, Dragon-Durey MA & Fremeaux-Bacchi V. Autoantibodies in haemolytic uraemic syndrome (HUS). *Thromb Haemost* 2009;101:227-32
- Sheth KJ, Swick HM & Haworth N. Neurological involvement in HSU. *Ann Neurol* 1986;19:90-93
- Steinborn M, Leiz S, Rüdiger K, Griebel M, Harder T & Halm H. CT and MRI in haemolytic uraemic syndrome with central nervous system involvement: distribution of lesions and prognostic value of image findings. *Pediatr Radiol* 2004;34:805-10
- Theobald I, Kuwertz-Bröking E, Schiborr M & Heindel. Central nervous system involvement in hemolytic uremic syndrome (HUS), a retrospective analysis of cerebral CT and MRI studies. *Clin Nephrol* 2001;56:S3-8

Zambrano O, Deluchi B & Hevia J. Síndrome hemolítico urémico en Santiago de Chile: Evolución de la función renal y factores pronósticos. *Rev Chil Pediatr* 2005;76: 48-56

IntechOpen

IntechOpen



Neuroimaging for Clinicians - Combining Research and Practice

Edited by Dr. Julio F. P. Peres

ISBN 978-953-307-450-4

Hard cover, 424 pages

Publisher InTech

Published online 09, December, 2011

Published in print edition December, 2011

Neuroimaging for clinicians sourced 19 chapters from some of the world's top brain-imaging researchers and clinicians to provide a timely review of the state of the art in neuroimaging, covering radiology, neurology, psychiatry, psychology, and geriatrics. Contributors from China, Brazil, France, Germany, Italy, Japan, Macedonia, Poland, Spain, South Africa, and the United States of America have collaborated enthusiastically and efficiently to create this reader-friendly but comprehensive work covering the diagnosis, pathophysiology, and effective treatment of several common health conditions, with many explanatory figures, tables and boxes to enhance legibility and make the book clinically useful. Countless hours have gone into writing these chapters, and our profound appreciation is in order for their consistent advice on the use of neuroimaging in diagnostic work-ups for conditions such as acute stroke, cell biology, ciliopathies, cognitive integration, dementia and other amnesic disorders, Post-Traumatic Stress Disorder, and many more

How to reference

In order to correctly reference this scholarly work, feel free to copy and paste the following:

Ana Roche Martínez, Pilar Póo Argüelles, Marta Maristany Cucurella, Antonio Jiménez Llort, Juan A Camacho and Jaume Campistol Plana (2011). Haemolytic-Uraemic Syndrome: Neurologic Symptoms, Neuroimaging and Neurocognitive Outcome, Neuroimaging for Clinicians - Combining Research and Practice, Dr. Julio F. P. Peres (Ed.), ISBN: 978-953-307-450-4, InTech, Available from:

<http://www.intechopen.com/books/neuroimaging-for-clinicians-combining-research-and-practice/haemolytic-uraemic-syndrome-neurologic-symptoms-neuroimaging-and-neurocognitive-outcome>

INTECH
open science | open minds

InTech Europe

University Campus STeP Ri
Slavka Krautzeka 83/A
51000 Rijeka, Croatia
Phone: +385 (51) 770 447
Fax: +385 (51) 686 166
www.intechopen.com

InTech China

Unit 405, Office Block, Hotel Equatorial Shanghai
No.65, Yan An Road (West), Shanghai, 200040, China
中国上海市延安西路65号上海国际贵都大饭店办公楼405单元
Phone: +86-21-62489820
Fax: +86-21-62489821

© 2011 The Author(s). Licensee IntechOpen. This is an open access article distributed under the terms of the [Creative Commons Attribution 3.0 License](https://creativecommons.org/licenses/by/3.0/), which permits unrestricted use, distribution, and reproduction in any medium, provided the original work is properly cited.

IntechOpen

IntechOpen