

We are IntechOpen, the world's leading publisher of Open Access books Built by scientists, for scientists

6,900

Open access books available

186,000

International authors and editors

200M

Downloads

Our authors are among the

154

Countries delivered to

TOP 1%

most cited scientists

12.2%

Contributors from top 500 universities



WEB OF SCIENCE™

Selection of our books indexed in the Book Citation Index
in Web of Science™ Core Collection (BKCI)

Interested in publishing with us?
Contact book.department@intechopen.com

Numbers displayed above are based on latest data collected.
For more information visit www.intechopen.com



Mucous Cysts as a Complication of Rhinoplasty

Aris Ntomouchtsis¹, Nikos Kechagias¹, Persefoni Xirou²,
Georgios Christos Balis², Katerina Xinou³ and Konstantinos Vahtsevanos¹
¹*Department of Oral and Maxillofacial Surgery, Theagenion Cancer Hospital, Thessaloniki*
²*Department of Histopathology, Theagenion Cancer Hospital, Thessaloniki*
³*Department of Radiology, Theagenion Cancer Hospital, Thessaloniki*
Greece

1. Introduction

Aesthetic and reconstructive surgery of the nose remains the most challenging and difficult of all head and neck plastic surgical operations. (Tardy, 1995) Rhinoplasty is considered as a highly demanding procedure. The nose is the most prominent part of the face and derogations may be less appropriate than deviations.

Complications can refer either to the skeletal framework or to the soft-tissue regions and they can be divided into functional and aesthetical. According to the time of presentation they can be intraoperative or postoperative early or late complications.

Implantation cysts and deforming masses are infrequent and very rare, but avoidable complications of rhinoplasty. Displacement of fragments of epithelium may result in subcutaneous graft entrapment and subsequent encystation. Epidermoid cysts or mucous cysts may be developed, depending on the type of epithelium trapped. They must be addressed with a thorough evaluation of the extent of the lesion to choose the most appropriate procedure for removal. Knowledge of the various capabilities and presentations of postrhinoplasty cysts, will better equip surgeons for a successful outcome. Although a mucous cyst is a benign lesion, it is considered to be a serious complication of rhinoplasty. Mucous cysts are presented in many locations and ages, with a wide range of concurrent symptoms. Most of them are appeared several months or years after rhinoplasty.

Complete resection of the mucous cyst is the gold standard of treatment. Identification of involved structures will ensure appropriate procedure selection. Almost all the cases reported in the literature have been described as solitary lesions which were successfully eradicated following a single surgical procedure.

There was only one paper reported a case of a patient who had presented two mucous cysts, the first one two months postoperatively and the second one five months after surgical extirpation (Mouly, 1970), and only two authors reported recurrence after surgical intervention. (Zijlker and Vuyk, 1993; Ntomouchtsis et.al. 2010) Regarding the high number of rhinoplasty procedures performed worldwide every year, the number of the 30 published cases is on the contrary very low. These observations make it possible that specific local conditions must exist before a mucous cyst may be expected to develop and one important factor is likely to be the size of the displaced epithelial fragment. There is also exists the possibility that all occurred complications have not been presented yet.

It is interesting that there have been two reports of respiratory implantation cysts of the mandible following combined rhinoplasty and genioplasty, where the chin augmentation is achieved using osteocartilagenous grafts harvested from the nasal dorsum. (Anastassov and Lee, 1999; Imholte and Schwartz, 2001)

A thorough evaluation of the extent of the lesion is the best way for the surgeon to choose the most appropriate procedure for removal.

2. Clinical signs and differential diagnosis

Patients normally complain about a gradually swelling mass in the operation field or in its proximity. They may also feel continuous pressure over the lesion. Cysts may be featured as circular, mobile and non tender mass when they are palpated. Otherwise it can be an immobile, painless, soft smooth subcutaneous mass fixed to the skin and to the deep planes. The overlying skin tends to be more vascular than the closest region.

Functional and aesthetic problems could be caused by the lesion, such as remarkable asymmetry of the tip and the nostrils, persistent nasal obstruction and increased snoring, impaired nasal breathing and swelling, deviation of the septum and saddle nose deformity. Symptoms and signs of inflammation, like infection and abscess formation, can accompany the mass. (Zijlker and Vuyk, 1993; Flaherty et al., 1996; Kotzur and Gubisch, 1997; Bracaglia et al., 2005; Tastan et al., 2010) It has been reported that antibiotics have managed to halt the enlargement but can not always achieve resolution of the cysts. (Shulman and Westreich, 1983; Dini, 2001)

The main differential diagnosis of mucous cyst must also includes other entities beyond infections, such as lipogranulomas/ paraffinomas, which are thought to represent foreign body reactions to displaced lipid ointment from nasal packings through intranasal incisions. (Gryskiewicz, 2001) Other various benign tumor-like nasal lesions must be taken under consideration, such as epidermoid inclusion cysts, tumefactive cartilage proliferation, osteomas, lipomas, pleomorphic salivary adenomas, granulomatous diseases. Congenital midline nasal masses including, gliomas, encephaloceles, and nasal dermoid sinus cysts are reported to occur. Lesions such as inverting papillomas, juvenile nasopharyngeal angiofibroma, ethesioneuroblastoma and even frontal sinus mucoceles must be excluded. (Baarsma, 1980; Hacker and Freeman, 1994; Romo T 3rd et al. 1999) It could be harmful to misdiagnose malignant neoplastic lesions that can involve the nasal region such as squamous cell carcinoma, malignant melanoma, adenocarcinoma, sarcoma, and lymphoma. Clinical examination, nasal endoscopy, imaging studies and finally cytology or/and histological analysis after biopsy will define the possible diagnosis.

The sites of mucous cyst occurrence can vary. The majority of these these cysts occur over the nasal bone along the line of nasal osteotomy, with the nasal dorsum being the most affected site. **Table 1.** In few cases, rare locations have been described, including paranasally along the maxillary osteotomy, (Karapantzios et al., 1999; Raine et al., 2003), the lateral wall, the tip of the nose, the alar, the inner canthus, the radix nasi, and even the glabellar region. (Mouly, 1970; Rettinger and Zenkel, 1997; Bracaglia et al. 2005; Riedel et al. 2007; Pausch et al. 2010; Ntomouchtsis et al. 2010; Dionyssopoulos et al. 2010)

3. Radiologic findings

The list of differential diagnoses ranges from postoperative nasal lesions, various other benign, congenital, infectious or neoplastic processes unrelated to surgery.

A/A	Author	Year	Sex/Age	Location	Duration	Rhinoplasty
1	McGregor	1958	N.A.	Dorsum	5 days	Direct open
2	Mouly	1970	F/N.A.	Canthus inner bilateral	2m & 5m	Direct open
3	Senechal	1981	M/31	Radix	10y	Direct open
4	» »	» »	F/44	Paranasal	8y	Direct open
5	Shulman	1983	F/32	Dorsum/Tip	2m	closed
6	Lawson	1983	M/28	Dorsum	Several m	Direct open
7	Harley	1990	F/27	Dorsum	6y	closed
8	» »	» »	M/22	Dorsum	10m	closed
9	Toriumi	1990	N.A	N.A	N.A	N.A
10	Zijlker	1993	F/31	Dorsum	1y	open
11	Flaherty	1996	F/24	Dorsum	5y	closed
12	Kotzur	1997	M/45	Dorsum	6y	Direct open
13	» »	» »	M/23	Dorsum	4y	closed
14	» »	» »	M/24	Dorsum	2y	closed
15	Rettinger	1997	M/N.A	Alar lateral	1y	Direct open
16	Karapantzios	1999	M/25	Paranasal	3m	Direct open
17	Romo	1999	M/33	Dorsum	2y	Direct open
18	Tan Ergin	2000	M/47	Dorsum	6m	Direct open
19	Dini	2001	M/29	Dorsum	3m	Direct open
20	Raine	2003	F/58	Paranasal	20y	close
21	Liu	2003	M/33	Dorsum	7y	Direct open
22	Bracaglia	2005	F/30	Lateral Wall	2m	Endoscopic
23	» »	» »	F/38	Radix	1y	Endoscopic
24	Riedel	2007	F/34	Lateral Wall	6m	close
25	Pausch	2010	F/17	Dorsum	14m	open
26	» »	» »	F/19	Alar lateral	1y	open
27	Struijs	2010	M/64	Dorsum	40y	open
28	Tastan	2010	F/25	Tip	1y	open
29	Dionyssopoulos	2010	F/26	Glabella	22m	Direct open
30	» »	» »	F/20	Canthus inner	6 m	open
31	Ntomouchtsis	2010	F/29	Glabella	15m	Direct open

Table 1. Table of all published cases in the English literature

Preoperative assessment with computed tomography and/or magnetic resonance imaging can help narrow the differential diagnosis by evaluating the nature of contents within the

mass and the possibility of bony or intracranial involvement. (Leong and Sharp, 2009) CT assesses for any bony involvement, while MRI gives better definition of soft tissues and is likely the best method for detecting intracranial masses. (Barkovich et al., 1991)

A CT scan or magnetic resonance imaging is needed to determine the extent of the lesion and thus the best surgical approach. Magnetic resonance imaging gives a more detailed image and has fewer false-negatives and fewer false-positives than CT. (Zerris et al., 2002)

Only 3 of the 31 reported cases have described the radiological (CT or MR) features of postrhinoplasty mucous cysts. (Raine et al., 2003; Leong and Sharp, 2009; Ntomouchtsis et al., 2010)

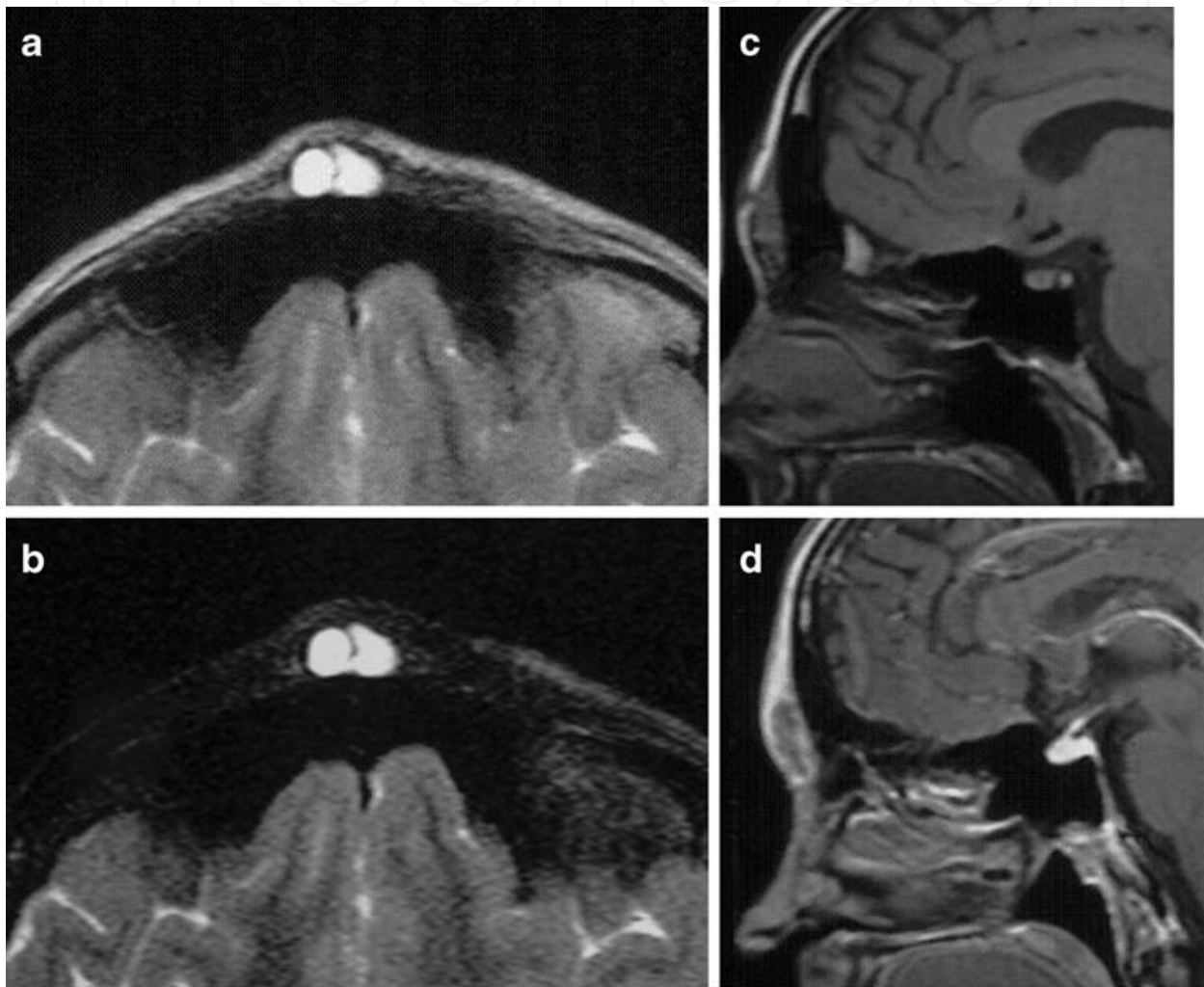


Fig. 1. a-d Brain MRI showing an oval-shaped subcutaneous cystic lesion in the midline, in front of the frontal sinuses. The lesion shows homogeneously high signal intensity in axial T2 (a) and STIR images (b), low signal intensity in sagittal T1-weighted image (c), and peripheral enhancement in sagittal T1-weighted image after gadolinium injection (d)

A CT scan or magnetic resonance imaging is needed to determine the extent of the lesion and thus the best surgical approach. Magnetic resonance imaging gives a more detailed image and has less false-negatives and less false-positives than CT. (Zerris et al., 2002) CT assess for any intracranial connection. MRI which gives better definition of soft tissues is likely the best method for detecting intracranial masses. (Barkovich et al., 1991)

Mucous cysts usually appear as well-defined, homogenous, non-enhancing or peripherally enhancing lesions with no bony destruction and without any intracranial communication. The content of these cysts is mostly hypointense in CT, and shows low to intermediate signal in T1-weighted and high signal in T2-weighted images in MR. (Koeller et al., 1999; Leong and Sharp, 2009; Ntomouchtsis et al., 2010) Unfortunately, these findings are not specific because they can be encountered also in foreign body inclusion cysts (Pausch et al., 2010), epidermoid cysts and sebaceous cysts. Raine et al described a case of a mucous cyst, which appeared as a well-defined hypointense soft tissue mass in CT with no bony elements, findings more consistent with a fibrous or granulomatous lesion. (Raine et al., 2003)

The differential diagnosis of mucous cysts from paraffinomas, dermoid cysts and lipomas is easier, because the latter are fat-containing hypointense lesions in CT, usually showing high signal in T1- and T2-weighted images in MR. (Koeller et al., 1999; Liu et al., 2003)

Therefore, CT and MR imaging is helpful in the preoperative evaluation of a post-rhinoplasty lesion, because it can demonstrate the benign nature and the cystic content of the mass, excluding other benign non-enhancing lesions (granuloma, sebaceous cyst, dermoid cyst, lipoma), solid enhancing lesions (traumatic aneurysm, hemangioma, neurofibroma, lymphoma, basal cell carcinoma, metastasis) or lesions that cover underlying calvarial masses (eosinophilic granuloma, meningioma, metastasis). Color Doppler ultrasonography can also be used in differential diagnostic problems of cystic lesions as an alternative of MRI. (Riedel et al., 2007) If any concern exists as to the possible diagnosis, a preoperative biopsy should be considered.

4. Surgery

Surgical eradication remains the appropriate treatment for mucous cysts of the nose. Complete resection avoiding rupture is curative. The surgical procedure is dependent on the location and extent of the lesion and on patient age. The reconstruction of the intraoperatively resulting defect is a challenging problem, which has to be solved, mainly from a aesthetic point of view.

Many surgical approaches have been described and successfully attempted as presented in the literature. Endonasal intercartilaginous and intracartilaginous incisions, although they offer limited exposure, they have been used successfully for mucous cysts involving the tip and supratip regions. (Flaherty et al., 1996; Kotzur and Gubisch, 1997; Shulman and Westreich, 1983; ; Dionyssopoulos et al. 2010) Extracolumellar incision is used for an open rhinoplasty technique. It gives excellent exposure for complete extirpation of the lesion and reconstruction of the defect and leaves inconspicuous scars in the long run. Incision through the overlying skin of the lesion permits direct and excellent exposure but must be considered as a third option due to visible scars are leaved.

The direct percutaneous approach, even when a geometrically broken line incision is used, may result in a visible scar. There has even been an endoscopic approach proposed. (Bracaglia et al., 2005)

The open approach through the existing scars should be preferred for revision of rhinoplasty in cleft lip patients. (Pausch et al., 2010)

Dorsal nasal cysts formation is prevented by extremely meticulous removal of all debris from the operative site by suction and submucosal separation of the upper lateral cartilages. There are two ways of dealing with the upper lateral cartilages where they are attached to the septum. The mucosa can either be detached and left intact or released by a transmucosal

incision by using “junction tunnels”, which preserve the mucosa. The mucoperichondrium and mucoperiosteum are elevated bilaterally at the junction of the septum with the nasal wall. The upper lateral cartilage is released by preserving the mucosal integrity through submucosal dissection. Entrapment of mucosa and formation of nasal cysts should be prevented by maintaining intact the mucosal integrity under osteotomy or cartilage incision sites. (Johnson and Anderson, 1977; Ress, 1980) Creation of dead space is declined by trying to avoid undermining osteotomy sites.

Irrigation at the end of the procedure can provide additional clearing of remnants from the surgical field. Careful removal of all mucosal fragments from the osteotomy sites at the time of primary surgery is mandatory and can be preventative.

Complete surgical extirpation of cysts may lead to disfigurement of the nasal framework.

Direct reconstruction of the defect sets the goal of surgical treatment of this rare condition. Cartilaginous grafts (e.g., rib or concha grafts) are recommended for reconstruction of the nasal frame in such cases.

5. Intraoperative findings

On exploration the cystic mass could appear as a distinct capsule with no direct connection between it and the nasal mucosa, as it has been reported in the majority of the published cases. (Harley and Erdman, 1990; Romo T 3rd et al., 1999) On the other hand the cyst could be found either tightly attached to the surrounding tissues, or adherent to the overlying skin, or in connection with the underlying cartilaginous and bony nasal structures, or even attached to previously used autogenous grafts. (Kotzur and Gubisch, 1997; Tan Ergin and Akkuzu, 2000; Pausch et al., 2010)

The underlying nasal bone or cartilage in the area of the lesion can be depressed with an impression deformity, or eroded or even resorbed. [21,30,31] (Harley and Erdman, 1990; Tan Ergin and Akkuzu, 2000; Pausch et al., 2010)

During the operation the lesion can be removed either intact or perforated. If the latter happens, clear fluid or partly fatty fluid or mucous fluid or even thick white-yellowish liquid usually is yielded from the cystic wall. (Flaherty et al., 1996; Kotzur and Gubisch, 1997; Romo T 3rd et al., 1999)

Dead space or deformity of bone or cartilage could be created in the operation field, after complete cyst removal, which has to be managed through careful suturing in layers and to be repaired, usually by using autogenous graft.

6. Histopathology

Macroscopically a mucous cyst appears as an oval shaped, soft smooth walled cyst, located subcutaneously, easily separated from its surrounding structures and filled with mucinous material. Microscopically the cyst wall is lined by ciliated columnar respiratory type epithelium with dispersed goblet cells. (Ntomouchtsis et al., 2010)

Due to the fact that diagnosis is based primarily on microscopic findings, particularly the lining of the cysts, similar cutaneous cystic formations can enter in the differential diagnosis. Cutaneous ciliated cysts show numerous papillary projections lined by a simple cuboidal or columnar ciliated epithelium, while mucin-secreting cells are absent. These cysts can be found on the lower extremities (females) or on the back (males) and measure several centimeters in diameter. (Elder et al., 2010)

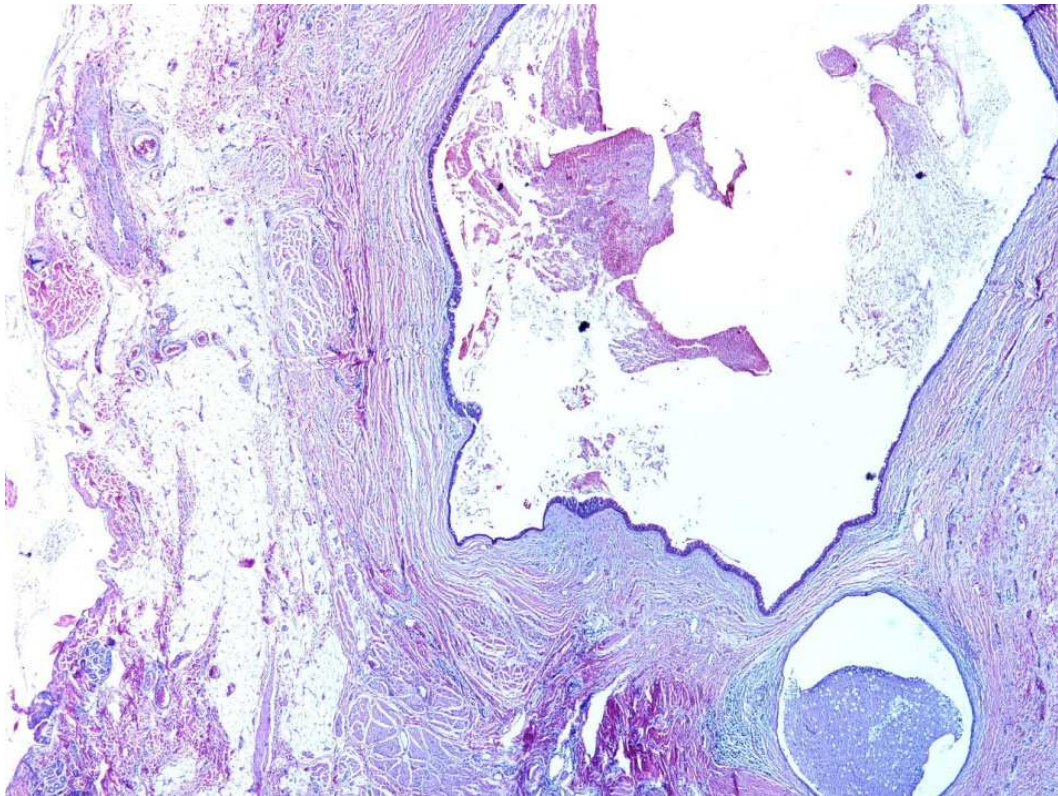


Fig. 2. Cyst filled with mucinous material (H-E ×20)

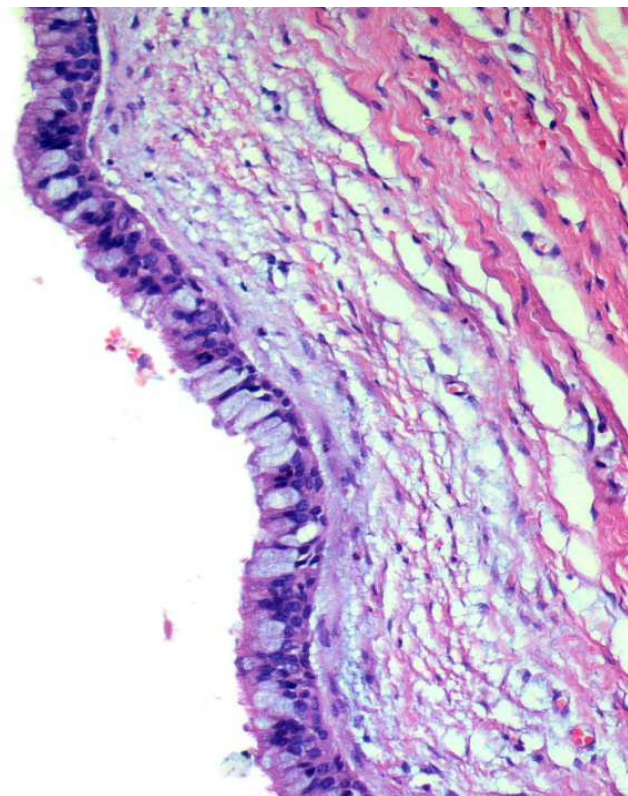


Fig. 3. The cyst wall is lined by ciliated columnar respiratory type epithelium with dispersed goblet cells (H-E ×200)

Bronchogenic cysts are lined by a mucosa consisting of ciliated pseudostratified columnar epithelium, while goblet cells may be interspersed. The wall frequently contains smooth muscle and mucous glands. Thyroglossal duct cysts differ from bronchogenic cysts in that they do not contain smooth muscle and they frequently contain thyroid follicles. Bronchogenic cysts are most commonly seen on the suprasternal notch and rarely on the anterior aspect of the neck or on the chin. Thyroglossal duct cysts are clinically indistinguishable from bronchogenic cysts, except that they are usually located on the anterior aspect of the neck. (Elder et al., 2010)

Apocrine hidrocystoma is a multi-loculated cystic lesion with occasional papillary projections. The inner surface of the cyst and the papillary projections are lined by a row of columnar secretory cells of variable height showing decapitation secretion indicative of apocrine secretion. Peripheral to the layer of secretory cells are elongated myoepithelial cells, their long axes running parallel to the cyst wall. Apocrine hidrocystoma occurs usually as a solitary, translucent cystic nodule on the face and occasionally on the ears, scalp, chest, shoulders, or vulva. Multiple apocrine hidrocystomas are rarely encountered. Frequently, the lesion has a blue hue, while the diameter ranges from 1 to 20 mm. (Elder et al., 2010)

Eccrine hidrocystoma shows a single cystic cavity, while the cyst wall usually shows two layers of small, cuboidal epithelial cells. In some areas, only a single layer of flattened epithelial cells can be seen, their flattened nuclei extending parallel to the cyst wall. Small papillary projections extending into the cavity of the cyst are observed rarely. Eccrine secretory tubules and ducts are often located below the cyst and in close approximation to it, and, on serial sections, one may find an eccrine duct leading into the cyst from below. However, no connection can be found between the cyst and the epidermis. In this condition, usually one lesion -- but occasionally several, and rarely numerous lesions -- are present on the face. As in apocrine hidrocystoma, the lesion consists of a small, translucent, cystic nodule 1 to 3 mm in diameter that often has a bluish hue. (Elder et al., 2010)

Cutaneous metaplastic synovial cysts show villous-like projections and a lining that resembles hyperplastic synovium (not epithelium). This type of cysts is rare and presents months or years after a surgery as solitary tender subcutaneous nodule. The cause of formation of cutaneous metaplastic synovial cysts remains unclear, but previous trauma usually precedes their onset. Taking in consideration this entity is significant, since a recent publication reports a case of cutaneous metaplastic synovial cyst on a patient's face after receiving hyaluronic acid filler injections. (Inchingolo et al., 2010)

Foreign body inclusion cysts, even though called cysts inappropriately, microscopically they represent granulomatous reaction to bone or cartilage fragments following rhinoplasty. [34] (Chang and Jin, 2008)

Follicular cysts (epidermal, trichilemmal, dermoid, etc) can be often found on the face, regardless of any previous intervention, but can easily be excluded from the diagnosis since they are lined by stratified squamous epithelium resembling epidermis and filled with keratinous material. Even though we should be aware of this type of cysts since there have been reports of post rhinoplasty epidermal cysts. (Grocutt and Fatah, 1989; Tastan et al., 2010)

All of the aforementioned cysts show similar clinical or pathological findings with the cutaneous mucous cysts, but a careful histological examination can spot the differences and exclude them from the diagnosis.

In conclusion, histological examination of all cysts that present on the face after an intervention is of paramount importance, not only to exclude malignancy, but also to narrow down the list of differential diagnoses.

7. Theories of creation

The aetiology of this lesion remains unknown and controversial. Different theories of creation exist. The first hypothesis assumes the herniation of nasal mucosa in the direct postoperative period, for example after a patient blew his or her nose. (McGregor et al., 1958) The herniation or subsequent growth of nasal mucosa can take place through the infracture sites or incisions, although no reported cases mentioned any connection of a cyst to the normal mucous layer of the nose. (Mouly, 1970; Harley and Erdman, 1990)

The most reasonable explanation is the proliferation of ectopic or displaced mucous membranes, followed by improper clearing of mucous epithelial remnants and bony or cartilage parts. This seeding of mucous tissue and remnants attached to bone or cartilage either in situ or as a part of an autogenous graft seems to be the main reason for which the mucous grafts grow and proliferate in their ectopic position (Shulman and Westreich, 1983; Harley and Erdman, 1990; Kotzur and Gubisch, 1997; Dini et al., 2001)

Another aspect that has to be emphasized is that in some of the described cases in the literature, the location of appearance does not coincide with the osteotomy lines or even with the intervention field of a rhinoplasty. This could be explained by poor surgical technique during a close rhinoplasty, which can lead to extreme surgical trauma, violation of the intranasal mucosal lining and subsequent encystation of nasal mucosal epithelium, displaced at the time of surgery. (Zijlker and Vuyk, 1993; Dini et al., 2001; Ntomouchtsis et al., 2010) This explains the different locations described in the literature, and the absence of connections with the internal nasal lining that is observed and described during surgical eradication.

On the other hand, the reappearance of a cyst can also be attributed to a faulty surgical technique. (Ntomouchtsis et al., 2010) It is also hypothesized that cysts may develop by occlusion of sebaceous glands because of scar tissue formation. (Rettinger and Zenkel, 1997) In cleft lip nose rhinoplasty, however, cystic masses of the nose might have other origins, so congenital malformations or remnants of the nasolacrimal duct have also been described. Mucous cysts of the nose are not specific complications of cleft nose surgery, although they have been observed in this specific patients group. (Aikawa et al., 2008; Pausch et al., 2010)

8. Prevention

In order to prevent iatrogenic cyst formation it is important to use an appropriate surgical technique. The manoeuvres must be executed carefully with respect to the soft and hard tissues of the operation field. The need for atraumatic and careful tissue dissection has been emphasized by virtually all authors who have described postrhinoplasty mucous cysts.

By preserving the mucosal integrity and using sharp instruments one can hope to avoid the involuntary dispersion of tissues into other layers while dissecting. The mucosal lining must be kept intact during the rhinoplasty, or in any case of disruption a meticulously restoration is mandatory. Mucosal lining can be preserved when subperichondrial and subperiosteal tunnels are being established over the septum and under the nasal dorsum before any surgical alterations will be made to the structures. (Zijlker and Vuyk, 1993) Completing of all osteotomies is also important for maintaining mucosal integrity during intranasal osteotomy and to decrease the chance of cyst formation. The osteotomy sites must be placed properly, and performed with adequate water injection and hydrodissection. The mucosa around the lateral osteotomy site should be elevated, to prevent entrapment. For security

the osteotomy sites should be thoroughly inspected at the completion of the procedure. (Liu and Kridel, 2003).

On the other hand many surgeons prefer not to elevate tunnels, as this additional stripping and dissection of periosteum decreases the structural support of the nasal framework after osteotomies are complete. They report better stability and more predictable outcomes with external perforated osteotomy, by using a small osteotome (2-4 mm) that simultaneously minimize disruption of periosteal surfaces, stabilize medial movement, reduce lateral wall collapse and decreases dead space. (Goldfarb et al., 1993; Rohrich et al., 2001; Rohrich et al., 2003) It has experimentally been shown that this technique decreases soft-tissue disruption or displacement compared to continuous osteotomies. (Byrne et al., 2003) It must also be emphasized that none of the reported postrhinoplasty cysts are connected to this surgical technique.

Meticulous removal of all bony, cartilaginous and mucous remnants is essential. It is essential that if osteocartilagenous grafts are used harvested from the nasal frame they must be prepared by removing the respiratory epithelium prior to implantation. (Raine et al., 2003) Irrigation at the end of the procedure can be an additional measure to clear the surgical field of remnants. (Gryskiewicz, 2001) The created dead space must be closed in layers. Intranasal incisions should be closed properly. Rhinoplasty is a very demanding procedure. In complicated cases, especially in revision surgery, the risk of complications is higher when performed by inexperienced surgeons. The best prevention of mucous cysts occurring after rhinoplasty is not only meticulous elimination of all bony, cartilage, and epithelial tissues and mucous parts, but also, and even more important, emphasis on a most atraumatic and careful operation. (Kotzur and Gubisch, 1997) The key to a good outcome is localizing the lesion and selecting the most appropriate procedure.

9. Conclusion

Relative to the high number of rhinoplasty procedures performed each year worldwide, the number of the 31 presented published cases is on the contrary very low. (Senechal et al., 1981; Lawson et al., 1983; Toriumi and Johnson, 1990; Struijs and Bauwens, 2010) The only data reported regarding the frequency of postrhinoplasty mucous cysts are from two case reports, where there are counts 1/6000 and 3/5000, a percentage of 0.02 and 0.06 respectively. (Kotzur and Gubisch, 1997; Dini et al., 2001) Otherwise there is a large number of unreported cases or the postrhinoplasty cyst is a really rare condition. (Karapantzios et al., 1999)

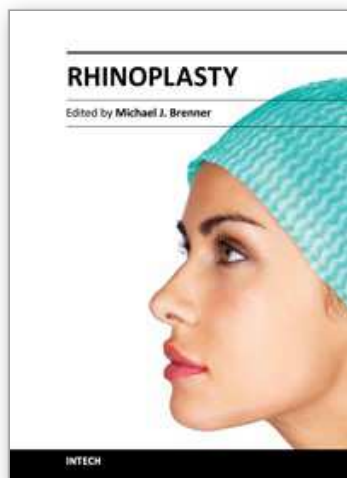
It is possible that intraoperative tissue dispersion would occur in large number of cases, but does not lead automatically to the development of cysts. Although the physiopathology is uncertain, it seems that entrapped fragments of epithelial tissue are proliferated, if specific local conditions are created. It remains unclear what factors influence the final formation in these rare cases.

10. References

- Aikawa T, Iida S, Fukuda Y, Nakano Y, Ota Y, Takao K, Kogo M. Nasolabial cyst in a patient with cleft lip and palate. *Int J Oral Maxillofac Surg*. 2008;37:874-876.
- Anastassov GE, Lee H. Respiratory mucocele formation after augmentation genioplasty with nasal osteocartilagenous graft. *J Oral Maxillofac Surg* 1999;57:1263-5.

- Baarsma EA. The median nasal sinus and dermoid cyst. *Arch Otorhinolaryngol* 1980;226:107- 13.
- Barkovich J, Vandermarck P, Edwards M, Cogen PH. Congenital nasal masses: CT and MR imaging features in 16 cases. *A J Neuroradiol* 1991;12,105-116
- Bracaglia R, Fortunato R, Gentileschi S Endoscopic excision for postrhinoplasty mucous cyst of the nose. *Br J Plast Surg*. 2005 Mar;58(2):271-4.
- Byrne PJ, Walsh WE, Hilger PA. The use of "inside-out" lateral osteotomies to improve outcome in rhinoplasty. *Arch Facial Plast Surg*. 2003 May-Jun;5(3):251-5.
- Chang DY, Jin HR. (2008). Foreign Body Inclusion Cyst of the Nasal Radix after Augmentation Rhinoplasty. *J Korean Med Sci*. 23, 6, pp. 1109-12.
- Dini M, Innocenti A, Agostini V. Postrhinoplasty mucous cyst of the nose. *Plast Reconstr Surg*. 2001;107:885– 886.
- Dionyssopoulos A, Nikolis A, Papaconstantino A, Kaka P, Miliaras D, Keke Gs, Mucous Cysts of the Nose: A Postrhinoplasty Complication? A Long-Term Follow-Up *Ann Plas Surg* 2010; 64(4),381-4
- Elder DE, Elenitsas R, Johnson BL Jr., Murphy GF, Xu X (2010). *Lever's Histopathology of the Skin*, Chapters 29-30
- Goldfarb M, Gallups JM, Gerwin J.M. Perforating osteotomies in rhinoplasty. *Arch. Otolaryngol. Head Neck Surg*. 119: 624, 1993.
- Flaherty G, Pestalardo CM, Itturalde JG et al (1996) Mucous cyst: postrhinoplasty complications. *Aesthetic Plast Surg* 20:29–31
- Grocutt M, Fatah MF. (1989). Recurrent multiple epidermoid inclusion cysts following rhinoplasty--an unusual complication. *J Laryngol Otol*. 103, 12, pp. 1214-6.
- Gryskiewicz JM. Paraffinoma or postrhinoplasty mucous cyst of the nose: which is it? *Plast Reconstr Surg*. 2001;108:2160 –2161.
- Hacker DC, Freeman JL. Intracranial extension of a nasal dermoid cyst in a 56-year-old man. *Head Neck* 1994;16:366- 71.
- Harley, E. H., and Erdman, J. P. Dorsal nasal cyst formation. *Arch. Otolaryngol. Head Neck Surg*. 116: 105, 1990
- Imholte M, Schwartz HC. Respiratory implantation cyst of the mandible after chin augmentation: report of case. *Otolaryngol – Head Neck Surg* 2001;124:586–7.
- Inchingolo F, Tatullo M, Abenavoli FM, Marrelli M, Inchingolo AD, Servili A, Inchingolo AM, Dipalma G. (2010). A hypothetical correlation between hyaluronic acid gel and development of cutaneous metaplastic synovial cyst. *Head Face Med*. 15, 6:13.
- Johnson CM, Anderson JR. The deviated nose- its correction. *Laryngoscope* 1977;87,1680-4
- Karapantzos I, Behrmann R, Simaskos N. Paranasal mucous cyst: a rare finding following septorhinoplasty. *Rhinology* 1999;37:190–1.
- Koeller KK, Alamo L, Adair CF and Smirniotopoulos JG. (1999). Congenital Cystic Masses of the Neck: Radiologic-Pathologic Correlation. *Radiographics*, 19, pp. 121-146.
- Kotzur A., Gubisch W. Mucous cyst--a postrhinoplasty complication: outcome and prevention. *Plast Reconstr Surg*. 1997 Aug;100(2):520-4.
- Lawson W, Kessler S, Biller HF (1983) Unusual and fatal complications of rhinoplasty. *Arch Otolaryngol Head Neck Surg* 109:164–169
- Leong AC, Sharp HR. (2009). Nasal septal cyst: a rare phenomenon. *Auris Nasus Larynx*. 36, 1, pp. 96-9.

- Liu ES, Kridel RW. (2003). Postrhinoplasty nasal cysts and the use of petroleum-based ointments and nasal packing. *Plast Reconstr Surg*, 112, pp. 282-287.
- McGregor, M. W., O'Connor, G. B., and Saffier, S. Complications of rhinoplasty: I. Skin and subcutaneous tissues. *J. Int. Coll. Surg.* 30: 179, 1958.
- Mouly R. Le kyste mucoïde, complication inhabituelle de la rhinoplastie. *Ann Chir Plast* 1970;15:153-5.
- Ntomouchtsis A, Kechagias N, Xirou P, Triaridis A, Xinou K, Vahtsevanos K. Recurrent glabellar mucous cyst: a rare postrhinoplasty complication. *Oral Maxillofac Surg.* 2010 Jun;14(2):129-32.
- Pausch NC, Bertolini J, Hemprich A, Hierl T. Inclusion mucous cysts of the nose: a late complication after septorhinoplasty in two cleft lip patients. *Cleft Palate Craniofac J.* 2010 Nov;47(6):668-72
- Raine C, Williamson SLH, McLean NR. Mucous cyst of the alar base: a rare complication following rhinoplasty. *Br J Plast Surg* 2003;56(2):176-7.
- Rees T, ed. The osteocartilaginous vault. In: *Aesthetic Plastic Surgery*. Philadelphia, Pa: WB. Saunders Co; 1980;114-176
- Rettinger G, Zenkel M. Skin and soft tissue complications. *Facial Plast Surg.* 1997;13:51-9
- Riedel F, Bersch C, Hörmann K (2007) Dorsal nasal mass formation—postrhinoplasty cyst. *HNO* 55:472-47
- Rohrich RJ, Krueger JK, Adams WP, Hollier LH. Achieving consistency in the lateral nasal osteotomy during rhinoplasty: An external perforated technique. *Plast. Reconstr. Surg.* 108: 2122, 2001
- Rohrich RJ, Janis JE, Adams WP, Krueger JK. An update on the lateral nasal osteotomy in rhinoplasty: An anatomic endoscopic comparison of the external versus the internal approach. *Plast. Reconstr. Surg.* 111: 2461, 2003.
- Romo T 3rd, Rizk SS, Suh GD (1999) Mucous cyst formation after rhinoplasty. *Arch Facial Plast Surg* 1: 208-211
- Senechal G, Senechal B, Mamelle G (1981) Une complication rare et tardive des rhinoplasties. *Ann Oto-Laryng (Paris)* 98:385-386
- Shulman Y, Westreich M. Postrhinoplasty mucous cyst of the nose. *Plast Reconstr Surg* 1983;71:421-2.
- Struijs B, Bauwens LJ. Post-rhinoplasty mucous cyst formation of the nasal dorsum. *B-ENT.* 2010;6(4):295-8.
- Tan Ergin N., Akkuzu B. Mucous cyst of the nasal dorsum. *Rhinology* 2000;38,206-7
- Tardy ME. Rhinoplasty, In: Tardy ME, Kastenbauer ER. *Head and Neck Surgery*. Thieme, 1995, pp239-302
- Tastan E, Kavuzlu A, Demirci M, Sungu N. A unique case of a postrhinoplasty epidermoid cyst. *Rhinology* 2010;48,244-6
- Toriumi DM, Johnson CM (1990) Revision rhinoplasty: case study. In: Toriumi DM, Johnson CM (eds) *Open structure rhinoplasty*. WB Saunders, Philadelphia, PA, pp 464-469
- Zerris VA, Annino D, Heilman CB. Nasofrontal dermoid sinus cyst: report of two cases. *Neurosurgery* 2002;51:811-4.
- Zijlker TD, Vuyk HD. Nasal dorsal cyst after rhinoplasty. *Rhinology.* 1993; 31:89 -91.



Rhinoplasty

Edited by Dr. Michael Brenner

ISBN 978-953-307-849-6

Hard cover, 146 pages

Publisher InTech

Published online 09, December, 2011

Published in print edition December, 2011

Rhinoplasty is one of the defining procedures of plastic and reconstructive surgery. Its roots stem from early efforts in nasal reconstruction to the emergence of modern rhinoplasty. This book describes the latest clinical and research perspectives in rhinoplasty and balances structural correction with aesthetic refinement. With treatises on rhinoplasty from a diverse set of thought leaders from around the world, the collective experience of this books' authors cover cosmetic and reconstructive approaches with a wealth of proven and innovative approaches ranging from minor refinement to major reconstruction. This diversity reflects the inherent complexity of the art and science of rhinoplasty. Discussion of structural approaches is balanced by consideration of judicious resection and refinement. The overarching goal is to instill an understanding of the subtleties of nasal structure and how the natural complexities of nasal anatomy can be adapted to maximize both function and natural appearance.

How to reference

In order to correctly reference this scholarly work, feel free to copy and paste the following:

Aris Ntomouchtsis, Nikos Kechagias, Persefoni Xirou, Georgios Christos Balis, Katerina Xinou and Konstantinos Vahtsevanos (2011). Mucous Cysts as a Complication of Rhinoplasty, Rhinoplasty, Dr. Michael Brenner (Ed.), ISBN: 978-953-307-849-6, InTech, Available from:
<http://www.intechopen.com/books/rhinoplasty/mucous-cysts-as-a-complication-of-rhinoplasty>

INTECH
open science | open minds

InTech Europe

University Campus STeP Ri
Slavka Krautzeka 83/A
51000 Rijeka, Croatia
Phone: +385 (51) 770 447
Fax: +385 (51) 686 166
www.intechopen.com

InTech China

Unit 405, Office Block, Hotel Equatorial Shanghai
No.65, Yan An Road (West), Shanghai, 200040, China
中国上海市延安西路65号上海国际贵都大饭店办公楼405单元
Phone: +86-21-62489820
Fax: +86-21-62489821

© 2011 The Author(s). Licensee IntechOpen. This is an open access article distributed under the terms of the [Creative Commons Attribution 3.0 License](https://creativecommons.org/licenses/by/3.0/), which permits unrestricted use, distribution, and reproduction in any medium, provided the original work is properly cited.

IntechOpen

IntechOpen