

# We are IntechOpen, the world's leading publisher of Open Access books Built by scientists, for scientists

6,900

Open access books available

185,000

International authors and editors

200M

Downloads

Our authors are among the

154

Countries delivered to

TOP 1%

most cited scientists

12.2%

Contributors from top 500 universities



WEB OF SCIENCE™

Selection of our books indexed in the Book Citation Index  
in Web of Science™ Core Collection (BKCI)

Interested in publishing with us?  
Contact [book.department@intechopen.com](mailto:book.department@intechopen.com)

Numbers displayed above are based on latest data collected.  
For more information visit [www.intechopen.com](http://www.intechopen.com)



# **Rhinoplasty – The Difficult Nasal Tip – Total Resection of the Alar Cartilages and Temporal Fascia Technique – A 24 Year Experience**

Salvador Rodríguez-Camps Devís  
*Division Chief of Aesthetic and Plastic Surgery,  
University Hospital Casa de Salud, Valencia  
Spain*

## **1. Introduction**

This technique begins with a secondary rhinoplasty case (operated 3 times previously) in 1987 with a highly unappealing nasal tip whose cartilages were completely broken. I had to choose between eliminating the whole nasal dome and resetting it with a new cartilaginous structure (taking cartilages from the ear), or removing all the cartilage remains and covering with two-layered temporal fascia. I decided on the second option, and the result was highly satisfactory (fig. 1). Why this unprecedented idea? It was an impulse. Because of my reflexive character and perfectionism, it seemed contradictory and, yet, I sensed that this nasal tip, so badly arranged and anti-aesthetic after 3 operations, would only withstand a fourth operation which guaranteed certain success. So I thought that submitting the patient to a reconstruction of the whole cartilaginous nasal tip structure was not the best solution. Amputating and reconstructing seemed more complex and bloody than amputating and covering with some soft tissue. I chose temporal fascia as it is soft and not very extensible, and would provide the new tip more solidity. It came to my mind in a flash and I acted with all the consequences to help my patient, Paquita. As I knew the patient, I did a follow-up and, years later, the result remained stable. However, as all the plastic surgery treaties and publications warn us about the importance of conserving an alar cartilage band of no less than 3-5 mm on its caudal edge to avoid collapses, I thought that this process could wait before being repeated. So gradually, I started performing more cases, and I saw that the result was no chance happening. I extended the indications and ventured with particularly difficult primary rhinoplasty cases involving extremely domed, flat and wide tips. The years went by and I continued improving and perfecting this process, which went against what was “technically correct”. I indicated it by taking great care and followed the results for as long as possible. After finishing the operation, I checked that the result remained aesthetic and that the nasal base was equilateral and stable; this was precisely one of the keys: a solid tripod and an equilateral stable base. To achieve this effect, I introduced some technical resources which helped me to convert a long-pointed or flattened nose into what ensured

me good results: an equilateral base. Then I started work with alar wedges, vestibular wedges, resecting or using a stitch in the centre of the crus medialis feet, partial reduction of the soft triangles, Converse stitch, etc., to stabilise the tip. As the years passed, I continued extending the indications and obtaining good results; but, beware; what I was doing was still “technically incorrect”. So I decided to wait a little longer and acquire as much experience as possible. I had to ensure that everything I was doing was not “incorrect by chance”, and all I wanted was absolute security to be able to defend the technique when it emerged with all the consequences. I began to attenuate some case or another during rhinoplasty speeches without causing commotion in the forum. When I felt quite certain, I presented the technique officially in a SECPRE (Spanish Society of Reconstructive, Aesthetic and Plastic Surgery) Congress (Pamplona, Spain, 2006), then in Melbourne, Australia, in the ISAPS Congress (International Society of Aesthetic Plastic Surgery, 2008), where it went down well. Finally, I decided to publish it in *Aesthetic Plastic Surgery* (2009), in *Cirugía Plástica Ibero-latinoamericana* (2010) and in the *Spanish Association of Aesthetic and Plastic Surgery Journal* (2010). I can state that acknowledgement has been excellent, particularly thanks to the results achieved. Consequently, we should think the technique must be correct if the results are good.

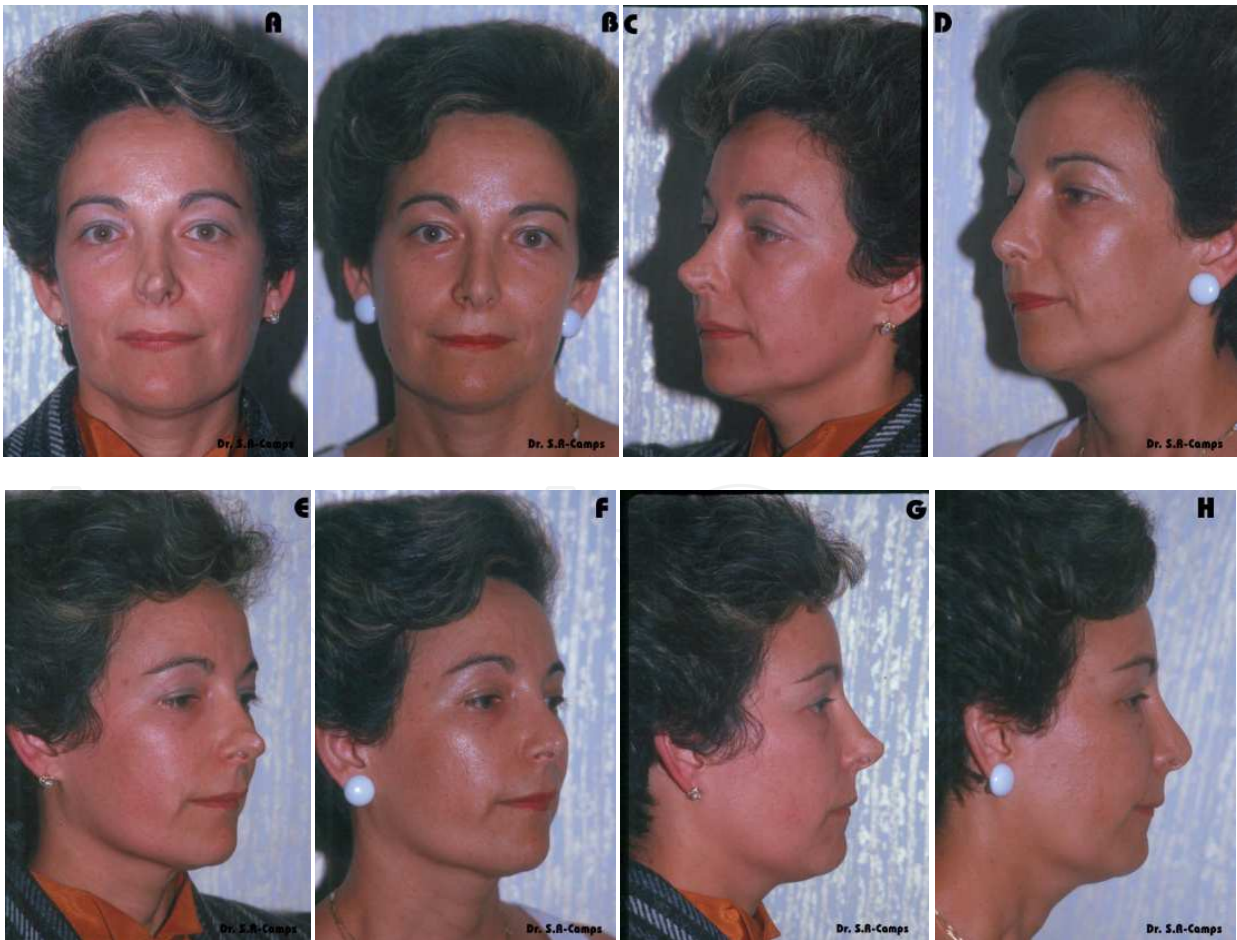

Fig. 1. (A, B, C, D, E, F, G and H)

This is my first case done in 1987.

Secondary rhinoplasty operated on 3 previous occasions. Details of completely destroyed, contorted alar cartilages, with a pointed and unsightly tip. Treatment was Type I resection-reconstruction: Total Resection of the Alar Cartilages, including domes and a trunk of crus medialis. Patch and band of temporal fascia for covering. Result after 2 years.

Since Joseph masterly established the basic concepts of Modern Rhinoplasty in 1904, upon which plastic surgeons still base ourselves today, research and contributions to this fascinating surgical technique have been constant, and each and every millimetre of the nasal pyramid has been studied and discussed from both the functional and aesthetic viewpoints. And all this always with the same maxim: “NO excessive resection, and even less TOTAL resection, of alar cartilages given the risk of alar collapse”. Nonetheless for almost 25 years, we have studied, verified and finally demonstrated, with good results, that ,YES, alar cartilages can be removed totally after correct diagnosis and suitable indication. A correct anatomical diagnosis of the tip and nasal base, and of the respiratory tract (septum, nasal turbinates and valves), and adequate indication, are always suitable in a nose whose tip is extremely difficult to put right with traditional techniques using cartilage grafts.

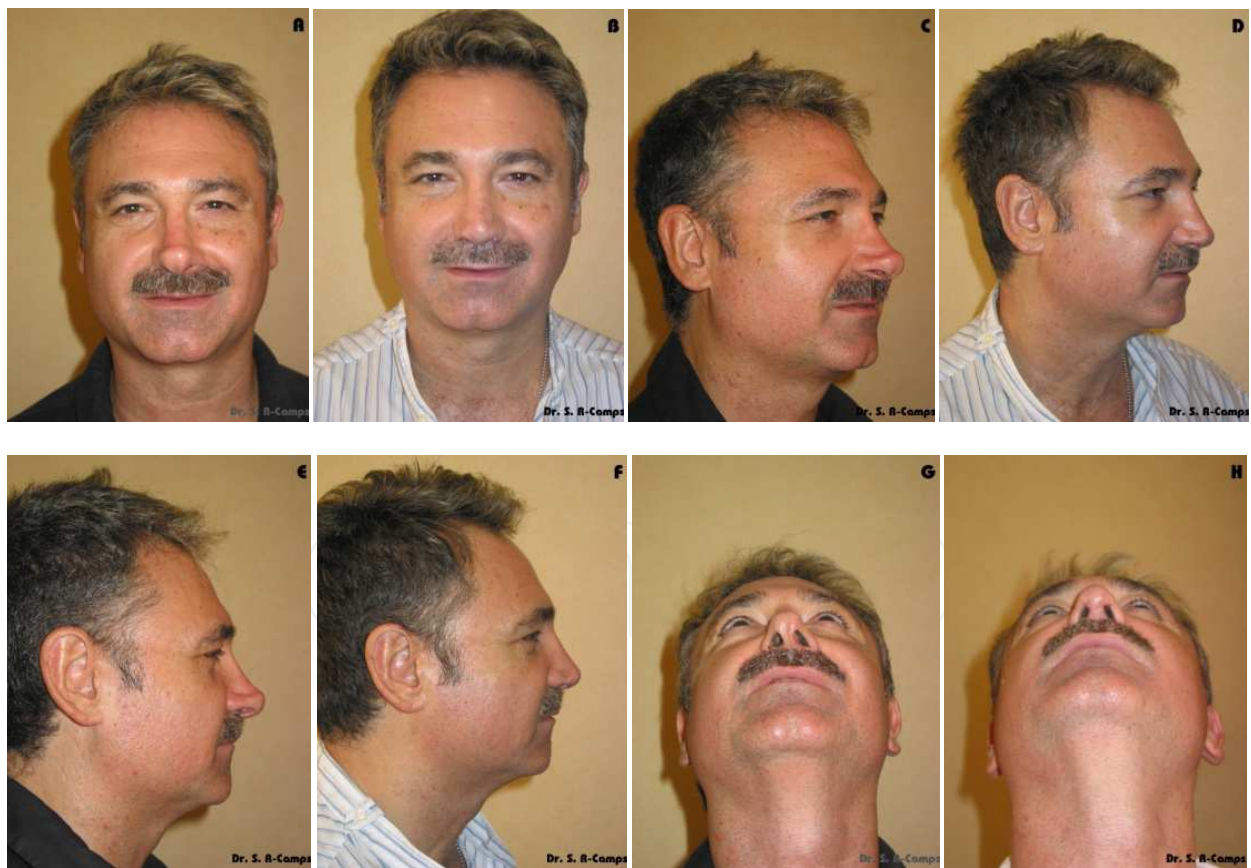


Fig. 2. (A, B, C, D, E, F, G and H) Secondary rhinoplasty. “Pinocchio” nose. Inadequately removed thick alar cartilages. Treatment was Type I resection-reconstruction.: Total Resection of the Alar Cartilages, including domes and a trunk of crus medialis. Patch and band of temporal fascia for covering. Killian septoplasty. Result after 1 year



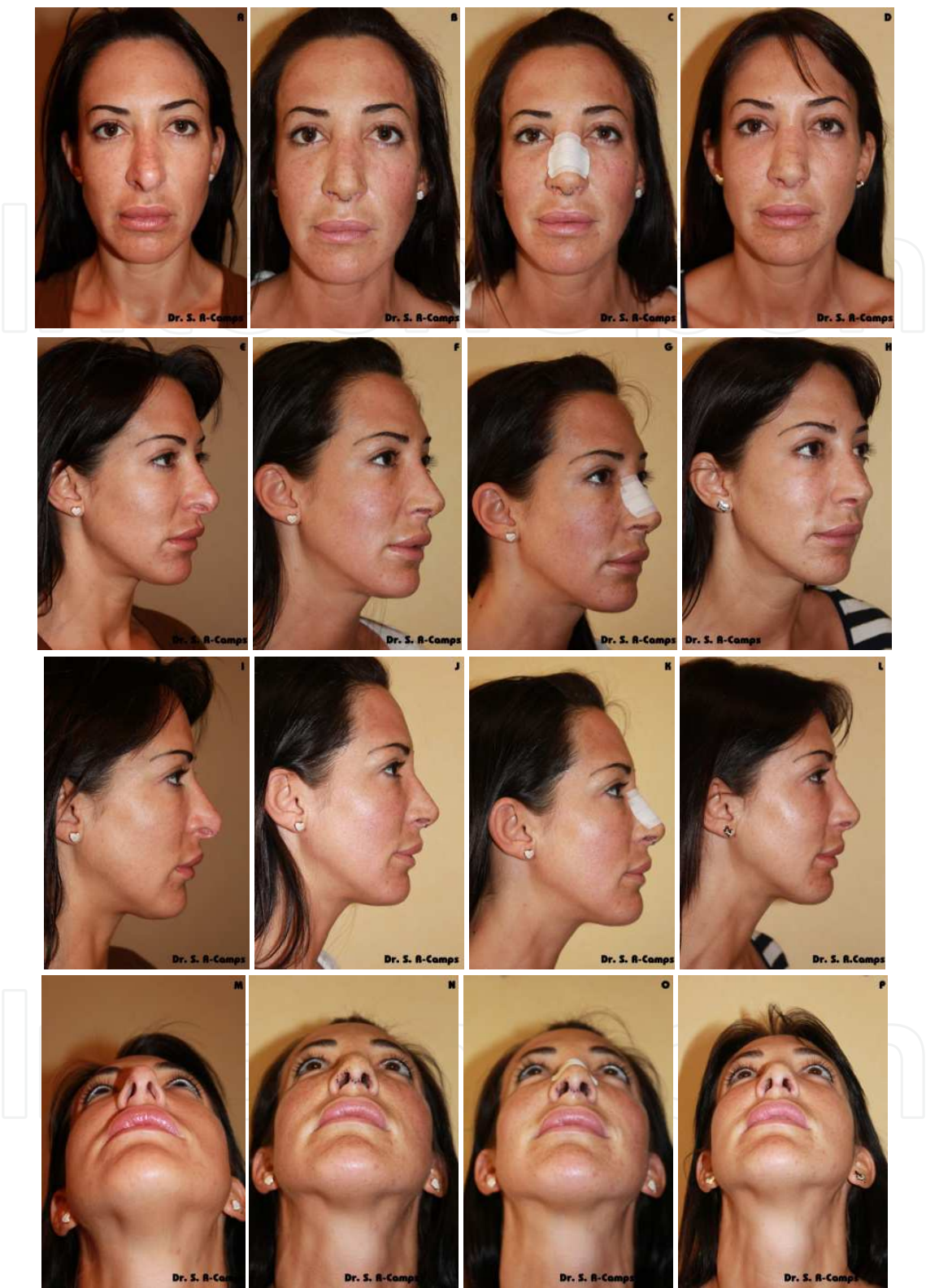

Fig. 3. (A, B, C, D, E, F, G, H, I, J, K, L, M, N, O and P) Secondary rhinoplasty. Details of inadequately treated cartilages and the tip-columela-lip unit. Postoperative sequence: after 7 days (removing the splint and placing Steri-Strip<sup>®</sup> protection); aspect after 15 days. Type III resection-reconstruction: Total Resection of the Alar Cartilages, respecting domes. Patch of Temporal Fascia

This paper attends to something new: a rhinoplasty technique based on the total resection of alar cartilages, which are replaced with a temporal fascia covering to soften the nasal tip by forming a single covering among the skin, the underlying fibroadipose tissue, the temporal fascia itself and vestibular skin.

The indication for this new technique is secondary rhinoplasty cases, for extremely difficult nasal tip cases with broken or badly arranged cartilages (fig. 2 and fig. 3), for traumatic rhinoplasty, and also for primary rhinoplasty situations in which the nasal tip is excessively bulbous, disfigured, flat or wide (fig. 4; fig. 5; fig. 6, fig. 7 and fig. 8). Where a “surgical tip” may appear after the oedema disappears, it is highly competitive with other techniques based on complex cartilaginous structures with auricular grafts.

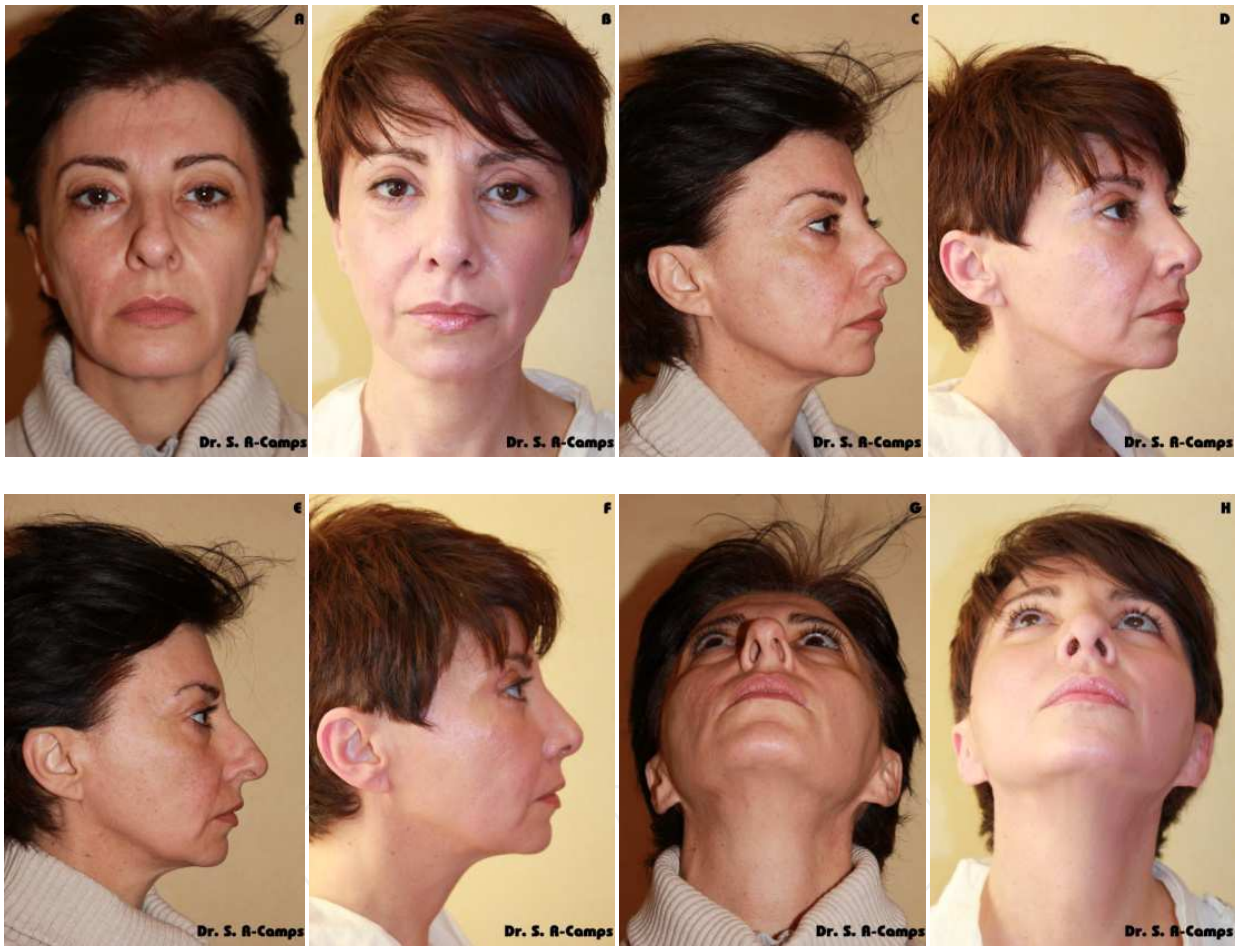

Fig. 4. (A, B, C, D, E, F, G and H) Primary rhinoplasty. Excessively bulbous and protruding tip. Type II resection-reconstruction: Total Resection of the Alar Cartilages, including domes. Patch and band of temporal fascia. Killian septoplasty. Result after 1 year

We have 24 years experience (1987 – 2011) and more than 550 successful operations with fully satisfied patients.

The refinement and beauty of the nasal tip with a solid and equilateral base are the aim of this technique, without historical prejudices and taboos; and we have achieved this exactly.



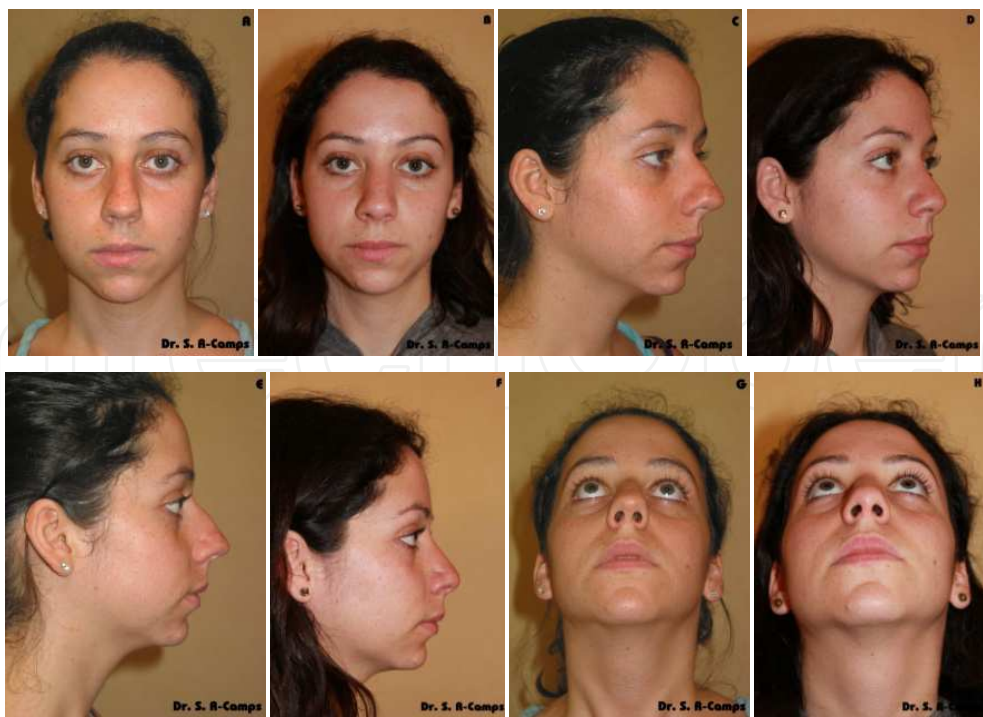

Fig. 5. (A, B, C, D, E, F, G and H) Primary rhinoplasty. The tip is not only protruding, but also bulbous and fleshy. Type II resection-reconstruction: Total Resection of the Alar Cartilages, including domes. Patch and band of temporal fascia. Result after 1 year

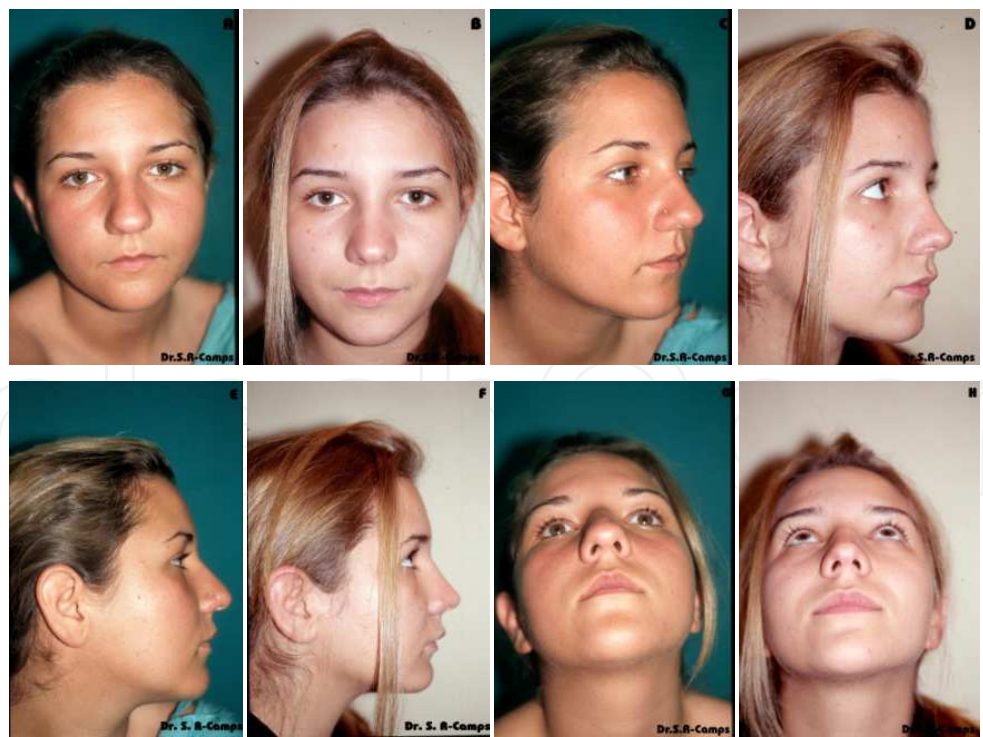

Fig. 6. (A, B, C, D, E, F, G and H) Primary rhinoplasty. Broad tip with a thick skin and a retracted columella. Type V resection-reconstruction.: Total Resection of the Alar Cartilages, respecting domes and suturing both crus medialis high. Temporal fascia patch, Inter-crus-medialis tutor and filled in nasal-labial angle. Result after 1 year

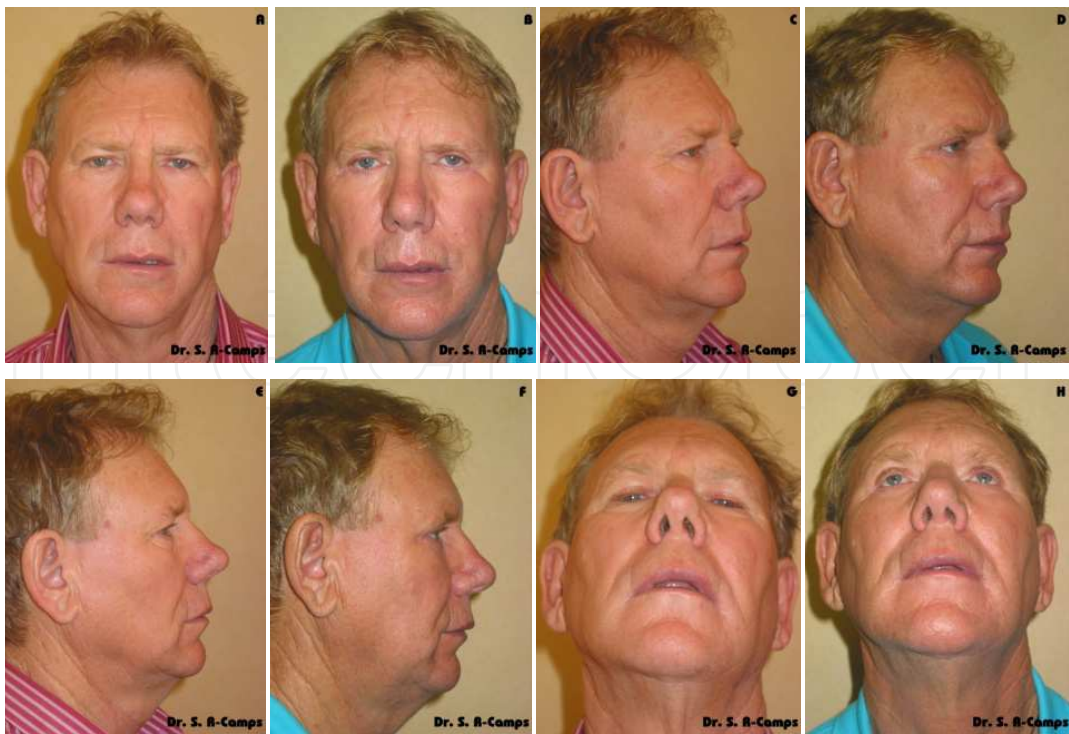

Fig. 7. (A, B, C, D, E, F, G and H) Primary rhinoplasty. Protruding and bulbous tip with very thick skin. Type III resection-reconstruction: Total Resection of the Alar Cartilages, respecting domes. There was no need for temporal fascia given the thickness of the skin. In this particular case, we performed a blepharoplasty simultaneously. Result after 1 year

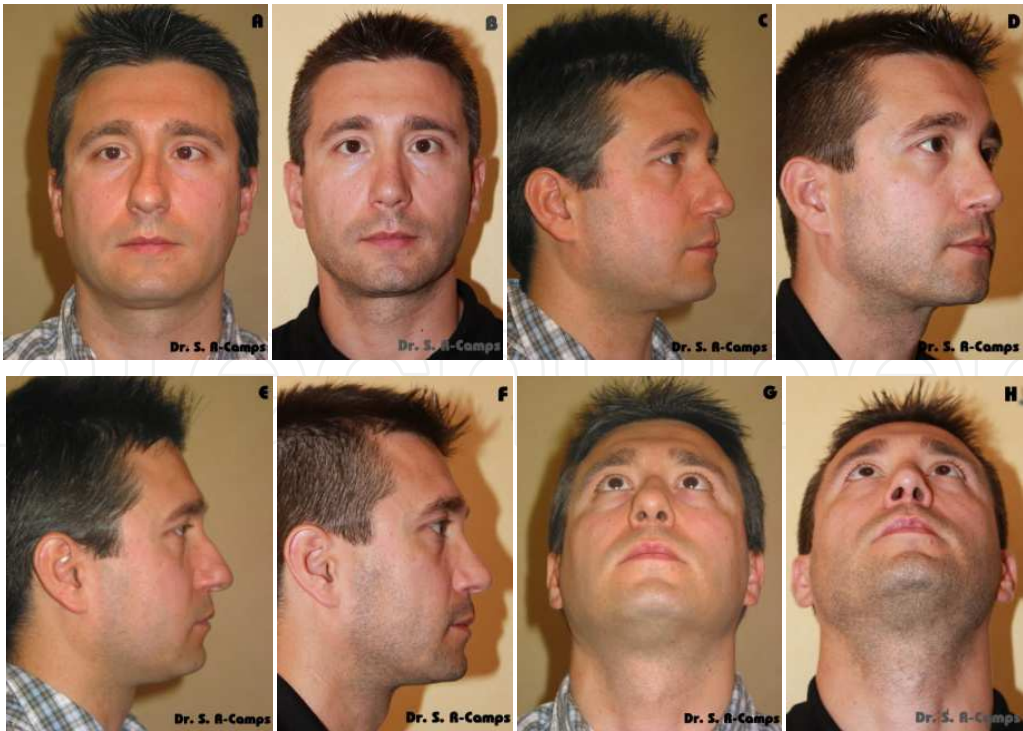

Fig. 8. (A, B, C, D, E, F and H) Primary rhinoplasty. Deviated nose with globulous nasal tip. Type II resection-reconstruction: Total Resection of the Alar Cartilages, including domes. Patch and band of temporal fascia. Killian septoplasty. Result after 1 year



## 2. Material and methods

*“Rhinoplasty is decidedly a very difficult operation although, technically, it seems deceptively easy”* (Jack Sheen).

I have operated more than 550 patients with this technique and have over 24 years experience in it (1987–2011) with highly satisfactory results.

In secondary and traumatic Rhinoplasty suits this technique, always Rethi’s approach (Open Rhinoplasty), which is especially designed for it. Yet we are increasingly employing it in primary rhinoplasty when the solution for a cartilaginous dome proves difficult with other techniques. We are fully accelerating in this last case and have introduced some variation, as we will go on to explain. Mainly after cancer surgery on the nasal tip, we also have gained experience in nasal reconstruction.

What do I mean when I speak of other nasal tip remodelling techniques? All those known as conventional techniques based on repositioning alar cartilages with grafts removed from ears. Then there are the extreme cases in which the creation of a genuine cartilage scaffolding is easy to detect in many cases when the oedema has disappeared some months later. It is true that these techniques always improve the appearance of the new nasal tip, but it is not hard to detect the presence of peaks and edges corresponding to the grafts taken mainly from the auricular concha. Although I am not in favour of cartilaginous grafts in the nasal tip given the subsequent reabsorption, torsion, asymmetry problems or noted through the skin, I admit I still use some of them to project and define a nasal tip with the shield of Sheen or the champagne glass of Juri, but I no longer use cartilaginous grafts to reconstruct the nasal dome and/or the nasal wings. Other techniques have contributed to the success of the nasal tip treatment, to refine it. Thus, Safian (1930) begins an interesting process which Goldman (1957) would significantly improve, with his vertical dome division (VDD: anterior triangular shape incision of both domes), and Simons and Adamson will popularize it definitively. Lipsett (1959) will modify this technique with multiple partial thickness incisions in the nasal domes for bending the cartilages.

### 2.1 The resection

An equilateral and stable nasal base is our main objective. To fulfil this objective, we have classified resections into 5 types (although, in very special cases, it is convenient to make some little combinations between them).

#### 2.1.1 Type I

Complete resection of alar cartilages, including domes and one trunk of the crus medialis.

This is indicated for noses that are long-pointed, have a long columela, and for large and elongated nostrils. Here we introduce some of our technical resources, such as alar wedges, and resecting the crus medialis feet.

#### 2.1.2 Type II

Complete resection of alar cartilages, including domes. This is indicated for noses with a slightly elongated nasal base.

### 2.1.3 Type III

Total resection of alar cartilages, respecting domes. Applicable to noses whose nasal base is very close to the objective (equilateral nasal base).

### 2.1.4 Type IV

Total resection of alar cartilages, respecting domes, and leaving two small alar wedges whose latero-caudal length is no longer than 8 mm and is of an arrow-tip shape. Indicated for cases where the nasal base is equilateral.

### 2.1.5 Type V

Total resection of alar cartilages, respecting domes and approaching the Crus Medialis feet, and suturing domes as high as possible to accomplish projection. Then we remove vestibular wedges, place a Converse stitch, smoothly reduce the soft triangles, release the columela of the base and remove a trunk of the septum depressor muscle. Generally, it is only here where we introduce a septum tutor intercrus to prolong and strengthen the columela projecting the nasal tip. This is indicated for flat and negroid noses with a short columela, separated nasal wings and broad nostrils.

Many times, it is not necessary to use the temporal fascia for covering the crus medialis, because of the thickness of the skin (fig. 7).

(Fig. 9, fig. 10, fig. 11, fig. 12, fig. 13)

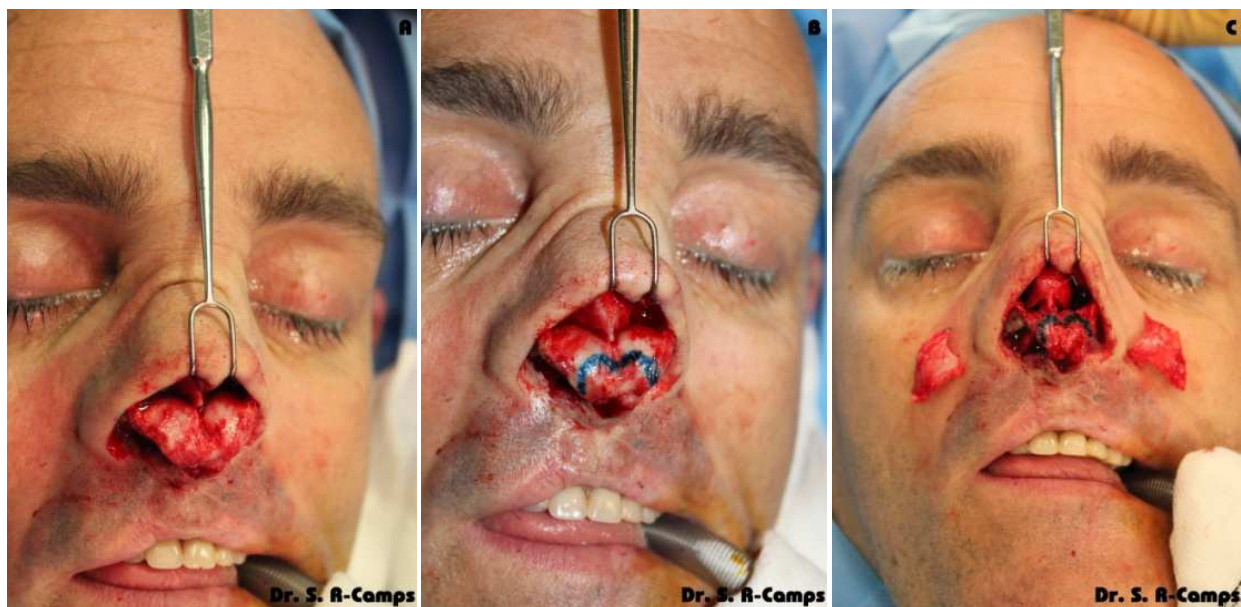

Fig. 9. (A, B and C) Cleft rhinoplasty. Very broad tip with cartilaginous hypertrophy. Type III resection marking: Total Resection of the Alar Cartilages, respecting domes

## 2.2 The reconstruction

We place two stitches with 5-0 nylon, and conceal the knots, on top of the crus medialis to keep them firmly together. If the approach is complete, sometimes it is not necessary. A patch and/or a band of temporal fascia is placed covering the crus medialis.

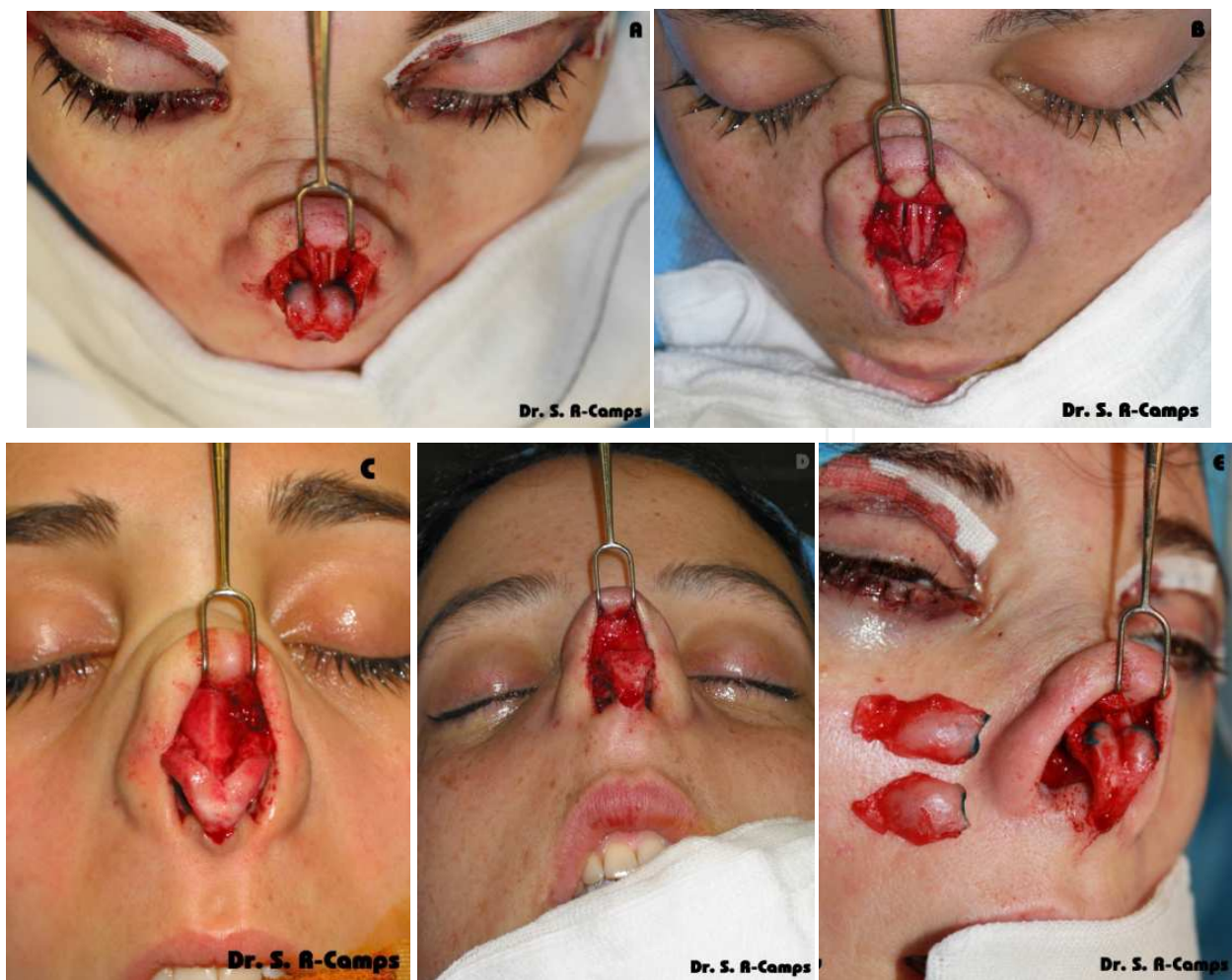

Fig. 10. (A, B, C, D and E) Different resection types

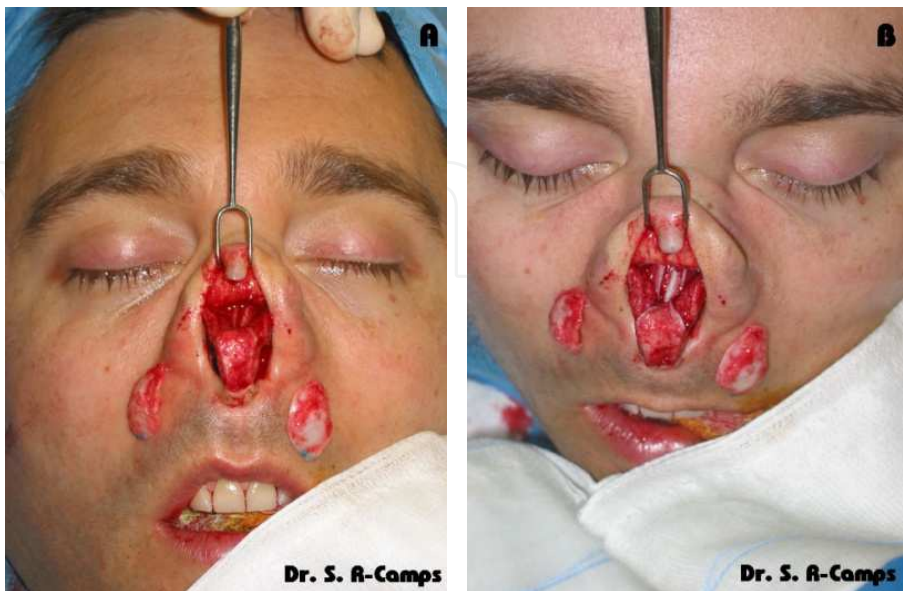

Fig. 11. (A and B) Details of Type II resection: Total Resection of the Alar Cartilages, including domes. Patch and band of temporal fascia



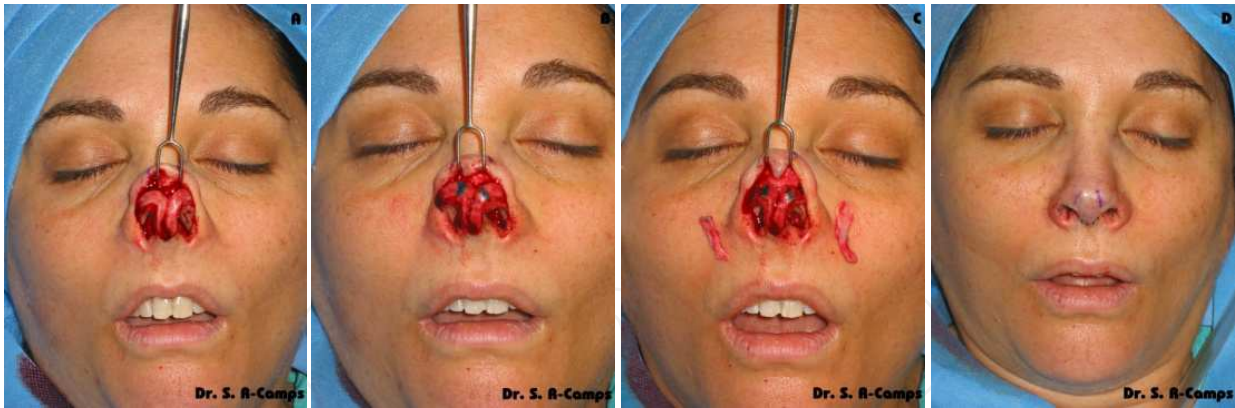

Fig. 12. (A, B, C and D) Secondary rhinoplasty on an extremely broad tip and an inadequate resection. Details of Type II resection and immediate result: Total Resection of the Alar Cartilages, including domes. Patch and band of temporal fascia

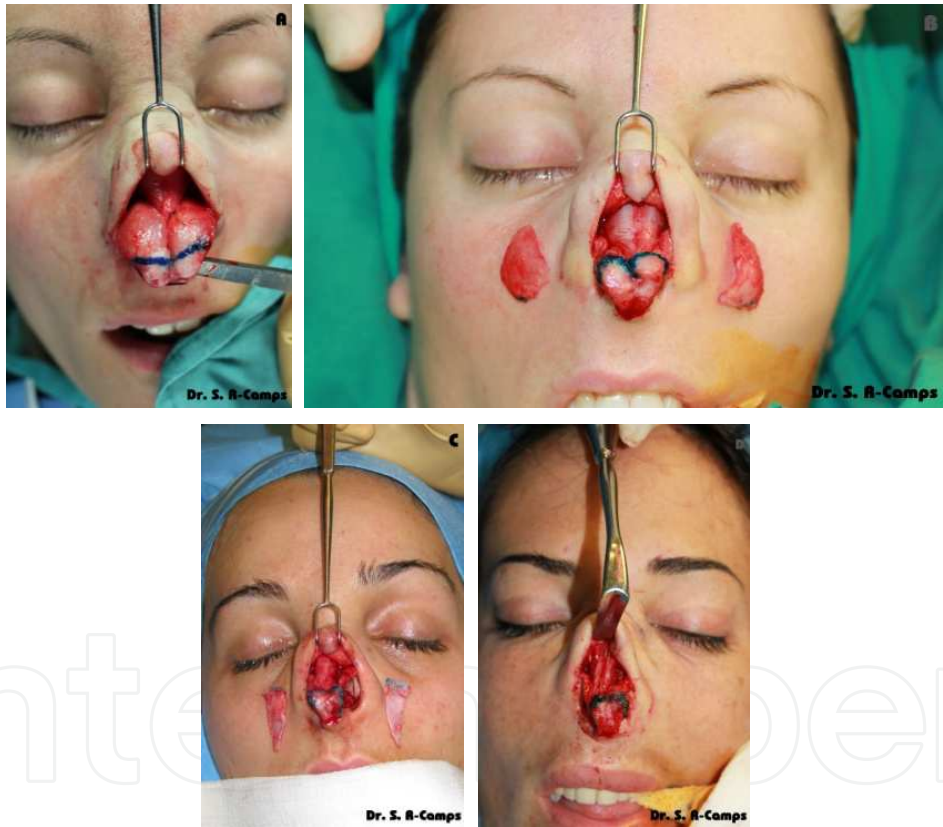


Fig. 13. (A, B, C and D) Different resection types

### 2.3 The temporal fascia

In 1984, Dr. Guerrerosantos introduced this procedure to increase the dorsal unit of the nose and to fill the naso-frontal angle. We use it for the tip to achieve a firm covering and a beautiful, smooth protection in terms of both sight and touch by joining it as a single plane to the fibroadipose covering to the skin (fig. 14). We only exclude temporal fascia in those nasal tips with a thick skin, with abundant sebaceous glands and a dense fibroadipose covering.

To avoid a pointed nasal tip, conversely, its placing is essential in Caucasian women and European north-eastern people with delicate and thin skin. There is no problem with a “shrink wrap effect”, until nowadays. The technique works very similar in every ethnic group, but we need to use the temporal fascia generally and, however, rarely in black or Asian people because of the thickness of the skin. In every ethnic group we have had no problem with retraction.

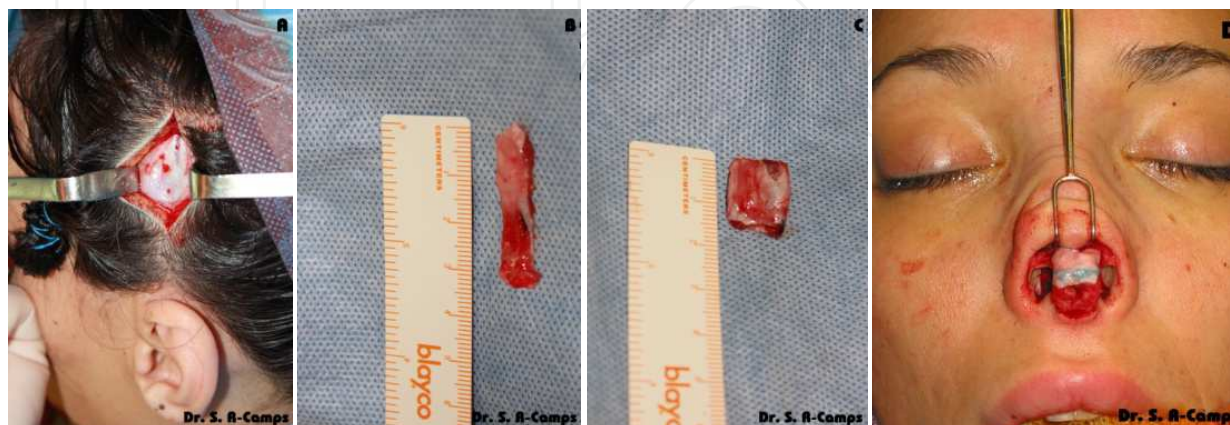


Fig. 14. (A, B, C and D) Details of temporal fascia arranged to be utilized for reconstruction purposes. A fascia seal covering the ends of the crus medialis in a Type II reconstruction

The seal extension will also depend on the thickness of the wings' skin. We place 1 or 2-layered temporal fascia depending on requirements and the resection type, and we sometimes include muscle fibres to provide bulk.

In this way, the anatomy of the new nasal tip and the wings will outwardly to inwardly comprise the following single-body layers:

- Superficial skin
- Fibroadipose covering
- External fibrous lamina
- Temporal fascia
- Internal fibrous lamina
- Internal vestibular skin

## 2.4 The technical resources

According to the former shape of the nasal base, and to achieve an equilateral nasal base, we use a serie of technical details that enable a firm, consistent base which resists alar collapse during inspiration: reduction of soft triangles (to achieve nostrils with a longer look), resecting a trunk of the septum depressor muscle (to help project the nasal tip and avoid it from moving and lowering when talking and laughing), Converse stitch (to narrow an excessively wide columelar base), releasing the columela (to project the tip, block it and open the naso-labial angle), alar wedges (to bring wings closer together and to reduce the nostrils size), resection or approach of the Crus Medialis Feet (to lower the nasal tip or to project it), tutor intercrus (to strengthen the columela and to project the tip), vestibular wedges (to narrow nostrils), septoplasty (Killian) and/or luxation or cauterisation of the nasal turbinates (to ensure the respiratory tract function and to be able to perform the technique without the possibility of collapse), and filling the naso-

labial angle with resected remains (fig. 15) (to obtain beauty between the lip and the nasal base).

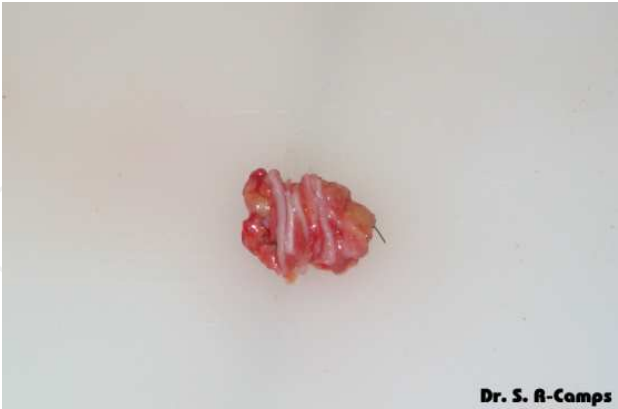

Fig. 15. Details of removed and sutured alar cartilages prepared to be introduced into the naso-labial angle for the purpose of opening it

As regards the septum and nasal turbinates being responsible for a correct respiratory tract, we have highlighted that many of the bulges in the cartilaginous dome of the tip are due to natural compensation caused by a deviation of the septum and/or to a hypertrophy of the turbinates. If we perform the total resection of alar cartilages technique with their domes without having previously treated any pathology in the septum and turbinates, then we will cause nasal respiratory insufficiency with spontaneous collapse and/or during inhalation. If, on the other hand, the septum and turbinates are normal, we should not come across complications of any kind of either a functional or an aesthetic type when undertaking a total resection of the cartilaginous dome of the nasal tip.

### 2.5 The postoperative period

The postoperative period does not differ much with our technique from that of other techniques (if anything, recuperation is shorter). However, we have to maintain the vestibular cotton pads pushing the domes for 4-5 days (fig. 16). A plaster splint remains in place for 7 days, and a double layer of Steri-Strip<sup>®</sup> is used for 7 additional days.

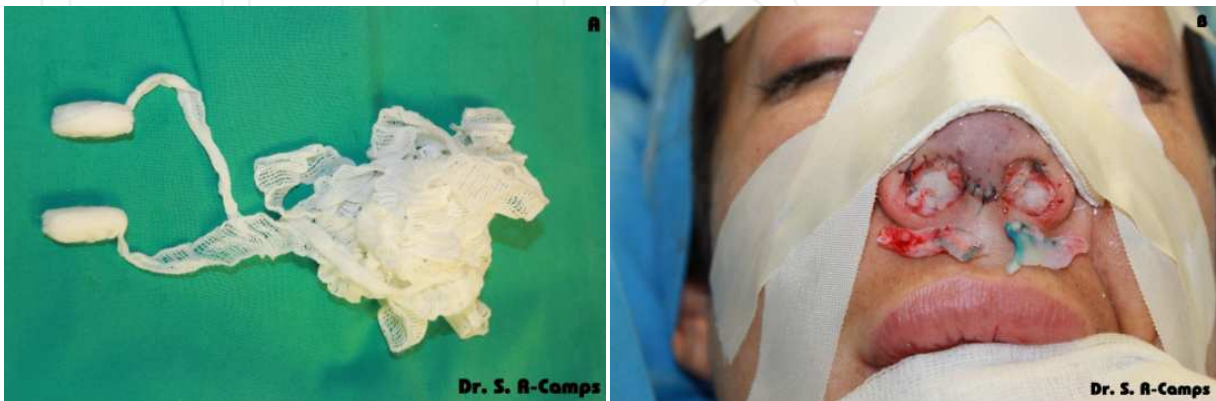

Fig. 16. (A and B) Details of prepared cotton pads of sufficient length to be positioned to push the vestibular skin from the dome and to ensure a compact union with the fascia and tip skin



### 3. Results

Judging from our patients' degree of satisfaction, the results obtained since 1987 to date in 2011, range from very good to excellent. Other nasal tip reconstruction techniques performed with complex cartilaginous structures did not provide us with the best results because a "surgical tip" emerged when the oedema disappeared, with traces of barely admissible tips and edges.

We reconstruct the nasal tip using the cartilages we have available, and if they do not serve this purpose, we resect them directly. We very rarely resort to cartilaginous grafts since we adopted our technique. Personally, I reached the conclusion some time ago of NOT using cartilaginous grafts in the nasal tip, provided this is feasible, for ultimate problems of displacement, reabsorption, distortion and an unappealing presentation in terms of sight and touch.

Despite what I have stated herein, I wish to express my maximum respect and admiration to all the Rhinoplasty Masters from whom I have learnt.

We have had no problems with the ever-feared alar collapse, which is most certainly due to other factors such as an excessive resection of the triangular cartilages, a vestibular valve lesion without correcting a significant deviation of the septum during surgery, or hypertrophic turbinates which could contribute to or even cause nasal respiratory failure with a uni or a bilateral collapse. Regarding complications, there is nothing particular to highlight in either aesthetic or functional terms.

### 4. Discussion

I realised that this technique was controversial, from the beginning, and that our Rhinoplasty Masters did no advice an excessive resection of alar cartilages, but preferred to maintain a cartilage band of a width of no less than 3-5 mm in the latero-caudal sense to avoid alar collapse. However, by following the steps of our technique and by maintaining its main objective (an equilateral, solid nasal base with a firm, yet soft nasal tip in terms of sight and touch, with no cartilaginous remains in view) I have verified and demonstrated that this may be avoided.

Nonetheless, all this involves experience in rhinoplasty and a totally accurate technique. It proves a most useful technique, but to be used only in extremely difficult nasal tip cases.

### 5. Conclusion

My new technique has posed no problems when well indicated, diagnosed and performed, and has matured sufficiently over time in casuistry.

Finally, the nasal tip becomes as firm and consistent, or more, than prior to surgery. Its five anatomical layers retract in a uniform fashion without distortions. To the touch, it is solid yet smooth and, aesthetically, it offers a beautiful result. Only a biopsy would enable us to verify the state of the stratification, but it is complicated proposing this to a patient who is satisfied with his or her nose, and we are all aware of the possible negative consequences of extracting a cylinder of tissue with the more than likely alteration to the vectorial system and to shape. It would be rather like requesting a "structural sampling" in a cathedral vault to learn the characteristics or state of its materials. Thus, our colleagues should trust in the technique thanks to its results.

The most difficult plastic surgery operation is undoubtedly rhinoplasty and, within it, nasal tip cases are extremely difficult. Nonetheless, the operation is the most appealing and fascinating of our speciality, but great care must be taken while performing it.

I literally cite: ... *"The author must be congratulated for his work, and be honoured and highly commended for the results obtained. This study is unique and it offers excellent results"...* *"Indeed, these results will convince many of us in practicing these aggressive resections"...*

*"The complete and permanent removal of what Mother Nature has designed requires the broadest experience, competence and an aesthetic feel by a Master Craftsman in a procedure that permits a minor error, or absolutely none. I therefore completely agree with the author that this procedure cannot be generally applied to all nasal tip operations, and that it is not suitable for enthusiastic beginners in surgery who lack both experience and aesthetic criteria"...* *"It is likely that the author has found temporal fascia an ideal substitute after totally resecting alar cartilages. (Dr. Neeta Patel, in her commentary on this technique in the Aesthetic Plastic Surgery Journal. January 2009). Furthermore: "Dr. Rodríguez-Camps' contribution makes this nasal tip technique most interesting for difficult cases"...*

*"We are well aware that the nasal tip is one of the most difficult parts of Rhinoplasty, and that all of us have the technique that provides the best results available; but we also know that some rhinoplasty cases are very difficult to solve. Dr. Rodríguez-Camps' technique of totally removing alar cartilages and then introducing temporal fascia is novel and interesting"...* *"Needless to say, the results obtained by Dr. Rodríguez-Camps are excellent and we are enthusiastic about using this nasal aesthetic technique" (Dr. Guerrerosantos in his commentary on the technique in Cirugía Plástica Ibero-latinoamericana. Jan.-Feb.-March 2010).*

We conclude that when it seemed that everything had been described, and that the results depended only on our hands, something new and fresh appears: *"The Total Resection of the Alar Cartilages and Temporal Fascia Technique"*.

## 6. References

- Burget G, M.D. & Menick F, M.D.: Aesthetic Reconstruction of the Nose. First Edition. Mosby. 1994.
- Converse J, M.D.: Reconstructive Plastic Surgery. Second Edition. W. B. Saunders Company. Philadelphia, London, Toronto. Vol. 2 Chapter 29, 1040-1281. 1977.
- Ezquerro Carrera F., Sainz-Arregui J. & Berrazueta Fernández M. J.: La Rinoplastia No Basica Primaria. Cir. Plast. Ibero-latinoamer. Vol. 27 – N0. 1. January-February-March 2001. Pages 45-54.
- Goldman IB.: Eye Ear Nose Throat Mon, 1957 Dec; 36 (12):742-3.
- Guerrerosantos, J.: Temporoparietal Free Fascia Grafts in Rhinoplasty. Plastic and Reconstructive Surgery. Vol. 74. Issue 4. pag. 465-474. October 1984.
- Jack P. Gunter, M.D., Rod J. Rohrich, M.D. & William P. Adams, Jr. M.D.: Dallas Rhinoplasty. Nasal Surgery by the Masters. Second Edition. Quality Medical Publishing, Inc. St. Louis, Missouri. Vol. I, 303-590. 2007.
- Juri J, M.D., Juri C, M.D., Grilli D, M.D., Zeaiter MC, M.D. & Belmont J, M.D.: Correction of the Secondary Nasal Tip. Annals of Plastic Surgery. Vol. 16. N0. 4. 322-332. April 1986.
- Lipsett EM.: A new approach surgery of the lower cartilaginous vault. AMA Arch Otolaryngol, 1959 Jul; 70(1): 42-7.

- Meyer R.: Secondary and Functional Rhinoplasty. The Difficult Nose. First Edition. Grune & Stratton, Inc. Orlando, Florida. 1988.
- Peck G, M.D. Techniques in Aesthetic Rhinoplasty. First Edition. Gower Medical Publishing Ltd. New York, NY, U.S.A. 1984.
- Rodriguez-Camps S: Secondary Rhinoplasty in Cleft Nose. Rethi Technique. XX Spanish National Plastic, Reconstructive and Aesthetic Surgery Society (SECPRE) Meeting. Video Presentation. León, Spain. October, 1989.
- Rodriguez-Camps S: Nasal Reconstruction after Mohs Micrographic Surgery. Poster. Spanish National Reconstructive, Aesthetic and Plastic Surgery Society (SECPRE) Congress. Valladolid, Spain. June, 1994.
- Rodriguez-Camps S: Reconstrucción Nasal tras Cirugía Micrográfica de Mohs. Cir Plast Iberolatinoamer. Vol. XXI, no.3, 215-223, 1995.
- Rodriguez-Camps S: Total Reconstructive Rhinoplasty with the medial forehead flap. VIII Spanish National Reconstructive, Aesthetic and Plastic Surgery Society (SECPRE) Congress. Video Presentation. Santiago de Compostela, Spain. June, 1995.
- Rodriguez-Camps S: Nose Reconstruction with medial forehead flap after Mohs Surgery. International Video-Journal of Plastic and Aesthetic Surgery. Vol. 2, n° 3, December 1995.
- Rodriguez-Camps S: Aesthetic Rhinoplasty under local anaesthesia without sedation. XXXI Spanish National Reconstructive, Aesthetic and Plastic Surgery Society (SECPRE) Congress. Video Presentation. Madrid, Spain. September, 1996.
- Rodriguez-Camps S: Augmentative Rhinoplasty with auricular cartilage. Spanish National Reconstructive, Aesthetic and Plastic Surgery Society (SECPRE) Congress. Barcelona, Spain. April, 1997.
- Rodriguez-Camps S: Relapsing Basal Cell Ephithelioma of the nasal tip. Resection. Two-stage reconstruction with a frontal flap. Nasal Plastic surgery Symposium, tribute to Dr. Vilar-Sancho. The Ramón y Cajal Hospital, Madrid, Spain. February, 1998.
- Rodriguez-Camps S: Augmentative Rhinoplasty with an Auricular Gibbus. Aesth Plast Surg. Vol.22. n°. 3.196-205, 1998.
- Rodriguez-Camps S: Miscellaneous Rhinoplasty: Primary and Secondary. XXXIV Spanish National Reconstructive, Aesthetic and Plastic Surgery Society (SECPRE) Congress. Marbella, Spain. April, 1999.
- Rodriguez-Camps S: Rhinoplasty: Primary, Secondary and Reconstructive. II Plastic, Reconstructive and Aesthetic Surgery Society Meeting of the Valencian Community (SCPREECV). Alicante, Spain. February, 2000.
- Rodriguez-Camps S: Nasal Reconstruction After Epithelioma. Aesth Plastic Surg. Vol. 25. No. 4:273-277. July-August 2001.
- Rodriguez-Camps S: Aesthetic Nasal Reconstruction from the Oficial Book of the XXXVII Spanish National Reconstructive, Aesthetic and Plastic Surgery Society (SECPRE) Congress. Rhinoplasty, Chapter 11. Oviedo, Spain. June, 2002.
- Rodriguez-Camps S: Rhinoplasty. The Aesthetic Tip-Columela-Lip Unit. XV Latin American Federation of Plastic Surgery Congress (FILACP) and XXXIX Spanish National Reconstructive, Aesthetic and Plastic Surgery Society (SECPRE) Congress. Seville, Spain. May, 2004.

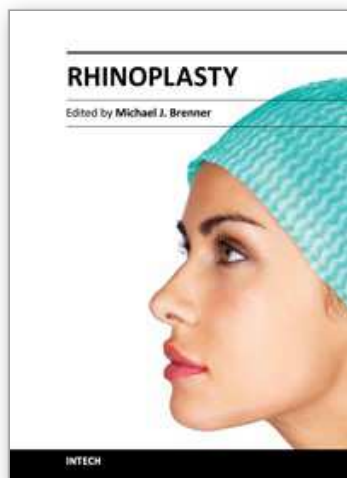


- Rodriguez-Camps S: Rhinoplasty: Nasal Base. V Plastic, Reconstructive and Aesthetic Surgery Society Meeting of the Valencian Community (SCPRECV). General University Hospital, Alicante, Spain. November, 2004.
- Rodriguez-Camps S: Nasal Reconstruction. VI National Reconstructive, Aesthetic and Plastic Surgery Society Meeting of the Valencian Community (SCPRECV). Valencia, Spain. October, 2005.
- Rodriguez-Camps S: Closed Rhinoplasty. Teaching Course on National Reconstructive, Aesthetic and Plastic Surgery. School of Medicine. University of Barcelona, Spain. November, 2005.
- Rodriguez-Camps S: Secondary Rhinoplasty: Our procedure. Total Resection of the Alar Cartilages and Domes with a Temporal Fascia Stamp on the Tip. XLI Spanish National Reconstructive, Aesthetic and Plastic Surgery Society (SECPRE) Congress. Paper. Pamplona, Spain. May, 2006.
- Rodriguez-Camps S: Nasal Reconstruction. VII Reconstructive, Aesthetic and Plastic Society Meeting of the Valencian Community (SCPRECV) Meeting. Alzira, Valencia, Spain. October, 2006.
- Rodriguez-Camps S: Reconstructive Rhinoplasty. Teaching Course on Reconstructive, Aesthetic and Plastic Surgery. School of Medicine. University of Barcelona, Spain. November, 2006.
- Rodriguez-Camps S: Rhinoplasty. The Difficult Nasal Tip: Total Resection of the Alar Cartilages. XIX Congress of the International Society of Aesthetic Plastic Surgery, (ISAPS). Panelist. Melbourne, Australia. February, 2008.
- Rodriguez-Camps S: Rhinoplasty. The Difficult Nasal Tip: Total Resection of the Alar Cartilages. Aesth. Plast. Surg. Vol. 33. No. 1. 72-83. January 2009.
- Rodriguez-Camps S: Una nueva técnica para el tratamiento de la punta nasal difícil. Experiencia personal de 22 años (1987-2009). Cirugía Plástica Ibero-latinoamericana Journal. Cir. Plast. Iberolatinoam. Vol. 36. No. 1. Pages 3-12. January-February-March 2010.
- Rodriguez-Camps S: New technique to treat a very difficult nasal tip. Total resection of the Alar Cartilages and Temporal Fascia Covering XLV Spanish National Reconstructive, Aesthetic and Plastic Surgery Society (SECPRE) Congress. Gerona, Spain. May, 2010.
- Rodriguez-Camps S: Demonstrating the Total Resection of the Alar Cartilages and Temporal Fascia Technique on a corpse as part of the VI Theoretical-Practical Course on Anatomical Dissection organized by the Spanish Association of Aesthetic Plastic Surgery (AECEP). I Course on Rhinoplasty and Facial Implants. Department of Human Anatomy and Embryology II, School of Medicine at the Complutense University of Madrid. Madrid, Spain. July 2010.
- Rodriguez-Camps S: Un paso adelante en Rinoplastia: Técnica de Resección Total de los Cartílagos Alares y Fascia Temporal. Spanish Association of Aesthetic Plastic Surgery Journal (AECEP). N°. 12. Pages 13-24. July-December 2010.
- Sheen J.: Aesthetic Rhinoplasty. Second Edition. The C.V. Mosby Company. Saint Louis 1978.
- Soria, J.H., Pintos, J.C., Conde, C.G. & Losardo, R.J.: Sobrepunta Nasal como Expresión de una Comunicación Septal. Cir.Plast. Iberolatinoam. Vol.35 n°. 4. October-

November–December 2009. Pages 243-248. Commentary on the work: Dr. Rodríguez-Camps, S.

Tardy M. E. Jr., M.D.: Surgical Anatomy of the Nose. First Edition. Raven Press, Ltd. New York, USA. 1990.

Wolfgang Gubisch, M.D.: Overresection of the Lower Lateral Cartilages: A Common Conceptual Mistake with Functional and Aesthetic Consequences. Aesth. Plast. Surg. 33:6-13 (2009).



## **Rhinoplasty**

Edited by Dr. Michael Brenner

ISBN 978-953-307-849-6

Hard cover, 146 pages

**Publisher** InTech

**Published online** 09, December, 2011

**Published in print edition** December, 2011

Rhinoplasty is one of the defining procedures of plastic and reconstructive surgery. Its roots stem from early efforts in nasal reconstruction to the emergence of modern rhinoplasty. This book describes the latest clinical and research perspectives in rhinoplasty and balances structural correction with aesthetic refinement. With treatises on rhinoplasty from a diverse set of thought leaders from around the world, the collective experience of this books' authors cover cosmetic and reconstructive approaches with a wealth of proven and innovative approaches ranging from minor refinement to major reconstruction. This diversity reflects the inherent complexity of the art and science of rhinoplasty. Discussion of structural approaches is balanced by consideration of judicious resection and refinement. The overarching goal is to instill an understanding of the subtleties of nasal structure and how the natural complexities of nasal anatomy can be adapted to maximize both function and natural appearance.

### **How to reference**

In order to correctly reference this scholarly work, feel free to copy and paste the following:

Salvador Rodríguez-Camps Devís (2011). Rhinoplasty – The Difficult Nasal Tip – Total Resection of the Alar Cartilages and Temporal Fascia Technique – A 24 Year Experience, Rhinoplasty, Dr. Michael Brenner (Ed.), ISBN: 978-953-307-849-6, InTech, Available from: <http://www.intechopen.com/books/rhinoplasty/rhinoplasty-the-difficult-nasal-tip-total-resection-of-the-alar-cartilages-and-temporal-fascia-techn>

**INTech**  
open science | open minds

### **InTech Europe**

University Campus STeP Ri  
Slavka Krautzeka 83/A  
51000 Rijeka, Croatia  
Phone: +385 (51) 770 447  
Fax: +385 (51) 686 166  
[www.intechopen.com](http://www.intechopen.com)

### **InTech China**

Unit 405, Office Block, Hotel Equatorial Shanghai  
No.65, Yan An Road (West), Shanghai, 200040, China  
中国上海市延安西路65号上海国际贵都大饭店办公楼405单元  
Phone: +86-21-62489820  
Fax: +86-21-62489821



© 2011 The Author(s). Licensee IntechOpen. This is an open access article distributed under the terms of the [Creative Commons Attribution 3.0 License](https://creativecommons.org/licenses/by/3.0/), which permits unrestricted use, distribution, and reproduction in any medium, provided the original work is properly cited.

IntechOpen

IntechOpen