

We are IntechOpen, the world's leading publisher of Open Access books Built by scientists, for scientists

6,900

Open access books available

186,000

International authors and editors

200M

Downloads

Our authors are among the

154

Countries delivered to

TOP 1%

most cited scientists

12.2%

Contributors from top 500 universities



WEB OF SCIENCE™

Selection of our books indexed in the Book Citation Index
in Web of Science™ Core Collection (BKCI)

Interested in publishing with us?
Contact book.department@intechopen.com

Numbers displayed above are based on latest data collected.
For more information visit www.intechopen.com



The Brachio-Brachial Arteriovenous Fistula

Lucian Florin Dorobanțu, Ovidiu Știru, Cristian Bulescu,
Șerban Bubenek and Vlad Anton Iliescu
*UMF "Carol Davila" București
Romania*

1. Introduction

The autogenous arteriovenous fistula (AVF) is the preferred access for chronic hemodialysis in patients with end-stage kidney disease. Careful examination of the upper extremity is essential for the creation of a successful fistula. The quality of the arterial and venous circulation should be well established prior to surgery. However, there are cases when the superficial venous system of the upper extremity is unsuitable for the creation of an autogenous AVF. This problem has two solutions: the use of a prosthetic graft or the creation of a brachio-brachial AVF. Prosthetic grafts have a 1-year patency rate of 65-75% (Haimov, 1978), mostly due to the frequent and varying complications that they may sustain, especially ischemia, thrombosis, infection, and aneurysms. The brachio-brachial AVF, a relatively new type of angioaccess, is shown to have similar patency rates to the prosthetic grafts, but without their number of complications and is a very good alternative for patients with an unsatisfactory superficial venous system (Dorobanțu et al., 2006, 2010).

2. Anatomy of the brachial artery and the venous system of the upper arm

The brachial artery is the continuation of the axillary artery beyond the inferior margin of the teres major muscle. It continues down the anterior aspect of the arm to the cubital fossa, being accompanied by two venae comitantes and the brachial nerve. Proximally, the nerve is lateral to the artery but it crosses the medial side of the artery distally, lying anterior to the elbow joint. The brachial artery divides into its terminal branches, the radial and the ulnar, 2 cm below the elbow bend (Gabella, 1995).

The venous system of the upper extremity comprises the superficial and the deep veins. Both groups have valves. The superficial veins (figure 1) are the cephalic, the basilic and the median vein of the forearm; they are subcutaneous in the superficial fascia. The cephalic vein forms over the "anatomical snuffbox" and ascends along the forearm's radial side and then in front of the elbow, in a groove between the brachioradialis and the biceps. It then crosses anteriorly the lateral cutaneous nerve and continues along the lateral border of the biceps, up to the delto-pectoral groove. It pierces the clavipectoral fascia and joins the axillary vein below the clavicular level.

The basilic vein begins medially in the hand's dorsal venous network and continues on the medial side of the forearm and then anterior to the elbow. Just distally to the elbow, it is joined by the median vein of the forearm. It ascends superficially between the biceps and the pronator teres, between filaments of the medial cutaneous nerve. It perforates the deep

fascia midway in the arm, continuing medial to the brachial artery to the lower border of the teres major, where it becomes the axillary vein.

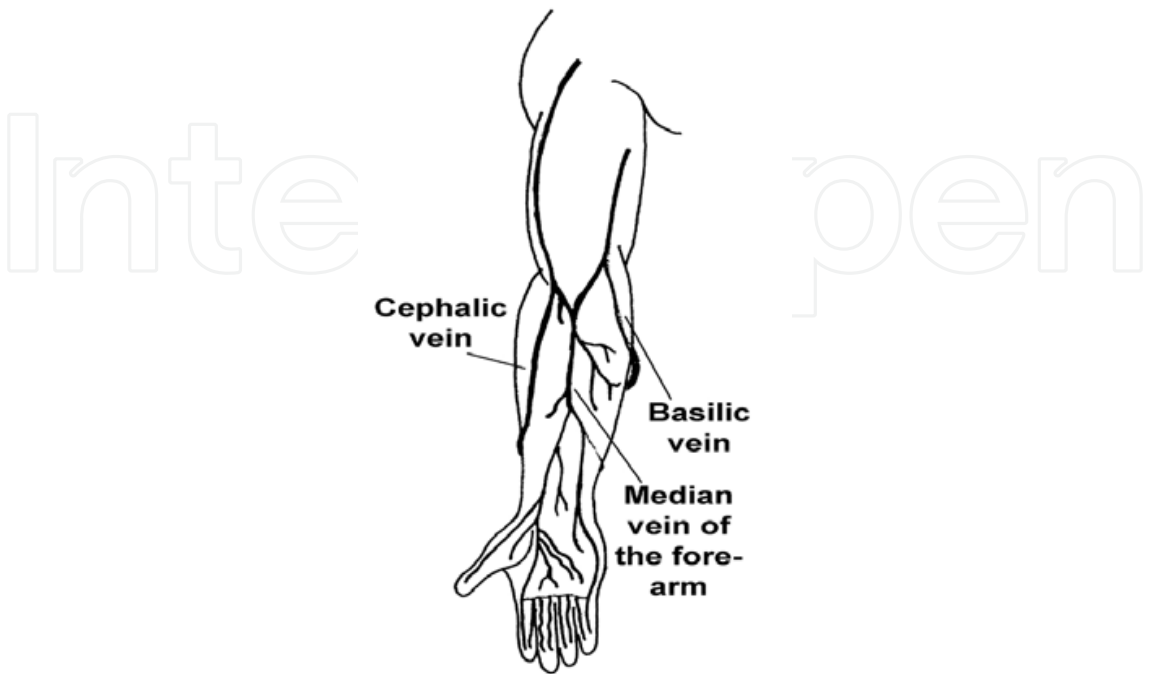


Fig. 1. The superficial veins of the upper limb

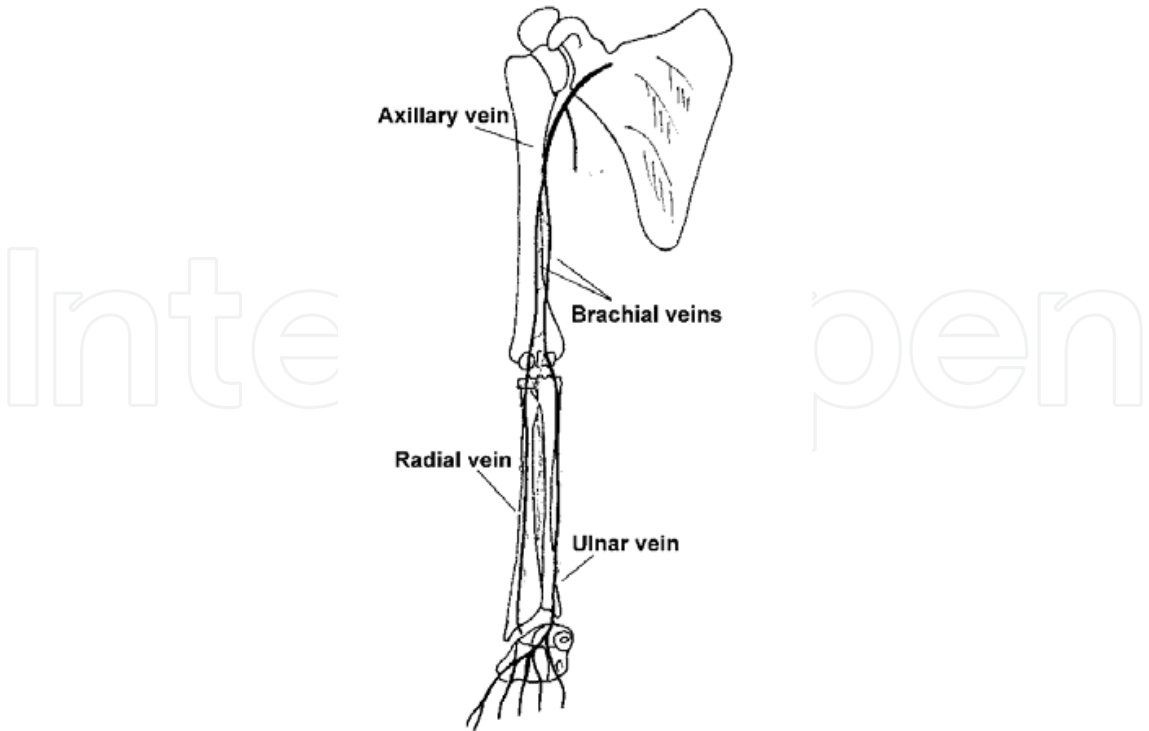


Fig. 2. The deep veins of the upper limb

The brachial veins (figure 2) share their path with the brachial artery. They begin at the junction between the radial and the ulnar veins and end at the inferior margin of the teres major muscle, where they are joined by the basilic vein, forming the axillary vein. There are many collaterals between the two veins and small tributaries that drain the muscles of the upper arm (Lupu et al., 2010).

3. Hemodynamics of an arteriovenous fistula

The arteriovenous fistula is an abnormal connection between a donor artery and a receiving vein. The permeability of the fistula depends on several factors. One of them is the resistance of the outflow vascular bed, which in this case is venous, and thus has a low pressure and a low resistance. As the vein's diameter increases through the maturation process, the venous resistance decreases. This process occurs during the first 4-8 weeks after the creation of the AVF and comprises a thickening of the venous wall, an increase in diameter for the vein, its distal branches, and for the arterial segment proximal to the anastomosis. As the vein is connected to a high-pressure, high-velocity artery, the blood flow through the vein induces an increased wall shear stress. Experiments have shown that acute increases in wall shear stress results in endothelial release of nitric oxide, which in turn increases the lumen radius. This is available for both acute and chronic wall shear alterations (Zarins et al., 2004). Experimentally produced arteriovenous fistulas produce an immediate 10-fold increase in blood flow and a three-fold increase in wall shear stress. Within 24 hours, vessel enlargement begins, and at the end of 4 weeks lumen radius enlarges twofold and wall shear stress returns to normal (Masuda & Bassiouny, 1989).

The flow through the AVF is insignificant as long as the vein's diameter doesn't exceed that of the artery by at least 20%; however, a palpable thrill means that the AVF is functional. When the diameter of the vein exceeds that of the artery by 75%, the venous resistance is virtually null, and the flow through the fistula is limited only by the arterial flow. Between 20 and 75%, the flow through the AVF increases on an exponential basis and it depends mainly on the venous resistance (Hobson et al., 1973).

It is noteworthy that the portion of the artery distal to the AVF does not suffer any modifications, thereby maintaining its high resistance relative to the outflow of the fistula. This can lead to a reversal of flow in this segment, the so-called "steal syndrome", which can result in ischemic complications. This is especially true in proximal fistulas.

The body's adaptation to the presence of an AVF includes global decreased vascular resistance and an increase in cardiac output, which can lead to a hyperdynamic syndrome or even to congestive heart failure. This is easily explained when the flow through a fistula ranges from 650 ml/min (for a radio-cephalic fistula) to 1000-1100 ml/min (for a brachio-cephalic, brachio-brachial or prosthetic fistula) (Schanzer, 2004; Știru, 2006). Any cardiovascular comorbidity can alter these patients' long-term prognosis.

4. Advantages of an autogenous arteriovenous fistula

A great number of studies have proven higher patency rates and lower complication rates for autogenous AVF when compared to synthetic bridge AVF (Palder et al., 1985; Enzler et al., 1996; Matsuura et al., 1998; Kherlakian et al., 2006; Kappos et al., 2007). Taking this into account, the National Kidney Foundation Dialysis Outcomes Quality Initiative (NKF-DOQI) guidelines for vascular access emphasize the use of the former over the latter (NKF-DOQI,

2001). Prosthetic and autologous AVF have similar patency rates for the first 4 postoperative weeks. After this period of time, synthetic bridge grafts require further interventions for angioplasty. Even with newer types of grafts, such as the Vectra Vascular Access grafts, the primary assisted rate of the prosthetic AVF is lower than that of the autogenous AVF at 18 months of follow-up (58% vs 78%, respectively) (Kappos, 2007). The same study shows an overall access thrombosis rate of 17% for autogenous AVF and 34% for the Vectra graft. This rate is higher for other materials, such as ePTFE (Segal et al., 2003; Choi et al., 2003).

Most complications can be treated conservatively, without compromising the fistula (Matsuura et al., 1998). Severe hand ischemia, necessitating surgical treatment, occurs in 1% of patients with AVF and 2.7-4.3% of patients with graft AVF (Porter et al., 1985). Also, steal syndrome occurs in 73% of autogenous AVF and in 91% of graft AVF, as demonstrated by hemodynamic studies. Therapeutic options for hand ischemia always involve surgical interventions and include banding of the AVF (which is sometimes impractical, especially with prosthetic AVFs) and complex revascularization procedures.

Infection is a rare complication of the autogenous AVF; because there is no foreign body, it responds well to drainage and antibiotics. On the other hand, an infected prosthetic graft is a potentially lethal complication. The presence of foreign material makes this complication very difficult to treat. Prophylactic antibiotics are given before constructing the prosthetic AVF. Treatment requires removal of the whole prosthetic segment, debridement and systemic antibiotics.

Perigraft seroma is a very rare complication of the autogenous AVF (Blumenberg et al., 1985). It is more common with prosthetic grafts, because of changes in the structure of the ePTFE and of certain biological alterations in the host (Sladen & Mandl, 1985; Ahn & Machleder, 1986). Minimally invasive treatment is often unsuccessful, so more aggressive measures must be taken, leading even to replacement of the graft.

There is also a decreased risk of intimal hyperplasia because the anastomosis is much smaller compared to the one used with a prosthetic graft (Lumsden & Chen, 1997). In the rare case of fistula failure, the surgeon still has the backup possibility of creating a synthetic bridge fistula, an option that he would lose should he employ a prosthetic fistula in the first place.

5. Surgical technique

We use the two-stage approach in creating a functional brachio-brachial fistula. Although a single-stage approach has been described by Bazan and Schanzer (Bazan & Schanzer, 2004), we found the two-stage procedure to be safer as mobilization of the arterialized vein is easier than the thin-walled initial vein (Dorobanțu et al., 2010).

The first stage involves anastomosing the brachial vein to the brachial artery. The upper extremity is circumferentially prepared up to the axilla and is placed in extension and abduction, with the hand in supination. Local anesthesia is used, infiltrating 1% Lidocaine in the cutaneous and subcutaneous tissue. A 4-5 cm longitudinal incision is made in the antecubital fossa, following the medial border of the biceps muscle. The muscle is retracted slightly laterally in order to allow access to the thin aponeurotic sheath which contains the neuro-vascular bundle. The sheath is opened and the artery is dissected clear of the median nerve, passing a loop tape underneath it. With the arteries are two venae comitantes, connected by fragile transverse and oblique branches. The vein with the greater diameter is chosen for the AVF. All of its branches are ligated and a longitudinal venotomy is performed. Flushing the vein with a heparinated saline solution (2500 units in 250 ml of

saline) verifies the vein's permeability. The entire length of the catheter is inserted into the vein. Now the brachial artery is cross-clamped proximally and distally to the proposed site of anastomosis and a longitudinal arteriotomy is performed. An end-to-side anastomosis is performed using a running nonabsorbable 7-0 polypropylene suture. The posterior wall is performed first and the brachial vein is divided distally before completing the anastomosis. Before tying the suture, the permeability of the fistula, as well as of the brachial artery should be evaluated. The vein should be inspected for a thrill; its absence indicates poor outflow and the surgeon must look for a potential problem and correct it (figure 3). All bleeding sources should be controlled and the skin is closed using interrupted simple sutures, without drainage (Știru, 2006; Iliescu, 2007).

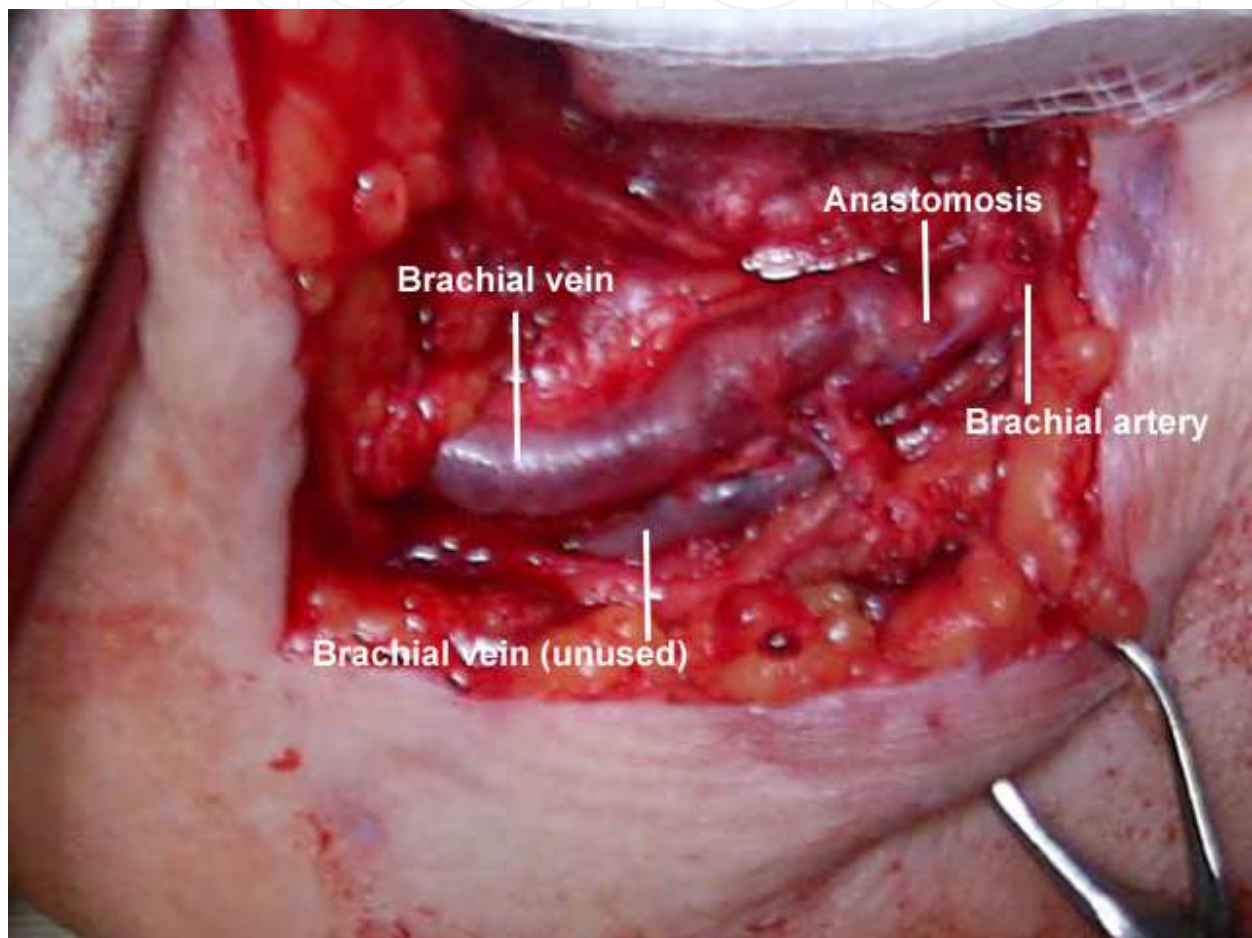


Fig. 3. The brachio-brachial fistula – intraoperative view

After 4 weeks, the vein is evaluated using Duplex scanning and, if its diameter is greater than 4 mm, it is transposed in a superficial plane in order to ease access for punctures. A longitudinal incision is performed on the antero-medial side of the arm, from the antecubital fossa to the axillary region. The neuro-vascular bundle is exposed, with the vein on the lateral side, the artery in the middle and the median nerve on the medial side. All of the venous collaterals are ligated, thus mobilizing the vein so that the aponeurosis can be closed underneath the vein with interrupted sutures (figure 4). A drainage tube is inserted and kept in place for 24 hours. The skin is closed with interrupted sutures, making sure that there is a 1.5 cm layer of tissue between the vein and the skin's surface to allow healing between needle punctures. The fistula can be used for hemodialysis after 3 weeks (Schanzer, 2004; Știru, 2006).

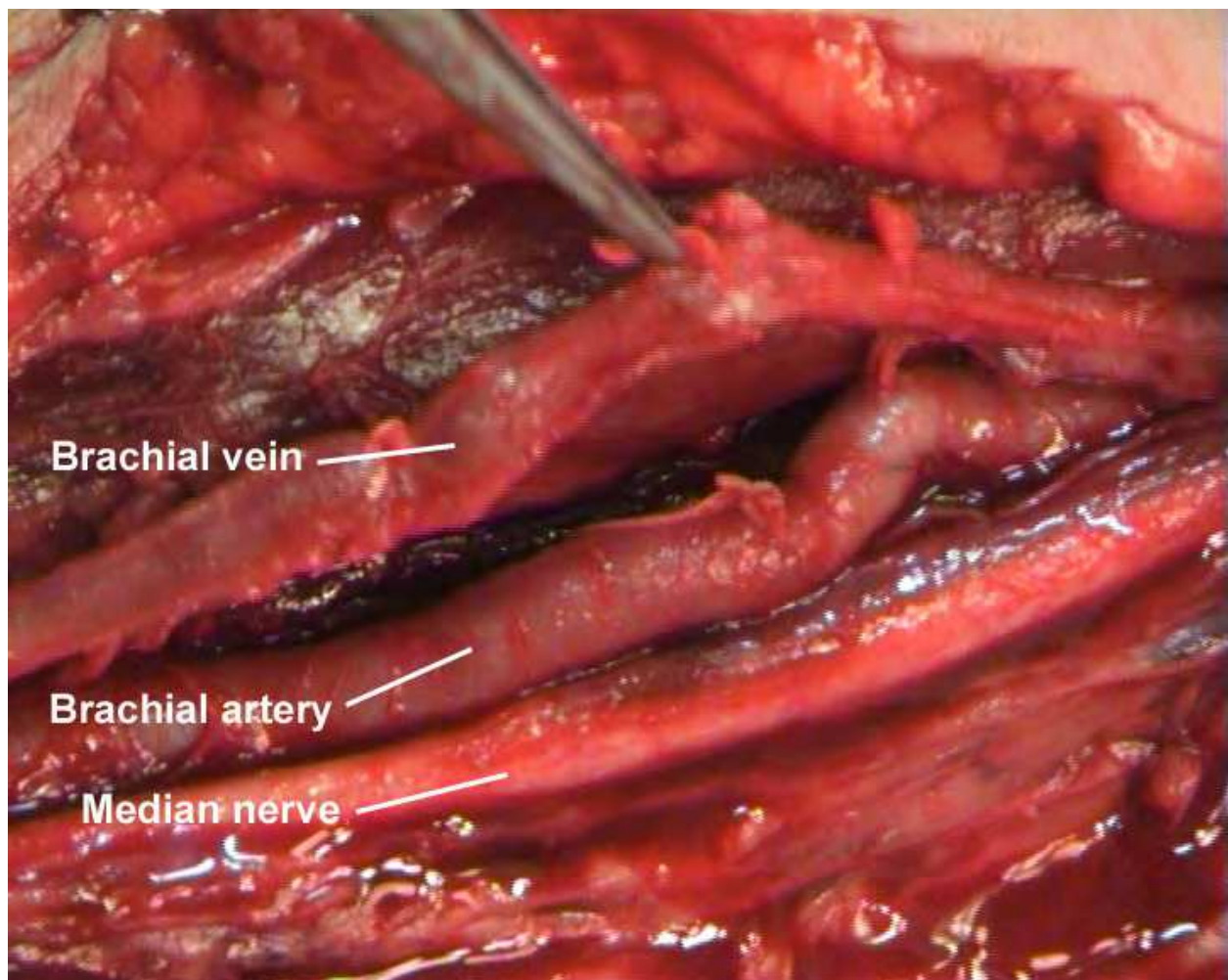


Fig. 4. Mobilization of the brachial vein

6. Results

Between 2004 and 2007 our team has operated on 49 patients with an upper arm venous system unsuitable for long term hemodialysis access, creating 49 brachio-brachial fistulas (Dorobantu et al., 2010). To date, this is the largest reported cohort of patients with a brachio-brachial AVF. Other groups have reported 17 (Casey et al., 2008), 20 (Angle et al., 2005) and 21 patients (Elwakeel et al. 2007). Thirty-nine patients (79,6%) had a functional fistula at the time of brachial vein transposition, after 4 weeks. The follow-up study was performed only in patients with a native functional brachio-brachial fistula after the two-step procedure. Mean follow-up period was 18.0 ± 11.1 months (range 3-37 months), longer than that of other published works, which ranged from 8 to 15.85 months. The overall patency rate at 37 months was 82.1%, compared to 75.89% at 1 year and 55.39% at 2 years reported by Elwakeel and 40% at 1 year reported by Casey. During this period, only seven patients presented with fistula occlusion 6, 6.4, 7.1, 9.4, 12.3, 23.5 and 35.0 months, respectively after superficialization.

No major complications have occurred with the patients. In 17 cases (43.6%) we noted discrete edema of the forearm, which disappeared after the first post-operative month; in only two cases has the edema extended to the entire arm. This was probably related to the greater pressure at the level of the remaining brachial vein, due to arterial pressure at the

level of the brachio-brachial fistula, and numerous collaterals between the two brachial veins. In nearly all the patients we noted the presence of a collateral superficial venous network, as an adaptive reaction to the greater pressure in the deep venous system. After the superficialization and the ligation of the collaterals between the two brachial veins, this edema disappeared. We noted only one important edema of the arm, which regressed after the transposition in the subcutaneous tissue of the arterialized brachial vein. We believe that the absence of other complications like persistent forearm edema, ischemic lesions, etc, was related to the presence of two satellite brachial veins; therefore, the remaining brachial vein sustains the deep venous drainage. Other groups have reported a higher number of complications, including hematomas, wound infections (Casey, 2008) and steal syndrome which required reintervention and revascularization of the upper extremity.

	Casey	Angle	Elwakeel	Dorobanțu
No. of patients	17	20	21	49
Mean follow-up (months)	8	14 ± 4	15.85 ± 9	18 ± 11.1
Maturation rate at 4 weeks	47%	100%	66.6%	79.6%
Patency rate				
At 12 months	40%		75.89%	
At 24 months			55.39%	
At 37 months				82.1%
Major complications				
• Hematoma	• 2		• 1	0
• Infection	• 2		• 1	
• Steal sdr.	• 3		• 0	
• Aneurysm	• 0		• 2	

Table 1. Comparison between several groups of patients with brachio-brachial fistulas

There were two cases of technical difficulties in mobilization of the brachial vein that had not been reported before: in one case we managed to maintain the native AVF (due to successful reconstruction of the arterialized vein in front of the median nerve) (figures 5 & 6), while in the other case where the arterialized vein remained too small, we were forced to make a prosthetic fistula. That was a rare event and we believe that it does not diminish the good results achieved with this technique.

No operative deaths occurred, but three patients died (after 2, 8 and 10 months) due to non-related causes and another three patients were lost at follow-up.

We consider that pre-operative ultrasound deep vein evaluation for the first step of the procedure is useless because the brachial vein is always a good native conduit with a variable diameter which does not influence the future of the AVF. Although there are authors that used only brachial veins with a diameter superior to 3 mm, they did not resolve the non-maturation problem (Pisoni et al., 2002).

When compared to the more traditional brachio-cephalic and brachio-basilic AVF, the brachio-brachial fistula shows similar patency and complications rates. A study published by Woo et al. in 2007, analyzing 190 patients with brachio-cephalic and brachio-basilic AVFs shows a patency rate of 56% for the brachio-cephalic and 71% for the brachio-basilic at 1 year. At 5 years, the patency rate was 40% for the brachio-cephalic and 56% for the brachio-

basilic. Complications rates were low, including 6 cases of steal syndrome (3.15%), 7 cases of bleeding (3.68%), 3 cases of infection (1.57%) and 1 case of early thrombosis (0.52%), but greater than in the brachio-brachial AVF.

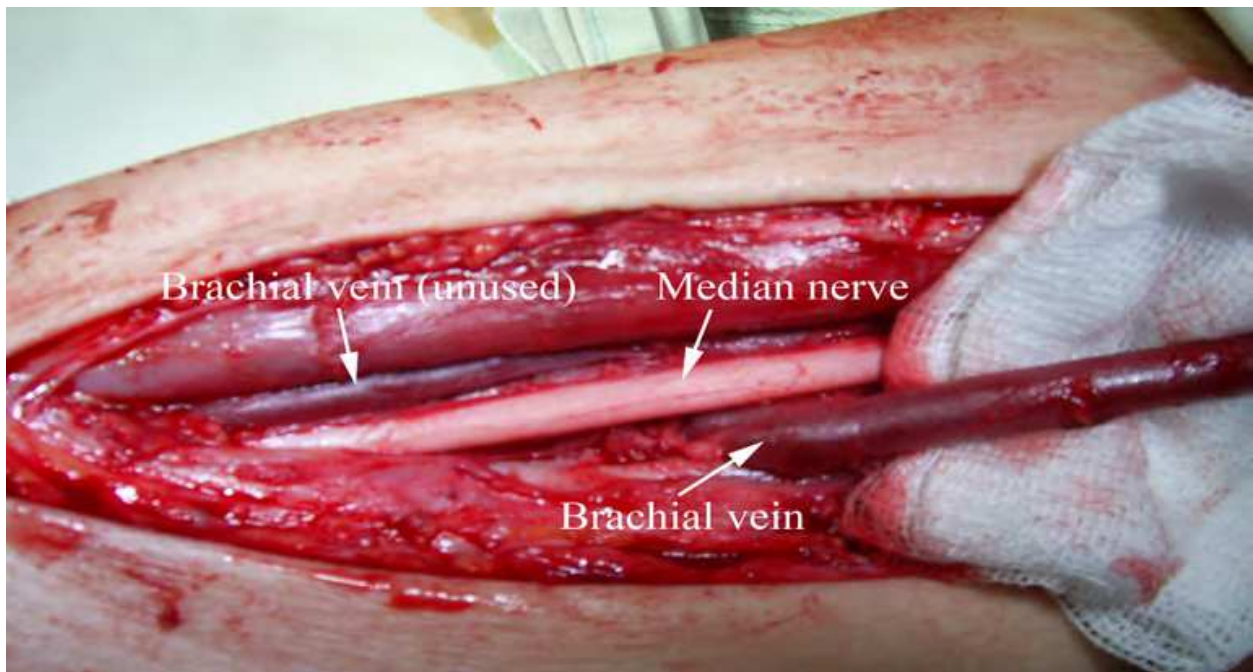


Fig. 5. The arterialized brachial vein runs under the median nerve

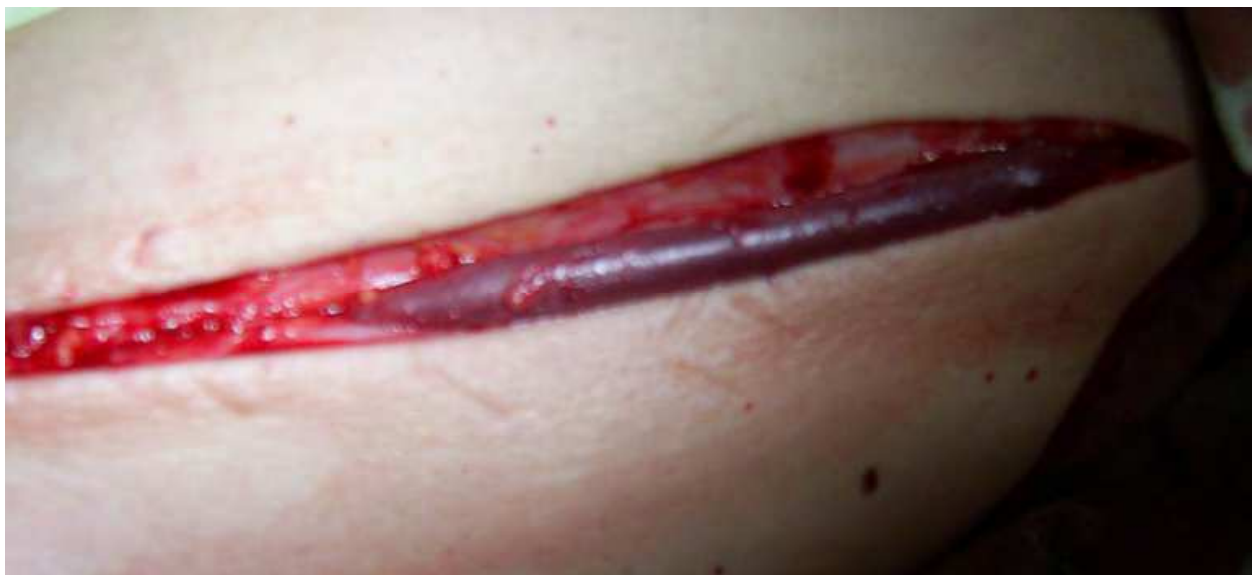

Fig. 6. Final result, after the vein has been divided and reconnected using an end-to-end anastomosis

7. Conclusions

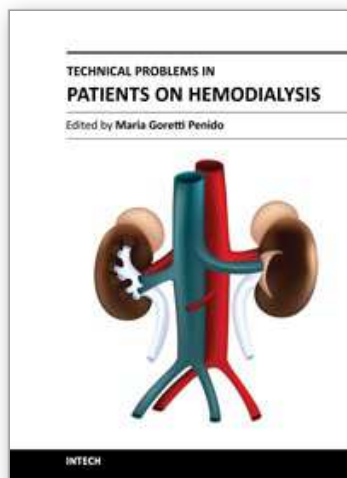
The brachio-brachial arteriovenous fistula is a viable solution for patients with an unsuitable superficial venous system. It can also be used in patients who already have malfunctioning arteriovenous fistulas using the superficial veins of the upper extremity. Studies have

shown that it has good patency and low complication rates, therefore its construction can postpone the use of a prosthetic bridge graft or a long-life hemodialysis catheter by several years. The surgical technique includes the same principles of other venous transpositions, so it should be incorporated into the arsenal of techniques that are routinely used by vascular access surgeons.

8. References

- Ahn, S.; Machleder, H., et al. (1986). Pathogenesis of perigraft seroma: evidence of a humoral fibroblast inhibitor. *Surg Forum*, No.37 (1986), pp. 460-461, ISSN 1522-666
- Angle, N.; Chandra, A. (2005). The two-stage brachial artery- brachial vein autogenous fistula for hemodialysis: An alternative autogenous option for hemodialysis access. *J Vasc Surg*, No.42 (2005), pp. 806-810, ISSN 0741-5214
- Bazan, H.A.; Schanzer, H. (2004). Transposition of the brachial vein: a new source for autologous arteriovenous fistulas. *J Vasc Surg*, No.40 (2004), pp. 184-186, ISSN 0741-5214
- Blumenberg, R.M.; Gelfand, M.; Dale, W. (1985). Perigraft seromas complicating arterial grafts. *Surgery*, No.97 (1985), pp. 192-203, ISSN 0039-6060
- Casey, K.; Tonnessen, B.K.; Mannava, K.; Noll, R.; Money, S.R. & Sternbergh W.C.III (2008). Brachial versus basilic vein dialysis fistulas: A comparison of maturation and patency rates. *J Vasc Surg*, No.47 (2008), pp. 202-206, ISSN 0741-5214
- Choi, H.M.; Lal, B.K.; Cerveira, J.J.; Padberg, F.T.; Silva, M.B.; Hobson, R.W. & Pappas, P.J. (2003). Durability and cumulative patency functional patency of transposed and non-transposed arteriovenous fistulas. *J Vasc Surg*, No.38 (2003), pp. 1206-1212, ISSN 0741-5214
- Dorobantu, L.F.; Stiru, O.; Iliescu, V.A.; Novelli, E. (2006). The brachio-brachial fistula: a new method in patients without a superficial venous system in the upper limb. *J Vasc Access*, No. 7 (2006), pp. 87-89, ISSN 1129-7298
- Dorobantu, L.F.; Stiru, O.; Iliescu, V.A.; Bubenek, S.; Novelli, E. (2010). The brachio-brachial arteriovenous fistula: mid-term results. *J Vasc Access*, No.11 (2010), pp.23-25, ISSN 1129-7298
- Elwakeel, H.A.; Saad, E.M.; Elkiran, Y.M. & Awad, I. (2007). Unusual vascular access for hemodialysis: transposed venae comitantes of the brachial artery. *Ann Vasc Surg* Vol.21, No.5 (2007), pp. 560-563, ISSN 0890-5096
- Enzler, M.A.; Rajmon, T.; Lachet, M.; Lagrader, F. (1996). Long-term function of vascular access for hemodialysis. *Clin Transplant*, Vol.10, No.5 (1996), pp. 511-515, ISSN 0890-9016
- Gabella, G. (1995). Arterial system, In Williams, P.L. (Ed.), *Gray's Anatomy*, 38th ed, pp. 1538-1539, Churchill Livingstone, ISBN 0-443-05717-6, Edinburgh, UK
- Haimov M. (1978). Clinical experience with the expanded polytetrafluoroethylene vascular prosthesis. *Angiology*, Vol.29, No.1 (1978)
- Hobson, R., Croom, R., Swan, K. (1973). Hemodynamics of the distal arteriovenous fistula in venous reconstruction. *J Surg Res*, No.14 (1973), pp. 438, ISBN 0022-4804
- Huber, T.S.; Carter, J.W.; Carter, R.L.; Seeker, J.M. (2003). Patency of autogenous and polytetrafluoroethylene upper extremity arteriovenous hemodialysis accesses: a systematic review. *J Vasc Surg*, No.38 (2003), pp. 1005-1011, ISSN 0741-5214
- Iliescu, V.A.; Stiru, O. & Dorobantu, L.F. (2007). *Fistula arteriovenoasa protetica*, Editura Academiei Romane, ISBN 978-973-27-1542-0, Bucharest, Romania

- Kakkos, K.S.; Andrzejewski, T.; Haddad, J.A.; Haddad, G.K.; Reddy, D.J.; Nypaver, T.J.; Scully, M.M.; RN & Schmid, D.L. (2008). Equivalent secondary patency rates of upper extremity Vectra Vascular Access Grafts and transposed brachial-basilic fistulas with aggressive access surveillance and endovascular treatment. *J Vasc Surg*, No.47 (2008), pp. 407-414, ISSN 0741-5214
- Kherlakian, G.M.; Roedersheimer, L.R.; Arbaugh, J.J., et al. (1986). Comparison of autogenous fistula versus expanded polytetrafluoroethylene graft fistula for angioaccess in hemodialysis. *Am J Surg*, No.152 (1986), pp. 238-243, ISSN 0002-9610
- Lumsden, B.M.; Chen, C. (1997). Accelerated neointimal hyperplasia in haemodialysis access grafts, In: Henry ML, Ferguson RM, (Ed.), *Vascular access for haemodialysis*, 5th ed., pp. 43-50, WL Gore and Precept Press, ISBN 0-944496-50-4, Chicago, Illinois, USA
- Lupu, G.; Terteliu, F.; Bulescu, I. (2009). Vascularizatia membrului superior, In Lupu, G. (Ed.), *Anatomie – Membrele*, pp. 47, Editura Universitara "Carol Davila", ISBN 978-973-708-428-6, Bucharest, Romania
- Masuda, H.; Bassiouny, H., et al. (1989). Artery wall restructuring in response to increased flow. *Surg Forum*, No.40 (1989), pp. 285-286, ISSN 1522-666
- Matsuura, J.H.; Rosenthal, D.; Clark, M., et al. (1998). Transposed basilic vein versus polytetrafluoroethylene for brachial-axillary arteriovenous fistulas. *Am J Surg*, No.176 (1998), pp. 219-221, ISSN 0002-9610
- Palder, S.B.; Kirkman, R.L.; Whittemore, A.D., et al. (1985). Vascular access for hemodialysis: Patency rates and results of revision. *Ann Surg*, No.202 (1985), pp. 235-239, ISSN 0003-4932
- Pisoni, R.; Young, E.W.; Dykstra, D., et al. (2002). Vascular access use in Europe and the United States: results from the DOPPS. *Kidney Int*, No.61 (2002), pp. 305-316, ISSN 1523-1755
- Porter, J.A.; Sharp, W.V.; Walsh, E.J. (1985). Complications of vascular access in a dialysis population. *Curr Surg*, No.42 (1985), pp. 298-300, ISSN 0149-7944
- Schanzer, H.; Schanzer, A. (2004). Vascular access for dialysis, In Ascher, E. (Ed.), *Haimovici's Vascular Surgery*, 5th ed., pp.1015-1030, Blackwell Science, ISBN 978-0-632-04458-0, Malden, Massachusetts, USA
- Segal, J.H.; Kayler, L.K.; Henke, P.; Merion, R.M.; Leavey, S.; Campbell, D.A. Jr. (2003). Vascular access outcomes using the transposed basilic vein arteriovenous fistula. *Am J Kidney Dis*, No.42 (2003), pp. 151-157, ISSN 0272-6386
- Sladen, J.; Mandl, M., et al. (1985) Fibroblast inhibition: a new and treatable cause of prosthetic graft failure. *Am J Surg*, No.149 (1985), pp. 588-590, ISSN 0002-9610
- Stiru, O.; Iliescu V.A. & Dorobantu, L.F. (2006). *Tehnici de fistule arteriovenoase native la nivelul membrului superior*, Editura Universitara "Carol Davila", ISBN 973-708-126-9, Bucharest, Romania
- The National Kidney Foundation Kidney Disease Outcomes Quality Initiative (2001). Clinical practice guidelines for vascular access: update. *Am J Kidney Dis*, No.37 (2001), pp. 137-181, ISSN 0272-6386
- Woo, K.; Farber, A.; Doros, G.; Killeen, K. & Kokanzadeh, S. (2007). Evaluation of the efficacy of the transposed upper arm arteriovenous fistula: A single institutional review of 190 basilic and cephalic vein transposition procedures. *J Vasc Surg*, No.46 (2007), pp. 94-101, ISSN 0741-5214
- Zarins, C.K.; Xu, C.; Bassiouny, H.S.; Glagov, S. (2004). Intimal hyperplasia, In Ascher, E. (Ed.), *Haimovici's Vascular Surgery*, 5th ed., pp. 165-167, Blackwell Science, ISBN 978-0-632-04458-0, Malden, Massachusetts, USA



Technical Problems in Patients on Hemodialysis

Edited by Prof. Maria Goretti Penido

ISBN 978-953-307-403-0

Hard cover, 312 pages

Publisher InTech

Published online 07, December, 2011

Published in print edition December, 2011

This book provides an overview of technical aspects in treatment of hemodialysis patients. Authors have contributed their most interesting findings in dealing with hemodialysis from the aspect of the tools and techniques used. Each chapter has been thoroughly revised and updated so the readers are acquainted with the latest data and observations in the area, where several aspects are to be considered. The book is comprehensive and not limited to a partial discussion of hemodialysis. To accomplish this we are pleased to have been able to summarize state of the art knowledge in each chapter of the book.

How to reference

In order to correctly reference this scholarly work, feel free to copy and paste the following:

Lucian Florin Dorobanțu, Ovidiu Știru, Cristian Bulescu, Șerban Bubenek and Vlad Anton Iliescu (2011). The Brachio-Brachial Arteriovenous Fistula, Technical Problems in Patients on Hemodialysis, Prof. Maria Goretti Penido (Ed.), ISBN: 978-953-307-403-0, InTech, Available from: <http://www.intechopen.com/books/technical-problems-in-patients-on-hemodialysis/the-brachio-brachial-arteriovenous-fistula>

INTECH
open science | open minds

InTech Europe

University Campus STeP Ri
Slavka Krautzeka 83/A
51000 Rijeka, Croatia
Phone: +385 (51) 770 447
Fax: +385 (51) 686 166
www.intechopen.com

InTech China

Unit 405, Office Block, Hotel Equatorial Shanghai
No.65, Yan An Road (West), Shanghai, 200040, China
中国上海市延安西路65号上海国际贵都大饭店办公楼405单元
Phone: +86-21-62489820
Fax: +86-21-62489821

© 2011 The Author(s). Licensee IntechOpen. This is an open access article distributed under the terms of the [Creative Commons Attribution 3.0 License](https://creativecommons.org/licenses/by/3.0/), which permits unrestricted use, distribution, and reproduction in any medium, provided the original work is properly cited.

IntechOpen

IntechOpen