

# We are IntechOpen, the world's leading publisher of Open Access books Built by scientists, for scientists

6,900

Open access books available

186,000

International authors and editors

200M

Downloads

Our authors are among the

154

Countries delivered to

TOP 1%

most cited scientists

12.2%

Contributors from top 500 universities



WEB OF SCIENCE™

Selection of our books indexed in the Book Citation Index  
in Web of Science™ Core Collection (BKCI)

Interested in publishing with us?  
Contact [book.department@intechopen.com](mailto:book.department@intechopen.com)

Numbers displayed above are based on latest data collected.  
For more information visit [www.intechopen.com](http://www.intechopen.com)



# Estimation of Electrode Position with Fused Images of Preoperative MRI and Postoperative CT Using the Mutual Information Technique After STN DBS in Patients with Advanced Parkinson's Disease

Sun Ha Paek

*Movement Disorder Center, Department of Neurosurgery, Seoul National University Hospital, Seoul National University College of Medicine, South Korea*

## 1. Introduction

Since the introduction of deep brain stimulation (DBS) by Benabid and colleagues in 1987, this technique has become the preferred treatment for patients with various movement disorders including Parkinson's disease (Benabid et al., 1987). Patients with advanced Parkinson's disease (PD) who have intolerable drug-induced side effects or motor complications following the long-term use of dopaminergic drugs have shown significant improvement in symptoms such as motor fluctuation and dyskinesia following subthalamic nucleus (STN) deep brain stimulation (DBS), facilitating reductions in dosages of levodopa (Limousin et al., 1998). Significant improvements in motor function have been documented in both short-term and long-term periods (Krack et al., 2003; Benabid et al., 2005; Lyons & Pahwa, 2005; Rodriguez-Oroz et al., 2005; Deuschl et al., 2006; Kleiner-Fisman et al., 2006; Tsai et al., 2009). However, variable improvement of symptoms has been observed after STN DBS even in well-selected patients with advanced PD (Paek et al., 2008). Such individual variation was not predictable before surgery and its cause is not obvious. Differences in the extent of disease progression or constitutional differences in response to STN DBS might lead to such variation; alternatively, it might be caused by differences in the accuracy of electrode positioning in relation to the STN.

The precise positioning of the electrodes in the STN is considered an important factor in achieving good clinical outcome following STN DBS. To achieve precise targeting of electrodes, many approaches have been taken; these include direct targeting based on fused images of CT-MRI, MRI-MRI, and MRI-brain atlas, as well as intra-operative microelectrode recording and intra-operative stimulation (Bejjani et al., 2000; Benazzou et al., 2002; Hamid et al., 2005; Godinho et al., 2006; Cho et al., 2010). However, many unexpected factors, such as possible brain shift due to CSF leakage, electrode artifacts in the MRI, and error in the manipulation of instruments, make it difficult to precisely position electrodes in the center of the STN (Martinez-Santesteban et al., 2007; Miyagi et al., 2007; Halpern et al., 2008; Khan et al., 2008). Thus, following surgery, not all patients have electrodes positioned exactly in

the STN. This might lead to different clinical outcomes following STN DBS in advanced PD patients. However, the existing literature contains few reports on the possible correlation between clinical outcome and electrode position confirmed at a stable period after bilateral STN stimulation.

The foregoing considerations suggest that it is necessary to determine the exact location of DBS electrodes after surgery in order to accurately predict clinical outcomes and to program appropriate stimulation parameters for STN DBS. The Movement Disorder Center of Seoul National University Hospital (SNUH MDC) was launched in March, 2005; at that time, DBS began to be covered by the National Health Insurance system in Korea. During the past six years, we have systematically approached the analysis of clinical outcome in terms of electrode position after bilateral STN stimulation (Heo et al., 2008; Kim et al., 2008a; Kim et al., 2008b; Lee et al., 2008; Kim et al., 2009; Kim et al., 2010; Lee et al., 2010a; Lee et al., 2010b; Paek et al., 2010).

In this chapter, I would like to briefly touch on these issues based on a review of the literature as well as on our own experience. I would also like to introduce the DBS Electrode Localization Analysis System (DELAS), an internet on-line service to estimate electrode positions with fused images of pre-operative MRI and post-operative CT using mutual information technique following STN DBS surgery in patients with advanced Parkinson's disease.

## **2. Image fusion using the mutual information technique and plotting of electrode positions with reference to the human brain atlas of Schaltenbrand and Wahren**

### **2.1 Image-to-image registration using the mutual information technique**

The mutual information technique is a commonly used image registration technique (Wells et al., 1996; Christensen et al., 1997; Maes et al., 1997). Fig. 1 (Lucion, Cybermed Inc., Korea) shows an instance of accurate registration between CT and MR images. The first image was obtained by preoperative MRI and the second by postoperative CT. The process of image-to-image registration using the mutual information technique can be briefly described as follows. Consider the 2D histogram of 3D images A and B for a given transform T between the two images: if the images have their discrete values m and n in  $[0 \dots M]$ , the 2D histogram is a function  $h(m,n)$  from  $[0 \dots M] \times [0 \dots N]$  to  $\ln$  that associates every pair of image values (m,n) with the number of occurrences in which image A equals n at the same spatial point x in 3D (for the given transform T, the number of such occurrences depends on parameters  $p:m=a(x)$  and  $n=B(T(x))$ ). If we consider 3D images A and B to be from the same modality, then when the images are registered, the histogram  $h(m,n)$  is an array that has accumulation points on the line  $m=n$ . These accumulation points are therefore very concentrated.

A possible way to characterize the complexity of a 2D histogram is to consider entropy. Entropy,  $e(p)$ , is minimal when the histogram is concentrated on very few accumulation points. It is given by the following equation:

$$e(p) = - \int P(m,n) \ln(P(m,n)) dm dn \quad (1)$$

When images are registered, the entropy will be minimized. Equation 1.1 is now replaced by the expression of mutual information, which has to be maximized, as follows:

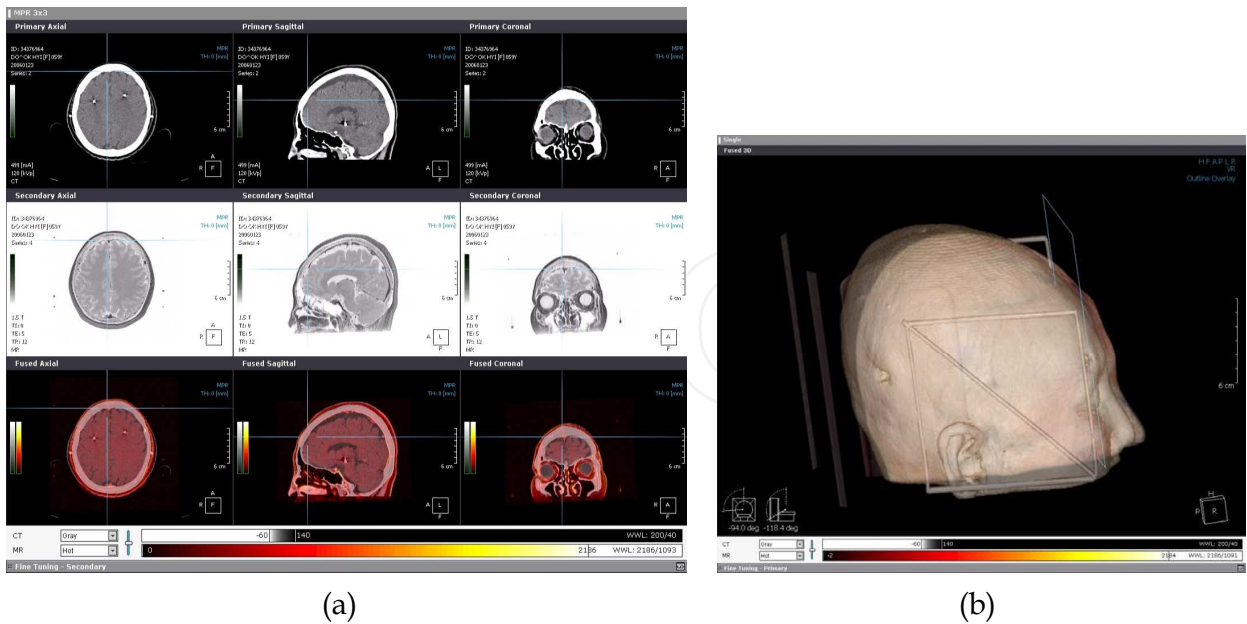


Fig. 1. Registration of multimodality images using entropy-based methods. (a) The different CT slices are shown with the edges of the registered and reformatted MR data overlaid. (b) A rendering of the 3D models constructed from different MR acquisitions that were registered together: anatomic information (the skin, the brain, the vessels, the ventricles) was generated from the post-contrast gradient echo (SPGR) MR images.

$$h(m,n)=-\int_s P(m)\ln(P(m))dm-\int_s P(n)\ln(P(n))dn+\int P(m,n)\ln(P(m,n))dm\,dn$$

(2)

The method of Wells et al. (1996) implements this principle very efficiently. In practice, images do not need to be of the same modality; they merely need to “look similar.” Obviously, there are some limitations to the method and many aspects remain to be explored; however, the technique has yielded very efficient results in a variety of instances (Pluim et al., 2003).

2.1.1 Calculation of mutual information (MI)

Calculation of MI is performed by employing formula (3) below. First, we need to obtain the mutual histogram,  $g(a,b)$ , of two volumetric images; then, by using the following equation, the normalized mutual information is obtained. As the optimization procedure proceeds, the value of MI gradually decreases. The optimization procedure terminates when the change in the MI value is below a threshold,

$$MI=\sum_{a,b}p_{u,v}(a,b)\log_2\frac{p_{uv}(a,b)}{p_u(a)p_v(b)},\text{ where}$$

$$p_u(x)=\sum_b p_{uv}(x,b),\; p_v(y)=\sum_a p_{uv}(a,y),\; \text{and}\; p_{uv}(x,y)=\frac{g(x,y)}{\sum_{a,b} g(a,b)}.$$

(3)

In this equation,  $g(a,b)$  represents the mutual histogram,  $x$  represents the intensity index of the primary image, and  $y$  represents the intensity index of the secondary image.



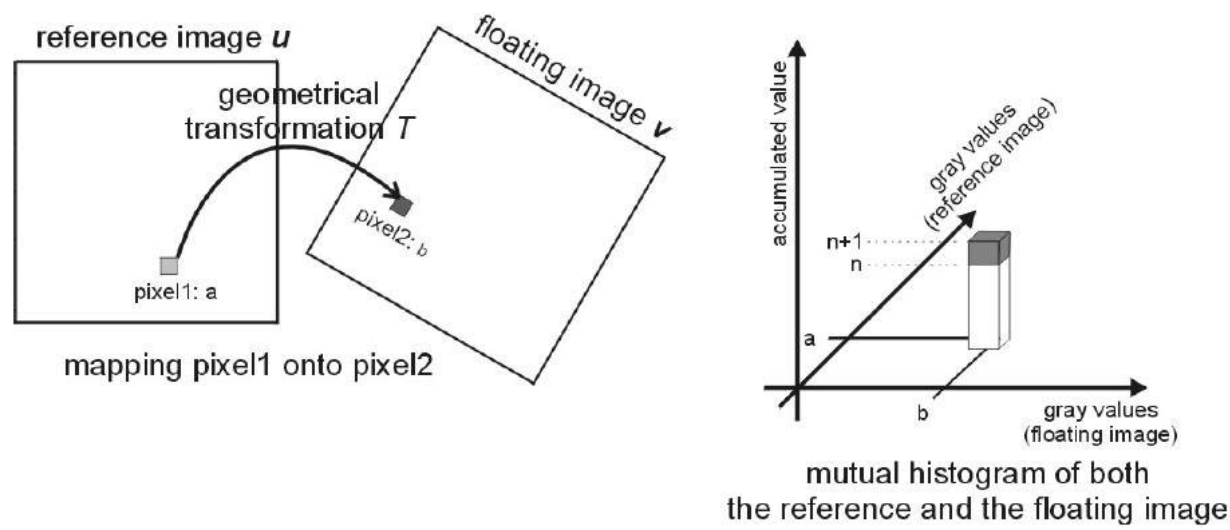


Fig. 2. Mutual histogram of two different images.

When the final screw vector is obtained, we can register the two volumetric images by applying the transformation to the secondary volume.

### 2.2 Image fusion of preoperative brain MRI and postoperative brain CT/MRI images and plotting of electrode positions with reference to the human brain atlas

Image fusions are performed using the mutual information technique with the preoperative brain MRI and the brain CT/MRI images taken after STN DBS. Window level and width are adjusted to best visualize the STN in the T2-weighted MRI and to best visualize the electrodes in the CT/MRI. The preoperative T2-weighted axial images are fused with the postoperative 3-D spiral CT scan images or T2-weighted axial images at the data set of 1-mm thickness reformatted images, aligned to the anterior commissure-posterior commissure

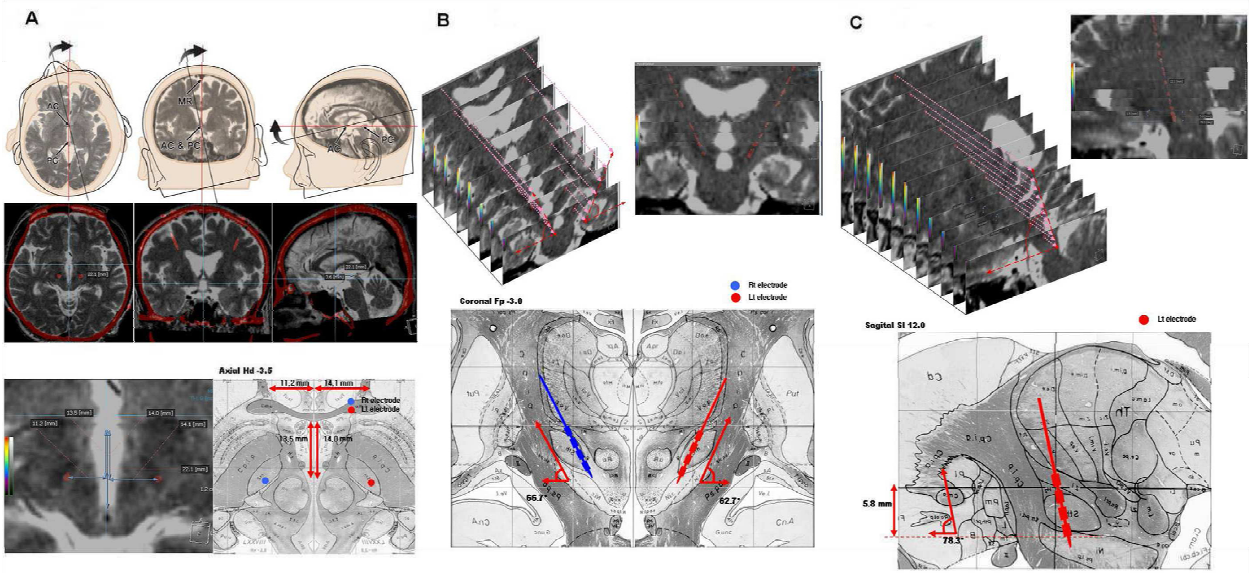


Fig. 3. Image fusion of preoperative MRI and postoperative brain CT.

(AC-PC) line. For the correction of head-rotation error, the midline of the reformatted coronal images is positioned to intersect the midsagittal plane. The length of the AC-PC line and the width of the third ventricle are taken into consideration for the proportional localization of electrode position with reference to the human brain atlas of Schaltenbrandt and Wahren (1998). In the reformatted axial images, the lateral distance from the midline and the antero-posterior distance from the mid-commissural line to each electrode are measured (Fig 3-A). In the reformatted coronal images in which the electrode trajectory is best visualized, the lateral angles of the electrode trajectory from the midline are measured for each electrode in every patient (Fig 3-B). In the reformatted sagittal images in which the electrode trajectory is best shown, the antero-posterior angle of the electrode trajectory from the line perpendicular to the AC-PC line and the depth of the electrodes are also measured for each electrode in every patient (Fig 3-C).

### **3. Comparison study of estimated electrode locations obtained using various image fusion techniques**

#### **3.1 Comparison study of CT and MRI for the localization of electrodes following subthalamic nucleus deep brain stimulation**

Despite the wide use of MRI in stereotactic neurosurgical procedures, the potential for distortion of normal anatomical structures in MRI in comparison with brain CT scans has been noted. Several studies focused on the reliability of MRI in target localization and concluded that though some differences were identified, they were not significant and that MRI alone may be used for target localization (Kondziolka et al., 1992; Holtzheimer et al., 1999). Relatively less attention has been paid to the accuracy of MRI in localization of electrode position, and the results have been controversial. However, by calculating magnetic field perturbations using a Fourier-based method for various wire microelectrodes, one study showed that significant artifact is produced depending on the magnetic susceptibility of the material used and on the size, shape, and orientation of the electrodes with respect to the primary magnetic field (Martinez-Santesteban et al., 2007). This study concluded that the platinum-iridium microwire commonly used for DBS shows a complete signal loss that covers a volume 400 times larger than the actual volume occupied by the microelectrode. Thus, artifacts caused by electrode interference with local magnetic fields can make it difficult to precisely localize the center of the electrodes in MRI.

We found that there is a considerable difference in the estimated electrode position obtained using postoperative CT and that obtained using MRI. Figure 4 shows fused images of a brain CT and a brain MRI from one patient, both taken 6 months after bilateral subthalamic stimulation. The fused images obtained from the MRI and the CT are aligned along the AC-PC line at the level of the AC and the PC in the axial, sagittal, and coronal planes. The red signal represents the position of the electrode extracted from brain CT images obtained six months after surgery, and the gray signal represents the position of the electrode extracted from brain MRI images obtained six months after surgery. The centers of the red and gray areas, representing the center of the electrode as extracted from brain CT and brain MRI images, respectively, do not coincide but instead show significant discrepancy in their positions in the axial, coronal, and sagittal planes of the fused images (Fig 4-A). With the adjustment of window level and width of the fused images, only the electrodes in red color are superimposed in 3-D reconstructive rendering brain MR images of the superior anterior view (Fig 4-B), the left anterior superior oblique view (Fig 4-C), and the anterior posterior view (Fig 4-D). The discrepancy in the electrode position extracted

from the brain CT and the center of the electrode artifact from the brain MRI taken 6 months after surgery is remarkable in all three (axial, sagittal, and coronal) planes.

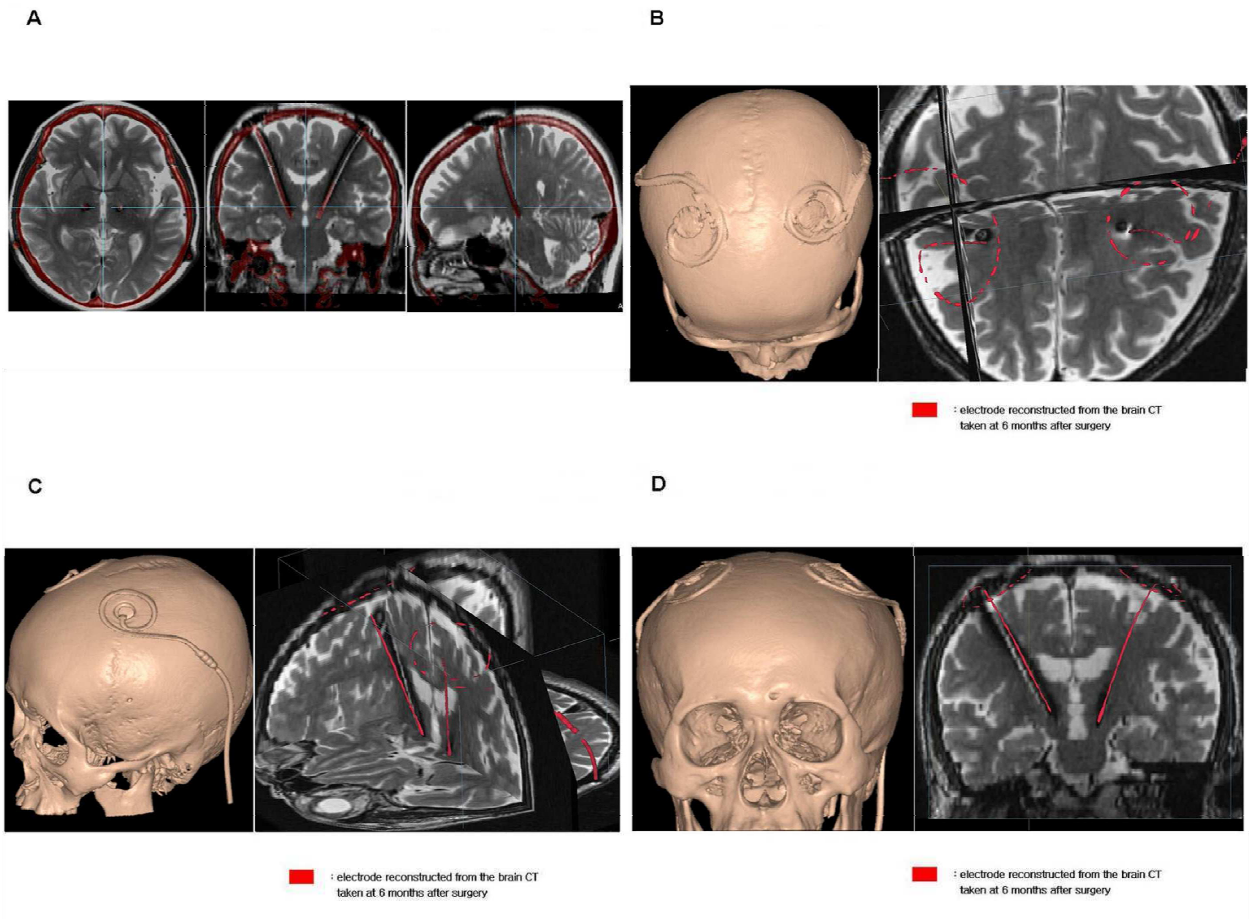


Fig. 4. Fused images of brain CT and brain MRI, both taken 6 months after bilateral subthalamic nucleus stimulation.

To validate the accuracy of MRI in electrode localization in comparison with CT scanning, we compared the X-, Y-, and Z- coordinates of the centers of the electrodes estimated by MRI and CT in 61 patients who received both MRI and CT at least six months after bilateral STN DBS (Lee et al., 2010b). The x- and y-coordinates of the centers of the electrodes shown by CT and MRI were compared in the fused images, and the average difference at five different levels was calculated. The difference in the location of the tips of the electrodes, designated as the z coordinate, was also calculated.

The average distance between the centers of the electrodes in the five levels estimated in the fused images of brain CT and MRI taken at least 6 months after STN DBS was 1.33 mm (0.1–5.8 mm). The average discrepancy of the x coordinates for all five levels between MRI and CT was  $0.56 \pm 0.54$  mm (0–5.7 mm); the discrepancy of the y coordinates was  $1.06 \pm 0.59$  mm (0–3.5 mm) and that of the z coordinates was  $0.98 \pm 0.52$  mm (0–3.1 mm) (all p values <0.001). Notably, the average discrepancy of x coordinates at 3.5 mm below the AC-PC level, i.e., at the level of the STN, was  $0.59 \pm 0.42$  mm (0–2.4) between MRI and CT; the discrepancy of the y coordinates at this level was  $0.81 \pm 0.47$  mm (0–2.9) (p values <0.001). It is suggested that the electrode location evaluated by postoperative MRI may show significant discrepancy with that estimated by brain CT scan.



**3.2 Comparison of electrode location measured on the immediate postoperative day and six months after bilateral STN DBS**

Despite the wide use of brain CT scans during and immediately after DBS surgery, unexpected circumstances during surgery, such as electrode bending and possible brain shift due to CSF leakage, have not been seriously considered in the estimation of electrode position using brain CT in the immediate postoperative period after DBS surgeries. One study, which used brain CT to evaluate and correct geometrical error due to brain shift during stereotactic brain surgery (van den Munckhof et al., 2010), showed that the stereotactically implanted DBS electrodes were displaced in an upward direction with time and that this displacement was significantly correlated with the amount of air in the subdural space. This study calculated the displacement of the electrode on the fusion image of preoperative and postoperative images. However, the fiducial points for the fusion of different images were not associated with brain structures but with the skull. The migration of metallic material in the parenchyma of the central nervous system has also been reported (Ott et al., 1976; Sorensen & Krauss, 1991). We observed considerable brain shift when comparing immediate postoperative CT scans and CT scans taken 6 months after surgery. We also found considerable discrepancy in the apparent electrode position on immediate postoperative CT scans and brain CT scans taken 6 months after surgery (Fig. 5).

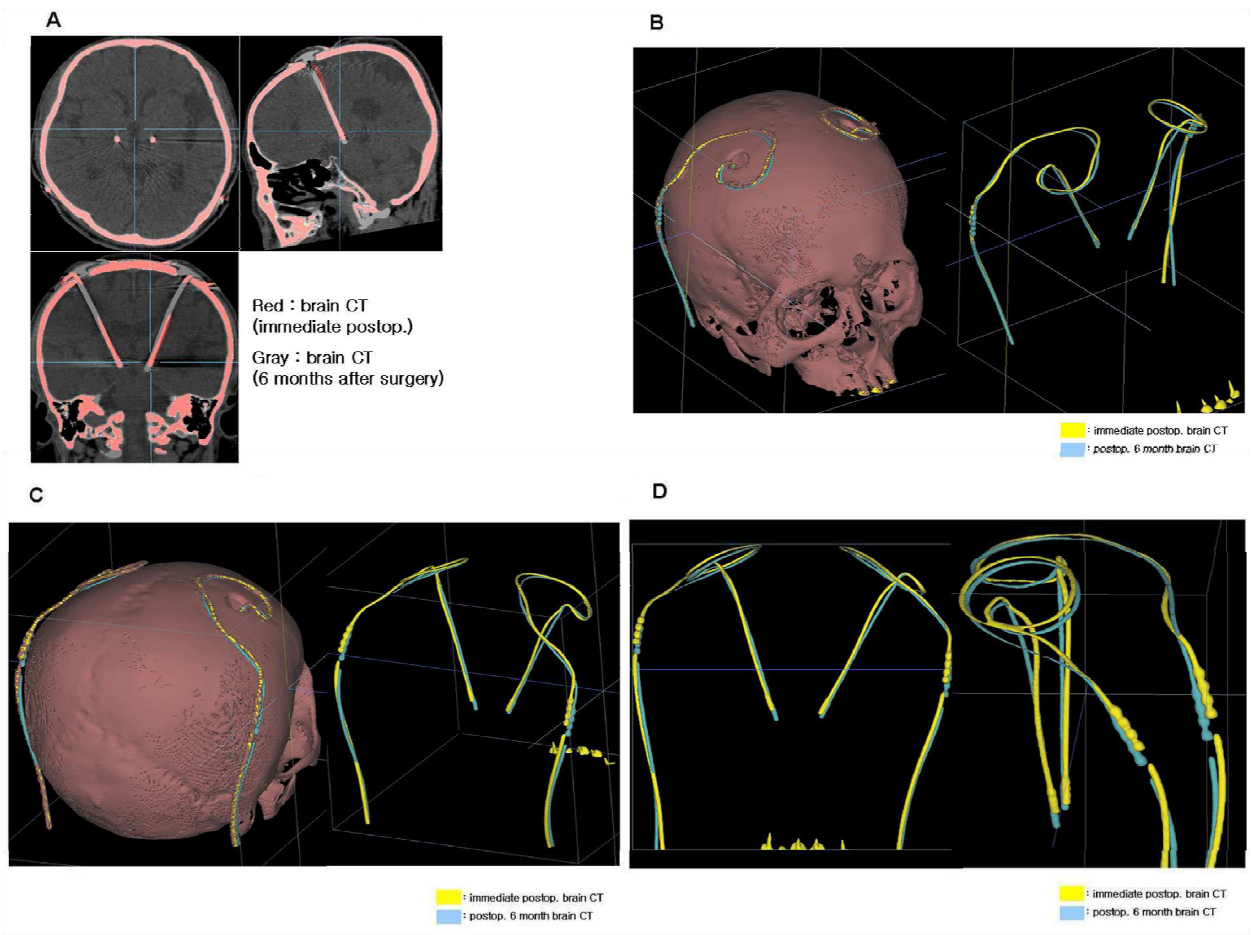


Fig. 5. Fused images of an immediate postoperative brain CT and a brain CT taken 6 months after bilateral subthalamic nucleus stimulation.

In Fig. 5, fused images obtained from two CT scans are aligned along the AC-PC line at the level of the AC and the PC in the axial, sagittal, and coronal planes. The red area represents the position of the electrode extracted from brain CT images obtained immediately after surgery, and the gray area represents the position of the electrode extracted from brain CT images taken six months after surgery. The red and the gray areas do not coincide, exhibiting significant discrepancy in their positions in the axial and coronal planes (Fig 5-A). With the adjustment of window level and width of the fused images, only the shadow of both electrodes is extracted in 3-D reconstructive rendering images of the right superior oblique view (Fig 5-B), the right posterior oblique view (Fig 5-C), and the AP and lateral views (Fig 5-D). In these views, the yellow area represents the position of the electrode extracted from brain CT images obtained immediately after surgery, and the sky-blue area represents the position of the electrode extracted from brain CT images taken six months after surgery. The discrepancy in the electrode position between the two CT scans is remarkable and significant.

We compared the positions of subthalamic nucleus (STN) deep brain stimulation (DBS) electrodes estimated during the immediate postoperative period with those estimated 6 months after surgery. Brain CT scans were taken immediately and 6 months after bilateral STN DBS in 53 patients with Parkinson's disease (Fig 5.). (Kim et al., 2010). The two images were fused using the mutual information technique. The discrepancies in electrode position in three coordinates were measured in the fused images, and the relationship with the pneumocephalus was evaluated.

The average discrepancies of the x- and y-coordinates of the electrode position at the level of the STN (3.5 mm below the anterior commissure-posterior commissure line) were  $0.6 \pm 0.5$  mm (range, 0-2.1 mm) and  $1.0 \pm 0.8$  mm (range, 0~5.2 mm), respectively. The average discrepancy of the z-coordinate of the electrode tip in the fused images was  $1.0 \pm 0.8$  mm (range, 0.1~4.0 mm). The volume of pneumocephalus (range, 0-76 ml) was correlated with the y-coordinate discrepancies ( $p < 0.005$ ).

We found that there was significant discrepancy in the implanted electrode position measured during the immediate postoperative period and that measured 6 months after DBS surgery. The discrepancy was greatest when the amount of pneumocephalus measured in the immediate postoperative CT scan was large. We think that the stabilization of the electrode position may require at least one month following surgery.

#### **4. Analysis of clinical outcome dependence on electrode position following subthalamic nucleus stimulation**

##### **4.1 Data management system in a movement disorder center**

When evaluating patients with movement disorders such as Parkinson's disease (PD), most neurologists observe patients only during a limited period at the outpatient clinic. Such limited periods of observation may be less than optimal for precise evaluation of patients with varying and unexpected patterns of movement and for supporting the development of optimal treatment plans for such patients. In order to have a good DBS program, a system that can handle the vast amount of data generated by a DBS program is required (Lee et al., 2008). Data include information on patients' pre- and postoperative clinical condition (including videos), medications and stimulation-related parameters. For proper management of patients, easy access to these data is essential. For this reason, we designed a specialized monitoring unit and data management system with systematic storage and



easy access for use in deep brain stimulation programs for patients with movement disorders (Paek et al., 2010). All patients were monitored and evaluated in a specialized 24-hour monitoring system, postoperatively as well as preoperatively, in order to provide information for making accurate diagnoses and thorough evaluation of surgical candidates, as well as to provide them with the best care based on a consistent management protocol and an organized follow-up system. We digitized all of the data and developed a data management system that allowed systematic storage and easy access to the data on demand by users in the offices and outpatient clinics. We describe our data management system and how it provides benefit to patients (Fig. 6), so that others may use it as a template for designing their own data management systems. The details have been described previously (Paek et al., 2010).

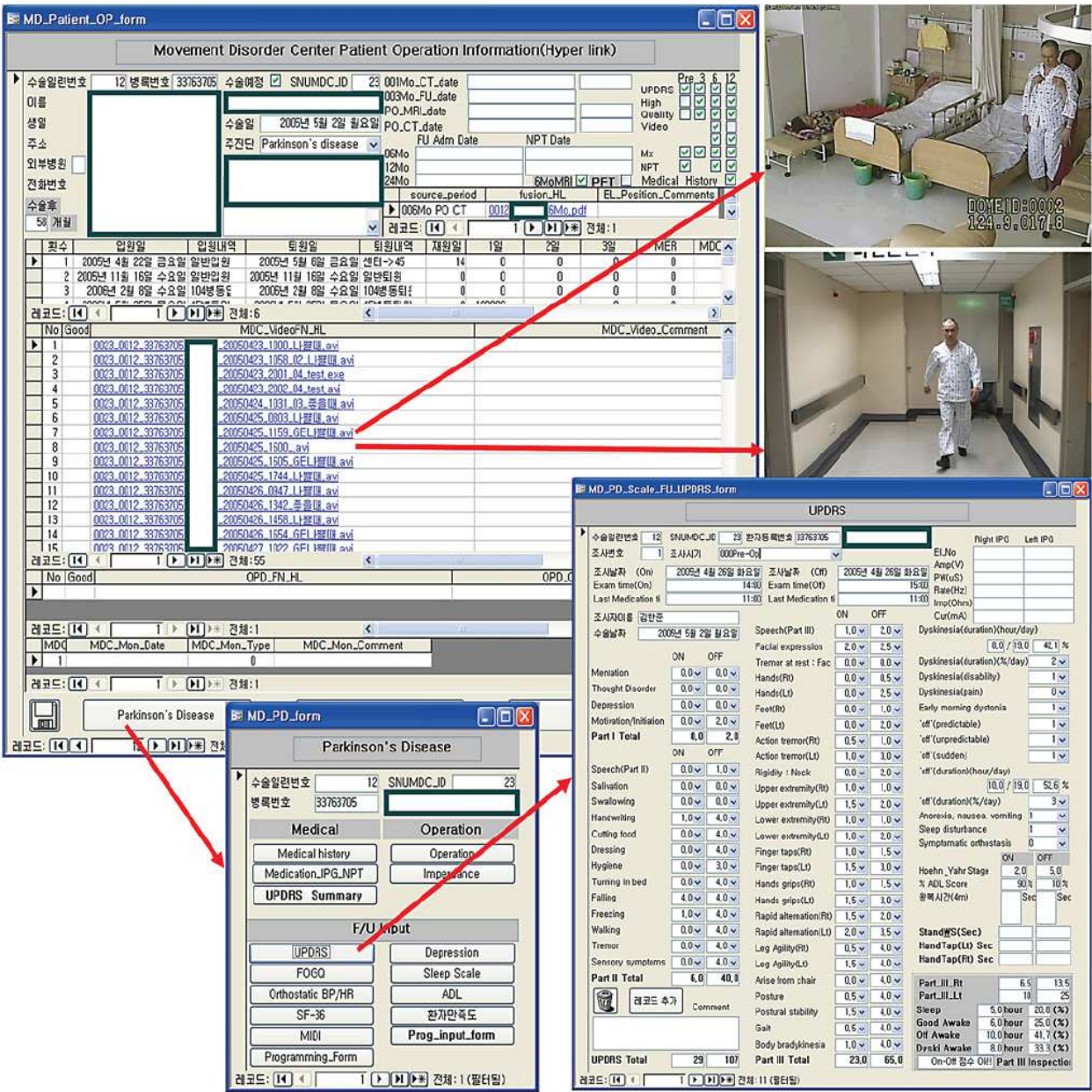


Fig. 6. Data management system in the Movement Disorder Center of SNUH.



The easy accessibility and the outstanding convenience for users of the stacked information in our data management system are useful in many ways.

First, they can improve the quality of patient management. Our specialized 24-hour monitoring system can provide more precise preoperative evaluation of patients with various movement disorders, including advanced PD, and can show various and unexpected side effects including the severe wearing-off phenomenon, dyskinesia and motor fluctuation during their 24-hour daily lives. The systematic management system can be useful not only for the selection of surgical candidates but also for dose adjustment of stimulation parameters before and after surgery.

Second, our data management system can be a useful tool for the education for patients and their caregivers. Many patients with PD have difficulty differentiating between off tremor, dystonia and dyskinesia. Video recordings were helpful in educating the patients about the conditions seen in the videos and in teaching them how to describe their symptoms correctly for future communication.

Third, we can use the data to continually review our performance and to perform standardized outcome analysis. With our data management system, we can access all the collected data representing integrated clinical information on all our patients and carry out a statistical evaluation of our performance.

#### **4.2 Short-term outcome dependence on electrode position as determined by fused images of preoperative and postoperative brain MRI following bilateral subthalamic nucleus stimulation**

STN DBS improves motor symptoms and daily activities in patients with advanced PD (Krack et al., 2003; Benabid et al., 2005; Lyons & Pahwa, 2005; Rodriguez-Oroz et al., 2005; Deuschl et al., 2006; Kleiner-Fisman et al., 2006; Tsai et al., 2009). However, variable improvement of symptoms has been observed after STN DBS, even in well-selected patients with advanced PD (Krack et al., 2003; Ford et al., 2004). Such individual variation was not predictable before surgery and no obvious explanation for it is evident; it might have resulted from differences in the extent of disease progression, constitutional differences in individual patients' responses to STN DBS, or the relative accuracy of electrode positioning. Many studies have discussed the technical details of electrode localization in postoperative magnetic resonance imaging (MRI) and have described the anatomical locations of clinically effective electrode contacts (Saint-Cyr et al., 2002; Schrader et al., 2002; Starr et al., 2002; Yelnik et al., 2003; Hamid et al., 2005; Plaha et al., 2006; Pollo et al., 2007). However, most reports do not include a comparison of electrode location and surgical outcome. Plaha et al. (2006) stated that electrodes located in the zona incerta resulted in greater improvement in contralateral motor scores than those located in the STN or dorsomedial/medial to the STN after STN DBS. These authors used guide tubes and plastic stylets implanted in the target point and performed intraoperative MRI to verify the electrode position. Postoperative confirmation of the electrode location was not carried out. McClelland et al. (2005) calculated the electrode tip coordinates in x, y, and z planes relative to the midcommissural point from fused MRI scans of postoperative and preoperative planning images in 26 consecutive patients and compared electrode tip location with clinical outcome. Yokoyama et al. (2006) compared the clinical improvement of Parkinsonian symptoms after monopolar stimulation using four electrode contacts, the locations of which were determined using intraoperative x-rays obtained after placing the DBS electrode in the STN. In both of these studies, the positions of the electrodes were determined by intraoperative x-ray or by using

fused images from immediate pre- and postoperative MRI. Possible brain shift during the operation and/or the immediate postoperative period could be a concern regarding the accuracy of the electrode localization. Both studies assessed electrode position relative to the AC-PC line or to the midcommissural point, but neither demonstrated a 3-dimensional relationship between the electrode and the STN.

We evaluated the clinical outcomes of 53 advanced PD patients at three and six months after bilateral STN DBS with respect to electrode position estimated from fused pre- and postoperative magnetic resonance images (Paek et al., 2008). Patients were evaluated using the Unified Parkinson's Disease Rating Scale, Hoehn and Yahr staging, Schwab and England Activities of Daily Living, L-dopa equivalent dose, and the Short Form-36 Health Survey before surgery and at 3 and 6 months after surgery. Brain magnetic resonance imaging (1.5-T) was performed in all 53 patients at 6 months after STN DBS.

In this group of patients, the Unified Parkinson's Disease Rating Scale, Hoehn and Yahr staging, Schwab and England Activities of Daily Living, and Short Form-36 Health Survey scores all improved at 3 and 6 months after STN DBS, while the L-dopa equivalent dose decreased by 60%. The electrode position was classified according to its relationship to the STN and the red nucleus. The off-medication speech subscale score improved only in patients whose electrodes were correctly bilaterally positioned in the STN; however, the improvement of Parkinsonian symptoms other than speech and stimulation side effects did not vary with the variation of electrode locations found. It seems that there is a significant target volume in the region of the STN that provides equivalent clinical efficacy.

Despite these correlations, we found that there is a significant difference in electrode position determined from the fused images of postoperative MRI and CT scans taken six months after surgery and those measured immediately following bilateral STN DBS surgery. Thus, we again compared the clinical outcomes of 57 advanced PD patients at six and twelve months following bilateral STN DBS according to electrode positions estimated using fused preoperative magnetic resonance images and postoperative computed tomography obtained six months after surgery. Electrode positions were determined in the fused images of preoperative magnetic resonance images and postoperative computed tomography taken at six months after surgery. The patients were divided into three groups: group I, both electrodes in the subthalamic nucleus; group II, only one electrode in the subthalamic nucleus; group III, neither electrode in the subthalamic nucleus. Unified Parkinson's Disease Rating Scale, Hoehn and Yahr Stage, Schwab and England Activities of Daily Living were prospectively evaluated before and at 6 and 12 months after surgery.

In Groups I and II, the Unified Parkinson's Disease Rating Scale, the Hoehn and Yahr Stage, and the Schwab and England Activities of Daily Living scores significantly improved with a reduced L-dopa equivalent daily dose at 6 and 12 months after subthalamic nucleus stimulation. The patients of group I, especially those in whom the electrodes were located in the middle third of both subthalamic nuclei 3.5 mm below the anterior-posterior commissural line, had better outcome in speech with a smaller L-dopa equivalent daily dose than that of the two other groups.

The LEDD of 13 of the 57 patients was zero at their last follow up. The preoperative characteristics of this group were not different from those of the other patients. Their total UPDRS scores, H&Y Stage, SEADL, and dyskinesia disability scores improved dramatically at 12 months after STN DBS. Their off-time UPDRS part III subscores, including speech, were significantly improved at 12 months after surgery. On investigating electrode positioning in these patients, it was found that all had both electrodes positioned in or close

to the middle one third of the STN on axial view, at a level of 3.5 mm below the AC-PC line. It is suggested that the best symptom relief, including improved speech with reduced LEDD, was observed in the patients whose electrodes were accurately positioned in both STN. Thus, a good long-term outcome of subthalamic nucleus stimulation is predicted when the electrodes are positioned in the middle third of the subthalamic nucleus (Fig. 7). However, the improvement of Parkinsonian symptoms, LEDD, neuropsychological changes other than speech, and stimulation side effects did not vary with the variation of electrode location found in this series of patients. This study thus supports the idea proposed by McClelland et al. (2005) that there is a significant target volume in the region of the STN that provides equivalent clinical efficacy.

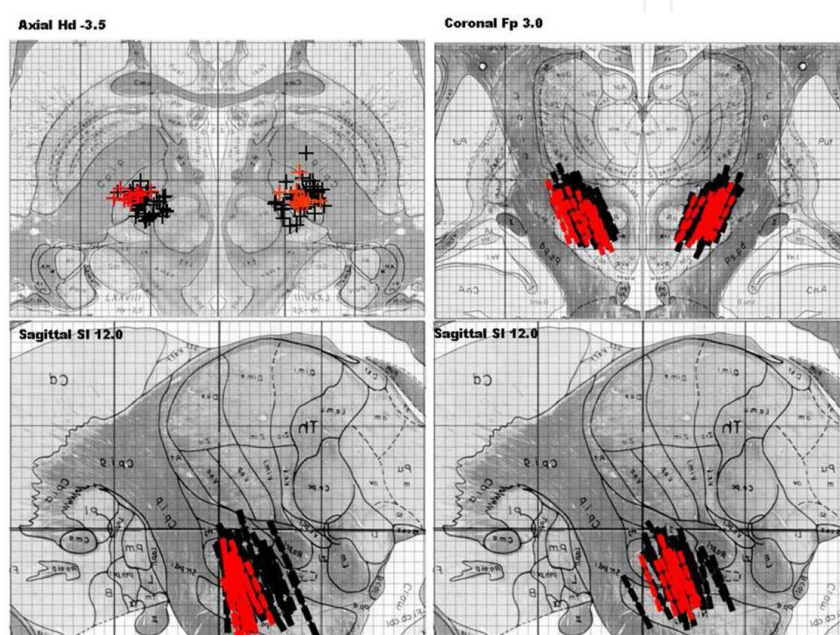


Fig. 7. Locations of the electrodes based on fused images obtained from 13 patients who showed significant clinical improvement in UPDRS part III including speech with nil LEDD (shown in red) and on fused images obtained from the remaining 44 patients (shown in black) at the last follow-up period more than one year after surgery. Most of the electrodes in the 13 patients who showed improvement are positioned in the middle one third of the subthalamic nucleus (in the axial view) at a level of 3.5 mm below the AC-PC line (upper left); they are also positioned in the subthalamic nucleus in the coronal view at a level of 3.0 mm posterior to the midcommissural point (upper right) and in the sagittal view at a level of 12 mm lateral to the midline (lower panels).

#### 4.3 Three-year long-term outcome following bilateral STN DBS with respect to electrode position

Although many studies have addressed the relationship between patients' clinical outcomes and prognostic factors, few studies have analyzed the long-term clinical outcome of STN DBS as a function of inserted electrode positioning (Tsai et al., 2009). Many studies have shown stable improvement in patients' UDPRS scores after bilateral STN DBS (Krack et al., 2003; Liang et al., 2006; Ostergaard & Sunde., 2006; Piboolnurak et al., 2007; Wider et al., 2008; Tsai et al., 2009), although the scores were observed to diminish over time due to disease progression (Olanow et al., 1995; Louis et al., 1999; Jankovic et al., 2001; Krack et al.,



2003; Rodriguez-Oroz et al., 2005; Tsai et al., 2009). In a review of the literature, Benabid et al. (2009) found that improvements in UDPRS III scores after STN DBS were reasonably stable over time, decreasing from 66% improvement at one year to 54% improvement five years after surgery (Benabid et al., 2009). It is suggested that the progression of symptoms over time after STN DBS closely resembles the natural history of PD on medically-treated PD but motor complications, which was thought to represent disease progression. Piboolnurak et al. (2007) investigated the long-term levodopa response after bilateral STN DBS and the predictive value of preoperative L-dopa response in 33 patients with PD (Piboolnurak et al., 2007). They found a trend of decreasing DBS response and observed that preoperative L-dopa responsiveness was not predictive of long-term DBS benefit. Wider et al. (2008) have described the long-term outcomes of 50 consecutive PD patients up to five years after bilateral STN DBS. They noted that a highly significant improvement in UPDRS part III sub-scores with stimulation was maintained at five years; however, this tended to diminish over time due to disease progression. They suggest that the observation of worsening symptoms in these cases argues against the neuroprotective effect hypothesis of STN DBS and actually reflects disease progression (Olanow et al., 1995; Louis et al., 1999; Jankovic et al., 2001; Krack et al., 2003). Unfortunately, there is little information available in the literature on how patients' long-term outcomes relate to electrode position measured in a stable period following bilateral STN stimulation.

We investigated the three-year outcomes of 42 PD patients following bilateral STN DBS and related the outcomes to electrode position as determined by means of fused preoperative MRI and postoperative CT images. Forty-two advanced PD patients were followed for three years after bilateral STN DBS using a prospective protocol. Patients were evaluated before surgery and one, two, and three years after surgery using the Unified Parkinson's Disease Rating Scale, Hoehn and Yahr staging, Schwab and England Activities of Daily Living, and the Short Form-36 Health Survey. The patients were divided into two groups according to electrode position; group I included patients who had both electrodes in the STN (n=31), whereas group II included patients who did not have both electrodes in the STN (n=11).

The UPDRS, Hoehn & Yahr staging, Schwab and England Activities of Daily Living, and the Short Form-36 Health Survey scores showed significant improvements with decreased L-dopa equivalent daily doses (LEDDs) in both groups, as well as in the patient cohort as a whole, up to three years following bilateral STN DBS (Fig 8). However, for patients in group II, the off-medication UPDRS total and motor (part III) scores significantly deteriorated with increased LEDDs three years after STN DBS in comparison to patients in group I (Fig. 8).

It is suggested that electrode positioning influences the long-term outcome of advanced PD patients following STN DBS. Accurate electrode positioning and documentation thereof should be considered in long-term assessment following STN DBS.

## **5. Programming/reprogramming guided by the use of fused images from preoperative MRI and postoperative CT following STN DBS**

### **5.1 DBS Electrodes Location Analysis System (DELAS)**

We developed an on-line service called "DBS Electrode Localization Analysis System (DELAS)", (<http://delas.ondemand3d.com>) that can be used to estimate the location of an individual patient's electrodes following STN DBS. Based on our previous experience, estimation of electrode positions at a stable period (around one month) following STN DBS can provide a useful basis for predicting the surgical outcome of each patient and for programming appropriate IPG parameters for each advanced PD patient treated with STN DBS.

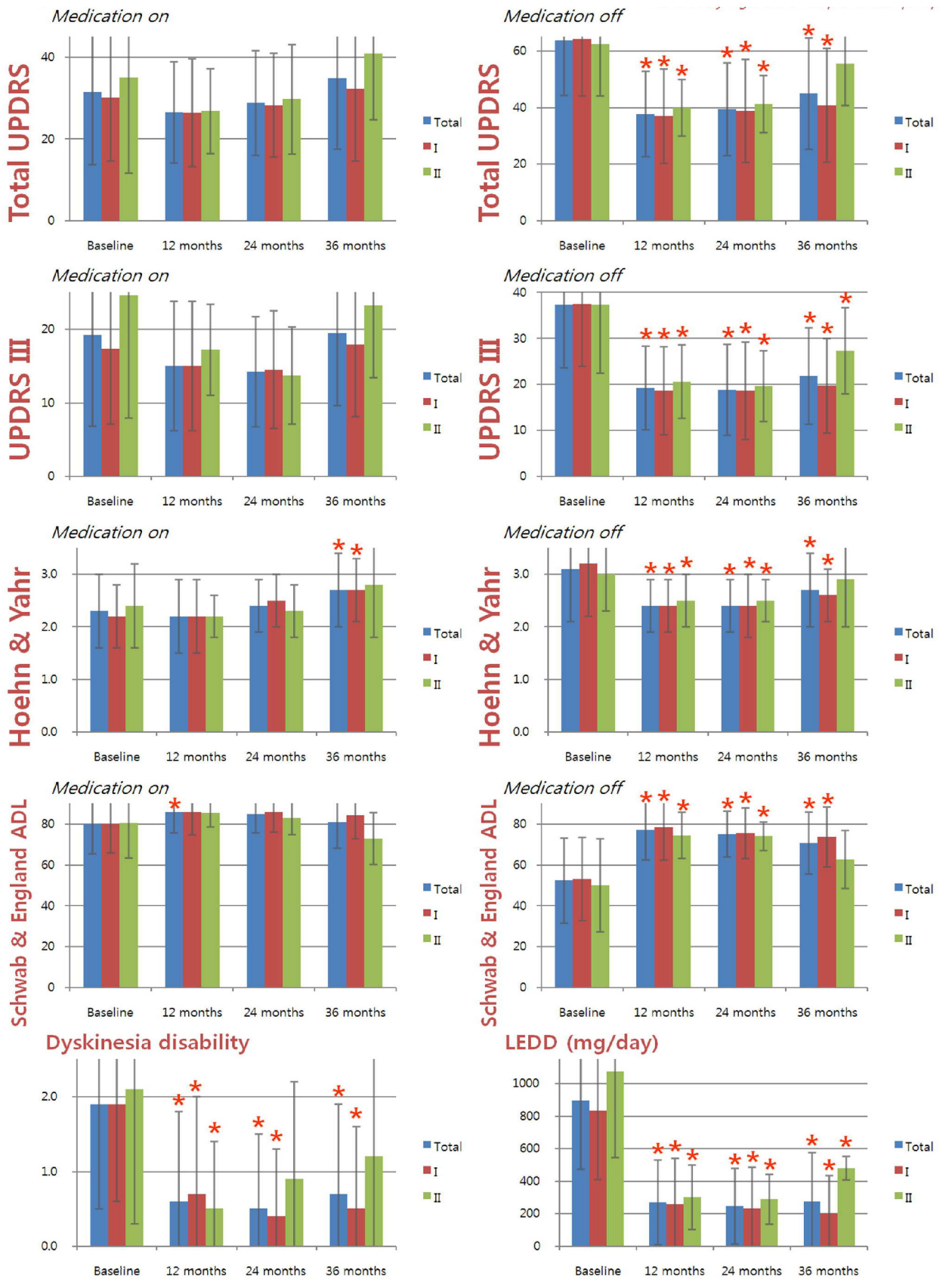


Fig. 8. On-time and off-time scores in 42 patients at 1, 2, and 3 years after subthalamic nucleus stimulation.

## 5.2 Programming/reprogramming guided by the use of fused images

An examination of the effectiveness and side effects of each of the four contacts of the electrodes used in DBS was performed using an N'vision® programmer (Medtronic, Minneapolis, WI) in all patients to select the best contact of the electrodes and electrical settings for chronic stimulation by the neurologist. After beginning stimulation at the minimal available level (around 1.0 volts), the medication and stimulation parameters were optimized to the demand for the best status of motor functions in harmony with the DBS programming via a 24-hour monitoring unit. Using this method and the electrode position identified by CT-MRI fused images, the stimulation parameters can be carefully adjusted with the selection of the best or the closest contacts of the stimulation electrodes.

### 5.2.1 Fusion-image-based programming

Subthalamic nucleus (STN) deep brain stimulation (DBS) is a standard therapy for patients with advanced Parkinson's disease (PD) and intolerance for long-term use of medication (Krack et al., 2003; Benabid et al., 2005; Lyons & Pahwa, 2005; Rodriguez-Oroz et al., 2005; Deuschl et al., 2006; Kleiner-Fisman et al., 2006; Tsai et al., 2009). DBS programming is a time-consuming task, however, that requires the patient to undergo a long period of adjustment after surgery (Moro et al., 2002; Deuschl et al., 2006a; Volkmann et al., 2006). Traditionally, DBS programming follows a standardized step-by-step approach (14, 19). The basic algorithm for DBS programming comprises (i) initial programming during the postoperative period; (ii) initiation of long-term stimulation; (iii) stimulation adjustment during the stabilization period (first 3–6 months after surgery) (Deuschl et al., 2006a; Volkmann et al., 2006). This approach tests each electrode individually to determine the most effective stimulation parameters. Generally, the starting point is set at a pulse width of 60  $\mu$ s and a frequency of 130 Hz. Subsequently, the amplitude thresholds for the induction of clinical responses and side effects are determined using monopolar stimulation for each electrode contact with stepwise increases in amplitude of 0.2–0.5 V. If clinical improvement is observed without side effects, the amplitude is increased further to determine the threshold of onset of adverse effects. If no beneficial or adverse effects are observed within the available amplitude range, the next contact is selected and tested. The electrode contact with the lowest threshold that induces a benefit and the largest therapeutic width (i.e., highest threshold for side effects) is selected for long-term stimulation.

We deemed that the determination of the best electrode contacts closest to the STN can be performed more easily and quickly via the use of fused preoperative magnetic resonance imaging (MRI) and postoperative computed tomography (CT) images. We proposed fusion-image-based programming to effectively adjust DBS parameters for patients with advanced Parkinson's disease (PD) after subthalamic nucleus (STN) deep brain stimulation (DBS) (Paek et al., 2011). Thirty-eight patients with advanced PD were consecutively treated with STN DBS between January 2007 and July 2008. The electrode positions and information regarding their contacts with the STN were determined via fusion of images obtained by preoperative magnetic resonance imaging (MRI) and postoperative computed tomography (CT) carried out 1 month after STN DBS (Fig. 9). Postoperative programming was performed using the information on electrode position acquired from the fused images.

All patients were evaluated using a prospective protocol of the Unified Parkinson's Disease Rating Scale, Hoehn and Yahr Staging, Schwab and England Activities of Daily Living, levodopa equivalent daily dose (LEDD), the Short Form-36 Health Survey, and neuropsychological tests prior to and at 3 and/or 6 months after surgery.



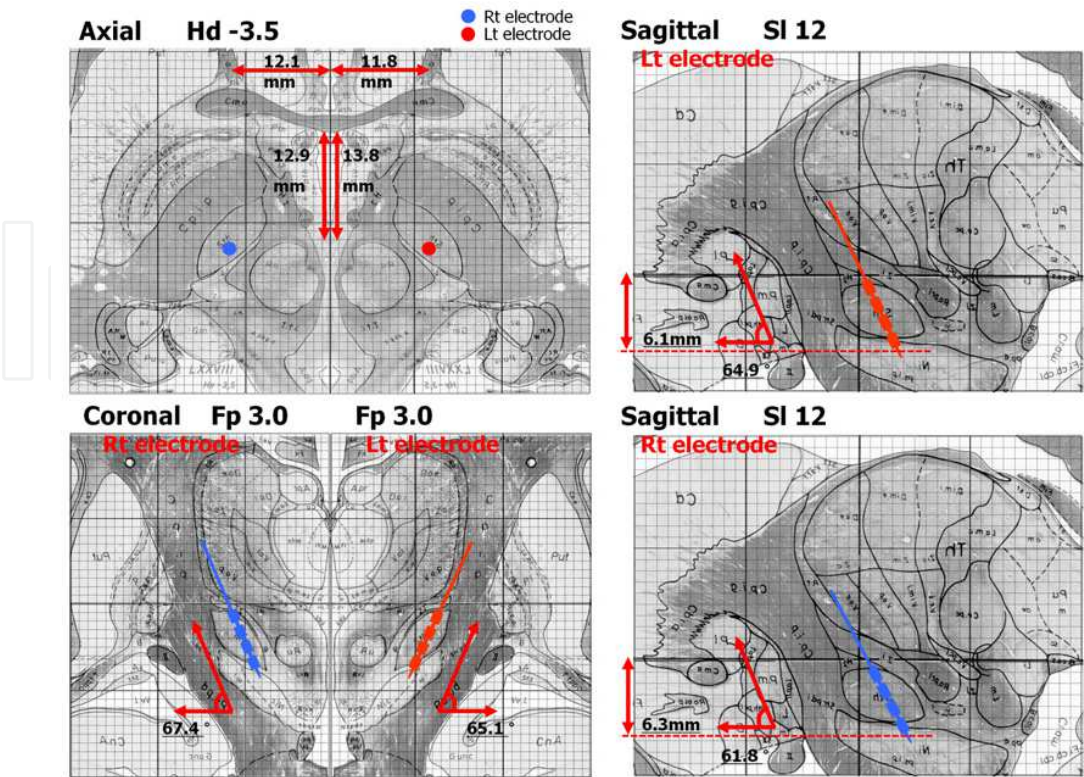


Fig. 9. Electrode positions plotted with reference to the human brain atlas of Schaltenbrandt and Wahren. The electrode positions are based on information obtained from fused images of preoperative MRI and postoperative CT taken one month after surgery.

After STN stimulation, there was rapid and significant improvement of motor symptoms, especially tremor and rigidity, with low morbidity. Stimulation led to an improvement in the off-medication UPRSR III scores of approximately 55% of the patients at 3 and 6 months after STN DBS. Dyskinesia was also significantly improved (74% at 3 months and 95% at 6 months) (Table 1).

In addition, LEDD values decreased to 50% of the level observed before surgery within 1 month after STN DBS surgery (Fig. 10).

When information from the fused images of preoperative MRI and postoperative CT was used to ascertain electrode position, the time spent selecting the stimulation contacts and appropriate stimulation parameters was markedly shortened, and patients were able to avoid prolonged experience of the unnecessary adverse effects caused by the selection of inappropriate contacts far from the STN target. With this approach, the selection of stimulation contacts with appropriate stimulation parameters can be achieved soon after surgery, in harmony with reduced dosages of antiparkinsonian drugs. When the fused images were used, the time and effort expended by physicians in the selection of the stimulation contacts and appropriate stimulation parameters were also markedly reduced, and the long-term trial-and-error rounds caused by the step-by-step selection of the contacts, which frequently occurred even with experienced specialists (Moro et al., 2002; Deuschl et al., 2006a; Volkmann et al., 2006), could be avoided. Thus, it is suggested that programming based on fused images of preoperative MRI and postoperative CT scans after STN DBS can often be carried out quickly, easily, and efficiently.

	Medication	DBS	Baseline	3 months	6 months	P-value	
						3 months vs. baseline	6 months vs. baseline
Total UPDRS	On	Off	30.8 ± 14.4				
	Off		65.7 ± 18.1				
UPDRS III	On	On		24.5 ± 12.8	25.3 ± 10.4	p=0.015	p=0.038
	Off			33.7 ± 16.4	33.4 ± 14.2	p<0.001*	p<0.001*
	On	Off	20.3 ± 11.7		33.4 ± 14.8		p<0.001*
	Off		40.9 ± 13.4		38.0 ± 13.6		P=0.203
H & Y	On	On		14.4 ± 8.3	14.5 ± 6.1	p=0.004*	p=0.005*
	Off			18.6 ± 8.4	18.1 ± 8.0	p<0.001*	p<0.001*
	On	Off	2.4 ± 0.5				
	Off		3.1 ± 0.9				
SEADL	On	On		2.4 ± 0.5	2.5 ± 0.5	p=0.729	p=0.337
	Off			2.6 ± 0.4	2.6 ± 0.5	p=0.001*	p<0.001*
	On	Off	83.3 ± 10.1				
	Off		64.2 ± 13.6				
Dyskinesia disability	On	On		86.1 ± 9.9	86.6 ± 9.7	p=0.185	p=0.085
	Off			80.6 ± 13.7	80.5 ± 14.3	p<0.001*	p<0.001*
	On	Off					
	Off						
LEDD (mg/day)			793.4 ± 527.0	285.3 ± 387.2	246.5 ± 322.1	p<0.001*	p<0.001*

Table 1. Clinical outcome in 38 patients after subthalamic nucleus stimulation. \* Asterisks indicate p<0.01 and statistical significance with use of the Bonferroni correction method to avoid a Type I error when conducting multiple analyses over time.

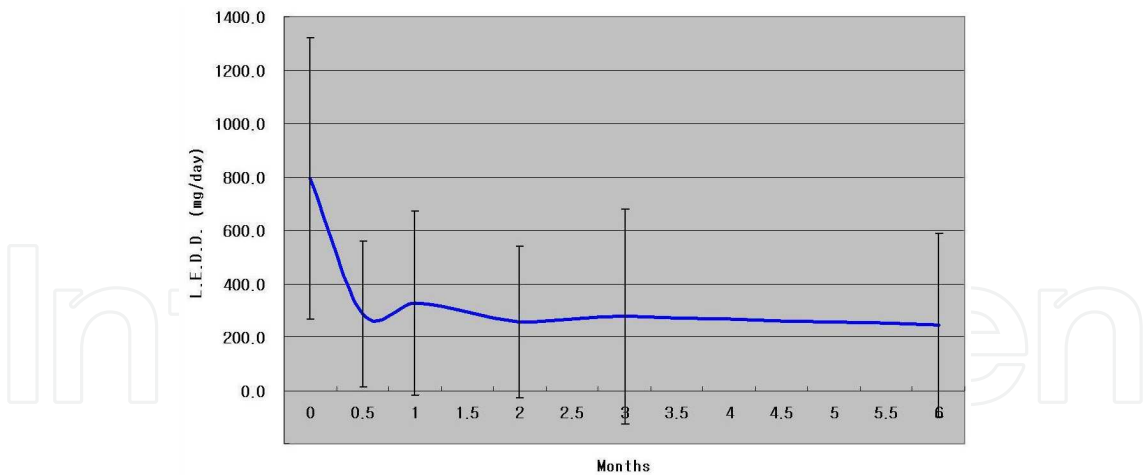


Fig. 10. Levodopa equivalent daily dose (LEDD) changes in 38 patients after subthalamic nucleus stimulation.

5.2.2 Fusion-image-based reprogramming

Published guidelines for DBS programming in PD recommend that the contact for chronic stimulation be selected after testing the efficacy of each electrode separately to evaluate its effective threshold and therapeutic width (Volkman et al., 2002; Volkman et al., 2006). Although the established guidelines provide a systematic approach, several practical

difficulties are encountered in DBS programming. First, the responses from stimulating each contact serially at several-minute intervals can be confounded by the effects of the previously stimulated electrode. Second, it is time-consuming to stimulate each electrode separately and to evaluate the threshold of each parameter. Third, adequate patient cooperation, which can be easily affected by the patients' subjective feelings and motivation, is essential to determining the thresholds. The placebo effect is yet another difficulty. Therefore, the outcome of DBS programming is highly dependent on the physician's capability and the capacity of the DBS care facility (Moro et al., 2002; Moro et al., 2006).

We have developed a fusion method that combines images of pre-operative magnetic resonance imaging (MRI) and postoperative computed tomography (CT) (Kim et al., 2008a; Kim et al., 2008b; Lee et al., 2008; Kim et al., 2009; Kim et al., 2010; Paek et al., 2010). This fusion method enabled us to determine the 3-dimensional (3D) location of the leads and each contact in relation to the STN.

Assuming that use of this visual information would improve the outcomes of DBS programming, we reprogrammed the stimulator based on the fused images of MRI and CT in patients who had been stably managed on the STN-DBS for at least 6 months. To evaluate the usefulness of the visual information about the location of the contacts in deep brain stimulation (DBS) programming, we compared the outcomes of subthalamic nucleus (STN) stimulation before and after reprogramming guided by the fused images of MRI and CT (Lee et al., 2010a).

Of 65 patients with Parkinson's disease who underwent bilateral STN-DBS surgery between March 2005 and September 2006 and had been managed for at least 6 months with conventional programming based only on physiological responses from the patients, 54 patients were reprogrammed based on the 3D anatomical location of the contacts revealed by the fused images of preoperative MRI and post-operative CT scans taken 6 months after surgery. A total of 51 patients completed the evaluation after reprogramming.

Reprogramming significantly improved the patients' UPDRS part III scores during both on- and off-medication conditions. The daily levodopa-equivalent dose was significantly reduced. Improvement in the UPDRS part III scores after reprogramming was greater in the patients with electrodes in the STN than in patients with electrodes located outside the STN (Table 2).

Characteristics	Pre-reprogramming	Post-reprogramming	p-Value
Primary outcomes			
UPDRS – III (0–108)			
Off-medication	22.5 ± 10.5	19.1 ± 11.5	0.0137 <sup>†</sup>
On-medication	17.0 ± 9.2	14.0 ± 7.9	0.0006 <sup>†</sup>
Secondary outcomes			
UPDRS – I (0–16)			
Off-medication	4.5 ± 3.4	4.2 ± 2.5	0.5535
On-medication	2.8 ± 2.6	3.1 ± 2.3	0.2415
UPDRS – II (0–52)			
Off-medication	17.8 ± 7.9	16.3 ± 7.3	0.1455
On-medication	10.0 ± 6.4	12.3 ± 6.9	0.0130 <sup>†</sup>
UPDRS – III subscores for axial symptoms (0–20)			
Off-medication	4.9 ± 2.2	5.0 ± 2.7	0.8645
On-medication	3.9 ± 2.0	4.0 ± 2.4	0.8812
Dyskinesia disability (0–4)	0.9 ± 1.3	0.6 ± 1.0	0.0598
Dyskinesia duration (0–4)	0.4 ± 0.6	0.3 ± 0.6	0.3991
Off-duration (0–4)	1.4 ± 1.1	1.1 ± 1.0	0.0549
Hoehn and Yahr stage (0–5)			
Off-medication	2.6 ± 0.5	2.6 ± 0.7	0.6465
On-medication	2.4 ± 0.6	2.5 ± 0.7	0.2620
LEDD (mg/day)	355.6 ± 321.3	276.7 ± 283.0	0.0155 <sup>†</sup>

Table 2. Outcomes before and after reprogramming in 51 patients.

It is suggested that CT-MR fusion images helped physicians reprogram stimulation parameters with ease and confidence in a time-saving manner and resulted in further clinical improvement. This method could complement the conventional method of adjusting stimulation parameters after bilateral STN-DBS.

## 6. Conclusion

In STN DBS, precise positioning of electrodes within the STN is important for good clinical outcome after surgery. Many approaches, including image fusion of CT-MRI, MRI-MRI, use of an MRI brain atlas, intraoperative microelectrode recording, and stimulation, have been used in efforts to achieve precise targeting of electrodes. However, many unexpected factors such as possible brain shift due to CSF leakage, electrode artifacts in the MRI, and error in the manipulation of instruments, make it difficult to have electrodes precisely positioned in the center of the STN. Thus, not all patients have electrodes positioned exactly in the STN after surgery. This might result in different clinical outcomes following STN DBS in advanced PD patients. Knowledge of the exact location of DBS electrodes may be important in the prediction of clinical outcomes as well as in the programming of stimulation parameters following STN DBS.

We developed the DBS Electrode Localization Analysis System (DELAS) to estimate the location of electrodes following STN DBS. We demonstrated that electrode location can influence long-term clinical outcome in advanced PD patients following STN DBS. Hence, electrode positioning in relation with the STN and documentation thereof should be emphasized when adjusting long-term management plans and assessing the long-term effects of DBS on disease progression in advanced PD patients following STN DBS. We believe that the DELAS system makes it possible to try a new approach of programming or reprogramming after STN DBS that consists of fusing images of preoperative MRI and postoperative CT using the mutual information technique. This technique allows the identification of the 3-D location of the leads and of each contact in relation to the STN. Using information on the 3-D location of the electrodes and their contacts based on fused images of preoperative MRI and postoperative CT scans acquired 1 month after surgery, programming can be quickly, easily, and efficiently performed after STN DBS.

## 7. Acknowledgements

This work was supported by a grant from the Korea Healthcare Technology R&D Project, Ministry for Health, Welfare and Family Affairs, Republic of Korea (A092052-0911-000100).

## 8. References

- Bejjani BP, Dormont D, Pidoux B, Yelnik J, Damier P, Arnulf I, Bonnet AM, Marsault C, Agid Y, Philippon J, Cornu P.(2000) Bilateral subthalamic stimulation for Parkinson's disease by using three-dimensional stereotactic magnetic resonance imaging and electrophysiological guidance. *J Neurosurg* 92(4):615-625. ISSN: 0022-3085
- Benabid AL, Pollak P, Louveau A, Henry S, de Rougemont J. (1987) Combined (thalamotomy and stimulation) stereotactic surgery of the VIM thalamic nucleus for bilateral Parkinson disease. *Appl Neurophysiol* 50(1-6):344-346 ISSN: 0302-2773



- Benabid AL, Chaudes S, Mitrofanis J, Pollak P. (2009) Deep brain stimulation of the subthalamic nucleus for the treatment of Parkinson's disease. *Lancet Neurol* 8 :67-81. ISSN: 1474-4422
- Benabid AL, Chabardès S, Seigneuret E. (2005) Deep-brain stimulation in Parkinson's disease: Long-term efficacy and safety—What happened this year? *Curr Opin Neurol* 18:623–630. ISSN: 1350-7540
- Benazzouz A, Breit S, Koudsie A, Pollak P, Krack P, Benabid AL. (2002) Intraoperative microrecordings of the subthalamic nucleus in parkinson's disease. *Mov Disord* 17:S145-149. ISSN: 0885-3185
- Cho ZH, Min HK, Oh SH, Han JY, Park CW, Chi JG, Kim YB, Paek SH, Lozano AM, Lee KH. (2010) Direct visualization of deep brain stimulation targets in Parkinson disease with the use of 7-tesla magnetic resonance imaging. *J Neurosurg* 113(3):639-647. ISSN: 0022-3085
- Christensen GE, Joshi SC, Miller MI. (1997) Volumetric transformation of brain anatomy. *IEEE Trans Med Imaging* 16:864–877. ISSN: 0278-0062
- Deuschl G, Herzog J, Kleiner-Fisman G, Kubu C, Lozano AM, Lyons KE, Rodriguez-Oroz MC, Tamma F, Troster AI, Vitek JL, Volkmann J, Voon V. (2006a) Deep brain stimulation: postoperative issues. *Mov Disord* 21(Suppl 14):S219-S237. ISSN: 0885-3185
- Deuschl G, Schade-Brittinger C, Krack P, Volkmann J, Schäfer H, Bötzel K, Daniels C, Deutschländer A, Dillmann U, Eisner W, Gruber D, Hamel W, Herzog J, Hilker R, Klebe S, Kloss M, Koy J, Krause M, Kupsch A, Lorenz D, Lorenzl S, Mehdorn HM, Moringlane JR, Oertel W, Pinsker MO, Reichmann H, Reuss A, Schneider GH, Schnitzler A, Steude U, Sturm V, Timmermann L, Tronnier V, Trottenberg T, Wojtecki L, Wolf E, Poewe W, Voges J; German Parkinson Study Group, Neurostimulation Section. (2006b) A randomized trial of deep-brain stimulation for Parkinson's disease. *N Engl J Med* 355:896–908. ISSN: 0028-4793
- Ford B, Winfield L, Pullman SL, Frucht SJ, Du Y, Greene P, Cheringal JH, Yu O, Cote LJ, Fahn S, McKhann GM 2nd, Goodman RR. (2004) Subthalamic nucleus stimulation in advanced Parkinson's disease: Blinded assessments at oneyear follow-up. *J Neurol Neurosurg Psychiatry* 75:1255–1259. ISSN: 0022-3050
- Godinho F, Thobois S, Magnin M, Guenot M, Polo G, Benatru I, Xie J, Salvetti A, Garcia-Larrea L, Broussolle E, Mertens P. (2006) Subthalamic nucleus stimulation in Parkinson's disease: anatomical and electrophysiological localization of active contacts. *J Neurol* 253:1347-1355. ISSN: 0885-3185
- Halpern CH, Danish SF, Baltuch GH, Jaggi JL. (2008) Brain shift during deep brain stimulation surgery for Parkinson's disease. *Stereotact Funct Neurosurg* 86:37-43. ISSN: 1011-6125
- Hamid NA, Mitchell RD, Mocoft P, Westby GW, Milner J, Pall H. (2005) Targeting the subthalamic nucleus for deep brain stimulation: technical approach and fusion of pre-and postoperative MR images to define accuracy of lead placement. *J Neurol Neurosurg Psychiatry* 76:409-414. ISSN: 0022-3050
- Heo JH, Lee KM, Paek SH, Kim MJ, Lee JY, Kim JY, Cho SY, Lim YH, Kim MR, Jeong SY, Jeon BS. (2008) The effects of bilateral Subthalamic Nucleus Deep Brain Stimulation (STN DBS) on cognition in Parkinson disease. *J Neurol Sci.* 273(1-2):19-24. ISSN: 0022-510X

- Holtzheimer PE 3rd, Roberts DW, Darcey TM (1999) Magnetic resonance imaging versus computed tomography for target localization in functional stereotactic neurosurgery. *Neurosurgery* 45:290-297. ISSN: 0148-396X
- Jankovic J & Kapadia AS. (2001) Functional decline in Parkinson disease. *Arch Neurol* 2001;58:1611-1615. ISSN: 0003-9942
- Khan MF, Mewes K, Gross RE, Skrinjar O. (2008) Assessment of brain shift related to deep brain stimulation surgery. *Stereotact Funct Neurosurg* 86:44-53. ISSN: 1011-6125
- Kim HJ, Lee JY, Kim JY, Kim DG, Paek SH, Jeon BS.(2008a) Effect of bilateral subthalamic deep brain stimulation on diphasic dyskinesia. *Clin Neurol Neurosurg* 110(4):328-332. ISSN: 0303-8467
- Kim HJ, Paek SH, Kim JY, Lee JY, Lim YH, Kim MR, Kim DG, Jeon BS. (2008b) Chronic subthalamic deep brain stimulation improves pain in Parkinson disease. *J Neurol*. 255(12):1889-1894. ISSN: 0885-3185
- Kim HJ, Paek SH, Kim JY, Lee JY, Lim YH, Kim DG, Jeon BS. (2009) Two-year follow-up on the effect of unilateral subthalamic deep brain stimulation in highly asymmetric Parkinson's disease. *Mov Disord* 15;24(3):329-335. ISSN: 0885-3185
- Kim HJ, Jeon BS, Paek SH, Lee JY, Kim HJ, Kim CK, Kim DG. (2010) Bilateral subthalamic deep brain stimulation in Parkinson disease patients with severe tremor. *Neurosurgery* 67(3):626-632 ISSN: 0148-396X
- Kim YH, Kim HJ, Kim C, Kim DG, Jeon BS, Paek SH. (2010) Comparison of electrode location between immediate postoperative day and 6 months after bilateral subthalamic nucleus deep brain stimulation. *Acta Neurochir (Wien)* 152(12):2037-2045. ISSN: 0001-6268
- Kleiner-Fisman G, Herzog J, Fisman DN, Tamma F, Lyons KE, Pahwa R, Lang AE, Deuschl G. (2006) Subthalamic nucleus deep brain stimulation: summary and meta-analysis of outcomes. *Mov Disord* 21(Suppl.14): S290-S304. ISSN: 0885-3185
- Kondziolka D, Dempsey PK, Lunsford LD, Kestle JR, Dolan EJ, Kanal E, Tasker RR (1992) A comparison between magnetic resonance imaging and computed tomography for stereotactic coordinate determination. *Neurosurgery* 30:402-406. ISSN: 0148-396X
- Krack P, Batir A, Van Blercom N, Chabardes S, Fraix V, Ardouin C, Koudsie A, Limousin PD, Benazzouz A, Le Bas JF, Benabid AL, Pollak P. (2003) Five-year follow-up of bilateral stimulation of the subthalamic nucleus in advanced Parkinson's disease. *N Engl J Med* 349:1925-1934. ISSN: 0028-4793
- Lee JY, Han JH, Kim HJ, Jeon BS, Kim DG, Paek SH. (2008) STN DBS of Advanced Parkinson's Disease Experienced in a Specialized Monitoring Unit with a Prospective Protocol J Korean Neurosurg Soc. 44(1):26-35. ISSN: 2005-3711
- Lee JY, Jeon BS, Paek SH, Lim YH, Kim MR, Kim C. (2010a) Reprogramming guided by the fused images of MRI and CT in subthalamic nucleus stimulation in Parkinson disease. *Clin Neurol Neurosurg* 112(1):47-53. ISSN: 0303-8467
- Lee JY, Kim JW, Lee JY, Lim YH, Kim C, Kim DG, Jeon BS, Paek SH. (2010b) Is MRI a reliable tool to locate the electrode after deep brain stimulation surgery? Comparison study of CT and MRI for the localization of electrodes after DBS. *Acta Neurochir (Wien)* 152(12):2029-2036. ISSN: 0001-6268
- Liang GS, Chou KL, Baltuch GH, Jaggi JL, Loveland-Jones C, Leng L, Maccarone H, Hurtig HI, Colcher A, Stern MB, Kleiner-Fisman G, Simuni T, Siderowf AD. (2006) Long-term outcomes of bilateral subthalamic nucleus stimulation in patients with




- advanced Parkinson's disease. *Stereotact Funct Neurosurg* 84 :221-227. ISSN: 1011-6125
- Limousin P, Krack P, Pollak P, Benazzouz A, Ardouin C, Hoffmann D, Benabid AL. (1998) Electrical stimulation of the subthalamic nucleus in advanced Parkinson's disease. *N Engl J Med* 339:1105-1111. ISSN: 0028-4793
- Louis ED, Tang MX, Cote L, Alfaro B, Mejia H, Marder K. (1999) Progression of parkinsonian signs in Parkinson disease. *Arch Neurol* 56:334-337. ISSN: 0003-9942
- Lyons KE, Pahwa R. (2005) Long-term benefits in quality of life provided by bilateral subthalamic stimulation in patients with Parkinson disease. *J Neurosurg* 103:252-255. ISSN: 0022-3085
- Maes F, Collignon A, Vandermeulen D, Marchal G, Suetens P. (1997) Multimodality image registration by maximization of mutual information. *IEEE Trans Med Imaging* 16:187-198. ISSN: 0278-0062
- Martinez-Santesteban FM, Swanson SD, Noll DC, Anderson DJ. (2007) Magnetic field perturbation of neural recording and stimulating microelectrodes. *Phys Med Biol* 52:2073-2088. ISSN: 0031-9155
- McClelland S 3rd, Ford B, Senatus PB, Winfield LM, Du YE, Pullman SL, Yu Q, Frucht SJ, McKhann GM 2nd, Goodman RR. (2005) Subthalamic stimulation for Parkinson disease: Determination of electrode location necessary for clinical efficacy. *Neurosurg Focus* 19:E12. ISSN: 1092-0684
- Miyagi Y, Shima F, Sasaki T. (2007) Brain shift: an error factor during implantation of deep brain stimulation electrodes. *J Neurosurg* 107:989-997. ISSN: 0022-3085
- Moro E, Esselink RJ, Xie J, Hommel M, Benabid AL, Pollak P. (2002) The impact on Parkinson's disease of electrical parameter settings in STN stimulation. *Neurology* 59:706-713. ISSN: 0028-3878
- Moro E, Poon YW, Lozano AM, Saint-Cyr JA, Lang AE. (2006) Subthalamic nucleus stimulation; improvements in outcome with reprogramming. *Arch Neurol* 63:1266-1272. ISSN: 0003-9942
- Olanow CW, Hauser RA, Gauger L, Malapira T, Koller W, Hubble J, Bushenbark K, Lilienfeld D, Esterlitz J. (1995) The effect of deprenyl and levodopa on the progression of Parkinson's disease. *Ann Neurol* 38:771-777. ISSN: 0364-5134
- Ott K, Tarlov E, Crowell R, Papadakis N (1976) Retained intracranial metallic foreign bodies. Report of two cases. *J Neurosurg* 44:80-83. ISSN: 0022-3085
- Ostergaard K, Sunde NA. (2006) Evolution of Parkinson's disease during 4 years of bilateral deep brain stimulation of the subthalamic nucleus. *Mov Disord* 21 :624-631. ISSN: 0885-3185
- Paek SH, Han JH, Lee JY, Kim C, Jeon BS, Kim DG. (2008) Electrode position determined by fused images of preoperative and postoperative magnetic resonance imaging and surgical outcome after subthalamic nucleus deep brain stimulation. *Neurosurgery* 2008; 63:925-937. ISSN: 0148-396X
- Paek SH, Kim JW, Lim YH, Kim MR, Kim DG, Jeon BS. (2010) Data Management System in a Movement Disorder Center: Technical Report. *Stereotact Funct Neurosurg* 88(4):216-223. ISSN: 1011-6125
- Paek SH, Kim HJ, Yoon JY, Heo JH, Kim CY, Kim MR, Lim YH, Kim KR, Han JH, Kim DG, Jeon BS. (2011) Fusion image-based programming after subthalamic nucleus deep brain stimulation. *World Neurosurgery* [Epub ahead of print]. ISSN:1878-8750

- Piboolnurak P, Lang AE, Lozano AM, Miyasaki JM, Saint-Cyr JA, Poon YY, Hutchison WD, Dostrovsky JO, Moro E (2007) Levodopa response in long-term bilateral subthalamic stimulation for Parkinson's disease. *Mov Disord* 22 : 990-997. ISSN: 0885-3185
- Plaha P, Ben-Shlomo Y, Patel NK, Gill SS. (2006) Stimulation of the caudal zona incerta is superior to stimulation of the subthalamic nucleus in improving contralateral parkinsonism. *Brain* 129:1732-1747. ISSN: 0006-8950
- Pluim JP, Maintz JB, Viergever MA. (2003) Mutual-information-based registration of medical images: a survey. *IEEE Trans Med Imaging* 22:986-1004. ISSN: 0278-0062
- Pollo C, Vingerhoets F, Pralong E, Ghika J, Maeder P, Meuli R, Thiran JP, Villemure JG. (2007) Localization of electrodes in the subthalamic nucleus on magnetic resonance imaging. *J Neurosurg* 106:36-44. ISSN: 0022-3085
- Rodriguez-Oroz MC, Obeso JA, Lang AE, Houeto JL, Pollak P, Rehncrona S, Kulisevsky J, Albanese A, Volkmann J, Hariz MI, Quinn NP, Speelman JD, Guridi J, Zamarbide I, Gironell A, Molet J, Pascual-Sedano B, Pidoux B, Bonnet AM, Agid Y, Xie J, Benabid AL, Lozano AM, Saint-Cyr J, Romito L, Contarino MF, Scerrati M, Fraix V, Van Blercom N. (2005) Bilateral deep brain stimulation in Parkinson's disease: a multicenter study with 4 years follow-up. *Brain* 128:2240-2249. ISSN: 0006-8950
- Saint-Cyr JA, Hoque T, Pereira LC, Dostrovsky JO, Hutchison WD, Mikulis DJ, Abosch A, Sime E, Lang AE, Lozano AM. (2002) Localization of clinically effective stimulating electrodes in the human subthalamic nucleus on magnetic resonance imaging. *J Neurosurg* 97:1152-1166. ISSN: 0022-3085
- Schaltenbrand G & Wharen W. (1998) Atlas of Stereotaxy of the Human Brain, 2nd ed. New York: Thieme. ISBN (Americas): 9780865770553, ISBN (EUR, Asia, Africa, AUS): 9783133937023
- Schrader B, Hamel W, Weinert D, Mehdorn HM. (2002) Documentation of electrode localization. *Mov Disord* 17 [Suppl 3]:S167-S174. ISSN: 0885-3185
- Sorensen N & Krauss J (1991) Movement of hemostatic clips from the ventricles through the aqueduct to the lumbar spinal canal. Case report *J Neurosurg* 74:143-146. ISSN: 0022-3085
- Starr PA, Christine CW, Theodosopoulos PV, Lindsey N, Byrd D, Mosley A, Marks WJ Jr. (2002) Implantation of deep brain stimulators into the subthalamic nucleus: Technical approach and magnetic resonance imaging-verified lead locations. *J Neurosurg* 97:370-387. ISSN: 0022-3085
- Tsai ST, Lin SH, Chou YC, Pan YH, Hung HY, Li CW, Lin SZ, Chen SY. (2009) Prognostic factors of subthalamic stimulation in Parkinson's disease: a comparative study between short- and long-term effects. *Stereotact Funct Neurosurg* 87:241-248. ISSN: 1011-6125
- van den Munckhof P, Contarino MF, Bour LJ, Speelman JD, de Bie RM, Schuurman PR (2010) Postoperative curving and upward displacement of deep brain stimulation electrodes caused by brain shift. *Neurosurgery* 67:49-53. ISSN: 0148-396X
- Volkmann J, Herzog J, Kopper F, Deuschl G. (2002) Introduction to the programming of deep brain stimulators. *Mov Disord* 17:S181-S187. ISSN: 0885-3185
- Volkmann J, Moro E, Pahwa R. (2006) Basic algorithms for the programming of deep brain stimulation in Parkinson's disease. *Mov Disord* 21:S284-S289. ISSN: 0885-3185

- Wells WM 3rd, Viola P, Atsumi H, Nakajima S, Kikinis R. (1996) Multimodal volume registration by maximization of mutual information. *Med Image Anal* 1:35–51. ISSN: 1361-8415
- Wider C, Pollo C, Bloch J, Vingerhoets FJ. (2008) Long-term outcome of 50 consecutive Parkinson's disease patients treated with subthalamic deep brain stimulation. *Parkinsonism and Relat Disord* 14 :114-119. ISSN: 1353-8020
- Yelnik J, Damier P, Demeret S, Gervais D, Bardinet E, Bejjani BP, Francois C, Houeto JL, Arnule I, Dormont D, Galanaud D, Pidoux B, Cornu P, Aqid Y. (2003) Localization of stimulating electrodes in patients with Parkinson disease by using a three-dimensional atlas-magnetic resonance imaging coregistration method. *J Neurosurg* 99:89–99. ISSN: 0022-3085
- Yokoyama T, Ando N, Sugiyama K, Akamine S, Namba H. (2006) Relationship of stimulation site location within the subthalamic nucleus region to clinical effects on parkinsonian symptoms. *Stereotact Funct Neurosurg* 84:170–175. ISSN: 1011-6125

IntechOpen



## **Diagnostics and Rehabilitation of Parkinson's Disease**

Edited by Dr. Juliana Dushanova

ISBN 978-953-307-791-8

Hard cover, 528 pages

**Publisher** InTech

**Published online** 07, December, 2011

**Published in print edition** December, 2011

Diagnostics and Rehabilitation of Parkinson's Disease presents the most current information pertaining to news-making topics relating to this disease, including etiology, early biomarkers for the diagnostics, novel methods to evaluate symptoms, research, multidisciplinary rehabilitation, new applications of brain imaging and invasive methods to the study of Parkinson's disease. Researchers have only recently begun to focus on the non-motor symptoms of Parkinson's disease, which are poorly recognized and inadequately treated by clinicians. The non-motor symptoms of Parkinson's disease have a significant impact on patient quality of life and mortality and include cognitive impairments, autonomic, gastrointestinal, and sensory symptoms. In-depth discussion of the use of imaging tools to study disease mechanisms is also provided, with emphasis on the abnormal network organization in parkinsonism. Deep brain stimulation management is a paradigm-shifting therapy for Parkinson's disease, essential tremor, and dystonia. In the recent years, new approaches of early diagnostics, training programmes and treatments have vastly improved the lives of people with Parkinson's disease, substantially reducing symptoms and significantly delaying disability. Written by leading scientists on movement and neurological disorders, this comprehensive book should appeal to a multidisciplinary audience and help people cope with medical, emotional, and practical challenges.

### **How to reference**

In order to correctly reference this scholarly work, feel free to copy and paste the following:

Sun Ha Paek (2011). Estimation of Electrode Position with Fused Images of Preoperative MRI and Postoperative CT Using the Mutual Information Technique After STN DBS in Patients with Advanced Parkinson's Disease, *Diagnostics and Rehabilitation of Parkinson's Disease*, Dr. Juliana Dushanova (Ed.), ISBN: 978-953-307-791-8, InTech, Available from: <http://www.intechopen.com/books/diagnostics-and-rehabilitation-of-parkinson-s-disease/estimation-of-electrode-position-with-fused-images-of-preoperative-mri-and-postoperative-ct-using-th>

**INTECH**  
open science | open minds

### **InTech Europe**

University Campus STeP Ri  
Slavka Krautzeka 83/A  
51000 Rijeka, Croatia  
Phone: +385 (51) 770 447

### **InTech China**

Unit 405, Office Block, Hotel Equatorial Shanghai  
No.65, Yan An Road (West), Shanghai, 200040, China  
中国上海市延安西路65号上海国际贵都大饭店办公楼405单元  
Phone: +86-21-62489820

[www.intechopen.com](http://www.intechopen.com)

Fax: +385 (51) 686 166  
www.intechopen.com

Fax: +86-21-62489821

IntechOpen

IntechOpen

© 2011 The Author(s). Licensee IntechOpen. This is an open access article distributed under the terms of the [Creative Commons Attribution 3.0 License](https://creativecommons.org/licenses/by/3.0/), which permits unrestricted use, distribution, and reproduction in any medium, provided the original work is properly cited.

IntechOpen

IntechOpen