

We are IntechOpen, the world's leading publisher of Open Access books Built by scientists, for scientists

6,900

Open access books available

185,000

International authors and editors

200M

Downloads

Our authors are among the

154

Countries delivered to

TOP 1%

most cited scientists

12.2%

Contributors from top 500 universities



WEB OF SCIENCE™

Selection of our books indexed in the Book Citation Index
in Web of Science™ Core Collection (BKCI)

Interested in publishing with us?
Contact book.department@intechopen.com

Numbers displayed above are based on latest data collected.
For more information visit www.intechopen.com



Clinical Application of Three-Dimensional Reverse Engineering Technology in Orthodontic Diagnosis

Bong-Kuen Cha

Gangneung-Wonju National University
Korea

1. Introduction

A three-dimensional (3D) surface scanning system was recently introduced in dental fields and has been used most extensively for example, for assessing morphological changes in maxillofacial surgery or in orthopedic treatment with a functional appliance. Another use for the 3D data acquisition in orthodontics is bending art system (BAS) or Invisalign® system introduced as a new treatment modality. However, research on the various clinical applications of 3D digital model is still in its early stage, as it has been used as a simple model analysis, a digitized data storage (Alcan *et al.*, 2009; Ayoub *et al.*, 2003; Birnbaum & Aaronson, 2008; Cha *et al.*, 2007; Choi *et al.*, 2010; Costalos *et al.*, 2005; Dalstra & Melsen, 2009; Gracco *et al.*, 2007; Keating *et al.*, 2008; Krejci *et al.*, 1994; Leifert *et al.*, 2009; Macchi *et al.*, 2006; Santoro *et al.*, 2003; Stevens *et al.*, 2006; Van der Linden, 1987).

This chapter is intended to investigate the possibility of the clinical application of 3D reverse engineering technology used in the analysis of orthodontic models and facial morphology.

The theme of this chapter is divided into seven parts:

1. The measuring accuracy and process of the 3D model scanning technique was evaluated in terms of linear, surface and volumetric parameters. The diverse clinical applications of model analysis, including measuring basal arch width, or sectional areas concerned will be presented.
2. Giving the evidences that the superimposition of the 3D digital maxillary model is clinically as reliable as cephalometric superimposition for assessing orthodontic tooth movements.
3. Presenting the clinical cases, using the superimposition technique for the 3D measuring of orthodontic tooth movement in maxilla.
4. Describing the clinical procedure for digital diagnostic setup.
5. Introducing a novel method concerning the volumetric assessment of tooth wear using 3D reverse engineering technology.
6. Presenting a quantitative 3D soft tissue facial analysis using a color coding system.
7. Presenting feasible methods of the integrating 3D digital model into a 3D facial image to visualize the anatomic position of the dentition.

1.1 Reliability of measurement and clinical application of 3D digital model

The accuracy and reproducibility of a 3D surface scanning device to record the surface detail of study models is well documented and evaluated with respect to linear, surface, and volumetric parameters in the literature (Alcan *et al.*, 2009; Cha *et al.*, 2007; Costalos *et al.*, 2005; Dalstra & Melsen, 2009; Eraso *et al.*, 2007; Gracco *et al.*, 2007; Horton *et al.*, 2009; Keating *et al.*, 2008; Leifert *et al.*, 2009; Miller *et al.*, 2003). We have taken a comparison study using 30 dental study models (Cha *et al.*, 2007). Orthodontic linear measurements were recorded between landmarks, directly on the study models and indirectly on the 3D digital models by using the INUS dental scanning solution® (composed of Breuckmann's opto TOP scanner®, INUS Rapidform 2002®, Autoscan system®). The resolution of the Topometric & Photogrametric 3D scanner® after calibration is 8 µm and the reliability is 15 µm. This exceeds the accuracy required for orthodontic measurements such as the mesiodistal tooth width, arch length, and arch width. There were no significant differences between the measurements at the 1% level. The similar study (Keating *et al.*, 2008) using another laser scanning device (Minolta VIVID® 900, non-contact 3D surface laser scanner, Konica Minolta Inc., Tokyo, Japan) also shows that the difference between measurements on the study and 3D digital models was 0.14 mm, and was not statistically significant. In conclusion, measurements carried out on 3D digital models are a valid and reliable alternative to those currently used in study models in orthodontic practice with the advantage of significantly reducing measurement time.

1.2 Some examples of research and clinical applications using 3D digital model

Tooth size, crowding or spacing, overjet, overbite, and Bolton analysis are typically measured by hand on study models. 3D digital model is valuable alternative to conventional study models and can be used to determine routine diagnostic value, such as the Bolton analysis, arch length discrepancy, sagittal or transverse symmetry (Cha *et al.*, 2007; Santoro *et al.*, 2003) (Fig. 1). Automatic identification system (the automatic recognition of tooth morphology) will be a suite of technologies, that enable and facilitate the accurate capture and rapid transmission of machine readable data, e.g. cusp tip or pit and fissure of certain teeth, to automated information systems, thereby enhancing the readiness of capabilities in support of their respective mission.

Furthermore it also held information, which could previously be gathered only by complicated laboratory procedure, as sawing or wax up etc. There are numerous clinical examples to illustrate how such information could be applied in the diagnostic or treatment evaluation in orthodontics (Fig. 2). In counterpoint to the two-dimensional analysis, it is possible with 3D digital model to determine further parameters, such as palatal volume before and after maxillary expansion (Fig. 3) or volume or surface square measure of the deep structure of the palate (Fig. 4).

3D digital model offers many advantages, including elimination of model breakage and storage problems, instant retrieval of models, ease of communication with patients and colleagues. A single set of 3D digital models typically requires 8 MByte of disc space. It means that the data of 5,000 patients can be stored on a 40 GByte drive. It enables the orthodontist to e-mail images if desired and is a convenient presentation tool (Cha *et al.*, 2007).

Disadvantages include lack of tactile input for the orthodontist and time needed to learn how to use the system (Santoro *et al.*, 2003). 3D digital models present several unique challenges compared with conventional study models. Because the 3D computer image is

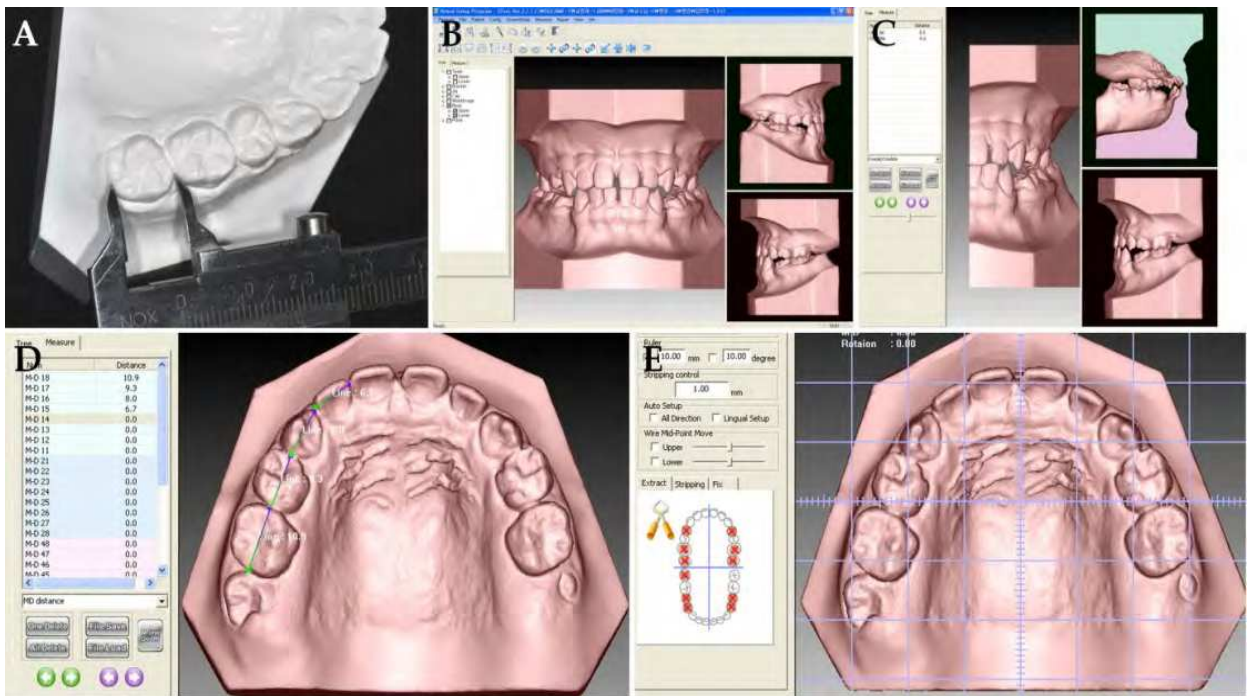


Fig. 1. **A.** Tooth size analysis: traditional manual method with sliding caliper. **B.** Gallery 3D digital model images in 3Txer software®(Orapix Co., Seoul, Korea). **C.** Selection of digital model for overbite and overjet measurements. Models can be rotated, which facilitates cross-sectioning at point of maximum overjet. **D.** Tooth size measurement tools (mesiodistal diameters) in 3Txer software®. **E.** Assessment of sagittal and transverse arch form symmetry in 3Txer software®.

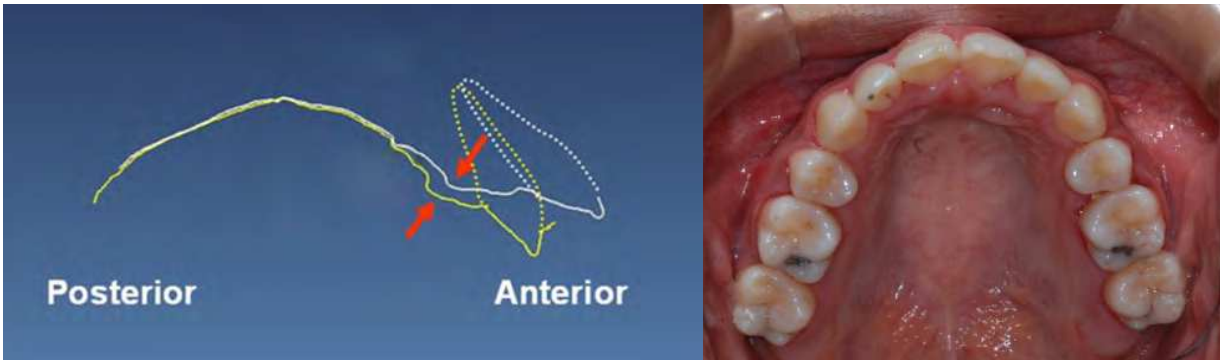


Fig. 2. Notice the change in palatal surface with gingival enlargement after retraction of anterior teeth. Enlarged soft tissue was denoted by the red arrow.

displayed on a 2D screen, the greatest challenge was observing crossbite. They will seem to have a positive overjet in the posterior segment when they really do not. Details for midlines, occlusal anatomy, and wear facets are not as clear on the 3D digital model (Stevens *et al.*, 2006).

Despite such limitations, 3D digital model provide a valuable source of information and continuous development of technology will suggest ways to overcome some of its shortcomings.

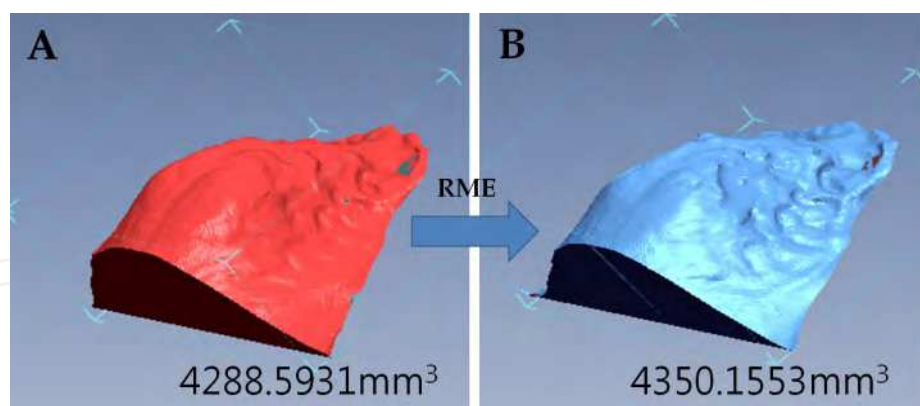


Fig. 3. Volumetric change of the palate before **A** and after **B** rapid maxillary expansion (volumetric change was about 61.6 mm³).

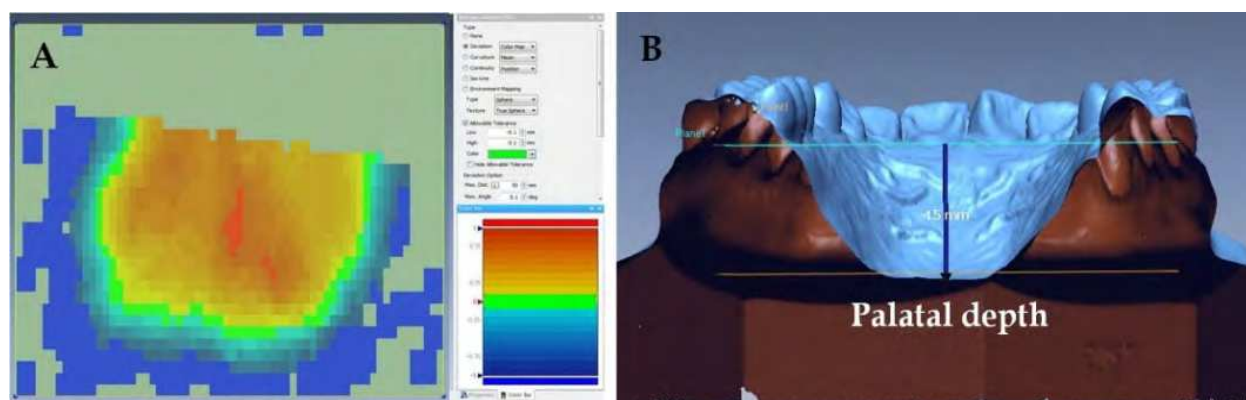


Fig. 4. **A.** Color contour analysis locating the deepest point that cannot be recognized accurately by manual method, light green means zero point, dark red area means deepest point of palate. **B.** Measuring accurate palatal depth from the arbitrary reference plane to the deepest point of mid-palatal suture located by using color contour analysis.

2. Evidences that the superimposition of the 3D digital maxillary model is clinically as reliable as cephalometric superimposition for assessing orthodontic tooth movement

Despite inherent errors, cephalometric superimpositions are currently the most widely used means for assessing sagittal and vertical tooth movement. However, there are some disadvantages and limitations of cephalometric radiographs and superimposition. Its drawbacks include difficulties in evaluating 3D tooth movement and identifying inherent landmarks. Further disadvantages are tracing errors, frequent radiation exposure, and high costs (Ghafari *et al.*, 1998).

We have performed a study, comparing 3D digital model superimposition with cephalometric superimposition (Cha *et al.*, 2007). The material was collected from initial and final maxillary study models and lateral cephalometric radiographs of 30 patients, who underwent orthodontic treatment with extraction of permanent teeth. The 3D superimposition was carried out using the surface-to-surface matching (best-fit method)

(Fig. 5). The antero-posterior movement of the maxillary first molar and central incisor was evaluated cephalometrically and on 3D digital models. The results revealed no statistical differences between the incisor and molar movements as assessed cephalometrically and by 3D model superimposition. These findings suggest that the 3D digital model superimposition technique used in this study is clinically as reliable as cephalometric superimposition for assessing orthodontic tooth movements.

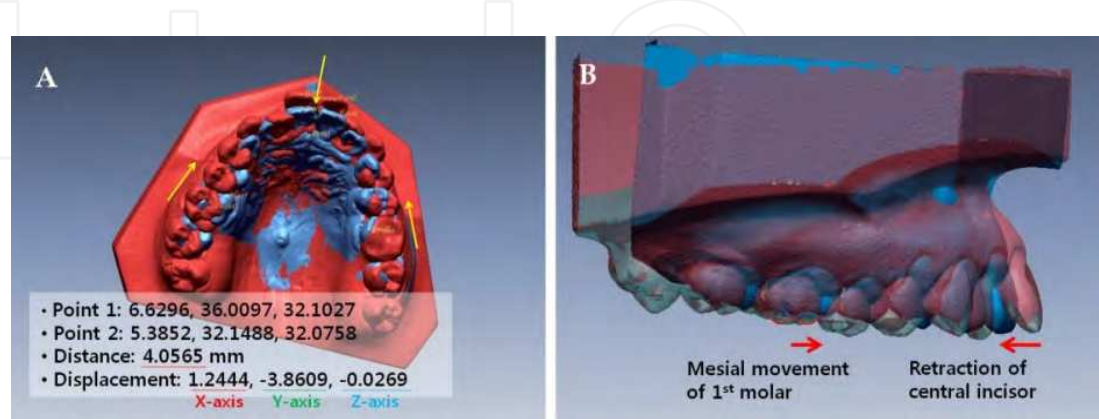


Fig. 5. Assessment of tooth movements on superimposed 3D digital models (red: before treatment, blue: after treatment). A. Occlusal view. B. Sagittal view.




Fig. 6. Measurement of the study model with the Reference Measurement Instrument (RMI) A. Digital calipers for X-, Y-, and Z-axis. B. Measuring from the tip of the canine.

To evaluate the accuracy of the superimposition of 3D digital models using the palatal surface as a reference for measuring tooth movements, we have performed a comparison study of the correlation between the tooth movement of the setup model and that of the superimposition in its 3D digital model (Choi *et al.*, 2010). Teeth on the study model were randomly moved after sawing, subsequently scanned to produce another set of 3D digital models. 3D digital model were superimposed using the palatal area as reference via surface-to-surface matching and the changes in tooth movement were calculated. In the study models, the tooth movements were directly measured using the Reference Measurement Instrument (Fig. 6). The means of the anteroposterior (x-axis), transverse (y-axis), and vertical (z-axis) tooth movements of the study models and those of the digital models did

not differ significantly, and very high correlations were found between the study models and the digital models.

Recently, Jang *et al.* (Jang *et al.*, 2009) superimposed serial models treated by premolar extraction by means of three miniscrews as registration landmarks (miniscrew-superimposition method) and compared with ruga-palate superimposition method. The displacement of the central incisors measured using the ruga-palate-superimposition method showed no significant difference with that measured using the miniscrew-superimposition method.

Moreover, with the superimposition method introduced here, it seems promising that, in the future, a simple mouse click will enable fast computer-assisted evaluation of 3D tooth movements (Choi *et al.*, 2010).

Despite promising possibilities of the applications, the validity of this method has not been examined in growing patients, who underwent orthopedic treatment, such as rapid maxillary expansion (RME) treatment or maxillary surgery. In addition, we must not overlook the fact, that we encounter difficulties when we try to superimpose the mandibular arch because of the lack of the stable registration area (Fig. 7). Further research on this field is needed to clarify the evidences for the stable area for the superimposition.

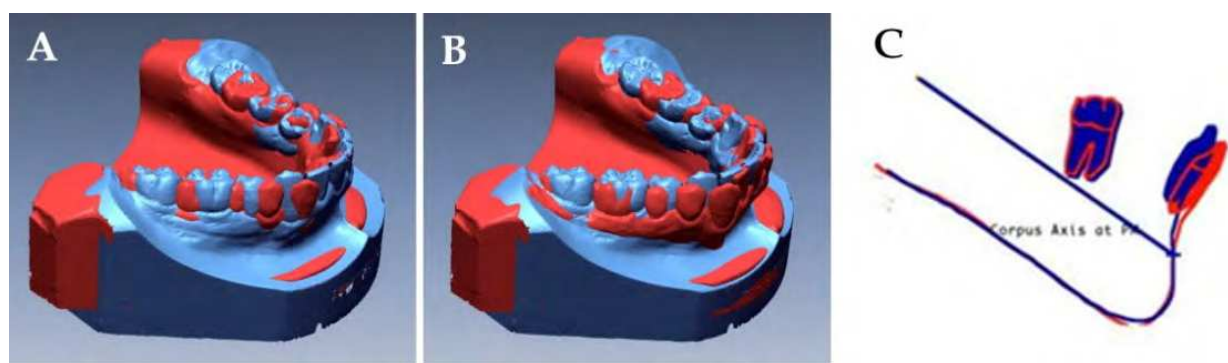


Fig. 7. Different results of mandibular superimposition due to the lack of stable registration area. Superimposition (A) shows no lingual movement of lower incisor. Note the tremendous lingual movement of lower incisor on superimposition (B) in same patient (red: before treatment, blue: after treatment). C. Superimposition on mandible in 2D cephalometrics shows lingual movement of lower incisor.

3. Presentation of clinical cases, using the superimposition technique for the 3D measurement of orthodontic tooth movement in maxilla

A 32-year-old Korean female presented with chief complaint of facial convexity. Cephalometric analysis showed a skeletal Class II relationship, significant obtuse mandibular plane angle, and retrognathic chin. After extraction of four premolars, pre-adjusted fixed appliances were bonded for initial leveling and alignment of both arches. An L-shaped mini-plate was adjusted to fit the contour of each cortical bone surface and was fixed with bone screws with the long arm exposed to the oral cavity, between upper first and second molars, for the intrusion of upper molars and retraction of upper dentition without any anchorage loss. After 30 months of orthodontic treatment, the patient showed a Class I occlusion with normal overbite, overjet and improved profile (Fig. 8).

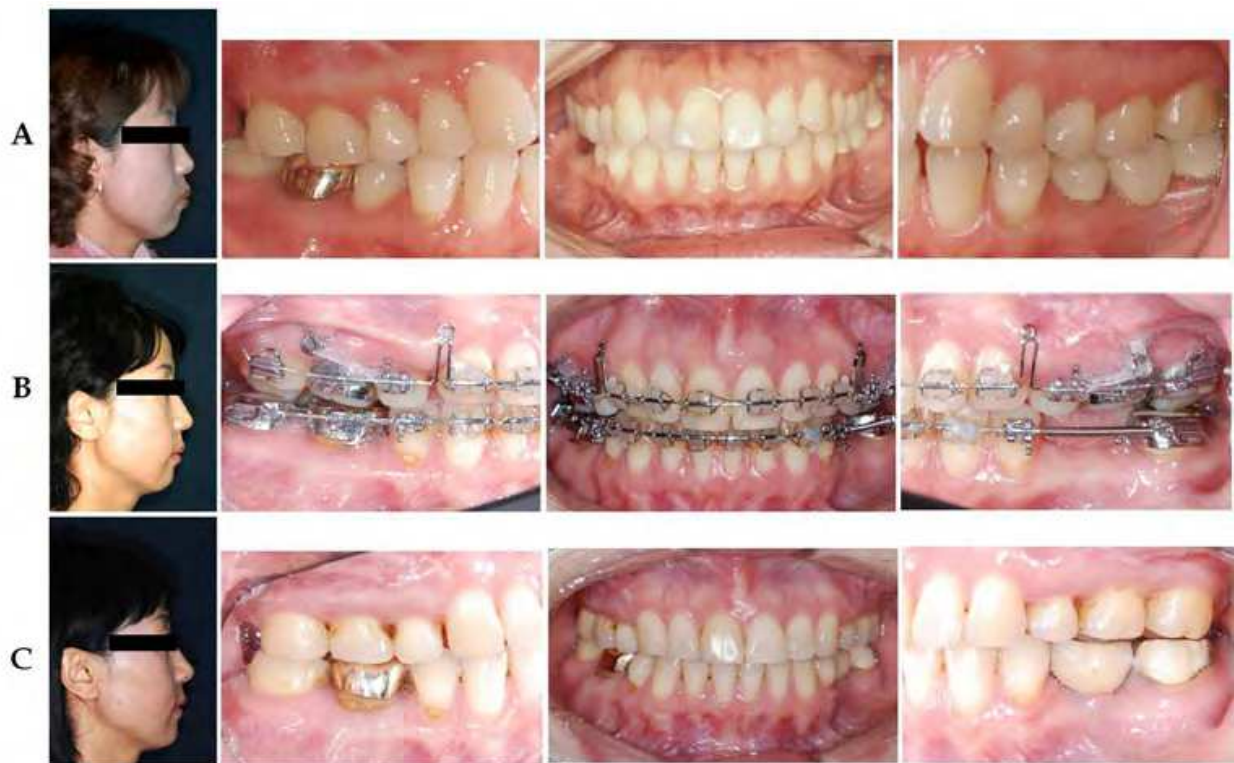

Fig. 8. A 32-year-old female with skeletal Class II relationship, hyperdivergent long-face pattern, and retrognathic chin. **A.** Pre-treatment. **B.** Contraction arch and miniplate for retraction of anterior teeth and intrusion of posterior teeth. **C.** Post-treatment.

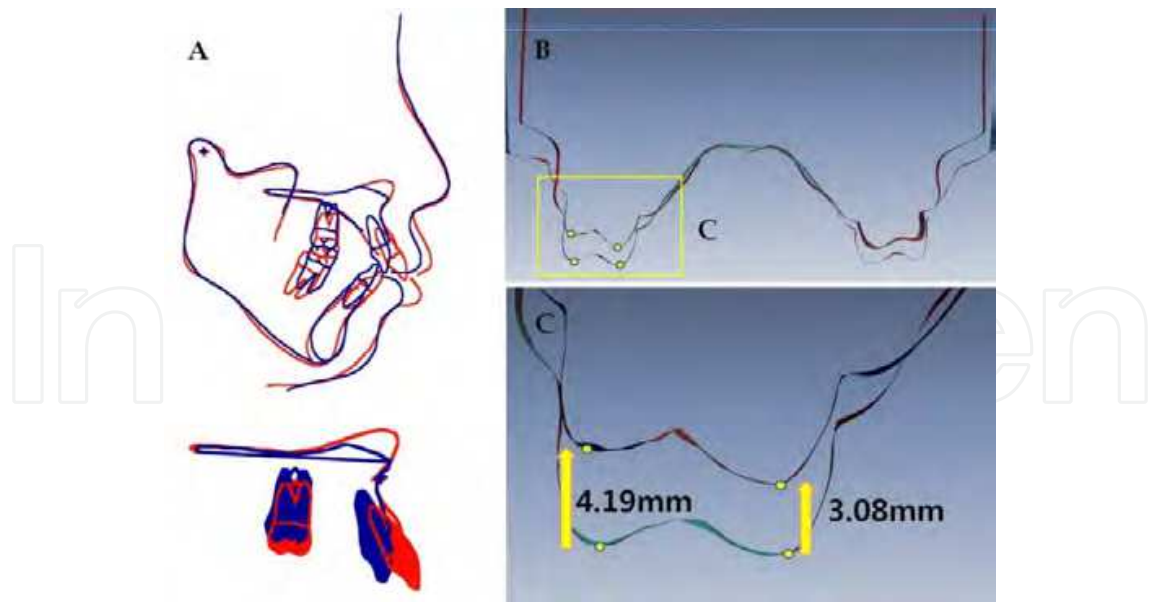


Fig. 9. **A.** Superimposition of pre-and post-treatment cephalometric tracings. Significant intrusion and distalization of upper molars were noted. (red: before treatment, blue: after treatment) **B.** Superimposition using 3D digital models. **C.** The amount of intrusion on the buccal and palatal cusp can be measured on the superimposed 3D digital models respectively. Note the different amount of intrusion between buccal and palatal cusp.

Superimposition of the pre- and post-treatment cephalometric radiography demonstrated significant intrusion of the upper posterior teeth. The entire upper dentition appeared to have been retracted. Fig. 9 shows, that in superimposed 3D digital model between before and after orthodontic treatment, the mesiobuccal cusp of upper right first molar was intruded 4.2 mm, on the other hand, palatal cusp as a functional cusp, was intruded only 3.1 mm. Such a result, it is impossible for us to get with the conventional cephalometric superimposition method.

A 10-year-old girl presented with a skeletal Class III malocclusion, a concave facial profile due to an anterior crossbite. Based on the cephalometric and clinical examinations, the patient was diagnosed as a functional Class III. The treatment plan for this patient included Class III activator (Fig. 10).

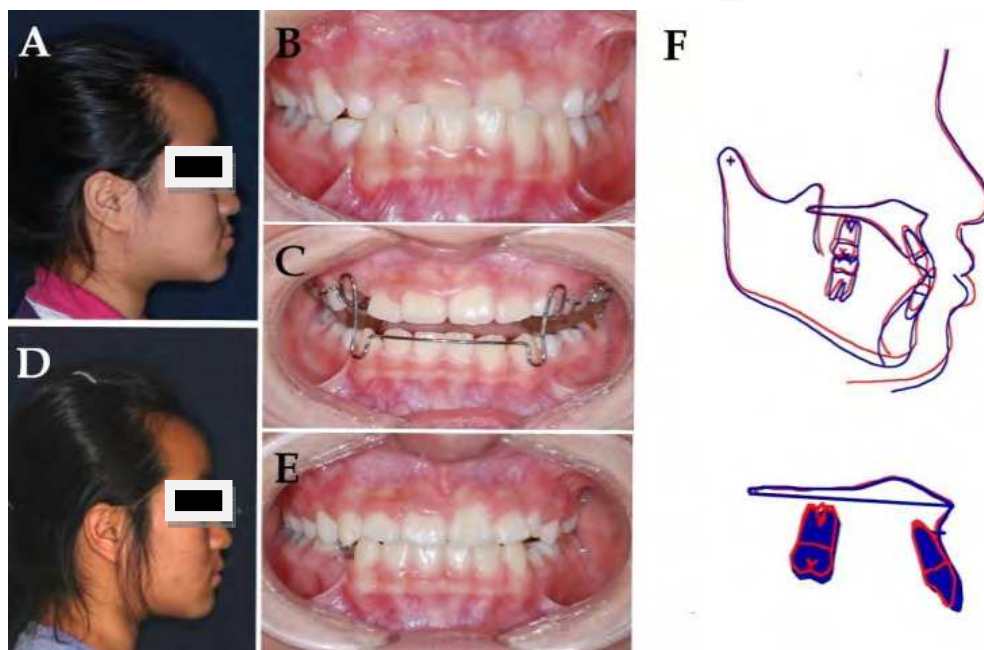


Fig. 10. A, B. Pre-treatment. Notice the anterior crossbite. C. Class III activator was used. D, E. Post-treatment. Notice normal overjet and overbite. F. Superimposition of pre-and post-treatment shows extrusion of upper molar and labioversion of upper incisors. (red: before treatment, blue: after treatment)

Post-treatment superimposed tracing revealed that anterior crossbite was corrected mainly by dentoalveolar movement and clockwise rotation of the mandible (Fig. 10). The maxillary incisors were flared and mandibular incisors were retruded and somehow extruded. However, correct measurement of the amount of tooth movement was not possible, because of inherent errors of the tracing and bisecting tracing of the cephalometrics.

The extrusion of upper molars exerts a downward vector of force on the mandible, causing the lower jaw to rotate downwards and backwards in a clockwise direction. Palatal cusp specially plays a more important role in this phenomenon rather than buccal cusp, which we are unable to measure separately in conventional superimposition of the 2D cephalometrics. Fig. 11 shows, that in superimposed 3D digital model between before and after orthodontic treatment, the mesiobuccal cusp of right upper first molar extruded 2.21 mm, on the other hand, mesiopalatal cusp as a functional cusp, extruded 1.30 mm. This different result might come from the change of the amount in the torque of the upper molars




Fig. 11. **A, B** Different amount of the extrusion between mesiobuccal cusp and mesiopalatal cusp, which plays an important role as a functional cusp.

4. The clinical procedure for digital diagnostic setup and fabrication of indirect bonding tray

The diagnostic setup is a valuable aid in testing the effect of complex therapy, such as asymmetric extractions, space redistribution in the congenital missing cases. By replacing the teeth on the model in their desired position after suitable trimming, one can obtain an idea of the proportions between dental arch, apical area, occlusion and the degree to which the anterior teeth should be displaced sagittally (Fig. 12)(Van der Linden, 1987). The infusion of computer-aided design/computer-assisted machining (CAD/CAM Technology) enables now orthodontist or technicians to make virtual diagnostic setup, that provide not only diagnostic aids, but also simplify the laboratory procedure for precise indirect bonding (Fig. 13).

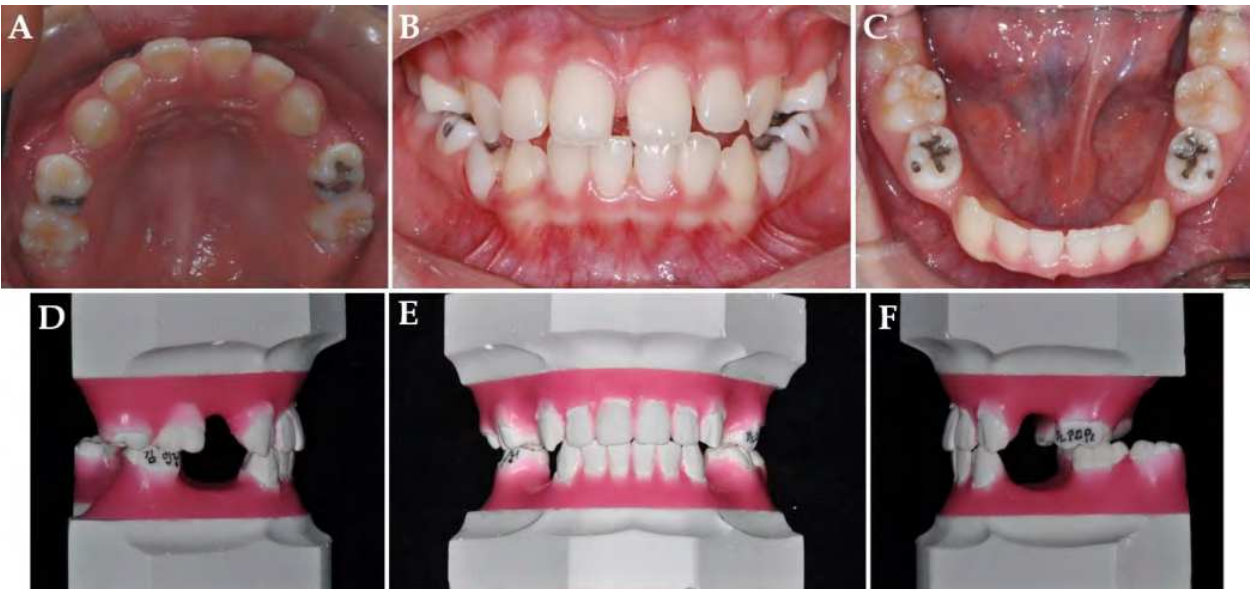


Fig. 12. **A~C**. This patient is Angle Class III with congenital missing teeth on #14, 15, 24, 25, 34, 35, 44, and 45. Treatment planning is prosthodontic treatment for #15, 25, 34, 35, 44, and 45 with full protraction of maxillary buccal teeth, as the lower anterior group remains unchanged. **D~F**. Traditional diagnostic set-up model.

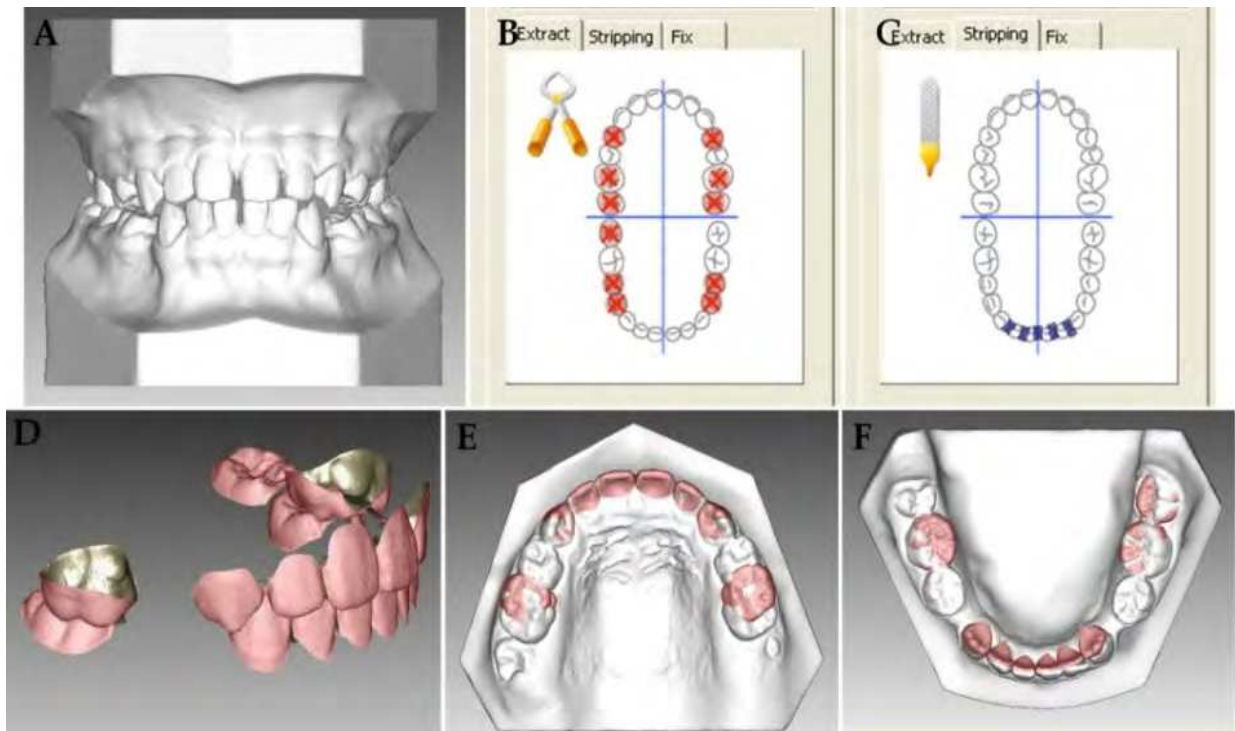


Fig. 13. 3D digital model in 3Txer software® (Orapix Co., Seoul, Korea). A~C. The program includes extractions or stripping functions, which can be planned in diagnostic set-up. In this case, we use “Extract” function. D. 3D virtual set-up in 3Txer software®. E, F. Superimpositions before and after set-up can visualize and quantify tooth movement in comparison to traditional set-up.

It is important in making the diagnostic setup to select correct arch form. For this purpose, we use an individualized template, which is able to give the precise arch form for each patient, provided by the 3Txer software® (Orapix Co., Seoul, Korea). These references are selected by the practitioner from a 3D virtual setup with virtual bracket positioning (Fig. 13).

Bracket positioning is an important factor for efficient orthodontic treatment. Traditionally, direct bonding of the bracket is used by most of the orthodontists. Advantages of direct bonding over the indirect procedure were summarized as follows (Zachrisson & Brobakken, 1978);

1. The bracket bases were fitted closer to the tooth surface.
2. It was easier to remove excess adhesive flash around the bracket bases.
3. The bonding adhesive constantly filled out the entire contact surface of the bracket.

As straight arch wire technique and lingual orthodontics were developed, because of the irregularity of lingual or labial tooth surface and the difficulty of access to some teeth, indirect bonding became very rapidly the technique of choice (Fillion, 2007).

Indirect bonding technique may be classified into two main categories; procedure with, or without setup of individual teeth. The difference between the two procedures is that while the purpose of the indirect bonding without setup is to reduce the possible positioning error often confronted in direct bonding, with setup is to realize the ideal straight arch wire technique that does not require arch wire bending. Fig. 14 shows typical procedure of indirect bonding without setup, using dual tray method.

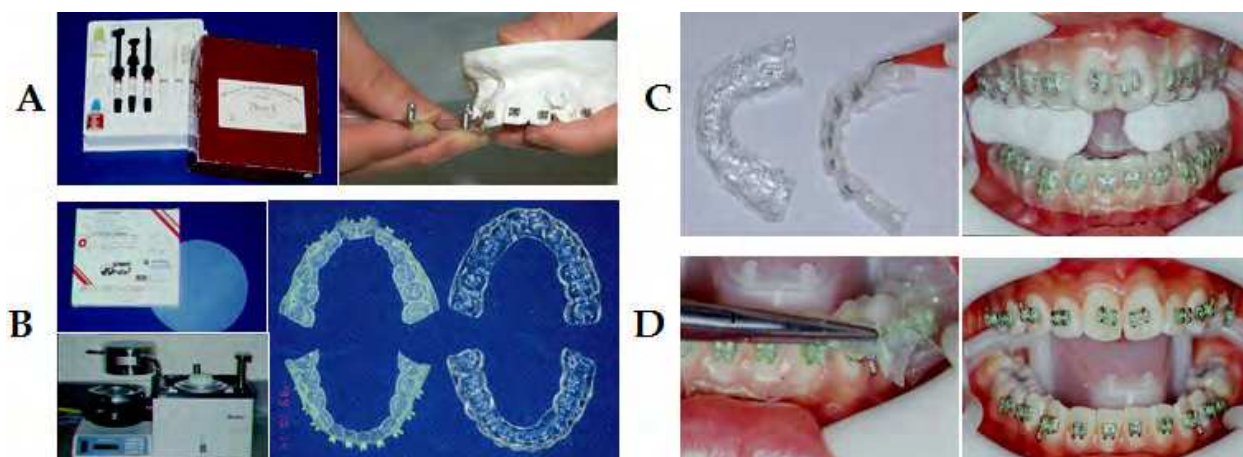


Fig. 14. Indirect bonding procedure. **A.** Apply double coat of liquid separator to dry stone models and positioning brackets using Phase II composite® on brackets' base. **B.** Fabricate two indirect transfer trays using 0.5 mm Copyplast material and 1.25 mm Biocryl material from Bioplast® company. **C.** Brackets' base is rinsed with acetone and the teeth are etched, rinsed, and dried. Excel composite® is added to brackets' base and the dual trays are applied. **D.** Removing transfer trays.

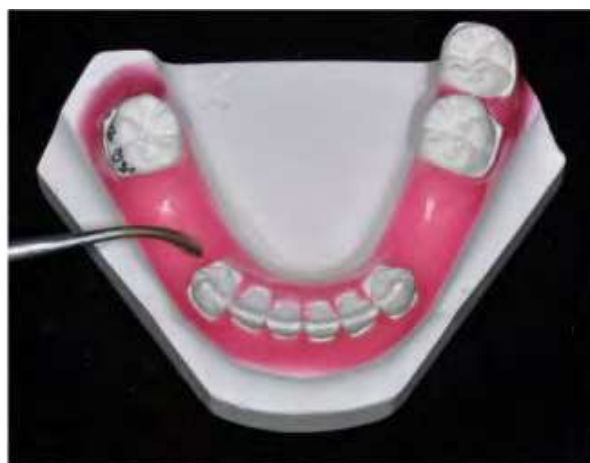

Fig. 15. The individual teeth are sawn out. Setting the separate block on the wax roll permits alternations in position.

In 1982, Myrberg and Warner (Myrberg & Warner, 1982) presented a technique, in which individual bracket placement indicators were made for each tooth based on the concept of a dental setup that suits the individual functional, occlusal, and esthetic requirements of each patient. Subsequent to this, numerous techniques have been developed based on indirect bonding from diagnostic setups (Hoffman, 1988). The traditional method of fabricating a diagnostic setup is to saw through the root areas, separate the teeth by hand, and affix them in their new positions with wax (Fig. 15). The technique is difficult to master and furthermore the laboratory procedure is tedious and time consuming for both the technician and orthodontist.

The rapid development of CAD/CAM technology enables not only bonding the brackets in precisely corrected position, but ensures that their individualized placements will produce the ideal occlusion incorporated in the virtual setup (Fillion, 2007).

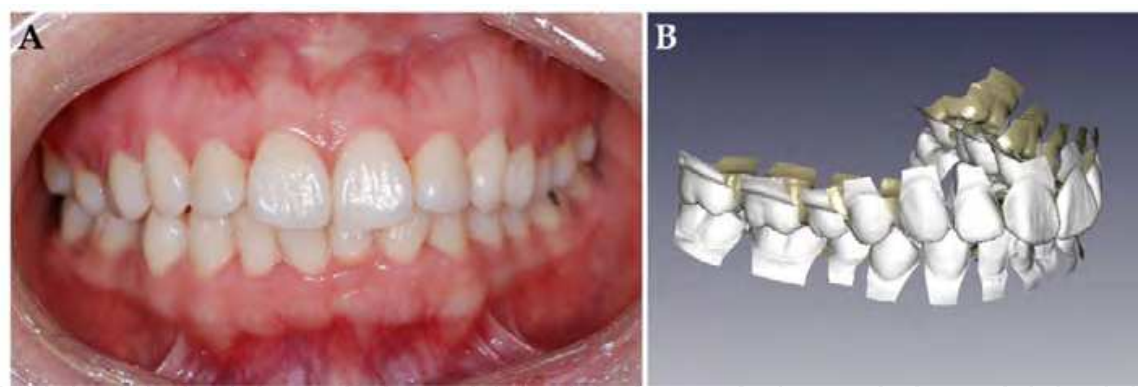


Fig. 16. **A.** This patient’s chief complaint was anterior crowding. **B.** Visualization of the scanned model and establishing the geometrically independent tooth unit.

In the followings, an indirect bonding technique will be introduced and summarized based on a virtual setup from CAD/CAM transfer trays. For a more detailed discussion of this procedure, the reader can refer some publications (Fillion, 2007; 2010).

1. Dental arch should be segmented into individual dental units perceived as geometric units (Fig. 16).
2. Making the treatment plan, including extraction or non-extraction, stripping, final arch form. Such prescriptions are incorporated in 3Txer software®.
3. After setup, according to the selected prescription, upper and lower arch are manually adjusted to fit the final treatment result. (Fig. 17 C, D).
4. The virtual brackets are placed on the same horizontal plane and centered on each tooth. In this procedure, individual arch form (virtual arch) can be determined.(Fig. 17 E)
5. Virtual transfer trays are constructed. A rapid-prototype machine constructs in real time the transfer tray (Fig. 18 A).
6. Positioning the tray over the teeth and seating the tray (Fig. 18 B).

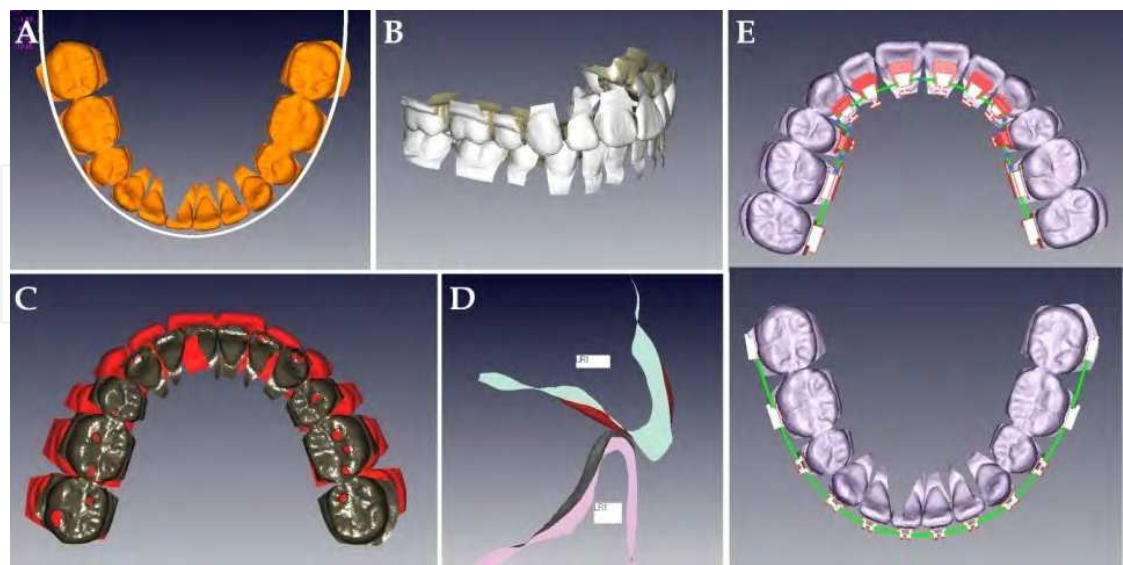


Fig. 17. **A.** Selection of the curve, on which the teeth will be positioned in construction of the set-up. **B.** Visualization of the set-up. **C, D.** Occlusion test: the red-colored zones represent the areas of contact. **E.** Precise positioning of the virtual brackets on the virtual set-up and placement of the ideal virtual arch wire.

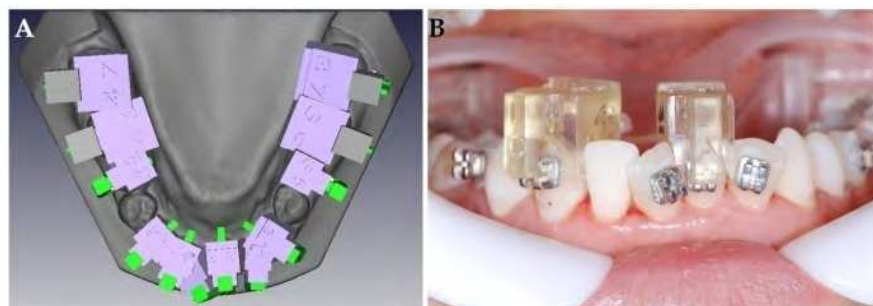


Fig. 18. **A.** Construction of the virtual transfer trays. **B.** Bonding of the brackets.

Material and equipment manufacturers continually introduce new and innovative products that further advance virtual technology. A fabrication procedure of virtual surgical splint procedure in virtual articulator has been also introduced, which spare the time consuming procedure of model surgery and surgical wafer fabrications (Song & Baek, 2009). Recently, a new imaging method, using computed tomography technology and laser scanning provides complete 3D views of the maxilla and the mandible, and the model setup with individual roots (Harrell *et al.*, 2002; Macchi *et al.*, 2006). The development of a 3D digital setup that displays individual crowns, roots and craniofacial structures will greatly help the clinician in diagnosis and treatment planning to determine various treatment options, monitor the changes after treatment over time, predict and display final treatment results, and measure treatment outcomes accurately (Macchi *et al.*, 2006).

Recently, Rangel and colleagues (Rangel *et al.*, 2008) reported the registration of digital models to 3D facial images. These multimodal images could improve our diagnosis and treatment planning processes and eventually will become the clinical standard, enhancing treatments provided by different specialties, including orthodontics, periodontics, prosthodontics, and restorative dentistry.

5. Introducing a novel method of the volumetric assessment of tooth wear using 3D reverse engineering technology

Tooth wear is defined as the non carious loss of tooth substance as a result of attrition, abrasion and erosion. Tooth attrition is regular and slow progressive loss of dental tissues as a consequence of tooth to tooth contact during mastication (Milicic *et al.*, 1987; Shafer *et al.*, 1983.) especially by parafunctions and unbalanced morphological occlusion.

Loss of occlusal surface of the tooth affects the vertical dimension and might induce deep bite (Ramjford & Ash, 1983). If there is attritional wear on the posterior teeth, they induce interference with completely seated TMJs and/or the anterior guidance (Dawson, 2007). High correlations among tooth wear, maximal bite force and the size of the gonial angle were reported (Kiliaridis *et al.*, 1995). Some previous studies reported the association between greater tooth wear and malocclusion (Carlsson *et al.*, 2003), although there were controversial opinions.

There are a few studies which investigated the relationship between tooth wear and orthodontic treatment (Kuijpers *et al.*, 2009). Until now there is no study focused on the tooth wear during orthodontic treatment, moreover no information about the quantity of tooth wear caused by orthodontic treatment. The main reason is probably due to the technical limit in quantifying the volumetric change of the tooth material. For that reason the most previous studies on tooth wear evaluated the tooth wear index only on study models. Recently, Cha *et*

al. (Cha et al., 2007) suggested the clinical method of the quantifying volumetric change due to tooth wear by using 3D digital model superimposition.

The followings will show you how to use the superimposition method of 3D digital models to quantify the amount of central incisor wear occurred during the orthodontic treatment (Fig. 19).

The maxillary and mandibular dental casts were taken before and after orthodontic treatment and scanned by a laser surface scanning system (KOD300®, Orapix co. LTD, Seoul, Korea) with the reliability of 50 μm . 3D virtual models of central incisors were reconstructed and imported to a 3D reverse modeling software (Rapidform XOR3®, INUS Technology, Seoul, Korea) (Fig 19. A, B). The 3D images of central incisor before and after orthodontic treatment were superimposed with best-fitting method. As reference area, the middle third of labial and lingual surface of central incisor were used, because these areas are considered to be rarely affected by attritional wear and the pathologic condition of gingival (Fig. 19 C)

To calculate the volume of central incisor, the 3 boundary planes were constructed on the 3D images of central incisor before treatment (Fig. 19 D, E). We compared the volume of the central incisors before and after treatment in relation with the boundary planes and we arrived at the conclusion that the second one was smaller (Fig. 19 F, G).

This technology can be applied into a quite diverse area in dentistry, e.g. quantity evaluation of teeth after prosthetic or conservative treatments.

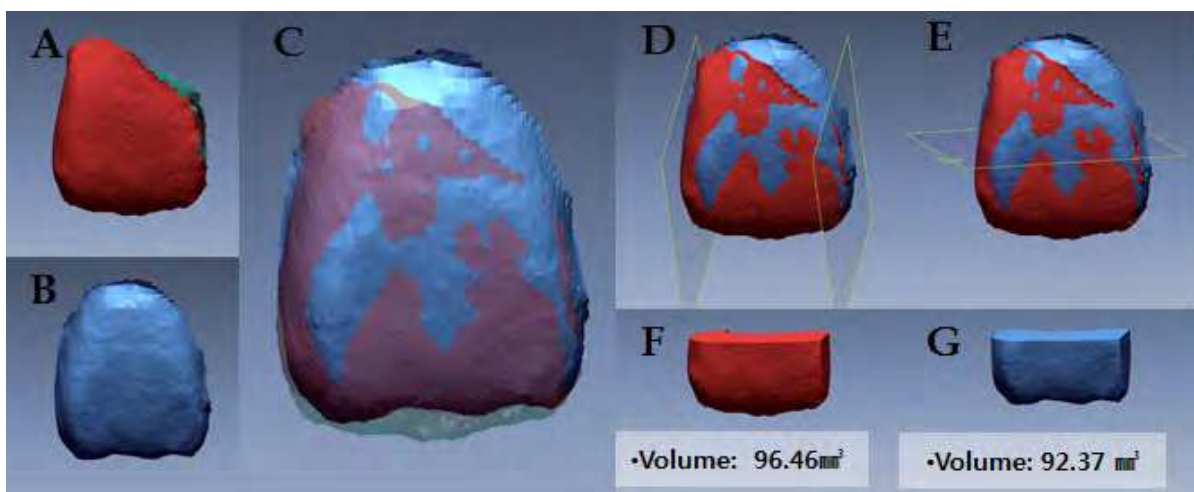


Fig. 19. Procedure for quantifying the amount of tooth wear. A. 3D digital model of maxillary incisor before orthodontic treatment (red). B. 3D digital model of the same tooth after orthodontic treatment (blue). C. Superimposition of A and B with best-fitting method using the middle third of labial and lingual surface as reference area. D, E. Mesial plane, distal plane, and gingival plane as boundary planes. F, G. 3D digital model before and after orthodontic treatment with the same boundary planes for volumetric calculation of tooth wear. The volume of tooth materials was reduced to about 4.09 mm^3 .

6. Presenting a quantitative 3D soft tissue facial analysis using a color coding system

Orthodontists have recognized that objective evaluation of facial morphology is important for the effective treatment planning and evaluation in reference to the growth change.

Traditionally, orthodontists have used radiographs to assess the soft tissue facial change, e.g. they measure 2D landmarks on the lateral cephalogram that arguably do not exist in a 3D body (Kau & Richmond, 2008). The problems in traditional cephalometrics also come from landmark identification of hard and soft tissues on x-rays because of the superimposition of several structures, which might be the major source of cephalometric errors. In the patient Fig. 20, it is showed that the facial contour angle was improved after orthognathic surgery but there is a limitation and difficulty to evaluate it at full extent three dimensionally.

Medical CT or Cone-beam CT (CBCT) can be an alternative, but possible overuse might lead to radiation exposure problems, together with financial burden. For the reason mentioned above, it should be stated that traditional longitudinal growth studies with radiation sources might present ethical and moral dilemmas. How to solve such an ethical dilemma? We think that the use of alternative surface imaging devices can be one step forward in handling such ethical dilemmas.

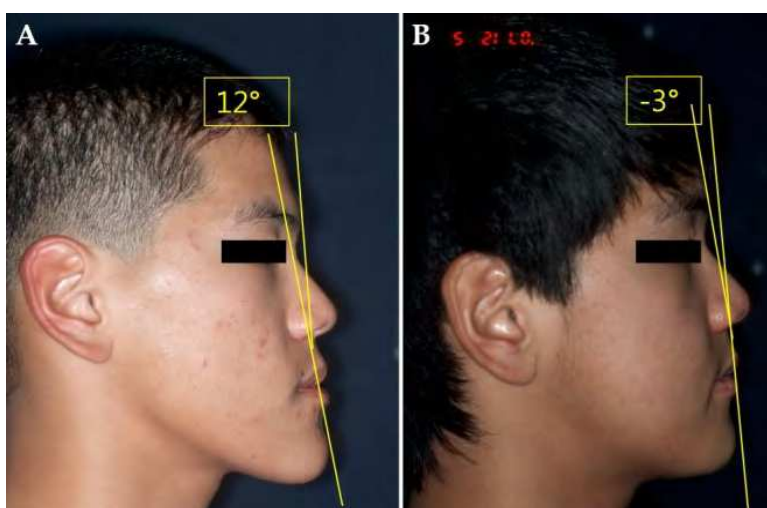


Fig. 20. **A.** Pre-treatment lateral view. **B.** Post-treatment lateral view. Note that although facial contour angle improved after surgery, there is a limitation to evaluate it at full extent.

With the advances in the technology, various devices, including laser scanners (Baik *et al.*, 2007), stereophotogrammetry (Ayoub *et al.*, 2003), and structured light systems (Weinberg *et al.*, 2004) have been used in acquiring the 3D images of the facial morphology. Among them, 3D laser scanner system or optical surface scanner is widely used because of its simple and rapid capture of the whole facial 3D image. It is quite likely that this system has a diverse possibility of clinical applications and researches (Baik *et al.*, 2007; Ismail & Moss, 2002; McCance *et al.*, 1997; McDonagh *et al.*, 2001; Moss, 2006; Moss *et al.*, 1995)

The laser scanning 3D technology allows to generate a high precision and can be used to calculate the morphological ground surface variations at different acquisition time intervals. The main advantages are that change due to growth or treatment of an individual can be monitored in three dimensions using this method, which is non-invasive and which can be repeated every few weeks (Moss, 2006; Moss *et al.*, 1995).

The registration program (Rapidform XOR3®, INUS technology, Seoul, Korea) enables superimposition of similar areas on two overlaid scans to demonstrate the surface differences in color coding system (Moss, 2006)(Fig. 22 E)

The purpose of 3D face registration is to align different 3D face data into a common coordinate system. So, registration is a crucial and indispensable step, as the accuracy of this step will greatly influence the performance of the whole face recognition system. The important step in the registration process is to determine which area will be used as a stable reference. The displacement, change in shape, or in size will be described relative to these structures. In the traditional 2D cephalometrics, the anterior cranial base e.g. Sella-Nasion is used for the superimpositions because of its relative stability after neural growth in brain. But locating 3D landmarks on complex curving structures is significantly more difficult (Miller et al., 2007; Morris et al., 1998; Moss et al., 1994).

Moss et al. (Moss *et al.*, 1994) combined five aforementioned anatomical landmarks (right and left endocanthion, right and left exocanthion and soft tissue Nasion) together with five constructed points projected onto the forehead. Hajeer et al. (Hajeer *et al.*, 2002) used seven superimposition points in the eye and nose area. Miller *et al.* (Miller et al., 2007) hold a view that the forehead area is stable area for superimposing 3D images. The superimposition points above were proved to be easy to locate and the landmarks well definable (Hoefert et al., 2010) (Fig. 21, Table 1).

There are, however, a number of problems that remain to be explored.

The forehead area with superimposition points 5, 6 and 7 in Fig. 21 and Table 1 were in an area, in which, according to the Bolton standards, 0.5 - 1.0 mm increase in Nasion-Sella line and a forward displacement of the frontal bone can be expected with normal growth in children between ages 4 and 5 (Hoefert et al., 2010). It means that the distance from sella turcica to foramen caecum does not increase after eruption of the first permanent molar and forehead can be used as a superimposing area.

However, this assumption is not supported by the mention that there was a correlation between frontal sinus pneumatization and the progression of skeletal maturity (Ruf & Panherz, 1996). Another recent case reports by author (Cha *et al.*, 2011) provides the evidence that infraorbitale can be moved forward by maxillary protraction by using the surgical miniplate anchorage. These observations suggest further questions that must be reserved for a more extensive study.




Fig. 21. Superimposition points (for explanation see Table 1).

Superimposition points	Description
Point 1	Right exocanthion
Point 2	Right endocanthion
Point 3	Left exocanthion
Point 4	Left endocanthion
Point 5	Intersection of forehead axis with the outer eye circle
Point 6	Intersection of forehead axis with the inner eye circle
Point 7	Middle of eye axis

Table 1. Superimposition points recommended by Hoefert *et al.* (Hoefert *et al.*, 2010).

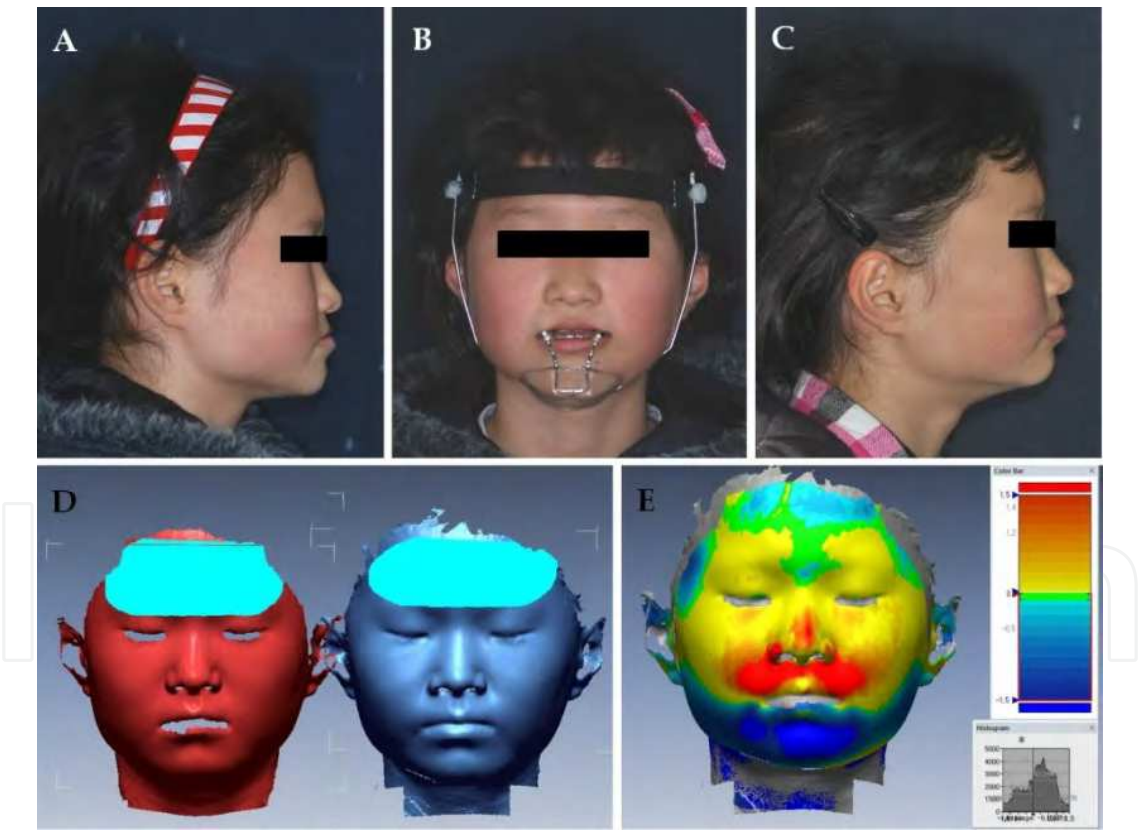


Fig. 22. 3D facial superimposition of the patient treated by maxillary protraction **A.** pre-treatment facial photo. **B.** Treatment by protraction headgear. **C.** Post-treatment facial photo. **D,E.** Superimposition of pre- and post-treatment 3D facial images using the forehead as reference area. According to the color-coding system, yellow/red color means forward movement, while blue color means backward movement.

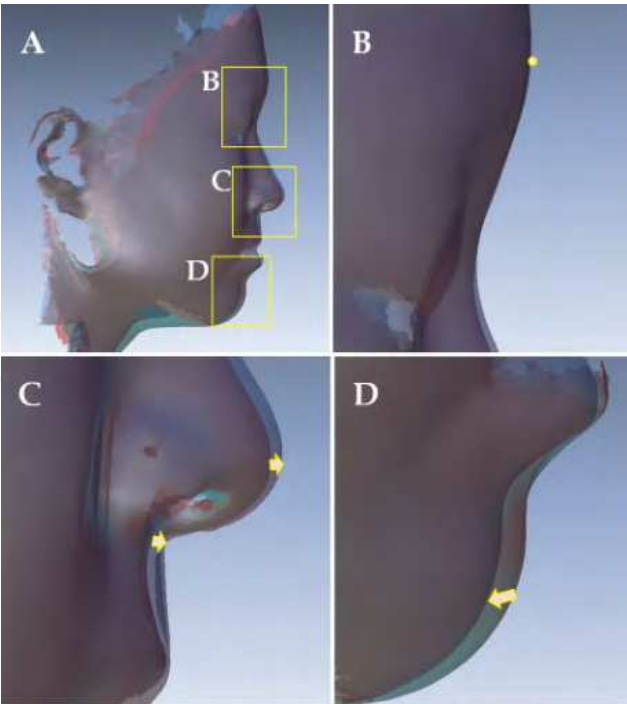


Fig. 23. **A.** Detailed sectional view of superimposition image in Fig. 22. **B.** Glabella was not changed. **C.** Nose tip and Subnasale was protruded by 0.6 mm and 1.2 mm, respectively. **D.** Pogonion was retruded in backward and downward direction by 2 mm.




Fig. 24. Method for evaluating the volumetric change of the lip. **A~C.** 3D facial images were acquired and superimposition on forehead area was performed. To measure the volumetric change of the lip, boundary planes for the upper lip were constructed on the 3D facial images. **D~F.** The changes of lip volume before debonding (yellow), after debonding (green), and 6 months after debonding (blue).

Following is the example of the application of 3D facial registration for the evaluation of the change of facial morphology after orthopedic treatment. A patient who has a developing Class III malocclusion was monitored in order to assess the direction of growth and the rate of change after maxillary protraction therapy (Fig. 22 and 23).

There were no apparent changes to the central portion of the forehead and Glabella area (Fig. 23 B). There was general thickening of the lateral brow region, from 0.34 to 0.50 mm. The nose showed the positive change by 1.20 mm during the treatment (Fig. 23 C). There were visible but small positive changes in the cheek areas similar on both sides of the face. There was large and distinct forward and downward translation of the maxilla away from the forehead. There was elongation of the face leading to the downward projection of the soft-tissue chin (Fig. 23 D).

Another example (Fig. 24) represents the procedures for the evaluation of the quantitative change of lip volume between the final stage of the orthodontic treatment and after debonding procedure, to investigate the influence of bracket thickness for facial profile in 29 year-old male patients. The 3D facial images were imported into the Rapidform XOR3 software® (INUS technology, Seoul, Korea) and the superimposition method known as the best-fit was used on the reference area at the forehead, soft tissue glabella, including zygoma and nose.

To evaluate the volumetric change of the lip, 5 boundary planes were constructed on the 3D facial images. The volume in upper lip decreased 644.80 mm³ immediately after debonding, and 650.01mm³ more for the 6 month of retention period. The technique of the detailed volumetric measurement of soft tissue points to several promising applications for future research.

7. Presenting feasible methods of the integrating digital 3D model into a 3D facial image to visualize the anatomic position of the dentition

One area of high interest is the study of the integration of 3D digital model into a 3D facial image, which can be used as possible alternatives to 2D cephalometric superimposition. The 3D digital models of each dental arch are scanned independently and need to be related in space to represent the patient occlusion. Different methods have been developed for this purpose: visually assessing the study models' occlusion and matching their relative position in the virtual space; by scanning a wax bite, and registering the upper model to the upper side of the wax bite and the lower model to its lower side; by mounting the models in a bracket of known relative position, or by scanning the study models in occlusion and using that relative positional information to register the upper model to the lower one.

Rangel et al. (Rangel *et al.*, 2008) first introduced the procedure for the integration of 3D digital model in 3D facial image. Fig. 26 shows summarized procedures of digital model integration method.

For matching the 3D digital model to the 3D facial image, the anterior teeth were used as the registration surface.

1. To see the teeth on the 3D facial image, cheek retractors were used to pull the lips open, then a 3D facial image was made (Fig. 25 A and B).
2. A second 3D facial image was made from the patient at rest with the teeth in occlusion (Fig. 25 C).
3. 3D digital model is matched to the 3D facial image with the cheek retractors. To improve the accuracy of the registration, two step registration procedure were needed (Fig. 26 A~C).

- 4. Two 3D facial image at rest and with retractor were matched. Here as above, two step registration procedure were needed (Fig. 26 D~F).
- 5. Final 3D data set could be established (Fig. 27).

It seems technically possible to make a data set of a patient’s face with the dentition positioned into this 3D picture. This procedure points to several promising applications for feature research about noncephalometric analysis or superimpositions.

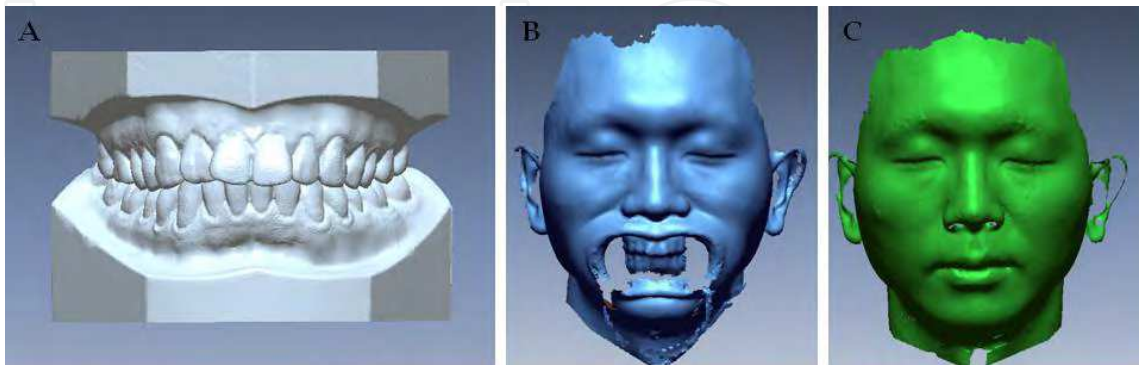


Fig. 25. **A.** 3D digital model. **B.** 3D facial image of the patient with cheek retractor. **C.** 3D facial image of the patient at rest position.




Fig. 26. Integration procedure of the 3D digital model into the 3D facial image. **A.** Region for surface registration is indicated on the 3D digital model(upper and lower anterior teeth were used). **B.** The same region in **A** is indicated on the 3D facial image with cheek retractor. **C.** Integration of 3D digital model and 3D facial image by using the registration area. **D, E.** Region for surface registration of two 3D facial images(forehead area was used). **F.** Superimposition of 3D facial images in **D** and **E**.

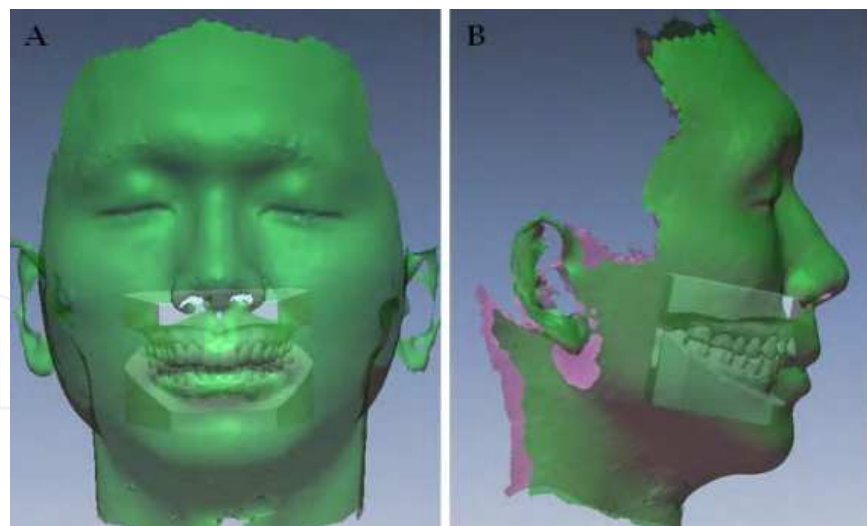


Fig. 27. Completed data set of the 3D digital model integrated into a 3D facial image. **A.** frontal view. **B.** profile view

8. Conclusion

In this chapter, we have reviewed the extent and limitation of the clinical application of 3D digital model and 3D facial image. The best-fit mathematical superimposition method of maxillary casts on the identical palatal vault is very accurate and allows for 3D evaluation of tooth movement. This technology can be also applied into a quite diverse area in dentistry, e.g. quantity evaluation of tooth material after conservative treatments or tooth wearing. The rapid development of CAD/CAM technology and the advances in 3D imaging of the face enable not only the virtual setup of the teeth but the results of treatment to be viewed from any perspective and to analyze the changes that have occurred by the treatment or growth.

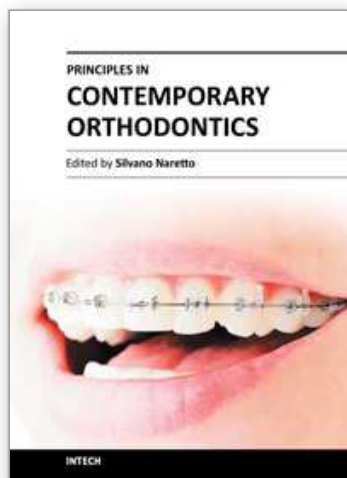
9. References

- Alcan, T.; Ceylanoglu, C. & Baysal, B. (2009). The relationship between digital model accuracy and time-dependent deformation of alginate impressions. *Angle Orthod*, Vol.79, No.1, pp. 30-36. ISSN 0003-3219
- Ayoub, A.; Garrahy, A.; Hood, C.; White, J.; Bock, M.; Siebert, J.P.; Spencer, R. & Ray, A. (2003). Validation of a vision-based, three-dimensional facial imaging system. *Cleft Palate Craniofac J*, Vol.40, No.5, pp. 523-529. ISSN 1055-6656
- Baik, H.S.; Jeon, J.M. & Lee, H.J. (2007). Facial soft-tissue analysis of Korean adults with normal occlusion using a 3-dimensional laser scanner. *Am J Orthod Dentofacial Orthop*, Vol.131, No.6, pp. 759-766. ISSN 1097-6752
- Carlsson, G.E.; Egermark, I. & Magnusson, T. (2003). Predictors of bruxism, other oral parafunctions, and tooth wear over a 20-year follow-up period. *J Orofac Pain*, Vol.17, No.1, pp. 50-57. ISSN 1064-6655
- Cha, B.K.; Choi, D.S.; Ngan, P.; Jost-Brinkmann, P.G.; Kim, S.M. & Jang, I.S. (2011). Maxillary protraction with miniplates providing skeletal anchorage in a growing Class III patient. *Am J Orthod Dentofacial Orthop*, Vol.139, No.1, pp. 99-112. ISSN 1097-6752

- Cha, B.K.; Choi, J.I.; Jost-Brinkmann, P.G. & Jeong, Y.M. (2007). Applications of three-dimensionally scanned models in orthodontics. *Int J Comput Dent*, Vol.10, No.1, pp. 41-52. ISSN 1463-4201
- Cha, B.K.; Lee, J.Y.; Jost-Brinkmann, P.G. & Yoshida, N. (2007). Analysis of tooth movement in extraction cases using three-dimensional reverse engineering technology. *Eur J Orthod*, Vol.29, No.4, pp. 325-331. ISSN 0141-5387
- Choi, D.S.; Jeong, Y.M.; Jang, I.; Jost-Brinkmann, P.G. & Cha, B.K. (2010). Accuracy and reliability of palatal superimposition of three-dimensional digital models. *Angle Orthod*, Vol.80, No.4, pp. 497-503. ISSN 1945-7103
- Costalos, P.A.; Sarraf, K.; Cangialosi, T.J. & Efstratiadis, S. (2005). Evaluation of the accuracy of digital model analysis for the American Board of Orthodontics objective grading system for dental casts. *Am J Orthod Dentofacial Orthop*, Vol.128, No.5, pp. 624-629. ISSN 0889-5406
- Dalstra, M. & Melsen, B. (2009). From alginate impressions to digital virtual models: accuracy and reproducibility. *J Orthod*, Vol.36, No.1, pp. 36-41; discussion 14. ISSN 1465-3133
- Dawson, P.E. (2007). *Functional occlusion: from TMJ to smile design*. Mosby. ISBN 978-0323033718, Philadelphia, USA
- Eraso, F.E.; Parks, E.T.; Roberts, W.E.; Hohlt, W.F. & Ofner, S. (2007). Density value means in the evaluation of external apical root resorption: an in vitro study for early detection in orthodontic case simulations. *Dentomaxillofac Radiol*, Vol.36, No.3, pp. 130-137. ISSN 0250-832X
- Fillion (2007). Computerized generated conception and fabrication of transfer trays for indirect bonding of lingual attachments: The Orapix system. *Rev Orthop Dento Facial*, Vol.41:1-15, pp. 1-15.
- Ghafari, J.; Baumrind, S. & Efstratiadis, S.S. (1998). Misinterpreting growth and treatment outcome from serial cephalographs. *Clin Orthod Res*, Vol.1, No.2, pp. 102-106. ISSN 1397-5927
- Gracco, A.; Buranello, M.; Cozzani, M. & Siciliani, G. (2007). Digital and plaster models: a comparison of measurements and times. *Prog Orthod*, Vol.8, No.2, pp. 252-259. ISSN 1723-7785
- Hajeer, M.Y.; Ayoub, A.F.; Millett, D.T.; Bock, M. & Siebert, J.P. (2002). Three-dimensional imaging in orthognathic surgery: the clinical application of a new method. *Int J Adult Orthodon Orthognath Surg*, Vol.17, No.4, pp. 318-330. ISSN 0742-1931
- Harrell, W.E., Jr.; Hatcher, D.C. & Bolt, R.L. (2002). In search of anatomic truth: 3-dimensional digital modeling and the future of orthodontics. *Am J Orthod Dentofacial Orthop*, Vol.122, No.3, pp. 325-330. ISSN 0889-5406
- Hoefert, C.S.; Bacher, M.; Herberts, T.; Krimmel, M.; Reinert, S.; Hoefert, S. & Goz, G. (2010). Implementing a superimposition and measurement model for 3D sagittal analysis of therapy-induced changes in facial soft tissue: a pilot study. *J Orofac Orthop*, Vol.71, No.3, pp. 221-234. ISSN 1615-6714
- Hoffman (1988). Indirect bonding with a diagnostic set-up. *J Clin Orthod*, Vol.8, pp. ISSN 509-511.
- Horton, H.M.; Miller, J.R.; Gaillard, P.R. & Larson, B.E. (2009). Technique comparison for efficient orthodontic tooth measurements using digital models. *Angle Orthod*, Vol.80, No.2, pp. 254-261. ISSN 0003-3219

- Ismail, S.F. & Moss, J.P. (2002). The three-dimensional effects of orthodontic treatment on the facial soft tissues--a preliminary study. *Br Dent J*, Vol.192, No.2, pp. 104-108. ISSN 0007-0610
- Jang, I.; Tanaka, M.; Koga, Y.; Iijima, S.; Yozgatian, J.H.; Cha, B.K. & Yoshida, N. (2009). A novel method for the assessment of three-dimensional tooth movement during orthodontic treatment. *Angle Orthod*, Vol.79, No.3, pp. 447-453. ISSN 0003-3219
- Kau, C.H. & Richmond, S. (2008). Three-dimensional analysis of facial morphology surface changes in untreated children from 12 to 14 years of age. *Am J Orthod Dentofacial Orthop*, Vol.134, No.6, pp. 751-760. ISSN 1097-6752
- Keating, A.P.; Knox, J.; Bibb, R. & Zhurov, A.I. (2008). A comparison of plaster, digital and reconstructed study model accuracy. *J Orthod*, Vol.35, No.3, pp. 191-201; discussion 175. ISSN 1465-3125
- Kiliaridis, S.; Johansson, A.; Haraldson, T.; Omar, R. & Carlsson, G.E. (1995). Craniofacial morphology, occlusal traits, and bite force in persons with advanced occlusal tooth wear. *Am J Orthod Dentofacial Orthop*, Vol.107, No.3, pp. 286-292. ISSN 0889-5406
- Krejci, I.; Reich, T.; Bucher, W. & Lutz, F. (1994). [A new method for 3-dimensional wear measurement]. *Schweiz Monatsschr Zahnmed*, Vol.104, No.2, pp. 160-169. ISSN 1011-4203
- Kuijpers, M.A.; Kiliaridis, S.; Renkema, A.; Bronkhorst, E.M. & Kuijpers-Jagtman, A.M. (2009). Anterior tooth wear and retention type until 5 years after orthodontic treatment. *Acta Odontol Scand*, Vol.67, No.3, pp. 176-181. ISSN 1502-3850 (Electronic)
- Leifert, M.F.; Leifert, M.M.; Efstratiadis, S.S. & Cangialosi, T.J. (2009). Comparison of space analysis evaluations with digital models and plaster dental casts. *Am J Orthod Dentofacial Orthop*, Vol.136, No.1, pp. 16 e11-14; discussion 16. ISSN 1097-6752
- Macchi, A.; Carrafiello, G.; Cacciafesta, V. & Norcini, A. (2006). Three-dimensional digital modeling and setup. *Am J Orthod Dentofacial Orthop*, Vol.129, No.5, pp. 605-610. ISSN 1097-6752
- McCance, A.M.; Moss, J.P.; Fright, W.R.; Linney, A.D. & James, D.R. (1997). Three-dimensional analysis techniques--Part 2: Laser scanning: a quantitative three-dimensional soft-tissue analysis using a color-coding system. *Cleft Palate Craniofac J*, Vol.34, No.1, pp. 46-51. ISSN 1055-6656
- McDonagh, S.; Moss, J.P.; Goodwin, P. & Lee, R.T. (2001). A prospective optical surface scanning and cephalometric assessment of the effect of functional appliances on the soft tissues. *Eur J Orthod*, Vol.23, No.2, pp. 115-126. ISSN 0141-5387
- Milicic, A.; Gazi-Coklica, V. & Slaj, M. (1987). Dental attrition in preschool children. *Acta Stomatol Croat*, Vol.21, No.4, pp. 271-276. ISSN 0001-7019
- Miller, L.; Morris, D.O. & Berry, E. (2007). Visualizing three-dimensional facial soft tissue changes following orthognathic surgery. *Eur J Orthod*, Vol.29, No.1, pp. 14-20. ISSN 0141-5387
- Miller, R.J.; Kuo, E. & Choi, W. (2003). Validation of Align Technology's Treat III digital model superimposition tool and its case application. *Orthod Craniofac Res*, Vol.6 Suppl 1, pp. 143-149. ISSN 1601-6335
- Morris, D.O.; Illing, H.M. & Lee, R.T. (1998). A prospective evaluation of Bass, Bionator and Twin Block appliances. Part II--The soft tissues. *Eur J Orthod*, Vol.20, No.6, pp. 663-684. ISSN 0141-5387

- Moss, J.P. (2006). The use of three-dimensional imaging in orthodontics. *Eur J Orthod*, Vol.28, No.5, pp. 416-425. ISSN 0141-5387
- Moss, J.P.; Linney, A.D. & Lowey, M.N. (1995). The use of three-dimensional techniques in facial esthetics. *Semin Orthod*, Vol.1, No.2, pp. 94-104. ISSN 1073-8746
- Moss, J.P.; McCance, A.M.; Fright, W.R.; Linney, A.D. & James, D.R. (1994). A three-dimensional soft tissue analysis of fifteen patients with Class II, Division 1 malocclusions after bimaxillary surgery. *Am J Orthod Dentofacial Orthop*, Vol.105, No.5, pp. 430-437. ISSN 0889-5406
- Myrberg, N.E. & Warner, C.F. (1982). Indirect bonding technique. *J Clin Orthod*, Vol.16, No.4, pp. 269-272. ISSN 0022-3875
- Nagasaka, S.; Fujimura, T. & Segoshi, K. (2003). Development of a non-radiographic cephalometric system. *Eur J Orthod*, Vol.25, No.1, pp. 77-85. ISSN 0141-5387
- Orapix (2010). *3Txer 3D virtual treatment planner*. Orapix www.orapix.com.
- Ramjford, S.P. & Ash, M.M. (1983). *Occlusion*, W.B.Saunders, ISBN 978-0721655918, Philadelphia, USA
- Rangel, F.A.; Maal, T.J.; Berge, S.J.; van Vlijmen, O.J.; Plooi, J.M.; Schutyser, F. & Kuijpers-Jagtman, A.M. (2008). Integration of digital dental casts in 3-dimensional facial photographs. *Am J Orthod Dentofacial Orthop*, Vol.134, No.6, pp. 820-826. ISSN 1097-6752
- Ruf, S. & Pancherz, H. (1996). Frontal sinus development as an indicator for somatic maturity at puberty? *Am J Orthod Dentofacial Orthop*, Vol.110, No.5, pp. 476-482. ISSN 0889-5406
- Santoro, M.; Galkin, S.; Teredesai, M.; Nicolay, O.F. & Cangialosi, T.J. (2003). Comparison of measurements made on digital and plaster models. *American journal of orthodontics and dentofacial orthopedics*, Vol.124, No.1, pp. 101-105. ISSN 0889-5406
- Song, K.G. & Baek, S.H. (2009). Comparison of the accuracy of the three-dimensional virtual method and the conventional manual method for model surgery and intermediate wafer fabrication. *Oral Surg Oral Med Oral Pathol Oral Radiol Endod*, Vol.107, No.1, pp. 13-21. ISSN 1528-395X
- Stevens, D.R.; Flores-Mir, C.; Nebbe, B.; Raboud, D.W.; Heo, G. & Major, P.W. (2006). Validity, reliability, and reproducibility of plaster vs digital study models: comparison of peer assessment rating and Bolton analysis and their constituent measurements. *American journal of orthodontics and dentofacial orthopedics*, Vol.129, No.6, pp. 794-803. ISSN 0889-5406
- Weinberg, S.M.; Scott, N.M.; Neiswanger, K.; Brandon, C.A. & Marazita, M.L. (2004). Digital three-dimensional photogrammetry: evaluation of anthropometric precision and accuracy using a Genex 3D camera system. *Cleft Palate Craniofac J*, Vol.41, No.5, pp. 507-518. ISSN 1055-6656
- Zachrisson, B.U. & Brobakken, B.O. (1978). Clinical comparison of direct versus indirect bonding with different bracket types and adhesives. *Am J Orthod*, Vol.74, No.1, pp. 62-78. ISSN 0002-9416



Principles in Contemporary Orthodontics

Edited by Dr. Silvano Naretto

ISBN 978-953-307-687-4

Hard cover, 584 pages

Publisher InTech

Published online 25, November, 2011

Published in print edition November, 2011

Orthodontics is a fast developing science as well as the field of medicine in general. The attempt of this book is to propose new possibilities and new ways of thinking about Orthodontics beside the ones presented in established and outstanding publications available elsewhere. Some of the presented chapters transmit basic information, other clinical experiences and further offer even a window to the future. In the hands of the reader this book could provide an useful tool for the exploration of the application of information, knowledge and belief to some orthodontic topics and questions.

How to reference

In order to correctly reference this scholarly work, feel free to copy and paste the following:

Bong-Kuen Cha (2011). Clinical Application of Three-Dimensional Reverse Engineering Technology in Orthodontic Diagnosis, Principles in Contemporary Orthodontics, Dr. Silvano Naretto (Ed.), ISBN: 978-953-307-687-4, InTech, Available from: <http://www.intechopen.com/books/principles-in-contemporary-orthodontics/clinical-application-of-three-dimensional-reverse-engineering-technology-in-orthodontic-diagnosis>

INTECH
open science | open minds

InTech Europe

University Campus STeP Ri
Slavka Krautzeka 83/A
51000 Rijeka, Croatia
Phone: +385 (51) 770 447
Fax: +385 (51) 686 166
www.intechopen.com

InTech China

Unit 405, Office Block, Hotel Equatorial Shanghai
No.65, Yan An Road (West), Shanghai, 200040, China
中国上海市延安西路65号上海国际贵都大饭店办公楼405单元
Phone: +86-21-62489820
Fax: +86-21-62489821

© 2011 The Author(s). Licensee IntechOpen. This is an open access article distributed under the terms of the [Creative Commons Attribution 3.0 License](https://creativecommons.org/licenses/by/3.0/), which permits unrestricted use, distribution, and reproduction in any medium, provided the original work is properly cited.

IntechOpen

IntechOpen