

# We are IntechOpen, the world's leading publisher of Open Access books Built by scientists, for scientists

6,900

Open access books available

185,000

International authors and editors

200M

Downloads

Our authors are among the

154

Countries delivered to

TOP 1%

most cited scientists

12.2%

Contributors from top 500 universities



WEB OF SCIENCE™

Selection of our books indexed in the Book Citation Index  
in Web of Science™ Core Collection (BKCI)

Interested in publishing with us?  
Contact [book.department@intechopen.com](mailto:book.department@intechopen.com)

Numbers displayed above are based on latest data collected.  
For more information visit [www.intechopen.com](http://www.intechopen.com)



# **New Strategies for Class II Fixed Functional Orthodontics, Including MRI Diagnostics, Manual Functional Analysis and Physiotherapy**

Douglas Edward Toll, Nenad Popović and Nicole Drinkuth  
*Orthodontic Group Practice  
 Germany*

## **1. Introduction**

Frequently, Angle Class IIs display a retrognathic mandible rather than a prognathic maxilla [McNamara, Connelly & McBride, 1975<sup>1</sup>]. Since the mandible appears to be the primary cause, it is logical to focus on it when treatment options are discussed. Consequently, all major fixed and removable Class II correction appliances attempt to improve mandibular growth and position. Several types are available on the market: Fixed Functionals like the MARA (Mandibular Anterior Repositioning Appliance), the Herbst appliance and William Clark's Twin Block are, however, by far, more effective than removable appliances in more difficult cases and in cases with lacking or insufficient patient compliance. [O'Brien, Wright, Conboy et al., 2003<sup>2</sup>]

The primary difference between Class II/1 and Class II/2 is the angle of upper incisor inclination: In Class II/1s, the upper anteriors are proclined, creating a large sagittal step with the lingual, gingival part of the upper incisors holding the mandible posteriorly. This often causes enormous pressure on the TMJs and thus damage to the structures of the TMJ. In Class II/2s, the bite is usually very deep, and the upper incisors are retroclined, also producing a force vector that is directed distally, toward the TMJs. The bite in Class II/2s is not seldomly extremely deep, and the vertical height of the lower face is often reduced (brachycephalic growth).

A great help for optimal diagnostics and treatment planning in orthodontic patients, esp. in patients with TMD (Temporomandibular Disorder) symptoms, has been MRI (Magnetic Resonance Imaging). MFA (Manual Functional Analysis) has recently evolved in the Netherlands and Germany as an important complement to MRI scanning. It covers very well the functional aspects of TMD, because it is a thorough orthopaedic type of musculoskeletal examination. Although dynamic imaging has been developed to diagnose mandibular mobility and disc behaviour, the MFA is also still a valuable adjunct as a diagnostic tool. Combining the very important MRI with MFA, the clinician gains very important knowledge of the condition of the TMJs and if the condyles can be advanced or not. MRI scanning and MFA also are the decisive factors as to the type of manual therapy / physiotherapy that is indicated as complement to mechanical anterior mandibular advancement. The latter is crucial, because - without proper manual therapy -, it is much more difficult or even impossible to obtain satisfactory and stable treatment results.



In Class II patients, we often find severe TMJ degeneration in MRI scans and MFA [Toll, Popović & Drinkuth, 2010<sup>3</sup>]. This degree of condylar and disc degeneration and displacement is frequently not accompanied by the expected associated symptoms (craniofacial pain, muscular tenseness, dizziness, tinnitus, etc.). [45 years of empirical data from own practice<sup>4</sup>]

Fixed Functional orthodontic treatment in combination with flat build-ups on the last molars in the mandible can be used to unlock the bite, advance the condyles and give physiological TMJ decompression. Sometimes, sagittal (mesio-distal) stabilisation of the achieved results is necessary for a lifetime.

## **2. Magnetic Resonance Imaging (MRI) diagnostics and Manual Functional Analysis (MFA)**

In our practice, magnetic resonance imaging has been in use for over 14 years. Gradually, this method has evolved into the most significant method for the clinical diagnostics of temporomandibular pathologies. Our MRI scans comprise 7 to 9 different sequences, oriented parasagittally, paracoronally and transversally. The static sequences include 4 different bite positions – for which silicon bites are individually made. These bites dictate where the radiologists are to make the imaging position. In our practice, these silicone bites are made as follows: bite 0 (habitual occlusion, equals CO), bite A (CR, the most dorsally forced mandibular position), bite B (slightly overcorrected desired anterior mandibular position), and bite C (the most anterior mandibular position possible, with mouth opened approximately 10 mms). Bite B is the clinically most significant one: It tells us, if the patient's discs can be reduced, as the lower jaw is advanced to a slightly overcorrected, physiological position. A detailed MRI prescription is shown in fig. 1.

The MFA examination is a very thorough way to assess the condition of the upper craniofacial system. It begins with a good medical anamnesis, including especially a report on pain sensations, limited mobility, altered visual facial aspect (asymmetry), neurological problems (paraesthesias, paralyses, dystonias) and pre-existing conditions like rheumatism. The MFA is actually an orthopaedic examination, designed to test the components of the craniomandibular system in terms of condition, tightness and degree of mobility. This includes muscles, cartilage, bone and ligaments. The presence or absence of pain and its severity during specific manipulations (movement, palpation, and auscultation) is recorded. One advantage of the MFA is that conditions like disc adhesion, muscular problems (tightness, myogeloses) or tightness of the joint capsule can be diagnosed directly and without great difficulty.

## **3. Physiotherapy**

We feel, the professional field “physiotherapy” comprises a number of different techniques and disciplines, some of which are used interchangeably and synonymously with the term “physiotherapy”. Some disciplines that come under physiotherapy are:

- Manual Therapy
- Osteopathy
- Cranio-Sacral Therapy
- Chiropractic

Sometimes, the above (Osteopathy, Cranio-Sacral Therapy, Chiropractic) are listed as specialised discipline of manual therapy and manual therapy as a field in medicine (manual medicine) – as opposed to physiotherapy, which is often a trained profession.

- Physiotherapy/ professional training
  - Manual Therapy/ medicine
  - Osteopathy
  - Cranio-Sacral Therapy
  - Chiropractic

Manual therapy or physiotherapy should be used in gnathology to treat muscular imbalances and other functional disorders of the musculoskeletal system (including the ligaments). One is able to treat, e.g., undesirably hypertonic retractor muscles with intramuscular Botulinum A injections, mostly in severe cases. In less severe cases, primarily physiotherapy can be used to strengthen selected hypotonic muscles or muscle groups and loosen tight muscles, ligaments and/ or joint capsules.

Again, usually, physiotherapy is the main treatment to strengthen the mandibular protractors and to detonise the retractors, to give them normal strength. The TMJ capsules and ligaments sometimes are also too tight and should be treated with physiotherapy. Build-ups are necessary to permanently unlock the bite, so the desired mandibular positional change can be carried out. Physiotherapy, it has become obvious, is very helpful in assisting to unlock the bite.

#### **4. Orthognathic-orthodontic treatment for class IIs and class IIIs**

Previously, we have surgically treated many of our more severe Class II patients with and without TMJ problems. The maxillo-mandibular relation and the sagittal/ transverse/ vertical dimensions were corrected into Class I and neutral occlusion. Our task as orthodontists was, then, to correct the patient's occlusion into a Class I dental occlusion and to stabilise the obtained results. Sometimes, Class II correction involved the use of some type of Class II elastics and/or headgears to maintain the Class I dental occlusion.

Today, however, the number of Class II patients in our practice undergoing surgery has decreased greatly, thanks to the success of Class II Fixed Functional correction. Orthognathic surgery, in turn, is playing an increasingly important role for surgical Class I and Class III correction.

#### **5. Our recommended fixed functional treatment of Class II malocclusions**

Functional orthodontics is not a new discovery. In Germany, this kind of orthodontics has been in use for centuries. There are many functional orthodontic appliances available on the market. However, the fact remains, that they are removable and therefore depend upon the patient's compliance.

In easy patients with healthy TMJs and good patient compliance, however, removable appliances usually work well. If cases are difficult and require long hours of functional correction, it is easier, quicker, and more stable to give them a fixed functional appliance.

What makes a "difficult" case?

1. More than 3 mm sagittal correction
2. TMJ pathologies, such as disc and/or condylar degeneration and displacement
3. Positive findings in an MFA examination in dorsally, cranially or laterally forced condylar positions



4. Decreased mobility of the mandible in one or more directions

An effective way of tackling the problem is to combine European functional orthodontics with fixed appliances as were primarily developed in the United States. This achievement was actually done by Emil Herbst, in the beginning of the 20<sup>th</sup> century in Germany: the Herbst appliance. Several appliances have followed in its wake since its important rediscovery in the 1970s by Professors Pancherz and Ruf (Gießen/Germany). One of them is the MARA. In 1991, Dr. Toll introduced Dr. James Eckhart to the MARA. Dr. Eckhart had been using the Herbst appliance. First, two different concepts for the MARA were developed: a bite-jumper with an almost 90° elbow used mostly in the USA, and an angled German/ European version that incorporates the patient's condylar path and is sometimes also used in the USA.

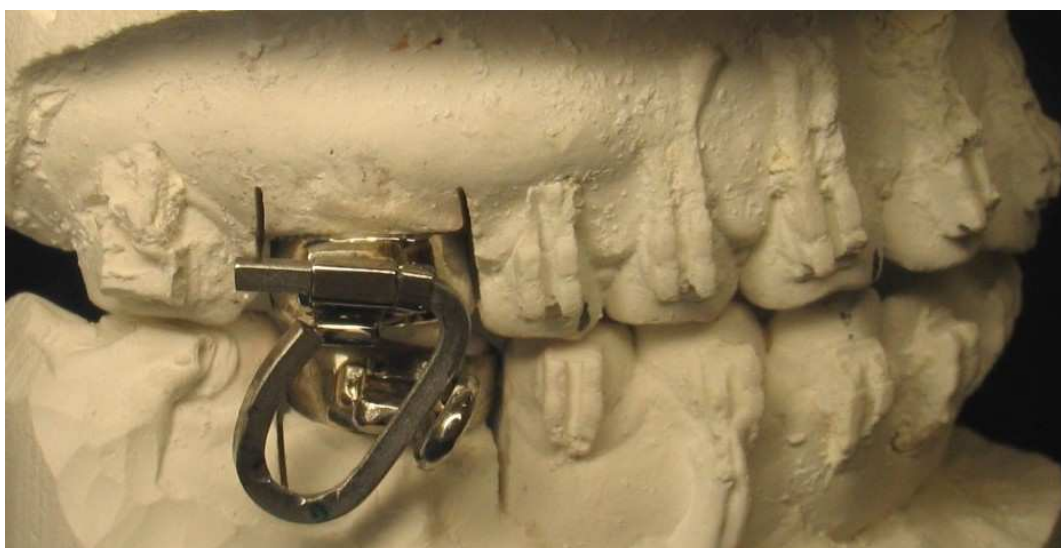

Fig. 2. Right lateral view of the Mandibular Anterior Repositioning Appliance, mounted on a plaster model.

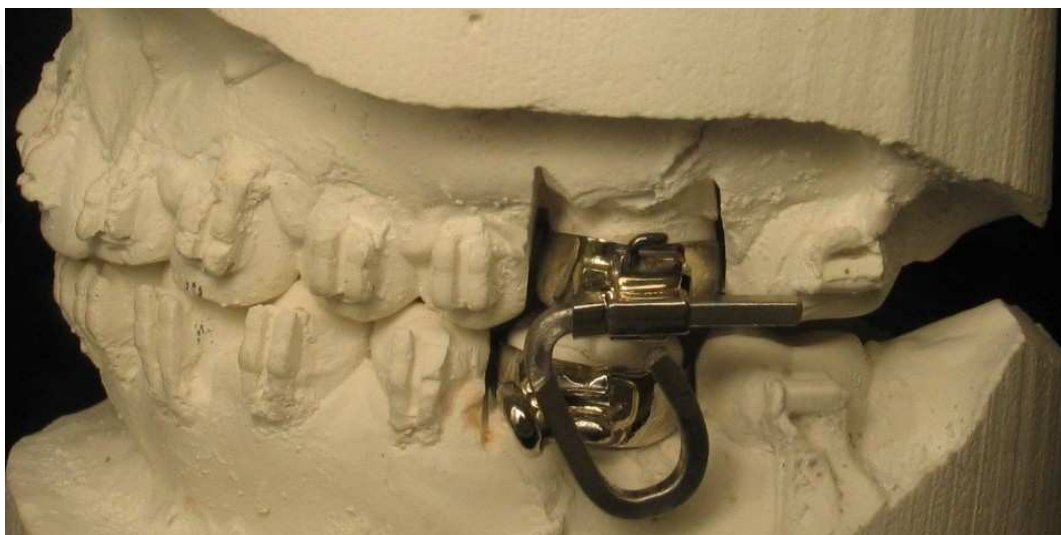


Fig. 3. Left lateral view of the Mandibular anterior Repositioning Appliance, mounted on a plaster model.

The MARA is usually cemented on the upper and lower 6s. The part designed for the lower jaw consists, among other, of special crowns or “beefy” bands, i.e. thicker bands, because the normal bands sometimes may break, unless soldered or welded correctly on the band without any band-weakening potential. Together, in cooperation with AOA (Allesee Orthodontic Appliances), Dr. Toll and Dr. Eckhart developed the first serial versions of that appliance in 1995. Fig. 2 and 3 show a lateral view of the MARA, mounted on a plaster model. It was decided by AOA that the version by Dr. Eckhart was preferable, so there is no danger of bringing the lower dental arch too far forward. For some time, however, important improvements have been made to the MARA, including the redesign that was mentioned and variations with different attachments and differently shaped elbows. The new design of the MARA usually incorporates a buccal shield on the lower part of the MARA, so the lower arm, fixed to the buccal, does not bother the cheek. This happens rarely, but it is a possibility in patients with strong buccal muscles [Allan-Noble, 2002<sup>5</sup>]. Actually, this effect is beneficial, because most patients with narrow jaws, i.e. transverse compression, need to have the muscular tone normalised. Hypertonic buccal muscles prevent stable transverse expansion. In our practice, maxillary lip-bumpers are a very good first phase treatment modality to normalise muscular tone, so the cheeks do not become irritated. In addition, a lip-bumper as a modified Fränkel appliance helps expand the maxilla, which is almost always desirable in a Class II case. With the MARA, as other Fixed Functionals, the usual expansion of the maxilla is necessary. In younger patients, this can be done first, followed by Class II correction with the MARA. When orthodontic treatment achieves transverse and sagittal overcorrection of the maxilla of almost one millimetre, the case will remain stable.

In the MARA, it is easy to take out the upper removable leg while leaving the rest of the appliance in, in order to check that the patients do not have an unstable anterior overcorrection. Another method is to make the upper removable leg much smaller to make sure the case stays stable before removing the appliance totally.

The MARA is used to advance the mandible, to encourage condylar growth enhancement in children and adolescents, and to stabilise the desired anterior repositioning. Even in adults, condyles and fossae usually show remodelling, bringing further functional improvement. It appears that there are no MARA cases as of today that have shown any occurrence of TMJ problems under MARA treatment and its condylar advancement. The opposite is the case: The MARA usually decreases or eliminates the problem (such as tinnitus, clicking, etc.). A study on 58 patients conducted in our practice shows that the TMD symptoms tend to improve greatly under MARA therapy [Toll, Popović & Drinkuth, 2010<sup>3</sup>]. A successful disc recapture achieved by anterior repositioning of the mandible is shown in fig. 4.

In conjunction with the MARA, other orthodontic appliances can be worn like brackets, Class II elastics, lip bumpers, surgical or non-surgical suture splits for the maxilla (rapid palatal expander), etc. The MARA, if used alone, is usually worn with a standard lower lingual arch and an upper palatal bar or expander.

It is definitely better to use the vertical leg in the upper jaw in cases where it is undesirable to advance the lower anterior teeth. The reason for this is: With the vertical version, the patients do not have a propulsion effect on the lower teeth, as with all other Functionals. The Class II correction is done by neuromuscular reprogramming, to advance the mandible and, thus maintaining the condyles in an advanced position. Another advantage of the MARA is that it does not create a permanent connection between maxilla and mandible, but allows the mandible to “float” freely. Also, it prevents the patients from biting in Class II:

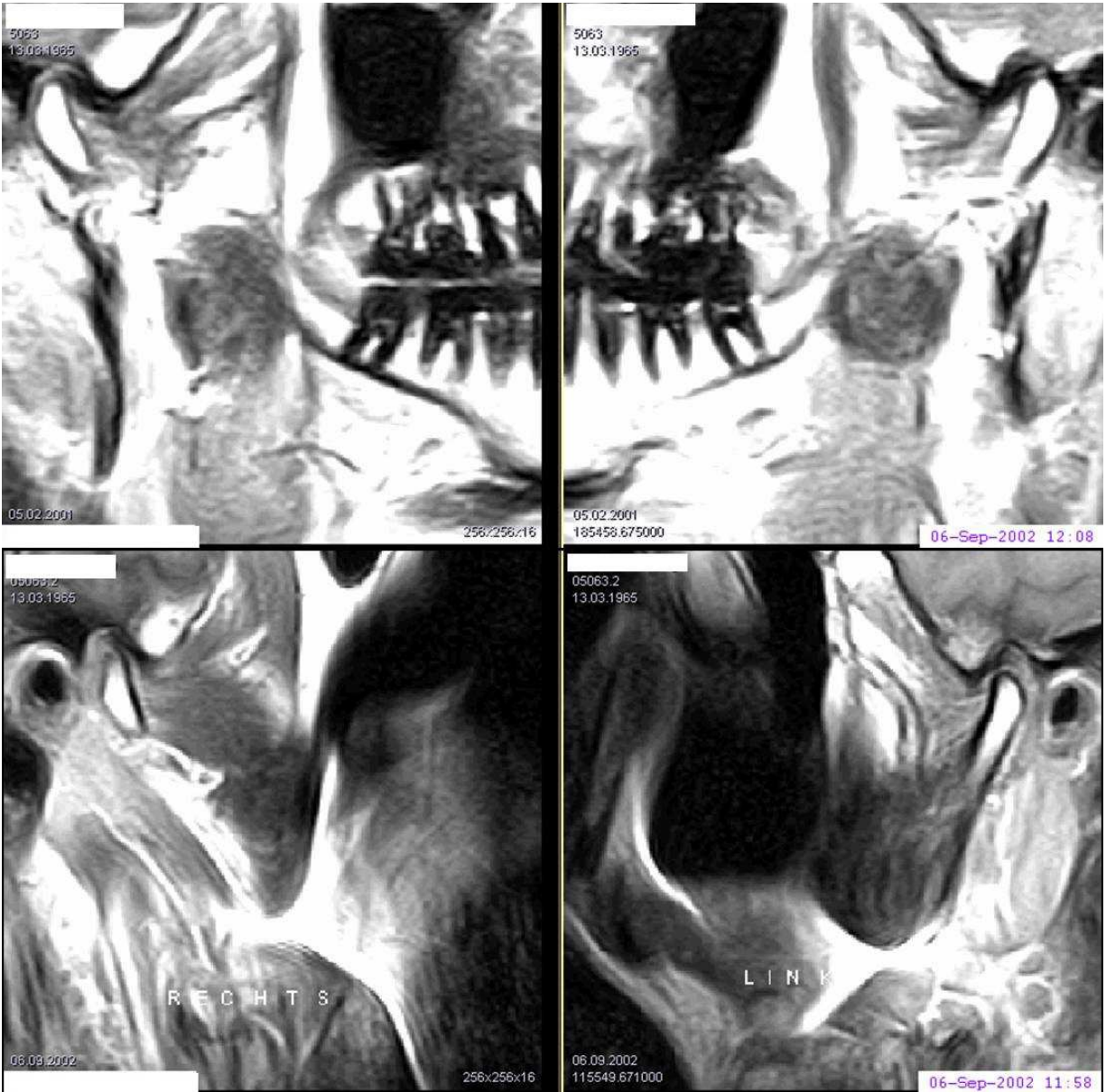


Fig. 4. Pre (top)- and post-treatment (bottom) TMJ MRI showing an anteriorly prolapsed disc pre-, and a recaptured disc post treatment.

When the patients try to bite retrally, the lower arm collides with the upper elbow. This prevents the jaw from closing, forcing the patients to bite anteriorly, in Class I, in order to be able to close the jaw. Thus, the mandibular advancement is solely a neuromuscular one, not



one enforced by propulsion mechanics. There is a proprioceptive feedback loop between masticatory muscular activity and mandibular/ occlusal position. When the mandible stays anteriorly, muscular activity and reflexive pathways adapt. The time it takes the muscles and ligaments to adapt to the new functional position is not easy to predict. Sometimes, the patients adapt within 2 -3 months, esp. if they start with a dorso-cranial condylar position. In contrast, the adaption sometimes may take over a year, particularly in patients with unhealthy TMJs, which can be demonstrated well in MRIs. With any type of appliance, it is important to retain the patients in this advanced position and to test them constantly with a so-called speech-centric test, with the upper arms removed and in which the clinician watches the patients speak as they sit in the chair. To have the patients reclined a little bit is even a more thorough test to see if, despite what gravity does to the position of the mandible, it stays in the anterior position. Because the MARA has no fixed connection from the maxilla to the mandible, it does not ever interfere with speech and with chewing and therefore is a very comfortable appliance.

## 6. Our treatment concept

The “entrapped mandible syndrome” is a combination of deep bite, retruded mandible and undesirably steep upper incisor angulation. This combination of factors is most often found in Class II/2 patients. To treat this “entrapped mandible syndrome” effectively and to stop present TMJ degeneration from growing worse, it is important to 1) eliminate the deep bite. This gives the mandible the “freedom” to advance on its own. This ability strongly depends upon how tight the joint capsules and the ligaments are. We call this “unlocking the bite”. 2) Once “unlocked”, it is crucial to allow the mandible to advance to its physiological position by correcting incisor angulation and by using a Fixed Functional, like the MARA.

This unlocking of the bite is done with temporary crowns on the 6s or sometimes even the 7s. Additionally, flat composite build-ups can be cemented on the other molars to totally eliminate any bucco-lingual or antero-posterior interdigitation, freeing the mandible.

Not only do we need to unlock the bite with build-ups, as described above. It is also very important that, in deep bites, simultaneous intrusion of the upper and lower anteriors is done, so the “entrapped mandible” is totally “free”. It appears that, at no time during the entire treatment, should the incisors and cuspids have any contact. The mandible must be totally free to grow and advance optimally. An important recommendation is that, during the night, light up-and-down elastics should be worn from the upper to the lower 6s, so the mandible cannot open wide and propulsion is lost. The MARA also works well on Class II open bites. It is important, here, that the patients learn to be able to close their lips. If any complications exist in the upper respiratory passage they need to be eliminated (enlarged tonsils, conchae, or adenoids, etc.). This means, of course, that mouth breathing should be treated in all orthodontic patients simultaneously during orthodontic correction, i.e. open bite patients should also be treated with the MARA, but one must be sure to eliminate the cause of the open bite simultaneously during treatment. Mouth breathing increases the amount of necessary correction and decreases stability. At the end of treatment, in our view, it is important to have delayed front tooth disclusion and cuspid guidance, so that the mandible can settle and stabilise in its new position.

When orthodontic treatment is finished, including very slight overcorrection, it is better to continue treating with the MARA for a slightly longer period of time than to try to prevent a relapse in a Class II direction with Class II elastics. During this time, the build-ups should remain in the mouth, so there is no cuspal interference. Class II elastics cause undesirable anterior tipping. Holding the Class II correction with the MARA, which is not visible, is the preferable way of making sure that the case remains stable. Mini-screws in the maxillary cuspid area to miniscrews in the mandibular molar area are another way of holding the Class II correction without undesirable tooth tipping, such as the lower arch slipping anteriorly.

A hypomochlion, i.e. a pivot in the 7s region, produces a TMJ decompression. Pivots on the 6s on teenagers do not cause TMJ decompression. In younger children, when the 7s have not erupted yet, the pivots can be inserted on the 6s, which does give some decompression. As soon as the 7s erupt, however, they should be removed from the 6s and put on the 7s.

## 7. Summary

Fixed Functionals are always indicated in difficult Class II cases. It is important to do the previously mentioned tests or examinations to see if the case is in any way difficult or easy. If the first is the case, it is strongly recommendable to use a Fixed Functional. The bite must be jumped and under no condition allowed to relapse distally during treatment. The cases should be monitored in the retention phase, so that the problem does not return. It is our opinion that, in Fixed Functionals, this is the only way to be assured that the Class II correction can be stably maintained.

Any of the removable functional appliances work well in patients with mild to moderate forms of the Class II malocclusion and/ or excellent patient compliance. Here, it is perhaps not necessary to use Fixed Functionals, as soon as the TMJs are proven (with MRI and MFA) to be healthy. In such a case, we usually use a positioner activator in our practice, because it is the only functional appliance that provides 4-dimensional control of the teeth.

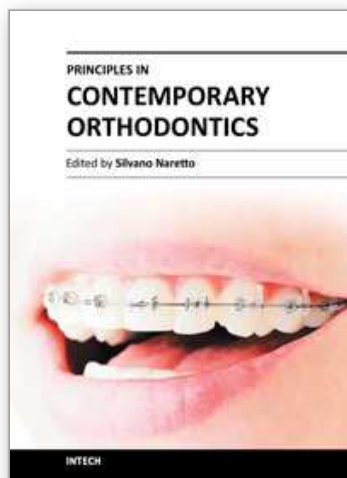
## 8. References

- [1] McNamara JA, Connelly TG & McBride, MC (1975) Histological Studies of Temporomandibular Joint Adaptations. In: Determinants of Mandibular Form and Growth. J.A. McNamara, Monography No. 4. Craniofacial growth Series, Ed. Ann Arbor Center for Human Growth and Development: 209-227
- [2] O'Brien K, Wright J, Conboy F (2003) Effectiveness of treatment for class II malocclusion with the herbst or twin-block appliances: a randomized, controlled trial. *AJO-DO* (124)2: 128-137
- [3] Toll DE, Popović N & Drinkuth N (2010) The Use of MRI Diagnostics in Orthognathic Surgery - Prevalence of TMJ Pathologies in Angle Class I, II, III Patients. *J Orof Orthop* (71)1: 68-80
- [4] 45 years of empirical data from own practice

- [5] Allan-Noble PS (2002) Clinical Management of the MARA – A Manual for Orthodontists and Staff. PDF-file by Allesee Orthodontic Appliances, version 02/2002 (URL <http://www.aolab.com/index/cms-filesystem-action?file=AOALab-Education-PDF/clinicalmanagementmara2002-manuals.pdf>)

IntechOpen

IntechOpen



## **Principles in Contemporary Orthodontics**

Edited by Dr. Silvano Naretto

ISBN 978-953-307-687-4

Hard cover, 584 pages

**Publisher** InTech

**Published online** 25, November, 2011

**Published in print edition** November, 2011

Orthodontics is a fast developing science as well as the field of medicine in general. The attempt of this book is to propose new possibilities and new ways of thinking about Orthodontics beside the ones presented in established and outstanding publications available elsewhere. Some of the presented chapters transmit basic information, other clinical experiences and further offer even a window to the future. In the hands of the reader this book could provide an useful tool for the exploration of the application of information, knowledge and belief to some orthodontic topics and questions.

### **How to reference**

In order to correctly reference this scholarly work, feel free to copy and paste the following:

Douglas Edward Toll, Nenad Popović and Nicole Drinkuth (2011). New Strategies for Class II Fixed Functional Orthodontics, Including MRI Diagnostics, Manual Functional Analysis and Physiotherapy, Principles in Contemporary Orthodontics, Dr. Silvano Naretto (Ed.), ISBN: 978-953-307-687-4, InTech, Available from: <http://www.intechopen.com/books/principles-in-contemporary-orthodontics/new-strategies-for-class-ii-fixed-functional-orthodontics-including-mri-diagnostics-manual-functiona>

**INTECH**  
open science | open minds

### **InTech Europe**

University Campus STeP Ri  
Slavka Krautzeka 83/A  
51000 Rijeka, Croatia  
Phone: +385 (51) 770 447  
Fax: +385 (51) 686 166  
[www.intechopen.com](http://www.intechopen.com)

### **InTech China**

Unit 405, Office Block, Hotel Equatorial Shanghai  
No.65, Yan An Road (West), Shanghai, 200040, China  
中国上海市延安西路65号上海国际贵都大饭店办公楼405单元  
Phone: +86-21-62489820  
Fax: +86-21-62489821



© 2011 The Author(s). Licensee IntechOpen. This is an open access article distributed under the terms of the [Creative Commons Attribution 3.0 License](https://creativecommons.org/licenses/by/3.0/), which permits unrestricted use, distribution, and reproduction in any medium, provided the original work is properly cited.

IntechOpen

IntechOpen