

We are IntechOpen, the world's leading publisher of Open Access books Built by scientists, for scientists

6,900

Open access books available

186,000

International authors and editors

200M

Downloads

Our authors are among the

154

Countries delivered to

TOP 1%

most cited scientists

12.2%

Contributors from top 500 universities



WEB OF SCIENCE™

Selection of our books indexed in the Book Citation Index
in Web of Science™ Core Collection (BKCI)

Interested in publishing with us?
Contact book.department@intechopen.com

Numbers displayed above are based on latest data collected.
For more information visit www.intechopen.com



Sagittal Skeletal and Occlusal Changes of Class II, Division 1 Postadolescent Cases in the Herbst and Activator Therapy

Nenad Nedeljkovic

*Clinic of Orthodontics, School of Dentistry, University of Belgrade
Serbia*

1. Introduction

Class II malocclusions are common orthodontic irregularities (they account for 27% of all orthodontic irregularities) and they are considered a major reason for consulting an orthodontist. The positive outcome of Class II malocclusion treatment has some significant advantages: the prevention of traumatic injuries of upper incisors associated with large overjet and hard palate injuries with lower incisors, prevention of trauma of temporomandibular joints resulting from excessive load during the performance of orofacial functions, prevention of the development of dysfunctions (breathing, speech...) and psycho-social adaptation for children during the important process of personality development.

In the treatment of skeletal Class II malocclusions, the objective is often to stimulate sagittal mandibular growth since the sagittal mandibular deficiency is the most common cause of this orthodontic irregularity. An appliance for affecting mandibular position and growth was first designed in 1877. It was introduced by Norman W. Kingsley and this treatment method was called "Jumping the bite" (Pancherz, 2008). This term denotes a treatment with an orthodontic appliance for the direction of bite mesially, advancement of the mandible. The appliance comprised of an upper plate furnished with an inclined plane that held the lower incisors and forced the mandible anteriorly.

The principle of bite jumping has led to the development of the different removable functional appliances that we use today such as the Activator by Andersen and Häupl, bionator according to Balters, Fränkel appliance etc. (Graber et al., 1997). The effect of the activator on mandibular growth has been a subject of debate for many years (Bjork, 1951; Korkhaus, 1960; Harvold & Vargervik, 1971; Ahlgren & Laurin, 1976, Pancherz, 1979, 1984; Wieslander L & Lagerstrom, 1979; Luder, 1982; Jacobsson & Paulin, 1990). Some researchers claim that mandibular condylar growth can be stimulated by removable functional appliances treatment while others state that the changes in the occlusion are a result of dentoalveolar remodeling processes. This disagreement between the scientists is mainly due to the difficulties in the evaluation of treatment results as the activator, like all other removable functional appliances, has several disadvantages: 1) the appliance is mostly used only part of the day. This implies that in certain individuals the threshold for condylar growth adaptation to forward displacement of the mandible will never be reached. 2)

Patient compliance can also present a moot point. In case of undetected insufficient appliance wear, the interpretation of the treatment outcome could be biased. 3) Treatment time is relatively long (over 2 years) and often there is no suitable control group of untreated patients. This is the reason for arising difficulties to differentiate between physiological growth changes and changes induced by treatment (Pancherz, 2008).

With the modification of dentofacial growth direction, alongside with dentoalveolar harmonization of the occlusion, the usage of functional orthodontic appliances can provide a possibility to change or prevent morphogenetic abnormalities (Graber et al., 1997; Harvold & Vargervik, 1971). Optimal timing, i.e., the age of patients for treatment with removable functional appliances is the period of adolescence or period just before the pubertal growth spurt. After this period, the growth progresses slowly until adulthood, when it continues but in smaller amount. This period of postadolescence (after pubertal peak of growth) which chronologically lasts several years, is very important in functional orthodontics. This age of patients with Class II irregularities is considered to be very respectable, aesthetically and psychologically as well as functionally, since the majority of patients tend to consult an orthodontist during this period for aesthetic reasons. An orthodontist has several possible treatment solutions at his disposal: removable and fixed functional appliances treatment, camouflage orthodontics and orthognathic surgery. Surgery with previous orthodontic preparation gives satisfactory results, however, patients should wait until the end of growth, and commonly, they refuse this type of intervention. The camouflage orthodontics of Class II, Division 1 malocclusion includes the reduction of number of teeth in order to accomplish normal occlusion with questionable skeletal-soft tissue results at the end of treatment. As regards removable functional appliances, we cannot adhere to the terms stimulation or redirection of growth at this age, but we will mainly speak about dentoalveolar effects, taking into account a very important fact – patient compliance. The similar problem appears in fixed multibracket appliance therapy with class II intermaxillary elastics.

The purpose of fixed functional appliances is to overcome the shortcomings of removable functional appliances. In recent years, functional appliances are more frequently divided into fixed and removable appliances. The Herbst appliance is one of the most used fixed appliances in treatment of Class II malocclusions that is effective even after the period of adolescence.

Taking into account age and growth development, the dominant current concept of Class II treatment is: 1. Growth adaptation in children and adolescents, 2. Camouflage orthodontics in postadolescents and 3. Surgical correction in adults.

However, when considering the fact that skeleto-facial growth continues many years after the cessation of body height growth and that the TMJ in adults is capable of remodeling, it seems logical to revise the above treatment concept. Therefore, with respect to age and growth development, the following modified new concept for the treatment of Class II irregularities is proposed (Pancherz & Ruf, 2000): 1. Growth adaptation in children, adolescents, postadolescents and young adults, 2. Camouflage orthodontics in older adults and 3. Surgical correction in older adults.

The aim of investigation was to establish the sagittal skeletal, dentoalveolar and occlusal changes that occurring during the Herbst treatment of patients with Class II/1 malocclusion in the late puberty, and to compare them with those that occurred during the Activator treatment.

2. Material and method

The sample for this study comprised 50 patients with skeletal Class II, division 1 malocclusion (treated at the Clinic of Orthodontics, School of Dentistry, University of Belgrade), of both sexes, aged 14 – 17 years. The previous careful functional analysis eliminated the possibility of functional distal occlusion. The cases with minimal ANB angle of 5.5° and minimal overjet of 6.5mm were enrolled in this study. The minimal age of the patients was 14 years, which provided the basis for the assumption that they had passed maximal pubertal growth, and thus, the optimal period for functional therapy. This was confirmed by the assessment of skeletal maturity (Fig 3.1), so the sample comprised postadolescents and distribution according to sex was not performed.

The patients were divided into two groups: 1. Herbst treatment group (25 patients treated with the Herbst appliance) and 2. Activator treatment group (25 patients treated with the Activator appliance). The Herbst group consisted of 11 male and 14 female patients, aged 14 – 17 years at the beginning of treatment. The Activator group consisted of 13 male and 12 female patients, aged 14 – 16 years. After the treatment plan has been prepared, the patients in the Activator group, like those in the Herbst group, were first offered the Herbst therapy. The Activator patients refused this type of treatment mainly for reasons related to comfort or financial reasons. For similar reasons, they denied alternative solutions of camouflage therapy or preparation for orthognathic surgery, which again suggested the use of fixed multibracket orthodontic appliances. Finally, they accepted the therapy option using the Activator, with detailed explanation of the treatment and possible treatment effects related to their age. All of the Class II, division 1 patients in the Herbst group were treated successfully (Class I molar relationship, normal overjet and overbite) at the end of treatment. In the Activator group, most of the patients were treated without complete achievement. Success at the end of treatment has observed in 5 (20%) patients only. Six patients in the Activator group switched the group (they accepted the Herbst appliance treatment), mostly because they were not satisfied with the course of the Activator treatment and its progress. Other patients without desirable results continued with camouflage orthodontic treatment and multibracket appliance.

The therapy with the Herbst appliance and therapy effects are considered as combined, because the Herbst appliance is used in the combination with multibracket appliance. The Herbst appliance was removed after 6-8 months and then multibracket fixed appliance was used so the mean overall treatment time was 17.5 months.

The Activator therapy lasted 12-25 months depending on the amount of progress observed during control visits. The patients' compliance was not monitored. Both subject groups were longitudinally monitored pre- and post treatment. At the start of treatment, the age of the Herbst patients approximately matched the age of the Activator patients. Pretreatment and post treatment study models, orthopantomographic images and standard profile cephalograms were obtained for each patient. The Ethical committee of the School of Dentistry in Belgrade approved the study, pointing out that the patients and their parents should sign the consent to the entire procedure related to the therapy. Since the examinations were conducted before and after treatment, both groups were additionally divided into two subgroups: pretreatment Herbst and pretreatment Activator group (before the treatment) and post treatment Herbst and post treatment Activator group (after the treatment).

2.1 Appliance characteristics
2.1.1 The Herbst appliance

The first phase in the usage of this appliance in treatment is obtaining the construction bite in incisal relationship, with careful attention to the middle of the jaws.

The Herbst appliance used in this study was type 1, manufactured in the German company Dentaaurum (Fig. 1.1 – 1.6). The Herbst appliance can be compared to an artificial joint working between the maxilla and mandible. A bilateral telescope mechanism attached to orthodontic bands of the Herbst appliance keeps the mandible in an anterior jumped position (Fig. 1.5 and Fig. 1.6). Each telescope mechanism consists of a tube, a plunger, two pivots and two screws, which enable the telescoping parts to make additional lateral movements over the pivots and prevent the telescoping parts from slipping of the pivots (Fig. 1.1).

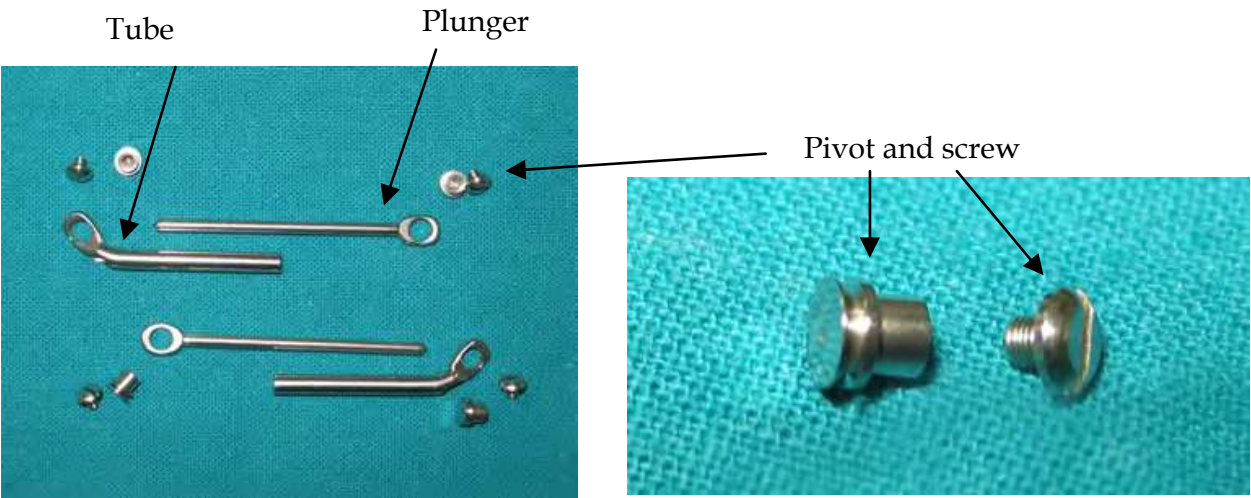


Fig. 1.1. Parts of the Herbst appliance: tube, plunger, pivot and screw.

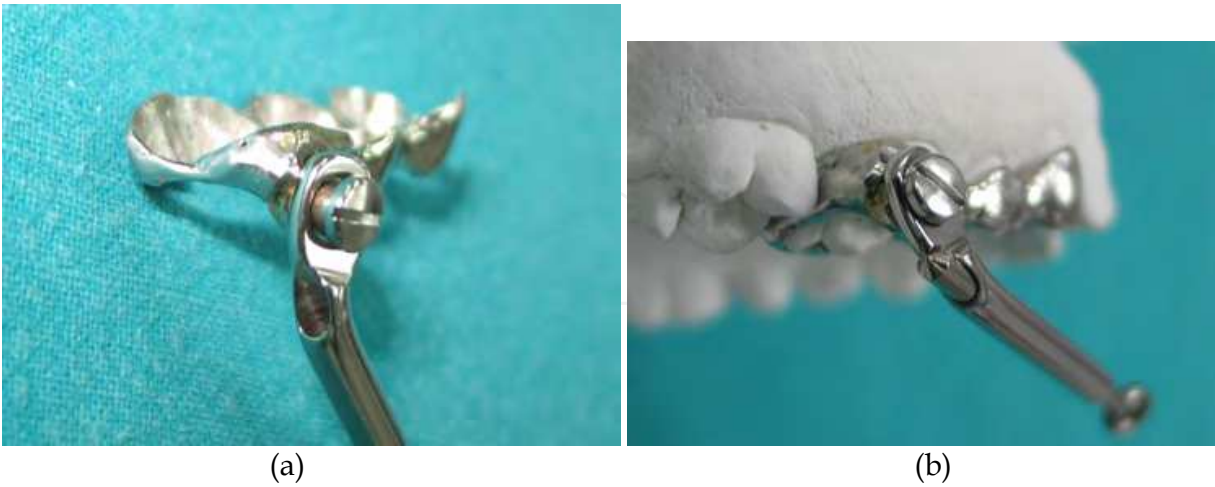


Fig. 1.2. a) fixing the tube on the pivot using the screw, b) the plunger in the tube of the Herbst appliance.

The pivot for the tube is usually soldered to the maxillary first molar band and the pivot for the plunger to the mandibular first premolar band (Figures 1.2, 1.3 and 1.4). The length of the tube determines the amount of sagittal activation, i.e. bite jumping. The mandible is

usually retained in an incisal edge-to-edge position, which is determined by the construction bite (Fig. 1.5).

A large interpivot distance prevents the plunger from slipping out of the tube when the mouth is wide open. Therefore, the upper pivot should be placed distally on the molar band and the lower pivot mesially on the premolar band (Fig. 1.5). The length of the plunger should be kept at a maximum in order to prevent it from disengaging from the tube.

The entire system is held on the splints of the Herbst appliance in the upper and lower jaw. The splints are cemented to the teeth and can be prepared in two ways (both types of splints are used in the study):

1. The cast splint Herbst appliance manufactured on double study models by casting it from CoCrMo alloy, the procedure similar to the construction of prosthetic denture with metal framework. It was constructed in the technical dental laboratory of the Clinic for Prosthodontics, School of Dentistry in Belgrade. In the upper jaw, the splint engaged both premolars and permanent first molars, and it is, basically, constructed separately for right and left side. In the lower jaw, because of the greater anchorage required, the splint incorporated the premolars and permanent first molars interconnected with a lingual arch wire behind the lower front teeth (Fig. 1.3.a and Fig. 1.4).

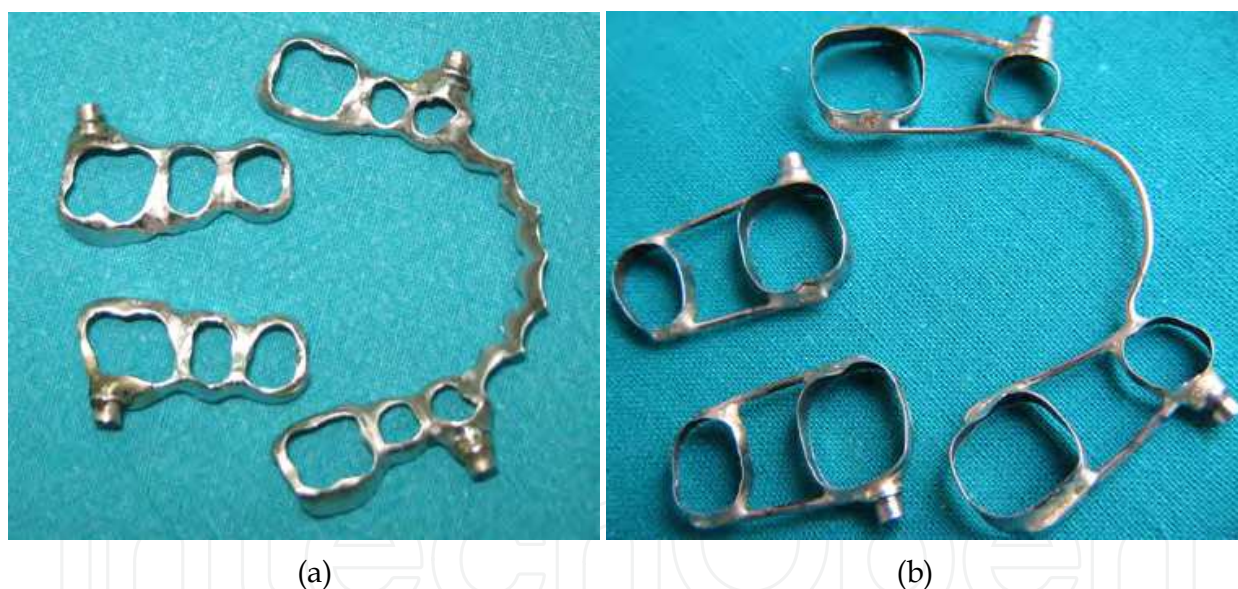
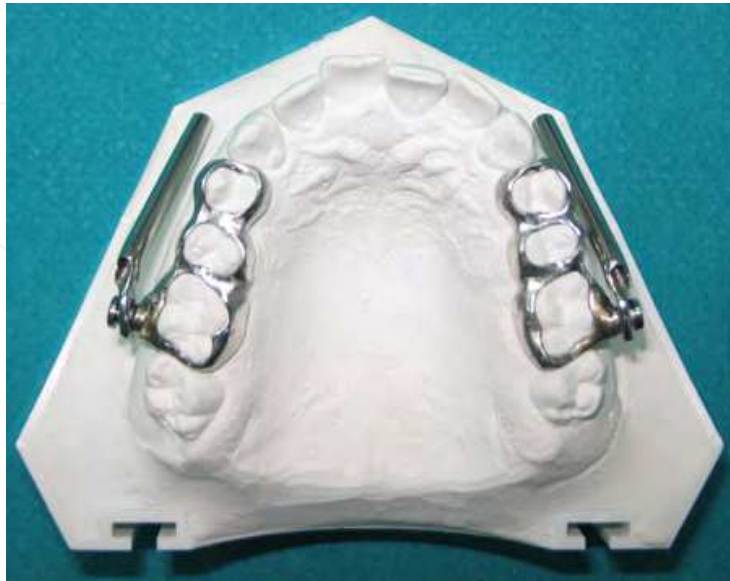
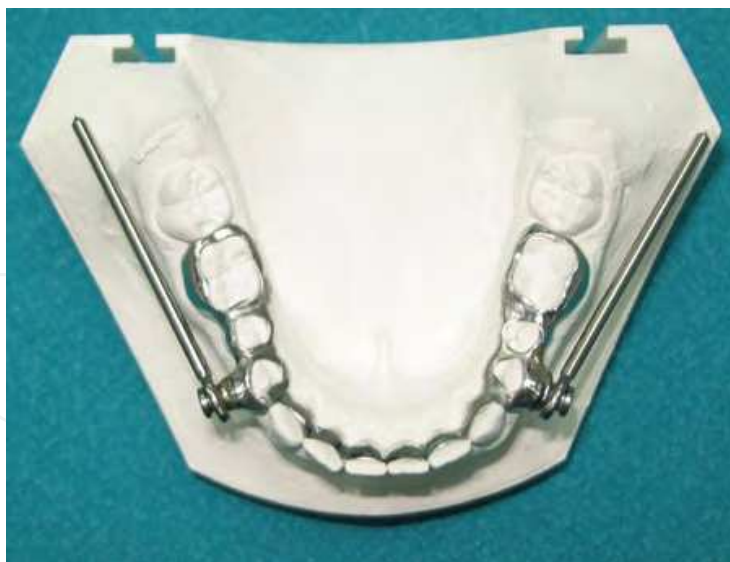Fig. 1.3. a) cast splint of the Herbst appliance, b) standard banded splint of the Herbst appliance.

2. The banded Herbst appliance, constructed on study models; first, the adjacent teeth that will not be banded are etched. Then, the bands for the first premolars and permanent first molars in both jaws are chosen and adjusted. In the upper dental arch, the splint is paired and reinforced with 1.0-1.2 mm wire on the vestibular and palatal side. The reinforcements are first punctured and then soldered. The process is similar in the lower dental arch, except that on the lingual side, a lingual arch is modeled from wire of the same diameter, which extends from the permanent first molar on one side to the same tooth on the other side, behind the lingual surfaces of the front teeth (Fig. 1.3b).



a)



b)

Fig. 1.4. The Herbst appliance a) on the upper and b) lower study model.

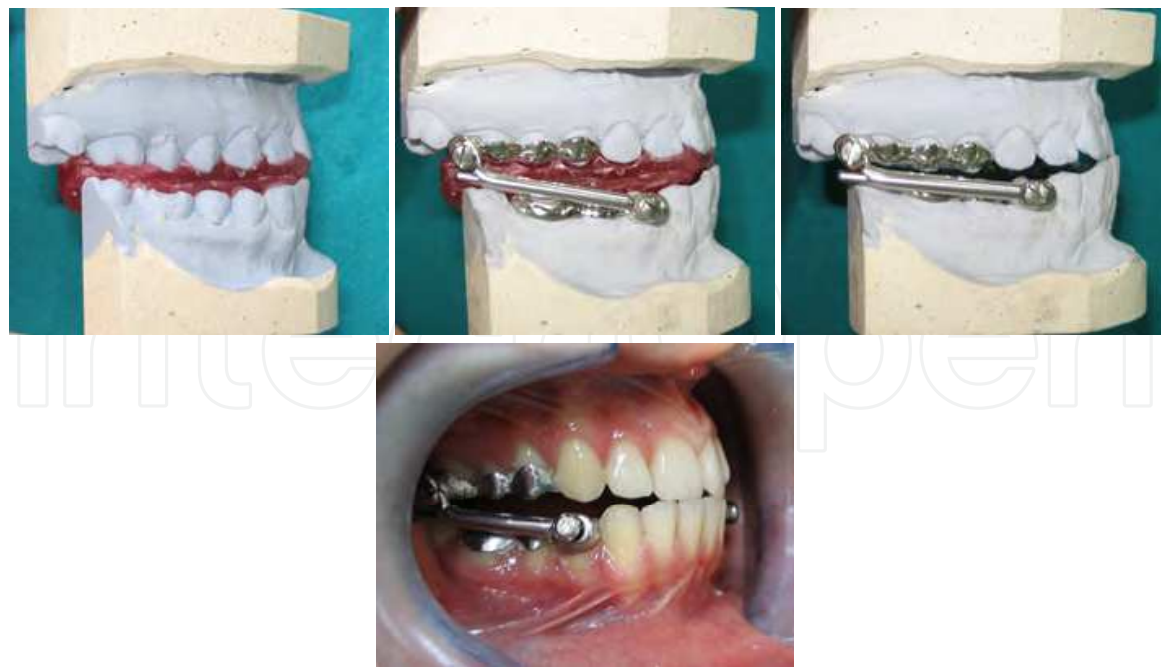

Fig. 1.5. Construction bite, adjusted Herbst appliance on a study model, cemented Herbst appliance.

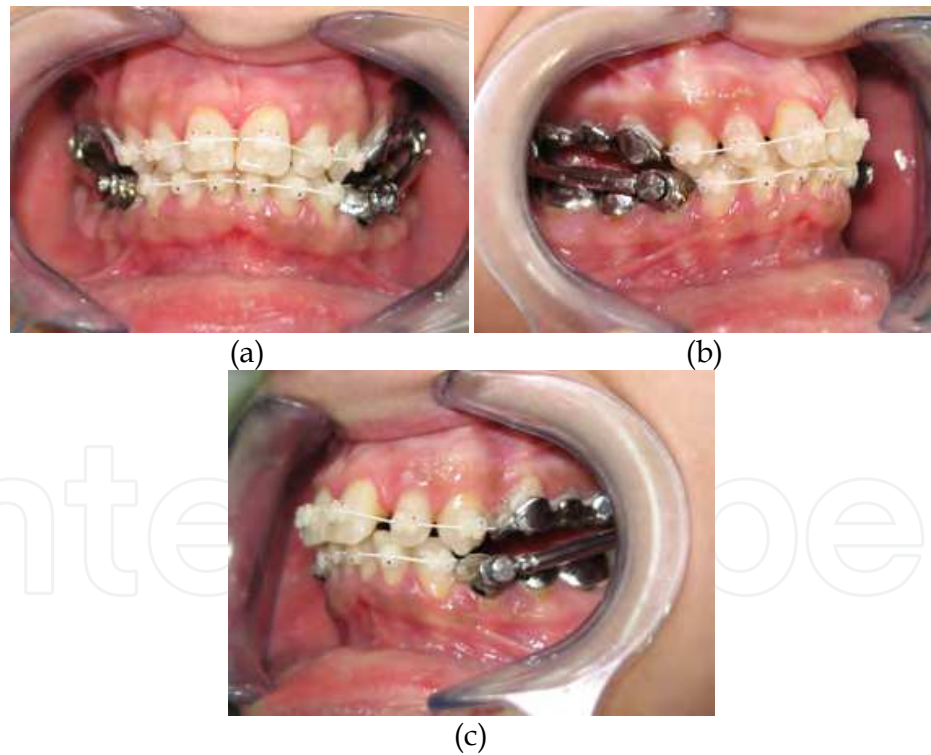


Fig. 1.6. The Herbst appliance and segmented multibracket appliance: a) front view, b) lateral right, and c) lateral left view.

2.1.2 The activator appliance

In the first phase of the activator construction, after the common clinical procedure, the construction bite in the eugnathic relationship (I class dentoalveolar relationship) was

taken, with the mandible forced forward until the upper canine between the lower canine and the first lower premolar relationship was achieved. The construction bite was taken with the mandible protruded 4-6 mm and interocclusal space of 2-3 mm above physiological rest in the molar region. During the procedure of construction bite taking, the great care was exercised regarding the middles of the jaws. After this, the trial of the wax activator followed to check the relationship between the jaws and possible corrections (Fig. 2.1).

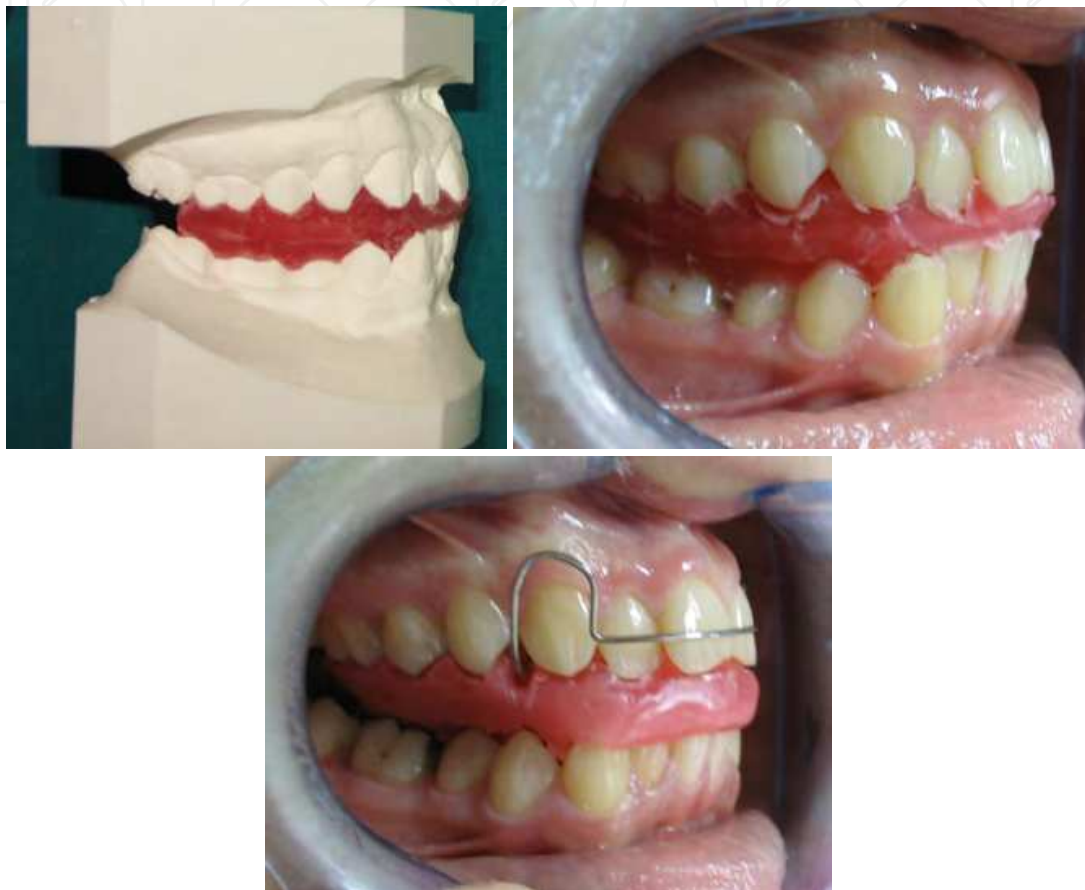

Fig. 2.1. Constructions bite and wax trial.

The activator appliance used in this study (Fig. 2.2) consisted of an acrylic intermaxillary block with upper labial arch (0.8 mm) which passively touched the incisal third of the upper incisors. The acrylic was extended to cover the incisal third of the mandibular incisors in order to prevent the labial tipping of these teeth. The acrylic extended to the lower lingual sulcus to provide stability and anchorage. The appliance was constructed in technical dental laboratory at the Clinic of Orthodontics, School of Dentistry in Belgrade. At control visits, the acrylic was trimmed behind the upper front teeth, which was in concordance with treatment of protruded incisors in the sense of their retrusion and overjet reduction. The interocclusal acrylic in the molar and premolar region was not trimmed until the improvement of the sagittal jaw relationship was achieved, in cases with associated deep bite. In the last phase, the acrylic was trimmed selectively according to the occlusal needs of the lateral teeth. Patients were advised to wear the appliance 15 hours a day, but their compliance was not monitored.

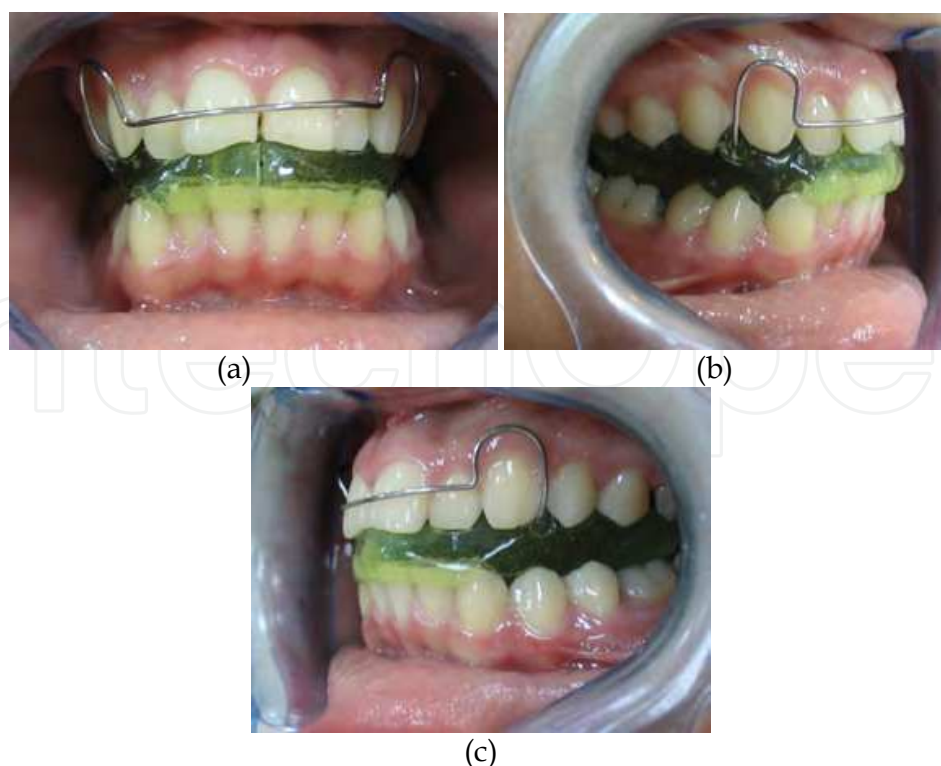


Fig. 2.2. The Activator supplied to the patient: a) frontal view, b) lateral right, and c) lateral left view.

2.2 Skeletal maturity assessment

Chronological maturity was determined for each patient on the date of the profile cephalometric imaging.

On these images, skeletal maturity was first determined for each patient according to the stages of the cervical vertebral maturation (Fig. 3.1 and Fig. 3.2):

- Stage 1 (CvS 1). The inferior borders of the bodies of all cervical vertebrae are flat. The superior borders are tapered from posterior to anterior.
- Stage 2 (CvS 2). A concavity develops in the inferior border of the second vertebra. The anterior vertical height of the bodies increases.
- Stage 3 (CvS 3). A concavity develops in the inferior border of the third vertebra.
- Stage 4 (CvS 4). A concavity develops in the inferior border of the fourth vertebra. Concavities in the lower borders of the fifth and sixth vertebrae are beginning to form. The bodies of all cervical vertebrae are rectangular in shape.
- Stage 5 (CvS 5). Concavities are well defined in the lower borders of the bodies of all six vertebrae. The bodies have become nearly square in shape and the spaces between the bodies are reduced.
- Stage 6 (CvS 6). All concavities have deepened. The bodies of vertebrae are now higher than they are wide.

The stages CvS 1 – CvS 2 represent the periods of prepubertal growth. The stages CvS 3 – CvS 4 are the period of maximal growth (pubertal growth spurt), while the stages CvS 5 – CvS 6 indicate the stage when the maximal growth has passed and the puberty is finished. All of the patients at the beginning of this study were in the stages from CvS 4 to CvS 6. The middle stage in both subjects was CvS 5, which means, they had passed maximal pubertal growth.

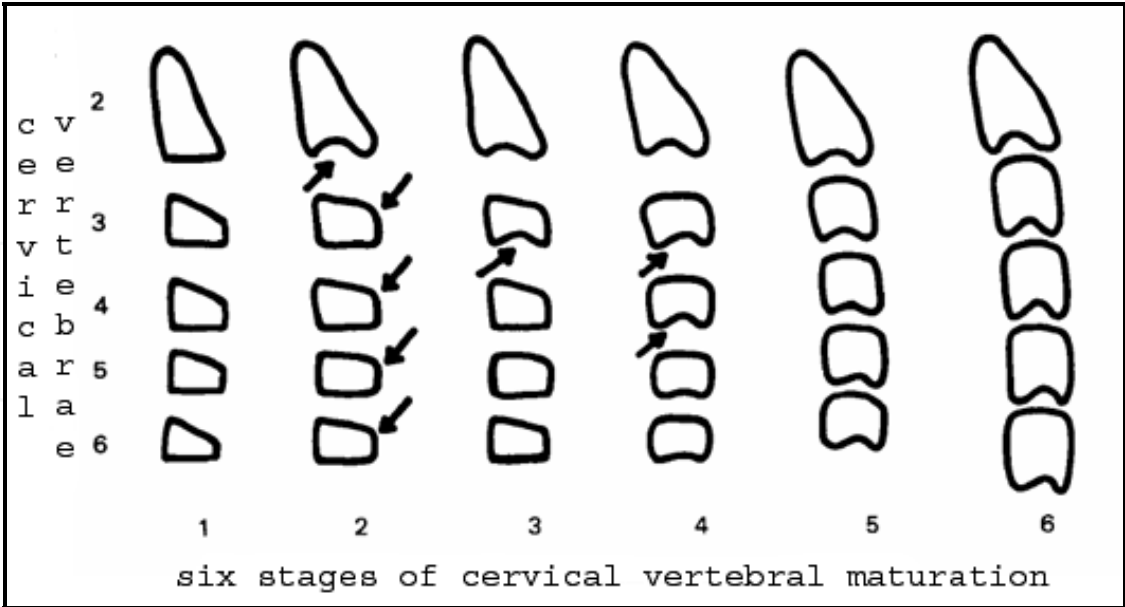


Fig. 3.1. Six stages of cervical vertebral maturation (O'Relly & Yanneillo, 1988).

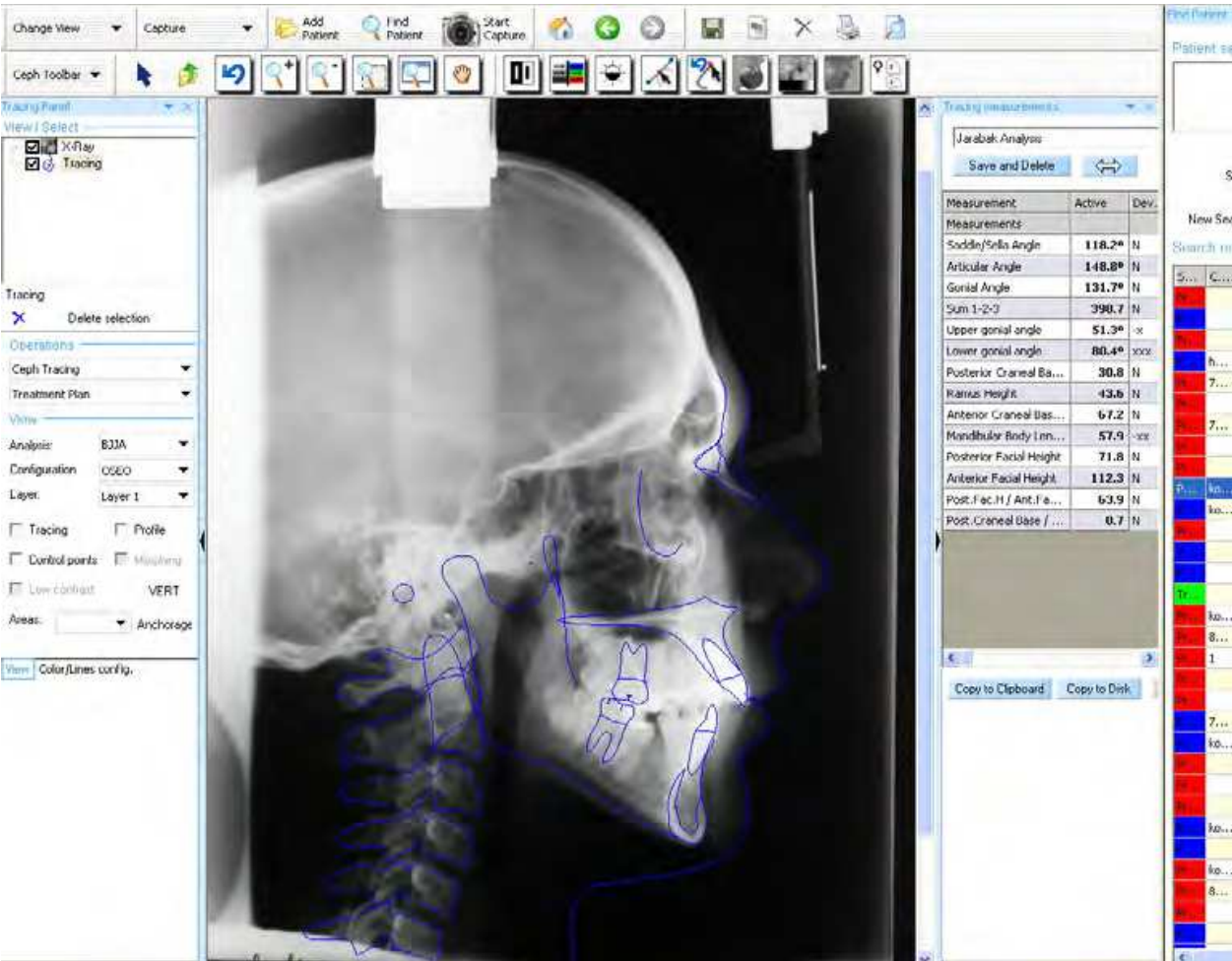


Fig. 3.2. Assessment of cervical vertebral maturation stages using computerized cephalometric analysis.

2.3 Profile cephalometric analysis

The profile cephalometric analysis was performed using the computer program Nemotec Dental Studio NX 2006 to assess sagittal skeletal and dentoalveolar changes. The sagittal occlusal changes were analyzed as well. Pretreatment and post treatment cephalometric images were first superimposed, in relation to nasion-sella line (NSL). Then, maxillary occlusal plane - RL (occlusal reference line passing through the incisal edge of the upper incisor and the most distal point of molar contact in the occlusion) was determined. A line perpendicular to RL through sella (point S) i.e. RLp was used in measurement (Fig. 4). Linear measurements are performed parallel with RL to RLp for each patient and selected in a table 1. of SO-Analysis (Analysis of changes in sagittal occlusion):

SO ANALYSIS	Variable (measurements to RLp)	Before	After	After - Before (D)	Correction Max.+ Mand.
Skeletal + Dental	ms				Molar relation
	mi				
Skeletal + Dental	is				Overjet
	ii				
Skeletal	ss				Skeletal
	Pg				
Dental (Molars)	ms(D)-ss(D)	-	-		Molars
	mi(D)-Pg(D)	-	-		
Dental (Incisors)	is(D)-ss(D)	-	-		Incisors
	ii(D)-Pg(D)	-	-		

Table 1. Analysis of sagittal skeletal and occlusal changes before and after treatment (SO-Analysis by Pancherz H).

1. ms-RLp - position of the maxillary permanent first molar (the shortest distance of the most mesial point of the approximal surface of the upper first molar to RLp),
2. mi-RLp - position of the mandibular permanent first molar (the shortest distance of the most mesial point of the approximal surface of the lower first molar to RLp),
3. (ms-RLp) - (mi- RLp) the molar relationship correction,
4. is-RLp - position of the maxillary central incisor (the shortest distance of the incisal edge of the upper incisor to RLp)
5. ii-RLp - position of the mandibular central incisor (the shortest distance of the incisal edge of the lower incisor to RLp),
6. (is-RLp) - (ii-RLp) the overjet correction,
7. ss-RLp - position of the maxillary base (the shortest distance of the most recessed point of the anterior side of the maxilla to RLp),
8. Pg-RLp - position of the mandibular base (the shortest distance of the most prominent point of the chin profile to RLp),

9. (ss-RLp) - (Pg-RLp) the skeletal correction,
10. (ms-RLp) - (ss-RLp) the correction of the permanent first maxillary molar position within the maxilla,
11. (mi-RLp) - (Pg-RLp) the correction of the permanent first mandibular molar position within the mandible,
12. (ms-ss) - (mi-Pg) the molar correction,
13. (is-RLp) - (ss-RLp) the correction of the upper incisor position within the maxilla,
14. (ii-RLp) - (Pg-RLp) the correction of the lower incisor position within the mandible,
15. (is-ss) - (ii-Pg) the incisor correction.

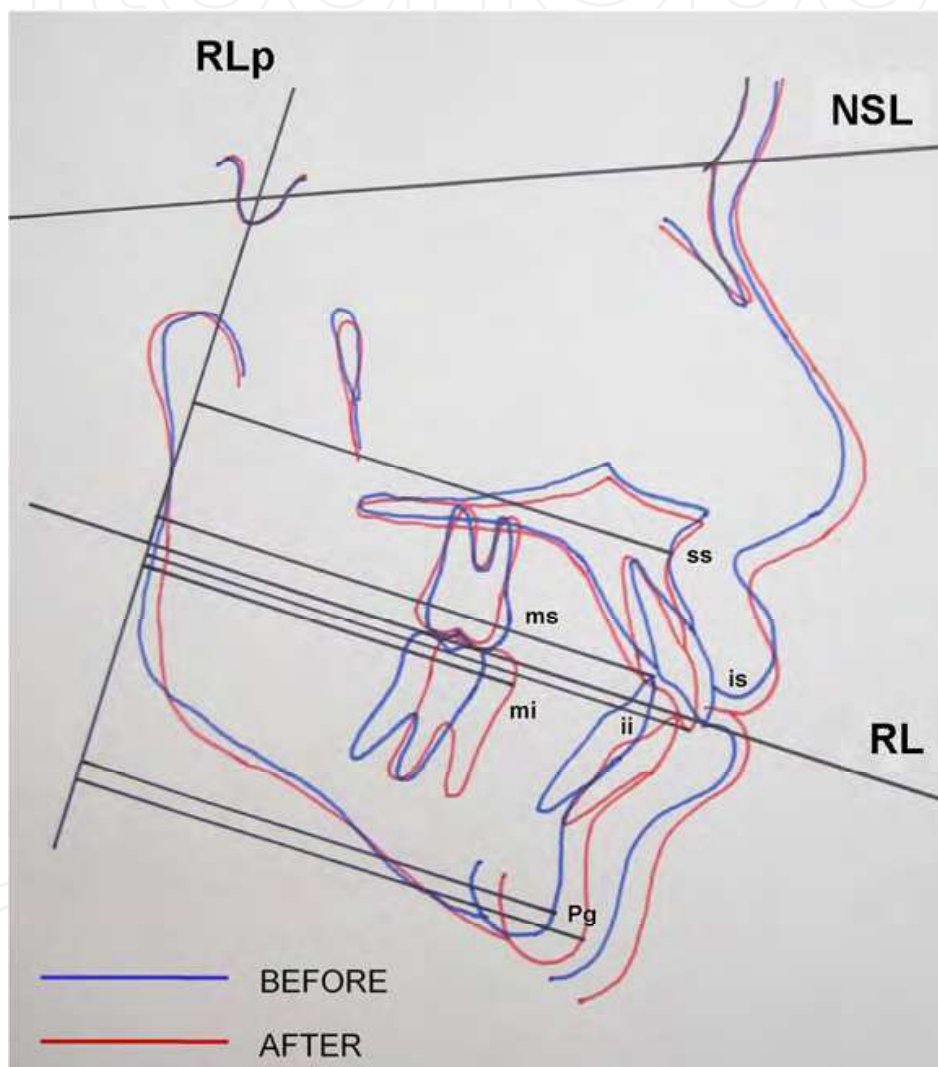


Fig. 4. Superposition of cephalometric images before (blue) and after (red) treatment with visible skeletal and dentoalveolar changes.

2.4 Statistical analysis

Statistical analysis was performed using Windows XP professional in the program Microsoft Office Excel 2003 and SPSS ver. 14. All values of the parameters are statistically evaluated using standard statistical analyses: 1. measurements of central tendency: arithmetic mean (average), 2. reliability intervals: max and min (maximal and minimal value); 3. variability

measurements: SD (standard deviation), variance (average square deviation), variation coefficient; 4. statistical hypothesis testing: t test (testing of statistical differences with Student's t-test: t test for independent samples – to test significant differences within groups and between groups; and t test for paired samples – to control treatment results within the examined groups before and after treatment), correlation coefficient – to explain relations and connections between two indicators or changes within one series before and after treatment), and f test (to compare two dependent samples - test of equivalent pairs).

3. Results

Parameters of sagittal skeletal and dental changes (the method according to Pancherz):

Statistical parameters	HERBST						Correction of molar relation
	ms			mi			
	before	after	after-before	before	after	after-before	
aver	54.70	53.74	0.96	53.10	55.76	2.66	3.62
s.d.	4.62	4.52	1.48	5.02	4.70	1.47	1.00
min	44.00	43.00	-4.00	42.50	44.50	1.00	2.00
max	64.00	62.00	3.00	62.00	64.00	8.00	5.50
var	21.35	20.46	2.19	25.19	22.06	2.16	1.01
KV	8.45%	8.42%		9.45%	8.42%		
TTEST	$p < 0.01^{**}$			$p < 0.001^{***}$			
Cor	0.9479			0.9564			
Ftest	0.9175			0.7484			
Statistical parameters	ACTIVATOR						Correction of molar relation
	ms			mi			
	before	after	after-before	before	after	after-before	
aver	52.80	52.98	-0.18	51.14	52.98	1.84	1.66
s.d.	5.58	5.81	1.58	6.08	6.08	1.44	1.07
min	39.00	39.00	-4.50	38.00	39.00	0.00	0.00
max	64.00	65.00	1.50	63.50	66.50	6.50	3.00
var	31.17	33.78	2.50	36.93	36.97	2.08	1.14
KV	10.57%	10.97%		11.88%	11.48%		
TTEST	0.5743			$p < 0.001^{***}$			
Cor	0.9623			0.9719			
Ftest	0.8452			0.9979			

Table 2. The upper and lower first permanent molar positions and molar relation.

The upper and lower first permanent molar position showed statistical significance in both groups (Table 2.). In the Herbst subjects, the maxillary permanent first molar was distalized ($p<0.01$), whereas the mandibular first molar shows mesial position ($p<0.001$) in both subject groups. Molar relation correction during Herbst treatment (3.62 mm) was more than two times larger than in the Activator group (1.66mm).

Statistical parameters	Pancherz analysis: comparison between groups					
	ms			mi		
	before	after	after - before	before	after	after - before
TTEST Activator-Herbst	0.1961	0.6083	$p < 0.01^{**}$	0.2197	$p < 0.05^{*}$	$p < 0.05^{*}$
Cor Activator-Herbst	0.1086	0.1555	-0.2083	0.0955	0.1133	-0.3709
Ftest Activator-Herbst	0.3608	0.2266	0.7467	0.3551	0.2134	0.9240

Table 3. The upper and lower first permanent molar positions – comparison between the Herbst and Activator group.

The upper and lower first permanent molar positions, showed statistical significance of treatment effects between the groups. Compared with the Activator subjects, the maxillary ($p<0.01$) and mandibular ($p<0.05$) permanent first molar changes during Herbst treatment were significantly pronounced (Table 3.).

Statistical parameters	HERBST						Overjet correction
	is			ii			
	before	after	after-before	before	after	after-before	
aver	86.90	83.82	3.32	75.60	80.46	4.86	8.18
s.d.	5.62	5.42	2.70	5.31	5.26	2.65	2.80
min	74.00	71.00	-5.00	63.00	68.50	0.00	3.50
max	95.00	94.00	7.00	84.50	90.50	10.00	14.00
var	31.63	29.41	7.29	28.23	27.62	7.03	7.83
KV	6.47%	6.47%		7.03%	6.53%		
<i>TTEST herbst</i>	$p < 0.001^{***}$			$p < 0.001^{***}$			
<i>Cor herbst</i>	0.8959			0.8742			
<i>Ftest herbst</i>	0.8606			0.9581			
Statistical parameters	ACTIVATOR						Overjet correction
	is			ii			
	before	after	after-before	before	after	after-before	
aver	85.86	84.62	1.24	76.56	78.66	2.10	3.34
s.d.	7.83	8.00	1.67	6.79	6.09	1.43	2.16
min	74.00	72.50	-2.50	65.50	67.00	0.00	0.00
max	99.00	97.00	4.00	89.00	90.50	5.00	6.50
var	61.32	63.92	2.77	46.09	37.12	2.04	4.68
KV	9.12%	9.45%		8.87%	7.75%		
<i>TTEST activator</i>	$p < 0.01^{**}$			$p < 0.001^{***}$			
<i>Cor activator</i>	0.9781			0.9769			
<i>Ftest activator</i>	0.9198			0.6001			

Table 4. The position of the upper and lower incisor and overjet.

The upper and lower incisors, showed statistical significance in both subjects (Table 4.). Maxillary incisors shows retroinclination (Herbst subjects, $p<0.001$ and Activator, $p<0.01$), whereas mandibular incisors show proclination ($p<0.001$) in both subjects. Overjet correction during Herbst treatment (8.18 mm) was more extensive than in Activator group (3.34mm).

Statistical parameters	Pancherz analysis: comparison between groups					
	is			ii		
	before	after	after - before	before	after	after - before
TTEST Activator-Herbst	0.5921	0.6807	$p<0.001^{***}$	0.5803	0.2689	$p<0.001^{***}$
Cor Activator-Herbst	-0.0346	0.0760	0.2347	-0.0363	-0.0047	-0.5350
Ftest Activator-Herbst	0.1116	0.0630	0.0215	0.2370	0.4746	0.0036

Table 5. The position of the upper and lower incisor – testing between the Herbst and Activator group.

The upper and lower incisors, showed statistical significance of treatment effects between the subjects (Table 5.). Compared with the Activator subjects, the maxillary and mandibular incisor changes during Herbst treatment were significantly pronounced ($p<0.001$).

Statistical parameters	HERBST						Skeletal correction
	ss			Pg			
	before	after	after-before	before	after	after-before	
aver	77.28	76.72	0.52	76.80	79.98	3.18	3.70
s.d.	4.49	4.14	1.29	5.72	4.83	2.43	1.78
min	67.0	67.0	-3.5	66.0	69.0	0.5	1.0
max	85.0	84.0	2.0	89.5	91.0	9.0	9.0
var	20.14	17.14	1.65	32.66	23.34	5.89	3.16
KV	5.81%	5.40%		7.44%	6.04%		
TTEST	$p < 0.05^*$			$p < 0.001^{***}$			
Cor	0.9666			0.9074			
Ftest	0.6961			0.4164			
Statistical parameters	ACTIVATOR						Skeletal correction
	ss			Pg			
	before	after	after-before	before	after	after-before	
aver	77.04	77.40	-0.36	77.76	79.26	1.5	1.14
s.d.	6.28	6.44	0.81	8.97	8.72	1.46	1.38
min	65.5	66.4	-2	59.5	61	0	-0.5
max	88.2	89.0	1.0	96.5	98.0	6.5	5.5
var	39.4775	41.583	0.65	80.52	75.98	2.14	1.90
KV	8.16%	8.33%		11.54%	11.00%		
TTEST	$p < 0.05^*$			$p < 0.01^{**}$			
Co r	0.9922			0.9867			
Ftest	0.8998			0.8881			

Table 6. The position of the upper and lower jaw and skeletal correction.

The upper and lower jaw position, showed statistical significance in both groups (Table 6.). In the Herbst group, point ss changed its position slightly backward ($p<0.05$), while in the Activator group shows anterior position ($p<0.05$). Point Pg changed its position anteriorly in both groups, but the amount of change was more extensive in the Herbst group ($p<0.001$). Skeletal correction during Herbst treatment (3.70mm) was about three times larger than in Activator group (1.14mm).

Statistical parameters	Pancherz analysis: comparison between groups					
	ss			Pg		
	before	after	after - before	before	after	after - before
TTEST Activator-Herbst	0.8772	0.6593	$p<0.01^{**}$	0.6539	0.7195	$p<0.01^{**}$
Cor Activator-Herbst	0.0820	0.0886	0.1570	-0.2577	-0.2732	-0.0264
Ftest Activator-Herbst	0.1061	0.0345	0.0275	0.0314	0.0054	0.0164

Table 7. The position of the upper and lower jaw – testing between the Herbst and Activator group.

The upper and lower jaw position parameters, showed statistical significance of treatment effects between the groups. Herbst treatment seemed to have some greater influence on maxillary and mandibular jaw base position. For both parameters: ss ($p<0.01$) and Pg ($p<0.01$) were significantly greater in the Herbst subject (Table 7.).

	HERBST					
	ms(D)-ss(D)	mi(D)-Pg(D)	Molars	is(D)-ss(D)	ii(D)-Pg(D)	Incisors
	after-before	after-before		after-before	after-before	
aver	0.44	-0.52	-0.08	2.80	1.68	4.48
s.d.	1.00	1.87	1.75	2.12	2.08	2.67
min	-1.00	-5.00	-3.50	-1.50	-2.00	-1.50
max	2.50	3.00	3.50	6.50	7.50	9.00
var	1.01	3.49	3.06	4.50	4.33	7.14
	ACTIVATOR					
	ms(D)-ss(D)	mi(D)-Pg(D)	Molars	is(D)-ss(D)	ii(D)-Pg(D)	Incisors
	after-before	after-before		after-before	after-before	
aver	0.18	0.34	0.52	1.60	0.60	2.20
s.d.	1.24	1.24	1.34	1.23	0.93	1.79
min	-3.50	-1.00	-3.50	-0.50	-1.50	-1.00
max	2.00	2.50	2.50	4.00	2.00	6.00
var	-3.50	-1.00	-3.50	-0.50	-1.50	-1.00

Table 8. The correction of the position of the molars and incisors.

The correction of the incisor position shows greater amount in the Herbst subjects (Table 8.).

Significance Herbst - Activator	Molar relation	Overjet	Skeletal relation	Molars	Incisors
TTEST Activator-Herbst	$p<0.001^{***}$	$p<0.001^{***}$	$p<0.001^{***}$	0.1798	$p<0.001^{***}$
Cor Activator-Herbst	-0.0868	0.0799	0.0008	-0.0792	0.1825
Ftest Activator-Herbst	0.7616	0.2147	0.2212	0.2028	0.0540

Table 9. Treatment effects (the correction of the molar relation, the overjet correction, the skeletal relationship correction, the correction of the molars and incisors).

The treatment effects parameters (the correction of the molar relationship, the overjet correction, the skeletal relationship correction, the correction of the molars and incisors), showed the statistical significance between the subjects. For parameters: the correction of the molar relationship, the overjet correction, the skeletal relationship correction, the correction of the incisors, the greater statistical significance was found ($p<0.001$) because of the bigger changes during the Herbst treatment (Table 9).

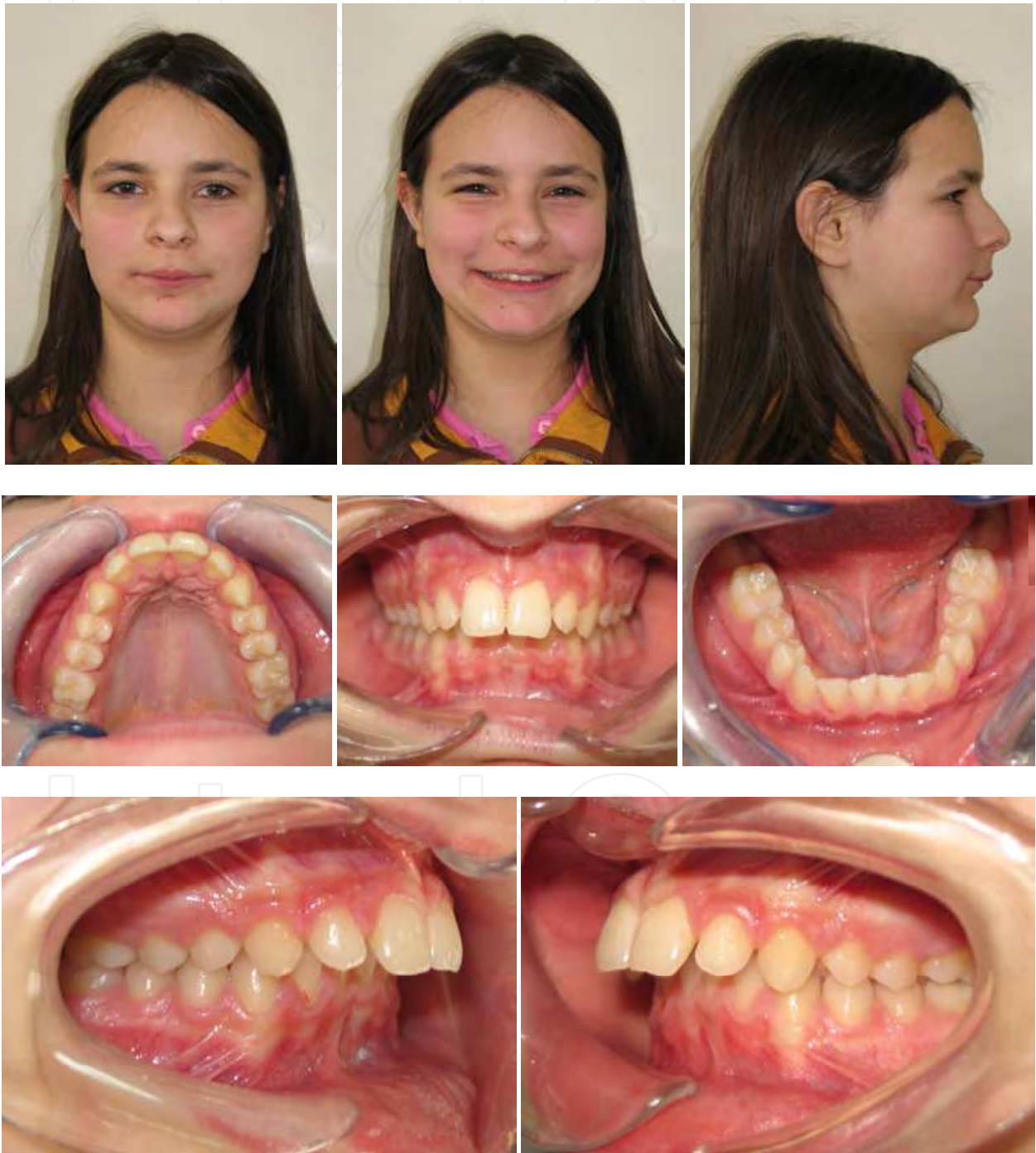

Fig. 5.1. Class II, division 1 patient before treatment (15 years old, female). Extraoral and intraoral photos.

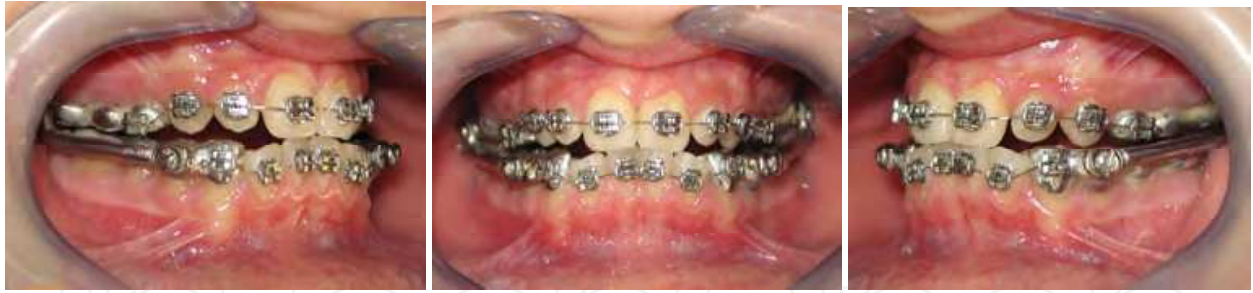
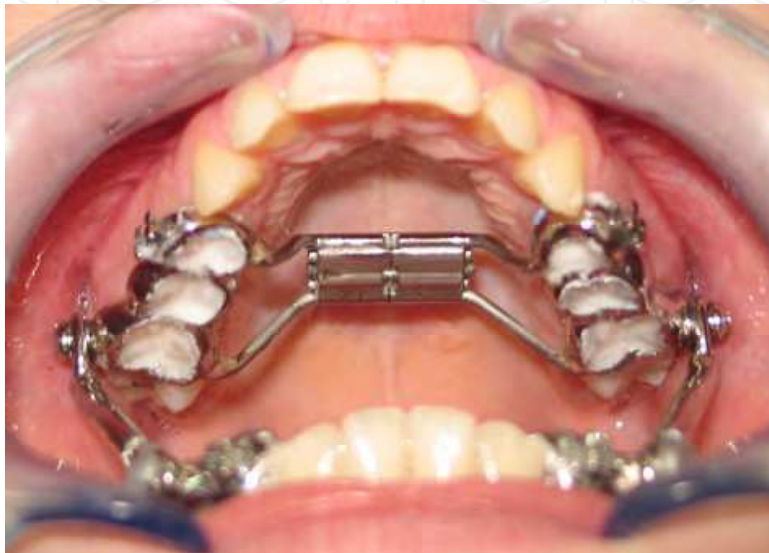
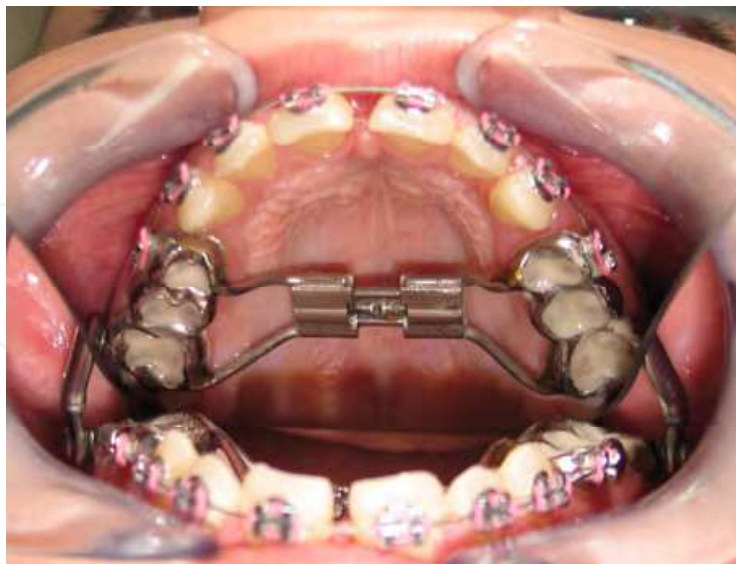Fig. 5.2. The Herbst appliance and segmented multibracket appliance.



a)



b)

Fig. 5.3. Sagittal and transversal treatment effects: a) The cast splint Herbst appliance with Rapid palatal expander (RPE), b) Headgear effect of Herbst appliance (diastema between canine and first premolar) and transversal RPE effect (diastema mediana).

IntechOpen

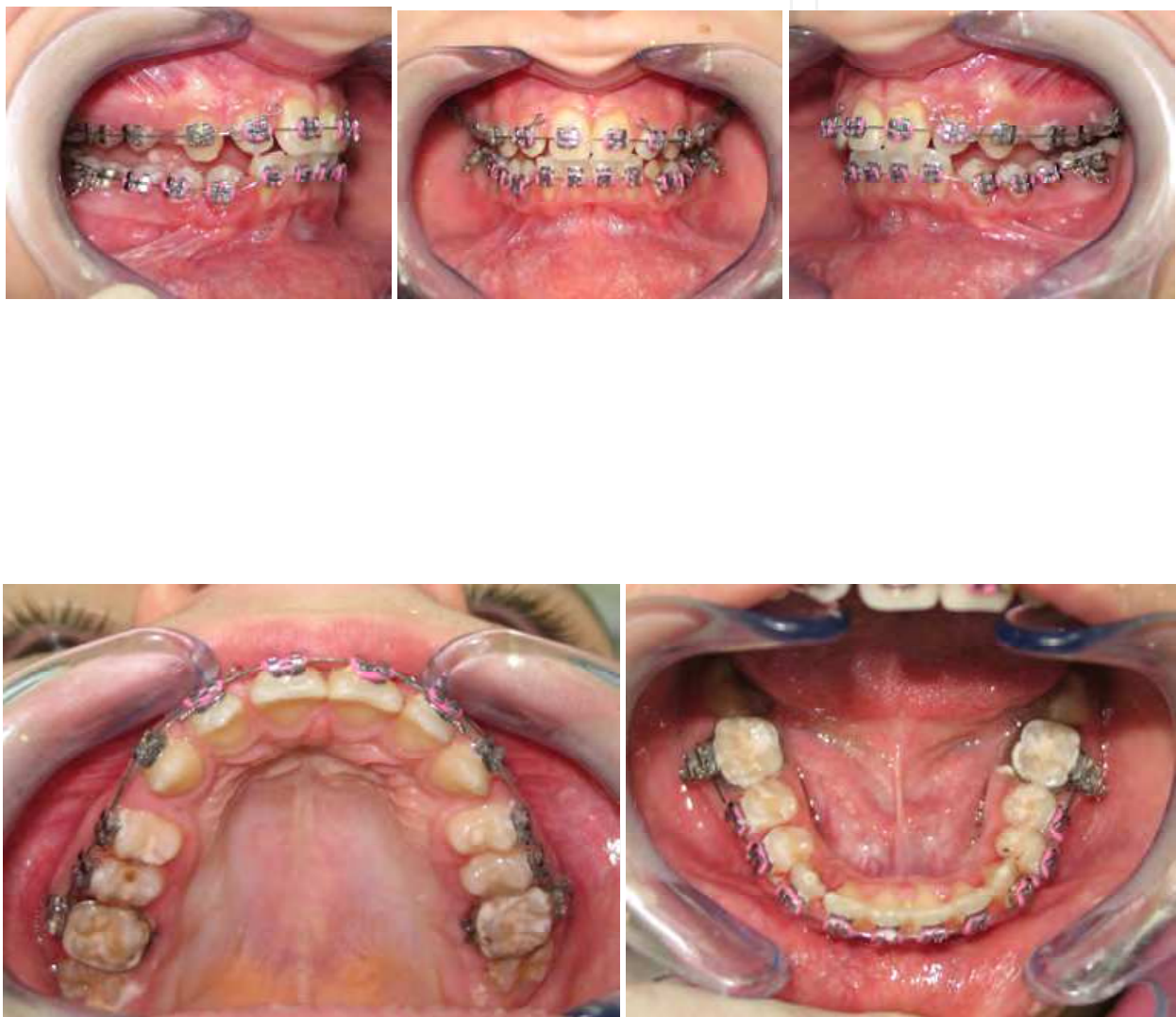

Fig. 5.4. Removed Herbst appliance (after 7 months) and completed multibacket appliance.

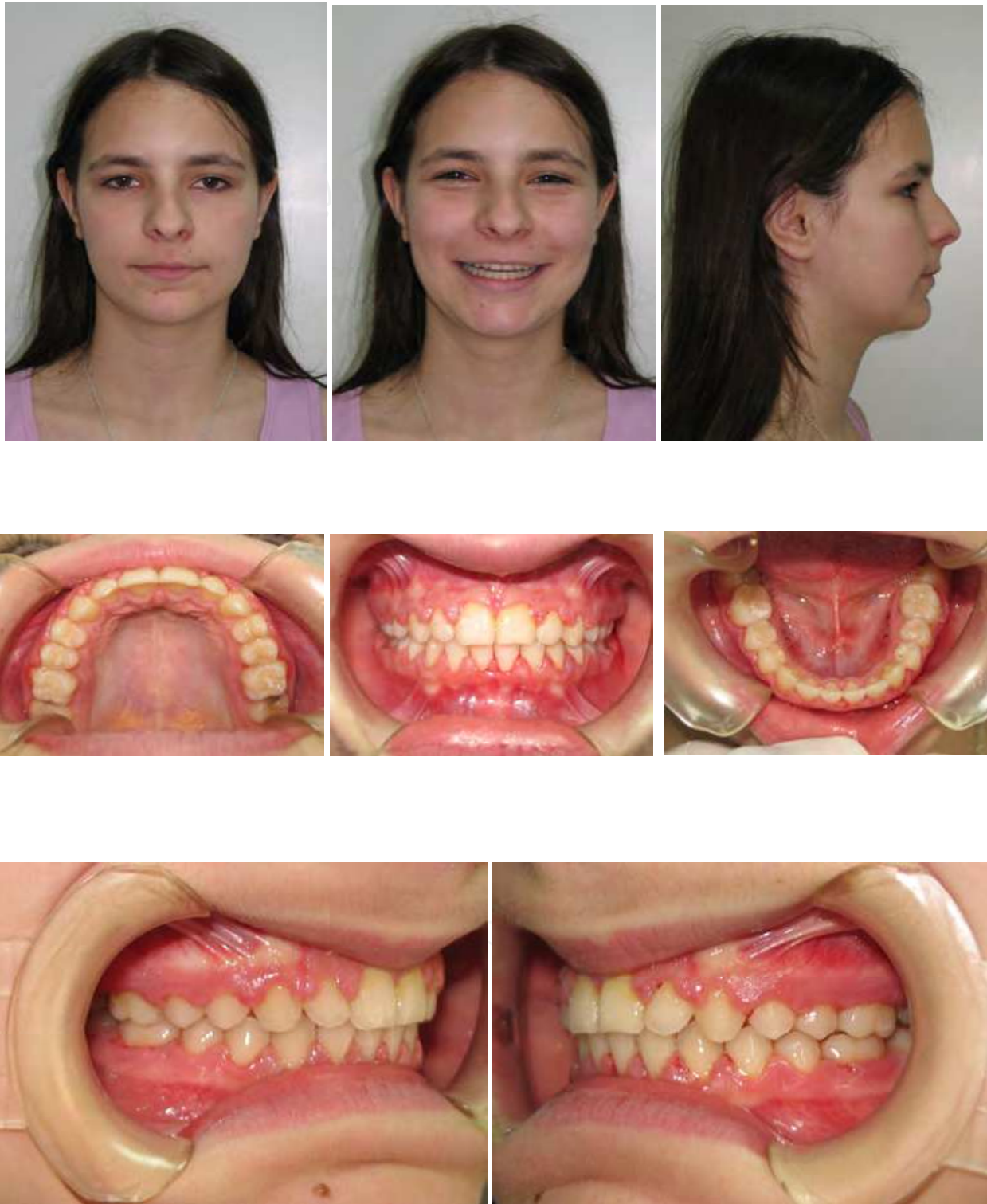

Fig. 5.5. The end of treatment (patient after 15 months of treatment). Extraoral and intraoral photos.

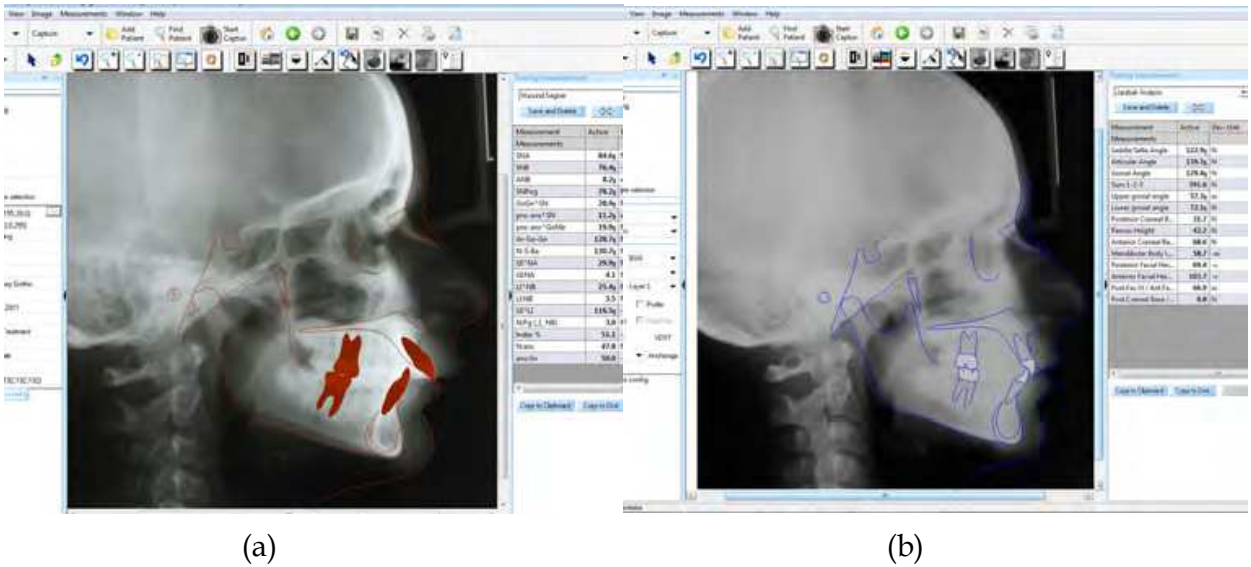


Fig. 5.6. Cephalometric diagnostic records: a) before treatment and b) after treatment.

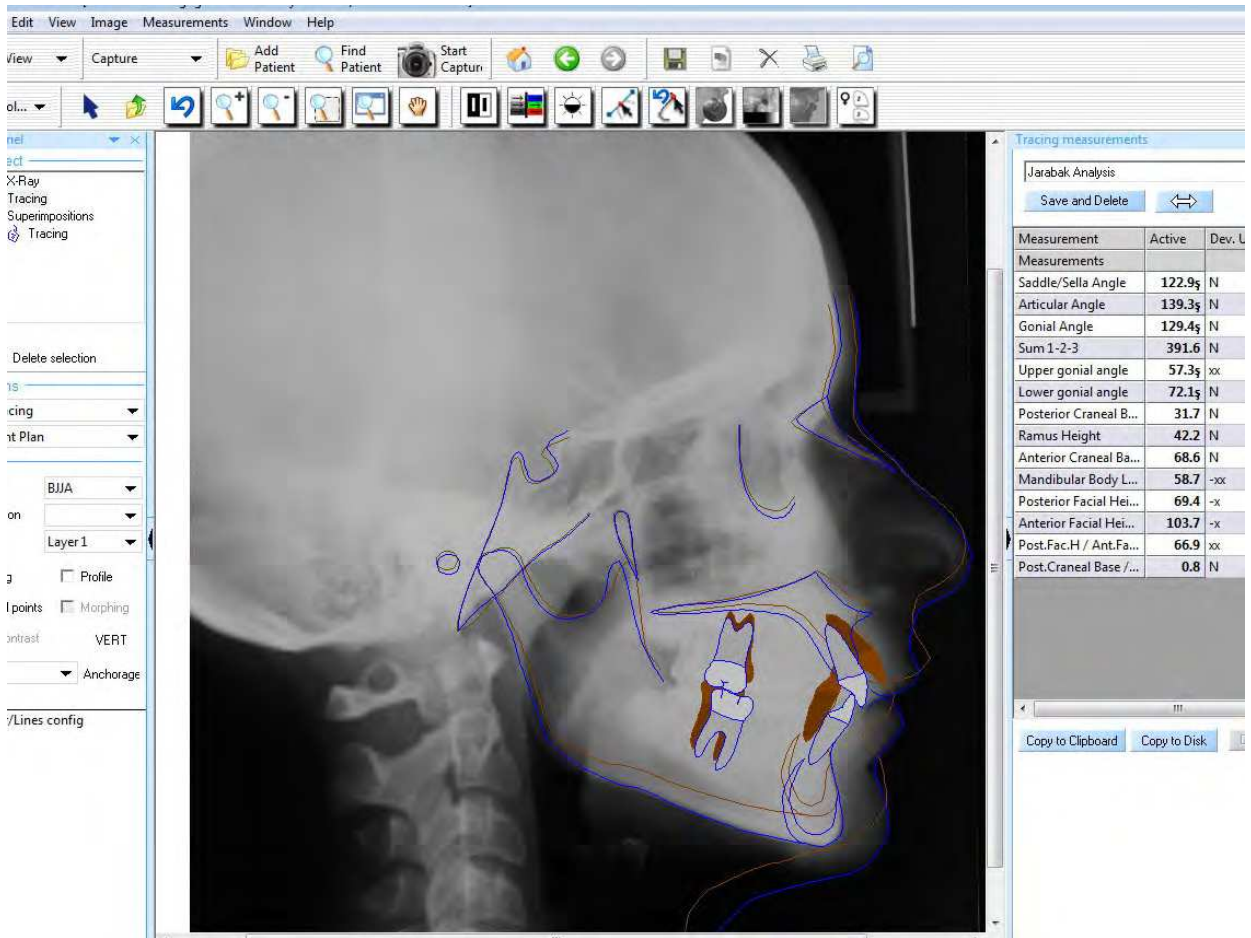


Fig. 5.7. Superimposition of cephalograms before (brown) and after (blue) treatment.

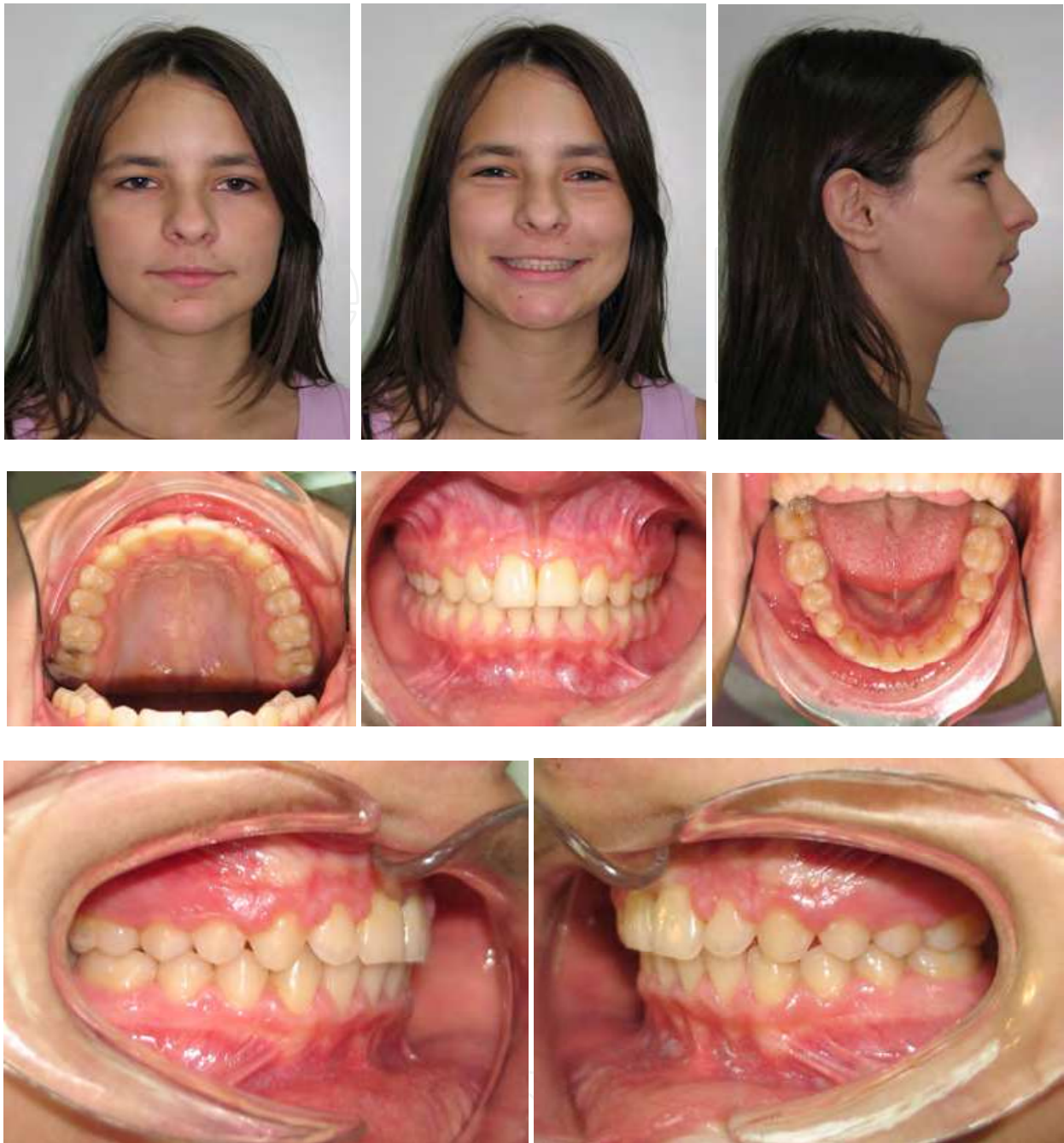

Fig. 5.8. Ten months in retention period after the end of treatment. Extraoral and intraoral photos.

4. Discussion

In the recent years, Pancherz analysis has been accepted by numerous orthodontists as a very reliable method of assessment of sagittal skeletal and dentoalveolar changes in longitudinal studies (Pancherz, 1981, 1982, 1989, 1991, 1994, 1997; Pancherz & Anehus-Pancherz 1993; Pancherz & Michailidou, 2004; Ruf & Pancherz, 1996, 1998, 1999, 2000, 2004; O'Brien et al., 2002, 2004; You & Hagg, 2002; Konik et al., 1997; Cura et al., 1996; Chen & Shen, 2003; Paulsen, 1997; Lin & Gu, 2005; Hansen & Pancherz, 1992; Hansen et al., 1997;

etc.). It is particularly used to monitor treatment effects in patients before and after treatment.

1. ms-RLp: The analysis of sagittal position of the upper molar before and after treatment showed statistically significant difference ($p < 0.01$). Before treatment, ms-RLp amounted to 54.70mm, and after treatment 53.74mm. The average total movement of point ms distally was 0.96mm. Namely, distalization of this tooth occurred as a result of headgear effect of the Herbst appliance on the upper molars (Table 2., Fig. 5.3., 5.7.). There was no significant difference for this parameter in the Activator group before and after treatment ($p = ns$). The total movement of ms point was slightly mesially and amounted to 0.18 mm on average.

2. mi-RLp: The analysis of sagittal position of the lower molar before and after treatment showed statistically significant difference ($p < 0.001$) in both groups, due to mesial movement of the lower molars. The average mi-RLp in the Herbst group before treatment was 53.10mm, and after treatment 55.76 mm, and in the Activator group it was 51.14mm before treatment, and 52.98mm after treatment. The overall average movement of mi point mesially was 2.66mm in the Herbst group, and 1.84mm in the Activator group. In the treatment of skeletal Class II malocclusion using functional appliances, this is a common finding. It is usually explained by the loss of mandibular anchorage for skeletal bite correction associated with dentoalveolar changes and occlusal compensation (Table 2., Fig. 5.6., 5.7.).

3. (ms-RLp) - (mi-RLp): molar relationship correction: There was an overall change in molar sagittal relationship amounting to average 3.62 mm in the Herbst group, due to the distalization of the upper molars and mesial movement of the lower molars (Fig. 5.7.). In the Activator group, this change was significantly smaller - 1.66mm.

The comparison between the Herbst and Activator group for parameters of the sagittal position of the upper and lower molar showed statistical difference for both parameters ($p < 0.01$), which suggests greater molar movement during Herbst treatment (Table 3.).

4. is-RLp: The analysis of sagittal position of the upper incisor before and after treatment showed statistically significant difference ($p < 0.001$) in the Herbst group. Before treatment, mi-RLp amounted to 86.90mm, and after treatment 83.82mm. The overall average movement of is point posteriorly was 3.32mm. Namely, the retrusion of the front teeth occurred as a result of headgear effect of the Herbst appliance on the upper molars and fixed multibracket appliance on the front teeth (Table 4., Fig. 5.6., 5.7.). This is a common finding with this type of treatment. The retrusion of the upper incisors occurred in the Activator group as well, with somewhat smaller statistical significance ($p < 0.01$). The mean pretreatment is-RLp was 85.86 mm and post treatment 84.62 mm. The average overall movement of point is distally was 1.24mm.

5. ii-RLp: The analysis of sagittal position of the lower incisor before and after treatment showed statistically significant difference ($p < 0.001$) in both examined groups, because of mesial movement of the lower lateral teeth and protrusion of the incisor teeth. The mean pretreatment and post treatment value of ii-RLp was 75.60 mm and 80.46 mm in the Herbst group, respectively 76.56 mm and 78.66 mm in the Activator group. The overall average movement of ii point mesially was 4.86mm in the Herbst group, and 2.10 mm in the Activator group. This treatment effect on the lower incisors can be explained by the loss of mandibular anchorage for skeletal bite correction (Table 4., Fig. 5.6., 5.7.).

6. (is-RLp) - (ii-RLp): overjet correction: In the Herbst group, there was an overall change in incisor position and overjet correction by 8.18 mm, as a result of the upper incisor retrusion and lower incisor protrusion (Fig. 5.1.-5.8.). In the Activator group, the average overjet reduction was only 3.34 mm (Table 4.).

The comparison between the Herbst and Activator group for parameters of the sagittal position of the upper and lower front teeth showed statistical difference for both parameters ($p < 0.001$), which suggests greater incisor movement in the sense of the upper incisor retrusion and lower incisor protrusion during Herbst treatment (Table 5.). Prominent lower incisor protrusion is not always desirable since there is a higher risk of relapse in the lower front teeth after treatment.

7.ss-RLp: The analysis of sagittal position of the upper jaw (ss point) in the Herbst group before and after treatment showed statistically significant difference ($p < 0.05$). Namely, the ss point (in cephalometric analysis frequently marked as point A) moved backward due to the headgear effect of the Herbst appliance and fixed multibracket appliance on the maxillary front teeth retrusion (Fig. 5.7.). The average pretreatment and post treatment distance from point ss to RLp was 77.28 mm and 76.72 mm. The average overall backward movement of ss point was 0.52 mm. This therapeutic effect can be explained as a consequence of the headgear effect of the Herbst appliance, as well as the headgear appliance too, that occurs due to the influence of orthopedic forces. They lead to maxillary growth disabling. The front teeth retrusion and their correct torque that cause the anterior part of the apical base (the anterior side of the maxilla) to follow the backward movement of the upper front teeth roots, leads to backward movement of the ss point too. In the Activator group, there was statistically significant difference regarding the position of ss point before and after treatment ($p < 0.05$). In this case, however, ss point was 77.04 mm before treatment and 77.40 mm after treatment, which implies that it moved forward (Table 6.). The average overall forward movement of ss point was 0.36 mm. This finding is associated with mild forward sagittal growth of the maxilla.

8. Pg-RLp: The analysis of sagittal position of the lower jaw (Pg point) in the Herbst group before and after treatment showed statistically significant difference ($p < 0.001$). Namely, Pg point moved forward, which means that the position of the mandible became more mesial (Fig. 5.7.). The average pretreatment and post treatment distance from point Pg to RLp was 76.80 mm and 79.98 mm. The average overall forward movement of Pg point was 3.18 mm. The treatment effect of functional appliance on mandibular growth and anterior displacement is a debatable issue. Namely, this claim is difficult to confirm since the treatment is provided mainly in the ideal treatment period of prepubertal growth spurt. In this study, however, the patients were in a declining growth phase with little residual growth. As we said, Herbst treatment effects come from the fact that skeleto-facial growth continues many years after the cessation of body height growth and that the TMJ in adults is capable of remodeling too. Also, in the Activator group, there was statistical difference regarding the position of Pg point before and after treatment with smaller statistical significance ($p < 0.01$). In this case, the average distance from point Pg to RLp was 77.76 mm before treatment and 79.26 mm after treatment. The average overall forward movement of Pg point was 1.50 mm (Table 6.).

9.(ss-RLp) - (Pg-RLp): skeletal correction: In the Herbst group, there was the overall skeletal change - correction of 3.70 mm due to the backward movement of ss point by 0.52 mm and mesial movement of Pg point by 3.18 mm. In the Activator group, the skeletal correction was only 1.14 mm (Table 6.).

The comparison between the Herbst and Activator group for the parameters of maxillary and mandibular sagittal position, the points ss and Pg, showed statistical significance for both parameters ($p < 0.01$), which implied greater skeletal changes during Herbst treatment

(Table 7.), in the sense of backward movement of ss point due to headgear effect of the Herbst appliance and greater mesial movement of Pg point due to anterior displacement of the mandible.

The parameters of the upper and lower molar correction: 10. **(ms-RLp) - (ss-RLp)** and 11. **(mi-RLp) - (Pg-RLp)** provide the data on the overall molar position in relation to the skeletal changes: 12. **(ms-ss) - (mi-Pg)**. The results suggest that the overall molar position correction in the Herbst group was 0.08 mm and in the Activator group 0.52mm (Table 8.).

The parameters of the upper and lower incisor correction: 13. **(is-RLp) - (ss-RLp)** and 14. **(ii-RLp) - (Pg-RLp)** provide the data on the overall incisor position in relation to the skeletal changes: 15. **(is-ss) - (ii-Pg)**. The results suggest that the overall incisor position correction in the Herbst group was 4.48 mm and in the Activator group 2.20 mm (Table 8.).

The last part of Pancherz analysis provides very important information on the comparable analysis of the treatment effects of Herbst and Activator appliance (Table 9.). The testing of statistical differences of treatment effects parameters (molar relationship correction, overjet correction, skeletal relationship correction, molar correction and incisor correction) between the examined groups confirmed the following:

1. a high level of statistical significance ($p < 0.001$) was established in the comparison of molar relationship correction as a result of greater changes occurring during Herbst treatment,
2. a high level of statistical significance ($p < 0.001$) was established in the comparison of overjet correction as a result of greater changes occurring during Herbst treatment,
3. a high level of statistical significance ($p < 0.001$) was established in the comparison of skeletal relationship correction as a result of greater changes occurring during Herbst treatment,
4. no statistical significance was established between the examined groups ($p = ns$) in the comparison of molar correction,
5. a high level of statistical significance ($p < 0.001$) was established in the comparison of incisor correction as a result of greater changes occurring during Herbst treatment.

Konik et al. (1997) investigated the Herbst effects in older patients, i.e. the patients that had passed the ideal period for functional therapy. They compared the effects of the Herbst appliance in older patients (late Herbst treatment – 21 subjects in stages MP3-E and F) and younger patients that are in prepubertal growth spurt period (early Herbst treatment – 22 subjects in stages MP3-H and I). They concluded that the Herbst appliance is equally effective both in adolescents and in young adults. This finding is in accordance with the findings by Pancherz & Ruf (2000) and Pancherz (2008). Also, conclusion of Von Bremen et al., (2009) research was: Herbst treatment can be considered equally efficient in adolescent and in adult Class II, division 1 subjects.

Sagittal skeletal changes in Herbst treatment were reported by many authors (Pancherz, 1981, 1982, 1989, 1991, 1994, 1997; Pancherz & Ruf, 1999, 2000, 2008; Pancherz et al., 1989; Pancherz & Fischer, 2003; Ruf & Pancherz, 1996, 1998, 1999, 2000, 2004; Ruf et al., 2001; White, 1994; Paulsen, 1997; Shen & Hagg, 2005; Smith, 1998, 2000; Graber et al., 1997; Windmiller, 1993; Weschler & Pancherz, 2005; Baltromejus et al., 2002; Dischinger, 1995, 1998; Du et al., 2002; Hansen et al., 1997; Hanks, 2003; Howe & McNamara, 1983; McNamara et al., 1990; O'Brien et al., 2003; Siara-Olds et al. 2010). These changes mainly relate to a more anterior position of the mandible as a result of mandibular growth stimulation and adaptation combined with TMJ remodeling. The headgear effect of the Herbst appliance

on the upper jaw and upper molars combined with multibracket fixed appliance effect on the frontal teeth retrusion can lead to the maxillary growth restriction and movement of point ss posteriorly. This Herbst effect was mostly examined by Pancherz (1982, 1987) and Ruf & Pancherz (2008). Valant & Sinclair (1989) state that the reduction of ANB angle at the end of treatment was achieved by mesial movement of the mandible by 1.3 mm as a result of growth stimulation and maxillary growth restriction and posterior movement of point A by 0.7 mm. This finding is concurrent with results from our study. The similar conclusion was reached by Creekmore & Radney (1983) in a investigation on Fränkel regulator treatment effects in patients with Class II malocclusion. Konik et al. (1997) compared the effects of the Herbst appliance in older patients (late Herbst treatment) and younger patients that are in prepubertal growth spurt period (early Herbst treatment). They concluded that the Herbst appliance had led to the maxillary growth restriction (the movement of point ss-OLP after treatment amounted to 0.1mm with $SD \pm 1.2$). The movement of point Pg anteriorly was $2.4\text{mm} \pm 2.2$. Siara-Olds et al. (2010) found that the Herbst appliance significantly restricted maxillary growth, comparing to other functional appliances in the treatment of skeletal Class II malocclusion.

Examining the effects of removable functional appliances during pubertal growth spurt, in Class II, division 1 treatment, some authors concluded that changes on the maxilla occurred as well. In Activator treatment these findings were reported by Harvold & Vargervik (1971), Baltromejus et al. (2002), Pancherz (1984), Cozza et al. (2006), Jakobson (1967) and Moreira et al. (2003) achieved maxillary growth restriction by Bionator treatment. Milosavljevic (2006) examined the effects of the Twin block appliance in Class II, division 1 treatment and reported the similar result. Fränkel (1969) confirmed slowed maxillary growth by means of a function regulator. McNamara et al. (1990) did not point out the similar result. Many research studies investigated whether functional appliance treatment produced a stimulation effect on mandibular growth or resulted in mesial movement only, i.e. whether skeletal or dentoalveolar changes occurred Chen et al. (2002), De Vincenzo (1991), Bascifci et al. (2003) and Nelson et al. (1993) in their studies on the Activator effects observed the increased growth of the mandible. In treatment of distal bite with Balters Bionator, the increased mandibular growth was reported by Moreira et al. (2003). However, other authors have found that there was only mesial movement of the mandible without any significant growth changes (Jorgensen, 1974; Wieslander & Lagerström, 1979; Pancherz, 1979, 1984; Cozza et al., 2006; Milosavljevic, 2006).

Comparing treatment effects of the Herbst and Activator appliance and monitoring changes of point Pg during treatment, Baltromejus et al. (2002) found great variations in both groups. In the Activator group Pg point moved anteriorly and caudally ($p < 0.001$). In the Herbst group Pg point also moved anteriorly and caudally ($p < 0.001$). Compared with the Activator group, the amount of changes in Pg point during Herbst treatment was smaller in both sagittal ($p < 0.001$) and vertical direction ($p < 0.001$). The mean age of Herbst and Activator subjects was 12.6 years and 10.3 years, respectively. There were no sex differences found in any group concerning the direction of Pg point changes.

The headgear effect of the Herbst appliance on the maxilla produces dentoalveolar effect on the upper molars. This can be seen in the upper molar distalization, which is a common finding in studies. The headgear effect of the Herbst appliance alongside with the effect of the multibracket fixed appliance produces dentoalveolar effect on the front teeth, which is

reflected in the upper incisor retrusion. In addition, activation forces on the lower jaw and the anchorage incorporating the lower first molars can lead to mesial bodily movement of these teeth. The strong activation forces on the mandible and the movement of the entire lower dental arch mesially particularly are reflected on the lower front teeth (Allen-Noble, 2003; Baltromejus et al., 2002; Dischinger, 1995, 1998; Du et al., 2002; Hansen et al., 1997; Hanks, 2003; Howe, 1982; McNamara et al., 1990; O'Brien et al., 2003; Pancherz, 1981, 1982, 1989, 1991, 1994, 1997; Pancherz & Ruf, 1999, 2000, 2008; Pancherz et al., 1989; Pancherz & Fischer, 2003; Ruf & Pancherz, 1996, 1998, 1999, 2000, 2004; Ruf et al., 2001; White, 1994; Schavioni et al., 1992; Shen & Hagg, 2005; Smith, 1998, 2000; Valant & Sinclair, 1989; Graber et al., 1997; Windmiller, 1993; Weschler & Pancherz, 2005). In essence, the entire lower arch moved mesially, excluding skeletal movements. The lower front teeth protrusion occurs, which is preferable when the lower incisors are retruded. However, the protrusion of the lower incisors frequently occurs when it is undesirable. It is mainly due to the loss of anchorage in the mandible. Konik et al. (1997) state that dentoalveolar movements such as distalization of the upper molars and mesial movement of the lower molars are more prominent in older patients with Class II, division 1 malocclusion treated with the Herbst appliance than in adolescent patients. Protrusion of the lower incisors and retrusion of the upper incisors, induced by the Herbst treatment in older patients with Class II, division 1 malocclusion, are more prominent than in adolescents. In older patients, the anchorage system includes the upper front teeth, while this can not be done in adolescents due to their mixed dentition. The lower front teeth were more protruded during Herbst treatment in adults, mainly because of stronger forces induced by the telescopic mechanism on the lower dental arch and relative loss of anchorage in the lower jaw. O'Brien et al. (2003) state that the Herbst appliance was more effective in overjet reduction in phase I of treatment in comparison with the Twin block appliance. In the study by Voudouris et al. (2003) on monkeys treated with the Herbst appliances, cephalometric superimposition on maxillary implants showed that in experimental animals the first permanent molars moved distally and were slightly intruded, and mandibular first molars moved mesially and slightly inferiorly, which was in accordance with the findings in humans. The upper incisors moved palatally and were extruded, but the mandibular incisors moved labially, inferiorly and tipped mesially. The incisors moved minimally in untreated animal control group but without statistical significance. Scean (1997) in research on the effects of the Activator treatment states that the upper molars inclined distally while the lower molars moved mesially. McNamara et al. (1990) report greater distal movement of the upper molars in patients treated with the Herbst appliance in comparison with the removable Fränkel appliance. The similar was reported by O'Brien et al. (2003) who compared treatment effects of the Herbst and Twin block appliance.

5. The future

Based on the literature review, results of this study and clinical experience, early treatment of patients with Class II malocclusions should be provided with removable functional appliances since these appliances are more efficient and easier to manipulate in younger children (adolescents). On the other hand, treatment with the Herbst appliance should be provided mainly in patients who are in post pubertal stage of development and have their permanent dentition; in this age and dental-alveolar-skeletal developmental phase, removable appliances are less efficient and patient compliance is decreased.

As mentioned above, a recent clinical cephalometric roentgenographic investigation and MRI investigation has shown that the Herbst appliance is very effective in patients with Class II malocclusion at the end of their growth (radius union: Deicke & Pancherz, 2005). Therefore, we consider this method to be an alternative to orthognatic surgery in many adult patients with Class II malocclusions. The findings from the study of Ruf & Pancherz (2004) comparing young adults with Class II malocclusion either treated with the Herbst appliance or with mandibular sagittal split osteotomy support our opinion. Comparable changes in sagittal maxillary/mandibular jaw base relationship and skeletal profile convexity can be observed in both groups at the end of treatment (after final teeth alignment with a fixed appliance). Furthermore, in comparison with surgery, Herbst treatment implies lower costs and lower risks for the patient without increasing total treatment time (Pancherz & Ruf, 2000). Growth adaptation should be performed with removable functional appliances in children and adolescents with mixed dentition since these appliances are more effective and easier to handle in younger children. However, in adolescents who have their permanent dentition, postadolescents and in young adults, fixed functional appliances, such as the Herbst appliance, are usually indicated. The approximate age for young adulthood would be 18 to 24 years in females and 20 to 25 years in males. An upper age limit for successful Herbst treatment is, however, difficult to define. Konik et al. (1997) have concluded that the optimal timing for treatment of Class II, division 1 subjects with the Herbst appliance is the period after the pubertal growth spurt (in young adults with the permanent dentition) since the results are the most stable in Class I occlusion. The late Herbst treatment reduces the need for prolonged retention period after treatment and the possibility of relapse.

Camouflage orthodontics mainly comprises tooth sacrifice in the maxillary dental arch to create space for retraction of the anterior teeth. However, by this approach the skeletal Class II problem (mandibular retrusion) remains. Surgical correction implies that the mandible is advanced to a Class I skeletal jaw relationship using either sagittal split osteotomy or mandibular distraction osteogenesis. Occasionally, mandibular advancement is combined with maxillary setback surgery (Le Fort I). The philosophical question is based on potential iatrogenic sequelae for primarily cosmetic problem: "What price surgery?" (Pancherz & Ruf, 2000).

The mechanism of growth modification is critical because a specific soft tissue mechanism might guide clinicians to plan appropriate future treatments. Some day treatment could include genetic therapies for condylar growth modification. These technologies could be directed to the soft or hard tissues. This might lead to stable condyle-fossa growth modification in the long term that has been elusive so far. Voudouris et al. (2003) claim that the general functional matrix theory was vague and largely unproven. Their results indicate a more specific mechanism from the connective tissues and the fluids in the growth relativity concept that uses more than muscle function alone to explain and achieve the clinical results of Herbst therapy. Nowadays, at the beginning of the 21st century, we can claim the following: Fixed functional appliances (Herbst) produce consistent changes in the condyl-fossa complex that can be reproduced in comparison with the inconsistent results reported in the literature for removable functional appliances (Voudouris et al., 2003).

As for the future design of the Herbst appliance, there are three goals (Hanks, 2003): to reduce the number of emergency appointments (breakage, particularly with banded splints, disengagement), to increase patient comfort (hygiene, possible ulcerations of the mucosa on

the distal assembly) and to transform the Herbst into a more user-friendly appliance (easier access, particularly to distal assemblies).

6. Conclusion

The clinical effect of the Herbst appliance and Activator in treatment of Class II, division 1 malocclusions shows significant improvement of the occlusal relationships because of sagittal skeletal and dentoalveolar changes in both jaws.

Class II molar correction in patients treated by the Herbst appliance and Class II molar improvement in patients treated by the Activator, are results of forward mandibular movement and posterior movement of the maxillary molars.

Overjet correction in patients treated by the Herbst appliance and overjet reduction in patients treated by the Activator, result from the mandibular advancement, proclination of mandibular incisors and retroinclination of maxillary incisors.

The Herbst appliance is more efficient in the correction of Class II, division 1 malocclusion in the patients after pubertal peak of growth, compared to the Activator, due to more prominent skeletal, dentoalveolar and combined changes.

7. References

- Ahlgren, J. & Laurin, C. (1976). Late results of activator treatment: a cephalometric study. *Br J Orthod*, Vol. 3, pp. 181-187.
- Allen-Noble, P. (2003). Multifunctional Herbst Solutions. *Clinical Impressions*, Vol. 12, No. 2, pp. 26-27.
- Bastiftici, A.F.; Uysal, T.; Buyukerkmen, A. & San, Z. (2003). The effects of activator treatment on the craniofacial structures of class II/1 patients. *Eur J Orthod*, Vol. 25, No. 1, pp. 87-94.
- Baltromejus, S.; Ruf, S. & Pancherz, H. (2002). Effective Temporomandibular joint growth and chin position changes: Activator versus Herbst treatment. A Cephalometric roentgenographic study. *Eur J Orthod*, Vol. 24, No. 6, pp. 627-637.
- Bjork, A. (1951). The principle of the Andresen method of orthodontic treatment, a discussion based on cephalometric X-ray analysis of treated cases. *Am J Orthod*, Vol. 37, pp. 437-458.
- Chen, R.J.; Will, L. & Niederman, R. (2002). Analysis of efficacy of functional appliances on mandibular growth. *Am J Orthod Dentofacial Orthop*, Vol. 122, pp. 470-476.
- Chen, R.J. & Shen, G. (2003). The feasibility and reliability of Pancherz's analysis in evaluating the treatment effects of bite-jumping on skeletal class II malocclusion. *Shang J Stom*, Vol. 12, No. 4, pp. 256-259. *Am J Orthod Dentofacial Orthop*, Vol. 122, pp. 470-476.
- Cozza, P.; Bracceti, T.; Franchi, L.; De Toffol, T. & McNamara J.A. (2006). Mandibular changes produced by functional appliances in Class II malocclusion: a systematic review. *Am J Orthod Dentofacial Orthop*, Vol. 129, pp. 599- 12.
- Creekmore, T.D. & Radney, L.J. (1983). Fränkel appliance therapy: Orthopedic or orthodontic? *Am J Orthod*, Vol. 82, pp. 89-108.

- Cura, N.; Sarac, M.; Ozturk, Y. & Surmeli N. (1996). Orthodontic and orthopedic effects of Activator, Activator-HG combination and Bass appliances: A comparative study. *Am J Orthod Dentofac Orthop*, Vol. 110, pp. 36-45.
- Deicke, M. & Pancherz, H. (2005). Is Radius-Union an indicator for completed facial growth? *Angle Orthod*, Vol. 75, No. 3, pp. 287-291.
- DeVincenzo, J. (1991). Changes in mandibular length before, during and after successful orthopedic correction of Class II malocclusions, using a functional appliance. *Am J Orthod Dentofac Orthop*, Vol. 99, pp. 241-257.
- Dischinger, T. (1995). Edgewise Herbst appliance. *J Clin Orthod*, Vol. 29, No. 12, pp. 738-742.
- Dischinger, T. (1998). Full-face Orthopedic with One Multifunctional Appliance - No Cooperation Required. *Clinical impressions*, Vol. 4, No. 7, pp. 2-7.
- Du, X.; Hagg, U. & Rabie, B. (2002). Effects of headgear Herbst and mandibular step - by - step advancement versus conventional herbst appliance and maximal jumping of the mandible. *Eur J Orthod*, Vol. 24, No. 2, pp. 167-174.
- Fränkel, R. (1969). The treatment of Class II, division 1 malocclusion with functional correctors. *Am J Orthod*, Vol. 54, pp. 265-275.
- Graber, T.; Rakosi, T. & Petrovic, A. (1997). *Dentofacial orthopedics with Functional appliances*. Mosby.
- Hansen, K. & Pancherz, H. (1992). Long-term effects of Herbst treatment in relation to normal growth development: a cephalometric study. *Eur J Orthod*, Vol. 14, pp. 285-295.
- Hansen, K.; Koutsonas, K.T. & Pancherz, H. (1997). Long-term effects of Herbst treatment on the mandibular incisor segment: A cephalometric and biometric investigation. *Am J Orthod Dentofac Orthop*, Vol. 112, pp. 92-103.
- Hanks, S. (2003). Herbst therapy: Trying to get out of the 20th Century. *Good practice*, Vol. 4, No. 1, pp. 2-4.
- Harvold, E.P. & Vargervik, K. (1971). Morphogenetic response to activator treatment. *Am J Orthod*, Vol. 60, pp. 478-490.
- Howe, R.P. (1982). The bonded Herbst appliance. *J Clin Orthod*, Vol. 10, pp. 663-667.
- Howe, R.P. & McNamara, J.A. (1983). Clinical management of the bonded Herbst appliance. *J Clin Orthod*, Vol. 17, No. 7, pp. 456-463.
- Jacobsson, S.O. (1967). Cephalometric evaluation of treatment effect on Class II, Division 1 malocclusions. *Am J Orthod*, Vol. 6, pp. 446-457.
- Jacobsson, S.O. & Paulin, G. (1990). The influence of activator treatment on skeletal growth in Angle II, 1 cases. A roentgenocephalometric study. *Eur J Orthod*, Vol. 12, pp. 174-184.
- Jorgensen, S.E. (1974). Activators in orthodontic treatment: Indications and advantages. *Am J Orthod*, Vol. 65, pp. 260-269.
- Konik, M.; Pancherz, H. & Hansen, K. (1997). The mechanism of Class II correction in late Herbst treatment, *Am J Orthod Dentofac Orthop*, Vol. 112, pp. 87-91.
- Korkhaus, G. (1960). Present orthodontic thought in Germany. *Am J Orthod*, Vol. 46, pp. 270-287.

- Lin, J. & Gu, Y. (2005). Lower second molar extraction in correction of severe skeletal class III malocclusion. *Angle Orthod*, Vol. 76, No. 2, pp. 217-225.
- Luder, H.U. (1982). Skeletal profile changes related to two patterns of activator effects. *Am J Orthod*, Vol. 80, pp. 390-396.
- McNamara, J.A.; Howe, R.P. & Dischinger T.G. (1990). A comparison of the Herbst and Frankel appliances in the treatment of Class II malocclusion. *Am J Orthod Dentofacial Orthop*, Vol. 98, pp. 134-144.
- Milosavljevic, Z. (2006). *Treatment effects of Twin Block appliance in the therapy of Class II malocclusion*. Doctoral thesis, Belgrade, Serbia.
- Moreira, M.C.; Santos-Pinto, A.; Rosa Martins, C.; Martins, P. & Sakima T. (2003). Orthopedic and orthodontic components of Class II, division 1 malocclusion correction with Balters Bionator: A cephalometric study with metallic implants. *World J Orthod*, Vol. 4, pp. 237-242.
- Nelson, C.; Harkness, M. & Herbison P. (1993). Mandibular changes during functional appliance treatment. *Am J Orthod Dentofacial Orthop*, Vol. 104, pp. 153-161.
- O'Brien, K. at all. (2003). Effectiveness of treatment for Class II malocclusion with the Herbst or twin-block appliances: A randomized, controlled trial. *Am J Orthod Dentofacial Orthop*, Vol. 124, No. 2, pp. 128-137.
- O'Brien, K. at all. (2003). Effectiveness of early orthodontic treatment with the Twin-block appliance: A multicenter, randomized, controlled trial. Part 1: Dental and skeletal effects. *Am J Orthod Dentofacial Orthop*, Vol. 124, No. 3, pp. 234-243.
- O'Brien, K. & Wright, J. (2002). How to write a protocol. *J Orthod*, Vol. 29, No. 1, pp. 58-61.
- O'Reilly, T. & Yanneillo, G. (1988). Mandibular growth changes and maturation of cervical vertebrae - A longitudinal cephalometric study. *Angle Orthod*, Vol. 4, pp. 179-184.
- Pancherz, H. (1979). The mandibular plane angle in activator treatment. *Angle Orthod*, Vol. 49, pp. 11-20.
- Pancherz, H. & Stickel, A. (1980). Can 'articulare' be used in the cephalometric analysis of mandibular length? A methodologic study. *Eur J Orthod*, Vol. 10, No. 1, pp. 362-368.
- Pancherz, H. (1981). The effect of continuous bite jumping on the dentofacial complex: A follow-up study after Herbst appliance treatment of Class II malocclusions. *Eur J Orthod*, Vol. 3, pp. 49-60.
- Pancherz, H. (1982). The mechanism of Class II correction in Herbst appliance treatment. A cephalometric investigation. *Am J Orthod*, Vol. 82, pp. 104-113.
- Pancherz, H. (1984). A cephalometric analysis of skeletal and dental changes contributing to Class II correction in activator treatment. *Am J Orthod*, Vol. 85, pp. 125-134.
- Pancherz, H.; Malmgren, O. & Haag, U. (1989). Class II correction in Herbst and Bass therapy. *Eur J Orthod*, Vol. 11, pp. 17-30.
- Pancherz, H. (1989). Die Herbst-Apparatur in der modernen Kieferorthopadie, *Informationen*, Vol. 4, pp. 467-490.

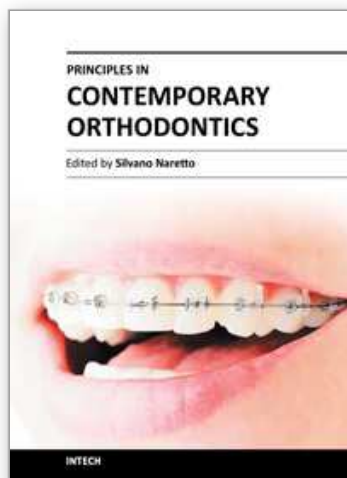
- Pancherz, H. (1991). The nature of Class II relapse after Herbst appliance treatment: A cephalometric long-term investigation. *Am J Orthod Dentofacial Orthop*, Vol. 100, pp. 220–233.
- Pancherz, H. & Anehus-Pancherz, M. (1993). The headgear effect of the Herbst appliance: A cephalometric long-term study. *Am J Orthod Dentofacial Orthop*, Vol. 103, No. 6, pp. 510–520.
- Pancherz, H. (1994). Das Herbstsche Scharnier, *Kieferorthop*, Vol. 8, pp. 125–131.
- Pancherz, H. (1997). The effects, limitations, and long-term dentofacial adaptations to treatment with the Herbst appliance. *Semin Orthod*, Vol. 3, No. 4, pp. 232–243.
- Pancherz, H.; Zeiber, K. & Hoyer, B. (1997). Cephalometric characteristics of Class II division 1 and Class II division 2 malocclusions: A comparative study in children. *Angle Orthod*, Vol. 2, pp. 111–20.
- Pancherz, H. & Ruf, S. (1999). Thomalske-Faubert C.: Mandibular articular disk position changes during Herbst treatment: a prospective longitudinal MRI study. *Am J Orthod Dentofacial Orthop*, Vol. 116, pp. 207–214.
- Pancherz, H. & Ruf, S. (2000). The Herbst Appliance: Research – based updated clinical possibilities. *World J Orthod*, Vol. 1, No. 1, pp. 17–31.
- Pancherz, H. & Fischer, S. (2003). Amount and direction of temporomandibular joint growth changes in Herbst treatment: A cephalometric long-term investigation. *Angle Orthod*, Vol. 73, pp. 493–501.
- Pancherz, H. & Michailidou, C. (2004). Temporoandibular joint growth changes in hyperdivergent and hypodivergent Herbst subjects. A long-term roentgenographic study. *Am J Orthod Dentofacial Orthop*, Vol. 126, No. 2, pp. 153–161.
- Pancherz, H.; Ruf, S.; Erbe, C. & Hansen K. (2004). The mechanism of Class II correction in Surgical Orthodontic treatment of Adult Class II, Division 1 malocclusion. *Angle Orthod*, Vol. 74, pp. 800–809.
- Pancherz, H. & Ruf, S. (2008). *The Herbst appliance*. Quintessence Publishing Co Ltd, Grafton Road, Great Britain.
- Paulsen, H.U. (1997). Morphological changes of the TMJ condyles of 100 patients treated with the Herbst appliance in the period of puberty to adulthood: a long-term radiographic study. *Eur J Orthod*, Vol. 19, pp. 657–688.
- Ruf, S. & Pancherz, H. (1996). Development of the frontal sinus in relation to somatic and skeletal maturity. A cephalometric roentgenographic study at puberty. *Eur J Orthod*, Vol. 18, pp. 491–497.
- Ruf, S. & Pancherz, H. (1998). Long-term TMJ effects of Herbst treatment: A clinical and MRI study. *Am J Orthod Dentofacial Orthop*, Vol. 114, No. 5, pp. 475–483.
- Ruf, S. & Pancherz, H. (1999). Temporomandibular joint remodeling in adolescents and young adults during Herbst treatment: A prospective longitudinal magnetic resonance imaging and cephalometric radiographic investigation. *Am J Orthod Dentofacial Orthop*, Vol. 115, pp. 607–618.

- Ruf, S. & Pancherz, H. (1999). Dentoskeletal effects and facial profile changes in young adults treated with the Herbst appliance. *Angle Orthod*, Vol. 69, pp. 239-246.
- Ruf, S. & Pancherz, H. (2000). Does Bite Jumping Damage the TMJ? A Orospective Longitudinal Clinical and MRI Study of Herbst Patients. *Angle Orthod*, Vol. 70, pp. 183-199.
- Ruf, S.; Baltromejus, S. & Pancherz, H. (2001). Effective condylar growth and chin position changes in Activator treatment: A cephalometric roentgenographic study. *Angle Orthod*, Vol. 71, No. 1, pp. 4-11.
- Ruf, S. & Pancherz, H. (2004). Ortognatic surgery and dentofacial orthopedics in adult Class II division 1 treatment: mandibular sagittal split osteotomy versus Herbst appliance. *Am J Orthod Dentofacial Orthop*, Vol. 126, pp. 140-152.
- Schavioni, R.; Grenga, V. & Macri, V. (1992). Treatment of Class II high angle malocclusion with the Herbst appliance: A cephalometric investigation. *Am J Orthod Dentofacial Orthop*, Vol. 102, No. 5, pp. 393-409.
- Shen, G. & Hagg, U. (2005). Darendeliler MA.: Skeletal effects of bite jumping therapy on the mandible – Removable vs. Fixed functional appliances. *Orthod Craniofacial Res*, Vol. 8, pp. 2-10.
- Siara-Olds, N.J.; Pangrazio-Kulbersh, V; Berger, J & Bayirli, B. (2010). Long-Term Dentoskeletal Changes with the Bionator, Herbst, Twin Block, and MARA Functional Appliances. *Angle Orthod*, Vol. 80, No. 1, pp. 18-29.
- Smith, R.J. (1998). Matching the Herbst to the malocclusion. *Clinical impressions*, Vol. 2, No. 7, pp. 6-12.
- Smith, R.J. (2000). How to improve practice efficiency and profitability. *Clinical Impressions*, Vol. 4, No. 4, pp. 6-21.
- Scepan I. (1997). *Functional appliances treatment effects of Class II malocclusions*. Doctoral thesis. Belgrade, Serbia.
- Valant, J.R. & Sinclair, P.M. (1989). Treatment effects of the Herbst appliance. *Am J Orthod Dentofacial Orthop*, Vol. 95, pp. 138-147.
- Von Bremen, J.; Bock, N. & Ruf, S. (2009). Is Herbst-Multibracket Appliance Treatment More Efficient in Adolescents than in Adults?. *Angle Orthod*, Vol. 79, No. 1, pp. 173-177.
- Voudouris, C.J.; Woodside, G.D. & Kuftinec, M.M. (2003). Condyle-fossa modifications and muscle interactions during Herbst treatment, Part 1. New technological methods. *Am J Orthod Dentofacial Orthop*, Vol. 123, No. 6, pp. 604-613.
- Voudouris, J.C. at all (2003). Condyle-fosa modifikations and muscle interactions during Herbst treatment, Part 2. Results and conclusions. *Am J Orthod Dentofacial Orthop*, Vol. 124, No. 1, pp. 13-29.
- White, L. (1994). Current Herbst appliance therapy. *J Clin Orthod*, Vol. 28, No. 5, pp. 296-309.
- Wieslander, L. & Lagerstrom, L. (1979). The effect of activator treatment on Class II malocclusions. *Am J Orthod*, Vol. 1, pp. 20-26.
- Windmiller, E. (1993). The acrylic-splint herbst appliance: A cephalometric evaluation. *Am J Orthod Dentofac Orthop*, Vol. 104, pp. 73-84.

- Weschler, D. & Pancherz, H. (2005). Efficiency of three mandibular anchorage forms in Herbst treatment: A cephalometric investigation. *Angle Orthod*, Vol. 75, No. 1, pp. 23-27.
- You, Q.L. & Hagg, U. (2002). A comparison of three cephalometric analysis on the evaluation of orthodontic treatment. *J Stomatol*, Vol. 11, No. 2, pp. 97-100.

IntechOpen

IntechOpen



Principles in Contemporary Orthodontics

Edited by Dr. Silvano Naretto

ISBN 978-953-307-687-4

Hard cover, 584 pages

Publisher InTech

Published online 25, November, 2011

Published in print edition November, 2011

Orthodontics is a fast developing science as well as the field of medicine in general. The attempt of this book is to propose new possibilities and new ways of thinking about Orthodontics beside the ones presented in established and outstanding publications available elsewhere. Some of the presented chapters transmit basic information, other clinical experiences and further offer even a window to the future. In the hands of the reader this book could provide an useful tool for the exploration of the application of information, knowledge and belief to some orthodontic topics and questions.

How to reference

In order to correctly reference this scholarly work, feel free to copy and paste the following:

Nenad Nedeljkovic (2011). Sagittal Skeletal and Occlusal Changes of Class II, Division 1 Postadolescent Cases in the Herbst and Activator Therapy, Principles in Contemporary Orthodontics, Dr. Silvano Naretto (Ed.), ISBN: 978-953-307-687-4, InTech, Available from: <http://www.intechopen.com/books/principles-in-contemporary-orthodontics/sagittal-skeletal-and-occlusal-changes-of-class-ii-division-1-postadolescent-cases-in-the-herbst-and>

INTECH
open science | open minds

InTech Europe

University Campus STeP Ri
Slavka Krautzeka 83/A
51000 Rijeka, Croatia
Phone: +385 (51) 770 447
Fax: +385 (51) 686 166
www.intechopen.com

InTech China

Unit 405, Office Block, Hotel Equatorial Shanghai
No.65, Yan An Road (West), Shanghai, 200040, China
中国上海市延安西路65号上海国际贵都大饭店办公楼405单元
Phone: +86-21-62489820
Fax: +86-21-62489821

© 2011 The Author(s). Licensee IntechOpen. This is an open access article distributed under the terms of the [Creative Commons Attribution 3.0 License](https://creativecommons.org/licenses/by/3.0/), which permits unrestricted use, distribution, and reproduction in any medium, provided the original work is properly cited.

IntechOpen

IntechOpen