

# We are IntechOpen, the world's leading publisher of Open Access books Built by scientists, for scientists

6,900

Open access books available

186,000

International authors and editors

200M

Downloads

Our authors are among the

154

Countries delivered to

TOP 1%

most cited scientists

12.2%

Contributors from top 500 universities



WEB OF SCIENCE™

Selection of our books indexed in the Book Citation Index  
in Web of Science™ Core Collection (BKCI)

Interested in publishing with us?  
Contact [book.department@intechopen.com](mailto:book.department@intechopen.com)

Numbers displayed above are based on latest data collected.  
For more information visit [www.intechopen.com](http://www.intechopen.com)



# Treatment of Class II Deep Overbite with Multiloop Edgewise Arch-Wire (MEAW) Therapy

Paulo Beltrão  
French Board Of Orthodontics  
Portugal

## 1. Introduction

The deepbite occlusion together with a deepbite skeletal pattern is difficult to treat, and the time needed for treatment is long because of patient's strong muscle pattern.

Apart from genetic factors some of the reasons for the frequent appearance of class II anomalies of the bone structure are mouth breathing and muscular malfunctioning in the environment of the oral cavity. However, 3 factors of class II are likely to be the most important ones associated with the adaptation of the mandible and the occlusal function. The 3 factors are:

1. Insufficient height of bite
2. Strong inclination of the occlusal plane
3. Lacking of occlusal support and pressure of mandibular joint

The upper dentition of people who have class II malocclusion have insufficient vertical dimension on the molar area and steepening of the upper posterior occlusal plane. Due to these occlusal interferences in the molar area, the mandible cannot adapt anteriorly. Instead, it adapts posteriorly, aggravating the distocclusion. The loss of the posterior support causes the condyle to be compressed and decreasing or suppressing condylar growth.

Sassouni and Nanda (1964) proved the vertical disproportion were, in many cases, at the origin of anteroposterior dysplasias. Therefore, treatment strategies should focus on vertical control in order to correct anteroposterior disharmony.

Actually, 70% of the class II malocclusion does not imply the protrusion of the maxilla but it is known to be caused by retrusion of the mandible (McNamara 1982).

Mandibular growth is possible by allowing the functional anterior adaptation of the mandible (Carlson 1985, Moss 1971, McNamara 1979 and 1987).

Morphological characteristics of the class II deep overbite are: the mandible is small and retruded; small vertical dimension and insufficient occlusal support; accentuated curved of spee with two occlusal plane (flat occlusal plane in the upper anterior area and steepening of the occlusal plane in the upper posterior area); occlusal interference in the molar area, labial tipping of the upper anterior tooth; functional failure due to poor anterior guidance. The skeletal feature of the class II deep overbite malocclusions are closely related to the deviation in the vertical aspect of the occlusion. According to this, correcting the occlusal plane by controlling the vertical dimension is extremely important in the treatment of class II deepbite malocclusion. The treatment's purposes for class II deepbite are: Eliminate

pernicious habits and respiratory problems; Increase the vertical dimension (upper and lower molar eruption); To rebuild and flatten the upper posterior occlusal plane; Eliminate the discrepancy in the upper and lower dental arch width; Reposition the mandible forward; Improve overbite (deepbite) and obtain an appropriate occlusal and anterior guidance; Obtain normal intercuspitation and acquire an excellent profile.

The treatment of low-angle class II malocclusions must prevent occlusal interference and extrude the upper molars to increase their vertical height and flatten the occlusal plane. The lower dentition, especially the premolars are extruded to increase vertical height and to reduce the excessive curve of spee. As result, the mandible readapts to the physiological position and the occlusal function is restored. This kind of treatment will help to overcome many of the existing problems when we treat class II malocclusion in non-growing patients and provide the means to establishing functional occlusion in cases that are difficult to treat. The steps of the class II deep overbite malocclusion are: Levelling; Eliminate of occlusal interference; Establishing mandibular position; Reconstruction of the occlusal plane; Achieving a physiological occlusion.

2. The multiloop edgewise arch wire (MEAW)

The MEAW was developed in 1967 by Young H. KIM as a mean for correcting marked open bite malocclusion and has been found to be extremely effective.

Further development of MEAW Technique extends its applications to treat any type of malocclusion, especially during the final stage of the treatment.

The MEAW's are constructed with .016x.022 stainless steel (bracket 0.018 - inch slot) or .017x.025 ss (bracket 0.022 - inch slot).

The arches have ideal arch form with five loops on each side of the arch.

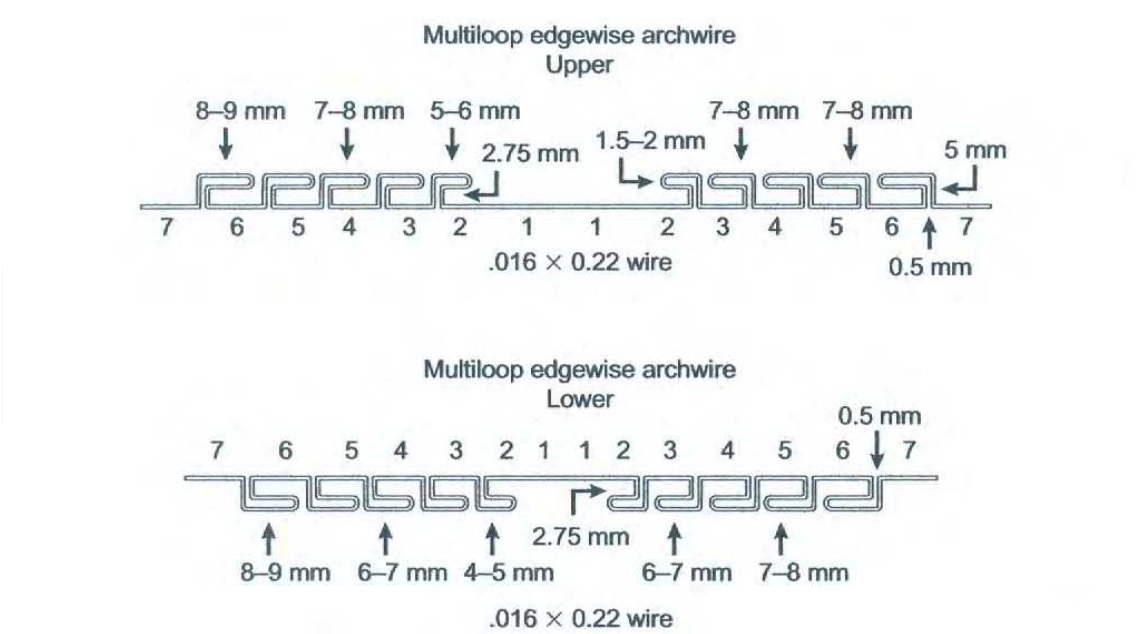


Fig. 1. Upper and lower multiloop edgewise archwire (MEAWs)

2.1 Functions of the loops on each side of the archwire

- a. The loops between the teeth reduce the load deflection rate (LDR) of the wire significantly, providing a low but continuous orthodontic force of the teeth. The relative

LDR of the MEAW compared to a stainless steel wire without loops is 40%, 32% for TMA, 28% for sentalloy and 20% for nitinol.

- b. The horizontal loop allows an easier control of movement for each tooth.
- c. The vertical component serves as a “breaker” between the teeth and allows teeth to move independently.
- d. Makes the alignment and intrusion of the supra erupted tooth as well as the torque adjustment easy.
- e. The tip back activation in the posterior segment of the wire produces the uprighting of the posterior teeth. Fifteen degrees of molar uprighting produce as much as 4,5mm of distalization of the teeth.
- f. With the aid of the elastics, it can reconstruct the occlusal plane.

An experimental study developed by Lee and Co-Workers (1995) of Seoul National University using the MEAW on Rhesus monkeys showed that marked tooth movement occurred along with considerable bone remodelling cellular activity, while on a control group of monkeys with a standard ideal arch-wire of the same size showed insignificant cellular activity with signs of root resorption.

To create an ideal arch with multiloops extended from the distal of lateral incisors to mesial of second molars, the ideal arch wire length is 2,5 - 3 x the length of the usual arch wire. This would decrease the orthodontic force by 1/5 and at the same time continuously applies an orthodontic force to the teeth. Activation of the wire involves the incorporation of progressive reverse curve onto the arch wire (second order bend). The tip back activation creates side effects; which must be counteracted by adding progressive buccal root torque and toe in. To incorporate the torque in upper arch, it is necessary to grab the wire at the distal portion of the canine with KIM plier and tilt the second loop 3 degrees laterally. It is necessary to do the same for the third, the fourth and the fifth loop to provide a gradual torque and to keep the loops away from the gingival tissue.

The progressive buccal root torque (third order bend) and the toe in (first order bend) are important to counteract the side effects of the tip back activation.

The tip back activation produces an intrusive force which is buccal of the centre of resistance of the posterior teeth and can create flaring of the posterior teeth and deformation of the arch wire. The use of vertical short class II elastics is necessary to produce the desired vertical and distal movement of the tooth segment in order to rebuild the occlusal plane and the sagittal relationship of the dentition. Since the wire is a relatively soft stainless steel, it should be heat treated, approximately at 500°, with the use of an electro-polishing treatment (to increase the resiliency), before the MEAW being inserted into the patient's mouth.

In the absence of a furnace, an alcohol lamp can be used. Heat the wire until the colour changes to golden brown. The colour must be even.

### 3. Cephalometric analysis

#### KIM'S METHOD ANALYSIS

- ODI (overbite depth indicator)
- APDI (anteroposterior dysplasia indicator)
- CF (combination factor)

#### 3.1 ODI- Overbite depth indicator

In 1978 Dr. KIM after studying cephalograms of 119 patients with normal occlusion and 500 various malocclusions, he selected fifteens cephalometric measurements to determine which

produced the highest correlation with the incisal overbite depth. The ODI is a combined measurement of two angles: the A-B plane to the mandibular plane (MP) and the palatal plane (PP) to the Frankfort horizontal (FH) plane. When the palatal plane slopes upward and forward in relation to the FH plane, it is read as a negative angle and this value is subtracted from the A-B to the mandibular plane angle.

When the palatal plane slopes downward and forward in relation to the FH plane, it is read as a positive angle and this value is added to the A-B to the mandibular plane angle. There is a norm of 74.5 degrees and with a standard deviation of 6.07. A value of 68° or less indicates a skeletal openbite tendency. A value of 80° or more indicates a deepbite skeletal pattern, and extraction of permanent teeth should be avoided, if possible, due to the strong potential to deepbite relapse. This skeletal pattern needs as much dental support as possible.

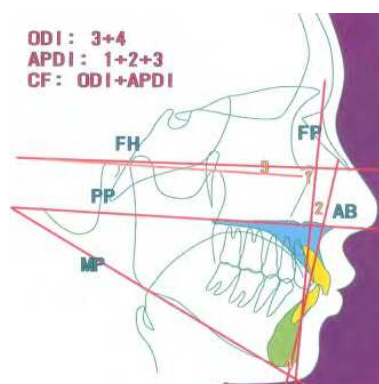


Fig. 2. Kim analysis (4-MP-AB angle)

### 3.2 APDI-anteroposterior dysplasia index

The APDI is determined from three angles: the facial plane angle (HF/FP (Na-Pog)), plus or minus the A-B plane angle (Downs), and plus or minus the palatal plane angle in relation to the FH plane, which is geometrically equivalent to the PP-AB.

PP-AB is apparently the antero-posterior relationship of the maxillary and mandible.

The normal mean of the APDI is 81, 4 degrees. The smaller the APDI value becomes in relation to the normal mean (81.4 degrees) the greater the probability of a distocclusion exists. Conversely, as the APDI value increases above the normal mean, the greater the probability of a mesiocclusion being present. The APDI is a measure of skeletal class II or III tendency, and reflects the horizontal discrepancies of a malocclusion.

The APDI reflects the treatment potential of a patient, because the APDI can be changed by growth and treatment. According to Kim (Kim and Vietas, 1978) APDI must be near 81° at the end of treatment, unless a strong relapse tendency will be present.

### 3.3 Combination factor

The combination factor (CF) is a combination of ODI and APDI.

A high CF ( >155°) indicates a tendency for low angle and a skeletal pattern that has the potential to accommodate all of the teeth.

A low CF ( <155°) shows the tendency for high angle and the need for tooth extraction is higher.

When the CF falls below 150° that indicates the teeth cannot be retracted due to a lack of posterior vertical space and indicates that extraction of some teeth is probable.



The CF factor indicates if a patient has the potential to be treated with an extraction or non-extraction protocol.

#### 4. The dynamic mechanism of the skeleton and the growth of the maxilla

The craniofacial bones are joined together by sutures or synchondrosis. These sutures allow slight relative movements.

The sphenoid is the principal central bone of the cranial base and makes the synchondrosis ethmosphenoidal with the ethmoid (fuses at 7-8 years old) and synchondrosis sphenoccipital (fuses in late puberty 18-20 years old) with the occipital.

According to Hooper (1986) the sphenobasilar articulation is the most important among the cranial bones and it is where the movement of flexion-extension occurs.

The degree of basicranial flexion differs in the various types of malocclusion. The cranial base angles (Na-S-Ar) comes to approximately  $124,2 \pm 5,2$  in class I patterns.

From this average value a more obtuse (extension) angle indicates skeletal Class II and a more acute (flexion) angle means skeletal Class III. The rotating movement of the cranial base (flexion/extension) occurs at the sphenoccipital articulation and it is transmitted to the maxilla through the Vomer. This dynamic mechanism has a great influence on the growth pattern of an individual during the growth period.

When the sphenoid makes flexion the rotating force of the vomer is posteroinferior and the maxilla is strongly pushed inferiorly. This causes vertical elongation of the maxillary complex, short antero posterior dimension and posterior crowding. This is related to the development of a class III skeletal frame (Sato 2001).

When the rotating movement of the sphenoid is extension the vomer will rotate anteriorly and the maxilla will be strongly pushed anteriorly. This movement of the maxilla causes anterosuperior tipping of the palatal surface and labial tipping in the anterior teeth, long anteroposterior dimension due growth of the posterior area of the maxillary tuberosity. This creates space for the downward movement of the tooth buds and eliminates the posterior crowding. This is typically seen in the development of Class II skeletal frame (Sato 2001).

According to Precious et al (1987) there are three types of maxillary growth and each growth pattern is closely related to the development of malocclusion: 1) translation with the frontal bone; 2) vertical elongation and 3) anterior rotation, which both advances and elongates the inferior part of the maxilla.

The maxillary also laterally rotates (internal and external rotation). In the internal rotation, the incisive bone is pushed forward because the length of the dental arch is increased and the width is decreased. This results in a deep palate typical of the Class II division malocclusion.

External rotation of the maxilla decreases the length and increases the width of the dental arch and creates a shallow palate. This is typical in class III malocclusion.

#### 5. Occlusal function and mandibular growth

In the 1970's several studies (Petrovic, Carlson, McNamara, Woodside) showed the possibility of modifying the mandibular growth pattern if it was related with its function - McNamara, Graber, Harvold, Bass (1970's) showed that the amount of mandibular growth changes due to cell proliferation in the condyles was related to occlusal function changes.

Petrovic (1975) created his cybernetic model of mandibular growth with the concept of Moss's functional Matrix Theory as its basis. The most important aspect in the cybernetic model was that occlusal function was an important factor in mandibular growth. According to him the maxillary antero inferior growth functionally "shifts" the mandibula and the TMJ adapts to the new position by secondary growth of the condyles.

In the pubertal and post pubertal period the principal factor that influences the skeletal craniofacial growth is the occlusal function, rather than the heredity. According to this, it's important to improve the occlusal function to prevent the abnormal growth.

Therefore, the early orthodontic treatment is important to take advantage of the benefits of the period of growth, in order to obtain the harmony of maxilla facial skeleton growth.

## 6. Relation of the vertical dimension with mandibular growth

The increase in the vertical dimension and mandibular growth are closely related. When there is an increase or decrease in vertical dimension, the mandible adapts through functional displacement. If the functional displacement is persistent the TMJ adapts by secondary growth of the condyle and produces a displacement of the skeletal morphology.

Shudy (1964) reported the relationship of the vertical growth of the craniofacial skeleton and mandibular rotation.

When the increase of the vertical dimension is bigger than the growth of condyle the result is backward rotation of the mandible and anterior openbite. When the increase of the vertical dimension is lesser than the growth of the condyle, the result is forward rotation of the mandible and anterior deepbite.

## 7. The development process of skeletal class II low angle malocclusion

The craniofacial skeleton is a dynamic mechanism.

The functional force due to mandibular function like mastication, swallowing etc...is transmitted by the neuromuscular system and temporomandibular joint (TMJ) to the temporal bone. The temporal bone reacts with internal or external rotation and affects the rotating movement of the sphenotemporal articulation and the temporal-occipital articulation. The rotation movement of the sphenoid is transmitted through the Vomer to the maxillary and then the mandible will functionally adapts to the upper occlusal surface.

The whole facial bone is secondarily affected once the mandibular movement is transmitted to the temporal bone.

This produces a cycle (feedback regulatory mechanism).

When the degree of the cranial base is extension, the sphenoid bone through the vomer will strongly push the maxilla protrusively. The protrusive rotation of the maxilla will stimulate the anteroposterior growth of the maxilla.

The growth in the tuberosity area allows the elimination of the posterior discrepancy. According to this the maxilla has a good anteroposterior growth and a feeble vertical growth. The protrusive rotation of the maxilla secondarily produces the labial tipping of the maxillary anterior teeth axis and space between them (typical in class II division one malocclusion).

The consequence of a poor maxillary vertical height is:

- Insufficient height of bite
- Lacking of occlusal support

- Strong inclination of the posterior occlusal plane

The inclination of the upper occlusal plane is determined by:

- a. Growth and rotation of the sphenoid and maxillary bone
- b. Vertical growth of the maxillary alveolar bone (Hyun-Sook Kim 2004 )

A lesser increase in vertical dimension than the growth of the mandibular ramus results in anterior rotation of the mandible (increasing the deepbite). In this condition, the posterior occlusal plane of the maxilla always shows a strong tipping and the mandible usually adapts posteriorly aggravating the distocclusion.

The mandibular distocclusion increases the pressure in the TMJ and decreases the condylar growth. The occlusion consequently becomes deep, increases the occlusal force and the pressure to the temporal bone increases too.

The temporal bone reacts with internal rotation, which increases the extension of the neurocranial base. The treatment objective of class II deepbite is to break this vicious cycle, rebuilding the occlusal plane.

## 8. General characterization of low angle class II malocclusion

McNamara and Moyers et al have suggested that the fundamental problems in the balance of craniofacial skeletal structures in class II malocclusion are due to mandibular retrognathism rather than maxillary prognathism.

The skeletal features of class II malocclusion are not characterized by overgrowth of the maxilla, but rather by restrained growth of the mandible.

The mandible is small with short corpus length and retruded, accentuated curve of spee with two occlusal planes (flat occlusal plane in the upper anterior area and steep occlusal plane in the upper posterior area), occlusal interference in the molar area, labial tipping of the upper anterior teeth, lip incompetence, small vertical dimension and insufficient occlusal support, insufficient eruption of the molar teeth (infraeruption), anterior inclination of the condyle (class II high angle has posterior inclination of the condyle), deep overbite; small gonial angle (GOA), small LFH (lower facial height).

Sadao Sato et al in a study (2004) about morphological characterization of different types of class II malocclusion, selected three groups of twenty adults in each group (10 males and 10 females). One group with normal occlusion and no missing teeth and two other groups of untreated high and low angle class II malocclusion subjects.

The results of skeletal features of the low angle class II groups were: LFH (lower facial height), gonial angle (GOA) and APDI were significantly smaller than those of the normal group. The ODI (overbite depth indicator) were significantly larger than the same measures in the normal group and the high angle class II group.

The corpus length were significantly smaller than those of the normal group, indicating that small and retruded mandibles are typical of class II group (high-angle and low-angle). The condylar axis in the low-angle class II group was inclined upward from back to front.

The anterior and posterior cranial base length were both long and the cranial angle base was long (extension) too. The morphology of pterygopalatine fosse was curve, the floor of maxillary sinus was high, the floor of nasal cavity was flat, the palatal plane (PP) had posterior tipping, the anteroposterior dimension of maxilla was long, and steepening of the posterior occlusal plane.

The results of dental pattern of the low angle class II group were: the vertical height of every upper teeth were significantly smaller than those of the normal group and the vertical



height of incisors canines and premolars were significantly smaller than those of the high angle class II group.

The values of vertical height of the lower teeth of the low angle class II were: short vertical height of incisors, canines and premolars, especially the first premolar, were always short and it causes an excessive curve of spee.

The skeletal features of the class II malocclusion are closely related to the deviation in the vertical aspect of the occlusion.

In the treatment of class II malocclusion the correction of the occlusal plane by controlling the vertical dimension is very important.

## **9. Treatment of class II low angle based on the dynamics of the craniofacial skeleton**

The skeletal features of class II malocclusion are closely related to the handicaps in the vertical aspect of the occlusion.

FUSHIMA el AL (1989) measured the vertical height of posterior teeth in subjects with mandibular asymmetry. He found that the vertical height of posterior teeth on the side toward which the mandible had shifted was lower than the contralateral dental height.

The treatment of low angle class II malocclusion must prevent occlusal interferences and extrude upper molars to increase the vertical dimension and flatten the occlusal plane. Once vertical dimension changes the mandible adapts through functional displacement.

According to Dawson (1989) the inclination of the occlusal plane must match the anteroposterior inclination of the condylar trajectory and the guidance of lingual concavity of the upper incisors.

The lower dentition, especially the premolars are extruded to increase the vertical dimension and to level the curve of spee. As a result, the mandible moves forward to the physiological position and the occlusal function is improved.

The advancement of the mandible followed by condylar growth and adaptive remodelling of the TMJ are desirable in order to improve the profile. This kind of treatment is very useful when we treat non-growing patients with class II low angle malocclusion.

However, it is very important to treat the patients during the period of good growth and development to increase the results. According to this, we use a double arch wire (DAW) to control the vertical dimension from the mixed dentition period to the permanent dentition.

### **9.1 The treatment goals for class II deepbite are**

- Elimination of the pernicious habits and respiratory problems
- Increase vertical dimension
- Rebuild and flatten the upper posterior occlusal plane
- Eliminate the discrepancy in upper and lower dental arch width
- Reposition the mandible forward in a physiological position
- Inhibition of the VICIOUS CYCLE
- Improve overbite (deepbite)
- Obtain normal intercuspidation and excellent profile

### **9.2 The treatment steps of class II deepbite malocclusion are**

1. Levelling;
2. Elimination of occlusal interferences;

3. Establishing mandibular position;
4. Reconstruction of the occlusal plane;
5. Achieving a physiological occlusion .

**9.2.1** The first step is the leveling (0.016 round wire SS) to start the correction of the mandibular curve of spee.

**9.2.2** Elimination of occlusal interferences (cuspal and occlusal interferences) with 017x.025 MEAWS arch wire (bracket with slot 0.022 inch ) step down bend (premolars) for maxillary bite rising and step up bend (premolars) for mandibular bite rising, with reverse curve in the mandible. The reverse curve in the mandibular arch wire is to eliminate the posterior molar interference with the alignment of lower second molar.

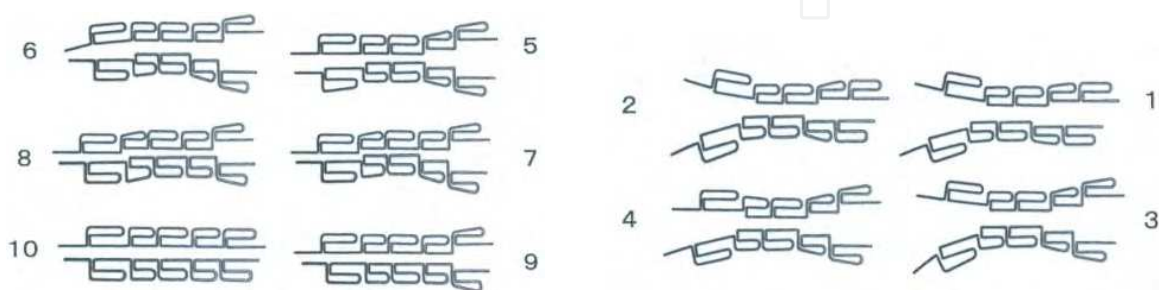


Fig. 3. Sequence of class II deep bite treatment

#### Case report 1

Patient male 13 years old and 5 months of age, with skeletal class II and dental class II/1 on a hypodivergent face pattern, mandibular retrognathism, deepbite (10mm), overjet (12mm), curve of spee deep with steep occlusal plane in the molar area producing interference in the posterior area, insufficient occlusal support due to absence of 46 and 36. The patient began the treatment with 13 years old and 5 months and the duration of the treatment was 27 months. The type of appliance was a edgewise multi-bracket 0,022x0,028 slot, 0° torque, 0° angulation, high pull head gear (HPHG) and MEAWs arch wires. The appliance was removed in July 2008 (15Y+9M).

The purpose of this treatment for this patient with class II deepite malocclusion was the elimination of the posterior interference and bite raising to produce anterior adaptation of the mandible and secondarily to induce mandibular growth.

The steps of the treatment:

- a-Leveling; b-Elimination of occlusal interferences ; c-Establishing mandibular position ;  
d- Reconstruction of the occlusal plane; e- Achieving a physiological occlusion.

Step one - Leveling (alignment, mesialization of 47 e 37, use of HPHG with j hooks with application point in the anterior zone (to produce intrusion of the upper incisors), upper arch 0,017x0,025 ss, 0.016 ss lower arch followed by 0.018x0,025 ss with "shoe horn" to mesialize 37 and 47.

Step two - Elimination of occlusal interferences, use of the same lower arch and 0,017x0,025 multiloop edgewise arch wire (MEAW) in the maxillary, use of short class II ,3/16 inch, 6oz elastics on both side and the HPHG was discontinued.

Step three - Establishing mandibular position: the space in the mandible was closed and step down bend (in the premolars) was done in the upper MEAW to bite rising (use of short class II 3/16 inch, 6oz elastics). Step up bend in the lower arch was done. At the end of this phase the molar occlusion was in class one.

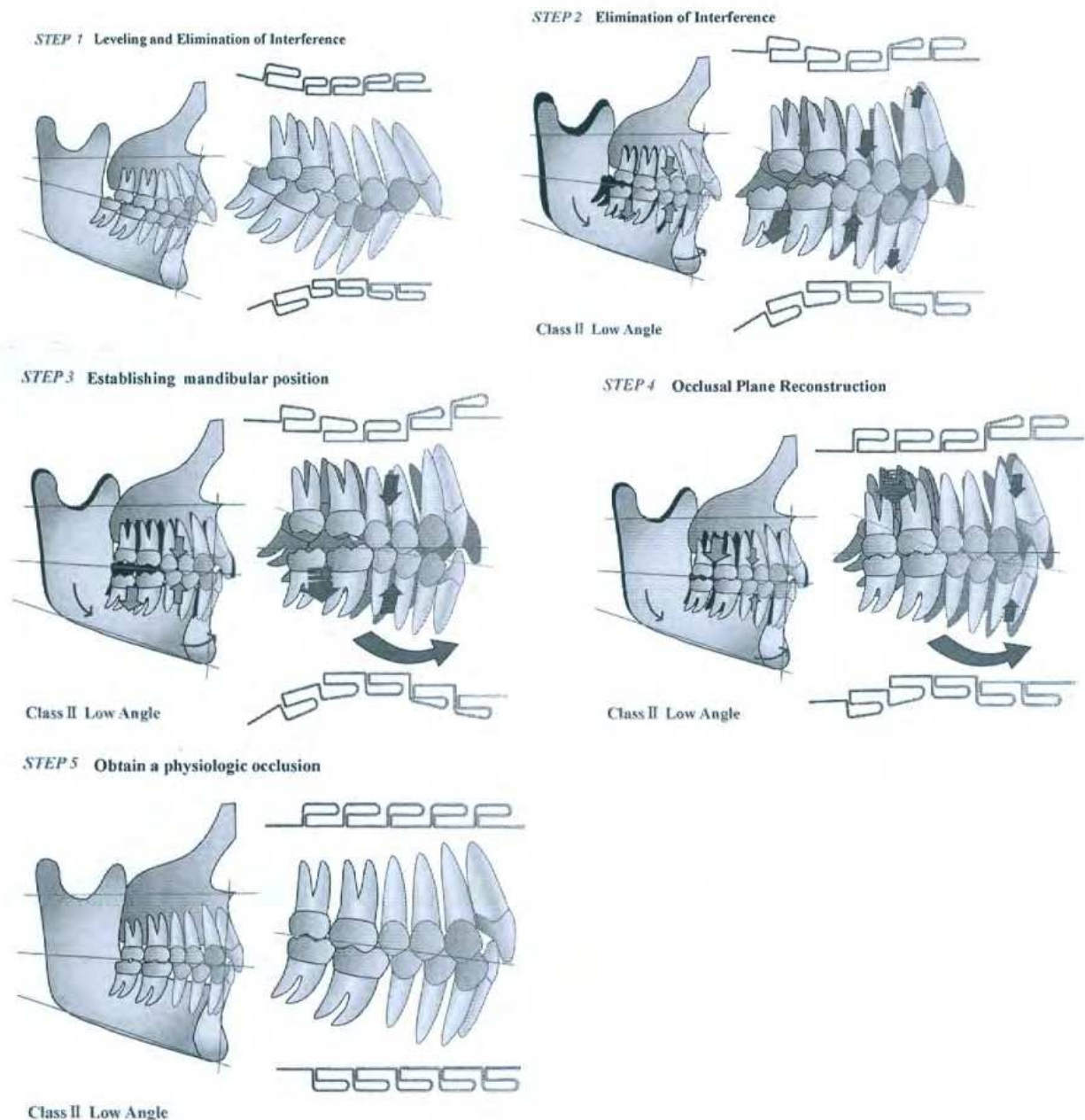


Fig. 4. Sequence of class II deep bite treatment (Sato 2008)

Step four/five - Reconstruction of the occlusal plane and achieving a physiological occlusion: flatten the occlusal plane in the molar area - "artistics bends" in the anterior upper area.

The retention phase was done with maxillary Hawley plate for night time use (6months) and bonded lingual wire from 33 to 43.

Post-treatment results show a well balanced face, nice profile and a pleasant smile. The intra-oral photo show a good class I relationship, overbite and overjet have been corrected. The mandibular superposition shows a slight protusion of the lower incisors. The APDI of 81° is a guarantee of stability.

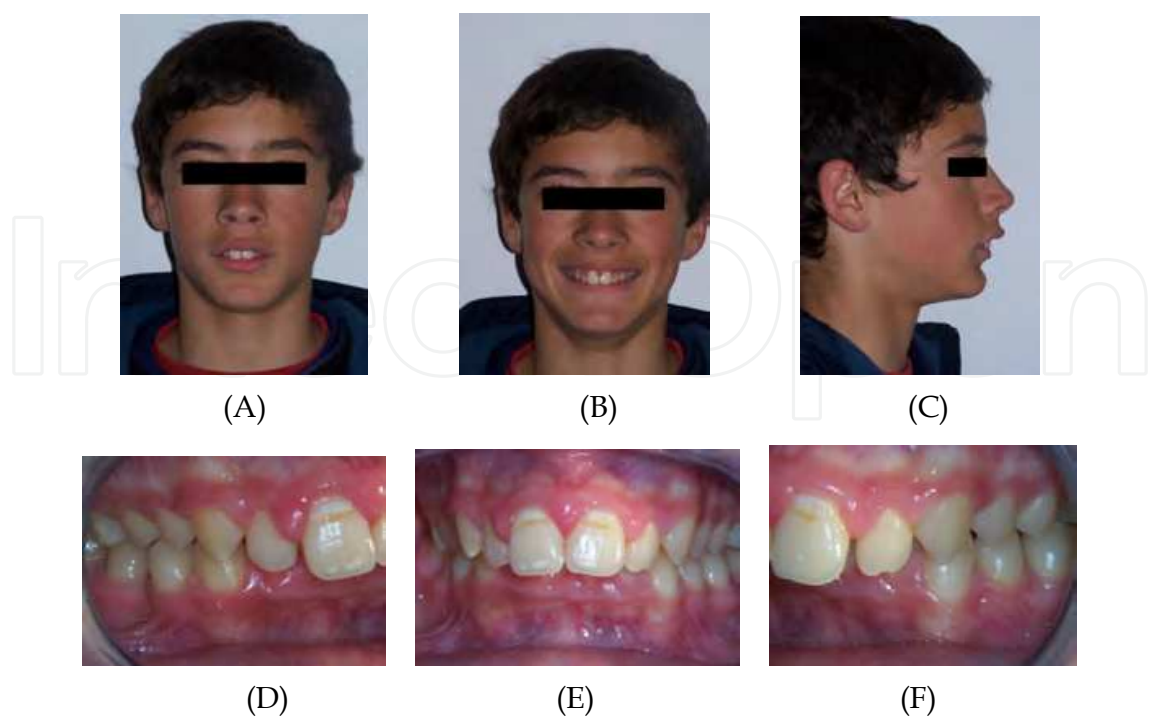


Fig. 5. Pre-treatment extraoral (A - B) and intraoral (D - F) photographs

	Range	Beginning	End of treatment		End of retention	
FMIA	67°+- 3	65	60		61	
FMA	25°+- 3	20	21		21	
IMPA	88°+- 3	95	99		98	
SNA	82°+- 2	78	76		76	
SNB	80°+- 2	70	73		73	
ANB	2°-+ 2	8	3		3	
Ao-Bo	2mm	8mm	4mm		4mm	
OP	10°-14°	7	4		4	
Z	75°+-5	67	74		74	
PFH	45mm	46	52		52	
AFH	65mm	66	75		75	
INDEX	0,69	0,69	0,69		0,69	

Table 1. Cephalometric analysis (Tweed- Merrifield)

	Beginning		End of treatment		End of retention	
ODI	MP/AB 87	84	78	77	80	79
	FH/PP -3		-1		-1	
APDI	HF/FP 88	70	90	81	90	80
	FP/AB -15		-8		-9	
	HF/PP -3		-1		-1	
CF	ODI+APDI	154		158		159

Table 2. Cephalometric analysis ( Kim



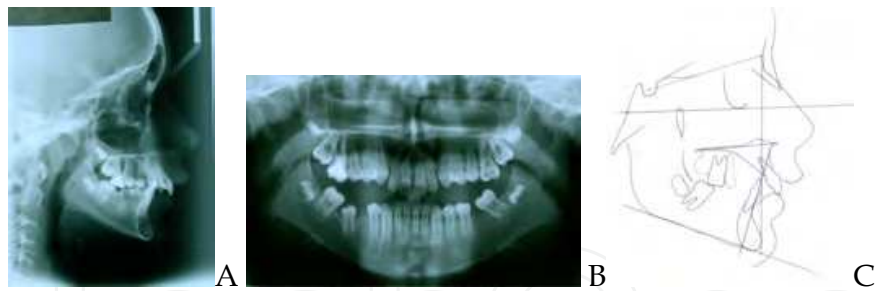

Fig. 6. Pre-treatment records

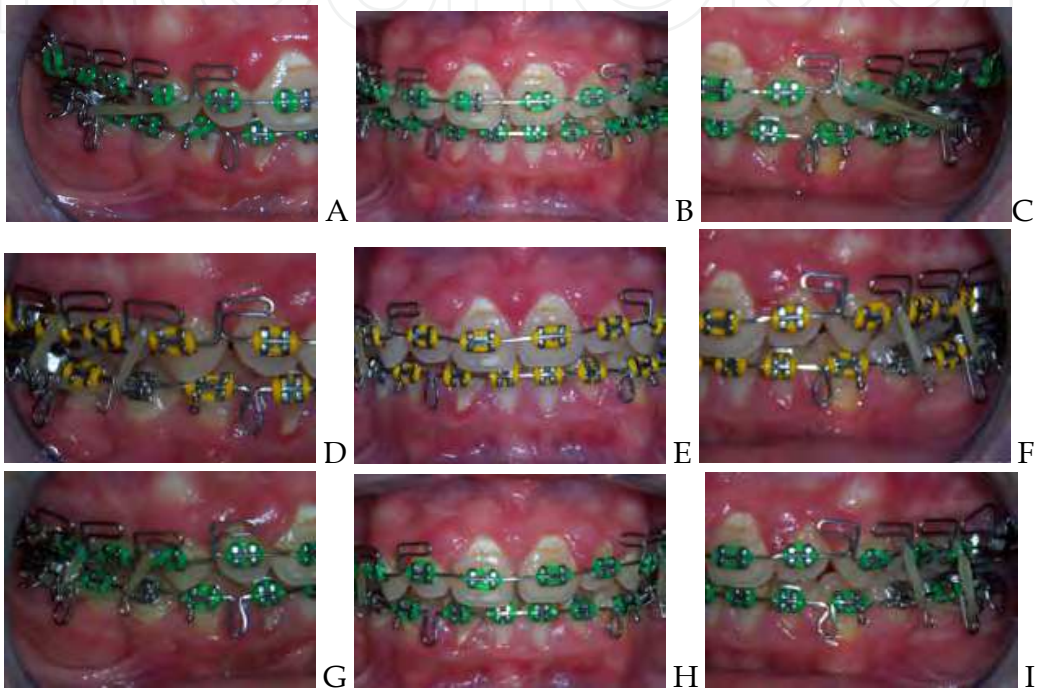


Fig. 7. Photos during the treatment (A -I)

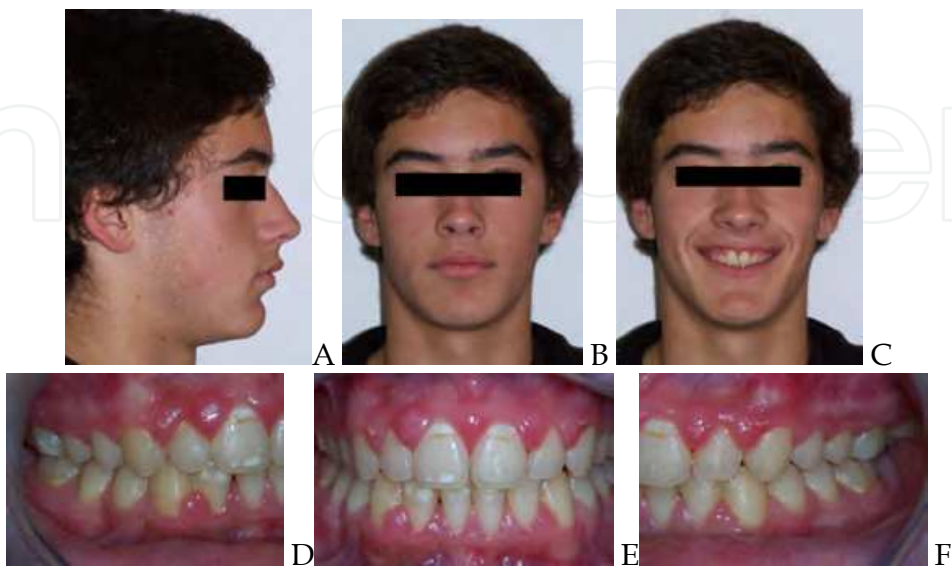


Fig. 8. Post-treatment extraoral (A-C) and intraoral (D-F) photos



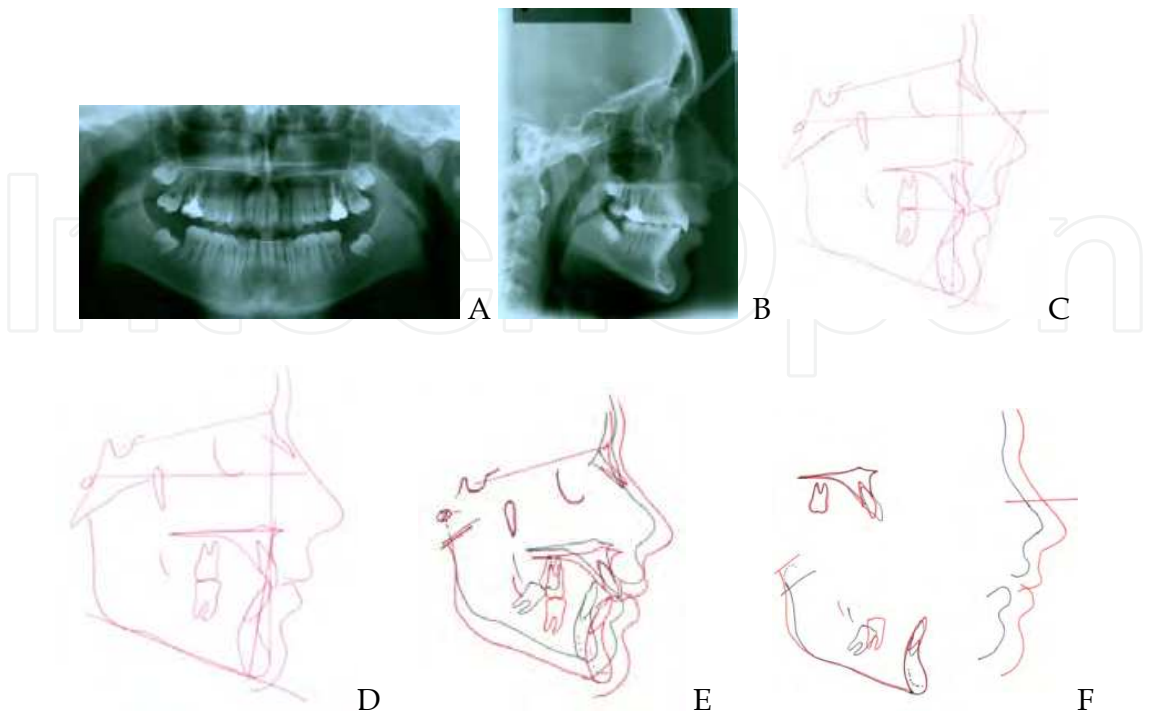


Fig. 9. Post-treatment records (A-D),superimpositions (E-F)

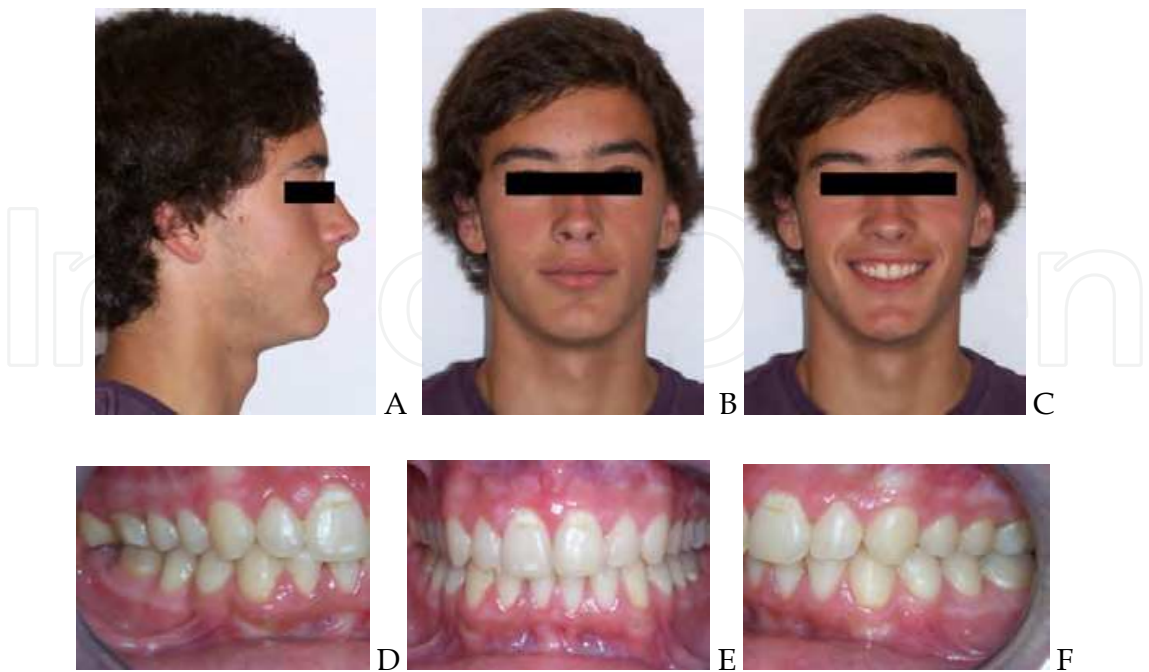


Fig. 10. Post-retention extra oral photos (A - C) and intraoral photos (D-F)

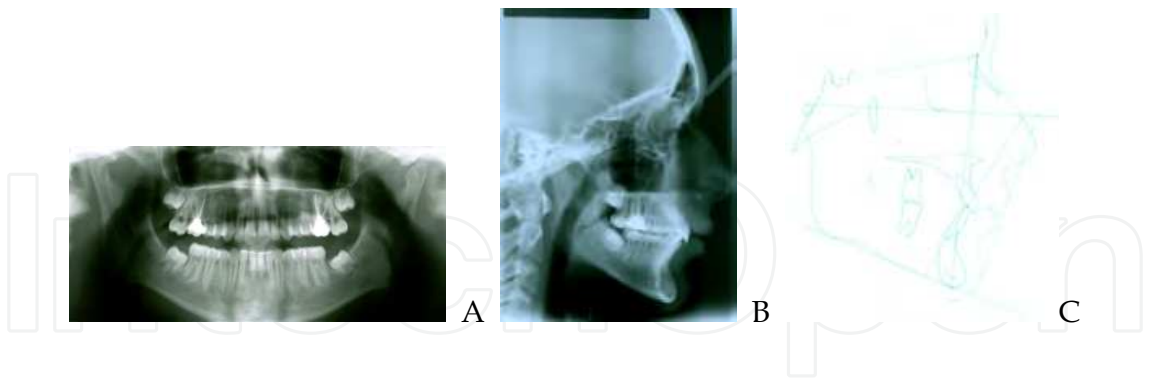


Fig. 11. Post-retention records (A - C)

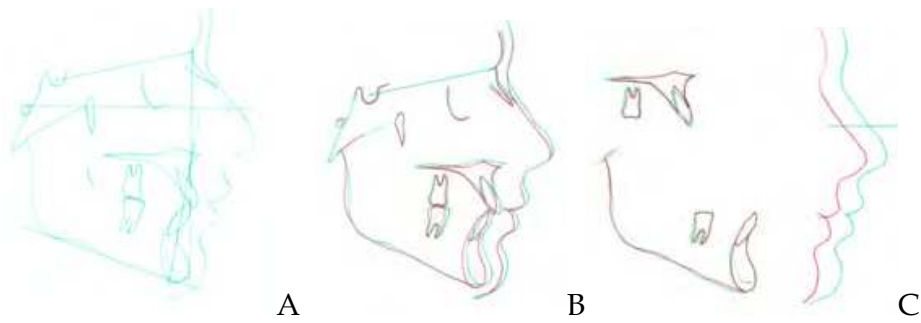


Fig. 12. Superimpositions (A- C)

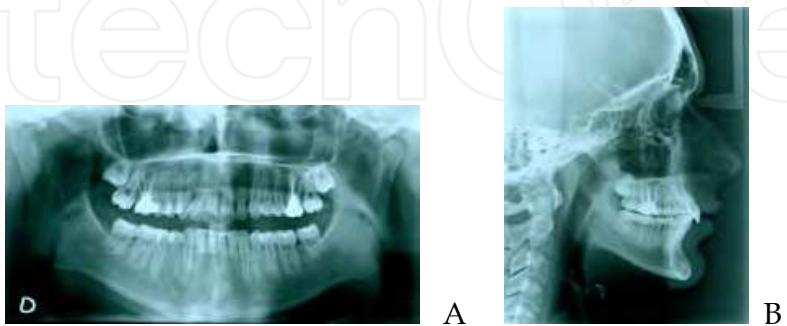


Fig. 13. 30 months post-treatment radiographs

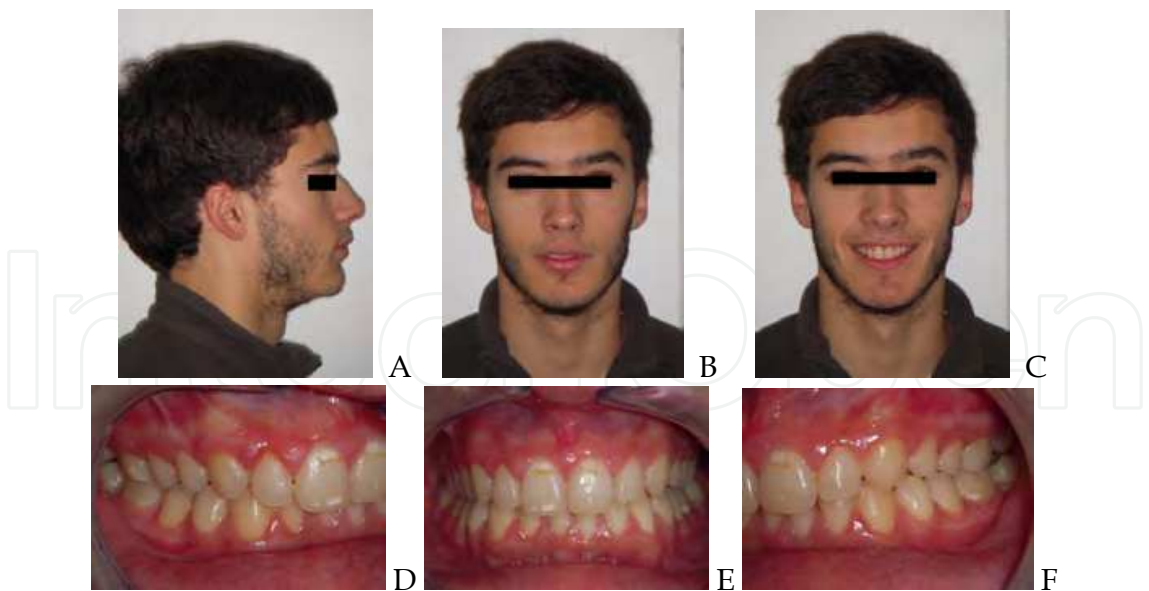


Fig. 14. 30 months post-treatment extraoral (A-B-C) and intraoral (D-E-F) photos

Case Report 2

Patient male (13 years old/10 months), short anterior facial height with skeletal class II and dental class II/1 on a hypodivergent face pattern, mandibular retrognathism, deep bite (7mm); overjet (10mm), curve of spee with steep occlusal plane in the molar area producing

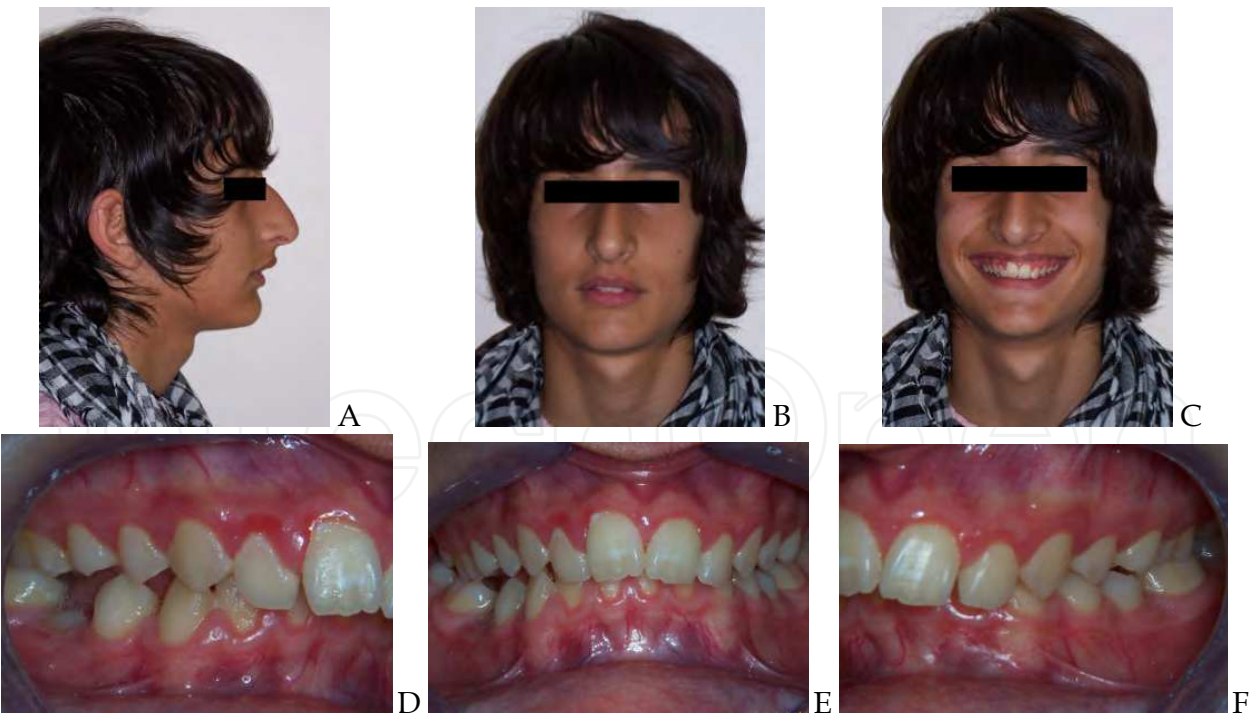

Fig. 15. Pre-treatment extraoral A-B-C) and intraoral (D-E-F) photos

Interference in the posterior area, insufficient occlusal support.  
The z angle of 66° confirms an unbalanced face which is based on a retrognathic chin. There is no crowding. Arches forms are different because of an old habit of thumb sucking.



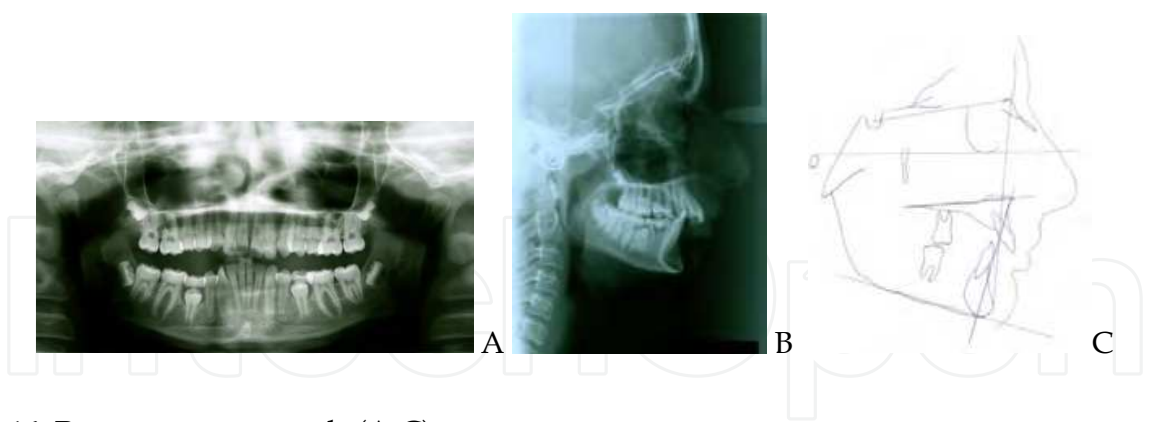


Fig. 16. Pre-treatment records (A-C)

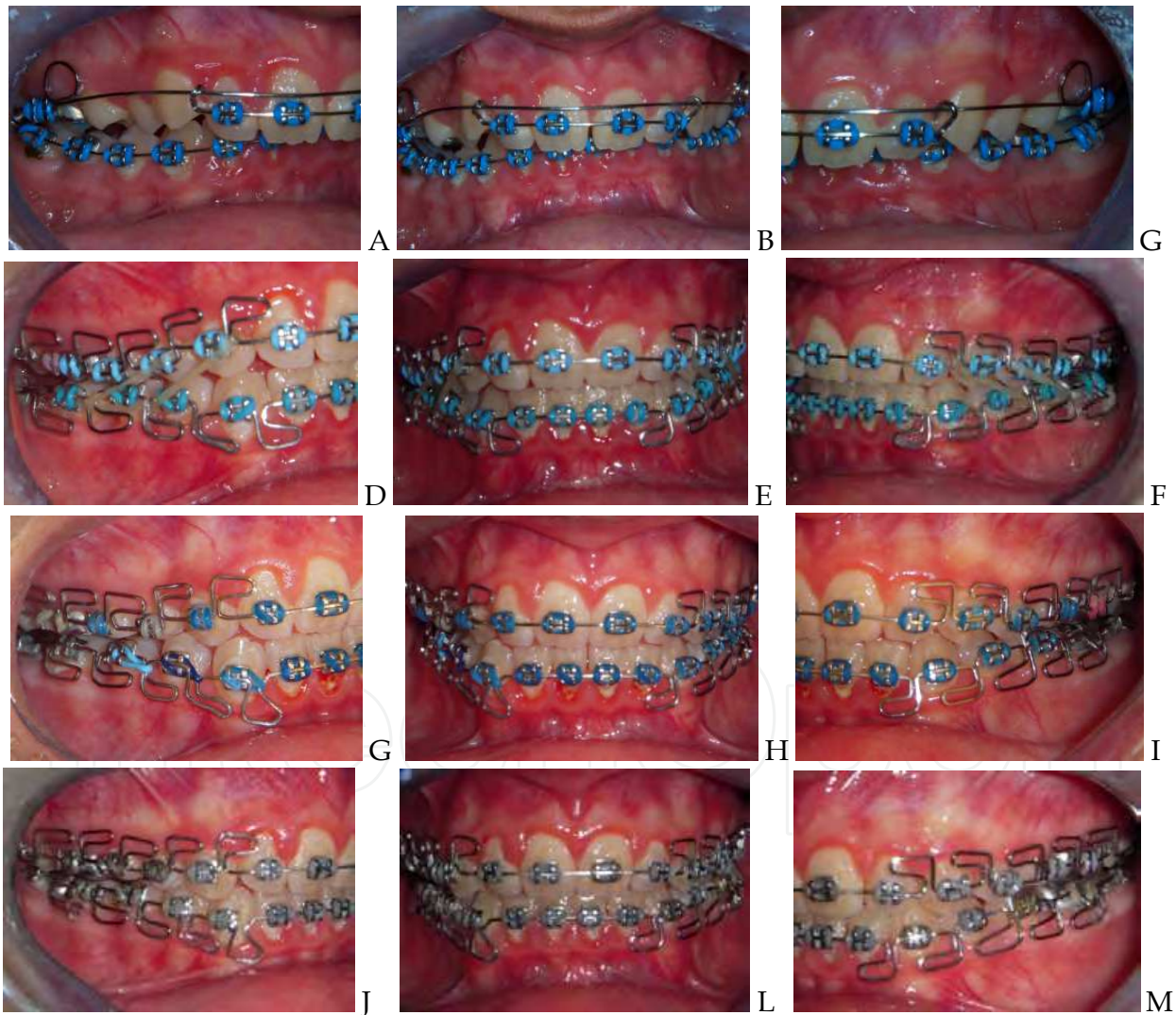

Fig. 17. Photos during the treatment.(A-C) after two months of treatment DAW(double arch wire) was inserted and was kept for five months. (D-F) twelve months of treatment (five months with MEAW upper and lower and short class II elastics (6 oz, 3/16 inch)). (G-I) 18 months of treatment.(J-M) 22 months of treatment

According to Kym’s analysis, the ODI (86°) indicates a deepbite skeletal pattern and extraction of permanent teeth should be avoided if possible, due to the strong potential for deepbite relapse. The APDI (70°).indicates a class II skeletal pattern and the CF (combination factor of 156) indicates a skeletal pattern with potential to accommodate all the teeth. Treatment began with age (13/7), after 2 months a DAW (double arch wire) was inserted to erupt upper molars and alignment, intrusion of the upper anterior teeth. After 5 months, the use of MEAW and short class II elastics (3/16 inch, 6 oz) started. This treatment lasts for 24 months. At the end of the treatment, the photographs (figure n°18.) illustrate a balanced face, a better profile and a pleasant smile, a good class I relationship, the overbite and overjet have been corrected. The lower incisor remains in its pre-treatment position. The general superimposition shows the total mandibular response in height and length. The post-treatment APDI is 80°, this value shows the stability of the treatment and counteract the tendency of relapse.

	Range	Beginning	End of treatment	End of retention
FMIA	67°+- 3	64	58	
FMA	25°+- 3	18	20	
IMPA	88°+- 3	98	102	
SNA	82°+- 2	79	76	
SNB	80°+- 2	74	73	
ANB	2°-+ 2	5	3	
Ao-Bo	2mm	7mm	2mm	
OP	10°-14°	7	8	
Z	75°+-5	67	73	
PFH	45mm	45	50	
AFH	65mm	60	65	
INDEX	0,69	0,75	0,77	

Table 3. Cephalometric analysis (Tweed- Merrifield)

	Beginning		End of treatment		End of retention	
ODI	MP/AB 82	80	82	80		
	FH/PP -2		-2			
APDI	HF/FP 80	73	82	80		
	FP/AB -5		-4			
	HF/PP -2		2			
CF	ODI+APDI	153		160		

Table 4. Cephalometric analysis (Kim)



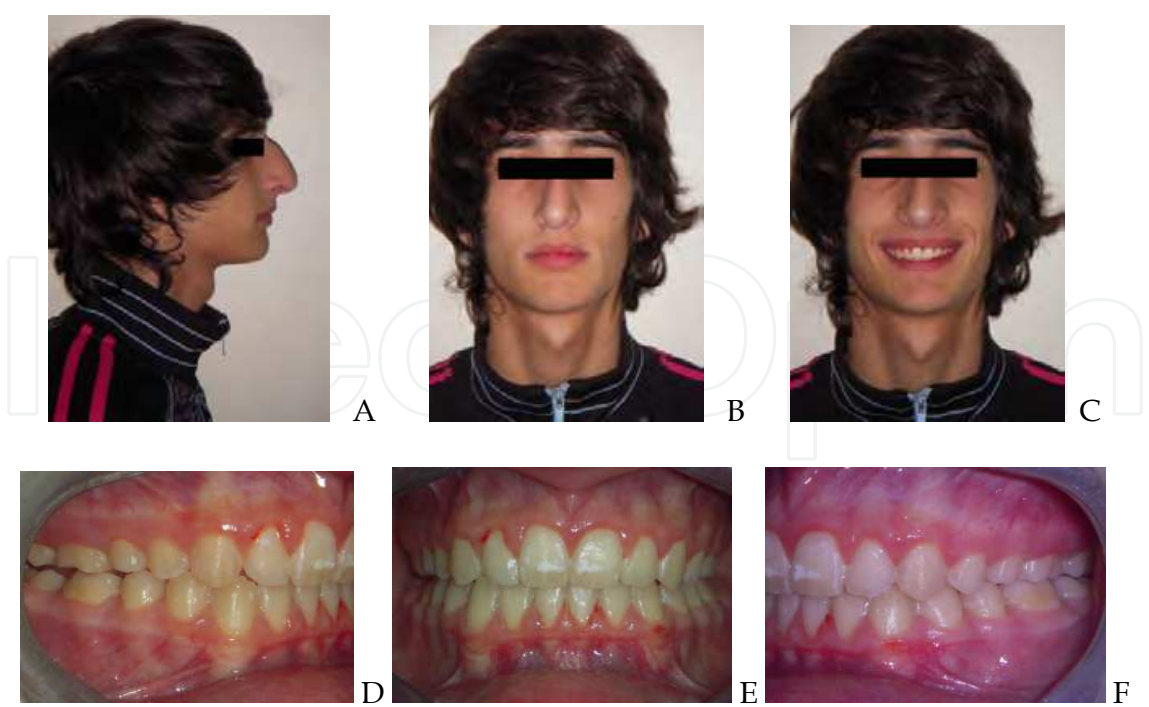


Fig. 18. Post-treatment extraoral photos (A-C) and intraoral photos (D-F)

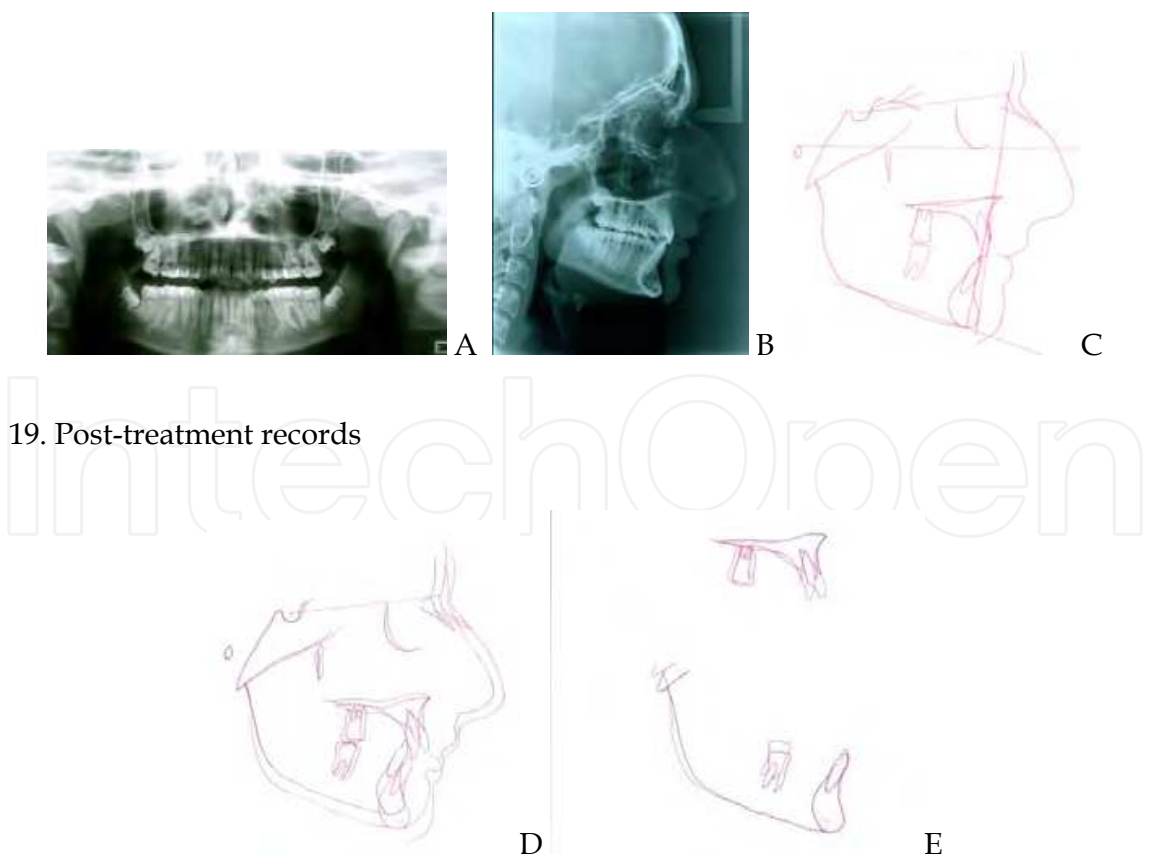


Fig. 19. Post-treatment records

Fig. 20. Superimpositions

Case Report 3

Patient male (13 years, 4 months), short anterior facial height, skeletal class II and dental class II/1 on a hypodivergent face pattern, mandibular retrusion , thin lips, deep overbite (7mm), overjet (7mm) curve of spee deep with steep occlusal plane in the molar area, insufficient occlusal support. (2mm of crowding).

According to KYM’s analysis the ODI=88 indicates a deep bite skeletal pattern and extraction of permanent teeth should be avoided if possible.

The APDI (66) indicates a class II skeletal pattern and the CF of 154 indicates a skeletal pattern that has a potential to accommodate all of the teeth.

Treatment goals: a- increase the vertical dimension , b- rebuild and flatten the upper posterior occlusal plane; c- reposition the mandible forward ; d- correction the crowding.

Treatment plane (steps): a – Leveling ; b-Elimination of interferences and crowding ; c – Establishing mandibular position; d- Occlusal plane reconstruction ; e- Obtain a physiologic occlusion.Treatment began with levelling using .0016 ss round wire, (brackets with 0.022 inch slot).Three months after the beginning of the treatment, MEAW’s (multiloop edgewise arch wires .0017x.0025 inch/ss) were applied to upper and lower arches. A reverse curve was done in the mandibular MEAW. Then step down bends were done in the upper arch and step up bends in the lower arch to bite rising. Short class II 3/16 inch elastics, 6 oz were used. 14 months after the beginning of the treatment the malocclusion was corrected. The retention phase was done with maxillary Hawley plate for night time use (6months) and bonded lingual wire from 43 to 33.The post-treatment photos show a well balanced face, a better smile, a good class I molar relationship, overbite and overjet correct. The mandibular superimposition shows a slight protrusion of the lower incisors (the IMPA was increased from 108 to 111).The APDI was increased from 69 to 77 .

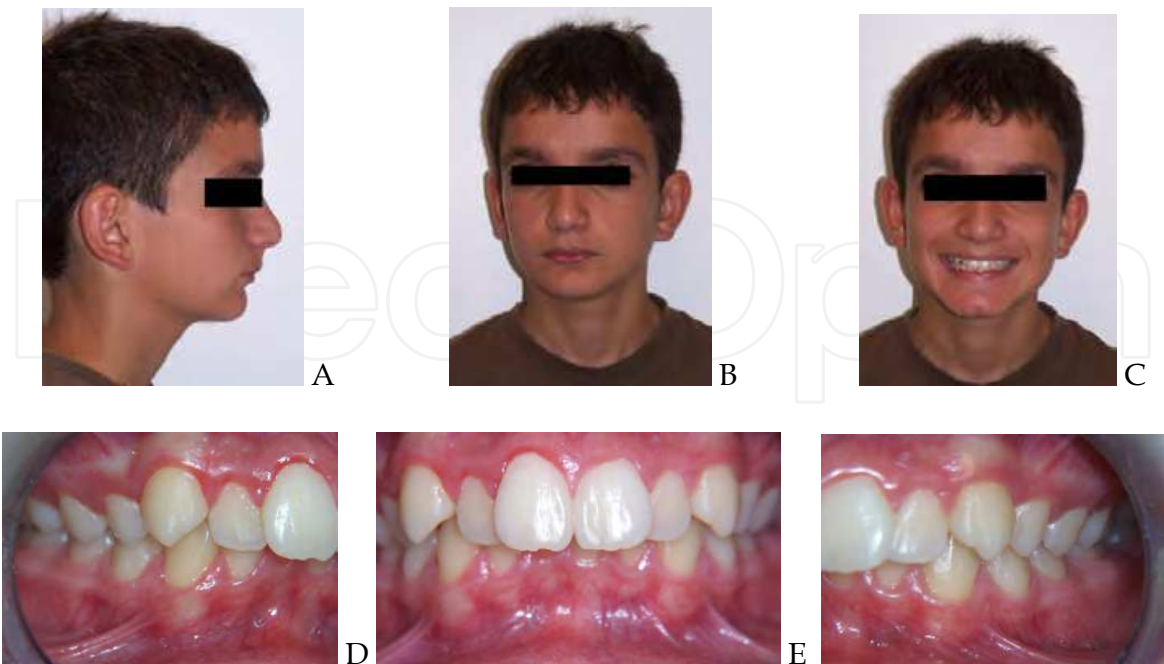


Fig. 21. Pre-treatment Photos A-F

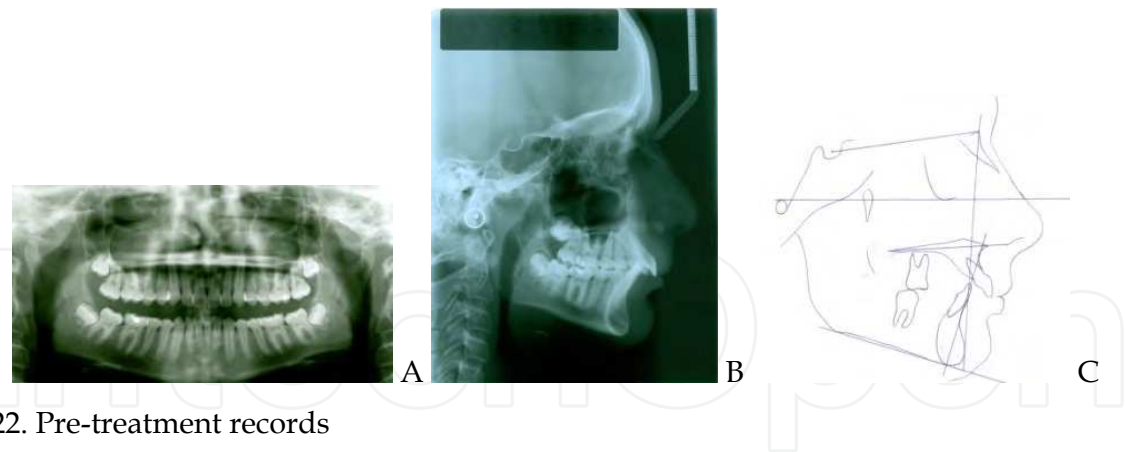


Fig. 22. Pre-treatment records

	Beginning		End of treatment		End of retention	
ODI	MP/AB 90	88	87	85		
	FH/PP -2		-2			
APDI	HF/FP 84	69	85	77		
	FP/AB -13		-7			
	HF/PP -2		-1			
CF	ODI+APDI	157		162		

Table 5. Cephalometric analysis (Kim)

	Range	Beginning	End of treatment	End of retention
FMIA	67°+- 3	55	52	
FMA	25°+- 3	17	17	
IMPA	88°+- 3	108	111	
SNA	82°+- 2	83	82	
SNB	80°+- 2	76	78	
ANB	2°-+ 2	7	4	
Ao-Bo	2mm	8mm	6mm	
OP	10°-14°	6	3	
Z	75°+-5	70	73	
PFH	45mm	49	51	
AFH	65mm	61	63	
INDEX	0,69	0,80	0,80	

Table 6. Cephalometric analysis (Tweed- Merrifield)

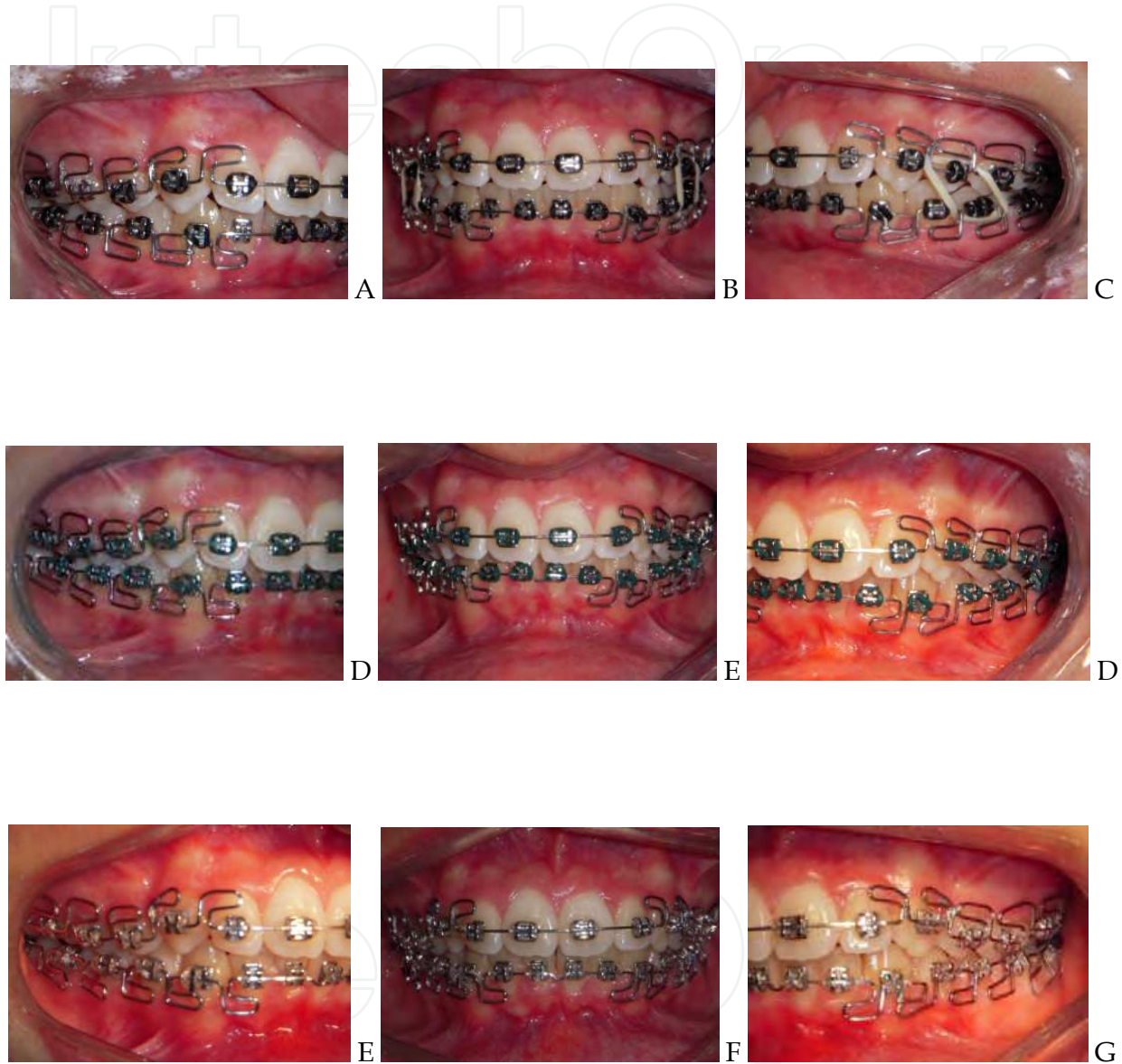

Fig. 23. Photos during the treatment (A – G)



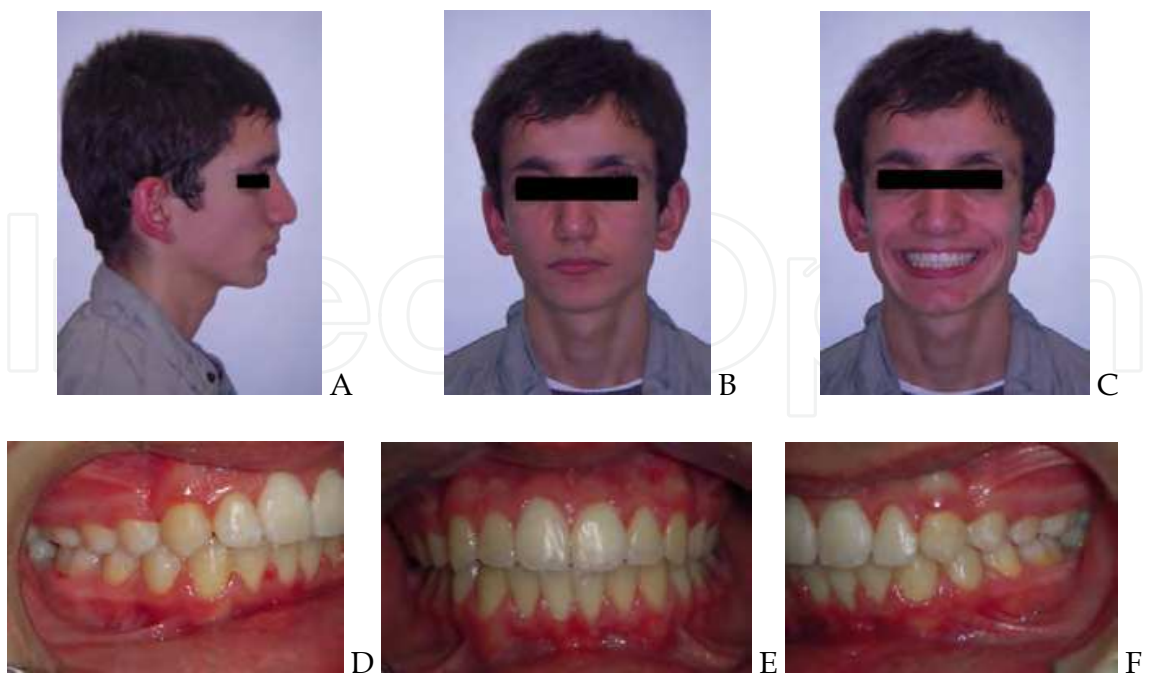


Fig. 24. Post-treatment extraoral (A-C) and intraoral (D-F) photos

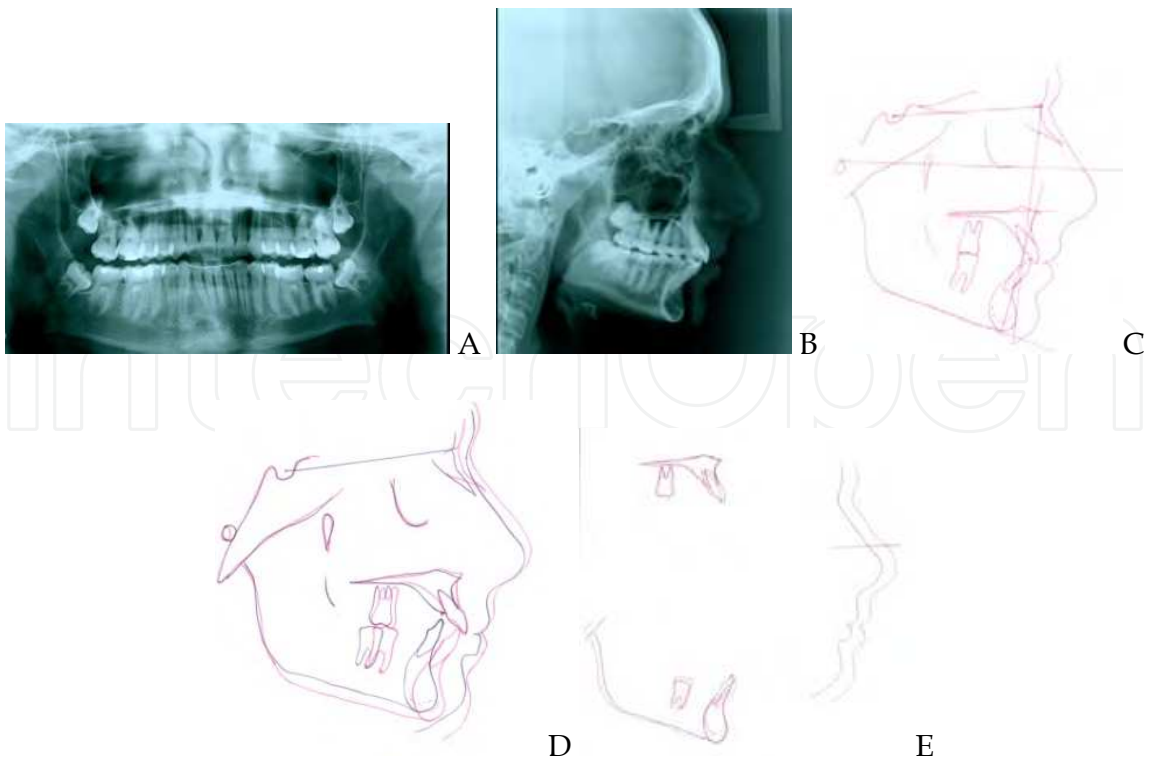


Fig. 25. Post-treatment records



## 10. Conclusion

The MEAW technique proved to be effective in the treatment of class II deepbite malocclusion, correcting the posterior occlusal plane and increasing the vertical dimension, allowing a stable mandibular advancement.

## 11. References

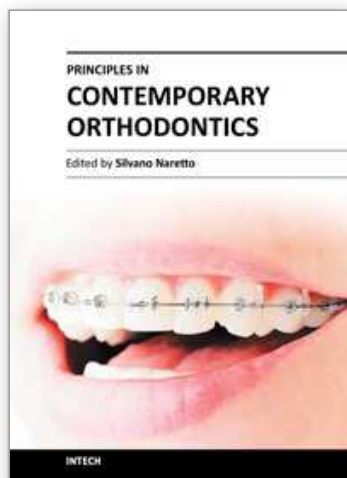
- Dawson, P.E.(1989) *Evaluation, diagnosis and treatment of occlusal problems*, Dawson, P.E.(ed), The C.V. Mosby company
- Decker, A (1989). Le traitement des classes II sans extractions de prémolaires, *journal de l'Edgewise* - vol 20 : 89-112
- Fushima, K ; Kitamura, Y; Mita, H ; Sato, S; Kim, Y (1996).The significance of the cant of occlusal plane in class II/1 malocclusion. *European journal of orthodontics*, 18, 27-40
- Hyun-Sook Kim, Seon-Young Kim (2004).Compensatory changes of a occlusal plane angles in relation to a skeletal factors; *Korea journal of orthodontics*:34 (3) :229-40
- Kato, Sae; Chung, Woo-Nahm; Sato, Sadao (2002), Morphological Characterization of different types of class II malocclusion; *bulletim of Kanagawa dental college*; vol 30, n°2, September, pp 93-98
- Kim, Young H, (1974)overbite depth indicator with particular reference to anterior openbite, *AJO*, 65:586-611
- Kim, YH; Vietas JJ(1978) Anteroposterior dysplasia indicator; *American journal of orthodontics* ; 73:619-33
- Kim, YH, (1979), ODI/ APDI combination factor, *Angle orthodontics*, 49:77-84
- Kim, YH; (1999); Treatment of anterior openbite and deepbite malocclusions with MEAW therapy; *The enigma of vertical dimension-craniofacial growth series vol 36 Ann Arbor (edited by James McNamara Jr): center for Human growth and development- University of Michigan*
- Knierim, RW (1999).diagnosis of openbite and deepbite problems: a clinician`s perspective on the Kim approach; ; *The enigma of vertical dimension-craniofacial growth series vol 36 Ann Arbor (edited by James McNamara Jr): center for Human growth and development- Univ.Michigan*
- Mc Namara, J.A. jr and Carlson, D.S. (1979)Quantitative analysis of temporomandibular joint adaptations to protrusive function; *American journal of orthodontics*, 76, 593-611
- Merrifield, LL.(1966)The profile line as an aid to critical evaluation of facial esthetics; *American journal of orthodontics*, 804-822
- Ortial, J.P(1989), Les modifications faciales par l'orthodontie, *journal de l'edgewise*, vol.20, 53-86
- Petrovic, A.G. and Stutzaman, J.(1975) Control process in the postnatal growth of the condylar cartilage, in McNamara J.A.jr, ed.determinants of mandibular growth, monograph 4:craniofacial growth series, Ann Arbor-Center for Human growth and development, University of Michigan
- Sassouni, V, (1969)A classification of skeletal facial types, *AJODO*, 55, 109-123
- Sato, Sadao(2001) -A treatment approach to malocclusions under the consideration of craniofacial dynamics, Grace printing press, inc

Sato, Sadao.(2002)Morphological characterization of different types of class II malocclusion;  
*Bulletin of Kanagawa dental College*, vol.30, n°2, September, pp, 93-98

Sato, Sadao (2008), orthodontic marathon course at Kanagawa dental college -Japan

IntechOpen

IntechOpen



## **Principles in Contemporary Orthodontics**

Edited by Dr. Silvano Naretto

ISBN 978-953-307-687-4

Hard cover, 584 pages

**Publisher** InTech

**Published online** 25, November, 2011

**Published in print edition** November, 2011

Orthodontics is a fast developing science as well as the field of medicine in general. The attempt of this book is to propose new possibilities and new ways of thinking about Orthodontics beside the ones presented in established and outstanding publications available elsewhere. Some of the presented chapters transmit basic information, other clinical experiences and further offer even a window to the future. In the hands of the reader this book could provide an useful tool for the exploration of the application of information, knowledge and belief to some orthodontic topics and questions.

### **How to reference**

In order to correctly reference this scholarly work, feel free to copy and paste the following:

Paulo Beltrão (2011). Treatment of Class II Deep Overbite with Multiloop Edgewise Arch-Wire (MEAW) Therapy, Principles in Contemporary Orthodontics, Dr. Silvano Naretto (Ed.), ISBN: 978-953-307-687-4, InTech, Available from: <http://www.intechopen.com/books/principles-in-contemporary-orthodontics/treatment-of-class-ii-deep-overbite-with-multiloop-edgewise-arch-wire-meaw-therapy>

**INTECH**  
open science | open minds

### **InTech Europe**

University Campus STeP Ri  
Slavka Krautzeka 83/A  
51000 Rijeka, Croatia  
Phone: +385 (51) 770 447  
Fax: +385 (51) 686 166  
[www.intechopen.com](http://www.intechopen.com)

### **InTech China**

Unit 405, Office Block, Hotel Equatorial Shanghai  
No.65, Yan An Road (West), Shanghai, 200040, China  
中国上海市延安西路65号上海国际贵都大饭店办公楼405单元  
Phone: +86-21-62489820  
Fax: +86-21-62489821

© 2011 The Author(s). Licensee IntechOpen. This is an open access article distributed under the terms of the [Creative Commons Attribution 3.0 License](https://creativecommons.org/licenses/by/3.0/), which permits unrestricted use, distribution, and reproduction in any medium, provided the original work is properly cited.

IntechOpen

IntechOpen