

We are IntechOpen, the world's leading publisher of Open Access books Built by scientists, for scientists

6,900

Open access books available

186,000

International authors and editors

200M

Downloads

Our authors are among the

154

Countries delivered to

TOP 1%

most cited scientists

12.2%

Contributors from top 500 universities



WEB OF SCIENCE™

Selection of our books indexed in the Book Citation Index
in Web of Science™ Core Collection (BKCI)

Interested in publishing with us?
Contact book.department@intechopen.com

Numbers displayed above are based on latest data collected.
For more information visit www.intechopen.com



Laparoscopic Surgery: An Almost Scarless Approach

Peng Soon Koh and Kin Fah Chin
*Department of Surgery, Faculty of Medicine,
 University of Malaya, Kuala Lumpur
 Malaysia*

1. Introduction

Minimally invasive surgery is gaining popularity worldwide as it contributes to less post-operative pain, shorter hospital stay and reduced morbidity. Since laparoscopic cholecystectomy was first performed in the 80's, a wide array of different types of laparoscopic surgery was performed and this has been extended to colorectal resection, where the first reported case of laparoscopic colorectal resection was made in 1991. Conventionally, a mini laparotomy is required to extract the specimen following laparoscopic colorectal resection, which may increase post-operative pain, wound infection, a bigger scar and other pain related morbidities. Thus, the use of natural orifice specimen extraction (NOSE) for the extraction of colorectal specimen is slowly gaining worldwide acceptance and evolving.

Single Incision laparoscopic Surgery or Single Port Access Surgery is also gaining popularity as an alternative approach to NOSE and Natural Orifice Transluminal Endoscopic Surgery (NOTES) in order to provide an almost scarless surgery. Often at times, such procedures are complementary to one another.

However, there is a significant cost implication due to the expensive disposable port and hand instruments but the main aim of having such procedures is the retrieval of resected surgical specimens through exploitation of natural body orifices such as the mouth, anus, vagina or urethra.

In this chapter, we described a technique for retrieval of the colonic specimen via a natural orifice or transvaginal for a 78 year old lady who had sigmoid carcinoma and underwent a total laparoscopic high anterior resection, hence avoiding a mini-laparotomy for retrieval of the specimen. We also described various instrumentation and developments in Single Incision Laparoscopic Surgery, NOSE or NOTES, including the latest technique to make this surgery safe. This is concluded with a Health Technology Assessment (HTA) of this emerging technology in health care.

2. Case illustration

2.1 Clinical history

Madam A is a 78 year old lady who complained of per rectal bleeding for 2 months. She had no history of altered bowel habit, loss of appetite or weight and symptoms of bowel

obstruction. Examination was unremarkable except for haemorrhoids on proctoscopy. She had a colonoscopy which showed a fungating polypoidal mass at sigmoid colon and biopsy confirmed the lesion to be malignant. Computed Tomography (CT) scan for staging was done and showed no evidence of extra-colonic metastases. She underwent a total laparoscopic high anterior resection with natural orifice specimen extraction (NOSE) after obtaining an informed consent.

2.2 Operative technique

In the operating theatre, the necessary laparoscopic equipments were readily available. The use of various intracorporeal and extracorporeal stapling devices was also necessary for the operation to be carried out. We also find that the use of Harmonic scalpel ® or ultrasonic dissector to be very useful for tissue dissection during the procedure (Figure 1). Once patient was placed under general anaesthesia, she was positioned into Lloyd-Davies position. This position allows access to the vagina for specimen retrieval as well as via the anal canal for bowel end to end anastomosis (Figure 2).



Fig. 1. The various stapling devices, equipments and ultrasonic dissector required for the surgery

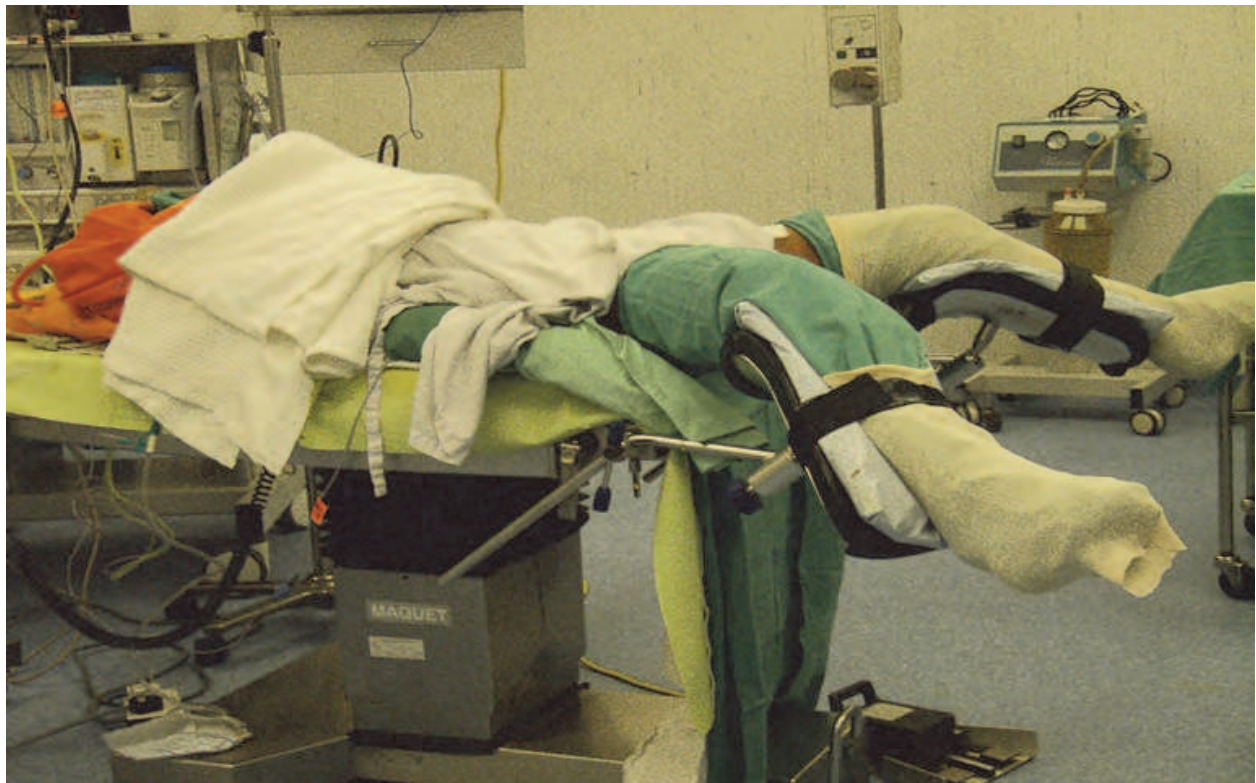

Fig. 2. Positioning of patient for the procedure to be carried out on the operating table.

Intra-operatively, laparoscopic ports were inserted at the appropriate place following pneumoperitoneum. The sigmoid colon was found to be redundant and the tumour was noted to be at the lower sigmoid colon. We began by hitching up the uterus by using a straight needle inserted percutaneously and into the broad ligament of the uterus and retrieving back the needle from the skin where the suture was tied hence lifting the uterus up onto the anterior abdominal wall (Figure 3).

Once there was adequate exposure, we began mobilizing the sigmoid colon from medially to laterally and the left ureter was identified and preserved. The inferior mesenteric vessels were then identified and ligated using vascular staplers. Mesorectal excision was then performed with the tumour further mobilized. The bowel distal to the tumour is then transected using a stapler.

Next, with the assistance from the gynaecologist, the posterior fornix was lifted up using a swab on a sponge forcep that was inserted via the vagina. With the posterior fornix lifted up, a transverse incision is made across the posterior fornix (Figure 4).

The sponge forcep is removed and a laparoscopic hand-port is inserted transvaginally to maintain pneumoperitoneum (Figure 5). The tumour is then delivered transvaginally where it is resected proximally (Figure 6).

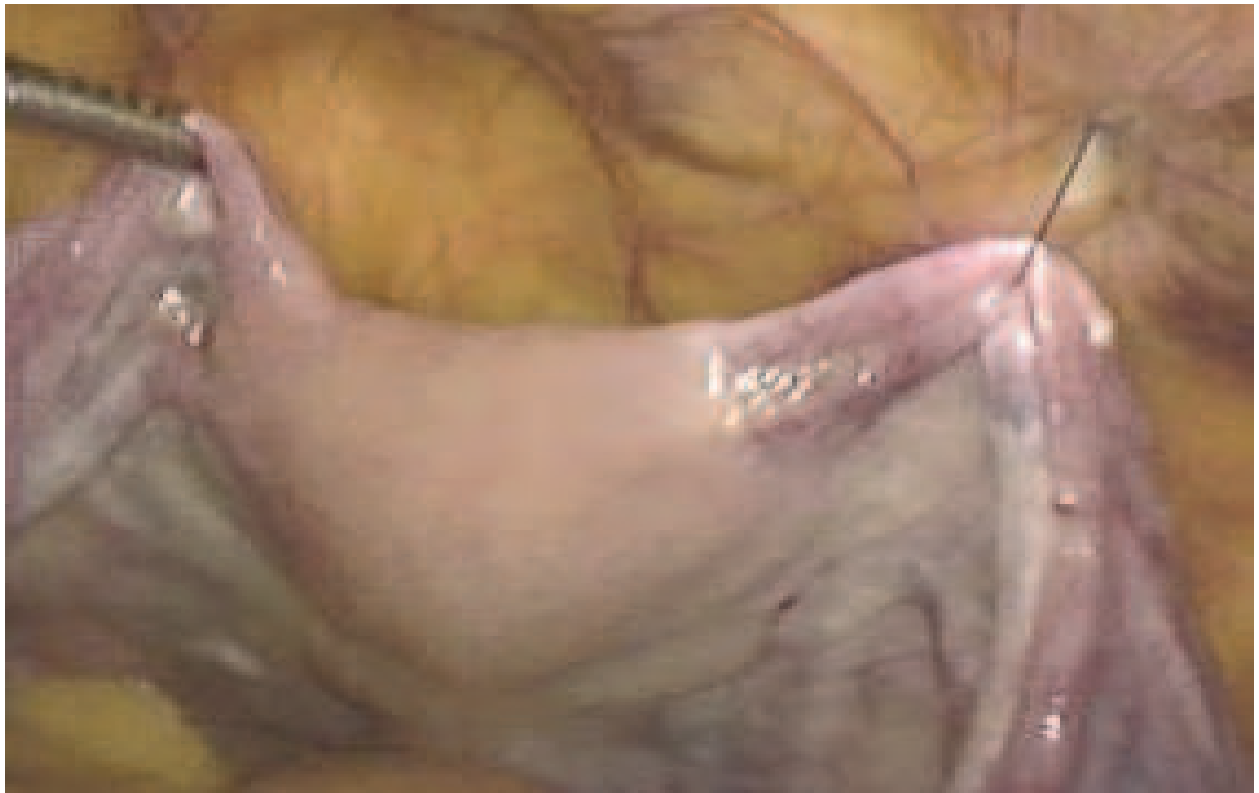

Fig. 3. The uterus hitched to the anterior abdominal wall using sutures passed through the broad ligament

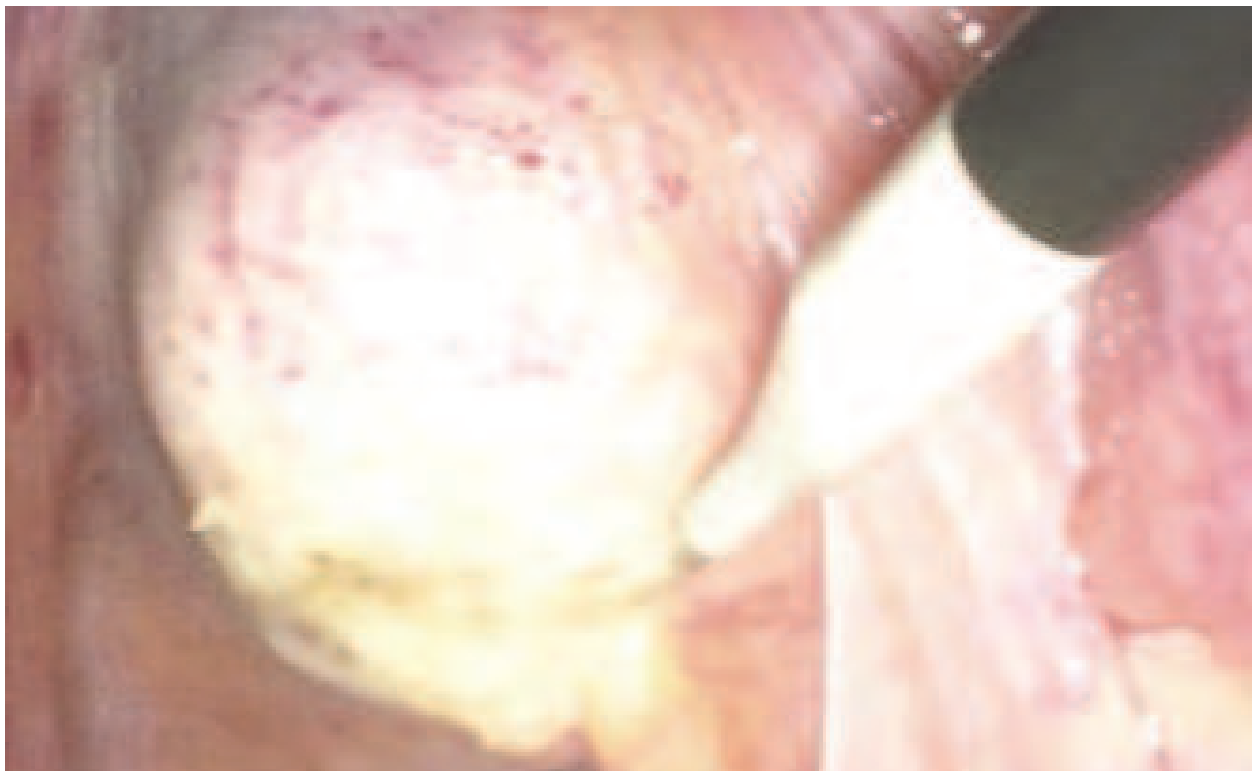


Fig. 4. Incision made across posterior fornix using diathermy following lifting up by the assistant transvaginally

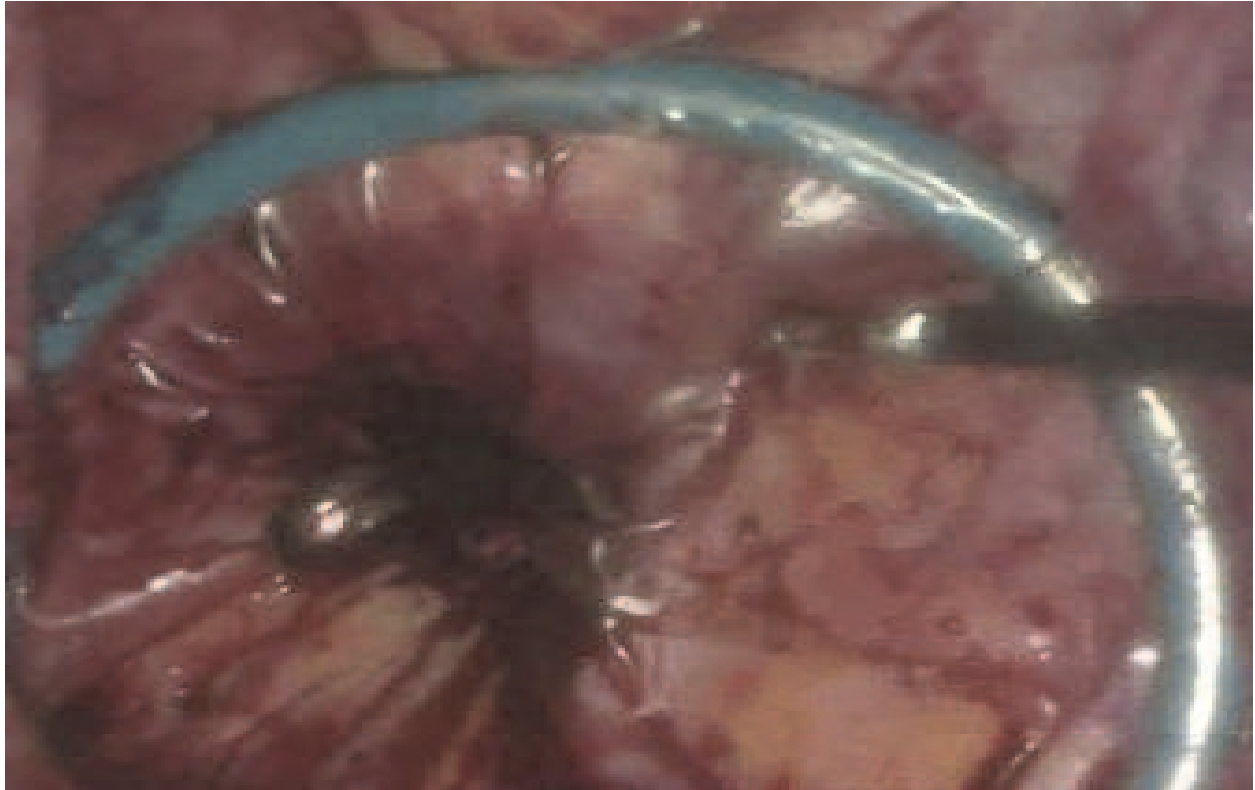

Fig. 5. Hand port inserted via vagina and through the incision made across the posterior fornix. Seen here within the abdomen.

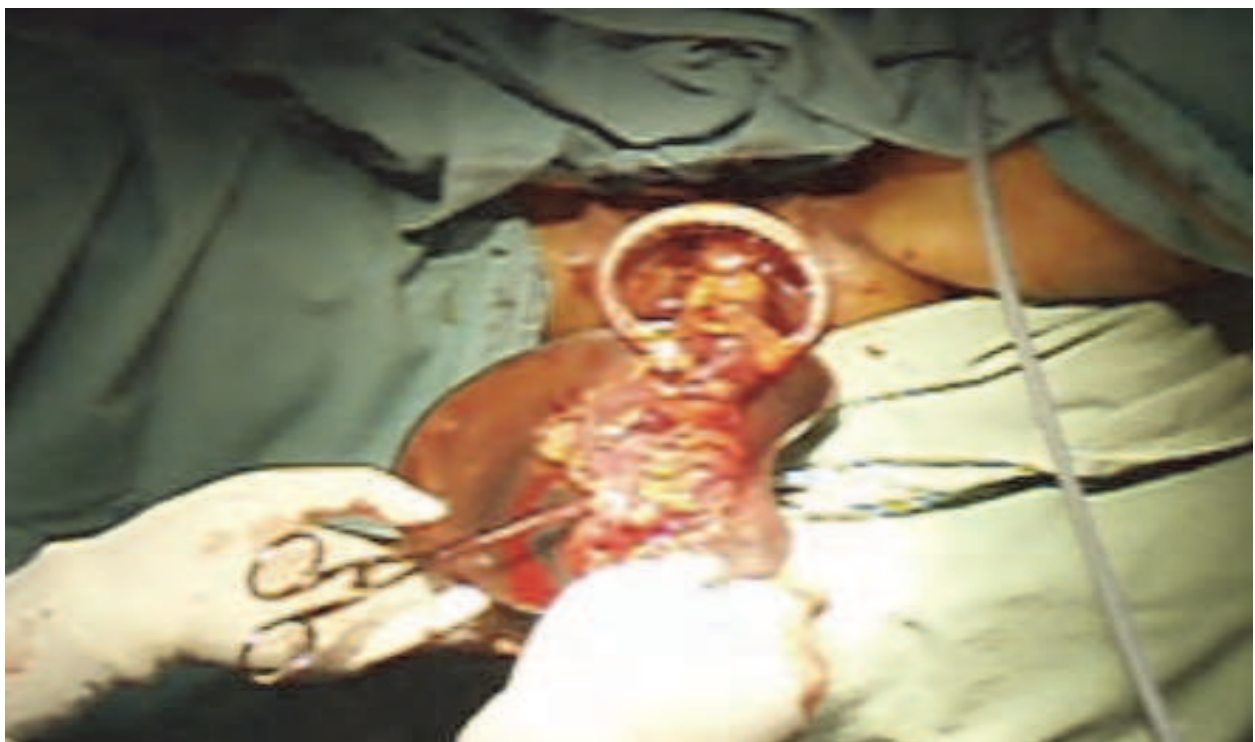

Fig. 6. Tumour extracted out via the vagina and transected proximally to tumour.

The anvil of the circular stapler is then inserted into the proximal colon and closed using purse string suture. The proximal colon is then returned into the abdomen with the anvil. The hand port is removed and the posterior fornix is closed via intracorporeal suturing (Figure 7). Bowel end to end anastomosis was completed by inserting the CDH 29mm circular stapler via anal canal (Figure 8). No leak was encountered intraoperatively when checked post anastomosis.

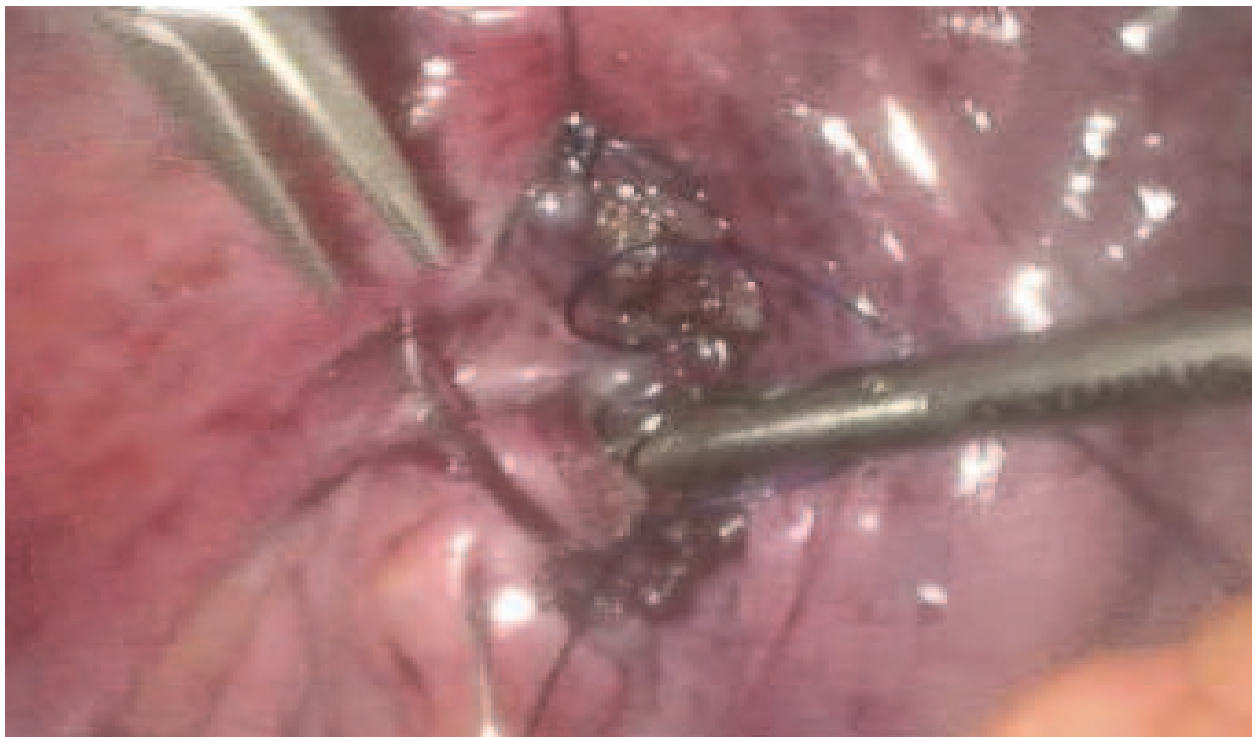

Fig. 7. Posterior fornix is stitched via intracorporeal technique after removal of specimen

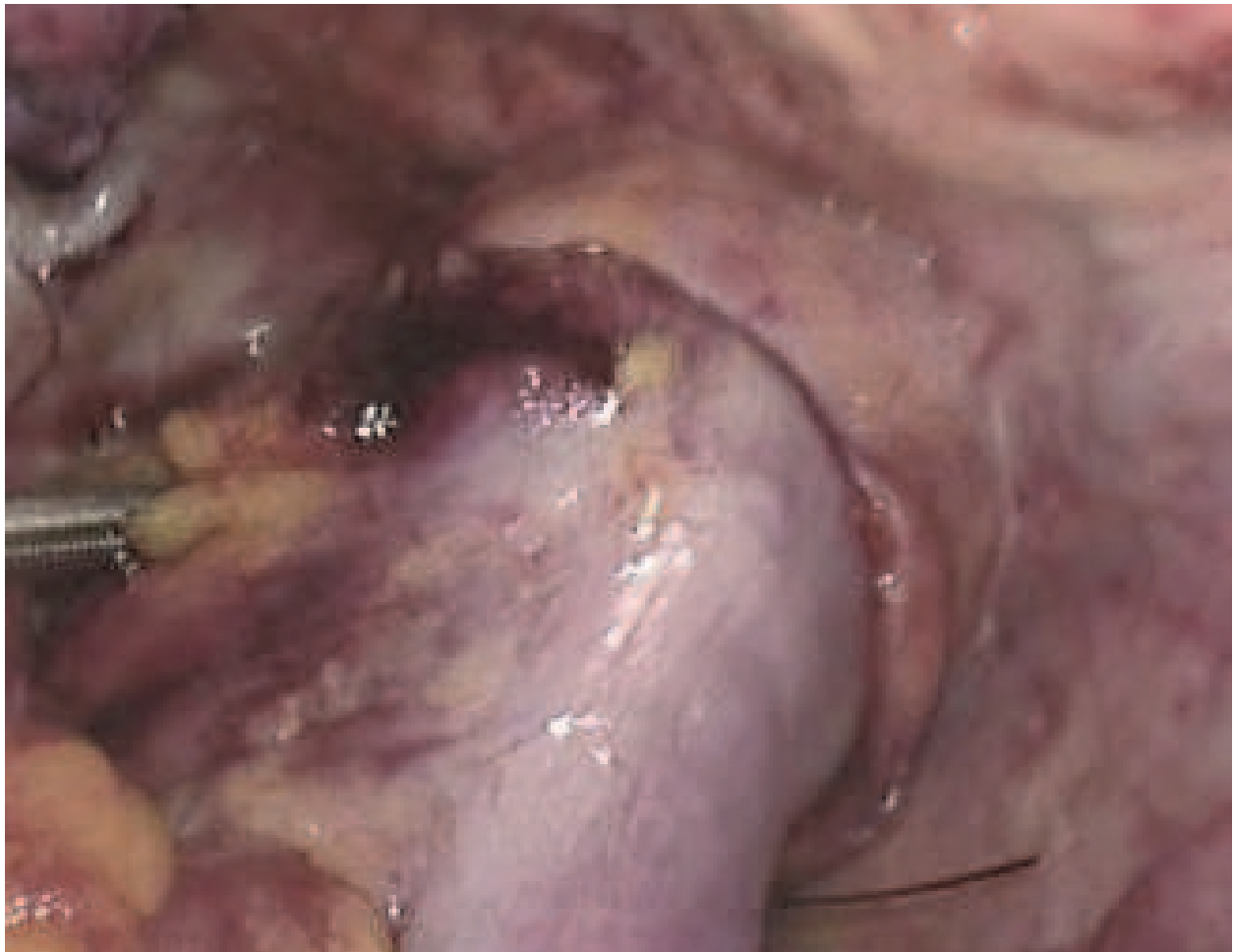

Fig. 8. Bowel end to end anastomosis performed and shown here.

2.3 Clinical progress

Postoperative recovery was uneventful. Pain score was reported to be VAS 0 to 1 throughout her stay. Her post-operative bloods taken did not show any significant changes and blood loss was very minimal. She was put on thrombo-embolic deterrent (TED) stockings, low molecular weight heparin for thromboprophylaxis and was encouraged for incentive spirometry post operatively. We allowed her liquids on the 1st postoperative day and resume normal diet on the 2nd day. There was hardly any post-operative ileus experienced. Her drains were removed at 3rd post-operative day (Figure 9). She began ambulating at day 3 and was discharged on the 5th post-operative day.

On follow up, patient was very happy with the outcome of surgery and was impressed that there was hardly any major scar associated with the operative approach.

2.4 Histopathological result

Histopathological examination showed an 18cm length of colon was removed on gross examination (Figure 10). On microscopic examination, there was no lymphovascular permeation and the tumour only involved the mucosa layer. The margins were clear of tumour. All lymph nodes harvested were negative for malignancy. Proximal and distal donuts were clear of tumour. Pathological staging was noted to be T1, N0, M0 (Stage 1).

The final result showed a moderately differentiated adenocarcinoma.

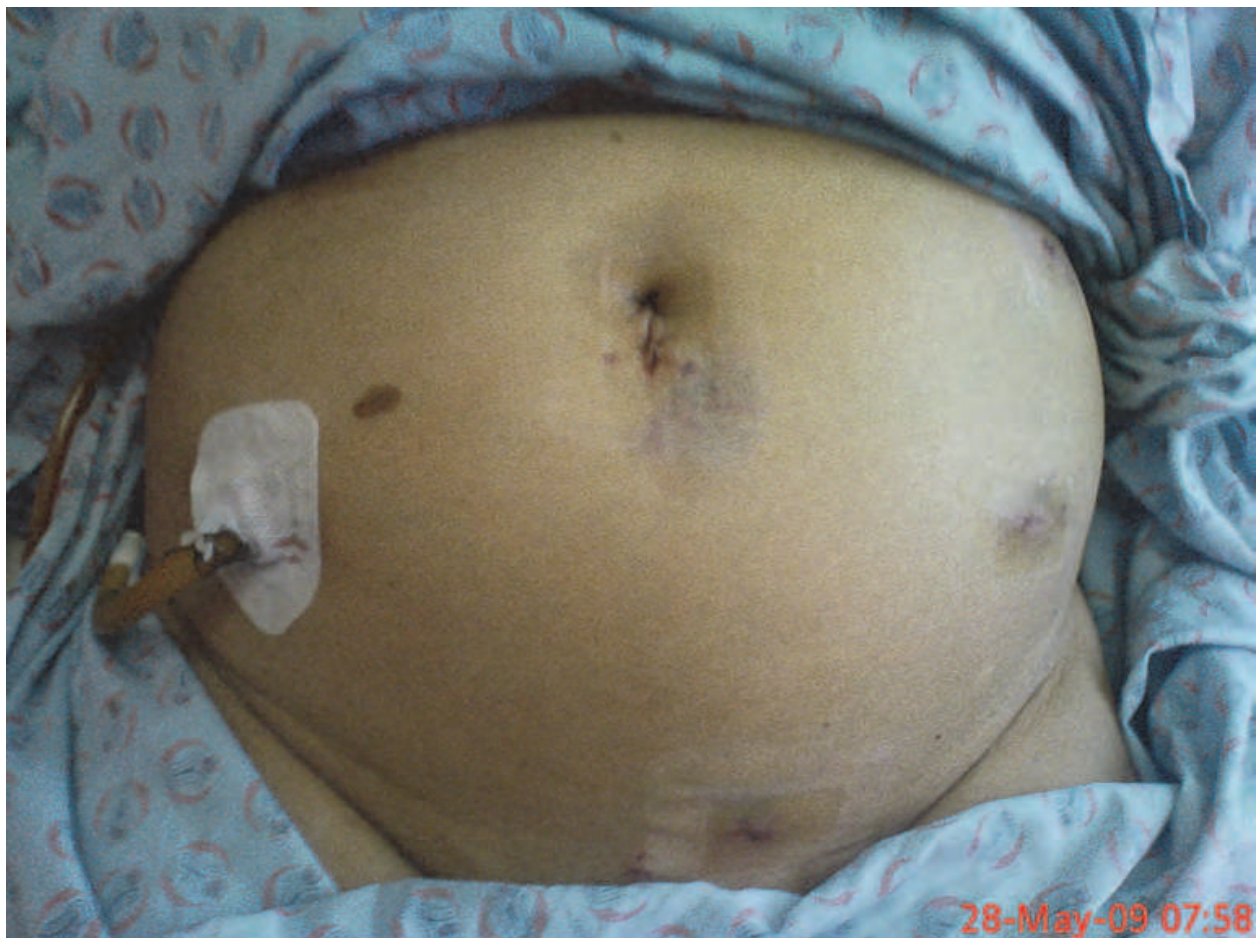

Fig. 9. Wound inspection at post-operative Day 2 showing an almost scarless abdomen

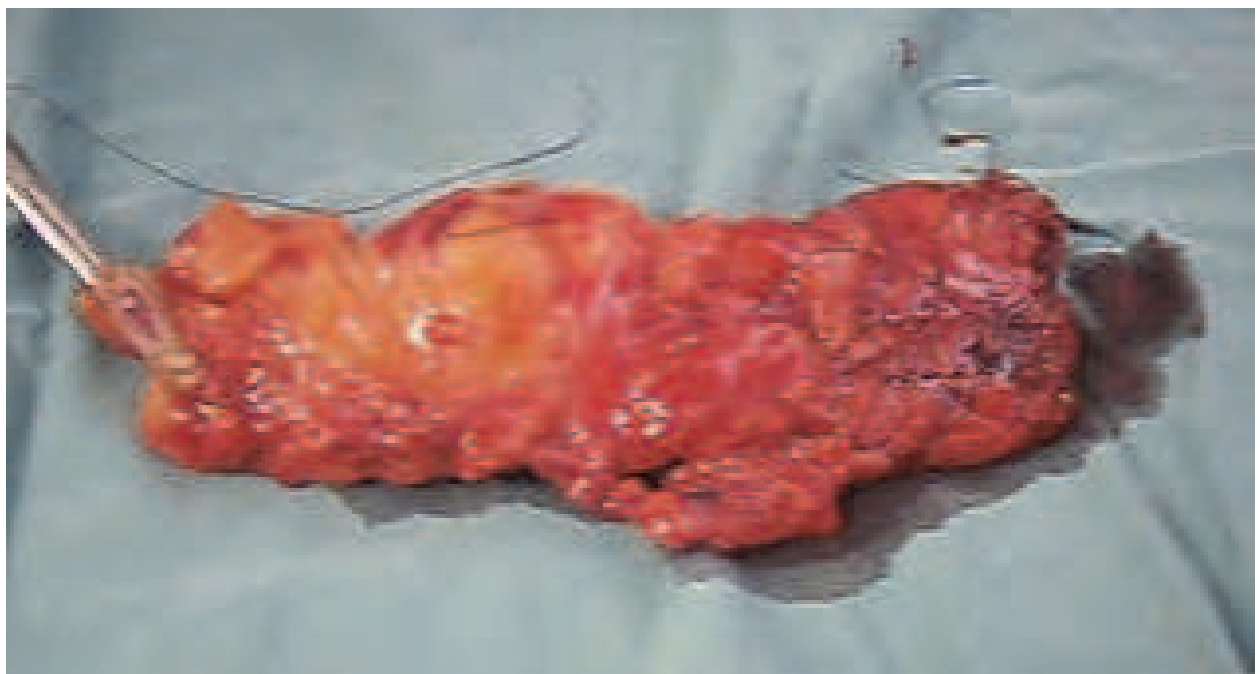

Fig. 10. The entire length of bowel removed along with the tumour.

3. Laparoscopic surgery with Natural Orifice Specimen Extraction (NOSE) in colorectal surgery: The way forward in the scarless surgical approach?

In laparoscopic colorectal resection, it was conventional to retrieve the resected colonic specimen via a mini-laparotomy. This is rather a frustrating situation for most laparoscopic surgeons who took pain to ensure minimal scarring for patients following a long and arduous laparoscopic dissection. Such situation can now be overlooked with the advent of natural orifice surgery, which is gaining popularity and evolving.

It is without doubt that a mini-laparotomy which is required for the retrieval of colonic specimen following resection is associated with a bigger scar hence poor cosmetic appearance, increase in pain outcome, increase risk of wound infection and other pain related complications [1]. This can now be avoided with the technique of retrieving specimens via natural orifices via the transvaginal, transanal or transgastric routes.

In our patient, we have described the retrieval of specimen via the transvaginal route. This is feasible in female patients with colonic cancers. This technique had also been described in other literature. Palanivelu et al. had described the transvaginal route for a series of patients with familial adenosis polyposis (FAP) with early rectal adenocarcinoma who had laparoscopic proctocolectomy with ileoanal pouch anastomosis who had the specimen retrieved transvaginally [2].

Extraction of specimen via the transvaginal route has also been described in other operations besides colorectal surgery such as nephrectomy, cholecystectomy, appendectomy, spleen and so forth which will be elaborated much later in this chapter [3, 4].

Retrieval of colonic specimen via other natural orifice such as the transgastric or transanal routes had also been described in literature but not without limitations. In this case, the transgastric approach would be limited by the restriction point in the oesophagus, the long travel distance and lack of adequate instruments for extraction as described by Franklin et al [5]. Similarly, the transanal approach also had its limitations such as the risk of fecal contamination, wound infection, injury to the anal sphincters and limitation to the size of the specimen extracted [2, 5]. At this moment, the transanal approach can only be recommended for small benign tumours or early colorectal cancers [6].

One of the reasons for choosing the transvaginal route is the advantage of the elasticity of the vagina, hence allowing specimen of various sizes to be able to retrieve. Literature has shown that transvaginal extraction is most ideal and patients undergoing this technique had good post-operative outcome with clinically no significant impact on orgasm, pregnancy, dyspareunia or sexual function [7].

One of the main concerns regarding retrieval of specimen is port site or retrieval incision metastasis which was reported to be 0.9 to 3.4% by Schaeff et al [8]. However, this fear is allayed as was described in our patient where the use of a handport, which was inserted transvaginally, was used to retrieve the specimen. We also found that the advantage of using the handport also allowed us to minimize infection or contamination, and to maintain pneumoperitoneum throughout the operation.

As can be seen in our patient, the post-recovery was excellent. Pain outcome was good with almost no pain reported. Normal diet was able to resume from the 2nd post-operative day onwards. By the 3rd day, patient was ambulating. On hindsight, patient was actually able to go home on the 3rd post-operative day with the drains removed. We have kept her longer as this was the first case performed in our centre, hence the longer observation period.

The end result of this technique is very satisfactory and patient was highly satisfied with the post-operative outcome.

4. Application of NOSE or NOTES in other surgical disciplines

The sudden rise in interest towards NOSE or NOTES have also seen its application flourish and boomed in various surgical discipline as we moved into the 21st century. Although still in its infancy, it is slowly gaining popularity and clinical acceptance as can be seen in its application in non-colorectal surgery.

4.1 Other general surgical procedures

Although much has been reported regarding the retrieval of colonic specimens be it a right sided colectomy, left sided colectomy or an anterior resection via the more popular natural orifices such as transvaginal or transanal routes, the application of NOSE and NOTES can also be seen in other non-colorectal procedures.

Similar to retrieval of colonic specimen where feasibility is not an option via the transgastric or the transurethral route, the use of NOSE in retrieval of stomach specimen via the transvaginal route had been described by Jeong et al in 2010. This was the first ever description of retrieval of stomach specimen using NOSE method published for early gastric cancer where patients in its series undergone a subtotal gastrectomy [9].

When compared to NOSE in colorectal surgeries, it has been almost 15 years from the first reported extraction of colonic specimen via natural body orifices to its first stomach specimen extraction via NOSE today. Even then, the first NOSE was first described in 1993 by Delvaux et al who removed the gallbladder via the transvaginal route [10]. What have happened along those years?

One can only wonder that such a procedure must have slowly gained acceptance and changed in perception among the clinical community and public acceptance towards NOSE where the procedure can now extend to extraction of other bodily specimens as the people are slowly more inclined towards a scarless surgery.

With regards to NOTES, the use of natural orifices to perform surgery without any bodily incision thus providing patients with a scarless surgery have also been described although it has its limitations. Nevertheless, the future looks promising with the advent of such newer techniques.

At the moment NOTES have been described using an endoscope which is channeled through various bodily orifices and perforating the viscus to perform the intended procedure. Here, examples of peritoneoscopy, appendectomy, cholecystectomy and so forth had been performed via the transgastric route with retrieval of the specimen. Other routes such as the transcolonic or transvesical or transvaginal route have also been described where once the instruments is in the peritoneal cavity, pneumoperitoneum is created and surgery is performed [11].

In the present, there are still limitations for NOTES when it comes to performing more complex surgery and as for now, most procedures are still performed on animal models. With better technological advancement and improvement in the development of equipments used in NOTES the future indeed looks promising.

4.2 Urology

The use of natural body orifices in Urology began first with the extraction of resected specimen. This was first reported in 1993 by Breda et al following a laparoscopic

nephrectomy where the kidney was removed via the transvaginal route [12]. Following this, numerous application of NOSE and NOTES began the flourish in the urological world with popularity began to soar.

The use of transvaginal route for specimen extraction in females was also widely reported by Gill et al who extended the procedure to include radical nephrectomy [13].

Further evidence in the use of other natural orifices slowly took place where the transanal route was used for the extraction of bladder following cystectomy for bladder tumours where a rectosigmoid pouch was created for urinary diversion and the tumour removed via the transanal route [14].

The above described techniques often combined the use of laparoscopic techniques coupled with natural orifice specimen extraction often known as the Hybrid technique. However, pure NOTES where performing surgery via natural orifices without the possibility of any skin incision in Urological procedure began to emerge thus making Urological procedures a complete scarless surgery.

This was first described in animal models but Lima et al in 2006 described the first pure NOTES where peritoneoscopy was done via the transvesical route which allow peritoneal assessment and liver biopsy [15]. The very same author had gone on to describe other surgical procedures using the same transvesical route.

Another urological option towards an almost scarless surgery seems possible with the introduction of Single Incision Laparoscopic Surgery (SILS) making most urological procedure a possibility in using this approach. Of course, we will be touching on about SILS much later in the chapter.

Although it seem like such urological procedures are still a long way from gaining routine acceptance and at times seem experimental, nevertheless the road ahead looks promising. Nevertheless, limitations abound and there is still more work to be done.

4.3 Gynaecological procedures

The emergence of NOSE and NOTES can also be seen in the field of gynaecology. The use of endoscopic procedure via the transvaginal route has established both diagnostic and therapeutic needs in the field of gynaecology. This is better known as culdoscopy among the gynaecology fraternity.

This further transcends towards the use of fertility medicine such as investigation for infertility in both diagnostic and therapeutic means known as Transvaginal Hydrolaparoscopy (THL) [16]. THL is a modification of culdoscopy and was first introduced by Gordts in 1998. It enables the surgeon to assess or evaluate the posterior uterus, the pelvic side walls and adnexae structures. Such procedure acts as a diagnostic tool and can often times be performed under local anaesthesia without subjecting patients to the risk of general anaesthesia.

THL when coupled with chromotubation also allows assessment of infertility and can replace the conventional hysterosalpingography (HSG) which is often used as the first line of diagnostic modality in the assessment of infertility. It is able to show tubal patency as accurately as an HSG.

Besides diagnostic yield, it also allows various operative procedures to be performed such as ovarian drilling, adhesiolysis, treatment of ovarian cyst as well as endometriosis and salpingostomy.

5. Single Incision Laparoscopic Surgery (SILS) the almost scarless surgical approach and the transumbilical route as another natural body orifice?

5.1 SILS experience

Laparoscopic surgery when first introduced in the early 80's brought a revolutionary change to how surgery is performed. Since then, it has evolved from a simple cholecystectomy or appendectomy to a more complex surgical procedures such as colorectal resection, bariatric surgery, liver and pancreatic resection and so forth.

It is the intention of every laparoscopic surgeon to offer patients with a more feasible form of surgery in the hope of reducing pain, hospital stay and morbidity. Of utmost importance is the reduction or prevention of the conventional surgical scars associated with open surgery. Hence, laparoscopic surgery has evolved from the conventional laparoscopic ports used in certain laparoscopic surgical procedure to usage of much lesser ports for similar procedure.

A fine example is the conventional laparoscopic cholecystectomy with the use of four laparoscopic ports. From thence, literature has been published regarding use of three or even two ports for laparoscopic cholecystectomy with the intention of further reducing the amount of scar as well as tissue damage associated with port insertion [17, 18].

From here, laparoscopic surgery has further evolved when used in combination with NOSE or NOTES to further reduce surgical scars to an almost scarless surgery as was described in this chapter earlier. This is sometimes known as a hybrid procedure. Patients can now be offered this form of surgery as large specimens that cannot be retrieved via the small laparoscopic ports can be retrieved via the natural orifice. This enables us to avoid giving patient a big scar as it made no sense to make a big scar to retrieve specimen that is resected after going through many hours of performing such a complex surgery.

It is only a matter of time when laparoscopic surgery is performed via a single port, hence the introduction of single incision laparoscopic surgery (SILS). This may allow one to do away with some of the combined procedures with NOSE and NOTES as surgery can now be done via one incision with retrieval of specimen from the same incision.

When the single incision or port is inserted via the umbilicus or transumbilical, post-surgical scars is almost invisible when made over the umbilicus. Our experience in our centre has seen SILS being performed for operation such as cholecystectomy (Figure 11), excision of gastric Gastrointestinal stromal tumour (Figure 12), right hemi-colectomy (Figure 13), appendectomy, SILS anterior resection, SILS spleno-distal pancreatectomy and inguinal hernia repair where the port is inserted via the umbilicus. Post operatively, these scars were almost invisible or in other words scarless! Patients who have undergone these procedures were very satisfied with the outcome of this surgery and were happy that almost no scars were noticeable. Recovery is often uneventful and patients have experienced lower amount of pain.

In some literature, the umbilical route has also been described as a natural orifice as it is considered once as a natural orifice during embryological development. Hence, the term natural orifice transumbilical surgery (NOTUS) has been coined [19].

Not to rest on its laurels, SILS has also seen itself being evolved into more complex surgery such as colorectal resections or even bariatric surgery. The uses of SILS have also been described in various urological and gynaecological procedures as well with favourable outcomes.

Chambers et al have described the use of SILS in various colorectal resections ranging from appendectomy to hemicolectomies and anterior resection and proved that it was a safe and feasible surgery to perform in the hands of experience surgeons [20]. With regards to bariatric surgery, Reavis et al have described how sleeve gastrectomy was performed in obesity surgery via a single incision for laparoscopic ports placement and retrieval of the stomach specimen via the same incision [21].

The various literatures published to date regarding SILS augurs well for this surgical technology to further develop and as an offering to patients seeking a scarless surgery in the near future.

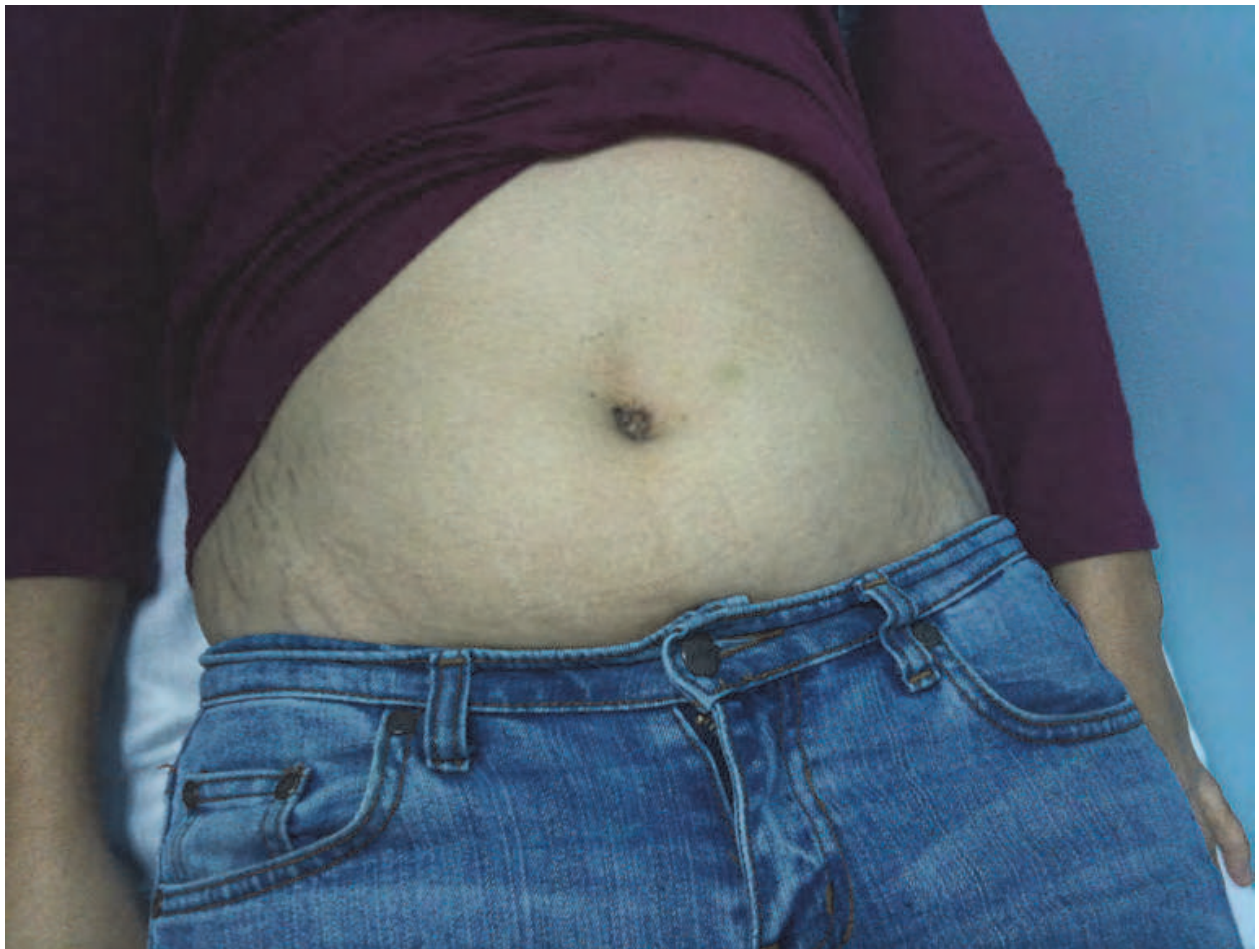


Fig. 11. Almost scarless wound at the umbilicus after SILS cholecystectomy

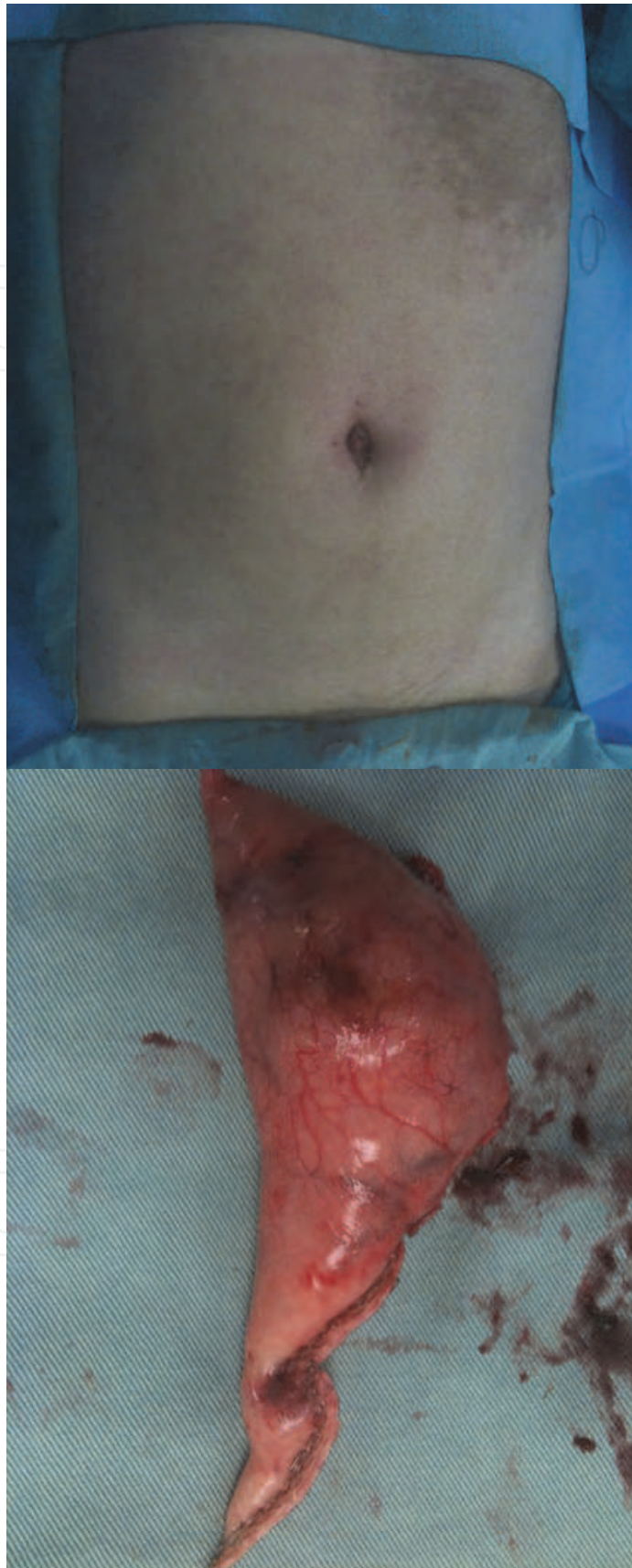


Fig. 12. Almost scarless wound at the umbilicus after SILS wedge excision of gastric GIST

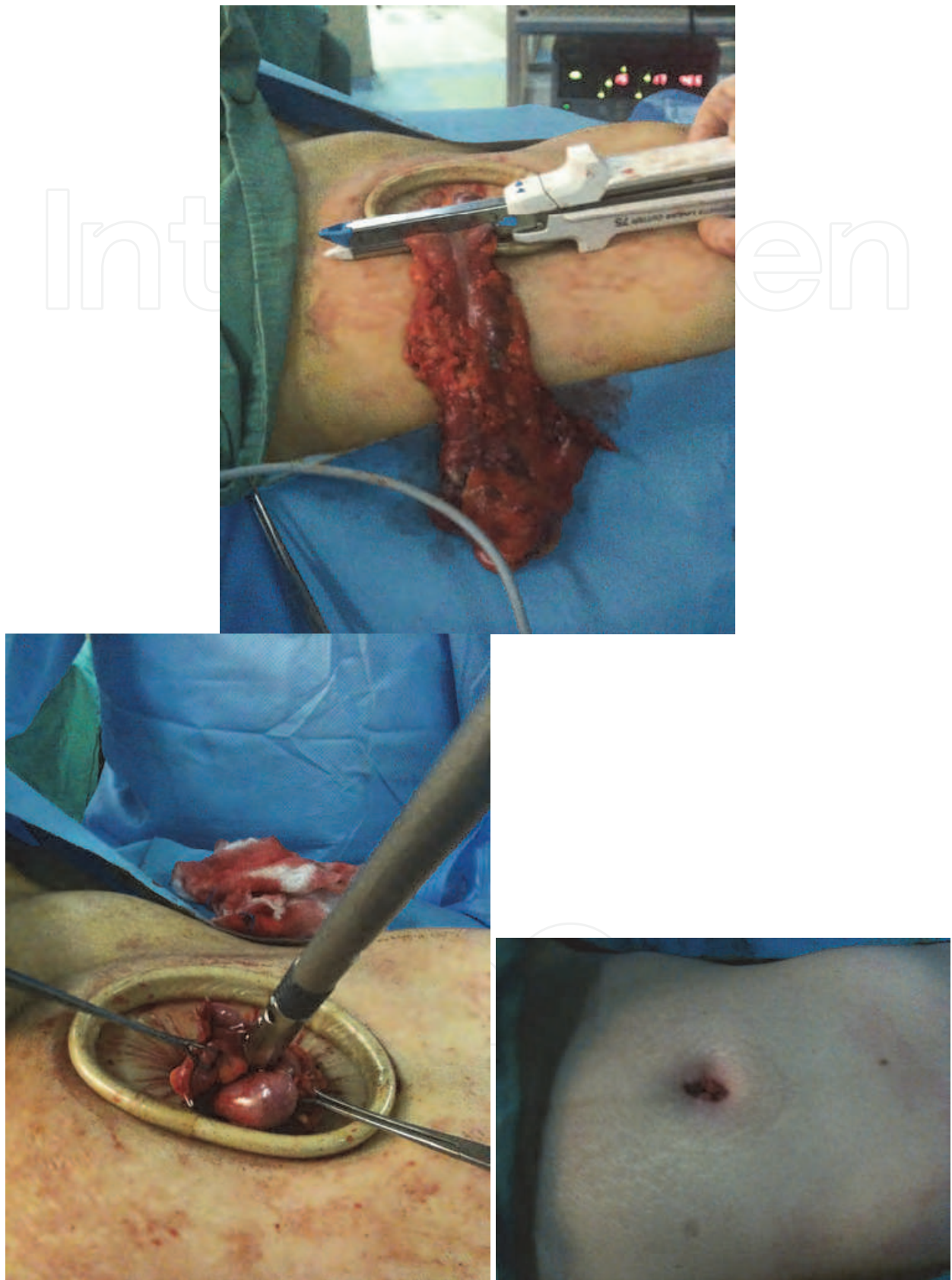


Fig. 13. An almost scarless wound at the umbilicus after a SILS right hemi-colectomy with extracorporeal anastomosis as demonstrated above.

5.2 The challenge ahead for SILS

Like any new surgical technology, SILS is not without its limitations. Among the many challenges faced by surgeons taking up SILS is the associated long learning curve. It is believed that one may overcome this limitation as more experience is gained from performing SILS on a regular basis.

More young surgeons should also be encouraged to take up this procedure as the longer exposure to SILS will in turn be gained as an experience over a period of time.

Next would be the instrumentation associated with SILS. The smaller degree of instrument triangulation often hampers or discourages one from taking up SILS. In our experience, this is one major drawback to SILS as oftentimes, surgeons find it difficult to perform SILS with the conventional and existing available instruments. It is not without doubt that smaller degrees of instrument triangulation often occurs compared to the conventional laparoscopic procedures when a single port is used. However, this may be overcome with better laparoscopic ports, platforms and devices which may allow flexibility and angulation to facilitate the use of SILS. This has actually encouraged industry players to inject funds into research and development for better instruments and equipment related to SILS as can be seen in today's modern day of surgical practice.

Is the future looking bright for SILS? We believe so, albeit a learning curve is associated with it and future development of newer laparoscopic instruments may further enhance and ease the use of this new surgical technology as more and more patients demand for a scarless approach to surgery in the near future.

6. Conclusion

The transvaginal route is most ideal for the retrieval of colonic specimens in laparoscopic colorectal surgery due to the advantage of its anatomical and physiological properties. Our experience with this technique showed that it is feasible for selected patients. It is also a safe procedure with low morbidity. Pain outcome is good and patient satisfaction is excellent.

The use of NOSE can also be seen in its application in other surgical disciplines allowing specimen extraction using various routes described.

Other techniques such as NOTES and SILS have also gained popularity and acceptance in this fast moving day and age of surgical technologies. These techniques described above often times complement each other or may be accomplished on its own in the case of SILS.

In conclusion, the advancement and evolution in surgical techniques this present day and for the future gives patients the satisfaction of an almost a scarless surgery.

7. References


- [1] Cheung, H.Y., et al., *Endo-laparoscopic colectomy without mini-laparotomy for left sided colonic tumors*. World J Surg, 2009. 33(6): p. 1287-1291.

- [2] Palanivelu, C., et al., *An innovative technique for colorectal specimen retrieval: A new era for Natural Orifice Specimen Extraction (NOSE)*. Diseases of the Colon and Rectum, 2008. 51: p. 1120-1124.
- [3] Gill, I.S., et al., *Vaginal extraction of the intact specimen following laparoscopic radical nephrectomy*. J Urol, 2002. 167: p. 238-241.
- [4] Vereczkei, A., et al., *Transvaginal extraction of the laparoscopically removed spleen*. Surg Endosc, 2003. 17: p. 157.
- [5] Franklin, M.E., et al., *Transvaginal extraction of the specimen after total laparoscopic right hemicolectomy with intracorporeal anastomosis*. Surg Laparosc Endosc Percutan Tech, 2008. 18(3): p. 294-298.
- [6] Ooi, B.S., et al., *Laparoscopic high anterior resection with natural orifice specimen extraction (NOSE) for early rectal cancer*. Tech Coloproctol 2009. 13: p. 61-64.
- [7] Roovers, J.P., et al., *A randomized comparison of post operative pain, quality of life, and physical performance during the first six weeks after abdominal or vaginal surgery correction of the uteri*. Neurourol Urodyn, 2005. 24: p. 334-340.
- [8] Schaeff, B., V. Paolucci, and J. Thomopoulos, *Port site recurrences after laparoscopic surgery. A review*. Dig Surg 1998. 15: p. 124-134.
- [9] Jeong, S.H., et al., *Trans-vaginal specimen extraction following totally laparoscopic subtotal gastrectomy in early gastric cancer*. Gastric Cancer, 2011. 14(1): p. 91-6.
- [10] Delvaux, G., et al., *Transvaginal removal of gallbladders with large stones after laparoscopic cholecystectomy*. Surg Laparosc Endosc, 1993. 3(4): p. 307-9.
- [11] Pearl, J.P. and J.L. Ponsky, *Natural orifice transluminal endoscopic surgery: a critical review*. J Gastrointest Surg, 2008. 12(7): p. 1293-300.
- [12] Breda, G., et al., *Laparoscopic nephrectomy with vaginal delivery of the intact kidney*. Eur Urol, 1993. 24(1): p. 116-7.
- [13] Gill, I.S., et al., *Vaginal extraction of the intact specimen following laparoscopic radical nephrectomy*. J Urol, 2002. 167(1): p. 238-41.
- [14] DeGer, S., et al., *Laparoscopic radical cystectomy with continent urinary diversion (rectosigmoid pouch) performed completely intracorporeally: an intermediate functional and oncologic analysis*. Urology, 2004. 64(5): p. 935-9.
- [15] Lima, E., et al., *Transvesical endoscopic peritoneoscopy: a novel 5 mm port for intra-abdominal scarless surgery*. J Urol, 2006. 176(2): p. 802-5.
- [16] Escobar, P.F., et al., *Laparoendoscopic single-site and natural orifice surgery in gynecology*. Fertil Steril, 2010. 94(7): p. 2497-502.
- [17] Kagaya, T., *Laparoscopic cholecystectomy via two ports, using the "Twin-Port" system*. J Hepatobiliary Pancreat Surg, 2001. 8(1): p. 76-80.
- [18] Leggett, P.L., et al., *Three-port microlaparoscopic cholecystectomy in 159 patients*. Surg Endosc, 2001. 15(3): p. 293-6.
- [19] Nguyen, N.T., et al., *Laparoscopic transumbilical cholecystectomy without visible abdominal scars*. J Gastrointest Surg, 2009. 13(6): p. 1125-8.
- [20] Chambers, W.M., et al., *Single-incision laparoscopic surgery (SILS) in complex colorectal surgery: a technique offering potential and not just cosmesis*. Colorectal Dis, 2011. 13(4): p. 393-8.

- [21] Reavis, K.M., et al., *Single-laparoscopic incision transabdominal surgery sleeve gastrectomy*. *Obes Surg*, 2008. 18(11): p. 1492-4.

IntechOpen

IntechOpen



Advances in Endoscopic Surgery

Edited by Prof. Cornel Iancu

ISBN 978-953-307-717-8

Hard cover, 444 pages

Publisher InTech

Published online 25, November, 2011

Published in print edition November, 2011

Surgeons from various domains have become fascinated by endoscopy with its very low complications rates, high diagnostic yields and the possibility to perform a large variety of therapeutic procedures. Therefore during the last 30 years, the number and diversity of surgical endoscopic procedures has advanced with many new methods for both diagnoses and treatment, and these achievements are presented in this book. Contributing to the development of endoscopic surgery from all over the world, this is a modern, educational, and engrossing publication precisely presenting the most recent development in the field. New technologies are described in detail and all aspects of both standard and advanced endoscopic maneuvers applied in gastroenterology, urogynecology, otorhinolaryngology, pediatrics and neurology are presented. The intended audience for this book includes surgeons from various specialities, radiologists, internists, and subspecialists.

How to reference

In order to correctly reference this scholarly work, feel free to copy and paste the following:

Peng Soon Koh and Kin Fah Chin (2011). Laparoscopic Surgery: An Almost Scarless Approach, Advances in Endoscopic Surgery, Prof. Cornel Iancu (Ed.), ISBN: 978-953-307-717-8, InTech, Available from: <http://www.intechopen.com/books/advances-in-endoscopic-surgery/laparoscopic-surgery-an-almost-scarless-approach>

INTECH
open science | open minds

InTech Europe

University Campus STeP Ri
Slavka Krautzeka 83/A
51000 Rijeka, Croatia
Phone: +385 (51) 770 447
Fax: +385 (51) 686 166
www.intechopen.com

InTech China

Unit 405, Office Block, Hotel Equatorial Shanghai
No.65, Yan An Road (West), Shanghai, 200040, China
中国上海市延安西路65号上海国际贵都大饭店办公楼405单元
Phone: +86-21-62489820
Fax: +86-21-62489821

© 2011 The Author(s). Licensee IntechOpen. This is an open access article distributed under the terms of the [Creative Commons Attribution 3.0 License](https://creativecommons.org/licenses/by/3.0/), which permits unrestricted use, distribution, and reproduction in any medium, provided the original work is properly cited.

IntechOpen

IntechOpen