

We are IntechOpen, the world's leading publisher of Open Access books Built by scientists, for scientists

6,900

Open access books available

186,000

International authors and editors

200M

Downloads

Our authors are among the

154

Countries delivered to

TOP 1%

most cited scientists

12.2%

Contributors from top 500 universities



WEB OF SCIENCE™

Selection of our books indexed in the Book Citation Index
in Web of Science™ Core Collection (BKCI)

Interested in publishing with us?
Contact book.department@intechopen.com

Numbers displayed above are based on latest data collected.
For more information visit www.intechopen.com



Ocular Endoscopy

Durval Moraes de Carvalho¹, Francisco Eduardo Lima²
and Durval Moraes de Carvalho Jr³

^{1,2}*Centro Brasileiro de Cirurgia de Olhos*

²*Universidade Federal de Goiás - UFG*

³*Centro Brasileiro da Visão
Brazil*

1. Introduction

The ocular endoscopy is available to the ophthalmology since the early 90's, however, until now there has not been consolidated as an essential tool to the world's ophthalmology (Uram, 1992b). The intraocular view is usually possible through adequate light and lens devices, due to the transparency of the part. These tools are practical and they may be also economical; in the cases which the cornea, anterior chamber, crystalline and vitreous are confusing the transparency, the ophthalmology has other resources using ultrasound and x-ray devices which enable the insight of the intraocular problems.

Nowadays the ocular endoscopy is an important resource to ophthalmology practice. Besides the sporadic use of it to the intraocular visualization, there are two other procedures in which it is essential: (a) In glaucoma surgery, Endoscopic cyclophotocoagulation (ECP) (Chen et al., 1997; Lima, 2000; Uram, 1992a; Lima, 1997). (b) In the implantation of intraocular lenses (IOL) in eyes without a capsular support (Scleral fixation) (Carvalho et al., 1996).

2. Glaucoma surgery using endoscopy: The Carvalho-Lima technique

The Glaucoma is an illness of the optical nerve which is irreversible and the intraocular pressure (IOP) is the most frequent cause of it. The primary open-angle glaucoma (POAG) is far the most common type of glaucoma in clinical practice, initially being treated with eye drops. For the cases in which the glaucoma surgery is indicated there are mainly two approaches:

One of them which is classical in all the world is the trying to increase the drainage of aqueous flow, the so called filtering surgeries. The main complications associated with filtering surgeries are due either to scaring process or overfiltration.

The other surgical approach to treat glaucoma is based on diminishing the aqueous production, and have the IOP reduced. Those are the cyclodestructive procedures. These procedures were usually performed by a transscleral route, either by freezing the ciliary body (cyclocryotherapy) or by coagulating the ciliary body with a laser source. Because the surgeon is not able to see the targets being treated, adjacent tissues may be damaged during

this process, which may contribute to a relatively high rate of complications, such as pain, visual acuity reduction, inflammation, hypotony and *phthisis bulbi*.

Recently, a new device (Fig. 1) that combines a laser source (Uram, 1992b), endoscopic probe (Fig. 2) and an illumination beam in the same probe has been developed. This instrument has the unique ability of simultaneous visualization and treatment of the ciliary body through a pars plana or anterior segment approach, or even combined with a cataract extraction. Additionally, some authors (Chen et al., 1997; Lima, 2000; Uram, 1992a; Lima, 1997) have demonstrated the safety and efficacy of the endocyclophotocoagulation (ECP) for treatment of refractory glaucoma.

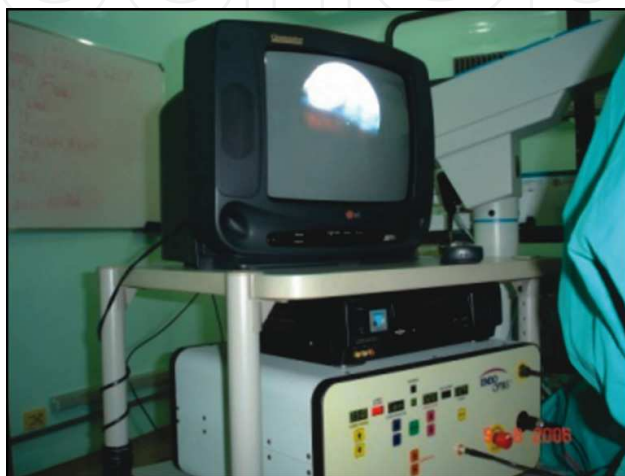


Fig. 1. Ocular endoscopy device; LASER (MicroProbe, ENDOOPTIKS, Little Silver, NJ, USA).




Fig. 2. The ECP probe showing its layers of optic fiber responsible for the light, videoendoscopy and LASER.

The ECP was done with a commercially available device (MicroProbe, ENDOOPTIKS, Little Silver, NJ, USA) with an endoscope with a 110-degree field of view and a focal distance of 2mm, camera and an 810 nm wavelength diode laser source with maximum power of 1.2W. In most of the cases the laser power used is 0.5W, continuous mode for approximately 2 seconds to produce both whitening and shrinkage of the ciliary processes. Laser power and/or duration is decreased if a “pop” is heard.

In phakic eyes the Carvalho-Lima's technique is indicated.

Carvalho-Lima's technique consists of phacoemulsification combined with ECP. ECP is accomplished through the bag and before the intraocular lens implantation (Fig. 3).

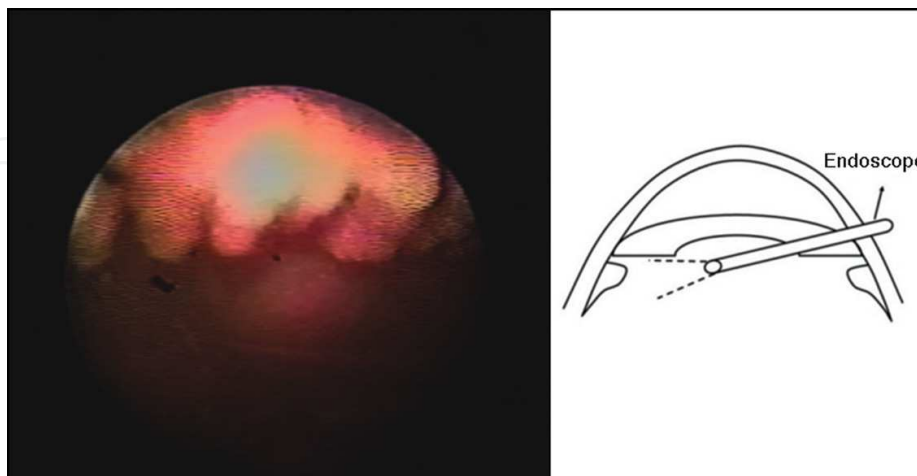


Fig. 3. Photocoagulation of the most bulging part of the ciliary process.

External scleral depression is performed to facilitate the photocoagulation of the entire ciliary process, including the valleys between the crests of the pars plicata and the anterior third of the pars plana. Additionally, external scleral depression is useful to guide the surgeon on how much of the ciliary process has been photocoagulated. This technique won a prize in the movies festival of ASCRS in 1999 (Fig. 4).

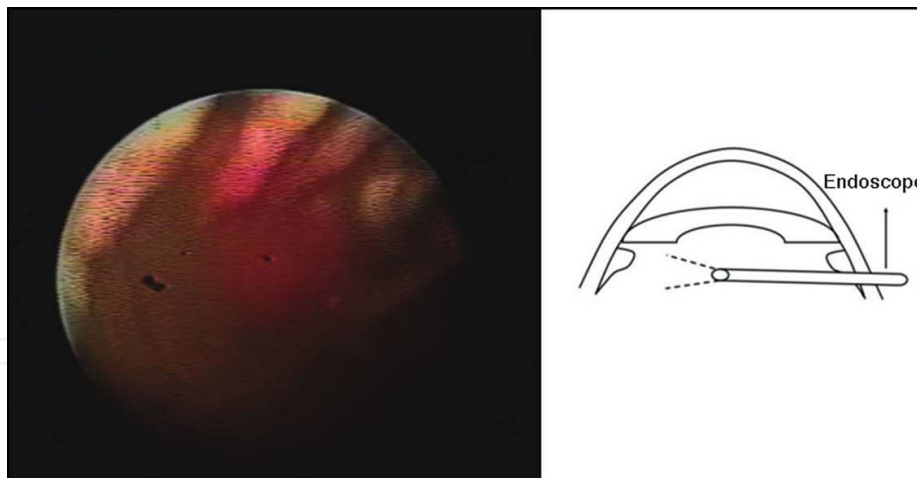


Fig. 4. Photocoagulation of the tail of the ciliary process with scleral depression.

In pseudophakic eyes the procedure is performed by a superior temporal pars plana incision, 3.5mm from the limbus after anterior vitrectomy.

In all eyes ECP is done to 210° of the ciliary body, corresponding to 2 to 9 hours in the right eye and from 3 to 10 hours in the left eye, including the anterior third of the pars plana. Subconjunctival injection of tobramycin and dexamethasone is performed after each procedure. Additionally, 0.1 ml of dexamethasone was injected in the anterior chamber. Topical antibiotics, corticosteroids and atropine were prescribed post-operatively and tapered as the intraocular inflammation decreased.

It has been observed that when the laser was used in the pars plana just behind the ciliary processes the hypotensive effect was greater. Would pars plana also be a secretor of aqueous? An experimental work done by Dr Durval M. Carvalho JR, MD (Carvalho Jr, 2002) in 2002 was to make it clear most of our doubts. The photocoagulation caused by the ECP causes three different tissue reactions, which varies according to the region of the ciliary body (Fig. 5 and 6), the intensity and time exposed to the laser. The first reaction observed is the whitening of the surface and if the laser exposition continues there is a shrinkage of the ciliary process. If the exposition is excessive, the energy is stored inside the ciliary process and it causes its explosion, emitting a short sound, possible to be heard (pop). The pop indicates overtreatment and is associated with hemorrhage, pigment dispersion and inflammatory reaction. Even though the explosion guarantees the destruction of the ciliary process, it must be avoided so as to cause less side effects.

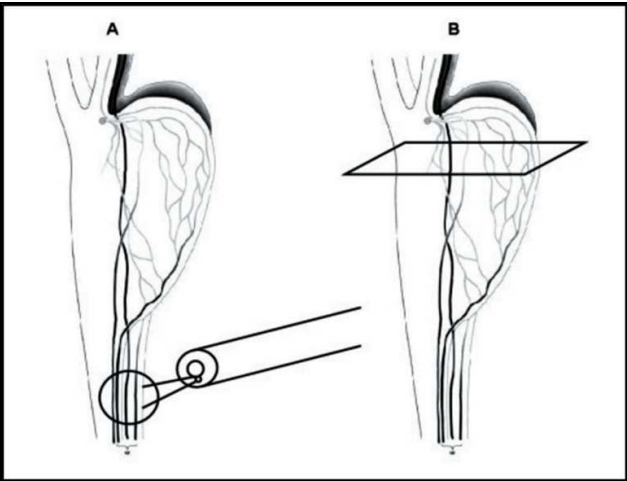


Fig. 5. Photocoagulation of the pars plana.

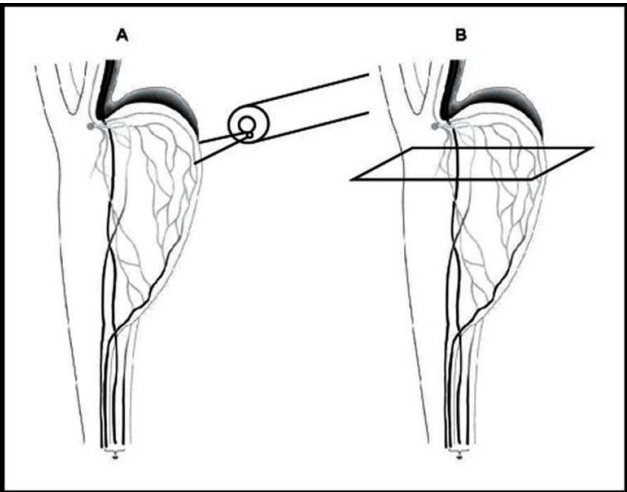


Fig. 6. Photocoagulation of the pars plicata.

In an experimental study (Carvalho Jr, 2002) evaluated the effect of the ECP in the different parts of the ciliary body in rabbit eyes. In the hystopathological analyses (Fig. 7) it was observed an indirect effect of the laser in the microcirculation of the ciliary body and not only the direct lesion to the epithelium. One of the most elucidative founds was the presence

of vascular congestion of all the ciliary process when only the pars plana was photocoagulated, suggesting strong suspect of a coagulative thrombosis caused by the laser (Fig. 8).

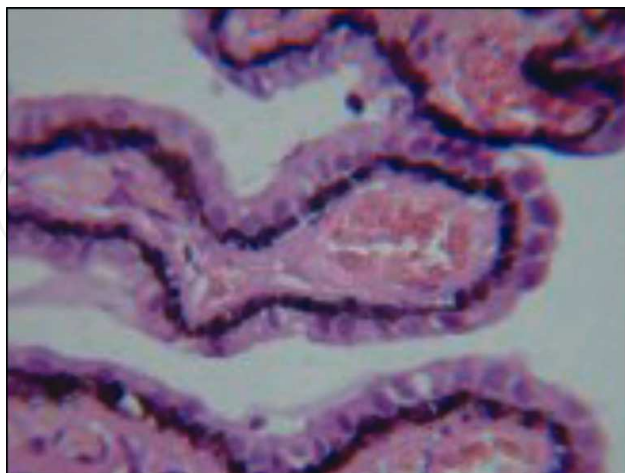


Fig. 7. Hystopathological photograph of a ciliary process of the eye of a rabbit without structure alterations.

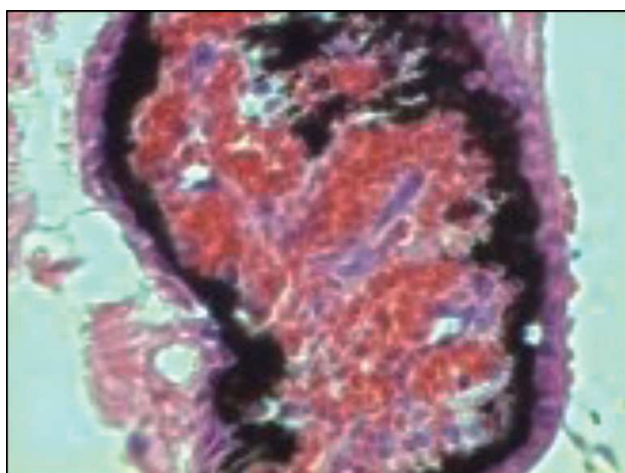


Fig. 8. Ciliary process enlarged with a vascular congestion after recent photocoagulation of the pars plana region.

So these findings may explain in part the variation of results according to the extension to be treated. The applications only in the part of the head (anterior) of the ciliary process can not achieve all the venule arcades, justifying this way an effect below the expected, and also explain the eyes treated 360° not to evolve to a bulbar atrophy. On the other hand the treatment only of the pars plana region reaches a higher hypotensor effect, justifying some cases of transcleral cyclophotocoagulation being effective achieving only the pars plana region. The practical application of this found comes to help with the interest of treating a shorter extension of the ciliary body and obtain higher effectivity reducing the IOP, reducing the risk of complications such as the bulbar atrophy. For this the application must be selective and assisted where the endoscopy showed superior itself, although this is an invasive procedure.

Lima and other authors, (Lima et al., 1997; Lima et al., 2004) obtained a clinical evidence in cases of refractory glaucoma treated by ECP, being photocoagulated all the ciliary process including its most posterior portion with the help of a scleral depression in a shorter extension. The reduction of the IOP to acceptable levels and its maintenance as time passes, and also the shorter risk of hypotony and bulbar atrophy has increased the confidence in the technique, that seems to be successful to other indications and not only as the last option.

Beyond the treatment of glaucoma and cataract combined, the main indications to ECP are:

- Eyes submitted to, at least, a filtration surgery with antimetabolics;
- As a primary procedure in eyes with glaucoma associated to a penetrating keratoplasty;
- As a primary procedure in neovascular glaucoma;
- Eyes submitted to drainage implant surgery;
- Eyes with the conjunctive attached and healed after the cataract surgery, retine surgeries, burn, traumas, etc.;
- Eyes with a congenital glaucoma after goniotomy and or trabeculotomy and a trabeculectomy.

Lima and other authors (Lima et al., 2004) have developed a prospective study to compare endoscopic cyclophotocoagulation (ECP) and the Ahmed drainage implant in the treatment of refractory glaucoma.

Sixty-eight eyes of 68 patients with refractory glaucoma were prospectively assigned to either ECP or Ahmed tube shunt implantation. All procedures were performed by a single surgeon. Eyes that were included were pseudophakic with a history of at least one trabeculectomy with antimetabolite, an intraocular pressure (IOP) equal to or above 35 mmHg on maximum tolerated medical therapy, and a visual acuity better than light perception.

Exclusion criteria included eyes that had had previous glaucoma drainage device implantation or a cyclodestructive procedure. Success was defined as an IOP more than 6 mmHg and less than 21 mmHg, with or without topical anti-hypertensive therapy.

The mean follow-up was 19.82 ± 8.35 months and 21.29 ± 6.42 months, for the Ahmed and ECP groups, respectively ($p = 0.4$). The pre-operative IOP, 41.32 ± 3.03 mmHg (Ahmed) and 41.61 ± 3.42 mmHg (ECP) ($p = 0.5$), and the mean post-operative IOP, at 24 months follow-up, 14.73 ± 6.44 mmHg (Ahmed) and 14.07 ± 7.21 mmHg (ECP) ($p = 0.7$), were significantly different from baseline in both groups ($p < 0.001$). Kaplan-Meier survival curve analysis showed a probability of success at 24 months of 70.59% and 73.53% for the Ahmed and ECP groups respectively ($p = 0.7$).

Complications included choroidal detachment (Ahmed 17.64%, ECP 2.94%), shallow anterior chamber (Ahmed 17.64%, ECP 0.0%) and hyphema (Ahmed 14.7%, ECP 17.64%).

In conclusion there was no difference in the success rate between the Ahmed Glaucoma Valve and ECP in refractory glaucoma. The eyes that underwent Ahmed tube shunt implantation had more complications than those treated with ECP.

A recent study (Lima et al., 2010) was designed to evaluate the safety and efficacy of phacoemulsification and endoscopic cyclophotocoagulation (ECP) as a primary surgical treatment for glaucoma and cataract.

Three hundred sixty-eight eyes from 243 patients with primary open-angle glaucoma and cataract that underwent an uncomplicated surgery from October 1998 to December 2006 with at least 2 years of follow-up were retrospectively enrolled. The patients were excluded if presented with a previous ocular history of any intraocular surgery or glaucoma laser treatment. Qualified success was defined as $5 \text{ mmHg} < \text{intraocular pressure (IOP)} < 21 \text{ mmHg}$ with or without topical antiglaucomatous drugs, and complete success as the same

IOP levels without therapy at all timepoints. Additionally, the needed of any further glaucoma surgery was defined as failure.

The mean follow-up was 35.15 ± 8.14 months. The IOP pre-operatively (23.07 ± 5.52 mmHg) was significantly greater than in the first day post-operatively (13.14 ± 6.09 mmHg), and months 1 (11.03 ± 2.59 mmHg), 6 (12.33 ± 3.01 mmHg), 12 (12.19 ± 2.19 mmHg), 24 (12.14 ± 2.89 mmHg) and in the last appointment (12.29 ± 2.44 mmHg) ($p < 0.001$ in all timepoints). The number of medications pre-operatively (1.44 ± 0.97) decreased (0.37 ± 0.74) ($p < 0.001$). Furthermore, there was significantly improvement in the LogMar visual acuity ($p = 0.01$). 334 (90.76%) eyes achieved qualified success, and 205 (55.7%), complete success.

Complications included immediate post-operative IOP spike 14.4% (53/368), post-operative fibrin exudates in anterior chamber 7.06% (26/368), cystoid macular edema 4.34% (16/368), transitory hypotony 2.17% (8/368), iris *bombé* 1.08% (4/368).

Phacoemulsification associated with Endoscopic Cyclophotocoagulation is safe and effective as a primary procedure for combined glaucoma and cataract.

There is no gold standard for surgical treatment of glaucoma. All the available techniques are unpredictable as far as the results and complications. Because of the direct approach to the ciliary body, the endoscopic cyclophotocoagulation (ECP) may be a reasonable option in these eyes.

3. Endoscopy in scleral fixation

In the past, cataract surgery just removed the opacified natural lens, leaving the patient without any substitute lens (aphakia), forced wear glasses with a very high degree. The history began to change in the war of 1945 when fragments of a transparent substance from the airplanes got incrustrated in the eye of one of the pilots and it did not cause any reaction; based on this Dr. Nicholas Harold Ridley was able to have a lens of this material which PMMA (polymethylmethacrylate) made and implanted it in the eye of a human; this was the first experience of a lens implantation inside the eye; since then, the technological evolution so as to substitute the glasses by intraocular lens (IOL) has got no limits. There has been a great advance in the industries that make lenses of different materials and functions, of equipments that make it easy the surgeries; surgical techniques more and more efficient and surgeons each time more able. Due to these concepts nobody else wants to wear glasses. Even all of this advanced technology, there are complicated cases of cataract surgery that intraocular lens support is lost. Not implanting the intraocular lens is a great complication, making necessary use postoperatively glasses with high degrees from 12 to 13 diopters, causing a poor quality of vision. How to implant an intraocular lens in the eye which does not have the capsule to support it anymore? So as to answer these questions we brought together our experience with other surgeons experts in different techniques and wrote a book: "Cataract Surgery - Fixation and Secondary Implants" edited by Elsevier in Portuguese (by now). Either in the literature and also in the ophthalmological practice we noticed that we are able to gather the techniques of lens fixation in eyes without a capsular support in the following groups: Anterior Chamber Intraocular Lens; Fixating the lens at the Iris; Fixating the lens at the sclera.

3.1 Anterior chamber intraocular lens

Anterior Chamber Intraocular Lens is an intraocular lens adapted to the anterior segment and implanted at anterior chamber angle, transition between the corneal and iris. The ease of

implantation is its advantage and the complications are related to corneal decompensation and iris inflammation.

3.2 Fixation of the lens in the iris

Fixation of the lens in the iris has the advantage of using most of the time the same intraocular lens of a regular cataract surgery. Its complications are most related to deviation of the pupil, iris inflammation, subluxation of the lens to fundus of the eye. This technique depends on good condition of the iris are therefore not for all cases.

3.3 Scleral fixation with endoscopy

We preferred the technique of fixation of the lens at the sclera because it can be applied in most of cases and intraocular lens stay closer to original position of the natural lens. Most of its complications like decentration of lens and cystic macular edema are related to incorrect positioning of the lens. These complications can be avoided by choosing the correct technique, its training and application of endoscopic findings. Part of scleral fixation works behind the iris, exactly where the haptics of the lens are fixated at scleral wall. The haptics are tightened by unabsorbable suture, fixating them in the scleral with buried stitches. The difficulty is that the ideal place for positioning and fixating the lens is just behind the iris, on blind area. Many decentrations of lens had unknown causes, and could not be repaired due to lack of visualization.

With the advent of the endoscope was first presented by Leon and al. in 1991, allowed us expose the blind region. With the technological advance of the ocular endoscopy in the 90's it was supposed to be given a solution to this problem to fixate an intra-ocular lens because with the endoscopy it is possible to have a visualization of the region behind the iris. With endoscopy we find the answer of all decentrations of the lens. However we have this visualization difficulty during the execution of techniques of sclera fixation. We observed that to use the ocular endoscopy in the surgery of sclera fixation it is essential that our technique is used: Finger Crafted Technique (Carvalho et al., 2009). Since we started to work with ocular endoscopy (1996), we perform the surgeries of scleral fixation with total visualization of the ciliary body (behind the iris) at the moment of the line passage and we know exactly where the loop of the lens will be positioned. We have observed that the surgeons have had difficulties on the use of the endoscopy to this procedure recently, not because of the device but due to the surgery technique. Using the Finger Crafted Technique the surgeon handles the needle with the fingers and this permits total security and control to the movement in which the line is passed. In this technique, the other hand gets free enabling the use of the Endoscope easily and with practice. In my conclusion, the scleral fixation is not yet a reproductive technique, standardized and safe, not because of lack of the endoscopy, but because of the non-use of a technique that enable the use of the device with practice similar to what happens when the Finger Crafted Technique is used.

3.4 Surgical technique

3.4.1 Materials

The materials used in this surgical technique include a 30.5-gauge needle that is often used for insulin administration as a guide needle. Suture used in this technique is a 9-0 prolene suture with 2 needles of 0.65 mm. A Blumental type of anterior maintainer is used to keep the anterior chamber from collapsing. A hook with a T tip is used as needed during the surgery. The endoscope provides direct visualization of the ciliary sulcus and aids in good positioning of the sutures and the IOL haptics (MicroProbe; EndoOptiks, Little Silver, NJ).

In all the other techniques which the needle is held by a needle holder and not by the fingers, at the moment of transfixation of the sclera, it is almost impossible or at least very hard to visualize with the endoscope and pass the line in the desirable local simultaneously. When the needle is handled with a needle holder, in all the moments, the other hand is needed to replace the needle on the needle holder and it is not possible to handle the endoscope. The details of this technique are complete in the link: Sclera Fixation of Posterior Chamber Lens Implant With Ocular Endoscopy= The Finger-Crafted Technique and Embedded Sclera Suture (Carvalho, D.M. & D.M. Jr., 2007).

3.4.2 Method

Together with our book about sclera fixation, there is a DVD with the videos of each surgical technique. Due to the great diversity of cases that need the sclera fixation, we thought it would be better to gather the cases in 14 situations and so 14 videos. As an example: The eyes that are being operated from the cataract and it was not possible to implant the lens at that moment, and the surgeon decides to wait so as to implant a lens in a second opportunity, in these cases the surgical strategy to make the sclera fixation is completely different for a case that comes with an intraocular lens sprained for the vitreous cavity, as it is different to program the sclera fixation in the eyes of people that are carriers of a crystalline bad formation syndrome such as the Marfan or Marchesane etc.

We will describe the Finger Crafted Technique when applied in the surgery of an eye with a good vision potential and a carrier patient of a sprained lens for the vitreous. Let's imagine a patient that has already been operated of cataract for a while, and scratching the eye, the lens were sprained to the macula. Even having restriction in a case like this, there are several strategic possibilities. Let's suppose it is a right eye, so we will observe first, what its ocular pressure is. The lens is next to the pupil or it is gathered to the retina? Supposing the ocular pressure over 25mm/hg and the lens next to the pupil we could program:

3.4.3 Preparing the eye to an sclera fixation

With the pupil dilated by eyedrops we make an incision in the conjunctiva in both sides of the eye, next to the EIXO of 3 and 9 hs. The conjunctiva is then folded in 2 equidistant points and the surgeon then performs a 1.5 mm sclerotomy perpendicular to the limbus, starting at 0.5 mm. This sclerotomy should go down almost to the point of reaching the choroid.

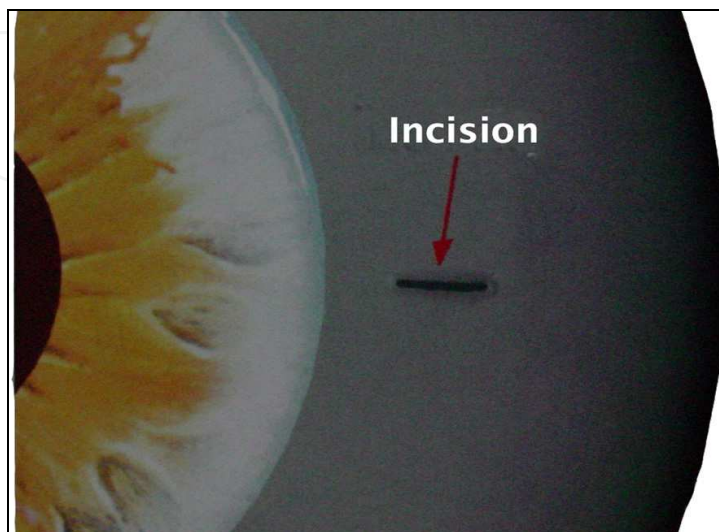


Fig. 9. Scleral Incision.

While preparing the surgery table, the assistant surgeon can hand the surgeon the 9-0 prolene suture material, already cut in half, in the 30.5 gauge guide needle (insulin needle). The surgeon will hold the body of the needle with one hand and Mcpherson forceps are used to pass the threat through the bevel until the other end comes out of the base of the needle. This thread is then pulled until it is the same size as the portion not inserted in the needle.




Fig. 10. Preparing the needle and bended needle prepared.

Using his fingers, the surgeon bends the tip of the needle to make it more ergonomic, pushing the eyelids away when the needle is introduced in the eye (fig. 10). In the temporal limbus, around 7hs we perform a parecentese to the implantation to the chamber maintainer which keeps conected to a balanced salt solution, in a height of 10cm over the eye level so as to keep it with a low pressure. Superior perictomy, opening the conjunctiva in an extension of 6 mm. With the sclera exposed next to the superior limbus an incision is made on the frown (incision as inverted smile) also of 6 mm and it is made a

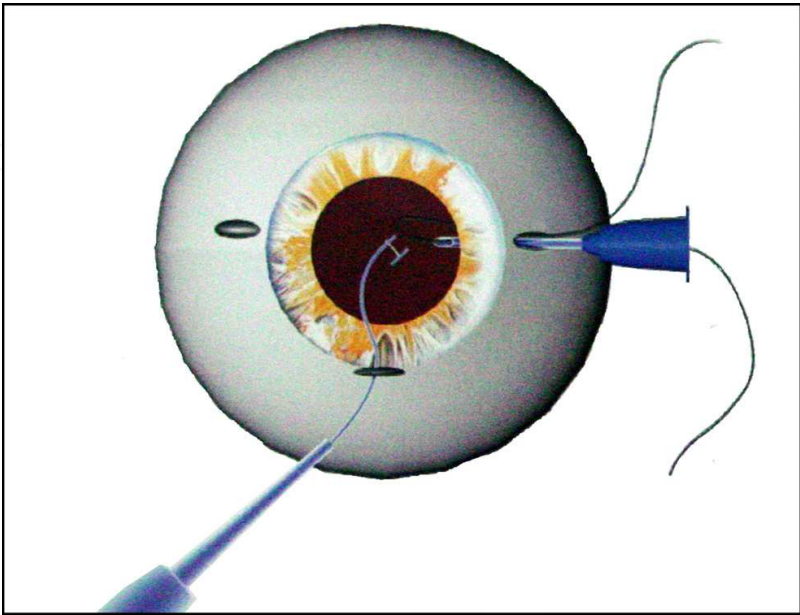


Fig. 11. Needle introduction.

sclera delamination until we get to the cornea. In this phase, the penetration in the anterior chamber must be only of 2 to 2.50 mm in the middle of the incision even though the dilamination is of 6mm; This dilamination typical of the incisions used in the cataract surgeries for extracapsulars.

The surgeon introduces the endoscope through the main incision while, with the other hand, he introduces the previously threaded needle for the sclerotomy, which will be monitored as it penetrates the ciliary sulcus. Using the saline solution, placed about 80 cm above the eye surface, connected by the anterior chamber maintainer.

Once the tip of the needle is inserted, the solution is lowered to 10 cm, the endoscope is removed and the needle is presented until it extends beyond the middle portion of the pupil. It is then retracted to loosen the loop of the thread which is found at the end, forming a loose loop. The other hand captures this loop with a hook, removing it from the eye.

The same maneuver is performed on the other side. Therefore, the main incision should be equidistant from the sclerotomy sites, to facilitate the view with the endoscope.

With the prolens made apparently by the main incision, the incision is increased to the 6 mm completing the incision of the delamination previously elaborated.

The folded prolens (loops) are positioned on the side of the incision of the sclera delamination so as not to bother the lens to be taken away (fig. 12).

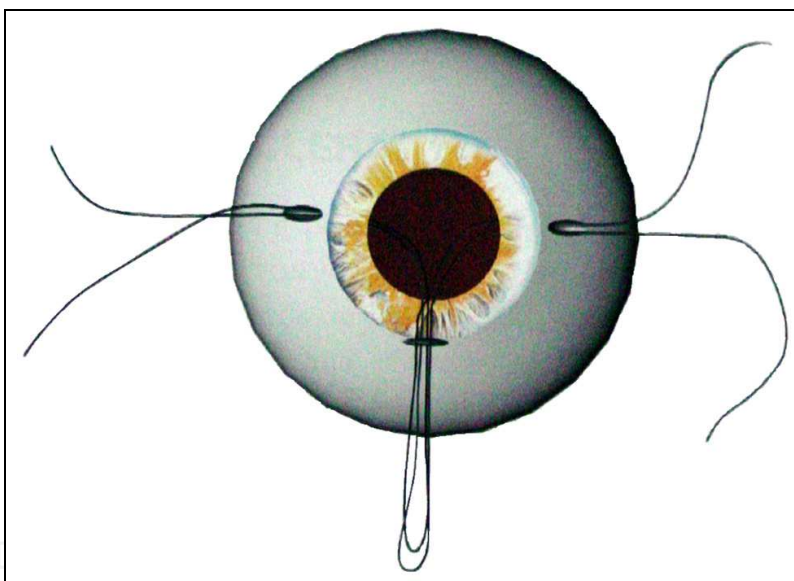


Fig. 12. Position of sutures after its introduction.

3.4.4 Correcting the decentred IOL

It is made one more paracentese of 1.50 mm in 2hs and it is introduced by it a hook with a straight holder so as to reach the haptic of the sprained lens in the vitreous. The lens is hold by the hook and it is moved softly and so as to avoid vitreous tractions in the moment of taking the lens we introduce the vitreofagus by the temporal sclerectomy, it is procedure one vitrectomy so as to totally set free the lens.

The lens is brought and kept in the anterior chamber by the hook and with the introduction of another hook by the main incision the function is passed to this new one which pulls and make it exterior the loop of the lens with the help of a spatula until it is taken from the eye (fig. 13).

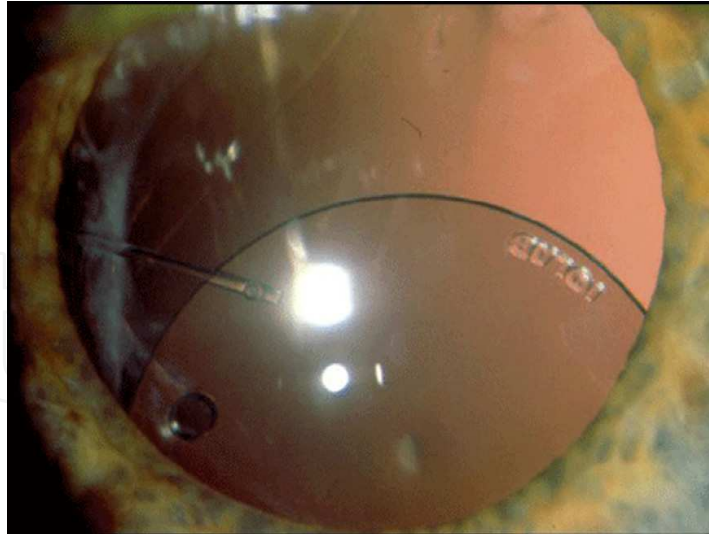


Fig. 13. Intraocular lens decentred.

3.4.5 Implanting the IOL

The chosen foldable, acrylic, monofocal or multifocal IOL in three pieces is placed on a support over the cornea, to prevent contamination.

Using those prolens that were resting on the side of the main incision the first haptic is tied with three simple knots and so the lens is twisted and the second loop is also tied the same way (fig. 14).

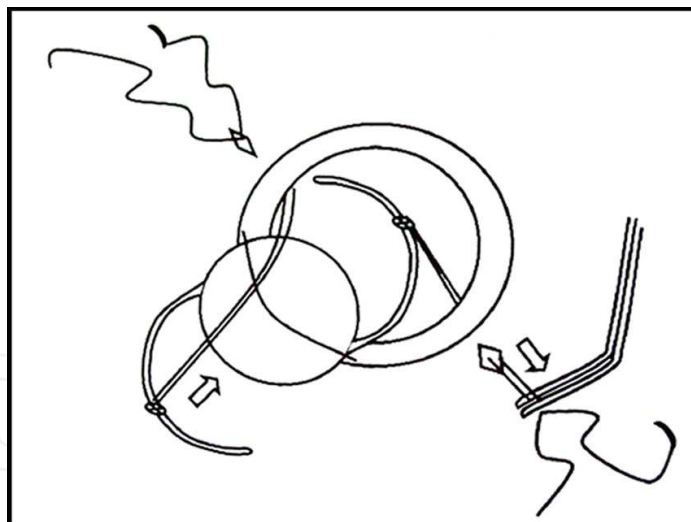


Fig. 14. Introducing lens attached to the prolens.

The anterior chamber is filled with viscoelastic, better if cohesive. In this moment it is closed the entrance of the balanced solution.

Carefully, with the MacPherson forceps the lens is introduced in the eye. In the same moment that it is being introduced, the prolens that go out from the sclerotomy are pulled and held in the first haptic, so as to direct it to the ciliary sulcus.

The first haptic, positioned, the auxiliary will keep it in the same position holding the prolens while the surgeon introduces and put in position the second haptic, using a forceps

and the holding that keeps it. In this moment sometimes opening the infusion helps in the position of the iol.

After the IOL is positioned, the embedded Sclera Stitch is then put in place with the 2 prolens from each sclerotomy, which came from the haptics. They are part of the same thread, and one end has been inserted into a needle while the other hasn't. The needle is then used to place a stitch outwards, on one of the borders, and then an inward stitch, on the other border. At the end, then, the embedded bared stitch is then placed in each sclerotomy. By tying the three single knots, the sclerotomy will be closed, thereby embedding the knots and fixating the IOL. After the prolens are cut close to the sclera, the knots will tend to go deeper into the scleral incision and the tips will remain inside the sulcus (fig. 15).

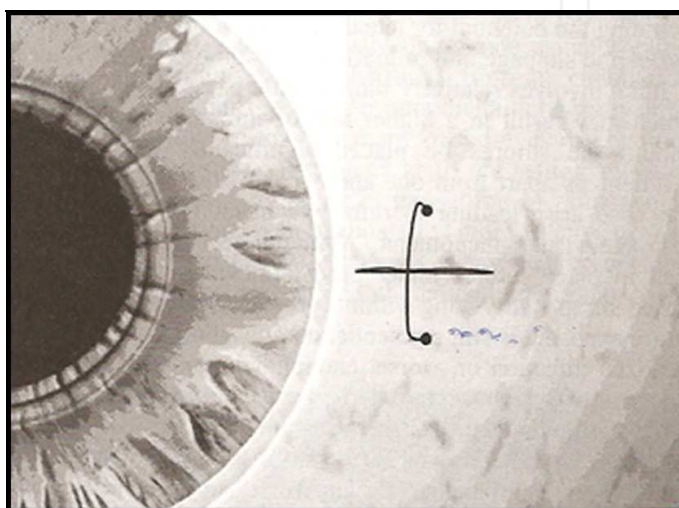


Fig. 15. Final Result of Buried Scleral Suture.

3.4.6 Endocyclophotocoagulation

As in this case the ocular pressure is high and, normally it tends to increase with the surgery, it was planned the endocyclophotocoagulation. When we notice that the lens is well stable in the eye we do not use its visualization by the endoscopy.

When the aim is only the photocoagulation:

The endoscope probe is introduced by the temporal sclerectomy and we perform the photocoagulation as it was already described before, reaching all the possible area of the ciliary body, when we use only an sclera incision. Generally we reach over 220 degrees.

After the endocyclophotocoagulation we take out the probe and introduces the vitreofagus through the same incision trying to take out the vitreous that may be held by the loops and that might get closed in the incisions. During the use of the vitreofagus it is necessary that the vial height is higher so as to balance the ocular pressure during the aspiration. At the end so as to avoid that the beams stay in the sclerectomy, we reduce the height of the vial before we take the vitreofagus and we also aspirate the incision very well.

The sclerectomy is closed, the chamber maintainer is taken, two or three stitches are made in the main incision so as to avoid the astigmatism, the conjunctiva is closed with absorbable prolens.

The post operative period is as simple as the cataract surgery post operative where we generally use antibiotic eyedrops for 8 days, prednisolone eyedrops for 15 days and non hormonal antiinflammatory eyedrops for 30 days applied 4 times a day.

3.4.7 Discussion

The videoendoscopy has a bunch of advantages for the sclera fixation. Before this videoendoscopy the patient and the surgeon used to have some complications such as glaucoma, cystic macular edema, hemorrhage, decentration, IOL inclination without resources for an immediate clear up.

The ocular endoscopy may help us in the implantation procedures of intraocular lens in eyes without a capsular support in several ways. For example:

3.4.7.1 Diagnosis

- Inspect the retroiridian region to identify vitreous beams, SINEQUIAS, and if the loop is positioned correctly in the recess.
- Inspect the posterior pole about the retinian hemorrhages, crystalline material, sprained IOL and others.

3.4.7.2 Procedure assistance

- Monitoring the entrance of the needle by the sulcus;
- Monitoring the vitreofagus point in the retroiridian space and posterior pole;
- Auxiliating in the repositioning of the sprained IOL;
- Auxiliating in the needle penetration, as a support.

3.4.7.3 Treatment

- Photocoagulate hemorrhage caused by the needle penetration;
- Photocoagulate the ciliary processes for the treatment of associated glaucoma;
- Photocoagulate the retina in the presence of associated retinian hemorrhages.

The penetration of the needle through the sclera monitored by the endoscope makes sure the thread fixation in the ciliary sulcus. It is a practical maneuver and it requires the pressurized eye through a maintainer and a protection with viscoelastic in the anterior chamber. As soon as the needle starts to be transfixated in the sclera, the surgeon stops looking through the microscope and follows through the screen the endoscope image. It is observed the showing of the indentation through the tip of the needle, allowing its redirection to the ciliary sulcus if it shows in a wrong place.

This technique, besides making sure the correct position of the thread in the ciliary sulcus, it permits the photocoagulation of the hemorrhages that may appear due to the needle penetration, observed more frequently, in hypotensive eyes or with an inflammatory reaction sign.

Another resource that this technique propotioned is the possibility of impeding the uveal dislocation, pressing on the sclera the optic fiber itself, working as an opposite point and making it easier the passage of the needle.

With the use of the endoscopy in the sclera fixation it increased the precise to get right the ciliary sulcus during the needle perforation from outside to inside directed by the indentation.

After implanting the lens it is possible to perform a review introducing behind the iris the endoscope probe to make sure that the lens is in the correct position. In the presence of decentration or inclination of the IOL in general we find one of the following alterations: Vitreous beam mixed with the haptic and the thread, the inadequate position in the introduction of the IOL, cortical mass lefts promoting kind of a gear over the haptic, fibrosis, rest of capsule gathered in the iris, dislocation of the knot on the holder and others.

When the haptic, of a sprained IOL is on the periferic area, positioned in the vitreous basis, it has its access more difficult and for many times being the cause of the vitreous traction and retine tears , even though specific lens for the vitrectomy surgeries are used. The endoscopy may offer a better angle of vision in the retroirian region, with the advantage of dispersating the sclera depression or the exaggerated twisting of the eye.


The third function of the URAM E2 is the application of laser using the endoscopy, very useful in the last cases of sclera fixation, that frequently are associated to the glaucoma and being worse when the conjunctive is already manipulated.

The association of the videoendoscopy with the photocoagulation brought for us practice for the cases of afacic with glaucoma. It is frequent the surgical reintervention in the eyes which have already being operated due to the cataract and they turn to have glaucoma, mainly the ones that showed a higher ocular pressure. Before the endocyclophotocoagulation we used to avoid the indication for sclera fixation in these cases because we knew that if the glaucoma showed up the consequences would be very hard.

4. References

- Althaus, C.; Sundmacher, R. (1993). Intraoperative intraocular endoscopy in transscleral suture fixation of posterior chamber lenses: consequences for suture technique, implantation procedure, and choice of PCL design. *Refract Corneal Surg.* 9(5):333-9.
- Busacca, A. (1955) Physiology of the ciliary muscle as studied by gonioscopy. *Ann Ocul.* 188(1):1-19. Paris.
- Burian, H.M.; Allen, L. (1955). Mechanical changes during accommodation observed by gonioscopy. *AMA Arch Ophthalmol.* 54(1):66-72.
- Carvalho, D.M.; Paranhos, F.R.L. (1993). Implante secundário de LIO de câmara posterior: fixação escleral. *Rev Bras Oftalmol.* 52(1):17-22.
- Carvalho, D.; Lima, F.E.; Degani, M.I. (1996). Endoscopia Ocular e Fixação de Lente Intra-Ocular. *Revista Brasileira de Oftalmologia* 55. (4):285-7.
- Carvalho, D.M. & D.M. Jr. (2007). Fixação escleral: técnica de agulha guia (finger crafted technique) com ponto escleral sepultado. *Cirurgia de catarata: fixação e implantes secundários.* (3):19-47. Elsevier Editora Ltda.
- Carvalho Jr, D.M. (2002). Ciclofotocoagulação endoscópica: estudo experimental com aplicação de laser diodo nas diferentes porções do corpo ciliar em olhos de coelhos pigmentados. *Tese de Doutorado.* Universidade de São Paulo. 70p. São Paulo, Brasil.
- Chen, J.; Cohn, R.A.; Lin, S.C.; et al. (1997). Endoscopic photocoagulation of the ciliary body for treatment of refractory glaucomas. *Am J Ophthalmol.* 124(6):787-96.
- Funk, R.; Rohen, J.W. (1987). SEM studies on the functional morphology of the rabbit ciliary process vasculature. *Exp Eye Res.* 45(4):579-95.
- Funk, R.; Rohen, J.W. (1987). Intraocular microendoscopy of the ciliary-process vasculature in albino rabbits: effects of vasoactive agents. *Exp Eye Res.* 45(4):597-606.
- Funk, R.; Rohen, J.W. (1988). Experimental studies on the functional morphology of the vascular system of the anterior eye segment in rabbits and primates. *Fortschr Ophthalmol.* 85(2):170-6.
- Funk, R.; Rohen, J.W. (1988). Reactions of efferent venous segments in the ciliary process vasculature of albino rabbits. *Exp Eye Res.* 46(1):95-104.

- Funk, R.; Rohen, J.W. (1988). SEM studies of the functional morphology of the ciliary process vasculature in the cynomolgus monkey: reactions after application of epinephrine. *Exp Eye Res.* 47(4):653-63.
- Funk, R.; Rohen, J.W. (1989). Microendoscopy of the anterior segment vasculature in the rabbit eye. *Ophthalmic Res.* 21(1):8-17.
- Leon, C.S.; Leon, J.A. (1991). Microendoscopic ocular surgery: a new intraoperative, diagnostic and therapeutic strategy. Part I: Endoscopic equipment/methodology applied to cataract surgery with intraocular lens implantation. *J Cataract Refract Surg.* 17(5):568-72.
- Leon, C.S.; Leon, J.A. (1991). Microendoscopic ocular surgery: a new intraoperative, diagnostic and therapeutic strategy. Part II: Preliminary results from the study of glaucomatous eyes. *J Cataract Refract Surg.* 17(5):573-6.
- Leon, J.A.; Leon, C.S.; Aron-Rosa, D.; et al. (2000). Endoscopic technique for suturing posterior chamber intraocular lenses. *J Cataract Refract Surg.* 26(5):644-9.
- Lima, F.E.; Carvalho, D.M.; Beniz, J.; Ávila, M. (1997). Ciclofotocoagulação endoscópica em glaucomas refratários. *Rev. bras. oftalmol* 56. (6):387-93.
- Lima, F.E.; Carvalho, D.M.; Beniz, J.; Ávila, M. (1997). Ciclofotocoagulação Endoscópica em Glaucomas Refratários. *Rev Bras Oft* 56. (6):397-406.
- Lima, F.E.; Costa, V. (2000). Management of complex glaucoma: Tube shunt versus cyclodestructive procedure. *Glaucoma Perspectives in Practice – Issue 2.3.*
- Lima, F.E.; Magacho, L; Carvalho, D.M.; Susanna, R.; Ávila, M.P. (2004). A Prospective, Comparative Study between Endoscopic Cyclophotocoagulation and the Ahmed Drainage Implant in Refractory Glaucoma. *Journal of Glaucoma* 13(3): 233-237.
- Lima, F.E.; Carvalho, D.M.; Ávila, M.P. (2010). Phacoemulsification and endoscopic cyclophotocoagulation as primary surgical procedure in coexisting cataract and glaucoma. *Arquivos Brasileiros de Oftalmologia.* 73(5).
- Malbran, E. S. & E. Jr.; Negri, I. (1986). Lens guide suture for transport and fixation in secondary IOL implantation after intracapsular extraction. *Int Ophthalmol.* 9 (2-3): 151-160.
- Mizuno, K.; Asaoka, M. (1976). Cycloscopy and fluorescein cycloscopy. *Invest Ophthalmol.* 15(7):561-4.
- Mizuno, K.; Asaoka, M.; Muroi, S. (1977). Cycloscopy and fluorescein cycloscopy of the ciliary process. *Am J Ophthalmol.* 84(4):487-95.
- Pavlin, C.J.; Rootman, D.; Arshinoff, S.; et al. (1993). Determination of haptic position of transsclerally fixated posterior chamber intraocular lenses by ultrasound biomicroscopy. *J Cataract Refract Surg.* 19(5):573-7.
- Pietrabissa, A.; Scarcello, E.; Carobbi, A.; Mosca, F. (1994). Three-dimensional versus two-dimensional video system for the trained endoscopic surgeon and the beginner. *Endosc Surg Allied Technol.* 2(6):315-7.
- Scheie, H.G. (1953). Gonioscopy in the diagnosis of tumors of the iris and ciliary body, with emphasis on intraepithelial cysts. *Trans Am Ophthalmol Soc.* 51:313-31.
- Uram, M. (1992a). Ophthalmic laser microendoscope ciliary process ablation in the management of neovascular glaucoma. *Ophthalmology* 99. (12):1823-8.
- Uram, M. (1992b). Ophthalmic laser microendoscope endophotocoagulation. *Ophthalmology* 99. (12):1829-32.
- Zarbin, M.A. et al. (1988). Endolaser treatment of the ciliary body for severe glaucoma. *Ophthalmology* 95. 1639.



Advances in Endoscopic Surgery

Edited by Prof. Cornel Iancu

ISBN 978-953-307-717-8

Hard cover, 444 pages

Publisher InTech

Published online 25, November, 2011

Published in print edition November, 2011

Surgeons from various domains have become fascinated by endoscopy with its very low complications rates, high diagnostic yields and the possibility to perform a large variety of therapeutic procedures. Therefore during the last 30 years, the number and diversity of surgical endoscopic procedures has advanced with many new methods for both diagnoses and treatment, and these achievements are presented in this book. Contributing to the development of endoscopic surgery from all over the world, this is a modern, educational, and engrossing publication precisely presenting the most recent development in the field. New technologies are described in detail and all aspects of both standard and advanced endoscopic maneuvers applied in gastroenterology, urogynecology, otorhinolaryngology, pediatrics and neurology are presented. The intended audience for this book includes surgeons from various specialities, radiologists, internists, and subspecialists.

How to reference

In order to correctly reference this scholarly work, feel free to copy and paste the following:

Durval Moraes de Carvalho, Francisco Eduardo Lima and Durval Moraes de Carvalho Jr (2011). Ocular Endoscopy, *Advances in Endoscopic Surgery*, Prof. Cornel Iancu (Ed.), ISBN: 978-953-307-717-8, InTech, Available from: <http://www.intechopen.com/books/advances-in-endoscopic-surgery/ocular-endoscopy>

INTECH
open science | open minds

InTech Europe

University Campus STeP Ri
Slavka Krautzeka 83/A
51000 Rijeka, Croatia
Phone: +385 (51) 770 447
Fax: +385 (51) 686 166
www.intechopen.com

InTech China

Unit 405, Office Block, Hotel Equatorial Shanghai
No.65, Yan An Road (West), Shanghai, 200040, China
中国上海市延安西路65号上海国际贵都大饭店办公楼405单元
Phone: +86-21-62489820
Fax: +86-21-62489821

© 2011 The Author(s). Licensee IntechOpen. This is an open access article distributed under the terms of the [Creative Commons Attribution 3.0 License](https://creativecommons.org/licenses/by/3.0/), which permits unrestricted use, distribution, and reproduction in any medium, provided the original work is properly cited.

IntechOpen

IntechOpen