

We are IntechOpen, the world's leading publisher of Open Access books Built by scientists, for scientists

6,900

Open access books available

186,000

International authors and editors

200M

Downloads

Our authors are among the

154

Countries delivered to

TOP 1%

most cited scientists

12.2%

Contributors from top 500 universities



WEB OF SCIENCE™

Selection of our books indexed in the Book Citation Index
in Web of Science™ Core Collection (BKCI)

Interested in publishing with us?
Contact book.department@intechopen.com

Numbers displayed above are based on latest data collected.
For more information visit www.intechopen.com



Evolution of the Adenoidectomy in the Endoscopic Era

Fabio Pagella, Alessandro Pusateri,
Georgios Giourgos and Elina Matti
*Foundation IRCCS Policlinico San Matteo
and University of Pavia
Italy*

1. Introduction

During the last 20 years, we have observed an increasing recognition of the high prevalence of sleep-disordered breathing (SDB) in children. Adenotonsillar enlargement, leading to a partial or a complete obstruction of the nasopharynx (or epipharynx, or rhinopharynx) and/or of the oropharynx, accounts for the vast majority of cases. Consequently, the number of adenoidectomies performed in children for SDB has increased significantly. An adenoidectomy can be performed as an isolated procedure or as part of an adenotonsillectomy operation. As a matter of fact, adenoidectomy with or without tonsillectomy is one of the most common surgical procedures performed by Otolaryngologists in the paediatric population. Historically, tonsil and adenoid surgery increasingly began to be carried out together in the early 20th century, as the popular “focus on infection” theory attributed various systemic disorders to diseased tonsils and adenoids; thus, tonsillectomy plus adenoidectomy were recommended as a standard treatment for several different conditions as anorexia, mental retardation and enuresis, or simply as a general measure to promote good health (Hays, 1924; Kaiser, 1932). In certain communities the surgical procedure was performed widely in the entire population of scholars in public school buildings (Baker, 1953). Over the years, things have changed, and precise indications were proposed for tonsillectomy and adenoidectomy. Adenoid hypertrophy can lead to obstructive sleep apnea, otitis media with effusion, recurrent otitis media and nasal obstruction, and nowadays these remain the most common indications for adenoidectomy.

Techniques and instruments have considerably evolved from the first techniques described by Cornelius Celsus in the first century A.D. (Thornval, 1969) and Paul of Aegina in 625 A.D. (Paul of Aegina, 1847) to the later contributions of surgeons such as Wilhelm Meyer of Copenhagen and Samuel J. Crowe in the last centuries (Curtin, 1987; Meyer, 1870; Wiatrak & Wooley, 2005; Younis & Lazar, 2002). Pioneers of tonsillectomy and adenoidectomy have developed novel techniques and instruments in order to increase the speed of the procedure, especially in the pre-anesthesia era, and to decrease the intra-operative complications and postoperative morbidity.

The classic surgical technique performed with an adenoid curette or an adenotome has recently evolved by the introduction of the endoscopic sinus surgery (ESS)

instrumentation, with an improved patients' outcome and a better satisfaction of the surgeon (Havas & Lowinger, 2002; Rodriguez et al., 2002; Stanislaw et al., 2000). The standard adenoidectomy technique is to remove the nasopharyngeal lymphatic tissue with an adenoid curette or an adenotome (Figure 1 – 3), under general anaesthesia via oro-tracheal intubation, with the patient placed in the Rose position, and a mouth gag inserted (Kornblut, 1987; Paradise 1996).

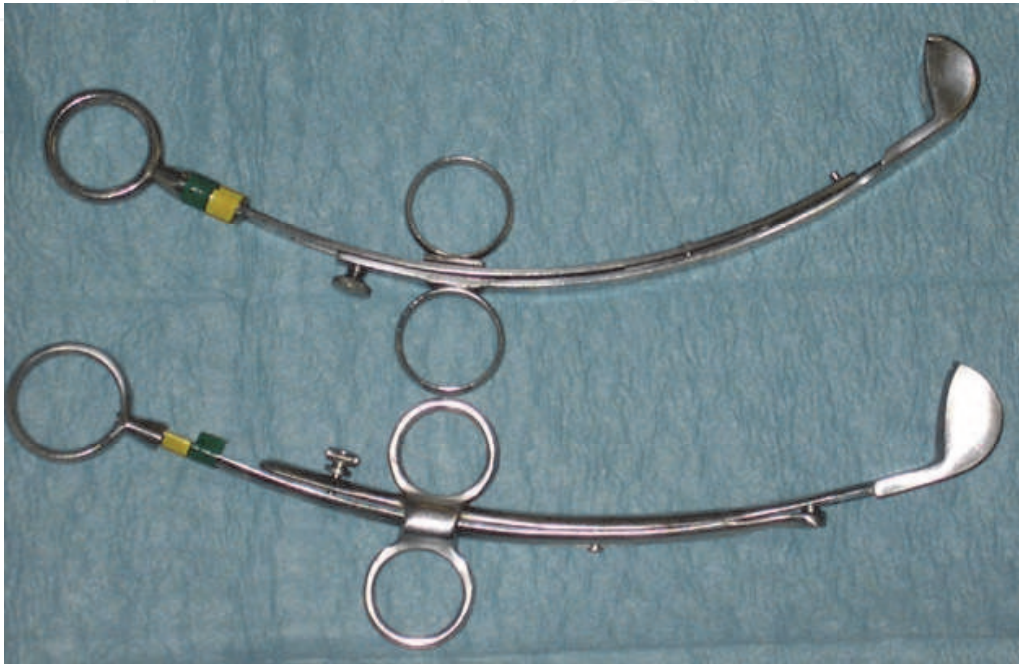

Fig. 1. Two, different sized, standard Shambaugh adenotomes.



Fig. 2. Distal end of the Shambaugh adenotome.



Fig. 3. Distal end of an adenoid curette.

The surgeon is placed at the head of the patient (Figure 4). The curette is transorally applied to the nasopharynx thus, by-passing the soft palate and the main bulk of the adenoids is removed, with a single or repeated passes. The majority of surgeons perform the procedure blindly, without a direct visualization of the nasopharynx (Figure 5). In some cases a partial visualization of the adenoid pad can be achieved by retracting the soft palate with rubber catheters or by using a laryngeal or a dental mirror. Bleeding is controlled by compression, through the placement of a gauze pack in the nasopharynx for several minutes.

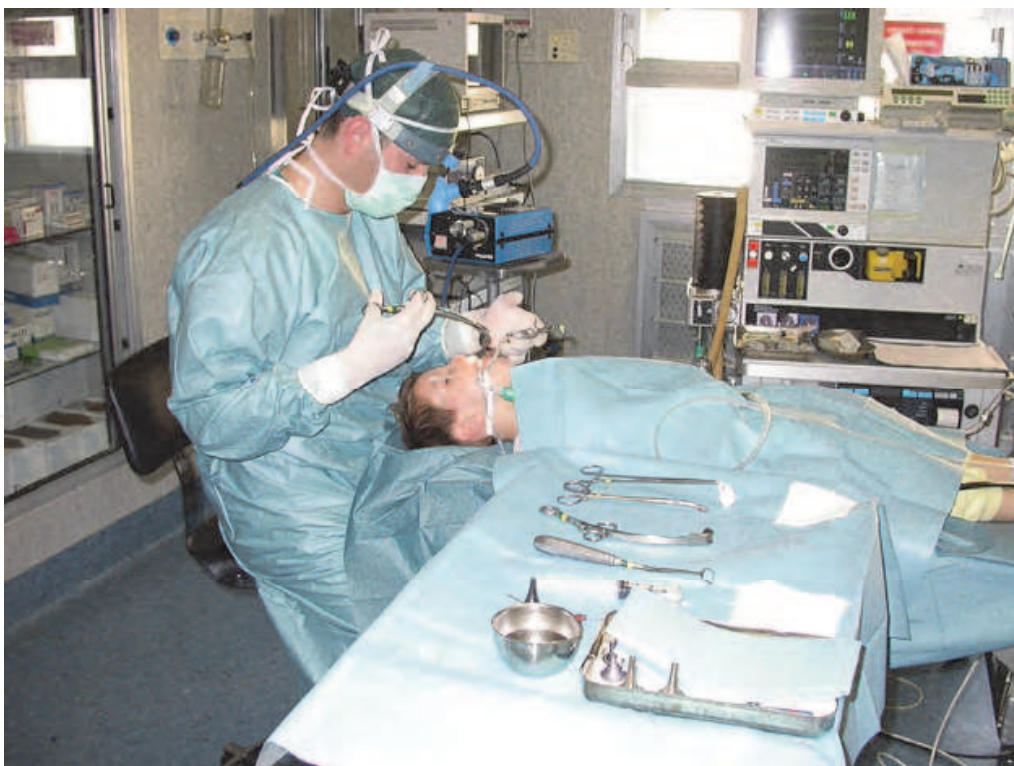

Fig. 4. Surgical position during a traditional adenoidectomy.

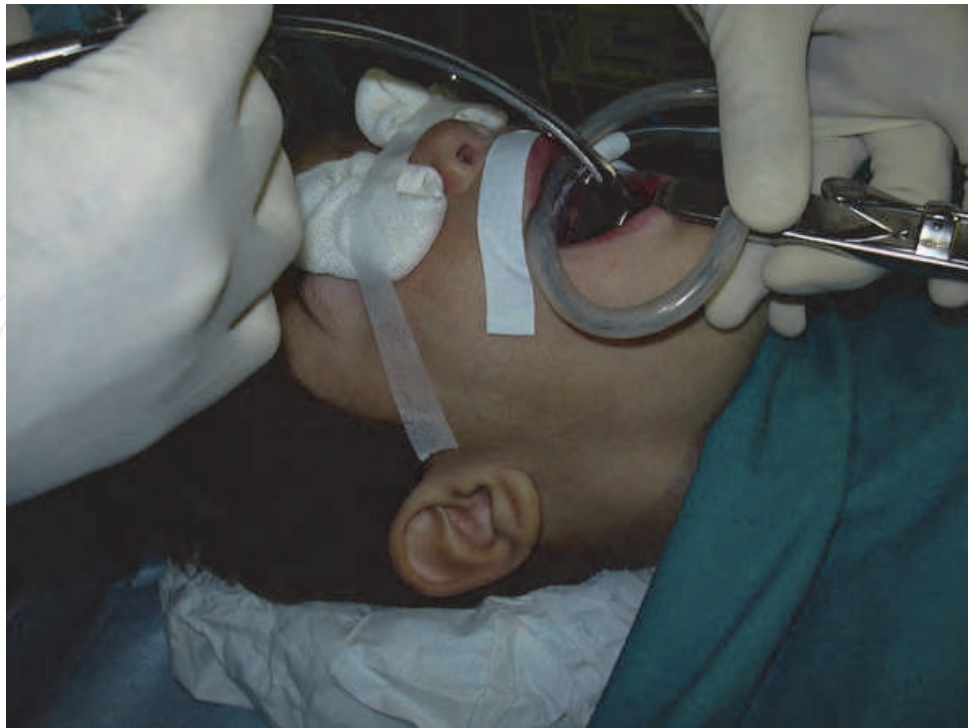

Fig. 5. External view of a traditional adenoidectomy performed with a Shambaugh adenotome; as underlined, the procedure is conducted without the visualization of the nasopharynx.

The visualization of the operative field is particularly useful in avoiding damages to important structures located nearby the adenoid tissue, such as the Eustachian tube and/or the pharyngeal muscles. Postoperative complications such as velopharyngeal insufficiency, tubaric stenosis and nasopharyngeal stenosis are rare but difficult to resolve when occurred. Several investigations prove that in up to one-third of children with clinically significant adenoid hypertrophy, conventional curettage adenoidectomy does not achieve an adequate removal of obstructive adenoid tissue, especially when there is an intranasal extension of the tissue, or a bulky mass of adenoids superiorly in the nasopharynx and in the peritubaric region (Buchinsky et al., 2000; Elluru et al, 2002; Havas & Lowinger, 2002; Stanislaw et al., 2000).

To possibly reduce the morbidity linked to the adenoid tissue persistence and to prevent recurrences, total excision of the adenoids is the most important goal of this operation. Initially, the surgical clearance was confirmed by a digital palpation of the rhinopharynx and this procedure is still performed by some Otolaryngologists (Buchinsky et al., 2000). Subsequently, the use of an angled mirror or an endoscope during the adenoidectomy provided adequate visualization of the field, and these techniques are currently preferred by most surgeons (Brodsky, 1996; Cannon et al., 1999; Discolo et al., 2001). A recent study published by Ark et al. showed that in order to achieve a complete adenoid tissue removal, a direct/indirect visual assistance is necessary. The authors considered a group of patients that underwent a conventional adenoidectomy (surgical efficacy confirmed by digital palpation at the end of the procedure); subsequently, the surgical field was inspected through an indirect laryngeal mirror visualization. Their finding was that only one-fifth of the patients had no residual adenoid tissue. Instead, in the 81% of the patients a residue of lymphatic tissue was still present on the pharyngeal roof nearby the choanal

opening; also, 11.4% of the patients had a residue along the torus tubarius on either side of the nasopharynx and in 6.3% the residual tissue was located at both cited sites (Ark et al., 2010).

The recurrence of adenoid hypertrophy after the surgical procedure is under debate in the literature, but several reports do not offer comparable results. According to Lundgren, the recurrence rate is 4 – 8%, in Hill's series instead it is 23.7 – 50% and Crowe states a recurrence rate of over 75% (Tolczynski, 1955). More recent studies cite a significantly lower recurrency rate till a 0.5% (Joshua et al., 2006; Monroy et al., 2008), and this success could be attributed to the evolution of the techniques. Historically, Tolczynski (Tolczynski, 1955) considered various situations to be responsible for the recurrence of adenoid hypertrophy, summarized in:

- Anatomical difficulties.
- Adenoidectomy is often performed in a hurry, and sometimes the inadequate anaesthesia could be responsible for an insufficient relaxation of the palato-pharyngeal muscles, whose contracture interferes with the manipulations of the adenoid pad.
- In many cases it is a "Surgical operation in the dark", without a visualization of the operatory field.

A recent paper in a cohort of over 300 patients reports that, when an endoscopic examination was performed at the end of the adenoidectomy, in the 14.5% of the cases some residual adenoid tissue that required additional removal was found; during the follow-up of these patients only 0.85% needed a revision adenoidectomy in the next 2 years. In contrast, when that endoscopic examination was not performed, there was a 6.7% persistence of the initial symptoms and a 5.6% of the patients required a revision adenoidectomy. By comparing such results, it becomes evident that the endoscopic examination at the end of the procedure, significantly reduces the incidence of recurrence and thus the need for a revision surgery (Ezzat, 2010).

In the last years, several surgical techniques have been proposed to ensure a finer removal of the adenoid mass, as well as to achieve a better control of intraoperative bleeding.

Suction diathermy was initially introduced for haemorrhage control following conventional curettage of the adenoid pad (Kwok & Hawke, 1987). Subsequently, the whole procedure was performed with this technique, always along a transoral approach and an indirect visualization by a laryngeal or dental mirror (Owens et al., 2005; Sherman, 1982; Skilbeck et al., 2007). As an evolution, in the following years suction diathermy was performed via a transnasal approach and under a transnasal endoscopic control, in the older paediatric population (Shin, 2003).

The introduction of powered instrumentation for sinus surgery prompted the use of a shaver system with an overbent cannula for a, power-assisted, total or partial adenoidectomy; however, the approach still was a transoral one, along with an indirect visualization through a laryngeal mirror (Heras et al., 1998; Koltai et al., 1997, 2002; Stanislaw et al. 2000).

In a recent article Walner et al presented a survey between 300 members of the American Society of Pediatric Otolaryngology, which examined the equipment used in adenotonsillectomy along the last 15 years in order to assess the surgical trends in instrument usage for paediatric adenotonsillectomy. About the adenoidectomy, there has been less consistency in the choice of an instrument over the years than for tonsillectomy.

The most promising instrument 15 years ago was a monopolar electrocautery curette, the use of which instead declined over the years against the simple curette adenoidectomy. One other instrument with a decreasing usage over the years is the adenotome. On the other hand, three adenoidectomy instruments faced an increasing success over the last 15 years. Firstly, a monopolar electrocautery's usage passed from a 7.1%, 15 years ago to a current 25.9%. This upgrade is, most likely, due to the increased speed of the procedure, the better control of the blood loss and the lower cost of the instrument. Secondly, although the use of a simple debriider showed a modest rise in popularity, instead its model enriched with a monopolar electrocautery went from a 0% to a current 19.8% in the surgeon's preferences during the last 15 years. According to the present study, when combining the data from debriider alone and debriider with monopolar electrocautery, the instrument is currently used more commonly than curette with monopolar electrocautery touch-up and is second only to monopolar electrocautery in total usage for adenoidectomy. A major advantage of the microdebriider is the possibility to use the angled blades to within the nasopharynx, the anatomy of which is problematic for some instruments, such as the curette or the adenotome. In addition, debriider's usage showed a low incidence of complications. One study evidenced no long-term complications, including significant blood loss, in over 1000 procedures carried out with the power-assisted instrument (Rodriguez et al., 2002). Finally, coblation adenoidectomy gained significant popularity over the years. When combining the current data from pure coblation adenoidectomy and adenoidectomy with monopolar electrocautery coblation procedures, the instrument is used by the 8.6% of the surgeons in over 50% of their cases (Walner et al, 2007). We must recognize that the cited survey was conducted in a restricted national cohort (U.S.A.), and this may not reflect the international trend on the surgical equipment for the adenoidectomy.

In the '90s, the advent of ESS popularized the use of intranasal scopes and the endoscopic adenoidectomy became the natural evolution of the conventional adenoidectomy, permitting a direct visualization throughout the procedure (Becker et al., 1992; Cannon et al., 1999). By using this technique the adenoid remnants along the superior portion of the nasopharynx, the choanae and the peritubal region, can be clearly visualized and, thus, removed; moreover, the likelihood of damage of the Eustachian tube and/or of the pharyngeal muscles is reduced, and the haemorrhage may be effectively controlled by a direct identification of the bleeding point. In addition to the endoscopic-assisted adenoid curettage, residual adenoid tissue can be removed piece by piece using, transnasally, either a straight or a 45° Blakesley forceps, always under an endoscopic view (Huang et al., 1998). In the following years, a power-assisted adenoidectomy conducted completely through a transnasal approach and under an endoscopic guidance was suggested by Parson in 1996 (Parson, 1996) and firstly reported by Yanagisawa in 1997 (Yanagisawa, 1997).

As reported in the literature, the usual approaches to the adenoid tissue with power-assisted instruments are: pure transnasal (Al-Mazrou et al., 2009; Havas & Lowinger, 2002; Pagella et al., 2009), transorally inserted curved debriider under a transoral control (with laryngeal mirrors or with 45° or 70° scopes) (Koltai et al., 2002; Rodriguez et al., 2002; Stanislaw et al., 2000) or transorally inserted curved microdebriider combined with a transnasal endoscopic control (Pagella et al., 2010).

In this chapter we expose the evolution of the adenoidectomy during the last decades, from the traditional procedures to the modern endoscopic-assisted methods, with a description of each surgical technique.

2. Preoperative evaluation

All children underwent a preoperative flexible fiberoptic nasal endoscopy; we used a paediatric flexible endoscope, diameter 3.6 mm. Before the exam, nasal secretions were removed either by nasal-blowing or by a gentle aspiration through a small flexible rubber tube. No topical intranasal decongestant was used to avoid a misdiagnosis of an inferior turbinate hypertrophy or generalized nasal mucosa congestion; moreover, the National guidelines proposed by the Italian Drugs Agency, permit the use of intranasal vasoconstrictor drugs in children over 12 years of age. No local or general anesthesia was used. We preferred the presence of the parents in the examination room, for a better compliance of the patient. Most children fully collaborated during the nasal endoscopy; if necessary, the head of the patient was gently immobilized by the assistant/nurse during the performance. The entire procedure could be followed on the video screen and taped, which facilitated review and discussion of the disease along with the parents.

The procedure enables the visualization of the entire nasal fossae and, in particular, key-areas as the inferior and middle turbinates, the septum, the Osteo-Meatal Complex (OMC), the fontanella area, the Spheno-Ethmoidal Recess (SER) and the nasopharynx. The child is laid supine on an examination bed with his head bent by about 30° - 45°. The endoscopic evaluation can be divided into three main phases. At first, the endoscope is introduced along the nasal floor (between the inferior turbinate and the septum) so as to evaluate the inferior turbinate volume, the inferior meatus and the septum's morphology; then, the scope proceeds towards the nasopharynx to evaluate the presence of lymphatic tissue (adenoids), oedema, pathologic drainages and the condition of the Eustachian orifices. As a second step, the scope is gently retracted thus, permitting the investigation of the SER and the lateral nasal wall along with the fontanella area and the OMC. In this area, evidence of pathological drainage is crucial. Purulent secretions at the level of the OMC and of the posterior fontanella zone are an endoscopic sign of an anterior compartment rhinosinusitis (maxillary, anterior ethmoid and frontal sinuses), whereas secretions within the SER mean rhinosinusitis of the posterior compartment (posterior ethmoid and sphenoid sinuses). As a final step, if requested, an endoscopic visualization of the oropharynx and of the hypopharynx/larynx can be obtained by passing through the nasopharynx. During this step particular importance should be given to the posterior extension of the palatine tonsils within the oropharynx, as long as both the laryngeal morphology and motility. The entire procedure lasts about 30 sec - 1 min.

The degree of obstruction by the adenoid tissue over the posterior choanae was estimated using the grading system proposed by Parikh et al. (Figure 6): grade 1 for adenoid tissue not in contact with adjacent structures; grade 2 for adenoid tissue in contact with torus tubarius, grade 3 for adenoid tissue in contact with vomer, and grade 4 for adenoid tissue in contact with soft palate (at rest) (Parikh et al., 2006). Other diseases usually noted during the examination, include inferior turbinate hypertrophy, septal deviation, choanal stenosis or atresia, mucosal infections and polypoid formations.

A clinical examination of the ear and the oropharynx is, usually, obtained in all children. Further exams as pure-tone audiometry (in children over 4 years-old) and tympanometry, are suggested in cases of referred hearing impairment or middle otitis.

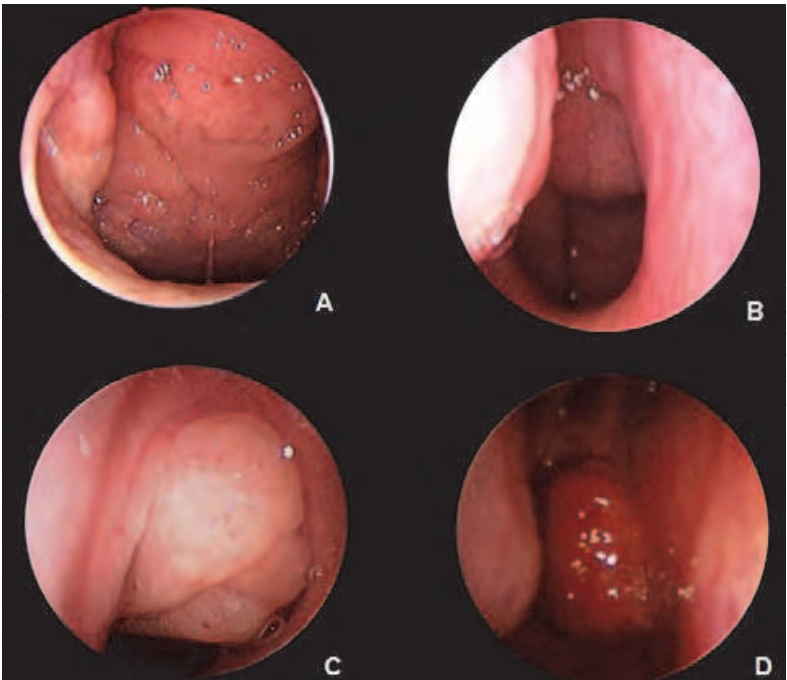


Fig. 6. Adenoid hypertrophy grading system proposed by Parikh et al. (Parikh et al., 2006): grade 1 (A), grade 2 (B), grade 3 (C) and grade 4 (D).

3. Evolution of surgical techniques

3.1 Adenoidectomy in the pre – endoscopic era

3.1.1 Traditional adenoidectomy

This is the “standard” surgical procedure of an adenoidectomy. As an initial step, the hard palate is inspected and palpated for the detection of an eventual submucous cleft (bifid uvula, zona pellucida, notching of the posterior hard palate). The palate’s length should also be inspected. In the present procedure, the whole procedure is conducted without visualization of the nasopharynx. A complete set of three adenotomes (Shambaugh or LaForce) – small, medium and large size – is prepared, and an adenoid curette is chosen based on the dimension of the child’s oropharynx and should fit between the tori (Figure 7).



Fig. 7. An Adenoid curette (left) and a Shambaugh adenotome (right).

The large-sized adenotome is inserted in the oral cavity by-passing the oropharynx in order to reach the nasopharynx and the adenoid pad; when the target is reached the adenotome is applied in order to remove the lymphatic nasopharyngeal tissue (Figure 8). The procedure is, then, repeated with both the medium and small sized adenotomes. After this passage, the curette is transorally inserted in the superior nasopharynx and in contact with the vomer; then is swept inferiorly with a side-to-side rocking motion to completely remove all the remaining adenoids. Care is taken to avoid injury to the deep muscular and vertebral plane, to the torus region or to the choanal area. A smaller curette can consequently be used to remove any retained tissue. After several saline solution irrigations, hemostasis is obtained by placing a tonsillar pack in the nasopharynx for some minutes. Complete removal of the adenoid tissue is confirmed by digital palpation.

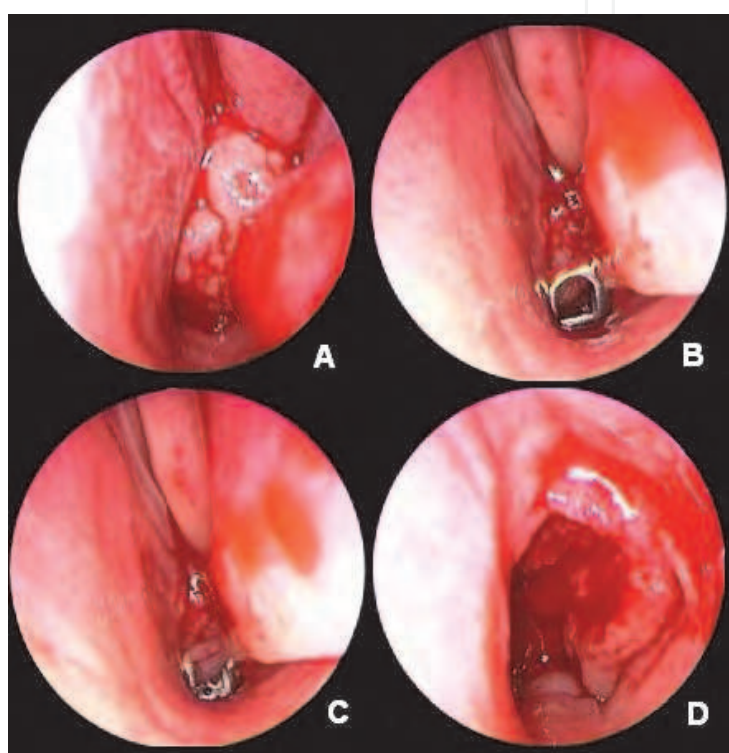


Fig. 8. Intraoperative steps of a traditional adenoidectomy with an adenotome. The procedure is showed under endoscopic view (transnasal 0° endoscope) only for didactic purposes because, as mentioned, the procedure is usually performed blindly. In A the adenoid pad is visualized from the left nasal fossa in the nasopharynx. In B and C the adenotome is transorally inserted to reach the adenoid tissue, opened (B), and then closed (C) in order to remove the lymphatic tissue. In D the surgical field at the end of the adenoidectomy.

The main limitations of the traditional technique include: less precise removal and potentially less effective treatment, possible increased bleeding, risk of neck pain and velopharyngeal insufficiency, and lack of surgical visualization. As known, this procedure does not always remove completely the adenoid tissue (Cannon et al., 1999).

This method showed an efficacy of tissue removal only in 30% of cases (Bross-Soriano et al., 2004). The superior and the peritubaric portions of the adenoid that obstruct the nasopharynx and the orifice of the Eustachian tube should be considered as zones of potential adenoid remnants. Moreover, excessive removal of adenoid tissue by curettage

may provoke damage to the pharyngeal muscles, to the posterior choana, to the Eustachian tubes, or to other structures. As a result, several complications might result from an excessive traditional adenoidectomy, including velopharyngeal insufficiency and persistence of obstructive symptoms (Gelder, 1974).

3.1.2 Laryngeal-mirror assisted adenoidectomy

In all these surgical techniques the surgical field is controlled through a transorally placed laryngeal (or dental) mirror, in order to achieve an adequate view of the nasopharynx.

3.1.2.1 Traditional adenoidectomy with transoral laryngeal-mirror control

The already described traditional adenoidectomy may also be conducted under a transoral laryngeal mirror control; in this case the curette, under indirect visualization, is passed through the oral cavity in order to reach the adenoid tissue, and adenoidectomy is performed. Hemostasis can also be obtained with an electrocautery under the mirror control.

3.1.2.2 Power assisted adenoidectomy with transoral laryngeal-mirror control (Koltai et al., 2002; Rodriguez et al., 2002; Stanislaw et al., 2000)

This technique consists in performing the adenoidectomy with a debriider under an indirect visualization, through a laryngeal mirror. The shaver cannula is usually curved (mainly 45° or 60°). The cannula is, transorally, introduced into the nasopharynx under indirect transoral mirror visualization, and the oscillating blade is then switched on. The adenoidectomy starts high in the nasopharynx, near the choanal sill. The resection is performed in a side-to-side manner, progressing on an even level until the inferior edge of the adenoid pad is reached. The depth of adenoid resection, as well as the resection around the choana and torus, is precisely controlled. The tip of the oscillating cannula is always under visual control via the laryngeal mirror. Electrocautery can be used in order to obtain an adequate hemostasis.

A complete adenoidectomy with a microdebrider was shown to be faster than, and as safe as, a traditional curettage adenoidectomy. A recent review evidenced that operative time was significantly less when applying the debriider and that blood loss, recovery time, and complications were comparable between those two techniques. Moreover, the main advantage of debriider adenoidectomy resides in its precision.

3.1.2.3 Suction diathermy (Elluru et al., 2002; Walker, 2001)

This technique is usually performed with an indirect visualization of the nasopharynx through a laryngeal mirror (but it can also be conducted under endoscopic control), as already seen. Diathermy ablation of the adenoid pad is accomplished by using an insulated, curved Frazier-type suction system or, more commonly, a disposable, malleable 10 French size, hand-switching suction coagulator (E2610-6, ValleyLab, Boulder, CO). When the Frazier-type system is used, a monopolar diathermy is applied. Typically, a setting of 30 to 45 W (depending on the patient's weight) is used to ablate the adenoid tissue.

The suction electrocautery device is applied to the adenoid pad, beginning at the most superior part of it (within the central bulk of the adenoid tissue, and not superficially). As the pad is cauterized, it shrinks and the suction device helps in evacuating the smoke. Thus, the obstructive adenoid tissue is ablated with care taken not to traumatize the soft palate, the opening of the Eustachian tube, or other adjacent pharyngeal structures. Surgery is completed when the choanae are clearly visible and the nasopharynx presents a smooth

level contour. There should be no heat damages on the vomer, nasal turbinates, soft palate, or lateral nasopharyngeal walls. In the literature, this method is defined as precise, easy to perform, fast, bloodless and relatively inexpensive.

In a recent prospective study published by Jonas et al., a comparison between suction-diathermy ablation and curettage adenoidectomy was performed. The majority of patients experienced symptom improvement after 6 months, regardless of the method used. Both techniques were very effective in controlling the symptoms of the adenoidal hypertrophy. As referred, suction diathermy technique was superior in reducing adenoidal regrowth at 6 months. Although this result was statistically significant, it is uncertain whether it is of a true clinical significance, as the symptom improvement for both groups were in excess of 95% (Jonas et al., 2007).

3.2 Adenoidectomy in the endoscopic era

3.2.1 The pure endoscopic approaches

3.2.1.1 Nasal endoscopic-guided curettage transoral adenoidectomy (EGA) (Wan et al., 2005)

The nasal cavities and nasopharynx are examined through a 0° nasal scope. A throat pack is then inserted to prevent blood from entering the trachea. A Boyle- Davis mouth gag is used to open the mouth widely as during the classic adenoidectomy. A suitably sized Beckmann adenoid curette is transorally placed into the nasopharynx. Under nasal endoscopic guidance, the blade of the adenoid curette is placed just above the superior border of the adenoid. The lateral ends of the blade should just be away from the Eustachian tube area on both sides. The nasal endoscope is then taken out from the nose and the curette is used as in conventional curettage.

Transoral packing gauze is used for some minutes to control bleeding, which usually stops spontaneously without need for cauterization. Nasal endoscopy, simply, allows an assessment of the adenoid size and extension and improves the accuracy of the adenoidectomy with the curette. This method is particularly useful in younger patients with a small oral cavity; in fact, adenoid palpation, mirror examination and consequent laryngeal mirror-adenoidectomy is challenging in patients with narrow passages. These problems can be addressed by the rigid nasal endoscope, which allows accurate and safe placement of the curette at the superior border of the tissue. Thus, we obtain a complete removal of the main bulk of the adenoid without the need for nasal grasping forceps or a debrider. Moreover, teaching is much easier when combined with the real-time video presentation. Last but not least, as sophisticated instruments are not required, the cost-effectiveness of such method remains highly acceptable.

In all cases, the EGA curettage method is sufficient to remove the main bulk of the adenoids in one attempt. In contrast, the adenoid tissue is removed piece by piece during the classic curette adenoidectomy. In conclusion, the EGA allows a more complete and precise removal of the adenoid compared with the conventional method.

3.2.1.2 Transoral endoscopic adenoidectomy with adenoid curette and St. Claire Thomson forceps (El-Badrawy & Abdel-Aziz, 2009)

Under general oro-tracheal anesthesia, a Boyle-Davis mouth gag is used. The soft palate is retracted with rubber catheters passed from the nose to the mouth. The 4 mm-70° rigid

nasal scope is introduced through the mouth, and the nasopharyngeal adenoid mass is identified. Curettage of the main adenoid mass is carried out using an adequate size adenoid curette; removal of any residual tissue is performed by a St. Claire Thomson forceps while suction is used to clear the field. At the end, a pack of gauze is inserted into the nasopharynx for some minutes.

According to the authors, the advantage of this method is the direct visualization of the operative field that would decrease the incidence of post-op adenoidal remnants, the reduced possibility of injury to the Eustachian tube with a consequent long-term fibrosis and the finer control of possible haemorrhage sites. Moreover, the procedure does not need any expensive equipment and it needs just a few minutes more than the conventional mirror-adenoidectomy method. However, the transoral endoscopic approach demands some experience in endoscopic surgery through curved scopes.

3.2.1.3 Transoral adenoid ablation by suction diathermy under a 45° scope vision (Lo & Rowe- Jones, 2006)

The procedure is undertaken under general anaesthesia. The patient is positioned and prepared as described in the latter technique. The surgeon stands on the right side of the patient's head. A 45° rigid scope is introduced through the oral cavity to the oropharynx with the lens pointing towards the nasopharynx. The suction coagulator device is introduced alongside the endoscope. Using a setting of 30 W of monopolar coagulation combined with suction, the adenoidectomy is performed under direct endoscopic vision.

The known limitations of the traditional indirect mirror adenoidectomy are mainly associated to the poor visualization and manoeuvrability. Thus, the endoscopic transoral approach overwhelms those limitations. More specifically, by the 30° endoscope and in particular in patients with small mouth opening, visualization of the nasopharynx, although better, could be limited. With a 90° endoscope, although the whole nasopharynx could be effectively visualised, however a closer look into the nasopharynx would be very difficult, and the endoscope and suction coagulator would be oriented at different axis, thus limiting manoeuvrability.

By using a 45° endoscope the entire nasopharynx can be easily visualised. In addition, the axis of introduction in both, scope and suction-coagulator, is the same so, bimanual co-ordination is easily achieved. As referred, with this technique and in patients with submucous cleft palate, adenoid tissue may be excised under direct vision preserving, however, a small pad inferiorly to avoid velopharyngeal insufficiency. In conclusion, this technique is both effective and presents a short learning curve.

3.2.1.4 Transnasal power assisted adenoidectomy with transnasal endoscopic control (Al-Mazrou et al., 2009; Havas & Lowinger, 2002)

The shaver blade used is the XPS Xomed Power System with the lightweight magnum-scaled handpiece and a 2.9-mm Tricut blade with straight-through suction irrigation (Medtronic Xomed Surgical Products, Jacksonville, FL). The theater setup and positioning is as for a standard functional endoscopic sinus surgery. Using the 0°, 2.7-mm rigid telescope (4 mm scope is used in older children with larger nasal cavities), the posterior choanae and nasopharynx are assessed. Under endoscopic vision the shaver cannula is passed into the nose with the suction switched off to allow passage to the adenoids without traumatizing the turbinates or the septum. The suction is then turned on and the obstructive tissue is removed under constant endoscopic vision with care not to lacerate the torus tubarius. The

cutting and aspirating action of the shaver removes both adenoid tissue and blood, providing a clear view. Tissue is removed at the site of the oscillating blade only, and the blade is kept under vision all the time using the telescope. Working from proximal to distal, intranasal adenoid and hypertrophic nasopharyngeal adenoid are removed until the surgeon is satisfied with the clearance. A small inferior rim of adenoid tissue can be left intact intentionally to preserve the velopharyngeal sphincter. With this technique a finer peritubal and perichoanal tissue clearance is possible, and a better control on the depth of the tissue resection is achieved. Careful tissue removal is carried out with the concomitant visual-protection of important nearby structures like Eustachian tubes, torus tubarius and the posterior pharyngeal wall. Moreover, this technique is reported to be faster and bloodless than the traditional curette adenoidectomy. A possible disadvantage, is the cost of the disposable blade of the shaver.

3.2.1.5 Transoral power assisted adenoidectomy with transoral 70° endoscopic control (Costantini et al., 2008)

A general orotracheal anaesthesia is performed for the surgery. The patient is placed in a supine position with the neck slightly extended and the surgeon placed to the right of the patient. A mouth gag, the same as for tonsillectomy, is positioned; two rubber catheters are introduced through the nasal fossae to apply light upward traction to the soft palate, thereby increasing the forward-back diameter of the passage. The slight stretching of the palate achieved with this manoeuvre can also help to detect a possible soft palate cleft.

A 70° endoscope with a video attachment is introduced through the mouth to visualize the nasopharynx, and consequently a 40° curved blade microdebrider is introduced through the mouth (Figure 9).

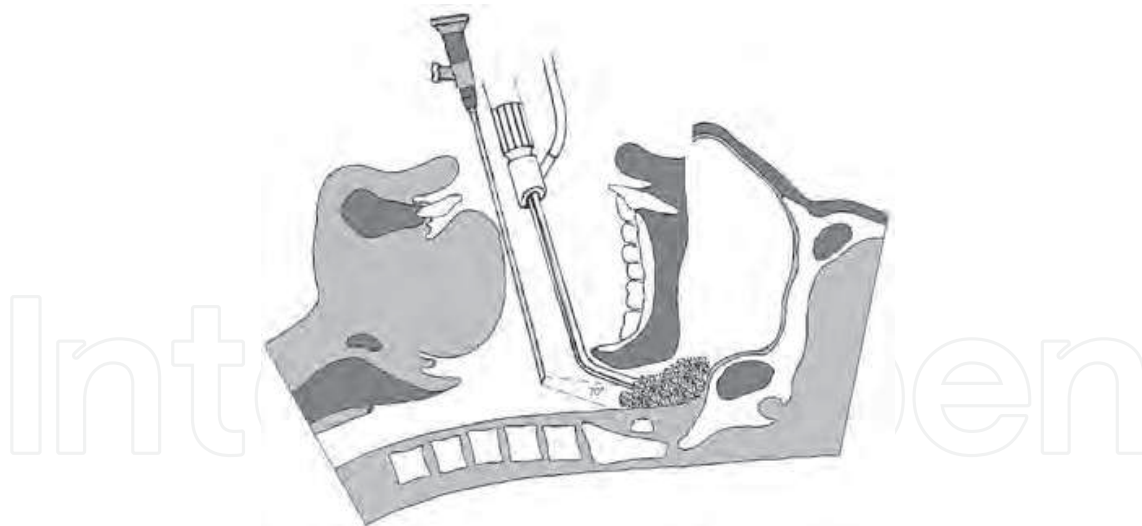


Fig. 9. Schematic representation of the transoral power assisted adenoidectomy with transoral 70° endoscopic control

The instrument is connected to an aspirator, and set a rotational speed of 1200 rpm. Removal of the adenoid tissue starts from the choanal extension, and proceeds backwards along the vault towards the posterior wall of the nasopharynx. The smooth tip of the microdebrider can be introduced into the recess between the side vegetations and the tubaric ostium so that the tissue can be completely removed without damaging the mucosa covering the torus tubarius.

The resection is interrupted at the passage from the regular adenoid vegetations to the chaotic aspect of the lymphatic tissue in this zone (Passavant ridge). From a functional point of view, the removal can be considered complete at this point. In doing so, such procedure prevents transitory velo-pharyngeal insufficiency and avoids excessive intraoperative bleeding.

At the end of the resection, a gauze packing could be placed and is maintained for some minutes. The packing is then removed and the cavity is checked for possible remnants and for the absence of bleeding. In the uneventful case of persistent bleeding, hemostasis can be established using a curved suction-coagulator, always under an endoscopic transoral control.

Several authors have described the high percentage of residual tissue remnant after traditional (adenotome or curette) adenoidectomy, especially in the choanal and the peritubaric region. A blindly performed surgical procedure is no longer satisfactory. A clear vision of the operating field is essential and this can be obtained, with excellent illumination and focus, with a transorally inserted 70° endoscope. Compared to the image obtained by a laryngeal or dental mirror, the quality of the image is unquestionably better.

In some cases, introduction of the catheters for suspending the soft palate can be rather difficult (especially in the presence of an important choanal obstruction), but, according to these authors, they do offer considerable advantages. The safety and precision of the transoral curved microdebrider for adenoidectomy is well documented by the Rodriguez et al. (Rodriguez et al., 2002), Koltai et al. (Koltai et al., 2002), and Murray et al. (Murray et al., 2002). This method can be effective to remove the lateral (peritubaric) adenoidal tissue with a precision that is difficult to achieve with any other instrument, thereby minimizing the risk of damaging the surrounding structures. If a partial adenoidectomy is appropriate, it is also possible to perform very selective removal of the adenoid tissue. Moreover, the continuous suction generated by the microdebrider maintains a bloodless field.

Although the technique described may appear, at a first view, more difficult than those traditionally used, it is easier to learn, particularly for the surgeon who is, somewhat, familiar with the endoscopic nasal surgery. Moreover, it is easy to teach using the video images. The duration of the procedure is slightly longer than a standard adenoidectomy. The organization and preparation times are also longer, while ablation and haemostasis times are substantially the same. However, the slightly longer duration is more than compensated by the greater precision and confidence gained by the surgeon.

3.2.2 The combined methods

A recent report (Saxby et al., 2009) comments on the incidence of residual adenoid tissue after 425 consecutive traditional curette adenoidectomies. This residual tissue can lead to a combination of potential problems, including peritubaric obstruction, bacterial reservoirs and hyperplasia of the remnants with the persistence of obstructive symptoms; all these aspects highlight the importance of addressing a complete removal of the adenoid tissue. In this report, the majority (73%) of patients who underwent to a traditional curettage adenoidectomy had some endoscopic evidence of residual adenoids, 26% of which presented also symptoms of nasal obstruction (grade 2 or 3 adenoid hypertrophy).

The incidence of residual adenoid tissue found in this study agrees with previously published results. (Havas & Lowinger, 2002; Cannon et al., 1999). Residual tissue revealed by the endoscopic control of the nasopharynx, occurred in a significant proportion of cases and would have been missed by palpation alone; this fact highlights the advantage of

endoscopically inspecting the nasopharynx after the curettage. However, it is still not clear whether lesser grades of residual tissue warrant further resection. In this study, and also according to our experience, all the residual lymphatic tissue should be removed. Some authors argue that grade 1 (up to one-third of choanal occlusion) is not clinically significant, but it appears interesting that this occurs in most cases. Herein, we report some of the different combined methods described in the literature.

3.2.2.1 Conventional curettage adenoidectomy with transnasal endoscopic forceps' residual asportation (Huang et al., 1998)

In this procedure, the patient is placed supine in Rose position with the head extended. The mouth is opened with a Dingmann mouth gag. Disinfection of the face and oral cavity is performed to avoid contamination. The soft palate is retracted with a Hurd tonsil retractor. After this passage, an adenoid curette is transorally applied to the nasopharynx and the main bulk of adenoid is removed. Care is required during this process in order to avoid injury to the choana and to the pharyngeal muscles, which could result in a massive bleeding.

Subsequently, a 4-mm or 2.7-mm, 0° or 30° endoscope is inserted transnasally till the nasopharynx. Residual adenoid tissue at the superior portion of the rhinopharynx and at the orifice of the Eustachian tube, is usually detected at this time. Under endoscopic guidance, the adenoidectomy is completed by removing the residual tissue piece by piece using either a straight or a 45° Blakesley forceps. The nasopharynx and the orifice of the Eustachian tube can be inspected by a direct endoscopic visualization without damage to other structures. Adjunctively, control of the hemostasis can be performed through a direct endoscopic view. The use of endoscopic equipment allows a piece by piece adenoid removal. However, in patients with important tissue volume, such approach requires more time than conventional surgery, which prolongs the anesthesia times and increase the peri-operative risks. In such cases, conventional surgical methods (curette and adenotome) may remove the main bulk of the adenoid mass. On the other hand, direct endoscopic visualization reduces the likelihood of damage to other structures by excessive excision and hemorrhage due to residual adenoid tissue. Direct visualization allows direct identification and treatment of the source of bleeding, thus sparing unaffected structures and is therefore highly suitable for children. If necessary, suction cautery or other hemostatic methods can be locally used under endoscopic control.

A similar method was proposed also by Cannon et al. in 1999 (Cannon et al., 1999) and called "Endoscopic-assisted adenoidectomy (EAA)"; according to this technique, at the end of a conventional adenoidectomy, both the nasal cavities and the rhinopharynx were inspected with a 4-mm 0° rigid telescope. Adenoid remnants in the rhinopharynx were removed under direct visualization by paediatric straight forceps or pituitary forceps.

3.2.2.2 Endoscopic-assisted combined curettage adenoidectomy (Regmi et al., 2011)

This is a simple but effective technique, as confirmed in our personal experience too. Surgery is conducted under general oro-tracheal anaesthesia, with the child placed in the Rose's position, and a mouth gag inserted to expose the oropharynx. A rubber catheter may be inserted through the mouth to obtain an adequate palatal retraction. As a first step a traditional curettage and / or adenotome adenoidectomy without a direct visualization of the nasopharynx is performed. Subsequently, the nasal cavities and nasopharynx are endoscopically examined with a rigid endoscope. If adenoid remnants are observed, those are removed under transnasal endoscopic control through the transoral adenoid curette.

By this method, the main disadvantages of the traditional technique such as the damage to the torus tubarius or the pharyngeal muscles and the persistence of adenoid remnants could be avoided.

3.2.2.3 Endoscopic suction diathermy following traditional curettage adenoidectomy (Saxby et al., 2009)

All the adenoidectomies are performed under general anaesthesia with the patient appropriately positioned and draped. A Boyle–Davis mouth gag is used in order to hold the mouth open. Digital palpation of the palate is performed to assess adenoidal size, and to identify any eventual submucosal cleft. The first part of the surgical procedure consists in the removal of the adenoid tissue with sweeping movements of an appropriately sized adenoid curette. Haemostasis is achieved with a moist gauze swab left in place for several minutes. After removal, any eventual residual adenoid tissue is transnasally assessed using a 0° scope. A Y-suction catheter is used to clear the field and allow assessment of the epipharynx. Ablation of residual tissue by electrocautery is achieved using a suction diathermy coagulator (Valleylab, Tyco Healthcare Group, Boulder, Colorado, USA) placed transorally under a transnasal endoscopic visualization. The suction diathermy is bent 90°, 2.5 cm from the distal end to get to the epipharynx through the mouth. Care should be taken to avoid a Eustachian injury by the diathermy tip. Thus, the removal of the residual adenoid tissue should proceed medially from anterior to posterior.

3.2.2.4 Traditional curette and transnasal endoscopic adenoidectomy (transnasal straight microdebridors and transnasal endoscopic view) (Pagella et al., 2009)

With the child under general anaesthesia via an orotracheal tube, a Crowe-Davis mouth gag is inserted; the patient is placed supine in the Rose position, then a conventional adenoidectomy with a Shambaugh adenotome and Shambaugh curette is performed. A catheter is passed through the nose to assure cessation of bleeding and removal of any clot, and the nasopharynx is inspected using a 0°, 2.7 mm rigid fibre-optic endoscope with a video attachment.

In the presence of residual adenoid tissue still causing a significant obstruction of the nasopharynx, the patients undergo completion of adenoidectomy using a powered shaver. The shaver used is the XPS (Xomed Powered System by Medtronic, Jacksonville, FL) with a 2.9 mm Tricut straight blade and straight-through suction irrigation (Figure 10).

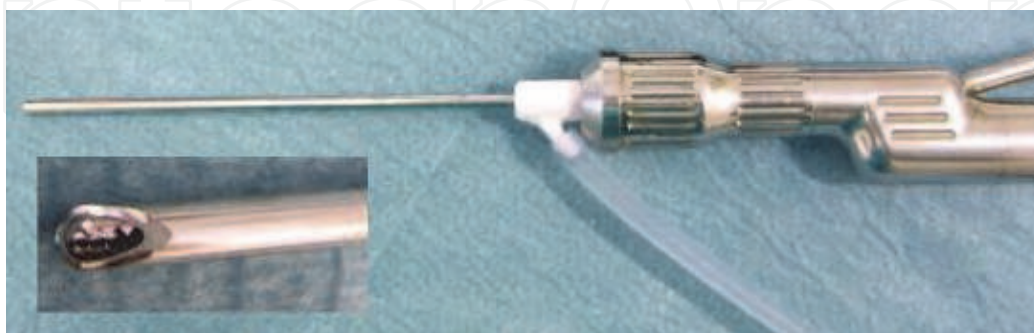


Fig. 10. The straight XPS shaver, as described above in the text.

The device should be set at 500 rpm in the oscillating mode, with concomitant irrigation. Under constant endoscopic view the shaver cannula is passed through the nose with the suction switched off, so as to allow passage to the nasopharynx without traumatizing the

nasal mucosa. The suction is then switched on and residual adenoid tissue is removed under endoscopic vision with care not to damage the torus tubarius (Figure 11 – 14). The cutting and aspirating action of the shaver removes both adenoid tissue and blood, providing a clear surgical field and keeping the oscillating cannula always under visual control. Once haemostasis is achieved by several saline solution irrigations, the equipment is removed and the child is then handed back to the anaesthetists for awakening and extubation.

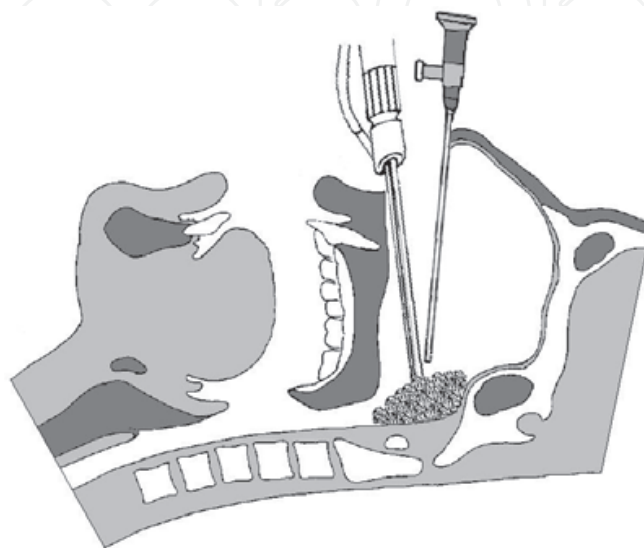


Fig. 11. Schematic representation of the traditional curette and transnasal endoscopic adenoidectomy.

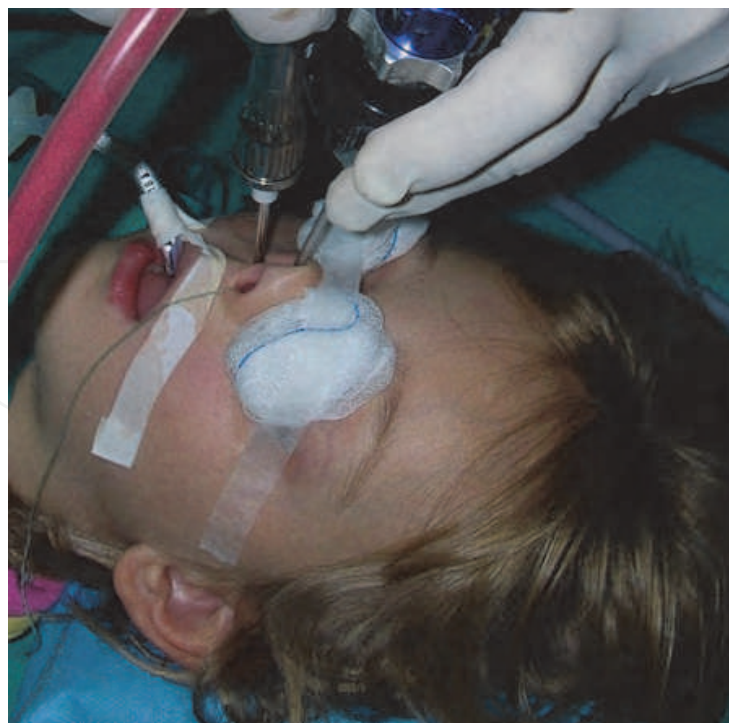

Fig. 12. External view of the microdebrider and the endoscope, both placed in the nasal cavity.

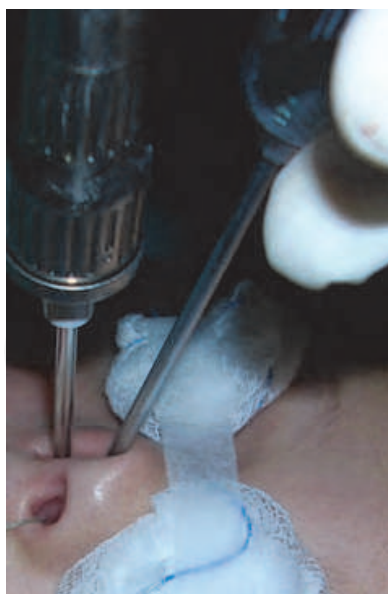

Fig. 13. Closed-detail of the relative placement of the two instruments into the right nostril.

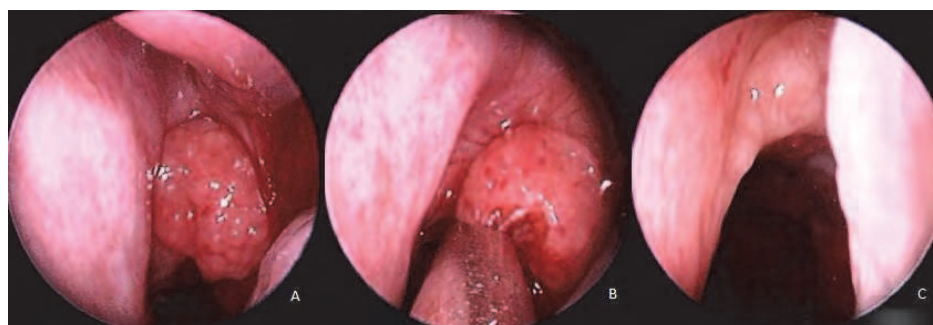


Fig. 14. Intraoperative sequential steps of the removal of adenoid remnants after a traditional adenoidectomy. The scope is introduced in the left nasal fossa to permit a safe control of the entire surgical act. Lymphatic tissue still obstructing the nasopharynx (A); removal of the latter tissue with the straight shaver (B); the surgical field at the end of the procedure (C).

The value of a transnasal endoscopic view for assessing the complete adenoid removal at the end of a traditional adenoidectomy has been repeatedly underlined; this counts especially for the tissue placed superiorly in the nasopharynx and around the choanal sill but is effective as well for the control of active bleeding areas. (Buchinsky et al., 2000; Elluru et al., 2002; Havas & Lowinger, 2002; Shin & Hartnick, 2003; Stanislaw et al., 2000)

The use of the transnasal microdebrider assures a complete adenoidectomy and, in particular, a better control over the extent of the resection, especially around the choanal sill, the posterior nose and the torus tubarius. On the other hand, and in the presence of bulky/obstructing adenoids, a pure microdebrider adenoidectomy is time-consuming procedure; moreover, sometimes results as a difficult act because of the limited manoeuvrability of the instruments in the inferior nasopharynx. In our experience, in case of children with large adenoids, a conventional curettage and/or the usage of the adenotome removes rapidly the main tissue bulk. Then, the transnasally controlled power-assisted endonasal approach, permits an accurate residual tissue exeresis, a correct evaluation and

effective treatment of active bleeding points, and a decreased traumatism of the region. By performing the combined adenoidectomy approach, there is an obvious increase in operative time when both curette and power-assisted techniques are used. However, in experienced hands, this increase is limited to some minutes. According to Koltai et al. (Koltai et al., 2002), initially it may appear that the power-assisted adenoidectomy is a more hemorrhagic operation than the traditional operation; this happens because the microdebrider removes small pieces of tissue with each oscillation, leaving a raw surface that bleeds during the rest of the procedure. However, when continuous suction is used, the blood is evacuated along with the excised tissue, leaving a clear and unobstructed view of the operating field. In our experience, there was no increased primary or secondary bleeding related to the use of the microdebrider. By contrast, we were certain that we had achieved a complete clearance of the rhinopharynx in every single patient.

3.2.2.5 Transoral Endonasal-Controlled Combined Adenoidectomy (TECCA) (Pagella et al., 2010)

As a first step a traditional transoral adenoidectomy is performed with a Shambaugh adenotome and Shambaugh curette. Secondly, a 0°, 2.7-mm, rigid fiber optic endoscope with a video attachment is introduced through the nostrils to inspect the nasopharynx and ensure a complete removal of the adenoid tissue. In the presence of residual adenoid tissue still obstructing the nasopharynx, the patient undergoes a completion of the adenoidectomy with the curved microdebrider. We use the 60° curved, 4-mm Tricut blade and straight-through suction irrigation microdebrider by XPS (Xomed Powered System by Medtronic, Jacksonville, FL). The device is set at 500 rpm in the oscillating mode. Under endoscopic transnasal view the curved microdebrider, with the suction switched off to avoid oropharyngeal damages during the introduction, is advanced through the oral cavity and reaches the nasopharynx. The suction is then switched on and the residual adenoid tissue is removed under transnasal endoscopic vision, with care not to damage the torus tubarius or the pharyngeal muscles (Figure 15 – 17). The constant aspiration of the power-assisted instrument permits a complete removal of the adenoid tissue and a bloodless surgical area. Once haemostasis is achieved, and abundant irrigation of the field with saline solution is performed, the equipment is removed.

This new technique seems to be as safe and effective as the previous described one (transnasal microdebrider and transnasal endoscopic control). Moreover by performing the TECCA technique, some problems encountered during the latter procedure (Traditional curette and transnasal endoscopic adenoidectomy), as the contact between the scope and the debrider if both are passed transnasally, seem to be addressed; to us, the efficacy and safety of both procedures are similar. As stated before, we underline that we would rather not perform the entire procedure with the debrider so as not to significantly extend the total operative time; this is why we propose to perform the first step with standard adenoidectomy instruments. One possible limitation of this technique might be the higher price of the curved blades, as usually happens with the new equipment.

In conclusion, TECCA appears to be efficient in removing adenoid tissue that still obstructs the nasopharynx, in particular, when such remnants are situated in the superior part of the nasopharynx and/or the peritubaric region. Apparently, such procedure carries no additional risk compared to other techniques. Indeed, it permits a better maneuverability of the instruments in cases of narrow nasal spaces for a complete clearance of the nasopharyngeal area.

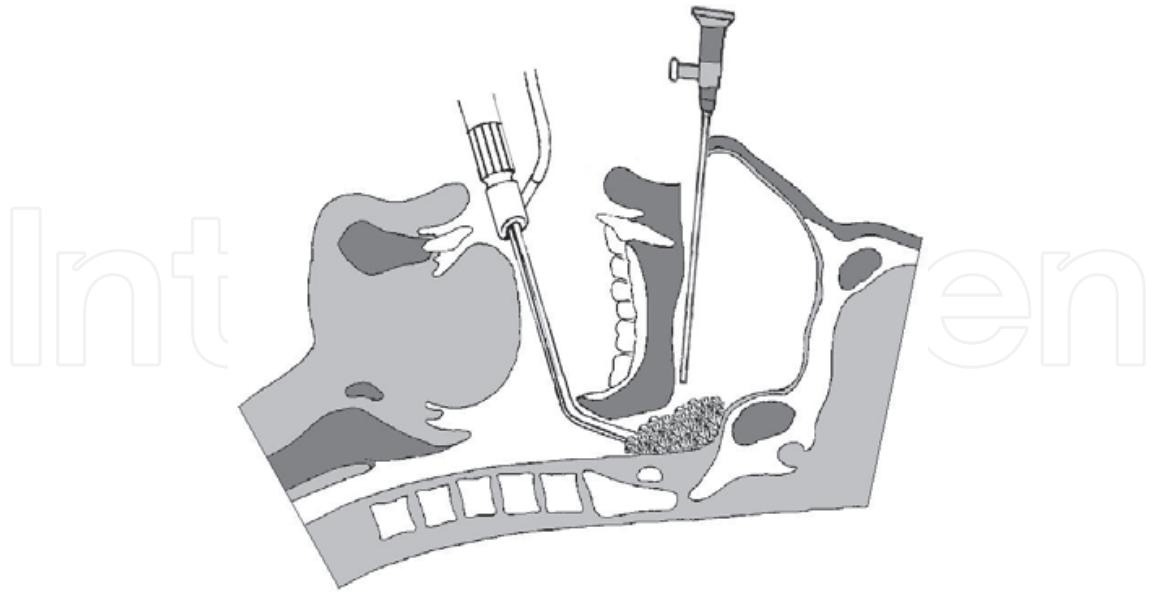


Fig. 15. Schematic representation of the second surgical step of the TECCA, as described in the text.

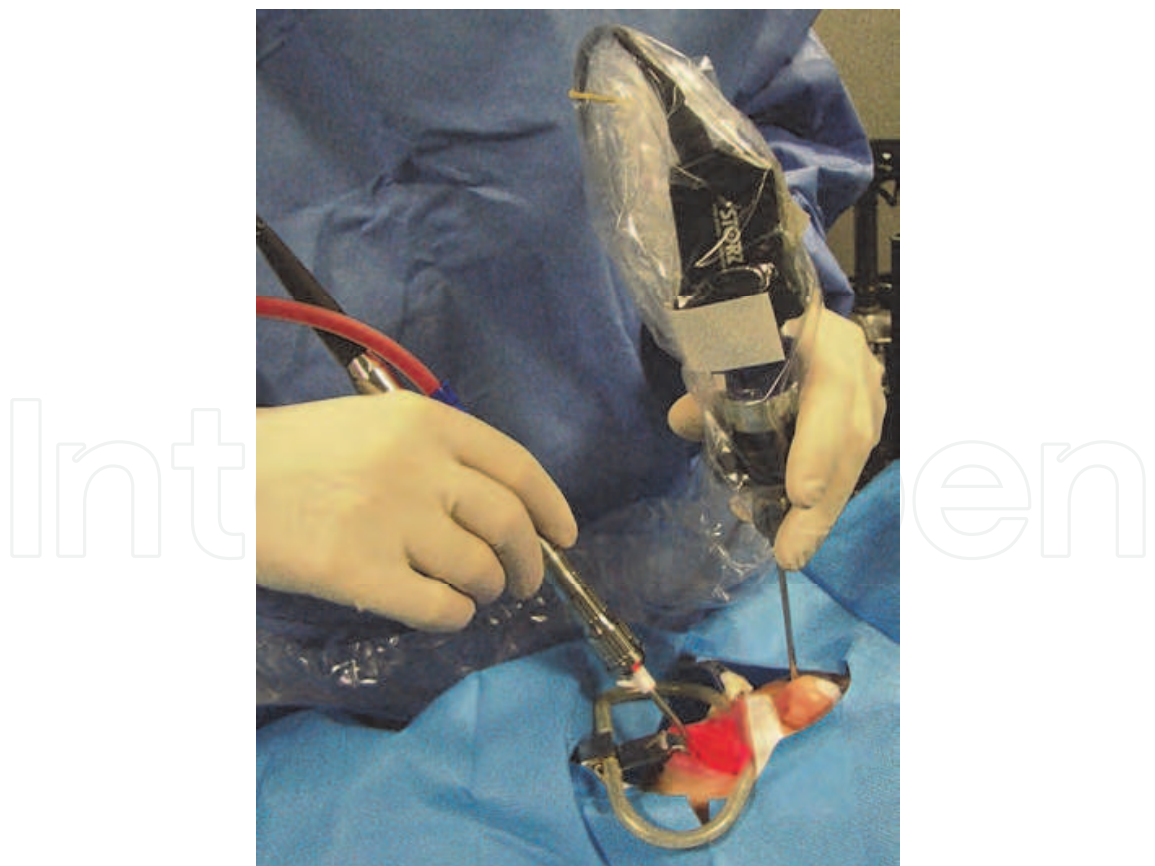


Fig. 16. External view of the second surgical step of a TECCA procedure.

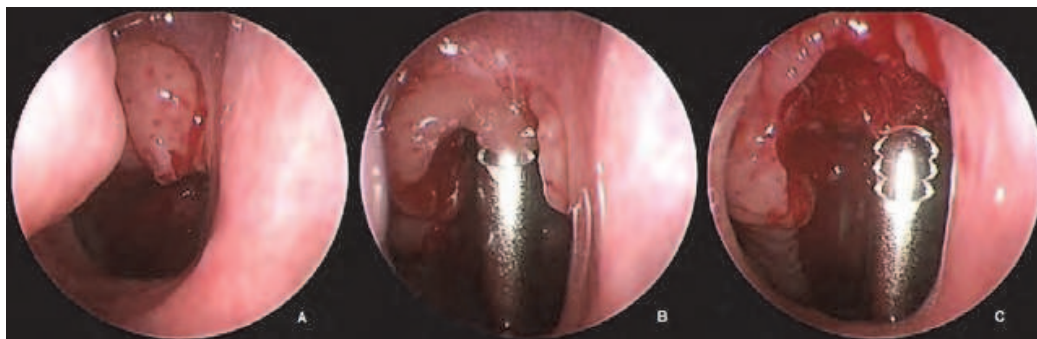

Fig. 17. Intraoperative sequential steps of residual adenoid removal by the TECCA technique. The scope is placed transnasally between the septum and the right inferior turbinate in order to control the transoral adenoidal clearance by the curved microdebrider. In A adenoid remnants at the end of a traditional adenoidectomy. In B and C remnant's exeresis through the transorally placed power-assisted instrument.

4. Conclusion

Since many years, adenoidectomy is one of the most common surgical procedures performed by Otolaryngologists in children. Historically, in the pre-endoscopic era, this procedure was performed blindly, without a direct visualization of the surgical field. Conventional "blind" adenoidectomy (adenotome or curette) may achieve the desired results in many patients; however, as many authors state, it frequently fails to obtain a complete tissue removal and, thus is less effective than direct/indirect visualization techniques. The indirect, mirror-controlled adenoidectomy was the first attempt to obtain a view of the nasopharynx during the operation. More recently, in the endoscopic era, the use of the endoscopes and other modern surgical equipment (p.e. microdebriders, suction-diathermy) permitted the development of several endoscopic-assisted approaches; these innovative techniques offered the surgeon a clear, direct view of the rhinopharynx, enabling a complete and fine removal of the adenoid tissue, thus, avoiding an excessive and unnecessary trauma to the surrounding structures.

5. References


- Al-Mazrou, KA; Al-Qahtani, A & Al-Fayez AI. (2009). Effectiveness of transnasal endoscopic powered adenoidectomy in patients with choanal adenoids. *International Journal of Pediatric Otorhinolaryngology*, Vol.73, No.12, pp. 1650-1652.
- Ark, N; Kurtaran, H; Ugur, KS; Yilmaz, T; Ozboduroglu, AA & Mutlu, C. (2010). Comparison of adenoidectomy methods: examining with digital palpation vs. visualizing the placement of the curette. *International Journal of Pediatric Otorhinolaryngology*, Vol.74, No.6, pp. 649-651.
- Baker, S. (1939). *Fighting for life*, pp. 140-141. The Macmillan Company. New York, NY.
- Becker, SP; Roberts, N & Coglianese, D. (1992). Endoscopic adenoidectomy or relief of serous otitis media. *Laryngoscope*, Vol.102, No.12 Pt 1, pp./1379-1384.
- Brodsky, L. (1996). Adenoidectomy, In: *Atlas of Head & Neck Surgery-Otolaryngology*, Bailey, BJ; Calhoun, KH; Coffey, AR & Neely, JG, pp. 816-817, Lippincott-Raven, Philadelphia, PA.

- Bross-Soriano, D; Schimelmitz-Idl, J & Arrieta-Gomez, JR. (2004), Endoscopic adenoidectomy: use or abuse of technology? *Cirugia y Cirujianos*, Vol.72, No.1, pp. 15-19, 21-22.
- Buchinsky, FJ; Lowry, MA & Isaacson, G. (2000). Do adenoids regrow after excision? *Otolaryngology-Head and Neck Surgery*, Vol.123, No.5, pp. 576-581.
- Cannon, CR; Repogle, WH & Schenk, MP. (1999). Endoscopic-assisted adenoidectomy. *Otolaryngology-Head and Neck Surgery*, Vol.121, No.6, pp.740-744.
- Costantini, F; Salamanca, F; Amaina, T & Zibordi, F. (2008). Videoendoscopic adenoidectomy with microdebrider. *ACTA Otorhinolaryngologica Italica*, Vol.28, No.1, pp.26-29.
- Curtin, JM. (1987). The history of tonsil and adenoid surgery. *Otolaryngologic Clinics of North America*, Vol.20, No.2, pp. 415-419.
- Discolo, CM; Younes, AA; Koltai, PJ. (2001). Current techniques of adenoidectomy. *Operative Techniques in Otolaryngology-Head and Neck Surgery*, Vol.12, No.4, pp. 199-203.
- El-Badrawy, A & Abdel-Aziz, M. (2009). Transoral Endoscopic Adenoidectomy. *International Journal of Otolaryngology*, 949315. Epub 2009 Jul 28.
- Elluru, RG; Johnson, L; Myer, CM. (2002). Electrocautery adenoidectomy compared with curettage and power-assisted methods. *Laryngoscope*, Vol.112, No.8 Pt. 2 Suppl.100, pp. 23-25.
- Ezzat, WF. (2010). Role of endoscopic nasal examination in reduction of nasopharyngeal adenoid recurrence rates. *International Journal of Pediatric Otorhinolaryngology*, Vol.74, No.4, pp. 404-406.
- Havas, T & Lowinger, D. (2002). Obstructive adenoid tissue: an indication for powered-shaver adenoidectomy. *Archives of Otolaryngology-Head and Neck Surgery*, Vol.128, No.7, pp. 789-791.
- Hays, HM. (1924). Diseases of pharynx, nasopharynx and hypopharynx, In: *Pediatrics*, Abt IA, (3rd Ed.), pp. 217-218, Saunders WB, Philadelphia, PA.
- Heras, HA & Koltai, PJ. (1998). Safety of powered instrumentation for adenoidectomy. *International Journal of Pediatric Otorhinolaryngology*, Vol.44, No.2, pp. 149-153.
- Huang, HM; Chao, MC; Chen, YL & Hsiao, HR. (1998). A combined method of conventional and endoscopic adenoidectomy. *Laryngoscope*, Vol.108, No.7, pp. 1104-1106.
- Jonas, NE; Sayed, R & Prescott, CA. (2007). Prospective, randomized, single-blind, controlled study to compare two methods of performing adenoidectomy. *International Journal of Pediatric Otorhinolaryngology*, Vol.71, No.10, pp. 1555-1562.
- Joshua, B; Bahar, G; Sulkes, J; Shpitzer, T & Raveh, E. (2006). Adenoidectomy: long-term follow-up. *Otolaryngology-Head and Neck Surgery*, Vol.135, No.4, pp. 576-580.
- Kaiser, AD. (1932). *Children's tonsils in or out?* pp. 2, 3, 8-10. JB Lippincott. Philadelphia, PA.
- Koltai, PJ; Kalathia, AS; Stanislaw, P & Heras, HA. (1997). Power-assisted adenoidectomy. *Archives of Otolaryngology-Head and Neck Surgery*, Vol.123, No.7, pp. 685-688.
- Koltai, PJ; Chan, J & Younes, A. (2002). Power-assisted adenoidectomy: total and partial resection. *Laryngoscope*, Vol.112, No.8 Pt.2 Suppl.100, pp. 29-31.
- Kornblut, AD. (1987). A traditional approach to surgery of the tonsil and adenoids. *Otolaryngologic Clinics of North America*, Vol.20, No.2, pp. 349-363.
- Kwok, P & Hawke, M. (1987). The use of suction cautery in adenoidectomy. *The Journal of Otolaryngology*, Vol.16, No.1, pp. 49-50.

- Lo, S & Rowe-Jones, J. (2006). How we do it: Transoral suction diathermy adenoid ablation under direct vision using a 45 degree endoscope. *Clinical Otolaryngology*, Vol.31, No.5, pp. 436-455.
- Meyer, W. (1870). On adenoid vegetations in the nasopharyngeal cavity: their pathology, diagnosis and treatment. *Medico-chirurgical Trans (London)*, Vol.53, pp. 191-216.
- Monroy, A; Behar, P & Brodsky, L. (2008). Revision adenoidectomy –a retrospective study, *International Journal of Pediatric Otorhinolaryngology*, Vol.72, No.5, pp. 565-570.
- Owens, D; Jaramillo, M & Saunders, M. (2005). Suction diathermy adenoid ablation. *The Journal of Laryngology and Otology*, Vol.119, No.1, pp. 34-35.
- Pagella, F; Matti, E; Colombo, A; Giourgos, G & Mira, E. (2009). How we do it: a combined method of traditional curette and power-assisted endoscopic adenoidectomy. *Acta Otolaryngologica*. Vol.129, No.5, pp. 556-559.
- Pagella, F; Pusateri, A; Matti, E & Giourgos, G. (2010). Transoral Endonasal-Controlled Combined Adenoidectomy (TECCA). *Laryngoscope*, Vol.120, No.10, pp. 2008-2010.
- Paradise, JL. (1996). Tonsillectomy and adenoidectomy, In: *Pediatric Otolaryngology*, Blueston, CD; Stool SE; Kenna MA, (3rd Ed.), pp. 1054-1065, WB Saunders, Philadelphia, PA.
- Parikh, SR; Coronel, M; Lee, JJ & Brown, SM. (2006). Validation of a new grading system for endoscopic examination of adenoid hypertrophy. *Otolaryngology-Head and Neck Surgery*, Vol.135, No.5, pp. 684-687.
- Parson, SP. (1996). Rhinologic uses of powered instrumentation in children beyond sinus surgery. *Otolaryngologic Clinics of North America*, Vol.29, No.1, pp. 105-114.
- Paul of Aegina (A.D. 625-690). *The seven books of Paulus Aegineta*. (1847). Translated from the Greek by Francis Adams, Sydenham Society Instituted, London.
- Regmi, D; Mathur, NN & Bhattarai, M. (2011). Rigid endoscopic evaluation of conventional curettage adenoidectomy. *The Journal of Laryngology and Otology*, Vol.125, No.1, pp. 53-58.
- Rodriguez, K; Murray, N & Guarisco, JL. (2002). Power-assisted partial adenoidectomy. *Laryngoscope*, Vol.112, No.8 Pt.2 Suppl.100, pp. 26-28.
- Saxby, AJ & Chappel, CA. (2009). Residual adenoid tissue post-curettage: role of nasopharyngoscopy in adenoidectomy. *ANZ Journal of Surgery*, Vol.79, No.11, pp. 809-811.
- Sherman, G. (1982). "How I do it"-head and neck and plastic surgery. A targeted problem and its solution. Innovative surgical procedure for adenoidectomy. *Laryngoscope*, Vol.92, No. 6 Pt. 1, pp. 700-701.
- Shin, JJ & Hartnick, CJ. (2003). Pediatric endoscopic transnasal adenoid ablation. *The Annals of Otology, Rhinology, and Laryngology*. Vol.112, No.6, pp. 511-514.
- Skilbeck, CJ; Tweedie, DJ; Lloyd-Thomas, AR & Albert, DM. (2007). Suction diathermy for adenoidectomy: complications and risk of recurrence. *International Journal of Pediatric Otorhinolaryngology*. Vol.71, No.6, pp. 917-920.
- Stanislaw, P; Koltai, PJ & Feustel, PJ. (2000). Comparison of power-assisted adenoidectomy vs adenoid curette adenoidectomy. *Archives of Otolaryngology-Head and Neck Surgery*. Vol.126, No.7, pp. 845-849.
- Thornval, A. (1969). Wilhelm Meyer and the adenoids. *Archives of Otolaryngology*, Vol.90, No.3, pp. 383-386.

- Tolczynski, B. (1955). The recurrence of adenoids. *Canadian Medical Association Journal*, Vol.72, No.9, pp. 672-673.
- Van Gelder, L. (1974). Open nasal speech following adenoidectomy and tonsillectomy. *Journal of Communication Disorders*, Vol.7, No.3, pp. 263-267.
- Walker, P. (2001). Pediatric Adenoidectomy Under Vision Using Suction-Diathermy Ablation. *Laryngoscope*, Vol.111, No.12, pp. 2173-2177.
- Walner, DL; Parker, NP & Miller, RP. (2007). Past and present instrument use in pediatric adenotonsillectomy. *Otolaryngology-Head and Neck Surgery*, Vol.137, No.1, pp. 49-53.
- Wan, YM; Wong, KC & Ma, KH. (2005). Endoscopic-guided adenoidectomy using a classic adenoid curette: a simple way to improve adenoidectomy. *Hong Kong Medical Journal*, Vol.11, No.1, pp. 42-44.
- Wiatrak, BJ & Wooley, AL. (2005). Pharyngitis and adeno tonsillar disease, In: *Otolaryngology-head and neck surgery*, Cummings, CW; Flint, PW; Harker, LA, et al., pp. 4150-4165, Mosby Inc., Philadelphia, PA.
- Yanagisawa, E & Weaver, E. (1997). Endoscopic adenoidectomy with the microdebrider. *Ear Nose and Throat Journal*, Vol.76, No.2, pp. 72-74.
- Younis, RT & Lazar, RH. (2002). History and current practice of tonsillectomy. *Laryngoscope*, Vol.112, No.8 Pt.2 Suppl.100, pp. 3-5.

IntechOpen



Advances in Endoscopic Surgery

Edited by Prof. Cornel Iancu

ISBN 978-953-307-717-8

Hard cover, 444 pages

Publisher InTech

Published online 25, November, 2011

Published in print edition November, 2011

Surgeons from various domains have become fascinated by endoscopy with its very low complications rates, high diagnostic yields and the possibility to perform a large variety of therapeutic procedures. Therefore during the last 30 years, the number and diversity of surgical endoscopic procedures has advanced with many new methods for both diagnoses and treatment, and these achievements are presented in this book. Contributing to the development of endoscopic surgery from all over the world, this is a modern, educational, and engrossing publication precisely presenting the most recent development in the field. New technologies are described in detail and all aspects of both standard and advanced endoscopic maneuvers applied in gastroenterology, urogynecology, otorhinolaryngology, pediatrics and neurology are presented. The intended audience for this book includes surgeons from various specialities, radiologists, internists, and subspecialists.

How to reference

In order to correctly reference this scholarly work, feel free to copy and paste the following:

Fabio Pagella, Alessandro Pusateri, Georgios Giourgos and Elina Matti (2011). Evolution of the Adenoidectomy in the Endoscopic Era, *Advances in Endoscopic Surgery*, Prof. Cornel Iancu (Ed.), ISBN: 978-953-307-717-8, InTech, Available from: <http://www.intechopen.com/books/advances-in-endoscopic-surgery/evolution-of-the-adenoidectomy-in-the-endoscopic-era>

INTech
open science | open minds

InTech Europe

University Campus STeP Ri
Slavka Krautzeka 83/A
51000 Rijeka, Croatia
Phone: +385 (51) 770 447
Fax: +385 (51) 686 166
www.intechopen.com

InTech China

Unit 405, Office Block, Hotel Equatorial Shanghai
No.65, Yan An Road (West), Shanghai, 200040, China
中国上海市延安西路65号上海国际贵都大饭店办公楼405单元
Phone: +86-21-62489820
Fax: +86-21-62489821

© 2011 The Author(s). Licensee IntechOpen. This is an open access article distributed under the terms of the [Creative Commons Attribution 3.0 License](https://creativecommons.org/licenses/by/3.0/), which permits unrestricted use, distribution, and reproduction in any medium, provided the original work is properly cited.

IntechOpen

IntechOpen