

We are IntechOpen, the world's leading publisher of Open Access books Built by scientists, for scientists

6,900

Open access books available

186,000

International authors and editors

200M

Downloads

Our authors are among the

154

Countries delivered to

TOP 1%

most cited scientists

12.2%

Contributors from top 500 universities



WEB OF SCIENCE™

Selection of our books indexed in the Book Citation Index
in Web of Science™ Core Collection (BKCI)

Interested in publishing with us?
Contact book.department@intechopen.com

Numbers displayed above are based on latest data collected.
For more information visit www.intechopen.com



Endoscopically Guided Balloon Dilatation of Recurrent Choanal Stenosis

B.J. Folz and C.-G. Konnerth

*Department of Otorhinolaryngology,
Karl Hansen Medical Center, Bad Lippspringe
Germany*

1. Introduction

Balloon Sinuplasty is a treatment modality, which has gained much attention since its introduction in 2005. Nasal and paranasal sinus disease can be treated with this new method in a less traumatic way than by Functional Endoscopic Sinus Surgery (FESS) or conventional sinus surgery. One of the advantages of Balloon Sinuplasty is the preservation of anatomical structures within the nose. Also there is no loss of mucosal lining, i.e. ciliated nasal epithelium normally remains intact. The basic principle is to place a balloon catheter (Fig. 1) via a guidewire into a sinus ostium, to inflate the balloon and thus to dilate the sinus ostium. Improved ventilation and drainage of the sinus via the dilated ostium ensures healing of the diseased cavity. Dilatation catheters, which are now being used in Rhinology derive from vascular medicine, where these devices are used to open occluded or partially occluded arteries. In this field dilatation catheters have led to significant reduction of operative trauma compared to conventional vascular surgery.

FESS currently is the gold standard in the treatment of recurrent sinusitis, if conservative therapy fails to achieve a permanent relief. It provides good results with acceptable discomfort for the patient. In most cases postoperative packing is necessary after FESS to stop nasal bleeding. Packing is uncomfortable for the patient and thus there are ongoing endeavours to develop even less traumatic methods to treat nasal diseases than FESS. Balloon dilatation is supposed to have the following benefits compared to FESS: less bleeding, more tissue preservation, less trauma to surrounding tissue, less complications, faster patient recovery and less postoperative care.

Initially all Balloon Sinuplasty procedures were performed under fluoroscopy. This fact was bound to technical prerequisites, which not every ENT-Department was able to provide. In addition exposure of patients and surgeons to X-rays during the procedure was a matter of continuous debate, especially in paediatric patients. This problem was overcome, when the LUMA™ technology was developed and catheters could be placed into the respective sinuses under endoscopic and diaphanoscopy control. We decided to use this technique for the restoration of the nasal airway passage in a child with recurrent choanal atresia. At the explicit wish of the parents no conventional surgery or FESS procedure was carried out. The parents reported, that the first operation had severely traumatized the child, therefore the parents asked for the least traumatic method, which was likely to give the child relief of his complaints.



Fig. 1. Inflated Sinus Balloon. The size of the respective Balloon catheter was 7 mm x 16 mm in diameter.

2. Case report

A 4 year-old boy had been operated on a right-sided choanal atresia via a transnasal approach at the age of two years. A silicone stent had been inserted for a period of three months postoperatively. Initially nasal breathing had been restored successfully, however within two years symptoms recurred. The child again suffered from persistent anterior rhinorrhoea, recurrent airway infections and snoring. Examination by flexible endoscopy and CT scanning revealed recurrent stenosis, which was partially bony and partially membranous (Fig.2). Repeated surgery was recommended, but the parents specifically asked for a less invasive treatment. The parents reported, that the child had suffered a lot after the initial operation and during the postoperative period, when the stent had to be kept in place for many months. The balloon method was explained to the parents and the interventional procedure was offered. Simultaneously it was pointed out that the balloon method was a treatment attempt and no standard therapy, as there were only few accounts in literature reporting that this method had already been used to open a choanal atresia. After weighing the potential advantages of the balloon dilatation method against their past experiences with endoscopic sinus surgery the parents explicitly asked for the balloon method.

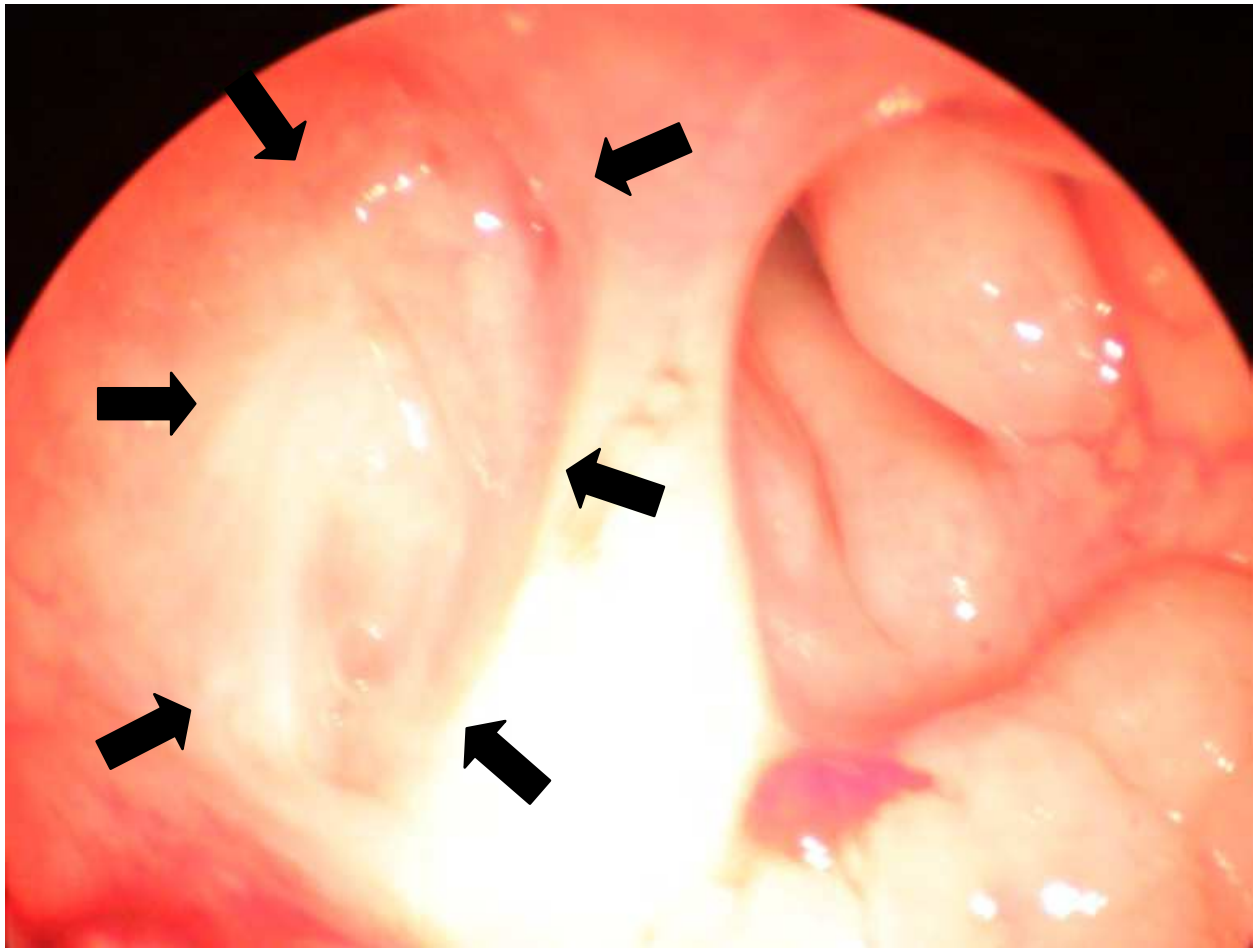


Fig. 2. Intraoperative view into the nasopharynx with a rigid 90° angled endoscope (transoral view). The left-sided choana shows a normal appearance. The posterior ends of the inferior and middle turbinate can be identified. The right-sided choana is occluded by a membranous plate (→) and a bony stenosis .

3. Method

A balloon catheter was placed in the nasal cavity under control with a 0°-degree rigid endoscope (Karl Storz Company, Tuttlingen) while the child was under general anaesthesia (Fig. 3). After decongestion of the nasal mucosa with cottonoids soaked in decongestant nose drops, a pinpoint-sized lumen within the atretic plate could be identified. Under simultaneous transoral endoscopy of the nasopharynx with a rigid 90°-angled endoscope (Karl Storz Company, Tuttlingen) (Fig 4.) a light source catheter was placed in the small choanal opening (Acclarent Company, Relieva Luma™ Sinus Illumination System, 7 mm diameter) (Fig. 5). The light source catheter was subsequently advanced into the nasopharynx. The sinuplasty balloon catheter was then gently rotated into the residual lumen, with the light source catheter as guide wire. The balloon was inflated with normal saline solution until a pressure of 8 atm. was reached (Fig. 6). The balloon remained inflated for 5 minutes and was then deflated. The residual lumen was thus enlarged to a diameter of 7 mm without any signs of hemorrhage or swelling (Fig.7). No packing was necessary and no postoperative bleeding occurred. After some

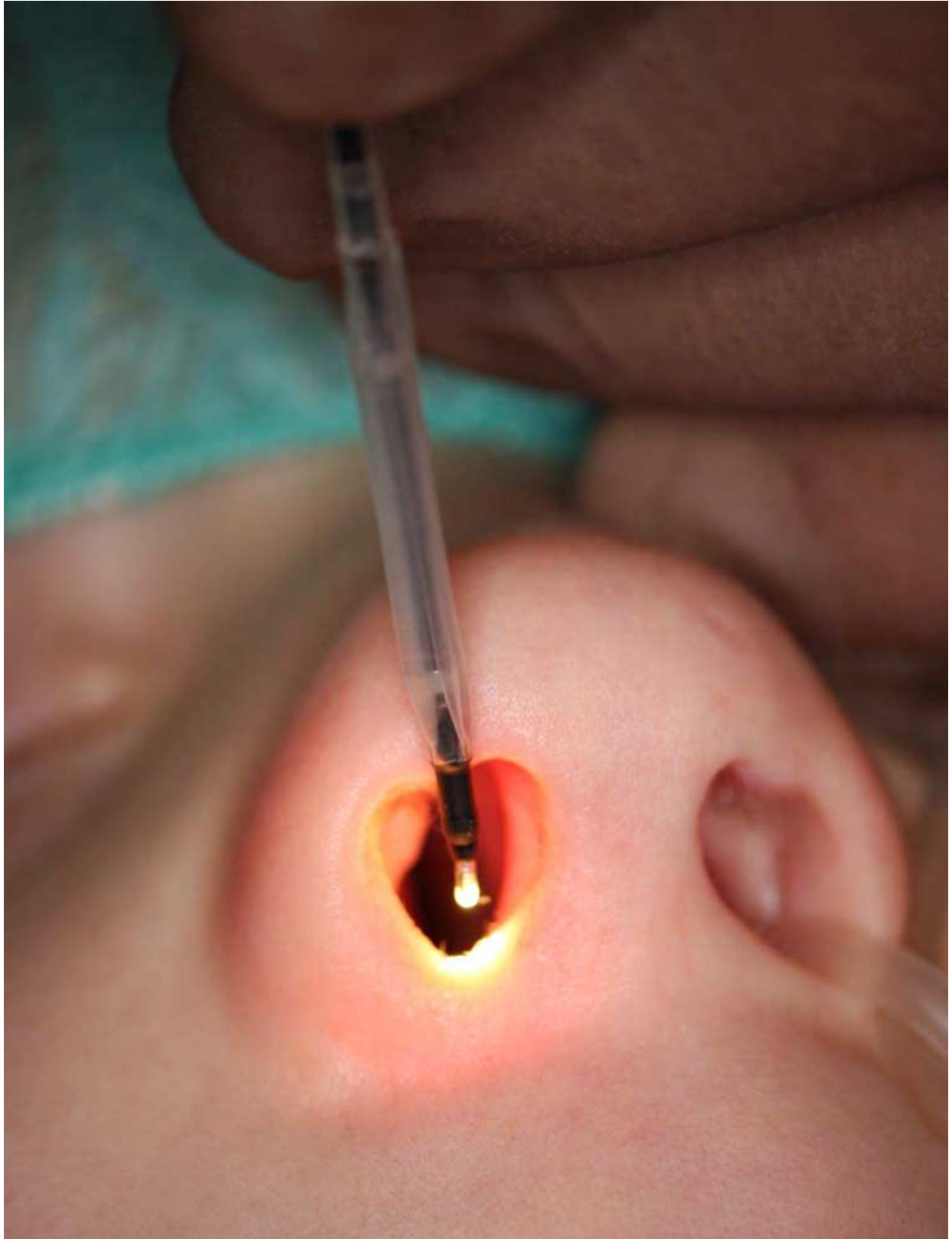


Fig. 3. The flexible light-fibre of the Relieva LUMA™ illumination system (straight tip) is the guide wire for the balloon catheter. The guide wire and the balloon catheter are inserted into the right nose and advanced to the stenosis.

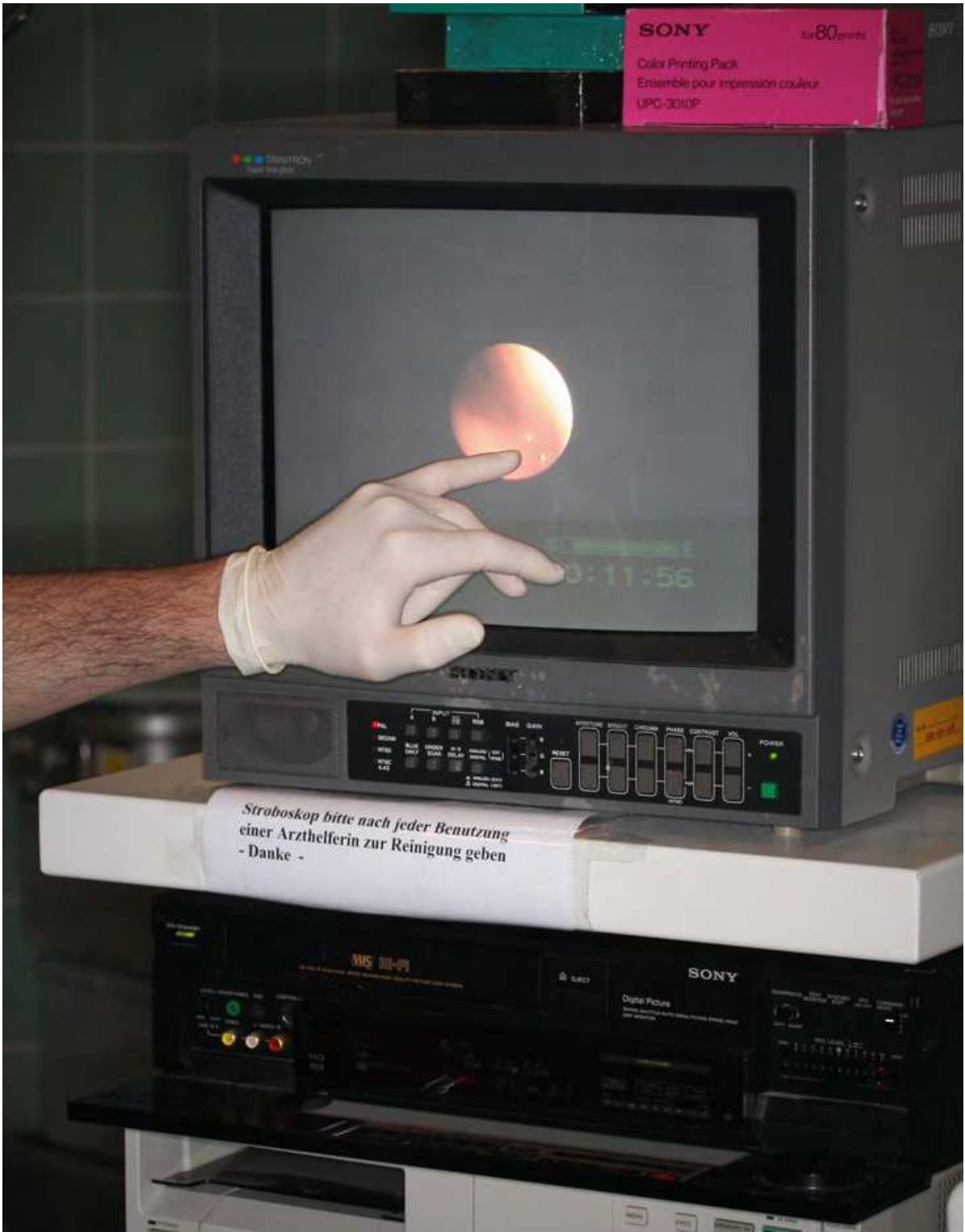

Fig. 4. Simultaneously the nasopharynx is controlled transorally with a 90° endoscope coupled with a digital camera. The position of the catheter can be controlled on a monitor. The position of the catheter is correct, if the choana lightens up on diaphanoscopy. By transnasal endoscopy the residual lumen of the choana was identified and the catheter was placed into the lumen.

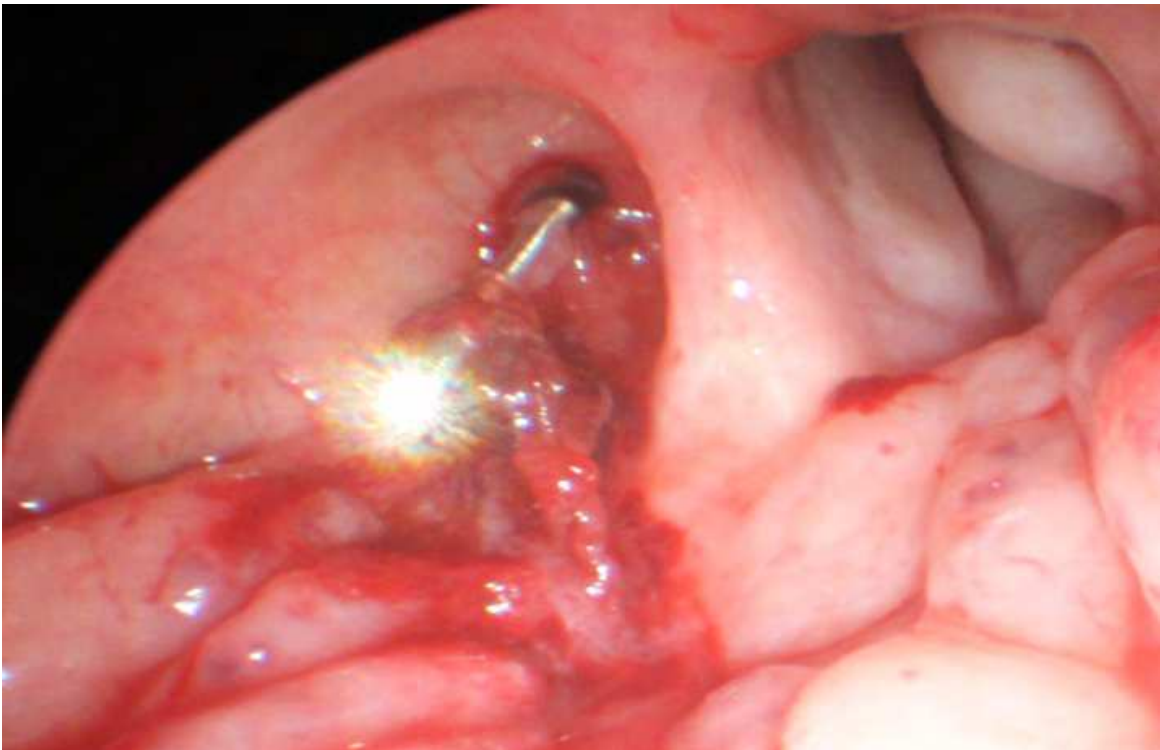


Fig. 5. The LUMA™ catheter is advanced into the nasopharynx (endoscopic image with a 90°-angled endoscope).

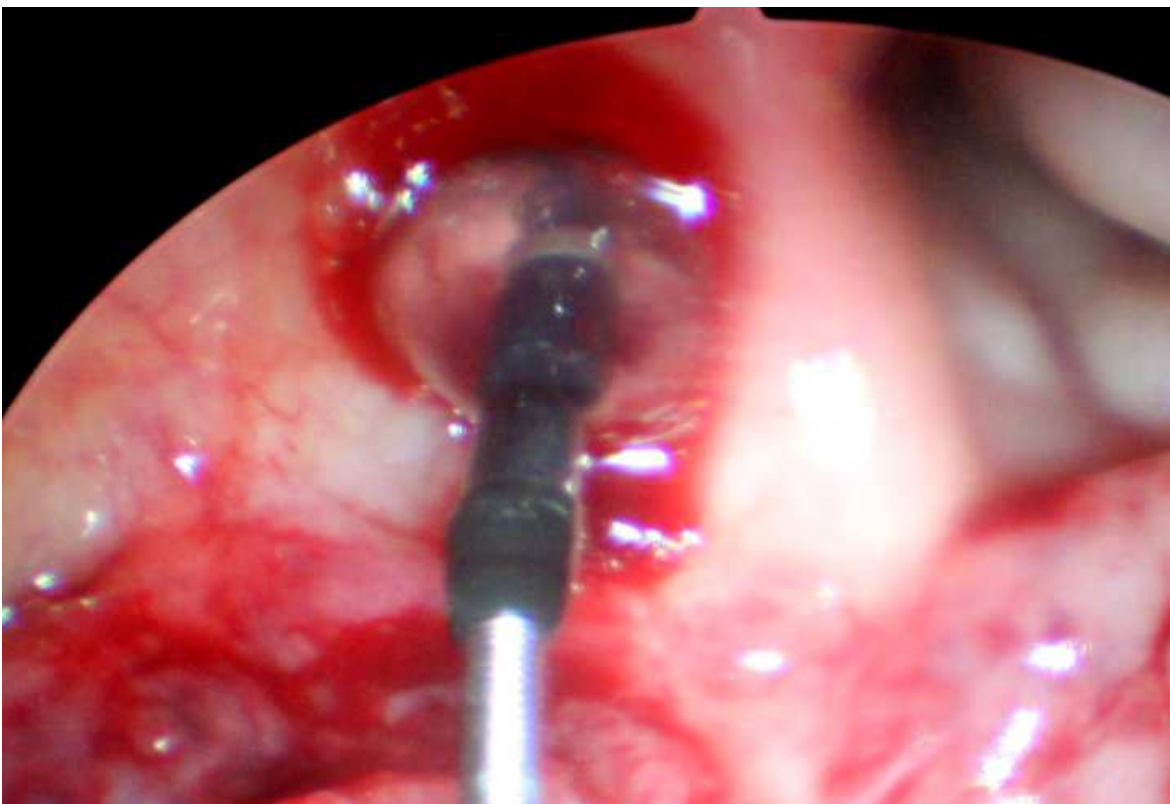


Fig. 6. Once the balloon catheter is in the correct position it is inflated with normal saline solution to a pressure of 8 atmospheres. The catheter stays in situ for 5 minutes.

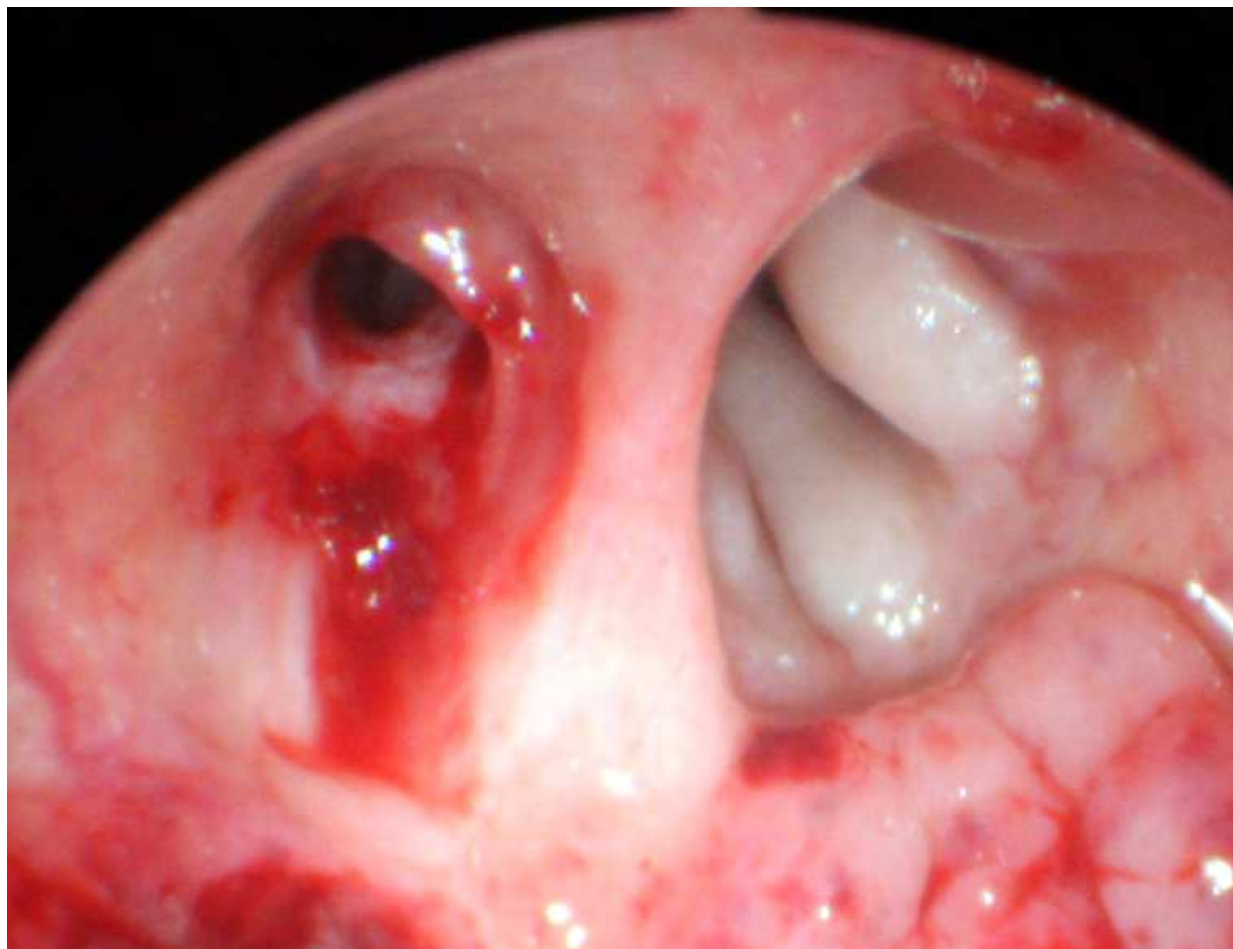


Fig. 7. After the removal of the catheter a circular dilatation of the atretic membrane is evident. The diameter of the choana is approximately 7 mm. Stenting of the choana was not necessary.

uneventful hours in the recovery area the patient was discharged home. Normal saline solution for nasal rinsing and nasal antiseptic cream were prescribed two times daily for the treatment of possible crusting.

4. Result

Intraoperatively the procedure was performed as planned, no adverse events occurred. The pressure in the balloon was successively increased at paces of 2 atms at each step until a target pressure of 8 atmospheres was reached. As shown in the respective image (Fig. 7), there was hardly any bleeding. The child had a normal recovery and did not complain about any pain or discomfort. There was no need for any specific postoperative therapy other than lubricating ointments, decongestive nose drops and rinsing the nose with normal saline. No antibiotics were administered. The child was under observation as an inpatient for 24 hours postoperatively. The boy was discharged on the following day. Postoperative packing or stenting was not necessary. On controls 6, 12, 18 and 24 months postoperatively the enlarged choanal lumen remained stable. Nasal breathing was restored successfully as could be shown by the mirror test (Fig. 8). There were no signs of rhinorrhoea, snoring or recurrent stenosis. The patient and his parents were extremely

happy with the result and the fact that the operation and postoperative phase was considerably less traumatizing than the initial operation. No specific therapy other than the above mentioned topical treatments were prescribed. The child is currently observed at 6 month intervals in our outpatient department.



Fig. 8. The patient at 6 months postop. The mirror test proves patency of the nasal airway. During an observation period of >24 months the child has been free of complaints.

5. Discussion

Balloon catheter dilatation started in February 1974, when Andreas Grüntzig of Zürich/Switzerland used this method for the first time to dilate a vascular stenosis. Grüntzig had designed, constructed and produced the Balloon catheters all by himself. In September 1974 he used a catheter of an advanced design to dilate an occluded coronary artery for the first time in medical history. Today the method which has been developed by Grüntzig is the standard treatment for occluded vessels in interventional cardiology and vascular medicine. Since Grüntzig's invention, balloon catheters have become a well established technique in modern medicine (Schlupf, 2004). This applies not only to Cardiology and Angiology, but also to many other medical specialities including Otorhinolaryngology. Most frequently balloon dilatations are performed in Rhinology in so-called Balloon Sinuplasty procedures. The principle idea of this technique is to dilate intranasal or sinusoidal bottle-necks without any classical surgical intervention, like incisions, tissue removal, suturing or coagulation. Balloon Sinuplasty also allows to perform interventions in areas of the nose and sinuses, which are difficult to access by conventional

endonasal techniques, like Functional Endoscopic Sinus Surgery (FESS). Based on these thoughts the idea of dilating a recurrent, predominantly membranous stenosis seemed to be promising. According to Meyer and Riemann stenoses and atresias of the choanae may be congenital, iatrogenic, post inflammatory or a result of radiation therapies for e.g. nasopharyngeal carcinoma (Meyer & Riemann, 2010). The incidence of a congenital choanal atresia is estimated to occur in 1:8000 children, girls are twice as often affected than boys (Jacob, 2001). In up to 2/3 of the cases choanal atresias may be combined with further congenital defects. The CHARGE syndrome (Coloboma of the eye, Heart disease, Atresia of choanae, Retarded growth and development and/or CNS anomalies, Genital hypoplasia, and Ear anomalies and/or deafness) may be an example for this observation (Pagon et al, 1981). Bilateral choanal atresia becomes evident in newborns immediately after birth. The healthy newborn usually breathes through the nose at rest. Nasal breathing is crucial for newborns especially while being fed. Newborns with bilateral choanal atresia show the clinical sign of „paradox cyanosis,“ while being fed, i.e. first they become cyanotic, then they stop swallowing and start to cry. At this point cyanosis resolves because the newborns can breathe orally again. In newborns with bilateral choanal atresia immediate action is therefore required. Unilateral choanal atresia on the other hand often is not recognized immediately. This defect usually becomes evident at a later point of time in life, when parents recognize permanent or recurrent unilateral rhinorrhoea. Therapy of unilateral choanal atresia mostly is surgical, either via the transnasal route or via the palatal route. Sometimes even a combined transnasal – transoral approach can be helpful. Although surgery nowadays is minimally invasive, large wounds and tissue defects may occur, necessitating intensive postoperative care and in some cases stenting. Despite all measures like excellent postoperative care, stenting or Mitomycin-C applications, the rate of secondary stenoses is high. Aside from the fact of a surgical intervention, insertion of a stent, which is supposed to keep the widened stenosis open, is often uncomfortable for the patient. Patients complain of foreign body sensation, rhinorrhoea and pain. Inflammation due to mucosal abrasions or foreign body reactions may occur. Many surgeons believe that only the reduction of trauma to surrounding tissue is likely to reduce the rate of recurrent stenoses. In 2006 Brown and Bolger described a new method for the dilation of sinus ostia for the treatment of recurrent nasal and paranasal sinusitis. One of the advantages of this new method was minimal trauma to surrounding tissues (Brown & Bolger, 2006, Siow et al., 2009). When performing Balloon Sinuplasty the surgeon can generally choose between two different techniques. The correct position of the guide wire can be controlled by fluoroscopy in a similar fashion like in interventional cardiology or interventional radiology. However, in the head and neck region this leads to a considerable radiation exposure, first of all for the patient and secondly for the surgeon. Due to the fact that the hands of the surgeon manipulate in close proximity to the nose, they are regularly exposed to radiation during fluoroscopy, which is needed to control the position of the guide wire and the balloon. Patient's eyes and the lenses are exposed to the radiation beam and it is not uncommon that patients, who are frequently exposed to radiation may develop cataract. The estimated radiation dose during Balloon Sinuplasty accounts to approximately 730 mrem (Bolger et al., 2007). In comparison the radiation dose of a CT scan of the head accounts to only 200 mrem, CT scan of the chest sums up to approximately 800 mrem. Angioplasty on the other hand exposes the patient to radiation between 750 and 5,700 mrem (Siow et al. 2008).

Due to the problem of unwanted radiation exposure and due to the fact that not every hospital offers the technical requirements, which are needed for Balloon Sinuplasty under fluoroscopy a novel technique was developed. The presented patient was also treated with the new technique, which is known under the acronym LUMA technology. The principle of LUMA technology is that the position of the guide wire and the balloon is not controlled by fluoroscopy, but by endoscopy and diaphanoscopy. In this variation of Balloon Sinuplasty the guide wire contains a flexible light fiber, which can be coupled to a cold light source, which is usually present in every ENT operating room. The tip of the guide wire is extremely soft and emits light in an intensity, that it illuminates the frontal and maxillary sinus perfectly. Thus the position of the guide wire can be controlled from the outside by diaphanoscopy and from the inside by routine endoscopy with rigid endoscopes. Correct placement of the balloons in the frontal recess or in the maxillary ostium is thus possible without any radiation. The advantages of the LUMA technology rendered the treatment of our presented patient, who was four years old at the time of treatment. We feel that this technique allows minimally invasive dilatations in paediatric patients or even in pregnant women. The risk of perforating the orbit or the skull base is low, due to the flexibility of the guide wire/light fiber. Complications or undesired side effects are unlikely to occur. This method seemed ideal for the presented case and a thorough analysis of the medical literature showed that balloon dilatation had already been tried in a similar case. Goettman and coworkers were probably the first, who had treated recurrent choanal atresia by balloon dilatation. They used repeated balloon dilatations in a 16-year-old girl, which had presented herself with a restenosis 3 weeks after conventional and laser surgical therapy of a choanal atresia. In their publication from the year 2000 the authors reported about good results during a follow-up period of 2 years (Goettman et al., 2000). We could show similar results with only one dilatation. In addition, our method had the advantage that all manipulations were carried out under endoscopic control with the LUMA™ technique, i.e. no X-ray control was needed to position or control the balloon. Thus exposure of the patient or the surgeons to radiation was not necessary. The presented technique may be especially suited for membranous recurrent stenosis. A comparison between Balloon Sinuplasty for dilatation of a choanal stenosis with conventional transnasal, transoral or combined operations show that the Balloon technique requires more resources in disposable material (Fig. 9), the time for the actual intervention however is considerably shorter than operation time in conventional surgery. It seems to be recommendable to increase the pressure in the balloon stepwise. An increase of pressure of 2 atmospheres during each step is sufficient to build up adequate pressure in the balloon, as Brehmer recommended (Brehmer D., 2008). There are no uniform recommendations about the ideal pressure or the duration of the actual dilatation process in literature. We chose to build up a pressure of 8 atmospheres within 5 minutes to dilate the atresia. Meyer und Riemann reported on dilatation of a choanal atresia in an oncologic patient with 12 atmospheres within 12 seconds (Meyer and Riemann, 2010) , Brown und Bolger used pressures between 10-16 atmospheres (mean maximum pressure 13 atm) for about 5 seconds, with an inflation/deflation interval of 10 seconds each (Brown & Bolger, 2006). Other authors like Brehmer estimate that the required pressure may be considerably lower, i.e. 8 atmospheres (Brehmer D., 2008).

Since it's initial description dilatation procedures in the nose have become more and more accepted in Otorhinolaryngology. The procedure are regarded to be safe, with hardly any side-effects. Bolger and coworkers could prove the safety and efficacy of Balloon Sinuplasty in a prospective multicentric trial with 115 patients. Patients were followed up for a period

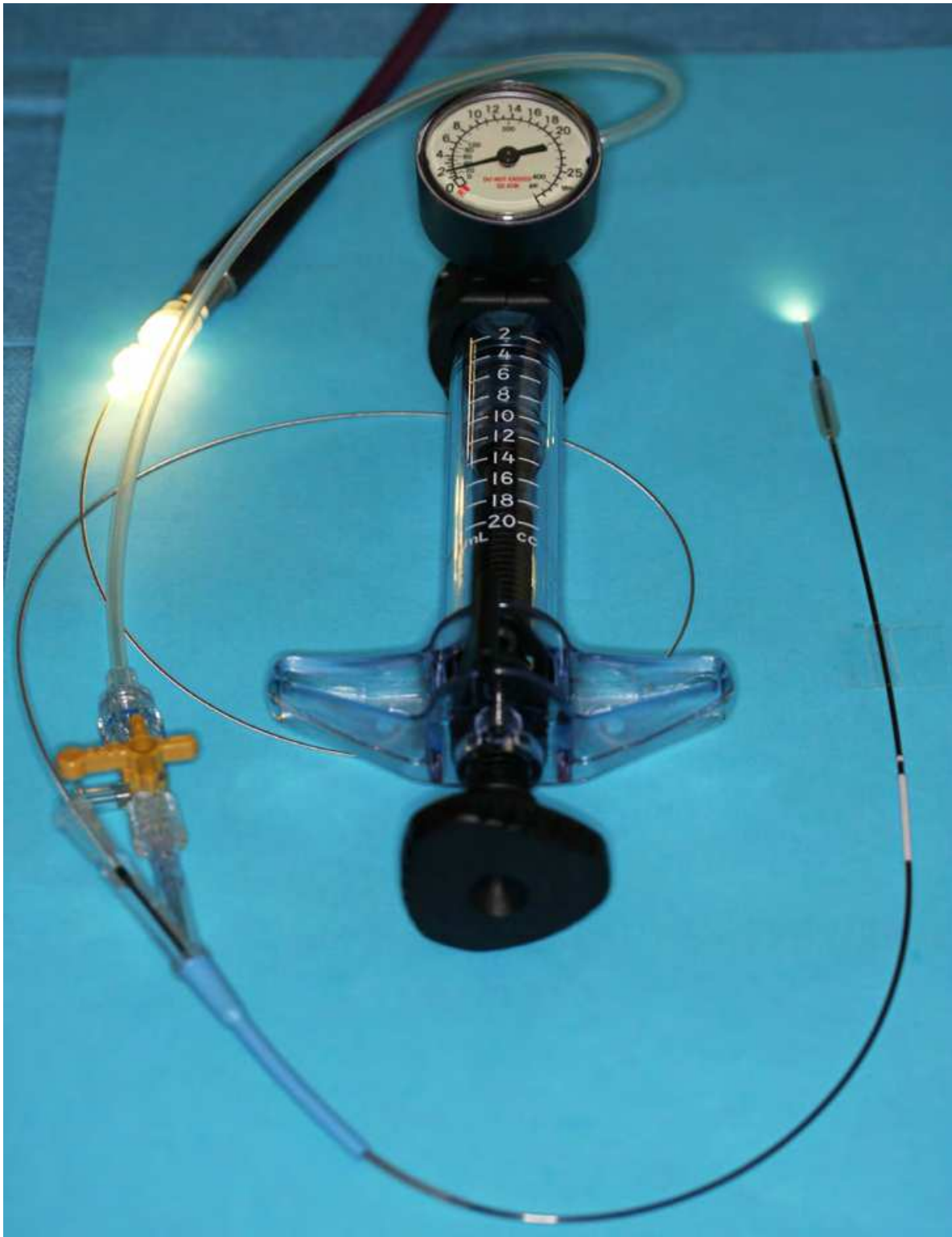


Fig. 9. System for Balloon dilatation as used for dilating the atresia of choanae. The guidewire is connected to a bright external light source with a detachable connector. Intraoperative the distal tip with the light fiber provides a direct visual confirmation via diaphanoscopic illumination. With the attached syringe-like Relieva® Sinus Balloon Inflation Device the balloon was inflated with normal saline solution until a pressure of 8 atm. was reached.


of 24 weeks and postinterventional endoscopies were performed. The trial showed a successful and persistent dilatation of sinus ostia in 80,5% of the patients. In 1,6% of the cases a persistent ostium could not be seen on endoscopy, in 17,9% of the cases the interior nose could not be assessed adequately by endoscopy (Bolger et al, 2007). Nine patients had developed bacterial sinusitis, which could be treated successfully by oral antibiotic therapy. Major complications had not occurred. In our case of a child with recurrent choanal atresia the results are similarly positive. Neither were there any undesired events during the intervention nor in the postinterventional period. No secondary hemorrhage or infection was observed. The good result encourages us to report this procedure as a possible alternative to conventional surgery in selected cases.

6. Conclusion

There is preliminary evidence that dilatation of membranous choanal atresia is feasible with balloon catheters. It is less invasive than FESS and requires only little postoperative care. Postoperatively no stents have to be inserted. This is of importance for patient's quality of life aspects. The patients does not have to endure any foreign bodies in his nasal airway. Additionally a second surgical procedure for removal of the stent is not necessary. Thus it seems to be of great value especially in the treatment of paediatric patients.

7. References

- Brown CL, Bolger WE. Safety and feasibility of balloon catheter dilation of paranasal sinus ostia: a preliminary investigation. *Ann Otol Rhinol Laryngol* 2006; 115:293-299
- Bolger WE, Brown CL, Church CA, Goldberg AN, Karanfilov B, Kuhn FA, Levine HL, Sillers MJ, Vaughan WC, Weiss RL. Safety and outcomes of balloon catheter sinustomy: a multicenter 24-week analysis in 115 patients. *Otolaryngol Head Neck Surg* 2007; 137:10-20
- Brehmer D. Catheter-based balloon dilatation of the frontal, maxillary und sphenoid ostia: a new procedure in sinus surgery. *HNO* 2008; 56:65-70
- Goettman D, Strohm M, Strecker EP. Treatment of a recurrent choanal atresia by balloon dilatation. *Cardiovasc Intervent Radiol* 2000; 23:480-481
- Meyer HJ, Riemann R. Behandlung erworbener Choanalstenosen durch Ballon-Dilatation. *Laryngorhinootologie* 2010; 89:289-10
- Siow JK, Al Kadah B, Werner JA. Balloon sinuplasty: a current hot topic in rhinology. *Eur Arch Otorhinolaryngol.* 2008; 265:509-11
- Schlupf M. 30 Jahre Ballonkatheter: Andreas Grüntzig, ein Pionier in Zürich. *Schweizerische Ärztezeitung*, 2004; 85, 7: 346-351
- Jacob R. 2001. Erkrankungen der Nase und des Pharynx: Pharynx. In: *Praxis der HNO-Hielkunde, Kopf- u. Halschirurgie*, J.Strutz & W.Mann. p 396, Thieme-Verlag Stuttgart, New York; ISBN: 3-13-116971-0
- Pagon RA, Graham JM Jr, Zonana J, Yong SL: *Coloboma*, congenital heart disease, and choanal atresia with multiple anomalies: CHARGE association. *JPediatr.*1981; 2:223-7.



Advances in Endoscopic Surgery

Edited by Prof. Cornel Iancu

ISBN 978-953-307-717-8

Hard cover, 444 pages

Publisher InTech

Published online 25, November, 2011

Published in print edition November, 2011

Surgeons from various domains have become fascinated by endoscopy with its very low complications rates, high diagnostic yields and the possibility to perform a large variety of therapeutic procedures. Therefore during the last 30 years, the number and diversity of surgical endoscopic procedures has advanced with many new methods for both diagnoses and treatment, and these achievements are presented in this book. Contributing to the development of endoscopic surgery from all over the world, this is a modern, educational, and engrossing publication precisely presenting the most recent development in the field. New technologies are described in detail and all aspects of both standard and advanced endoscopic maneuvers applied in gastroenterology, urogynecology, otorhinolaryngology, pediatrics and neurology are presented. The intended audience for this book includes surgeons from various specialities, radiologists, internists, and subspecialists.

How to reference

In order to correctly reference this scholarly work, feel free to copy and paste the following:

B.J. Folz and C.-G. Konnerth (2011). Endoscopically Guided Balloon Dilatation of Recurrent Choanal Stenosis, *Advances in Endoscopic Surgery*, Prof. Cornel Iancu (Ed.), ISBN: 978-953-307-717-8, InTech, Available from: <http://www.intechopen.com/books/advances-in-endoscopic-surgery/endoscopically-guided-balloon-dilatation-of-recurrent-choanal-stenosis>

INTECH
open science | open minds

InTech Europe

University Campus STeP Ri
Slavka Krautzeka 83/A
51000 Rijeka, Croatia
Phone: +385 (51) 770 447
Fax: +385 (51) 686 166
www.intechopen.com

InTech China

Unit 405, Office Block, Hotel Equatorial Shanghai
No.65, Yan An Road (West), Shanghai, 200040, China
中国上海市延安西路65号上海国际贵都大饭店办公楼405单元
Phone: +86-21-62489820
Fax: +86-21-62489821

© 2011 The Author(s). Licensee IntechOpen. This is an open access article distributed under the terms of the [Creative Commons Attribution 3.0 License](https://creativecommons.org/licenses/by/3.0/), which permits unrestricted use, distribution, and reproduction in any medium, provided the original work is properly cited.

IntechOpen

IntechOpen