

We are IntechOpen, the world's leading publisher of Open Access books Built by scientists, for scientists

6,900

Open access books available

185,000

International authors and editors

200M

Downloads

Our authors are among the

154

Countries delivered to

TOP 1%

most cited scientists

12.2%

Contributors from top 500 universities



WEB OF SCIENCE™

Selection of our books indexed in the Book Citation Index
in Web of Science™ Core Collection (BKCI)

Interested in publishing with us?
Contact book.department@intechopen.com

Numbers displayed above are based on latest data collected.
For more information visit www.intechopen.com



Management of Conjunctivitis in General Practice

Soumendra Sahoo¹, Adnaan Haq²,
Rashmirekha Sahoo³ and Indramani Sahoo⁴

¹Melaka Manipal Medical College

²St George University of London

³Nilai University College

⁴Retired Professor Ophthalmology

^{1,3}Malaysia

²UK

⁴India

1. Introduction

This chapter will describe various treatment options for infective conjunctivitis, allergic conjunctivitis, conjunctivitis in immunological disorders and other varieties of conjunctivitis that can be effectively managed in general practice whilst also highlighting various RCTs and systematic reviews on treatment of conjunctivitis.

The conjunctiva is a vascularised mucus membrane that covers some anterior portion of the globe and the inner aspects of eye lids. Like all mucous membranes, it also consists of epithelial and stromal layers. The continuum of the epithelial cell layer occurs in one side with epidermis of the lids at the lid margin and with the corneal epithelium at the limbus. Because of this anatomical architecture we call this pouch as conjunctival cul-de sac. The conjunctiva has enormous potential for combating infections mainly because of a) high vascularity b) different types of cells present in conjunctiva initiating and participating in defence inflammatory reactions c) immunopotent cells present in conjunctiva d) enzymatic activity of conjunctiva neutralising many pathogens including viruses. However the conjunctival sac is rarely sterile and is prone to external insult as well as victim of immunological reactions. It has been found that the normal conjunctival flora shares organisms with the skin and respiratory tract. The major organisms found are *Staphylococcus*, *Diphtheroids*, *Anaerobes*, *Streptococcus*, *Pneumococcus*, *Haemophilus*, *E.Coli* etc. However, as most of these potential pathogens are in their dormant stage, they rarely cause infection. Bacterial or infective conjunctivitis is mainly due to organisms of exogenous source. Though many forms of such infections are self-limiting because of barrier function of the conjunctival epithelium, there are exceptions for certain virulent organisms such as *N.gonorrhea*, *Listeria monocytogens*, *Corynebacterium diphtheriae* and the *Haemophilus* group. These bacteria possess proteolytic enzymes which damage the parenchymal structure of the conjunctiva. Some conjunctival infections may signify an underlying disease something more sinister such as a systemic disease. In neonates, infective conjunctivitis poses a greater

threat to the vision in comparison to adult varieties and therefore any visual problems must be assessed thoroughly.

1.1 Role of general practitioner in managing conjunctivitis

The majority of conjunctivitis cases report to their general practitioner for initial management. In a study in 1992, most general practitioners expressed confidence of managing conjunctivitis by themselves although many expressed that to refer the cases later if necessary. (Featherstone P I et al 1992)

The general practitioner needs to be well versed in diagnosing the type of conjunctivitis and rendering initial advices to the sufferer. Although conjunctivitis looks like a minor ailment, it can be frustrating and has social implications especially at work places.

1.2 Guidelines for GPs in achieving the following goals

- Identify patients at risk of developing conjunctivitis
- Accurately diagnose conjunctivitis of diverse origins
- Improve the quality of care rendered to patients with conjunctivitis
- Initiate appropriate treatment for conjunctivitis
- Reduce the potentially adverse effects of conjunctivitis
- Inform and educate patients and other health care providers about the diagnosis and management of conjunctivitis.

2. Management of conjunctivitis

It is essential to differentiate conjunctivitis from other vision threatening conditions that produce red eye such as in acute congestive glaucoma and uveitis. The GP should try to extract as much information from history taking. The second task with them is to find out the type of conjunctivitis. Cases with bacterial conjunctivitis will most likely present with white discharge, whilst watering of the eye has been associated with viral conjunctivitis. Itching is a prominent symptom in case of allergic conjunctivitis. Other forms of conjunctivitis such as in immunological disorders can be identified after finding some form of clinical clue during systemic examination. While managing cases of conjunctivitis, general practitioners must try to avoid contaminating themselves as well as clinic items.

2.1 Management of bacterial conjunctivitis

Although most cases of bacterial conjunctivitis run through benign course and self-healing, depending on the immune status of the patient, it might lead to severe lasting and with threat to vision too. As mentioned earlier, bacterial conjunctivitis usually presents with sticky eyes with white discharges. Unilateral conjunctivitis may be due to chemical, toxic, mechanical factors or may be due to the involvement of lacrimal gland or even a case of glaucoma, which the GP should be aware of while treating them.

Although there has been a tremendous decrease in incidence of most dangerous varieties of bacterial conjunctivitis such as caused by *Gonococcus* and *Diphtheria*, bacterial conjunctivitis still continues as commonest type of conjunctivitis in developing nations. The outbreak is usually during monsoon season. Conjunctival discharge (usually white) used to be the main diagnostic feature apart from red and gritty eye as major complains. Once a GP is certain of bacterial conjunctivitis, their first approach would be to clean the discharge with cotton

soaked with warm water, and to explain the same procedure to the patients, so they can do in home before applying medications. Generally most of the bacterial conjunctivitis cases are treated as outpatient cases but whenever any corneal involvement is suspected it would be ideal to treat the patient as an inpatient.

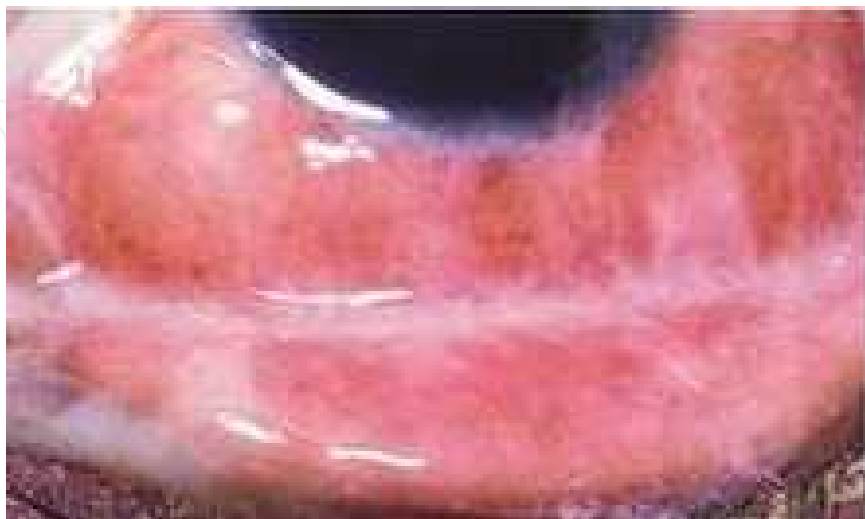

Fig. 1. Bacterial conjunctivitis (Look for the mucous discharge)

There are three categories of approaches of treating conjunctivitis in a GP setting; no use of antibiotic eye drops, delayed use of antibiotics and early use of antibiotics in conjunctivitis. (Everitt HA 2006).

The fundamental treatment of bacterial conjunctivitis is application of topical antibiotics. However, the pattern of antibiotics prescription varies in different practices. Most GPs prefer to start with broad spectrum antibiotics. The most commonly used broad-spectrum antibiotics are Ciloxan (ciprofloxacin) or Ocuflax (ofloxacin), Gatifloxacin, which are commonly prescribed. Sulfacetamide is also acceptable though not commonly used now days. Although aminoglycosides like Gentamycin and Tobramycin are often used they sometimes retard epithelial healing process, and so they should be used with caution. Polytrim (trimethoprim/sulfamethoxazole) is a reasonable choice particularly in children. Chloramphenicol eye drop is also a preferred choice especially in developing countries where the common organisms responsible are gram positive bacteria. The usual practice is to instil drops every 2 hours, although there is also an ointment that can be used at night or every 4-6 hours throughout the day.

To give a better idea on effectiveness of various topical antibiotics used in bacterial conjunctivitis we are quoting few study reports below.

A) Study on fluoroquinolone group of topical antibiotics:

One randomized, multicenter, double-masked, vehicle-controlled study, with a total of 957 patients aged 1 year and older with bacterial conjunctivitis were randomized to treatment with besifloxacin ophthalmic suspension 0.6% or vehicle applied topically three times daily for 5 days. It has been found that:

Three hundred and ninety patients had culture-confirmed bacterial conjunctivitis. Clinical resolution and microbial eradication were significantly greater with besifloxacin ophthalmic suspension than with vehicle at Visit 2 (45.2% vs. 33.0%, $p=0.0084$; and 91.5% vs.

59.7%, $p < 0.0001$, respectively) and Visit 3 (84.4% vs. 69.1%, $p = 0.0011$; and 88.4% vs. 71.7%, $p < 0.0001$, respectively). They had expressed that the results of secondary endpoints of individual clinical outcomes were consistent with primary endpoints. They also found that only few eyes receiving besifloxacin ophthalmic suspension experienced adverse events than those receiving vehicle (9.2% vs. 13.9%; $p = 0.0047$). They concluded by saying that the Besifloxacin ophthalmic suspension produced clinical resolution and microbial eradication rates significantly better than vehicle and was safe for the treatment of bacterial conjunctivitis. (Michael E T 2009)

In one recent comparative study on currently prescribed antibiotics in bacterial conjunctivitis, the authors evaluated the speed of clinical efficacy for two currently available topical antibiotics: polymyxin B sulfate/trimethoprim (polymyxin/trimethoprim) and 0.5% moxifloxacin ophthalmic solution. They had enrolled eighty-four eyes of 56 patients younger than 18 years with a clinical diagnosis of bacterial conjunctivitis in a multicenter study. Patients were randomly assigned to receive either 1 drop of polymyxin/trimethoprim four times daily for 7 days or 1 drop of 0.5% moxifloxacin three times daily for 7 days. Ocular signs and symptoms were evaluated at baseline and 24 and 48 hours after the start of dosing. Microbiological cultures were collected at baseline and 48 hours. They had noted patients rated ocular symptoms and adverse events on day 7 via telephone interview. They had included primary efficacy assessment as relief of all signs and symptoms of bacterial conjunctivitis. According to their reports all patients bar one completed all visits. At the 48-hour visit, complete resolution of ocular signs and symptoms was observed in 81% of the patients treated with moxifloxacin and 44% of the patients treated with polymyxin/trimethoprim ($P = .001$). No adverse events were reported in both the groups. They concluded by saying that Moxifloxacin 0.5% administered three times daily was safe and could cure bacterial conjunctivitis more effectively and significantly faster than polymyxin/trimethoprim dosed four times daily. The majority of patients were cured and symptom-free by 48 hours. They commented that moxifloxacin is cost-effective and significantly more efficacious than polymyxin/trimethoprim in the speed by which it reduced the symptoms and disease transmission. (Granet DB 2008)

B) Study on aminoglycoside group of topical antibiotics:

Similarly, one more comparative study was done for Gentamycin and Merimycin topical preparations in bacterial conjunctivitis. That study compared the clinical and microbiologic value of topical netilmicin with that of gentamicin in the treatment of acute bacterial conjunctivitis. It was a double-blind, randomized, prospective, controlled study, which was performed in 209 patients. One to two drop(s) of either antibiotic was applied to the affected eye(s) four times a day for up to 10 days. They examined the cases at the time of diagnosis and after 3, 5, and 10 days. Clinical efficacy was measured as the cumulative sum score (CSS) of the key signs and symptoms of acute bacterial ocular infection. Sensitivity/resistance was evaluated using the disk diffusion method. The drug efficacy assessment was restricted only to patients with positive baseline culture results ($n = 121$) in that study. Of the isolated organisms, 96.9% were sensitive to netilmicin, whereas only 75.0% were sensitive to gentamicin ($p = 0.00001$). They also observed that Netilmicin provided a broad-spectrum coverage comparable with that of ciprofloxacin, ofloxacin, and norfloxacin. Netilmicin also was more effective than gentamicin in eradicating infections ($p = 0.001$ at day 5 and $p = 0.037$ at day 10) and in ameliorating the CSS ($p = 0.037$ at day 3, $p = 0.001$ at both day 5 and day 10). Only minor adverse events occurred in patients

treated with either netilmicin or gentamicin. They concluded by saying that netilmicin was a safe and effective antibiotic that could be used as first-line therapy for the treatment of acute bacterial conjunctivitis. (Papa V 2002)

A study in Canada done by Jackson WB compared 1% fucidic acid viscous drop with 0.3% tobramycin eye drop in treating acute bacterial conjunctivitis and came with the conclusion that the clinical and bacteriologic efficacy of fusidic acid viscous drops combined with the convenience of a twice-daily dosage regimen establishes this antibiotic as first-line treatment for suspected acute bacterial conjunctivitis and a favourable alternative to other broad-spectrum antibiotics.

C) Recent study reports on Azithromycin eye drop:

Of late, studies on the use of Azithromycin in bacterial conjunctivitis provide some positive responses. Azithromycin 1% showed successful therapeutic intervention because therapy could be completed with 7 drops administered over 5 days, whilst high bactericidal levels were sustained in the eye overnight. they believed that there was the potential for reduction in the development of resistance by effectively killing sensitive organisms. (Friedlaender MH 2007).

Similarly, another study in 2008 showed that the topical therapy with azithromycin 1.5% administered only twice daily for 3 days effectively eradicated most pathogenic bacteria associated with bacterial conjunctivitis. Those microbiologic results were in accordance with the observed clinical outcome. The study claimed that the new anti-infective product had the advantage of a short treatment course which could lead to an improvement in patient compliance. (Denis F 2008)

One more study highlighted the kinetics of Azithromycin in treating bacterial conjunctivitis. This study tested the hypothesis that azithromycin demonstrates a bactericidal, concentration-dependent antibiotic effect at concentrations corresponding to and exceeding published tear and conjunctival levels. The antibacterial activity of different concentrations of azithromycin 1% in DuraSite® (AzaSite®; Inspire Pharmaceuticals Inc, Durham, NC, USA) was evaluated in this study by using a kinetics-of-kill model. Recent conjunctivitis isolates of *Staphylococcus aureus*, *Streptococcus pneumoniae* or *Haemophilus influenzae* were exposed to four concentrations of azithromycin (100, 250, 500 and 750 µg/ml). Starting concentrations were similar to the maximum concentrations (C_{max}) that have been demonstrated in conjunctiva (83 µg/g) and tears (288 µg/ml) following topical ocular administration. The percentage of surviving bacteria at 30 and 60 minutes following exposure to each concentration were determined. Azithromycin failed to demonstrate bactericidal activity (i.e. a 3-log reduction in surviving bacteria) against *S. aureus*, *S. pneumoniae* or *H. influenzae*. Furthermore, the rate and extent of antibacterial activity with azithromycin did not change with higher concentrations, even at the highest tested concentration of 750 µg/ml. They concluded by saying that azithromycin demonstrated bacteriostatic activity against common conjunctival pathogens up to the maximum tested concentration of 750 µg/ml (i.e. 2.6-times and 9-times published C_{max} tear and conjunctival concentration, respectively). Azithromycin's bacteriostatic effects and prolonged elimination half-life would likely lead to a corresponding increase in the emergence of macrolide-resistant isolates. (Mark S 2008)

The advantages of Azithromycin eye drop in bacterial conjunctivitis is its shorter duration of effective treatment. In one comparative study the authors compared the three day treatment bacterial conjunctivitis with 1.5% Azithromycin eye drop versus 7 days treatment with

Tobramycin eye drop. They compared the efficacy and safety of Azyter, azithromycin 1.5% eye drops, for 3 days with tobramycin 0.3% for 7 days to treat purulent bacterial conjunctivitis. That was a multicentre, randomised, investigator-masked study including 1043 children and adults with purulent bacterial conjunctivitis. Patients received either azithromycin 1.5% twice-daily for 3 days or tobramycin 0.3%, 1 drop every two hours for 2 days, then four times daily for 5 days. Clinical signs were evaluated and cultures obtained at D0, D3 and D9 (where D refers to “day”). Primary variable was the clinical cure at the Test-of-Cure (TOC)-visit (D9±1), for patients with D0-positive cultures. The cure was defined as: bulbar conjunctival injection and discharge scores of 0. They documented that among 471 patients with D0-positivity in the per protocol set, 87.8% of the azithromycin 1.5% group and 89.4% of the tobramycin group were clinically cured at the TOC-visit. Azithromycin was non-inferior to tobramycin for clinical and bacteriological cure. Clinical cure was significantly higher with azithromycin 1.5% at D3. The safety profile of azithromycin was satisfactory with a good patient and investigator’s acceptability. They concluded by saying that Azithromycin 1.5% for 3 days was as effective and as safe as tobramycin for 7 days. Furthermore, more azithromycin than tobramycin patients presented an early clinical cure at Day 3. Due to its twice daily dosing regimen for 3 days, azithromycin represents a step forward in the management of purulent bacterial conjunctivitis, especially in children. (Isabelle C 2006)

To start or not start antibiotics, or a delayed start of antibiotics?

There has been debate on this question. We quote few study reports which did not find much difference in antibiotic treated group and those not given antibiotics.

In one of the Cochrane systematic reviews the meta analysis reveals that acute bacterial conjunctivitis is frequently a self-limiting condition, as clinical remission occurred by days 2 to 5 in 64% (95% confidence interval (CI) = 57-71) of those treated with placebo. But the treatment with antibiotics was, however, associated with significantly better rates of clinical remission (days 2 to 5: relative risk (RR) = 1.31, 95% CI = 1.11-1.55), with a suggestion that this benefit was maintained for late clinical remission (days 6 to 10: RR = 1.27, 95% CI = 1.00-1.61). They concluded by saying that the acute bacterial conjunctivitis is frequently a self-limiting condition but the use of antibiotics is associated with significantly improved rates of early clinical remission, and early and late microbiological remission. (A Sheikh and B Hurwitz).

Similarly, one randomised control trial involving 30 GP centres in UK, Everitt HA et al compared the three management strategies; no antibiotic, immediate antibiotic and delayed antibiotic and came to a conclusion that the delayed prescribing approach may be the best approach. Compared with no initial offer of antibiotics, delayed prescribing had the advantage of reduced antibiotic use (almost 50%), no evidence of hospitalisation, similar symptom control to immediate prescribing, and reduced re-attendance for eye infections. (Everitt HA 2006)

In view of antibiotic eye drops being costly in various parts of developing countries an alternate way of treating with povidone iodine, especially in children, can serve as alternative. This was documented in one of the studies, which was done to report the efficacy of povidone-iodine as a treatment for conjunctivitis in paediatric patients. It was a double-masked, controlled, prospective clinical trial. The study was done in a general hospital in Manila, Philippines, 459 children (mean (SD) age 6.6 (6.6) years; range, 7 months-21 years) with acute conjunctivitis were studied. Infected eyes were cultured for bacteria and underwent immunofluorescent testing for *Chlamydia trachomatis*. Viral conjunctivitis was diagnosed if bacterial cultures were negative and diagnostic criteria were met. Subjects

were alternated to receive povidone-iodine 1.25% or neomycin-polymyxin-B-gramicidin ophthalmic solution, one drop 4 times daily in the affected eye. Ocular inflammation was evaluated daily by the family or patient and weekly by an ophthalmologist. The main outcome measures were days until cured and proportion cured after 1 and 2 weeks of treatment. It was found that despite adequate statistical power (power >80% for a 1-day difference and $P < .05$), there was no significant difference between treatment groups regarding the number of days to cure or proportion cured at 1 or 2 weeks whether caused by bacteria or virus ($P = .133-.824$ for the four comparisons). After 1 week of treatment, povidone-iodine cured marginally more chlamydial infections than the antibiotic ($P = .057$). By 2 weeks, fewer chlamydial infections were cured than those of viral or bacterial etiology ($P = .0001$). The younger the patient, the faster their conjunctivitis resolved ($R = 0.13$, $P = .013$). The authors concluded in saying that povidone-iodine 1.25% ophthalmic solution was as effective as neomycin-polymyxin B-gramicidin for treating bacterial conjunctivitis, somewhat more effective against chlamydia, and as ineffective against viral conjunctivitis. Povidone-iodine ophthalmic solution should be strongly considered as treatment for bacterial and chlamydial conjunctivitis, especially in developing countries where topical antibiotics are often unavailable or costly. (Sherwin JI 2002)

The overall idea of a successful treatment of bacterial conjunctivitis is to go for proper diagnosis and follow up. GPs should restrain themselves from early initiation of antibiotics; rather follow the case with maintenance of ocular hygiene. The choice of antibiotic should also measure cost effectiveness and availability. And worsening of symptoms and signs should prompt GPs in referring cases to the Consultants.

It is interesting to note that in one of the studies comparing treatment with different antibiotics, it did not demonstrate that any one antibiotic is superior. It said that the choice of antibiotic should be based on consideration of cost and bacterial resistance. The present practice of prescribing antibiotics in most cases is not necessary. (Rose P 2007)

Although the very severe form of conjunctivitis resulting from *gonococcal* infections are always referred and treated by consultants, GPs should have knowledge on treatment and preventative measures of *gonococcal* conjunctivitis. Infection by *N gonorrhoeae* in the newborn also requires systemic treatment of the neonate, the mother, and at-risk contacts. In usual practice, general practitioners refer the cases for consultant's intervention. The neonate may be treated with intravenous aqueous penicillin G 100 units per kg per day in 4 divided doses for 1 week. The mother and at-risk contacts may be treated with a single dose of intramuscular ceftriaxone 125 mg followed by oral doxycycline 100 mg twice daily for 7 days. Common regime for prophylaxis for such occurrence is by instillation of 1% silver nitrate solution, 1% tetracycline ointment, or 0.5% erythromycin ointment just after birth. Patients with *gonococcal* conjunctivitis should be seen daily until resolution of conjunctivitis at the same time each case should be simultaneously treated for Chlamydia trachomatis infection.

2.2 Management of viral conjunctivitis

Viral induced conjunctivitis is another form of conjunctivitis and although self limiting in many cases, they take longer duration for healing. The most common viral organisms responsible for this form of conjunctivitis are Herpes simplex virus (HSV), Varicella Zoster virus (VZV), pox virus, measles virus, immunodeficiency virus (HIV) etc. In all these forms of conjunctivitis, the common presentation is the development of conjunctival follicles, which arise due to hypertrophied lymphoid tissue caused by the inflammatory reaction from the viral presence.

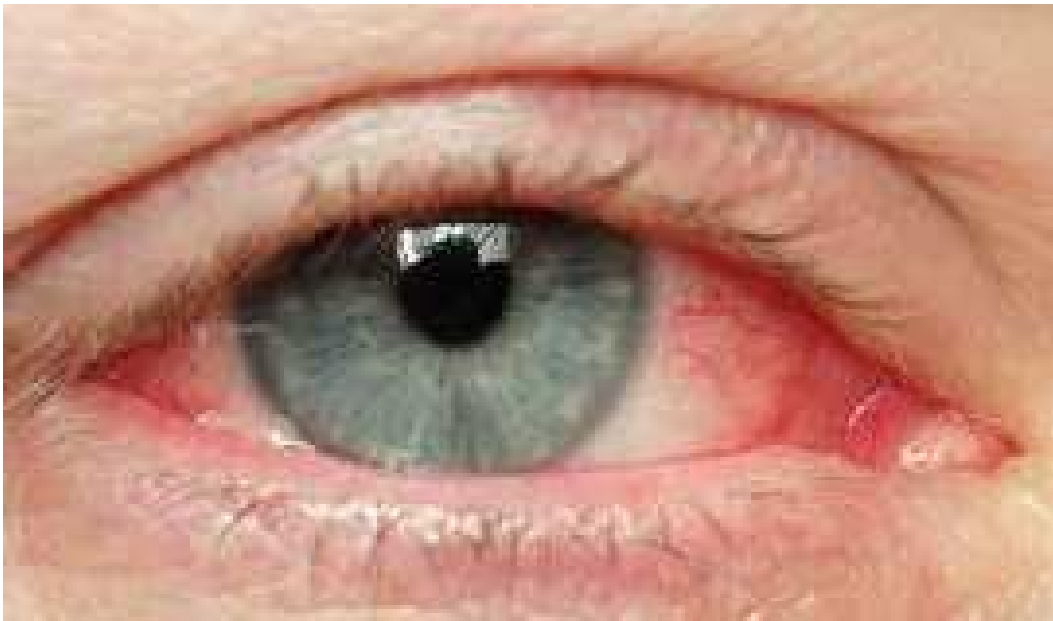

Fig. 2. Viral conjunctivitis (Look for pink eye without any discharge)

Herpes infection of the eye may be acquired as the patient's first exposure to the virus (primary infection) or as involvement of a new anatomical site (the eye) in a patient with previous HSV infection. In either case, patients with herpetic eye infection risk recurrent eye disease throughout their lives. The infective lesions of the corneal epithelium (dendritic and geographic ulcers) occasionally develop into non-infective indolent or trophic ulcers, particularly under the influence of cauterizing chemicals or corticosteroids. Inflammation of the corneal stroma may accompany herpetic epithelial lesions or occur independently. Stromal keratitis probably represents the host's immune response to viral antigens filtering down from epithelial lesions or from viral replication in stromal cells.

The choice of the optimal technique for diagnosing viral and chlamydial keratoconjunctivitis depends upon the efficiency, speed, and cost of the test. The performance of conventional laboratory procedures is relatively poor, and the interpretative difficulties documented with these tests are well recognised. Owing to their inherent sensitivity and high specificity, nucleic acid amplification procedures, in particular PCR, are recognised as the ultimate modern diagnostic tool for the identification of adenovirus, HSV, and *C trachomatis* in clinical eye swab samples. However, in laboratories without access to PCR, the conventional techniques of enzyme immunoassay, culture. (Elfath ME et al 1999)

Most cases of viral conjunctivitis, like that caused by adenovirus, need supportive treatment. No evidence exists that demonstrates efficacy of antiviral agents. Patients should be instructed to use cold compresses and lubricants, such as artificial tears, for comfort and symptom relief. For some susceptible individuals, a topical astringent or antibiotic may be used to prevent a bacterial super infection. Extreme caution should be taken when using corticosteroids, as they may worsen an underlying HSV infection. Recent reports suggest there is a beneficial effect of topical iodine povidone-iodine at a concentration of 1:10 (0.8%) in adenoviral conjunctivitis. Patients with acute conjunctivitis or those with corneal involvement, such as ulceration, herpetic keratitis, should be referred to an ophthalmologist without further delay.

General practitioners should not prescribe antibiotics in all cases of viral conjunctivitis, rather, they should offer supportive treatments such as cold compress, cleaning the

discharges with sterile cotton and sometimes prescribing artificial tears. They may also encourage using darker glasses as this not only reduces the photophobia experienced but also masks the virulent look of a red and swollen eye.

2.2.1 Tips on precautions during treatment

Patient instruction during treatment of viral conjunctivitis:

- Warning patients on contagious nature. They need to wash hand frequently and to avoid direct contact with others
- They need to be isolated from office/work place and from school at least for couple of weeks
- They need to know that the condition may get worse and should consult doctor frequently

Professional precautions:

- Hand washing before and after examining such cases
- Try to avoid contact of instruments
- If instruments get contaminated try to clean or sterilise. Immersing the instrument with 1-2% solution of sodium hypochlorite or 3% hydrogen peroxide is ideal

2.3 Management of allergic conjunctivitis

Allergic conjunctivitis comprises a group of diseases affecting the ocular surface and is usually associated with type 1 hypersensitivity reactions. Two acute disorders, seasonal allergic conjunctivitis and perennial allergic conjunctivitis, exist, as do 3 chronic diseases, vernal keratoconjunctivitis, atopic keratoconjunctivitis, and giant papillary conjunctivitis.

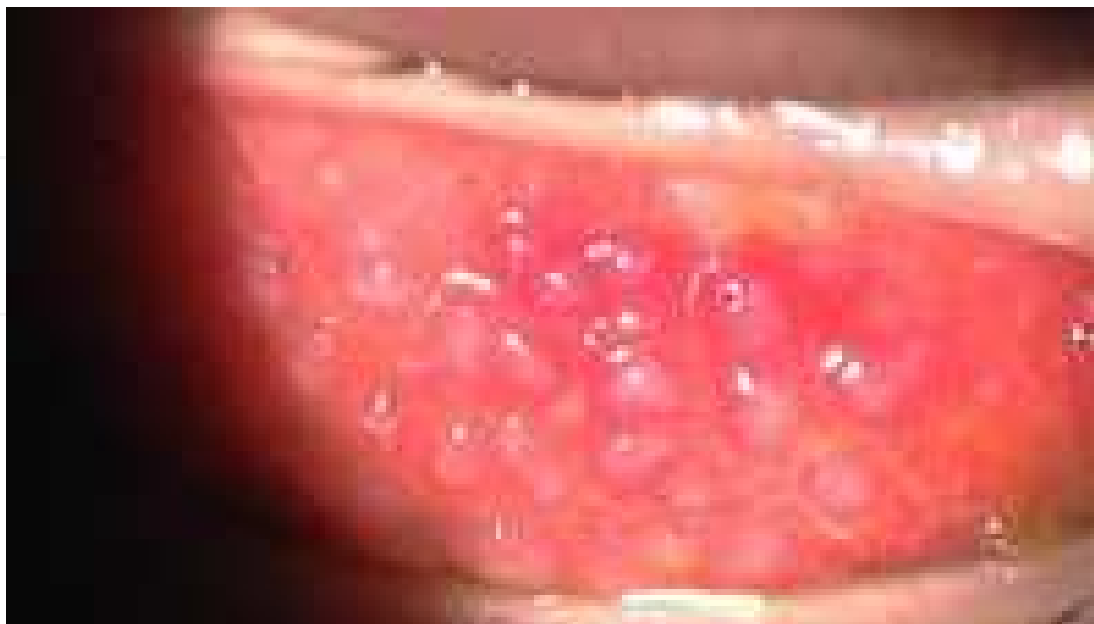

Fig. 3. Allergic conjunctivitis (Look for follicles and papillae)

The ocular surface inflammation (usually mast cell driven) results in itching, tearing, lid and conjunctival oedema-redness, and photophobia during the acute phase and can lead to a classic late-phase response (with associated eosinophilia and neutrophilia) in a subset of individuals. As is the case in other allergic diseases, a chronic disease can also develop, accompanied by remodelling of the ocular surface tissues. In severe cases, the patient experiences extreme discomfort and sustains damage to the ocular surface.

There are many varieties of both topical and systemic medications available for allergic conjunctivitis. It is often too confusing to select any one specifically for a purpose. Table 1 gives a broad idea on type of medication commonly available for treating allergic conjunctivitis with some examples and indications.

Group	Generic name	Indications
Systemic antihistamines	Cetirizine, Loratidine, Fexofenadine etc	Presence of systemic allergy along with conjunctivitis
Mast cell stabilisers	Cromolyn sodium, Lodoxamide, Nedocromil sodium	Effective in chronic conjunctivitis such as vernal conjunctivitis
Antihistamines with added property of mast cell stabilisation	Olopatadine, Ketotifen	Very good response in acute allergic conjunctivitis and in long run helps in stabilising mast cells too
Topical Steroids (Idealy the GPs should refrain from prescribing steroids; let this group used by Ophthalmologists only)	Fluorometholone, Loteprednol	Used for severe variety of allergic conjunctivitis but always look for toxicity in long term therapy
Vasoconstrictors	Naphazoline/Pheniramine	Any form of conjunctivitis as a support therapy but chronic use to be avoided
Topical NSAIDs	Keterolac	Symptomatic relief of itching in severe cases

Table 1. Summary of commonly available medications for allergic conjunctivitis

For such cases, there is no highly effective and safe treatment regimen. Topical administration of corticosteroids is used in severe cases but is associated with an increased risk for the development of cataracts and glaucoma. Thus, there is a worldwide search for new bio targets for the treatment of these diseases. Here, we provide a brief update of the clinical symptoms associated with these diseases, the rationale for disease classification, recent advances in our understanding of the pathogenesis of the diseases, and an update on both preclinical and clinical advances toward refined therapies for these diseases. (Santa JO et al 2005)

Another variety of conjunctivitis is produced because of the susceptibility of conjunctiva to allergens. They may be either exogenic or endogenic in nature. The conjunctival reaction is determined by the immune status of individuals. This variety of conjunctivitis is more challenging to treat than that resulted out of specific bacterial infections.

The primary aim of treating a conjunctivitis case is to relieve the common symptoms such as ocular itching, grittiness and discharge .Although many of the infective conjunctivitis have a self limiting course, patients often go to their General Practitioners or optometrists. General practitioners invariably prescribe antibiotics for a faster resolution of the symptoms whereas optometrists may offer a range of symptom relieving over the counter medication.

Mast cell stabilisers are another group which are used alone or in combination with steroid preparations. Commonly used are cromolyn sodium and lodoxamide (Alomide). Olopatadine (Patanol), nedocromil (Alocril), and ketotifen (Zaditor) . Nonsteroidal anti-inflammatory drugs (NSAIDs) which act on the cyclooxygenase metabolic pathway and inhibit production of prostaglandins and thromboxanes are found to be alternative to cortecosteroids and can be a better option. It is usually safe to prescribe vasoconstrictors in general practice due to the relatively low dose and fewer side effects. Common vasoconstrictors include naphazoline, phenylephrine, oxymetazoline, and tetrahydrozoline.

As mono-therapy, oral antihistamines are an excellent choice when attempting to control multiple early-phase, and some late-phase, allergic symptoms in the eyes, nose and pharynx. Topical antihistaminic agents not only provide faster and superior relief than systemic antihistamines, but they may also possess a longer duration of action than other classes including vasoconstrictors, pure mast cell stabilisers, NSAIDs and corticosteroids. Unfortunately, despite their efficacy in relief of allergic symptoms, systemic antihistamines may result in unwanted adverse effects, such as drowsiness and dry mouth. Newer second-generation antihistamines (cetirizine, fexofenadine, loratadine and desloratadine) are preferred over first-generation antihistamines in order to avoid the sedative and anticholinergic effects that are associated with first-generation agents. Finally it can be said that when the allergic symptom or complaint, such as ocular pruritus, is isolated, focused therapy with topical (ophthalmic) antihistamines is often efficacious and clearly superior to systemic antihistamines, either as monotherapy or in conjunction with an oral or intranasal agent.

Topical cyclosporine A is an effective treatment in the management of severe allergic conjunctivitis refractory to other medications mentioned earlier. It has additional benefit as a steroid-sparing agent. (Ozcan et al 2007)

In spite of using all the verities of above mentioned topical preparations allergic conjunctivitis sometimes more challenging and frustrating in general practice. They often

prompted for using steroid eye drops. The use of corticosteroid should aim at relatively weak steroids, such as rimexolone, medrysone, and fluorometholone, that tend to have less potency with fewer ocular adverse effects but can be prescribed for a longer durations. Topical corticosteroids may be considered for severe seasonal ocular allergy symptoms, although long-term use should be avoided because of risks of ocular adverse effects, including glaucoma and cataract formation. (Leonard B et al 2005). So it is better advisable for GPs not to start steroid eye drops.

Having said this, although the treatment for allergic conjunctivitis has markedly expanded in recent years, providing opportunities for more focused therapy, it often leaves both physicians and patients confused over the variety of options. Therefore a proper assurance and frequent counselling to the sufferers holds the key to successful management of allergic conjunctivitis.

2.3.1 Atopic keratoconjunctivitis

AKC is a bilateral inflammation of conjunctiva and eyelids, which has a strong association with atopic dermatitis. It is also a type I hypersensitivity disorder with many similarities to VKC, yet AKC is distinct in a number of ways.

In 1953, Hogan first described the association between atopic dermatitis and conjunctival inflammation.¹ He reported 5 cases of conjunctival inflammation in male patients with atopic dermatitis.¹ Atopic dermatitis is a common hereditary disorder that usually has its onset in childhood; symptoms may regress with advancing age. Approximately 3% of the population is afflicted with atopic dermatitis, and, of these, approximately 25% have ocular involvement. General practitioners should try with antihistamines and if not responding should refer the cases to Ophthalmologists.

2.3.2 Giant papillary conjunctivitis (GPC)

GPC is an immune-mediated inflammatory disorder of superior tarsal conjunctiva. As the name implies, the primary finding is the presence of “giant” papillae, which are typically greater than 0.3 mm in diameter. It is believed that GPC represents an immunologic reaction to a variety of foreign bodies, which may cause prolonged mechanical irritation to the superior tarsal conjunctiva. Although contact lenses (hard and soft) are the most common irritant, ocular prostheses, extruded scleral buckles, and exposed sutures following previous surgical intervention may precipitate GPC. Topical mast cell stabilisers can be given to such cases.

2.3.3 Follow-up of allergic conjunctivitis cases

Follow up is an important strategy while treating allergic conjunctivitis because of the following purposes

- GPs need to diagnose steroid related complication or steroid dependence early so that idiosyncrasy is saved
- GPs should go for change of medication or to go for some combination therapy if the initial response found ineffective.
- GPs should provide health education during all visits so that avoidance of allergy sensitive factors become a habit of the individual
- GPs should provide assurance to the cases and their relatives on every follow up.

Type of Conjunctivitis	Clinical features	Treatment	Prevention
Bacterial Conjunctivitis	Red eye Photophobia Discharge	Cleanliness of eyes Symptomatic If Antibiotics : 1. Ciprofloxacin, Ofloxacin, Gatifloxacin, Moxycloxacillin, 2. Chloramphenicol 3. Gentamycin	Hand washing Avoid share of napkins Cleaning and disinfectiveness of instruments used Avoid contact lens
Viral Conjunctivitis	Red eye Watering of eye Mild itching Sometimes with subconjunctival haemorrhage Presence of follicles	Mostly symptomatic with the use of cold compress In longstanding cases might prescribe antibiotics for secondary infection. No substantial benefit of antivirals.	Personal hygiene:Washing hands Disinfect the instruments used
Allergic Conjunctivitis	Red eye Intense Itching Lacrimation Cobblestone appearance Giant papillae Tranta’s spot Presence of mucus threads	Assurance 1. Steroid eye drops 2. Antihistamine eye drops 3. Disodium cromoglycate eye drops 4. Lodoxamide eye drop 5. Olapatadine eye drop	Avoidance of allergy Desensitisation in some cases
Conjunctivitis from Immunological	Red eye Dry eye Involvement of cornea and sclera Presence of systemic features depending on the case	Lubricant eye drops Corticosteroids in some cases Topical NSAIDs	Periodic Ophthalmic checkups in the presence of systemic immunological disorders
Other forms of conjunctivitis 1. Cicatrizing conjunctivitis 2. Superior limbic conjunctivitis	1.Dry eye,conjunctival scarring,corneal involvement 2.Foreign body sensation,photophobia,mucoid discharge & dry eye	1. Topical steroids,topical lubricating agents,surgical repair 2. Topical lubricants,Mast cell stabilisers	

Table 2. A quick guide to the diagnosis and treatment of various forms of conjunctivitis by general practitioners

2.4 Management of conjunctivitis from immunological reactions

Some examples of conjunctivitis resulted out of immunological reactions are cicatricial pemphigoid, conjunctivitis in erythema multiform, conjunctival reaction in Stevens Johnson syndrome etc. In most form of these immunological conjunctivitis there use to be great amount of scarring and cicatrization of conjunctival tissue. The treatment of these conditions may require some surgical approach apart from medicinal therapy. Hence these are out of scope in treating at the hand of general practitioners. However, GPs should be aware of such conditions and it would not be a bad idea from their side to start topical antibiotic earliest to avoid secondary infections. They should know to start topical antibiotics along with steroid if happen to see a case of Stevens Johnson syndrome. They should also be able to counsel the cases on severity of such cases and inform the cases regarding possible surgical interventions like ocular surface reconstruction, keratoprosthesis etc.

3. Preventive aspects of various forms of conjunctivitis

Prevention of infective conjunctivitis relies primarily on good personal hygiene. The bacterial conjunctivitis is uncommon but can be spread by the hands or from upper respiratory tract infections. Gonococcal infection is transmitted from the genital tract or urine to the eye by hands. This is a serious breach of normal hygiene. Ophthalmia neonatorum can be prevented by the use of povidone iodine drops, tetracycline eye ointment or other antiseptics or antibiotics at birth.

Viral conjunctivitis can sweep through a community or an institution such as a school very rapidly. This is highly infectious and needs to be controlled by the enforcement of strict hygiene standards. Contamination through possible articles like towels, face cloths and hands need to be avoided. Prevention of allergic conjunctivitis is not possible unless the patient is able to change his or her environment or job or identify the allergen causing the allergy and remove it, e.g., pollen, animal fur. Drugs such as atropine, neomycin can cause allergy and needs prompt withdrawal if detected.

4. Conclusion

Conjunctivitis is very frustrating and has social implications especially at work places if it is not treated comprehensively. General Practitioners must remain vigilant when suspecting conjunctivitis and have the ability to quickly determine whether it has been caused by bacteria, viruses or allergens. They should know that a past history of infectious conjunctivitis and complaints of itching invariably excludes the possibility of bacterial conjunctivitis, whereas complaints such as glued eye are indicative of bacterial conjunctivitis.

Another fact that general practitioners must take into consideration is that viral conjunctivitis is more prevalent and has a stronger tendency to recur than a bacterial conjunctivitis. Conjunctivitis with a dominant itch indicates an allergic cause. Failure to differentiate what the cause is may lead to wrong treatment and may, in some cases, prolong treatment. It must also be noted that General Practitioners should also remain aware of the differential diagnoses, such as uveitis, acute congestive glaucoma and instruct patients to seek follow-up care if the expected improvement does not occur or if vision becomes affected.

5. Acknowledgement

We would like to acknowledge the constant encouragement and support of the Chief Executive of MMMC, Malaysia and Pro-Vice Chancellor of Manipal University, India Prof Datuk Dr Razzak, Dean of Faculty of Medicine, MMMC Prof Jaspal, Deputy Dean Academic, Faculty of Medicine, MMMC Prof Adinegara in writing this chapter.


6. References

- Denis F et al. Microbiological efficacy of 3-day treatment with azithromycin 1.5% eye-drops for purulent bacterial conjunctivitis. *Eur J Ophthalmol*. 2008 Nov-Dec , Vol.18,No.6, 858-68.
- Elfath m elnifro & robert j cooper. Diagnosis of viral and chlamydial keratoconjunctivitis: which laboratory test? *Br J Ophthalmol*, 1999, Vol.83, 622-627.
- Everitt HA et al. Randomised controlled trial of management strategies for acute infective conjunctivitis in general practice. *BMJ*, 2006, 333-321.
- Featherstone PI et al. General practitioners' confidence in diagnosing and managing eye conditions: a survey in south Devon. *Br J Gen Pract*, 1992 January , Vol.42,No.354, 21-24.
- Friedlaender MH and Protzko E. Clinical development of 1% azithromycin in DuraSite®, a topical azalide anti-infective for ocular surface therapy. *Clin Ophthalmol*, 2007 March, Vol.1,No.1, 3-10.
- Granet DB et al. A Multicenter Comparison of Polymyxin B Sulfate/Trimethoprim Ophthalmic Solution and Moxifloxacin in the Speed of Clinical Efficacy for the Treatment of Bacterial Conjunctivitis. *J of Ped Oph and Stabismus*, 2008, Vol.45, No.6, 340-49.
- Isabelle C et al. 3-day treatment with azithromycin 1.5% eye drops versus 7-day treatment with tobramycin 0.3% for purulent bacterial conjunctivitis: multicentre, randomised and controlled trial in adults and children. *Br J Ophthalmol*, 2007, Vol. 91, 465-469.
- Jackson WB. Differentiating conjunctivitis of diverse origins. *Surv Ophthalmol.*, 1993 Jul-Aug, Vol.38, Suppl, 91-104.
- Leonard Bielory; Kenneth W. Lien; Steve Bigelsen. Efficacy and Tolerability of Newer Antihistamines in the Treatment of Allergic Conjunctivitis. *Drugs*, 2005 , Vol. 65, No. 2, 215-228.
- Michael ET et al. Phase III efficacy and safety study of besifloxacin ophthalmic suspension 0.6% in the treatment of bacterial conjunctivitis. *Informa Healthcare*, May 2009, Vol. 25, No. 5 , 1159-1169.
- Mark S et al. The pharmacodynamic of azithromycin in a kinetics-of-kill model and implications for bacterial conjunctivitis treatment.. *Advances in Therapy*, 2008, Vol. 25, No.3, 208-17.
- Ozcan, Altan A MD; Ersoz, T Reha MD; Dulger, Erol MD. Management of Severe Allergic Conjunctivitis With Topical Cyclosporin A 0.05% Eyedrops. *Cornea*, October 2007, Vol. 26, No. 9 , 1035-1038.
- Papa V et al. Treatment of Acute Bacterial Conjunctivitis With Topical Netilmicin *Cornea*, 2002, Vol.21, No.1, 43-47.
- Rose P. Management strategies for acute infective conjunctivitis in primary care: a systematic review. *Informa health care*, 2007, Vol.12,No.8, 1903-1921.

- Santa JO, Mark BA. Allergic conjunctivitis: updates on patho-physiology and prospects for future treatment. *J Allergy & Clin Immunology*, 2005, Vol.115, 118-122.
- Sheikh A, Hurwitz B. Antibiotics versus placebo for acute bacterial conjunctivitis. *Cochrane Database Syst Rev.*, 2006 Apr, Vol.19, No.2,
- Sherwin JI et al. A controlled trial of povidone-iodine to treat infectious conjunctivitis in children. *Am J Oph*, 2002, Vol.134, No.5, 681-88.

IntechOpen

IntechOpen



Conjunctivitis - A Complex and Multifaceted Disorder

Edited by Prof. Zdenek Pelikan

ISBN 978-953-307-750-5

Hard cover, 232 pages

Publisher InTech

Published online 23, November, 2011

Published in print edition November, 2011

This book presents a number of interesting and useful aspects and facets concerning the clinical features, properties and therapeutical management of this condition. Dr. H. Mejía-López et al. present an interesting survey of the world-wide epidemiologic aspects of infectious conjunctivitis. Dr. U. Ubani evaluates conjunctival symptoms/signs participating in the clinical features of this disorder. Dr. A. Robles-Contreras et al. discuss immunologic aspects underlying possibly the conjunctivitis. Dr. Z. Pelikan presents the cytologic and concentration changes of some mediators and cytokines in the tears accompanying the secondary conjunctival response induced by the nasal challenge with allergen. Dr. S. Sahoo et al. summarize the treatment and pharmacologic control of particular clinical forms of conjunctivitis in general practice. Dr. S. Leonardi et al. explain the basic pharmacologic effects of leukotriene antagonists and their use for the treatment of allergic conjunctivitis. Dr. J.A. Capriotti et al. evaluate the therapeutical effects of various anti-adenoviral agents on the acute conjunctivitis caused by adenovirus. Dr. V. Vanzzini-Zago et al. assess the prophylactic use and efficacy of "povidone-iodium solution", prior the ocular surgery. Dr. F. Abazi et al. present the clinical features, diagnostic and therapeutical aspects of "neonatal conjunctivitis". Dr. I.A. Chaudhry et al. review the special sub-form of conjunctivitis, being a part of the "Trachoma". Dr. B. Kwiatkowska and Dr. M. Maślińska describe the clinical, pathophysiologic and immunologic features of conjunctivitis. Dr. S. Naem reviews the conjunctivitis form caused by *Thelazia* nematodes, occurring principally in animals.

How to reference

In order to correctly reference this scholarly work, feel free to copy and paste the following:

Soumendra Sahoo, Adnaan Haq, Rashmirekha Sahoo and Indramani Sahoo (2011). Management of Conjunctivitis in General Practice, *Conjunctivitis - A Complex and Multifaceted Disorder*, Prof. Zdenek Pelikan (Ed.), ISBN: 978-953-307-750-5, InTech, Available from: <http://www.intechopen.com/books/conjunctivitis-a-complex-and-multifaceted-disorder/management-of-conjunctivitis-in-general-practice>

INTECH
open science | open minds

InTech Europe

University Campus STeP Ri
Slavka Krautzeka 83/A
51000 Rijeka, Croatia
Phone: +385 (51) 770 447

InTech China

Unit 405, Office Block, Hotel Equatorial Shanghai
No.65, Yan An Road (West), Shanghai, 200040, China
中国上海市延安西路65号上海国际贵都大饭店办公楼405单元
Phone: +86-21-62489820

www.intechopen.com

Fax: +385 (51) 686 166
www.intechopen.com

Fax: +86-21-62489821

IntechOpen

IntechOpen

© 2011 The Author(s). Licensee IntechOpen. This is an open access article distributed under the terms of the [Creative Commons Attribution 3.0 License](https://creativecommons.org/licenses/by/3.0/), which permits unrestricted use, distribution, and reproduction in any medium, provided the original work is properly cited.

IntechOpen

IntechOpen