

We are IntechOpen, the world's leading publisher of Open Access books Built by scientists, for scientists

6,900

Open access books available

186,000

International authors and editors

200M

Downloads

Our authors are among the

154

Countries delivered to

TOP 1%

most cited scientists

12.2%

Contributors from top 500 universities



WEB OF SCIENCE™

Selection of our books indexed in the Book Citation Index
in Web of Science™ Core Collection (BKCI)

Interested in publishing with us?
Contact book.department@intechopen.com

Numbers displayed above are based on latest data collected.
For more information visit www.intechopen.com



Unicuspid Aortic Valve

Venkata Thota and Farouk Mookadam
Mayo Clinic College of Medicine, Scottsdale, AZ
 USA

1. Introduction

Unicuspid aortic valve was first described more than half a century ago (Edwards, 1958). Although reported infrequently, the natural history of unicuspid aortic valve is poorly understood. Developmental abnormalities of aortic valve cusps in decreasing order of frequency include bicuspid (0.9%-1.3%), unicuspid (0.02%), quadricuspid (0.008%- 0.043%), and pentacupsid aortic valves (Cemri, 2000). Decreasing cusp number in the congenitally abnormal aortic valve has shown increasing male predilection, earlier valve failure and aggressive pathological changes compared to normal tricuspid aortic valve (Collins MJ, 2008).

2. Embryology

The normal aortic valve consists of three valve cusps, sinuses and coaptations (Angelini, 1989). During the embryological development, the bulbous cordis elongates and forms the proximal conus and distal truncus arteriosus. This initial single channel bifurcates into two separate trunks, namely, the aortic and pulmonary trunks by two spiral truncoconal ridges, derived from neural crest mesoderm. Simultaneous to this, cardiac mesoderm and cranial neural crest derivatives grow into the two separate lumens forming 3 leaflets for each trunk. These three leaflet structures will constitute the future aortic and pulmonary valves (Carlson, 1999). Abnormalities in the growth of this mesoderm into the lumen to form leaflets are believed to result congenital aortic valvular abnormalities. During the same time, out of the many buds which arise from the coronary sinuses of the aorta, generally only two buds establish a connection with the epicardial tree to form future coronary arteries. These developmental spatial associations can explain the frequent concurrence of abnormalities between the aortic valve and coronary arteries.

Two sub-types of UAV have been described. One is the pinhole shaped acommisural UAV and the second being the slit shaped unicommissural UAV. While the pinhole-shaped UAV presents early in infancy with severe aortic stenosis, the slit-shaped UAV presents relatively later in adults with a less aggressive course. Theoretically, if the leaflet mesoderm grows in circumferentially from annulus it results in pin-hole shaped UAV and if it grows in with two coaptation points, it results in the slit-shaped unicommissural UAV. (Fig. 1)

The association of UAV with various coronary artery anomalies, patent ductus arteriosus, aortic aneurysms and coarctation of aorta suggests a common abnormal embryological development. Temporal association of the aortic leaflet evolution with coronary artery development from sinuses of valsalva implies similar embryological derangements.

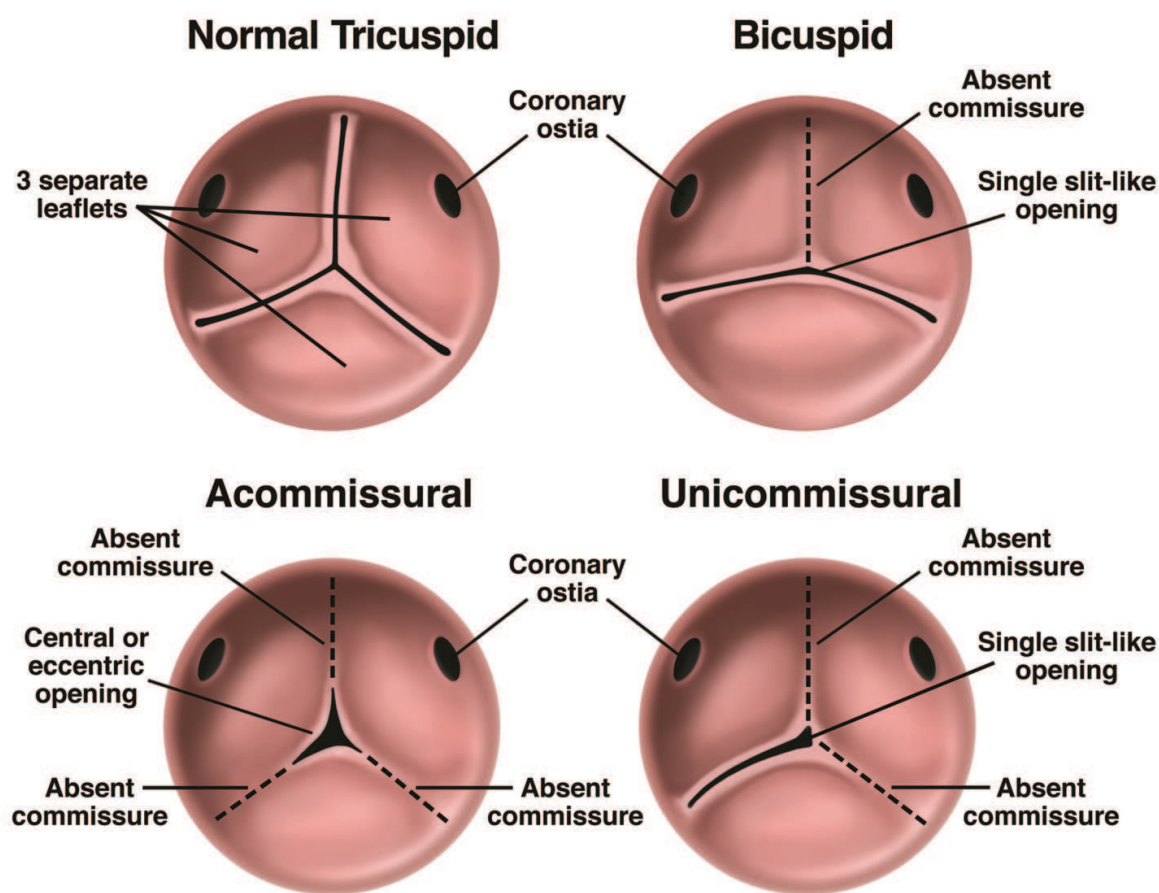


Fig. 1. Slit-shaped and pinhole shaped unicuspid aortic valves

Dilatation or aneurysm of aortic annulus/aortic root/ascending aorta
Patent ductus arteriosus
Coarctation of aorta
Aortic dissection
Anomalous coronary artery
Ventricular septal defect
Mycotic aneurysm of aorta

Table 1. Associated anomalies/complications of unicuspid aortic valve (Mookadam, 2010a and 2010b)

3. Epidemiology

While the more common bicuspid aortic valve has an incidence of 0.9-1.36% among the general population compared to unicuspid aortic valve which is about 50 fold less common with an incidence of 0.02% (Lewin, 2005; Mookadam, 2010a). Unicuspid aortic valve is more common in males with gender ratio of 4:1 in males:females (Mookadam, 2010a). It is relatively uncommon in adults when compared to neonates. Although an autosomal dominant pattern of inheritance with incomplete penetrance has been suggested for BAV, no familial cases of UAV have been reported in the literature to date.

4. Clinical presentation

The presenting features and associated anomalies/complications of UAV differ significantly in children as compared to adults.

	Pediatric Age<15yrs	Adult >15yrs
Mean age	14 months	42 years
Symptoms	Left heart failure, failure to thrive	Dyspnea,angina, syncope
Aortic stenosis	Common	Common
Aortic regurgitation	Uncommon	Fairly common
Aortic dilation	Very rare	Common
Coarctation of Aorta	Common	Rare
Ventricular septal defect	Common	Rare
Patent ductus arteriosus	Infrequent	Rare

Table 2. Clinical presentation of adult UAV and pediatric UAV

In the pediatric age group, the most common presentation included symptoms of left heart failure secondary to aortic stenosis. Pin hole shaped UAV is generally associated with a severe degree of stenosis compared to unicommissural UAV and tends to be symptomatic early in life. In the adults, reported symptoms in descending order of frequency include dyspnea, angina, dizziness and syncope. Most common aortic valve lesion included isolated aortic stenosis followed by combined AS with AR and isolated AR.

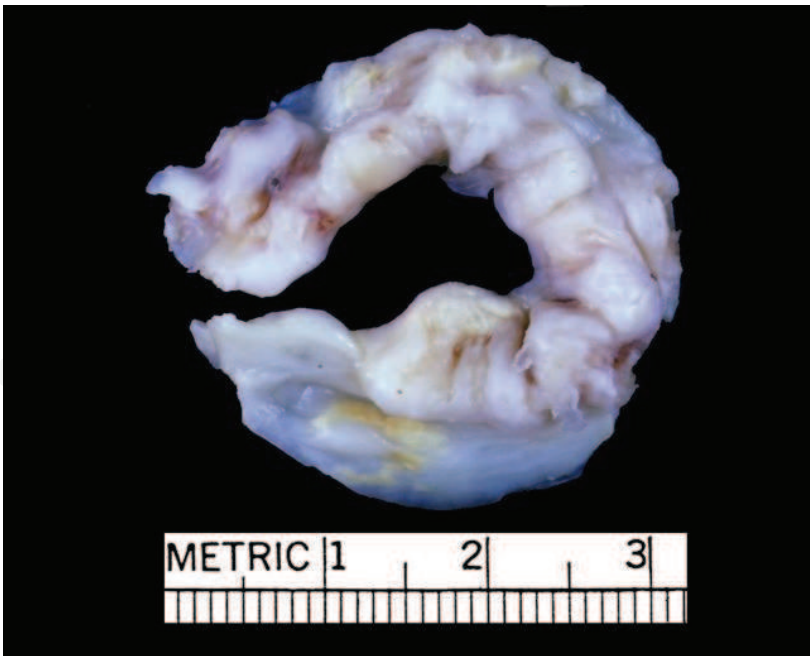

Fig. 2. Unicommissural AS-AI (1984, 2-630-422, Sawley 39F)

Associated anomalies in children included most commonly coarctation of aorta followed by ventricular septal defect and patent ductus arteriosus. However in adults, aortic aneurysm/dilatation was most common finding followed by aortic dissection, aortic mycotic aneurysm, coronary artery anomalies and ventricular septal defect.

UAV is more frequent among patients presenting to surgery with AS; approximately about 5% of patients presenting to surgery for pure AS will have UAV.

In adults, pathology of resected UAVs is characterized by heavy calcification implying early degeneration from hemodynamic stress. However, calcification is a very rare phenomenon in the pediatric age group. An important clinical implication of calcific UAV is the presence of calcification that extends into the interventricular septum, with possible damage to the conduction system during debridement at the time of surgery in preparation for replacement of the aortic valve.

5. UAV and aortopathy

Aortopathy is an important associated complication of UAV. Also a bimodal distribution of UAV has been described in the literature older UAV patients presenting without any pathological aortic dilatation and younger UAV patients with aggressive form of pathological aortic dilatation (Agnihotri, 2006). The UAV is also associated with pathological aortic dilatation over time which is thought to be secondary to hemodynamic stress and congenitally inherited weakness of aortic media. This congenitally inherited weakness in BAV is believed to be secondary to apoptosis of neural crest derivatives thereby predisposing to premature cystic medial necrosis. It is not known whether UAV shares similar pathological features of BAV. Aortic dissection also occurs at an increased rate in UAV patients compared to general population. And whenever it occurs, aortic dissection also presents at an earlier age in UAV patients compared to BAV and TAV.

6. Diagnosis

Clinically patients present with the usual and expected symptoms of syncope, chest pain, dyspnea and heart failure. As with any other etiology of aortic stenosis, however the age at presentation should alert the clinician as to the likely etiology as being unicuspid or bicuspid. Furthermore the aortopathy implies either unicuspid or bicuspid abnormalities of the aortic valve. The presence of associated congenital heart abnormalities would suggest a commissural unicuspid aortic valve especially in the very young. Auscultation is significant for a third heart sound, systolic and diastolic murmurs depending on the predominant lesion. With at least moderate AS and concomitant moderate or higher degree of AR, the murmur may be confused for a coronocaval fistula, the machinery like murmur of PDA or mixed valve diseases. This difficulty can be reflected from the fact that approximately 60% of the adult UAV cases are diagnosed at autopsy/surgical resection, while only 20% are diagnosed by TTE and TEE. (Mookadam 2010a)

Trans-thoracic echocardiographic imaging remains the most common modality deployed for diagnosing UAVs preoperatively. Echocardiographic imaging allows satisfactory assessment of valve morphology, valve orifice, annular attachment zone and severity of aortic stenosis and regurgitation.

In addition the ascending aorta, left ventricular changes in response to the hemodynamic load, other valvular structures and associated congenital anomalies (Table 2), can be identified. Other ancillary modalities including transesophageal echocardiography (TEE), real time 3-Dimensional echocardiographic imaging, cardiac computed tomography (CT) and magnetic resonance imaging (MRI) can also be used for better evaluation. All these ancillary imaging modalities have the capability to diagnose and identify preoperatively any associated anomalies.

Given the association, early progression and aggressive presentation between aortopathy and UAV, it is prudent to follow these patients regularly for timely intervention.

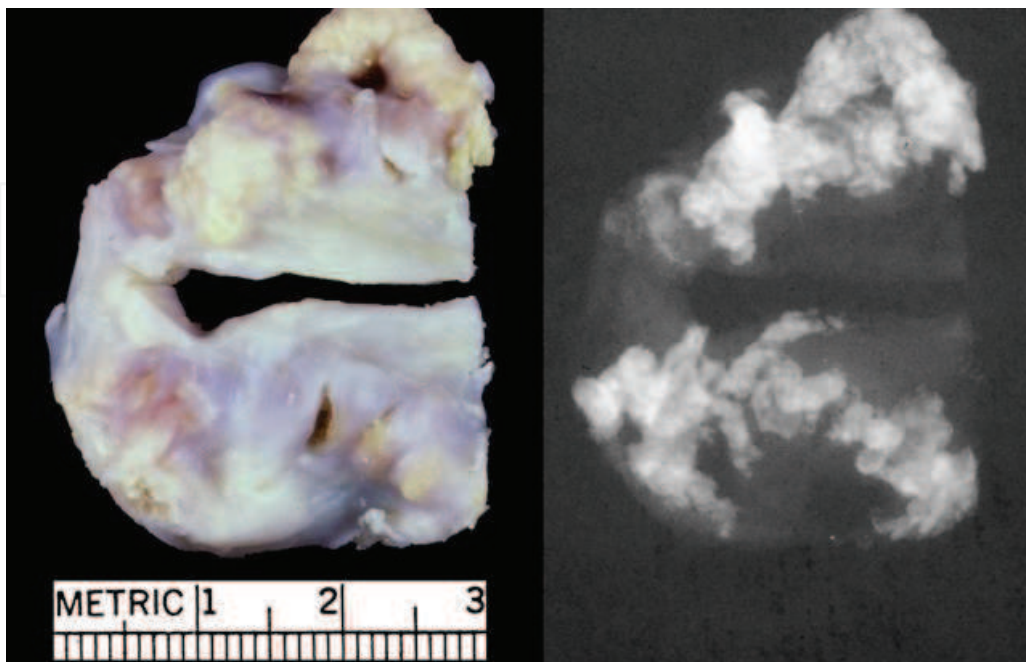


Fig. 3. Unicommissural AS (1983, 2-283-534, Eaton 42M), with x-ray

7. Management

The treatment approach differs significantly between adults and children. In children, treatment choices included aortic balloon valvoplasty, surgical valvotomy, and commissurotomy (Mookadam, 2010b). Repair of the aortic coarctation is also frequent among children, which was the most common associated anomaly. However, replacement of aortic root is uncommon in the pediatric age group.

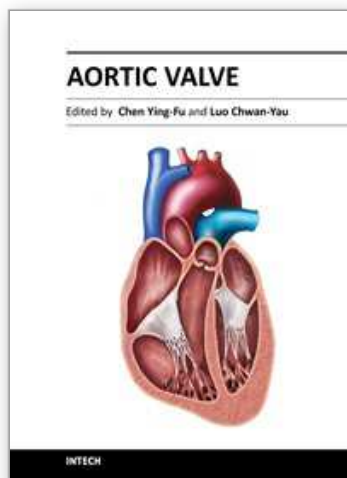
In adults, most common treatment modality was aortic valve replacement associated with replacement of aortic annulus/aortic root/ascending aorta. Other treatment modalities included bicuspidization of UAV, Bentall's operation, aortic valvotomy and Ross procedure. Also in UAV, aortic valve replacement (AVR) was about 10-20 years earlier than BAV, and 20-30 years earlier than normal TAV. The current management approach of UAV is to follow valve sparing techniques in children and delaying AVR to allow aorta to grow to adult size.

8. References

- Agnihotri AK, Desai SC, Lai YQ, et al. Two distinct clinical presentations in adult unicuspid aortic valve. *J Thorac Cardiovasc Surg* 2006; 131:1169-1170
- Angelini A, Ho SY, Anderson RH, et al. The morphology of the normal aortic valve as compared with the aortic valve having two leaflets. *J Thorac Cardiovasc Surg* 1989; 98:362-367
- Carlson BM. *Human Embryology and Developmental Biology*. 2nd edition. St. Louis, MO: Mosby, 1999; pp. 422-424. ISBN-10: 0815114583

- Cemri M, Cengel A, Timurkaynak T. Pentacuspid aortic valve diagnosed by transoesophageal echocardiography. *Heart* 2000; 84:E9
- Collins MJ, Butany J, Borger MA, Strauss BH, David TE. Implications of a congenitally abnormal valve: a study of 1025 consecutively excised aortic valves. *J Clin Pathol.* 2008 Apr; 61(4):530-6
- Edwards JE. Pathologic aspects of cardiac valvular insufficiencies. *AMA Arch Surg* 1958; 77:634-649
- Lewin MB, Otto CM. The bicuspid aortic valve: Adverse outcomes from infancy to old age. *Circulation* 2005; 111:832-834
- Mookadam F, Thota VR, Garcia-Lopez AM, et al. Unicuspid aortic valve in adults: A systematic review. *J Heart Valve Dis* 2010; 19:79-85
- Mookadam F, Thota VR, Garcia-Lopez AM, et al. Unicuspid aortic valve in children: A systematic review spanning four decades. *J Heart Valve Dis* 2010; 19:678-683.

IntechOpen



Aortic Valve

Edited by Prof. Chen Ying-Fu

ISBN 978-953-307-561-7

Hard cover, 350 pages

Publisher InTech

Published online 09, December, 2011

Published in print edition December, 2011

Much has evolved in the field of aortic valve disease because of the increase in knowledge in the last decade, especially in the area of its management. This book "Aortic Valve" is comprised of 18 chapters covering basic science, general consideration of aortic valve disease, infective endocarditis, aortic sclerosis and aortic stenosis, bioprosthetic valve, transcatheter aortic valve implantation and a special section on congenital anomalies of the aortic valve. We hope this book will be particularly useful to cardiologists and cardiovascular surgeons and trainees. We also believe that this book will be a valuable resource for radiologists, pathologists, cardiovascular anesthesiologists, and other healthcare professionals who have a special interest in treating patients with aortic valve disease. We are certain that information in this book will help to provide virtually most new areas of aortic valve disease that will be employed in the current era.

How to reference

In order to correctly reference this scholarly work, feel free to copy and paste the following:

Venkata Thota and Farouk Mookadam (2011). Unicuspid Aortic Valve, Aortic Valve, Prof. Chen Ying-Fu (Ed.), ISBN: 978-953-307-561-7, InTech, Available from: <http://www.intechopen.com/books/aortic-valve/unicuspid-aortic-valve>

INTech
open science | open minds

InTech Europe

University Campus STeP Ri
Slavka Krautzeka 83/A
51000 Rijeka, Croatia
Phone: +385 (51) 770 447
Fax: +385 (51) 686 166
www.intechopen.com

InTech China

Unit 405, Office Block, Hotel Equatorial Shanghai
No.65, Yan An Road (West), Shanghai, 200040, China
中国上海市延安西路65号上海国际贵都大饭店办公楼405单元
Phone: +86-21-62489820
Fax: +86-21-62489821

© 2011 The Author(s). Licensee IntechOpen. This is an open access article distributed under the terms of the [Creative Commons Attribution 3.0 License](https://creativecommons.org/licenses/by/3.0/), which permits unrestricted use, distribution, and reproduction in any medium, provided the original work is properly cited.

IntechOpen

IntechOpen