

We are IntechOpen, the world's leading publisher of Open Access books Built by scientists, for scientists

6,900

Open access books available

186,000

International authors and editors

200M

Downloads

Our authors are among the

154

Countries delivered to

TOP 1%

most cited scientists

12.2%

Contributors from top 500 universities



WEB OF SCIENCE™

Selection of our books indexed in the Book Citation Index
in Web of Science™ Core Collection (BKCI)

Interested in publishing with us?
Contact book.department@intechopen.com

Numbers displayed above are based on latest data collected.
For more information visit www.intechopen.com



The Progression of Aortic Sclerosis to Aortic Stenosis

Uzma Jalal Serageldin Raslan and Farouk Mookadam
Department of Cardiovascular Diseases, Mayo Clinic, Scottsdale, AZ, USA

1. Introduction

Aortic stenosis is the most frequent valvular heart disease in the western world and its incidence continues to rise. Until recently, aortic valve sclerosis (AVS) was considered to be a normal degenerative process associated with aging. For this reason, the common and well recognized soft, basal ejection murmur of aortic sclerosis was generally regarded by physicians to be of little or no clinical significance. In the last decade, AVS has been the focus of both clinical and animal research. AVS has emerged as a biomarker for cardiovascular risk, and ultimately leads to aortic stenosis in 16% of adults (Stewart et al., 1997; Cosmi et al., 2002).

Calcific aortic valve disease ranges from aortic sclerosis, defined as focal, irregular thickening of aortic valve leaflets with no hemodynamically significant derangement (i.e., peak velocity of ≤ 2 m/s and no significant aortic regurgitation), to severe calcification (with impaired leaflet motion and an aortic jet velocity of ≥ 2.5 m/s) referred to as aortic stenosis. The paradigm of aortic stenosis has shifted from being considered a degenerative aging process; it is now recognized as a dynamic inflammatory process with features similar to atherosclerotic plaque. These features include endothelial disruption, focal deposition of low density lipoprotein (LDL) cholesterol and lipoprotein A, accumulation of macrophages and T lymphocytes, and calcification (Freeman et al., 2004).

2. Epidemiology and etiology

Aortic valve sclerosis is present in approximately 25% of people 65 to 74 years old and in 50 % of people over 84 years (Lindroos et al., 1993; Stewart et al., 1997; Otto et al., 1999), while aortic stenosis affects 2% of the population over 65 years old, 3 % over 75 years old, and 4% over 85 years old (Stewart, 1997). The severity of aortic sclerosis on a scale of 0-3 has been quantified by echocardiography for echogenicity, thickening, or calcification of the valve leaflet as follows (Chandra et al., 2004):

- 0- Normal (No involvement)
- 1- Mild (Minor involvement of one leaflet)
- 2- Moderate (Minor involvement of two leaflets or extensive involvement of one leaflet)
- 3- Severe (Extensive involvement of two leaflets or involvement of all three leaflets)

In adults, valvular aortic stenosis is due to degenerative calcific changes of a trileaflet valve, rheumatic disease, or secondary calcification of a congenitally bicuspid valve (Roberts, 1970; Selzer, 1987). In developed countries, the most common cause of adult acquired aortic

stenosis at present is a chronic inflammatory and fibrotic process of the aortic valve very similar to atherosclerosis. Histologically, the valve consists of 3 layers: [1] the ventricularis (on the ventricular side of the leaflet), composed of elastin rich fibers; [2] the fibrosa (on the aortic side of leaflet), composed of fibroblasts and collagen fibres; and [3] the spongiosa (at the base of leaflet, between the fibrosa and ventricularis), a layer of loose connective tissue composed of fibroblasts, mesenchymal cells, and mucopolysaccharide- rich matrix. Progressive fibrosis and calcification can occur on a bileaflet or a trileaflet valve; it occurs earlier in life in the bicuspid valve. The most common cause of aortic stenosis in patients 65 years old and over is called "senile calcific aortic stenosis". With aging, the protein collagen of the valve leaflets is destroyed, and calcium is deposited on the leaflets. Turbulence across the valve increases, which causes scarring, thickening, and stenosis of the valve once valve leaflet mobility is reduced by calcification.

Rheumatic fever is the cause of aortic stenosis in developing countries. Rheumatic involvement of the aortic valve is characterized by commissural fusion between the aortic valve leaflets. When rheumatic fever is the cause of aortic stenosis, the mitral valve is also affected in most patients (Campbell, 1968).

3. Clinical presentation

The classic triad of symptoms in significant aortic stenosis is angina, syncope, and dyspnea, all of which typically occur with exertion. Occasionally, gastrointestinal bleeding occurs secondary to arteriovenous malformations, platelet dysfunction, and defective coagulation in what is termed as Heyde syndrome (Zigelman et al., 2009; Batur et al., 2003; Sucker, 2007). In older adults, symptoms are often delayed due to an age- associated decrease in activity, and symptom are attributed to other conditions common in the elderly; therefore, special attention should be focused on the elicitation of symptoms.

Angina is the first symptom in one-third of the patients, and it eventually occurs in one-half of patients with aortic stenosis. It is due to a supply and demand mismatch caused by a combination of left ventricular hypertrophy, increased afterload, increased wall strain, and excessive compression of the coronary arteries. Syncope related to aortic stenosis is usually associated with exertion or excitement. These conditions cause vasodilation and lowering of blood pressure. In aortic stenosis, the heart is unable to increase cardiac output due to fixed left ventricular outflow tract (LVOT) obstruction, and is unable to compensate for the drop in blood pressure. This results in decreased cerebral perfusion, thereby causing syncope. Dyspnea is a late- presenting symptom of severe aortic stenosis caused by failure of the left ventricle to compensate for the outflow obstruction.

On physical examination, the hallmark of aortic stenosis is a late peaking crescendo-decrescendo systolic murmur. It is best heard at the upper- right or left- sterna border, radiating to the carotids. Older adults exhibit certain variations of this characteristic pattern. The occurrence of heart failure and chronic lung disease common in this population results in a significant reduction in the intensity of the murmur, while pure aortic sclerosis without stenosis may present with an apical systolic high- pitched murmur (Gallavardin phenomenon) (Hage et al., 2011).

4. Risk factors

Several lines of evidence suggest that, in addition to the pathophysiological similarities to atherosclerosis, aortic stenosis and coronary disease share many risk factors, such as male

gender, older age group, tobacco use, diabetes mellitus, hypercholesterolemia, hypertension, hyperparathyroidism, renal disease, decreased bone density, and metabolic syndrome (Figure 1). Increased C-reactive protein (CRP) as a risk factor for aortic stenosis is controversial. Reports from a few studies show a positive association between aortic stenosis and increased CRP; however, a recent prospective trial (Novaro et al., 2007) involving 5621 subjects followed over a period of 5 years, and using echocardiography and CRP measurements, showed that there was no association between CRP and the development of aortic stenosis. In addition, being Caucasian and short in stature were found to have a positive association with development of aortic stenosis.

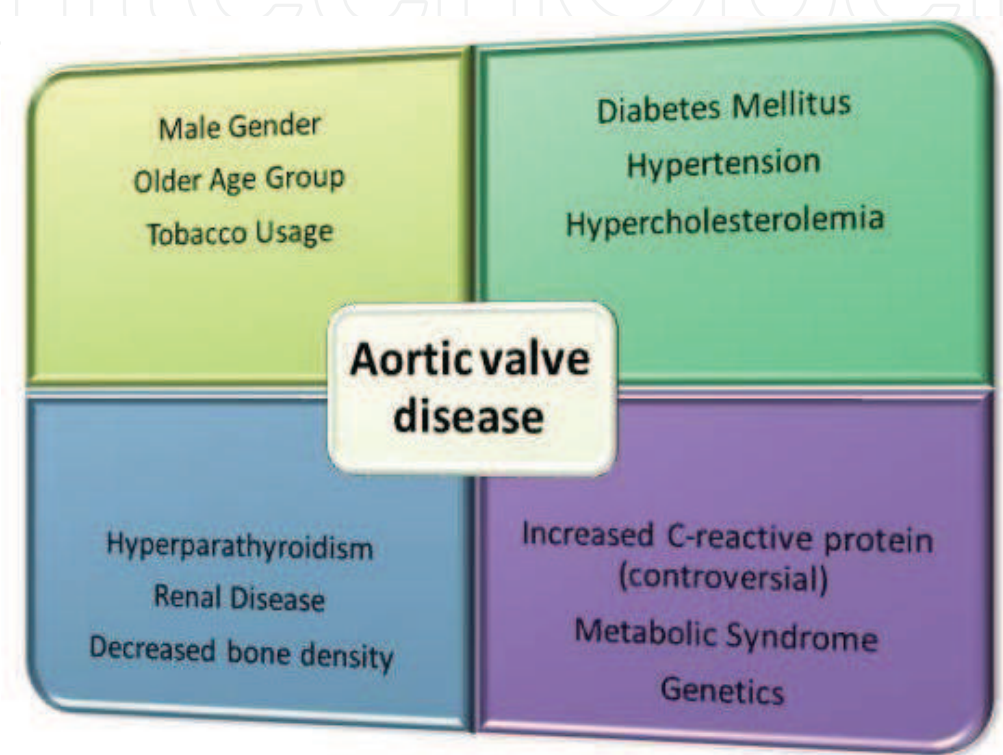


Fig. 1. Schematic view of risk factors involved in aortic valve disease

5. Pathogenesis

5.1 Early lesion

The early sclerotic lesion shows focal subendothelial plaque like lesions on the aortic surface of the leaflet that extends into the adjacent fibrosa layer. The initiating factor for these lesions is the endothelial disruption due to increased mechanical or decreased shear stress. The Mechanical stress of the aortic valve is highest on the aortic side of the leaflet in the flexion area. These lesions show similarities to atherosclerosis, with a prominent accumulation of atherogenic lipoproteins, low density lipoprotein (LDL) oxidation, inflammatory cell infiltrate, and microcalcification (O'Brien et al., 1996; Olsson et al., 1999; Otto et al., 1994).

5.2 Inflammation and lipoproteins

Over the course of time, mechanical stress leads to endothelial dysfunction, which is then perpetuated by inflammatory cell infiltrate consisting of both T-lymphocytes and macrophages. Monocytes infiltrate the endothelium and differentiate into macrophages via

adhesion molecules (Ghaisas et al., 2000). After infiltrating into the endothelium, these inflammatory cells upregulate inflammatory cytokines, transforming growth factor, and interleukin, all of which act on valvular fibroblasts and promote cellular proliferation, extracellular matrix remodeling, and local calcification. Focal, extracellular lipid accumulation is seen within each valve leaflet, in small areas in the subendothelial region, with displacement of elastic lamina and extension into adjacent fibrosa (Otto et al., 1994). LDL that is taken into the subendothelial layer undergoes oxidative modification and subsequent macrophage ingestion to become foam cells. Studies have shown that aortic stenosis is associated with high levels of plasma asymmetric dimethylarginine, a marker of endothelial dysfunction (Ngo et al., 2007) and that nitric oxide (NO) is involved in inhibiting valve calcification (Kennedy et al., 2009). Aortic sclerosis has been associated with NO resistance in platelets, which explains the thrombotic risk in patients with aortic sclerosis (Ngo et al., 2009).

5.3 Angiotensin converting enzyme and extracellular matrix

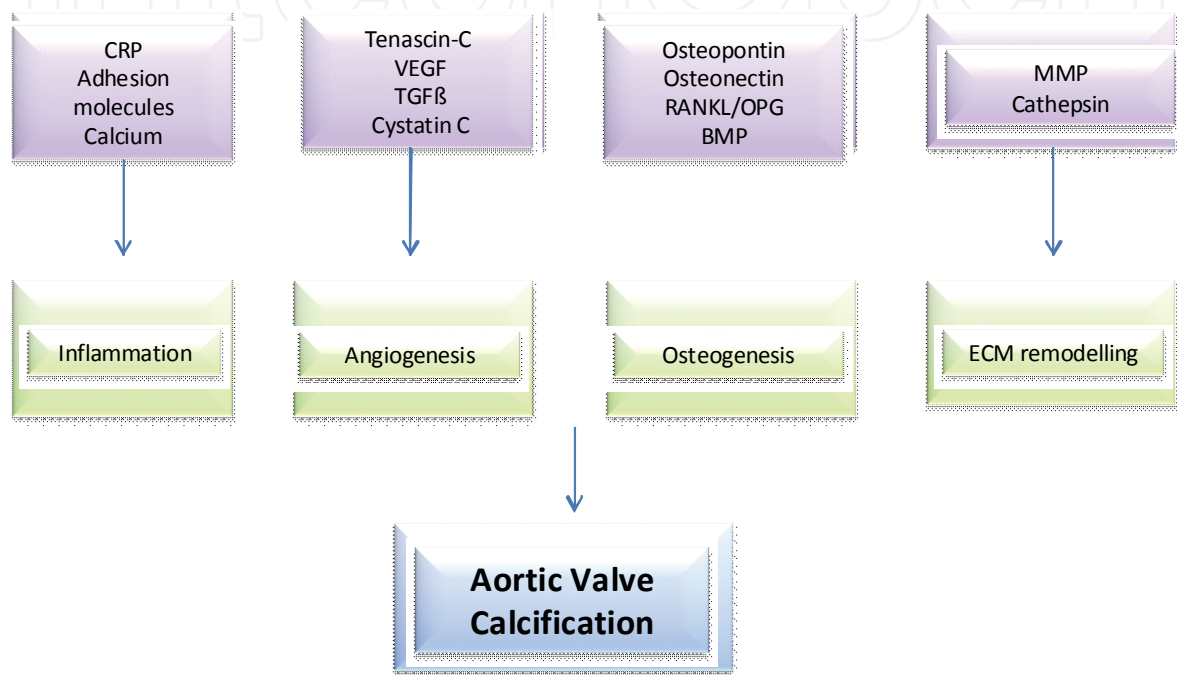
Angiotensin converting enzyme (ACE) has been identified in aortic sclerotic lesions (O'Brien et al., 2002). There is evidence that the majority of this enzyme is extracellular and co-localized with apolipoprotein B, even though some of it may be locally produced. The aortic valve is exposed to pulsatile repetitive pressure and shear stress during systole, whereas cyclical stretch and turbulent shear stress occur during diastole. These are transmitted to valve interstitial cells (VICs) by endothelial cells and the matrix (Sacks et al., 2007), which results in cell proliferation, increased collagen deposition, apoptosis, and enhanced cathepsin S and K expression. Furthermore, increased cyclic stretch increases the expression and activity of matrix metalloproteinase (MMP)-1, 2, and 9, whereas it reduces the expression as well as the activity of cathepsin L and tissue inhibitor of metalloproteinase-1 (TIMP-1) (Balachandran et al., 2009). In patients with aortic stenosis and coronary artery disease, an increase in soluble vascular cell adhesion molecule-1 (VCAM-1) occurs along with a decrease in soluble intercellular adhesion molecule-1 (ICAM-1) and s-E selectin (Linhartova et al., 2009). Increased expression of elastolytic cathepsins S, K, and V and their inhibitor cystatin C is also observed (Helske et al., 2006). The association of calcific aortic valve disease and increase in endothelin-1 and endothelin A receptor support the evidence of inflammation and fibrosis in aortic calcific disease (Peltonen et al., 2009).

5.4 Angiogenesis and osteogenesis

As the disease progresses, active bone formation is seen. Angiogenesis is predominant in the pathogenesis of aortic stenosis and is the hallmark for longitudinal bone growth. Angiogenetic factors such as vascular endothelial growth factor (VEGF) have been shown to be necessary for enchondral bone formation in calcified valves (Gerber et al., 1999). The lipids and inflammatory cells localize within the microscopic calcific areas, which results in macrophage-derived osteopontin, a key element in tissue calcification (Abdel-Azeez et al., 2010). Synthesis of bone sialoprotein, tenascin C and extracellular matrix proteins also ensues (Kaden et al., 2003; Satta et al., 2002; Kaden et al., 2004). There is evidence that native aortic valve disease involves mediators of bone homeostasis like osteoprotegerin (OPG), receptor activator of nuclear factor κ B (RANK), and receptor activator of nuclear factor κ B ligand (RANKL), and that OPG/RANKL ratio was less in stenotic than in sclerotic valves (Steinmetz et al., 2008).

5.5 Genetics

Genetic factors may be important in the development of aortic valve calcification. Genetic polymorphism of interleukin 10, connective tissue growth factor, chemokine receptor 5, apoprotein polymorphism, and estrogen receptors have been shown to influence valvular calcification (Ortlepp et al., 2004). In addition, the B allele of vitamin D receptor has an association with aortic valve stenosis, which confirms the abnormal bone signaling pathway in the pathogenesis of the disease (Ortlepp et al., 2001). Another finding that implies the role of genetics in aortic valve disease is the loss of function mutation of Notch 1 receptor in patients with aortic stenosis (Garg et al., 2005).



CRP: C-reactive protein; VEGF: Vascular endothelial growth factor; TGF: Transforming growth factor; RANKL: Receptor activator of nuclear factor κ B ligand; OPG: Osteoprotegerin; BMP: Bone morphogenetic protein; MMP: Matrix Metalloproteinase

Fig. 2. Schematic view of mediators in pathogenesis of aortic valve calcification

6. Animal models

Several elegant animal studies have advanced the pathogenetic understanding of aortic valve disease. Rajamannan et al. (2001) compared the aortic valves in rabbits fed on a high cholesterol diet to those fed on a standard diet. The microscopy of the hypercholesterolemia rabbits demonstrated a cholesterol infiltrative pattern along with low- grade apoptosis, neither of which was seen in the control rabbits. Furthermore, Rajamannan et al. (2005a) showed that aortic valves from hypercholesterolemic rabbits had evidence of atherosclerotic streaks, increased CRP, early calcification, and minor levels of nitric oxide synthase (eNOS) compared with controls. The rabbits treated with atorvastatin had less lipid accumulation and higher levels of eNOS. More recently (Rajamannan et al., 2005b), aortic valve calcification was shown to be similar to osteogenesis with a similar spectroscopic appearance and bone matrix markers (osteopontin, bone sialoprotein, osteocalcin) with increase in low-density receptor- related protein (Lrp5) using models fed on a cholesterol

Authur (Year)	Population(N)/ Age (Years)	Outcome Measures	Conclusion
Ngo et al. (2009)	n=253; 51-77	Transthoracic Echo, AVBS score	Association of platelet NO resistance with aortic sclerosis
Linhartova et al. (2009)	n=223;	Coronary angiography, Echo	Association of aortic stenosis with s-VCAM1 in CAD pts
Peltonen et al. (2009)	n=36; 58± 6	Immunohistochemistry, RT-PCR	Upregulation of ET1 & ETA receptor in aortic stenosis
Abdel-Azeez et al. (2010)	n=120	OPN & hsCRP measurement, coronary angio, Echo, lipid profile	OPN is an independent factor of aortic sclerosis
Steinmetz et al. (2008)	n=69	Immunostaining, Morphometry	OPG/RANKL/RANK system is involved in aortic valve calcification
Ortlepp et al. (2001)	n=200	Restricted fragment length polymorphism, PCR	Association of aortic stenosis with Vitamin D receptor genotype
Garg et al. (2005)	n=14	DNA collection, luciferase assay, PCR, Phenotypic evaluation, Genetic linkage analysis	NOTCH 1 mutation causes early defect in aortic valve & calcium deposition

Echo, Echocardiography; Angio, Angiography; RT-PCR, Reverse transcriptase-Polymerase chain reaction; AVBS, Aortic valve ultrasonic back scatter; NO, nitric oxide.

Table 1. Description of human studies

diet and atorvastatin. In addition, intervention with a statin showed a reduction in bone formation, less cellular proliferation, a lower Lrp5/beta catenin protein level, and an increase in endothelial NO synthase concentration (Rajamannan et al., 2005a, 2005b). Recently it was shown (Barrick et al., 2009) that epidermal growth factor receptor (EGFR) signaling contributes to normal valvulogenesis and that reduced EGFR was associated with aortic stenosis in mice models. Another mouse- model study (Matsumoto et al., 2010) showed the beneficial effect of regular exercise training in preventing aortic sclerosis by various pathways, e.g., reducing inflammation and oxidative stress, inhibiting osteogenic pathway, and maintaining endothelial integrity. Various studies suggest that vitamin D and an atherogenic diet induce aortic stenosis only when they act in combination (Drolet et al., 2008), and that an association of aortic valve stenosis and tissue factor was demonstrated (Marechaux et al., 2009).

7. Treatment

Accumulating animal and human studies suggest that aortic sclerosis is an inflammatory disease akin to atherosclerosis in addition to being an important biomarker of atherosclerosis and coronary artery disease. It is a slowly progressive disease that leads to aortic stenosis and, therefore, should be treated aggressively.

Authur (Year)	Model (N)	Intervention	Outcome Measures	Follow Up	Conclusion
Rajamannan et al. (2001)	Rabbits; n=16	Cholesterol	AV dissection	12 weeks	Aortic valve apoptosis
Rajamannan et al. (2005)	Rabbits; n=48	Cholesterol, Atorvastatin	eNOS expression, Western blot, Micro CT	3 months	Hypercholesterolemia produces bone mineralization in AV. Atorvastatin inhibits AVC & increases eNOS concentration
Rajamannan et al. (2005)	Rabbits; n= 54	Cholesterol, Atorvastatin	Micro CT, Calcein inj, Osteopontin expression	24 weeks	Positive bone formation in calcific AV but atorvastatin attenuates it.
Barrick et al. (2009)	Egfr-null mice; n=119	None	Echo, Histology, gene expression, Ventricular pressure	15months	EGFR is required for valvulogenesis & decreased EGFR is seen in AS
Matsumoto et al. (2010)	Mice; n=94	Cholesterol, regular ET, Occasional ET	Histologic analysis, Immunohistochemistry	16 weeks	Regular ET prevents AV sclerosis
Drolet et al. (2008)	Rabbits	Cholesterol, Vitamin D	Transvalvular gradient, AVA, Immunohistological study, Echo	12 weeks	Atherosclerosis & calcifying factors induce AS in combination
Marechaux et al. (2009)	Rabbits; n= 45	Cholesterol, Vitamin D	Immunohistology, Doppler AV performance, Histology	12 weeks	Association of AV sclerosis with tissue factor

REF, Reference; eNOS, Endothelial nitric oxide synthase; CT, Computed tomography; AV, Aortic valve; AVC, Aortic valve calcification; EGFR, Epidermal growth factor receptor; ET, Exercise training; AVA, Aortic valve area; Echo, Echocardiography; Inj, Injection.

Table 2. Description of animal model

7.1 Pharmacological therapy

Statins are known pleiotropic drugs with an anti-inflammatory and antioxidant effect in addition to their ability to lower lipid levels, stabilize, plaque, and prevent platelet aggregation. This underscores their role in preventing atherosclerotic vascular disease. With cumulative evidence on the similarities between vascular atherosclerosis and aortic valve disease, the hypothesis that statins halt the progression of aortic sclerosis to stenosis was proposed. Statins and ACE-I were considered the first-line candidates for slowing down the

Author (Year)	Population(N) / Age (Years)	Intervention	Outcome Measures	Study Type	Conclusion
Antonini-Canterin et al. (2008)	n=1046; 70±8	Statins	Echocardiogram	Retro-spective	Statins were effective in aortic sclerosis & mild stenosis.
Shavelle et al. (2002)	n=65; 67-68 (mean)	Statins	Electron beam computed tomogram	Retro-spective	Statins reduce aortic valve calcium accumulation.
Bellamy et al. (2002)	n=156; 77±12	Statins	Doppler echocardiogram	Pro-spective	Statin therapy results in slower progression of AS.
Moura et al. (2007)	n=121; 73±8.9	Rosuvastatin	Echo, serum lipids & inflammatory markers	Pro-spective	Rosuvastatin 20mg is beneficial in slowing AS progression
Cowell et al. (SALTIRE) (2005)	n=155	Atorvastatin 80mg	Doppler Echocardiogram, Helical CT	Double-blinded randomized	Statins do not halt the AS progression
Rossebo et al. (SEAS) (2008)	n=1873; 68±10	Simvastatin 10mg, Ezetimibe 40mg	Cardiovascular events, nonfatal MI	Double-blinded randomized	Simvastatin and ezetimibe did not reduce the composite outcome of combined aortic-valve events and ischemic events in patients with aortic stenosis
Chan et al. (ASTRONOMER) (2010)	N=269;	Rosuvastatin 40 mg	Echocardiogram	Double-blinded randomized	Rosuvastatin did not reduce progression of AS
Hamilton et al. (2011)	Rabbits	Cholesterol, statins	MRI, Excised AV tissue thickness, lipid accumulation	Pro-spective	In advance stages of AS, statin therapy is ineffective

REF, Reference; AS, Aortic stenosis; CT, Computed tomography; MI, Myocardial infarction; MRI, Magnetic resonance imaging

Table 3. Description of statin studies

progression of aortic sclerosis and mild aortic stenosis (Antonini-Canterin et al., 2008; Shavelle et al., 2002; Bellamy et al., 2002), but not for moderate-to-severe stenosis. Moura et al. (2007), in a 1.5-year prospective study, were the first to show the positive effect of statins in slowing the progression of aortic stenosis. Contrary evidence from three prospective randomized trials suggests that statins do not slow the progression of aortic valve disease but lower cholesterol and thus reduce coronary events. The three trials were SALTIRE (The Scottish Aortic Stenosis and Lipid Lowering Trial), SEAS (Simvastatin and Ezetimibe in Aortic Stenosis), and ASTRONOMER (Aortic Stenosis Progression Observation Measuring Effects of Rosuvastatin), which involved 155, 1873 and 269 participants, respectively (Cowell et al., 2005; Rossebo et al., 2008; Chan et al., 2010). In a recent animal experiment with rabbits (Hamilton et al., 2011), it was shown that statin therapy did not regress the disease process in valves with established sclerosis. Thus, medical intervention at an early stage of aortic sclerosis or trivial stenosis may be beneficial, but large outcome-based studies are lacking.

8. Conclusion

Aortic stenosis is the most common valvular pathology in older adults. It is emerging with increasing clarity that aortic valve sclerosis is an active inflammatory process and may be construed as a cardiovascular disease risk biomarker. Physicians should no longer ignore the murmur of aortic sclerosis as innocent; rather, it should be a beacon alerting us of the dangers that lie ahead for patients who harbor this murmur.

It is also evident that aortic sclerosis progresses to aortic stenosis. In fact, this progression is not infrequent. The take-home message from the larger trials and natural history studies seems to be that the target for therapy in established, calcific aortic stenosis may be too late, and that early, aggressive medical intervention be undertaken before the irrevocable process of calcification has occurred. Future studies are needed to fully estimate the benefits of medical therapy as well as the optimal timing for such interventions. Newer therapeutic options targeting the molecular and cellular mechanisms involved in the pathogenesis of aortic valve disease either singularly or in concert are needed.

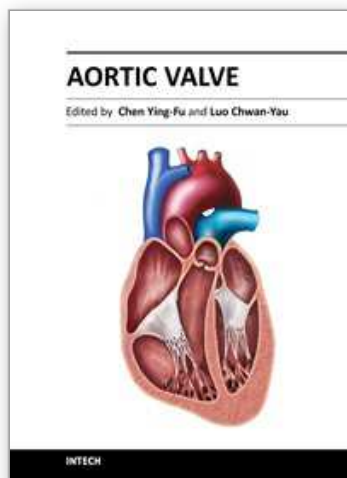
9. References

- Abdel-Azeez, H. A., Al-Zaky, M. (2010). Plasma osteopontin as a predictor of coronary artery disease: association with echocardiographic characteristics of atherosclerosis. *J Clin Lab Anal*, 24(3): 201-206.
- Antonini-Canterin, F., Hirsu, M., Popescu, B. A., et al. (2008). Stage-related effect of statin treatment on the progression of aortic valve sclerosis and stenosis. *Am J Cardiol*, 102(6): 738-742.
- Balachandran, K., Sucosky, P., Jo, H., et al. (2009). Elevated cyclic stretch alters matrix remodeling in aortic valve cusps: implications for degenerative aortic valve disease. *Am J Physiol Heart Circ Physiol*, 296(3): H756-764.
- Barrick, C. J., Roberts, R. B., Rojas, M., et al. (2009). Reduced EGFR causes abnormal valvular differentiation leading to calcific aortic stenosis and left ventricular hypertrophy in C57BL/6J but not 129S1/SvImJ mice. *Am J Physiol Heart Circ Physiol*, 297(1): H65-75.
- Batur, P., Stewart, W. J., Isaacson, J. H. (2003). Increased prevalence of aortic stenosis in patients with arteriovenous malformations of the gastrointestinal tract in Heyde syndrome. *Arch Intern Med*, 163(15): 1821-1824.

- Bellamy, M.F., Pellikka, P.A., Klarich, K.W., et al. (2002). Association of cholesterol levels, hydroxymethylglutaryl coenzyme-A reductase inhibitor treatment, and progression of aortic stenosis in the community. *J Am Coll Cardiol*, 40(10): 1723-1730.
- Campbell, M. (1968). Calcific aortic stenosis and congenital bicuspid aortic valves. *Br Heart J*, 30(5): 606-616.
- Chan, K.L., Teo, K., Dumesnil, J.G., et al. (2010). Effect of Lipid lowering with rosuvastatin on progression of aortic stenosis: results of the aortic stenosis progression observation: measuring effects of rosuvastatin (ASTRONOMER) trial. *Circulation*, 121(2): 306-314.
- Chandra, H. R., Goldstein, J.A., Choudhary, N., et al. (2004). Adverse outcome in aortic sclerosis is associated with coronary artery disease and inflammation. *J Am Coll Cardiol*, 43(2): 169-175.
- Cosmi, J.E., Kort, S., Tunick, P.A., et al. (2002). The risk of the development of aortic stenosis in patients with "benign" aortic valve thickening. *Arch Intern Med*, 162(20): 2345-2347.
- Cowell, S.J., Newby, D.E., Prescott, R.J., et al. (2005). A randomized trial of intensive lipid-lowering therapy in calcific aortic stenosis. *N Engl J Med*, 352(23): 2389-2397.
- Drolet, M.C., Couet, J., Arsenault, M. (2008). Development of aortic valve sclerosis or stenosis in rabbits: role of cholesterol and calcium. *J Heart Valve Dis*, 17(4): 381-387.
- Freeman, R.V., Crittenden, G., Otto, C. (2004). Acquired aortic stenosis. *Expert Rev Cardiovasc Ther*, 2(1): 107-116.
- Garg, V., Muth, A.N., Ransom, J.F., et al. (2005). Mutations in NOTCH1 cause aortic valve disease. *Nature*, 437(7056): 270-274.
- Gerber, H. P., Vu, T. H., Ryan, A. M., et al. (1999). VEGF couples hypertrophic cartilage remodeling, ossification and angiogenesis during endochondral bone formation. *Nat Med*, 5(6): 623-628.
- Ghaisas, N. K., Foley, J. B., O'Briain, D. S., et al. (2000). Adhesion molecules in nonrheumatic aortic valve disease: endothelial expression, serum levels and effects of valve replacement. *J Am Coll Cardiol*, 36(7): 2257-2262.
- Hage, F. G., Adegunsoye, A., Mundkur, M., et al. (2011). The role of echocardiography in the evaluation and management of aortic stenosis in the older adult. *Int J Cardiol*.
- Hamilton, A. M., Boughner, D. R., Drangova, M., et al. (2011). Statin treatment of hypercholesterolemic-induced aortic valve sclerosis. *Cardiovasc Pathol*, 20(2): 84-92.
- Helske, S., Syvaranta, S., Lindstedt, K.A., et al. (2006). Increased expression of elastolytic cathepsins S, K, and V and their inhibitor cystatin C in stenotic aortic valves. *Arterioscler Thromb Vasc Biol*, 26(8): 1791-1798.
- Kaden, J. J., Bickelhaupt, S., Grobholz, R., et al. (2004). Expression of bone sialoprotein and bone morphogenetic protein-2 in calcific aortic stenosis. *J Heart Valve Dis*, 13(4): 560-566.
- Kaden, J. J., Dempfle, C. E., Grobholz, R., et al. (2003). Interleukin-1 beta promotes matrix metalloproteinase expression and cell proliferation in calcific aortic valve stenosis. *Atherosclerosis*, 170(2): 205-211.
- Kennedy, J. A., Hua, X., Mishra, K., et al. (2009). Inhibition of calcifying nodule formation in cultured porcine aortic valve cells by nitric oxide donors. *Eur J Pharmacol*, 602(1): 28-35.

- Lindroos, M., Kupari, M., Heikkilä, J., et al. (1993). Prevalence of aortic valve abnormalities in the elderly: an echocardiographic study of a random population sample. *J Am Coll Cardiol*, 21(5): 1220-1225.
- Linhartova, K., Sterbakova, G., Racek, J., et al. (2009). Linking soluble vascular adhesion molecule-1 level to calcific aortic stenosis in patients with coronary artery disease. *Exp Clin Cardiol*, 14(3): e80-83.
- Marechaux, S., Corseaux, D., Vincentelli, A., et al. (2009). Identification of tissue factor in experimental aortic valve sclerosis. *Cardiovasc Pathol*, 18(2): 67-76.
- Matsumoto, Y., Adams, V., Jacob, S., et al. (2010). Regular exercise training prevents aortic valve disease in low-density lipoprotein-receptor-deficient mice. *Circulation*, 121(6): 759-767.
- Moura, L. M., Ramos, S. F., Zamorano, J. L., et al. (2007). Rosuvastatin affecting aortic valve endothelium to slow the progression of aortic stenosis. *J Am Coll Cardiol*, 49(5): 554-561.
- Ngo, D. T., Heresztyn, T., Mishra, K., et al. (2007). Aortic stenosis is associated with elevated plasma levels of asymmetric dimethylarginine (ADMA). *Nitric Oxide*, 16(2): 197-201.
- Ngo, D. T., Sverdlöv, A. L., Willoughby, S. R., et al. (2009). Determinants of occurrence of aortic sclerosis in an aging population. *JACC Cardiovasc Imaging*, 2(8): 919-927.
- Novaro, G. M., Katz, R., Aviles, R. J., et al. (2007). Clinical factors, but not C-reactive protein, predict progression of calcific aortic-valve disease: the Cardiovascular Health Study. *J Am Coll Cardiol*, 50(20): 1992-1998.
- O'Brien, K. D., Reichenbach, D. D., Marcovina, S. M., et al. (1996). Apolipoproteins B, (a), and E accumulate in the morphologically early lesion of 'degenerative' valvular aortic stenosis. *Arterioscler Thromb Vasc Biol*, 16(4): 523-532.
- O'Brien, K. D., Shavelle, D. M., Caulfield, M. T., et al. (2002). Association of angiotensin-converting enzyme with low-density lipoprotein in aortic valvular lesions and in human plasma. *Circulation*, 106(17): 2224-2230.
- Olsson, M., Thyberg, J., Nilsson, J. (1999). Presence of oxidized low density lipoprotein in nonrheumatic stenotic aortic valves. *Arterioscler Thromb Vasc Biol*, 19(5): 1218-1222.
- Ortlepp, J. R., Hoffmann, R., Ohme, F., et al. (2001). The vitamin D receptor genotype predisposes to the development of calcific aortic valve stenosis. *Heart*, 85(6): 635-638.
- Ortlepp, J. R., Schmitz, F., Mevissen, V., et al. (2004). The amount of calcium-deficient hexagonal hydroxyapatite in aortic valves is influenced by gender and associated with genetic polymorphisms in patients with severe calcific aortic stenosis. *Eur Heart J*, 25(6): 514-522.
- Otto, C. M., Kuusisto, J., Reichenbach, D. D., et al. (1994). Characterization of the early lesion of 'degenerative' valvular aortic stenosis. Histological and immunohistochemical studies. *Circulation*, 90(2): 844-853.
- Otto, C. M., Lind, B.K., Kitzman, D. W., et al. (1999). Association of aortic-valve sclerosis with cardiovascular mortality and morbidity in the elderly. *N Engl J Med*, 341(3): 142-147.
- Peltonen, T., Taskinen, P., Napankangas, J., et al. (2009). Increase in tissue endothelin-1 and ETA receptor levels in human aortic valve stenosis. *Eur Heart J*, 30(2): 242-249.

- Rajamannan, N. M., Sangiorgi, G., Springett, M., et al. (2001). Experimental hypercholesterolemia induces apoptosis in the aortic valve. *J Heart Valve Dis*, 10(3): 371-374.
- Rajamannan, N.M., Subramaniam, M., Caira, F., et al. (2005). Atorvastatin inhibits hypercholesterolemia-induced calcification in the aortic valves via the Lrp5 receptor pathway. *Circulation*, 112(9 Suppl): I229-234.
- Rajamannan, N. M., Subramaniam, M., Stock, S. R., et al. (2005). Atorvastatin inhibits calcification and enhances nitric oxide synthase production in the hypercholesterolaemic aortic valve. *Heart*, 91(6): 806-810.
- Roberts, W. C. (1970). Anatomically isolated aortic valvular disease. The case against its being of rheumatic etiology. *Am J Med*, 49(2): 151-159.
- Rossebo, A. B., Pedersen, T. R., Boman, K., et al. (2008). Intensive lipid lowering with simvastatin and ezetimibe in aortic stenosis. *N Engl J Med*, 359(13): 1343-1356.
- Sacks, M. S., Yoganathan, A. P. (2007). Heart valve function: a biomechanical perspective. *Philos Trans R Soc Lond B Biol Sci*, 362(1484): 1369-1391.
- Satta, J., Melkko, J., Pollanen, R., et al. (2002). Progression of human aortic valve stenosis is associated with tenascin-C expression. *J Am Coll Cardiol*, 39(1): 96-101.
- Selzer, A. (1987). Changing aspects of the natural history of valvular aortic stenosis. *N Engl J Med*, 317(2): 91-98.
- Shavelle, D. M., Takasu, J., Budoff, M. J., et al. (2002). HMG CoA reductase inhibitor (statin) and aortic valve calcium. *Lancet*, 359(9312): 1125-1126.
- Steinmetz, M., Skowasch, D., Wernert, N., et al. (2008). Differential profile of the OPG/RANKL/RANK-system in degenerative aortic native and bioprosthetic valves. *J Heart Valve Dis*, 17(2): 187-193.
- Stewart, B. F., Siscovick, D., Lind, B. K., et al. (1997). Clinical factors associated with calcific aortic valve disease. Cardiovascular Health Study. *J Am Coll Cardiol*, 29(3): 630-634.
- Sucker, C. (2007). The Heyde syndrome: proposal for a unifying concept explaining the association of aortic valve stenosis, gastrointestinal angiodysplasia and bleeding. *Int J Cardiol*, 115(1): 77-8.
- Zigelman, C. Z., Edelstein, P. M. (2009). Aortic valve stenostenosis. *Anesthesiol Clin*, 27(3): 519-532, table of contents



Aortic Valve

Edited by Prof. Chen Ying-Fu

ISBN 978-953-307-561-7

Hard cover, 350 pages

Publisher InTech

Published online 09, December, 2011

Published in print edition December, 2011

Much has evolved in the field of aortic valve disease because of the increase in knowledge in the last decade, especially in the area of its management. This book "Aortic Valve" is comprised of 18 chapters covering basic science, general consideration of aortic valve disease, infective endocarditis, aortic sclerosis and aortic stenosis, bioprosthetic valve, transcatheter aortic valve implantation and a special section on congenital anomalies of the aortic valve. We hope this book will be particularly useful to cardiologists and cardiovascular surgeons and trainees. We also believe that this book will be a valuable resource for radiologists, pathologists, cardiovascular anesthesiologists, and other healthcare professionals who have a special interest in treating patients with aortic valve disease. We are certain that information in this book will help to provide virtually most new areas of aortic valve disease that will be employed in the current era.

How to reference

In order to correctly reference this scholarly work, feel free to copy and paste the following:

Uzma Jalal Serageldin Raslan and Farouk Mookadam (2011). The Progression of Aortic Sclerosis to Aortic Stenosis, Aortic Valve, Prof. Chen Ying-Fu (Ed.), ISBN: 978-953-307-561-7, InTech, Available from: <http://www.intechopen.com/books/aortic-valve/the-progression-of-aortic-sclerosis-to-aortic-stenosis>

INTech
open science | open minds

InTech Europe

University Campus STeP Ri
Slavka Krautzeka 83/A
51000 Rijeka, Croatia
Phone: +385 (51) 770 447
Fax: +385 (51) 686 166
www.intechopen.com

InTech China

Unit 405, Office Block, Hotel Equatorial Shanghai
No.65, Yan An Road (West), Shanghai, 200040, China
中国上海市延安西路65号上海国际贵都大饭店办公楼405单元
Phone: +86-21-62489820
Fax: +86-21-62489821

© 2011 The Author(s). Licensee IntechOpen. This is an open access article distributed under the terms of the [Creative Commons Attribution 3.0 License](https://creativecommons.org/licenses/by/3.0/), which permits unrestricted use, distribution, and reproduction in any medium, provided the original work is properly cited.

IntechOpen

IntechOpen