

We are IntechOpen, the world's leading publisher of Open Access books Built by scientists, for scientists

6,900

Open access books available

186,000

International authors and editors

200M

Downloads

Our authors are among the

154

Countries delivered to

TOP 1%

most cited scientists

12.2%

Contributors from top 500 universities



WEB OF SCIENCE™

Selection of our books indexed in the Book Citation Index
in Web of Science™ Core Collection (BKCI)

Interested in publishing with us?
Contact book.department@intechopen.com

Numbers displayed above are based on latest data collected.
For more information visit www.intechopen.com



Sedation Related to Gastrointestinal Endoscopy

Mitrut Paul, Mitrut Anca Oana,
Streba Liliana, Calina Daniela and Salplahta Daniel
*University of Medicine and Pharmacy of Craiova
Romania*

1. Introduction

In the last ten years the number of worldwide gastrointestinal endoscopic procedures has significantly increased; the majority are ambulatory endoscopies with appropriate intravenous sedation and analgesia which seems to be used more and more frequent.

By definition, sedation is a drug-induced depression in the level of consciousness. Moderate sedation current terminology replaces the previous terminology called conscious sedation (American Society of Anesthesiologists [ASA], 2002). Sedation and analgesia are being used in order to improve patient tolerance to endoscopic procedures by diminishing anxiety and discomfort. There are several sequent benefits: an adequate sedation allows the endoscopist to focus on the technical performance of the endoscopy, increases the rate of patients returning for follow-up examinations or for colonoscopic screening, prevents potentially harmful autonomic stress responses and improves the public reputation of the procedure. However, these benefits must be weighed against the complications (especially in the form of potential compromise of ventilatory function) and the added cost associated with the use of sedation and analgesia.

Patients with associated comorbidities address to the gastroscopist to perform an endoscopy without being evaluated for their pathologies that could influence the procedures used in sedation. In addition, in cases where the examination is more invasive or conducted in a larger time interval, the level of sedation should be optimized to achieve an ideal procedure (ASA, 2002; Faigel *et al.*, 2002).

The practice of sedation varies from country to country, determined by cultural differences in pain perception and expectations of patients and physicians. A recent international study of 21 centers in 10 European countries and in Canada reported that the use of sedation during endoscopy varies from 0% to 100% at different sites: it was used in 44% of all procedures in Asia, 56% in Europe, and 72% in Canada, Central America and South Latin America. In the United States, only flexible sigmoidoscopy is performed without sedation (Wang&Lin, 1999). Such diversity reflects social, cultural, regulatory and economic consideration.

Best practices for analgesia and sedation during gastrointestinal endoscopy are still debated. Ensuring an adequate sedation and analgesia influences some aspects of endoscopic procedures such as quality of examination, patient cooperation, patient and performing physician satisfaction (Bell, 2004).

There are several practical issues with implications for endoscopic sedation (Thomson *et al.*, 2010):

- gastrointestinal endoscopic procedures have short duration, there is no need of skin incisions, there are not associated with significant changes in body fluids and do not require medication to eliminate the post-exploratory discomfort
- most procedures are performed ambulatory, as cases of "single day admission"
- the level of sedation necessary to prevent discomfort during the procedure may be adjusted depending on the situation
- many patients are medically well, presenting only for screening
- during endoscopic procedures patients are not intubated, the airway remains open

There are also disadvantages: more time for post procedural patient's recovery, higher costs, does not allow patients to leave the endoscopy unit immediately after the procedure and return to work after the sedation or analgesia.

To obtain maximum benefit it is desirable for gastrointestinal endoscopy to have a building designed or adapted specifically for this purpose, so that patients can be treated safely, quickly and efficiently.

Medical clinics with "one day" profile, fit for the activity of digestive endoscopy, are usually self clinics (individual or collective), with one basic specialty, with individual financial assurance for the location, secured space, related facilities, personnel policy and independent accounting and financial management which enables maximum efficiency for development. These can also be clinics attached to the base hospital or ambulatory clinical departments.

These "one day" clinics have in general in the operational structure their own specialized diagnostic services through clinical, paraclinical and laboratory investigations designed to substantiate both gastrointestinal endoscopy indication and anesthetic-endoscopic protocol which is to be established by the anesthesiologist in collaboration with the physician and patient. On this occasion, the staff repeated contact with the patients creates an atmosphere of trust and mutual affection beneficial in relation to the gastrointestinal endoscopy which is expected to be made.

Endoscopy room should be equipped with: good lighting, air conditioning, centralized administration of medical fluids, modern equipment for anesthesia and monitoring, pulse oximeter, resuscitation equipment (Sitcai, 2005).

2. Technical specifications

2.1 Patient selection and appropriate investigation (Lytle, 2005)

In carrying out a gastrointestinal (GI) endoscopy under anesthesia is very important that gastroenterologists agree with anesthesiologist about GI exploration that follows and about patient selection criteria. The initial selection of patients is done by the gastroenterologist. To reduce the cancellation from the day of GI endoscopy is better for patients to be interviewed personally or by phone by the anesthesiologist a few days before the planned GI endoscopy. The check performed by the anaesthesiologist is very important to identify cases that require precautions or contraindications for a particular type of medicine used to sedate patients. To save time there are very useful questionnaires completed by the patients containing simple questions about general state of health.

In general, patients admitted for GI exploration are from ASA I class and ASA II class. Patients with chronic respiratory disease, hypertension or symptomatic cardiovascular disease have a higher risk of developing complications, but diabetes mellitus, bronchial

asthma (AB), smoking and age are not necessarily problematic; biological age is more important than chronological age.

2.1.1 Selection criteria of patients for sedation in gastrointestinal endoscopy in an ambulatory unit (Lytle, 2005)

- ASA I and II
- Age 6 months – 70 years
- Patient weight – preferably BMI < 30
- - BMI = 31-34 – anesthesiologist decides if recommends sedation
- - BMI > 35: not recommended for sedation in ambulatory endoscopy, only in hospitals
- Good general condition (eg. the patient can safely climb two floors)

2.1.2 Exclusion criteria of patients for sedation in gastrointestinal endoscopy in an ambulatory unit (Lytle, 2005)

- Cardiovascular: history of heart attack, hypertension (diastolic arterial blood pressure > 100 mmHg), angina (angina crisis > 3 times/week or during effort), arrhythmias, cardiac insufficiency
- Respiratory: upper respiratory tract infection, corticoid-dependent bronchial asthma or asthma that requires chronic beta 2 agonists treatment, COPD
- Metabolic disorders: chronic alcohol consumption, insulin-dependent diabetes, renal failure, liver disorders
- Neurological: stroke or transient ischemic attack, hard controlled epilepsy
- Drugs: steroids, MAOIs, anticoagulants, antiarrhythmics
- Blood: sickle cell anemia, hemophilia, anemia after gastrointestinal bleeding
- History of drug allergies or anesthesia problems

2.1.3 Minimum investigation required for sedation in ambulatory gastrointestinal endoscopy (Lytle, 2005)

- Weight
- Height
- Body mass index (BMI)
- Blood pressure measurement
- Hemoleucogram if indicated (eg in case of menorrhagia)
- Serum ionogram, after treatment with diuretics
- ECG in patients over 60 years

Patient preparation is very important for sedation in ambulatory gastrointestinal endoscopy. During the pre-endoscopic examination, patients receive an informed consent about the risks of intravenous sedation. They also receive information leaflets and get the opportunity to ask questions (Clarks, 2007).

Patients will initially be consulted and informed in writing about the medication which will be given, will be instructed not to drive vehicles and not to work with machinery 24 – 48 hours after the investigation, to avoid alcohol, to avoid the use of sedatives and to not sign official and financial documents. Antihypertensive medication should be continued with the morning dose, hypoglycemic medication instead should be omitted.

Attempting to improve the patient understanding of the procedure, the presentation of video movies is not recommended because it may increase anxiety and therefore need higher doses of analgesics, especially in women (Bytzer & Lindeberg, 2007).

2.2 Pharmacology of drugs for sedation and analgesia

There are four stages of sedation defined by the American Society for Anesthesiology (ASA) that range from minimal to moderate, deep and general anesthesia: minimal sedation or anxiolysis (a drug-induced relief of apprehension with minimal effect on consciousness), moderate sedation (a depression of consciousness in which the patient can respond purposely to verbal or light tactile stimuli and spontaneous ventilation and cardiovascular function are maintained), deep sedation (the patient may not be able to maintain airway reflexes or spontaneous ventilation, but cardiovascular function is usually maintained) and general anesthesia (airway intervention is often required and cardiovascular function is usually maintained) (ASA, 2002).

Ideally, the patient should be slightly sedated (eg. drowsiness, but able to be waked up), with no pain, keeping the airway open, maintaining respiratory reflexes, being able to cooperate but unable to remember the procedure, without feeling anxiety and fear (Thomson *et al*, 2010).

During endoscopic sedation, some complications that must be avoided may arise: eg. worsening of the patient, lack of physical and verbal response to stimuli, loss of protective airway reflexes, inability to maintain spontaneous breathing, hypoxemia/hypercapnia, cardiovascular instability (arrhythmias or hypotension) (Thomson *et al*, 2010).

2.2.1 Characteristics of ideal drug (Zuccaro, 2006) used for sedation in gastrointestinal endoscopy

- Anxiolysis
- Amnesia
- Analgesia
- Rapid onset of pharmacological effect
- Dose-proportional sedative predictable effects
- Safety on a wide range of therapeutic doses, hemodynamic stability
- No pain or irritation at the injection site
- Rapid recovery without residual sleepiness

No drug used alone has all these properties and to achieve these goals it is often used a combination of two or even three drugs. Sedation is often performed with benzodiazepines in combination with an opioid for pain relief; a barbiturate hypnotic agent can be added only if there is required a deeper sedation.

All pharmacological agents used produce temporary mild depression in lung and cardiopulmonary function, especially when they are used in combination. This justifies the need for appropriate monitoring by direct observation by the anesthesiologist and monitoring equipment in the endoscopy room.

2.2.2 Types of drugs currently used for sedation in gastrointestinal endoscopy

The choice of sedatives depends on the endoscopist's preference and the type of procedure, but generally benzodiazepines are used alone or in combination with an opiate (frequently used for synergism).

The most commonly used benzodiazepines are midazolam and diazepam. The efficacy of sedation with these two benzodiazepines is comparable. Midazolam is now the preferred benzodiazepine more than diazepam because of its short duration of action and improved safety profile. Benzodiazepines used in most endoscopic procedures produce sedation, amnesia, anxiolysis, have anticonvulsant effects and muscle relaxing effects but have no effect on pain. These actions are considered to be the result of binding to gamma-aminobutyric acid (GABA) receptors in the central nervous system. Anxiolytic and muscle relaxing properties are not only mediated through GABA receptors, but also by glycine receptors in the spinal cord (Snyder *et al*, 1977). Respiratory depression is probably linked to a direct effect on the respiratory center in the brain, leading to hypoventilation and is an important side effect. Cardiovascular instability with decreased cardiac output and peripheral resistance and consequent hypotension usually occur only during deep sedation (Horn & Nesbit, 2004).

The benzodiazepine initially used in endoscopy was diazepam. However, for diazepam half-life was estimated between 24 and 57 hours, and its metabolites have also sedative properties. This means that it takes a long time to remove the effects, which often lasts until the next day. It is therefore an unsuitable agent for day procedures.

A new pharmacological sedative agent, midazolam, is now very commonly used in the practice of endoscopic sedation. This is a short-acting benzodiazepine; with good amnesic effect during the procedure (it does not cause amnesia before or after the endoscopic exploring). The half-life is less than one tenth compared to diazepam, and therefore, it is removed from the blood very quickly. Moreover, its metabolites have short-acting and do not have sedative properties. Dosages range from 1-5 mg (0.015-0.07 mg/kg).

Midazolam has few side effects and, if they occur are not serious. Respiratory depression is the most important adverse effect. It was also described a paradoxal response to midazolam with agitation instead of induced sedation (Yi&Shin, 2005) and is probably more common in the elderly (Horn&Nesbit, 2004). Pharmacological effects of midazolam may be antagonized by the administration of flumazenil, which competitively blocks GABA receptors. Other side effects: nasal itching, rash, dizziness, anxiety, irritability, dreams, seizures and unusual or involuntary muscle movements. Midazolam is contraindicated in patients with myasthenia gravis, acute glaucoma, in patients known to be allergic to this class of drugs. Caution should be exercised in patients with severe lung disease, COPD in particular (Horn & Nesbit, 2004).

From opioid class, fentanyl and meperidine are commonly used, endoscopic sedation with fentanyl being preferred by younger endoscopists. Endoscopic sedation with propofol is only made by the anesthesiologist (SAA, 2002, Faigel *et al*, 2002). Opioids have strong analgesic effect. In Australia, fentanyl is the most commonly used opiate, (Padmanabhan& Leslie, 2008; Clarke *et al*, 2002) and there is also significant use of pethidine. A London group showed a shorter recovery period for patients undergoing endoscopy if fentanyl and midazolam are used together, compared with the use of pethidine and midazolam, and there was no difference in pain perception (Hayee *et al*, 2009).

Fentanyl is a short acting opioid and is often used in combination with midazolam. The analgesic effect of fentanyl lasts about thirty minutes. These properties make it suitable for use in short-term exploration. The major side effect is respiratory distress and hypertension that may occur in one minute or less from the drug injection. It can also determine the decrease of heart rate (bradycardia). Hypovolemic patients and those with respiratory illnesses are particularly at risk of developing these complications (Horn & Nesbit, 2004). Fentanyl is

contraindicated in patients taking first-generation MAOI drugs. Special precautions: pregnancy - safe use of fentanyl has not been established in the first three months of pregnancy, and therefore should be used only if potential benefits outweigh possible risks; lactation - not known whether fentanyl is excreted in breast milk, so fentanyl should be avoided in nursing mothers, although it has no clear contraindications (Qureshi *et al*, 2005).

Opioids and benzodiazepines are used for analgesia and anxiolysis. When they are used alone, the incidence of respiratory complications is quite low. In contrast, the rate of complications increases several times when both drugs are administered in combination. It should be noted that both pharmacological effects and side effects of benzodiazepines and opioids are synergistic, so that these drugs must be used carefully. Sedative effects are dose dependent and there is a substantial synergism between narcotics and benzodiazepines. Although traditional management was using progressive increasing doses, one study found that in healthy patients under the age of 65, colonoscopy could be initiated by the administration of a standardized dose expressed in mg/kg body weight, followed by endoscopic procedure performed 2 minutes later, with improved technical efficiency and without loss of patient satisfaction (Morrow *et al*, 2000).

Use of benzodiazepines and opioids provides some important benefits, including a long history of safety, effectiveness and widespread acceptance by non-anesthesiologists (Arrowsmith *et al*, 1991). In addition, the existence of specific pharmacological antagonists for benzodiazepines and opioids give these drugs a high level of safety compared with other classes of drugs.

Typically, recovery from sedation in GI endoscopy is gradual and pleasant. However, specific antagonist for benzodiazepine and opioid drugs should be available in the endoscopy room in an emergency (rare) for the rapid antagonizing of the sedative effects produced by the drug. For example, Flumazenil is a specific benzodiazepine receptor antagonist that acts within seconds while Naloxone is an opioid antagonist which antagonizes the respiratory depressant and analgesic effects of opioids. Naloxone is a competitive antagonist that binds μ -opioid receptors that prevents or reduces the above complications. Repeated administration may be necessary. Doses vary between 1 to 1.5 mg/kg, with lower doses in the elderly, in renal or hepatic failure. Lower doses may be necessary in patients with chronic heart and lung disease and in patients taking antidepressant MAOI of second generation.

Propofol is the recently appeared non-barbiturate intravenous anesthetic approved by FDA in 1989 as a pharmacological agent in induction and maintenance of anesthesia. Due to the rapid onset of action and short recovery period is ideal for sedation in gastrointestinal endoscopy. It increases the sedative effect of hypnotic agents, producing deep sedation depending on dose. Safe therapeutic range is narrower than of benzodiazepines. It is a lipophilic drug that acts on GABA receptor subtype different from those that mediate the effects of benzodiazepines (Horn & Nesbit, 2004). Because in the propofol formulation are used soybean oil and egg lecithin, it is contraindicated in those with allergies to egg or soy protein. Propofol interacts with glycine, nicotinic and muscarinic receptors and has a direct effect on neuronal ion channels (Trapani *et al*, 2000). The duration of action is short, with the first phase of elimination usually at 2-3 minutes (Kanto & Gepts, 1989).

Propofol has a relatively small analgesic effect, and its effect is less amnesic than midazolam. In addition, it has a slightly antiemetic effect (Stark *et al*, 1985). Thus, it has a rapid onset of hypnotic action which usually occurs after a short lag time of 40 seconds (time for one arm-brain circulation). Waking up is relatively fast. It is rapidly metabolized by hepatic conjugation and excreted in urine. Its inactivation depends more on liver blood flow than

liver function. In patients with cirrhosis, the use of propofol for elective upper endoscopy does not precipitate the encephalopathy (Amoros *et al*, 2009). Therapeutic plasma concentrations can only be estimated by the anesthesiologist, as there are no technical means besides the system called Diprifusor (injectomate), which distributes only plasma concentrations independent of the desired therapeutic effect.

POSITIVE EFFECTS	NEGATIVE EFFECTS
<ul style="list-style-type: none">• Sedation• Hypnosis• Analgesia• Anticonvulsivant• Decreased intracranial pressure (reduces cerebral O₂ consumption and cerebral blood flow)• Good laryngeal relaxation	<ul style="list-style-type: none">• Lowers BP during induction• Hallucinations, sexual fantasies• Respiratory depression with increased CO₂ and reduced centers sensitivity to hypoxia and hypercapnia (sleep apnea is common 1-2 min after administration – lasts a few seconds)

Table 1. Pharmacological effects of propofol

Among the effects of propofol listed in the table above (Table 1), there is to know that it produces pain when is administered into a vein in about 30% of cases, which then disappears within 1 minute. This can be controlled, if immediately before administration a mixed afentanil or lidocaine solution (1-2 ml) is used. It is contraindicated in children under 3 years both as a sedative and as an anesthetic and also during pregnancy and lactation. It should not be stored in the refrigerator and should not be used within hours of opening as it is a good medium for bacteria culture.

PROPOFOL SIDE EFFECTS				
CNS	Cardiovascular	Respiratory	Gastrointestinal	Renal
<ul style="list-style-type: none">- headache- fever- dizziness- tremor- confusion- drowsiness- paresthesia- agitation- euphoria- fatigue- involuntary movements- modified dreams- vision problems	<ul style="list-style-type: none">- bradycardia- hypotension- ventricular tachycardia- changes in ECG- ST segment flattening- asystole	<ul style="list-style-type: none">- apnea- cough- hiccups- hypoventilation- wheezing- tachypnea- hypoxia	<ul style="list-style-type: none">- nausea and vomiting- abdominal cramps- dry mouth- hypersalivation	<ul style="list-style-type: none">- urinary retention- urine greenish hue

Table 2. Propofol side effects

In general, for the administration of propofol there are used two schemes:

- Combination - where a benzodiazepine and an opioid are administered intravenously (opioids may be omitted in some unstable patients and in elderly). After a pause, propofol can be administered as an infusion or by progressive increase doses.
- Propofol alone - administered as an infusion or by progressive increase doses.

If for the administration of the propofol is used the scheme, then the associated doses of fentanyl and midazolam are generally lower than if they were used without propofol. In general, if midazolam and fentanyl have been administered, the maximum dose of propofol should be 30 mg. In addition, once propofol administration started, the doses of fentanyl or midazolam should not be supplemented. In terms of approaching the "combination" scheme, an Australian study reported median total doses of 4 mg midazolam, 75 mg fentanyl and 60 mg propofol in a sample of 500 cases from a total of 28,472 patients undergoing ambulatory endoscopy. In all patients the three drugs were used (Qadeer *et al*, 2009).

In a Swiss study (Kulling *et al*, 2007) that included 27,061 patients undergoing ambulatory endoscopy, propofol was used as single agent for sedation. The initial dose of propofol was 0.5 mg/kg or 0.25 mg/kg in ASA III patients and those over 70 years, then were given additional 10-20 mg of propofol.

VanNatta and Rex from Indiana compared four schemes of sedation on a group of patients who received ambulatory colonoscopies (VanNatta & Rex, 2006). In each group the dose of propofol was increased under sedation requirements: (i) propofol alone (ii) fentanyl (50 micrograms with an optional add-on of 25 micrograms given for analgesia at the request of the endoscopist) and propofol (iii) midazolam (1 mg) and propofol and (iv) all three drugs: fentanyl (50 micrograms), midazolam (1mg) and propofol. When combination sedation was used, propofol was last administered. Those who received only propofol had the most profound sedation scores and received on average 215 mg of propofol compared with 82.5 mg in those who previously received midazolam and fentanyl. The doses of propofol in the other two groups were 140 mg (fentanyl alone group) and 125 mg (midazolam alone group). Those from the combination groups were sooner discharged from hospital. Patients from the group receiving the combination with fentanyl remembered the pain associated with the endoscopic procedure, compared with patients who received propofol alone and not remembered it. This study is important in highlighting the fact that the doses of propofol were reduced by almost 50% in association with only 1 mg of midazolam. Compared with the Australian study (Qadeer *et al*, 2009) the doses of fentanyl and midazolam were notably lower compared with higher doses in using propofol alone. In interpreting the Indiana trial one must take into account that in the study only a small number of patients (200 in total) were included.

To prevent complications related to propofol sedation in GI endoscopy, careful administration of appropriate doses is essential to avoid undesirable cardiorespiratory depression, especially in elderly and unstable patients. There is evidence that oxygen supplementation reduces the risk of hypoxemia during colonoscopy (Holm *et al*, 1999) but there are studies showing that when given supplemental oxygen, oxygen saturation levels do not reflect the ventilation function and may mask the CO₂ retention (Lazzaroni&Bianchi, 2001). However, a recent Australian study conducted by anesthesiologists showed that the use of supplemental oxygen was universal (Pena *et al*, 2005).

Preparing medical personnel in the management of airway obstruction and apnea is essential. Measures taken include: chin lift, jaw thrust, placing nasal tubes in airway and oral cavity, and for longer periods of respiratory depression, balloon and mask ventilation.

Pharmacological agents antagonizing with flumazenil and naloxone may occasionally be indicated.

Advanced respiratory ventilation measures, including the use of laryngeal masks and endotracheal intubation are rarely required in ambulatory (Rex&Deenadayalu, 2009). In patients who develop hypotension related to administration of sedative agents, intravenous fluids may be indicated.

For adults, several data suggest that sedation with propofol in endoscopic techniques may be sufficiently secure, without serious adverse events. Walker *et al* investigated the adverse events in 9,152 endoscopies (Walker *et al*, 2003). Seven patients had considerable respiratory complications and all were related to upper endoscopy, three had apnea, three had laryngospasm and one aspiration, five required assisted ventilation with face masks, but none were intubated. Rex *et al* collected data from two departments of endoscopy in the United States and one in Switzerland (Rex *et al*, 2005). Of 36,743 cases, of which about 50% were upper endoscopies, none required tracheal intubation and assisted ventilation was required in only one case from 500. There was no reported pulmonary aspiration. In all cases, propofol sedation was performed by non-anesthesiologists.

Who should administer propofol for sedation in GI endoscopy? Traditionally, the endoscopist themselves were administering sedative drugs, however recently it started being performed by a healthcare professional trained in this respect. In the U.S., 'nurse-anesthetists' have been used to manage a much selected range of sedative drugs in patients with decreased anesthetic risk in accordance to protocols. In the U.S., the use of the anesthesiologists for endoscopic sedation is very different between regions, ranging from less than 20% in most, to over 50% in states like New York and Florida (Brill, 2008). In recent years, in Australia, particularly in the private sector, the anesthesiologists were called to perform endoscopic sedation even in patients with low anesthesia risk.

Until recently, only anesthetists were allowed to administer propofol and their involvement measurably increased in performing sedated endoscopy. This fact allows the use of propofol in ambulatory and improves the quality of sedation without compromising patient safety. There is now evidence to suggest that propofol can be safely and effectively administered in ASA grade I, II and III patients by non-anesthesiologists. In a series of nearly 28,500 cases of sedated endoscopy, the sedative drugs were administered almost entirely by non-anesthetists (Qadeer *et al*, 2009) and there was no case of mortality and morbidity. In a multicenter trial (Rex&Deenadayalu, 2009) on 650,000 patients who received propofol sedation, given as unique pharmacological agent administered by a nurse under the direction of the endoscopist, there was only one death related to anesthesia. Whoever administered propofol sedation, there should be at least one properly trained individual whose sole function is to monitor the patient during the procedure. This person must possess the necessary skills and also to take necessary measures for the prevention and management of complications related to sedation.

Without being in contradiction with the above trials, the presence of anesthesiologists for sedated endoscopic procedures is mandatory in many cases, especially in the elderly and those with higher ASA classification, or if there were difficulties in intravenous sedation in the endoscopy history of the patient. In addition, complex procedures that require a longer time should not be undertaken without anesthesia support. In this regard, a recent Australian study showed that many Australian university hospitals have mentioned the presence of the anesthesiologist mandatory in sedated endoscopy (Louis *et al*, 2004).

In conclusion, propofol is a more "powerful" drug than midazolam in producing sedation, which makes it very useful in gastrointestinal endoscopic sedation, but requires a higher level of monitoring of vital functions.

Fospropofol is a pro-drug used for sedation in a variety of endoscopic procedures including colonoscopy (Fechner *et al*, 2004; Gibiansky *et al*, 2005). It is converted to propofol in a few minutes after intravenous injection and inactive metabolites: phosphate and formaldehyde (rapidly converted to formate). Therefore, the time for maximum plasma concentration is higher than for propofol and the elimination period is slower. This effect facilitates the administration, because for short-term endoscopic procedures such as upper endoscopy or colonoscopy, patients may require only one dose of fospropofol.

To improve pain control and to facilitate moderate sedation control, fospropofol is co-administered with a narcotic, typically fentanyl. Fospropofol is associated with slight increases in phosphorus serum levels after intravenous administration, but no significant clinical adverse effects are present as a result of these elevated levels of phosphorus (Fechner *et al*, 2004; Gibiansky *et al*, 2005). These apparent disadvantages were considered by the U.S. Food and Drug Administration (FDA) as "benefits" of this drug, and therefore recently approved (2008) for moderate sedation in gastroscopy. Any other requests for drugs approval to be used for deep sedation in gastroscopy were refused. FDA requires that fospropofol be used only by persons trained in general anesthesia (only anesthesist) and that all patients should be monitored continuously by the medical staff not involved itself in the endoscopic procedure.

Fospropofol does not cause pain at the injection site and is soluble in water. However, it has some side effects that are not described in propofol - particularly perineal pain or paresthesia (Fechner *et al*, 2004). Despite this, a preliminary report of a clinical trial indicates that patient satisfaction is very good (Pruitet *et al*, 2005).

Droperidol is a neuroleptic butyrophenone used for conscious sedation in gastroscopy especially in the USA (Horn & Nesbit, 2004). It also has antiemetic action at low doses, explained by it occupying a GABA receptor. If it is used in the precursory period of endoscopic procedures, it can cause dysphoria, characterized by an apparent state of calm that masks in fact the anxiety generated by the endoscopic act. As a dopamine antagonist, droperidol may cause extrapyramidal side effects that can be countered by combination with promethazine or difenilhidramine. Droperidol determines cerebral vasoconstriction, but does not reduce cerebral metabolic rate, which may be detrimental to patients with cerebrovascular disease undergoing GI endoscopy. It does not produce amnesia and does not have anticonvulsant properties. Due to a weak alpha blocking action, may reduce blood pressure, significant effect in hypovolemic patients and Parkinson's disease. It protects the heart of the anti-arrhythmic effects of catecholamine release. One of the advantages of droperidol is that the response to the CO₂ does not change, moreover, given intravenously, stimulates the respiratory response to hypoxemia, which is recommended for patients with COPD premedication. Neuroleptanalgesia produced by droperidol is characterized by a similar trance state in which the patient is immobile and unresponsive to external stimuli. Analgesia is strong, allowing the endoscopic procedure. Combined with fentanyl it does not provide stronger analgesia, but extends its duration (Ionescu, 2005).

Promethazine is a powerful H1 antihistamine with antiemetic, anticholinergic, hypnotic, sedative/tranquilizing, analgesic and local anesthetic properties. It is used as an adjunct to endoscopic sedation and sedative in pediatrics.

The addition of diphenhydramine on narcotics and benzodiazepines has shown to improve sedation quality (Tu *et al*, 2006).

3. Current approaches to sedation for GI endoscopy

3.1 Unsedated endoscopy

Trials have shown that a substantial proportion of the patients from Asia, Europe and Canada are subjected to digestive endoscopic exploration without any sedation (Wang&Lin, 1999). This practice is not common in the United States of America and Australia. There is evidence that the low prevalence of endoscopy without sedation is due more to patient reserves, rather than physician preference (Faulx *et al*, 2005).

In terms of patient tolerance, a Finn double-blind trial compared intravenous midazolam alone with each of three other groups: one group without any sedation, a group that used a local pharynx anesthetic and a third control group (Ristikankare *et al*, 2004). Patients in the Midazolam group could not remember the procedure and reported desire to return to repeat the procedure. The effects were more pronounced in younger patients. Regarding the assessment of the endoscopist, patients in the Midazolam group were assessed as being easier to intubate by the endoscopist compared with placebo group, but there was no difference between Midazolam group and pharyngeal anesthesia group or control group. Interestingly, Midazolam group had a higher difficulty rating at endoscopy and retching during the procedure, compared with the pharyngeal anesthesia group.

Another trial showed that performing endoscopy without sedation was moderately less well tolerated by patients but did not require a long time for the procedure, the risks were not higher and the patients' reserves to undergo a subsequent procedure did not increase (Bonta *et al*, 2003). In this study, however, there was no control group, only blinded (both patients and endoscopists), sedation and placebo groups. More recently, it was found that male patients, patients with previous bowel resection, those with a high body mass index (BMI) and those without gynecological surgery didn't need sedation to complete colonoscopy (Tsai *et al*, 2008).

Hypnosis has also been used to facilitate endoscopy (Conlong *et al*, 1999). Compared with intravenous Midazolam, its use was associated with greater patient discomfort (assessment made by the patient), and the lack of amnesia for the procedure. A higher technical difficulty of the endoscopist was also reported. However, using hypnosis led to less patient agitation, according to assessments made by independent observers compared with patients receiving throat spray and no intravenous sedation and those receiving midazolam.

3.2 Topical anesthesia

The use of throat sprays with various local anesthetics (lidocaine, tetracaine and benzocaine) as preparation for endoscopy is widespread, although few studies have evaluated their effectiveness.

A recent meta-analysis (Evans *et al*, 2006) of five randomized controlled trials on 500 patients showed that the use of local anesthetic sprays reduced throat discomfort and technical difficulties evaluated by the endoscopist. The main adverse effects are inhibition of gag reflex and the risk of pulmonary aspiration. There have also been reported systemic adverse effects such as arrhythmias and convulsions due to absorption of topical pharmacological agent, however extremely rare.

There is a small risk of methaemoglobinemia (Kane *et al*, 2007) especially for benzocaine, and some evidence that aspiration may occur after local anesthetic with throat spray (Ertekin *et al*, 2000).

3.3 Sedation and analgesia agent used for endoscopy

A key principle of medical sedation in GI endoscopy, especially in ambulatory units where narcotic and benzodiazepines administration have a long tradition, is that drugs should be administered in incremental dosages in order to achieve the desired sedative effect. Although certain patient characteristics (such as patient age, comorbidities, body mass, race, previous responses to sedation and routine use of oral narcotics or benzodiazepines) may help pre-establish the drug dose required to achieve adequate sedation, the exact dose that will be needed for a particular patient is impossible to be accurately predicted. This is because the pharmacological response of the patient is variable and individual to specific sedative agents. Therefore, the anesthesiologist is trying to achieve moderate sedation by administering an initial bolus selected through a process of clinical estimation and then to titrate the increased doses to achieve the desired sedative effect. The general principle is to start with a low dose, followed by an assessment of patient responsiveness, sedation level and ventilatory and cardiovascular function and status, and then gradually continue with increasing doses. The knowledge of the pharmacokinetic properties of pharmacological agents used is critical. However, it is possible that a variable number of individual responses might exist for any sedative or analgesic used (Gourlay, 1988; Levy, 1989; Wood, 1989).

Sedation agent	Pharmacokinetics			
	Onset of action (min)	Duration of action	Elimination half-life	Excretion metabolism
Meperidine	5	2-4 h	2-7 h	Hepatic; excreted in urine
Midazolam	1.0-2.5	2-6 h	1.8-6.4 h	Hepatic and intestinal; excreted in urine
Droperidol	5-10	2-4 h	2.3 h	Hepatic; Excreted in urine
Fentanyl	≤1.5	1-2 h	2-7 h	Hepatic; excreted in urine
Propofol	<1	3-10 min	Triphasic: 2.2 min, 20 min, 8 h	Hepatic; excreted in urine
Diphenhydramine	1-10	2-6 h	2.4-9.3 h	Hepatic; excreted in urine

Table 3. Pharmacological properties of sedative agents for endoscopy (Roseveare *et al*, 1998; Rudner *et al*, 2003)

For this reason, the determination of any pharmacological schemes for moderate endoscopic sedation should include an observation period supervised by an anesthesiologist, followed by a supervised drug administration period in which the anesthesiologist selects and distribute that medicine (Rex, 2006).

Reversal agents	Initial IV dose	Onset of action	Duration of action
Naloxone (for opioids)	0.2-0.4 mg (also IM)	1-2 min	45 min
Flumazenil (for benzodiazepines)	0.1-0.2 mg	30-60 s	30-60 min

Table 4. Commonly used reversal agents

Another important principle for moderate sedation in endoscopy is that combinations of drugs from different classes have synergistic effects, without being additive. Thus, even a small amount of narcotic can substantially reduce the required amount of benzodiazepines (Arrowsmith *et al*, 1991, Bailey *et al*, 1990) or propofol (Clarke *et al*, 2001, Cohen *et al*, 2004, Kern *et al*, 2004, Roseveare *et al*, 1998, Rudner *et al*, 1998) necessary to perform the endoscopy. Similarly, benzodiazepines have a synergistic effect with narcotics (Arrowsmith *et al*, 1991, Bailey *et al*, 1990) and propofol (Clarke *et al*, 2001, Cohen *et al*, 2004; Paspatis *et al*, 2002; Seifert *et al*, 2000, Reimann *et al*2000). The understanding and knowledge of the clinical impact of synergistic effects determine the appropriate selection of drug doses needed to achieve moderate sedation.

A final general principle for endoscopic moderate sedation is that each sedative agent has unique properties in terms of time period between intravenous injection and onset of sedative action and maximum drug effect (Huang&Eisen, 2004, Horn&Nesbit, 2004). If additional drug boluses are administered before reaching previous boluses plasmatic peak, the sedative effects may rapidly accumulate and may cause unwanted deeper levels of sedation. Therefore, for each pharmacological agent used, the clinician must wait an appropriate time to reach its maximum effect before injecting additional boluses of medication during the initial titration and during the maintenance phase of sedation. For example, midazolam has a longer period for achieving the maximum effect (8-12min) than diazepam (2-5 min) (Buhren *et al*, 1995). Propofol has a very short time to onset of action (45-60 seconds) and undergoes a rapid metabolism. These features have led to the necessity of quite frequent propofol administration (especially when it is used as single agent) to maintain sedation levels. For this reason, propofol administration requires more specialized attention and supervision compared to narcotics and benzodiazepines. There is the possibility that non-anesthesiologists to administer propofol for endoscopy, but the pharmacological properties of the drug are quite different from those of currently used narcotics and benzodiazepines and therefore higher risks. The use of narcotics and benzodiazepines to produce moderate sedation is already familiar to most of the endoscopists.

Key points and practical issues concerning the use of pharmacological agents for sedation and analgesia in GI endoscopy (Thomson *et al*, 2010):

- Endoscopy with intravenous sedation is a routine practice in many countries and therefore is very important that the selection of sedative drugs to be made for a maximum patient and endoscopist comfort and with minimal side effects. One option is

to spray the throat with local anesthetic that could be associated with soothing music, reducing the necessary amounts of intravenous sedative drugs.

- The pre-procedural assessment of patients undergoing sedation endoscopy is very important. Cardiovascular, respiratory and neurological comorbidities should be rigorously evaluated. Allergies and adverse reactions to sedative drugs, smoking, alcohol consumption, routinely sedatives use should also be known. The person who used pharmacological agents and monitors the effects of sedative should evaluate the nature of the proposed procedure, its likely duration and the potential for complications. This person should ideally be a physician anesthesiologist.
- Intravenous sedation for GI endoscopy should be administered only if there is sufficient space to allow easy personnel movement and require specialized monitoring equipment readily available: oximeter, frequent measurement of blood pressure, the insertion of intravenous cannula for the fluids administration.
- Propofol and its pro-drug, fospropofol can be safely administered in quality moderate sedation without patient safety compromising with low doses of narcotics and/or benzodiazepines and ideally by a physician anesthesiologist.
- Due to their pharmacological profiles, Midazolam, Fentanyl, Propofol and newer Fospropofol remain the most commonly used drugs for intravenous sedation in GI endoscopy. If sedatives are administered by the endoscopist, total dose of Midazolam and Fentanyl should not exceed 5 mg and 100 micrograms, respectively.

3.4 Anesthesia and sedation in pediatric gastrointestinal procedures

In children there are some particular morphological characteristics: the tongue fills the upper airways more than in adults, while the tonsils and adenoids may compromise the airway freedom. In addition, relatively high oxygen consumption in children and larger surface may lead to clinically significant hypoxemia, dehydration and hypothermia if not provided adequate strategies to prevent them. Endoscopy performed especially in children under 10 years of age almost always requires deep sedation with endotracheal intubation. In order to reduce the anxiety caused by the separation from parents and to improve the implementing of an intravenous catheter the physician can orally administer low doses of midazolam (0.5 mg/kg) (Liacouras *et al* 1998) before the procedure, together with special counseling for children (Mahajan *et al* 1998).

In performing GI endoscopy in children, two types of sedation are being used: minimal sedation and deep anesthesia. In deep sedation, combinations of midazolam, fentanyl and ketamine are useful; however they must be used with caution (Balsells *et al*, 1997; Bahal-O'Mara *et al*, 1994; Bouchut *et al*, 1997, Green *et al*, 2001). Even with the extensive experience of the anesthetist, there is a risk of laryngo-spasm (Green *et al*, 2001) and hypoxia (Cote *et al*, 2000). Usually the recovery is prolonged and Naloxone and Flumazenil antagonists are often required (Balsells *et al*, 1997; Lamireau *et al*, 1998). General anesthesia performed by an anesthesiologist offers safe conditions to perform endoscopic procedures in children, however, is perceived by the endoscopists as being expensive and requiring specialized personnel. However, short-term action of certain drugs such as propofol (Khoshoo *et al*, 2003) and sevoflurane (Montes & Bohn, 2000) can reduce costs because the post-anesthesia recovery time is shorter. Colonoscopy performed in pediatric patients causes pain due to bowel distension, which may alert the endoscopist about a possible perforation of the colon. General anesthesia reduces colonic tone and, therefore, deep sedation may be safer in this

respect. Conscious sedation can be used successfully in cooperating children, using combinations of opioids with benzodiazepines or nitrous oxide alone (Michaud, 2005; Annequin *et al*, 2000).

Minimum anesthesia for upper endoscopy in children does not require tracheal intubation as diagnostic procedures may take no longer than 10 minutes and cause no significant unpleasant effects afterwards. Two key points for the safety of the procedure should be highlighted: the endoscope can compress and obstruct the trachea (especially in infants) (Barbi *et al*, 2006; Casfeel *et al*, 1992) and achalasia is very dangerous (esophageal residue should be drained before any sedation or anesthesia in children). Tracheal intubation is much safer in these two situations. The anesthesia for endoscopy lasting 15-30 min, can be more easily done with a device for airway intubation, such as masks (Rauch&Brener, 2003) or laryngeal mask with a special port for the endoscope (Lopez-Gil *et al*, 2006).

Minimum anesthesia with an initial bolus of propofol (2-3 mg/kg) will suppress the gag reflex enough to allow easy introduction of the endoscope, and smaller doses as boluses or continuous infusion are also effective later on (Barbi *et al*, 2006; Khoshoo *et al*, 2003; Kaddu *et al*, 2002, Walker *et al*, 2003, Perera *et al*, 2006). Usually, no additional opioids are needed.

In children sedated endoscopy, two aspects are important: the safety of a technique in which gastric contents are not aspirated and the endoscopist's training and skill in using propofol. Barbi *et al* reported their experience in propofol use in a study involving 811 children who received upper endoscopies (Barbi *et al*, 2006). Desaturation ($SpO_2 < 90\%$) occurred in 16% of cases, but this was reduced to only 3% when supplemental oxygen was administered. Major desaturation occurred in six cases, three of them being infants (12% of all children). They required assisted ventilation by face mask and endoscopy was abandoned in three cases. None of them aspirated the gastric content in their lungs and did not require tracheal intubation. The anesthesia was made by non-anesthetists in all cases. In a study with a smaller group of 57 children, Perera *et al* (pediatric anesthesiologists) have successfully used Propofol, only a child was given suxamethonium to remove the occurring laryngospasm (Perera *et al*, 2006). Tracheal intubation was not necessary.

3.5 Anesthesia and sedation in pregnant and lactating women

Some small retrospective trials regarding intravenous sedation during upper and lower gastrointestinal endoscopy in pregnant women showed that there were no maternal or fetal adverse effects, nor did it associate congenital malformations (Capella *et al*, 1996a, 1996b). Notwithstanding this goal, endoscopy should be avoided during pregnancy, and if possible, especially during the first trimester of pregnancy to avoid potential teratogenic effects during embryogenesis. However there should be some therapeutic safety guidelines or protocols which include a minimum set of safety procedures in case of use of anesthetic care especially in emergency situations. In pregnant patients with higher gestational age, a lying position should be avoided because the uterus could compress the aorta and inferior vena cava.

Frequently administered benzodiazepines (midazolam and diazepam), fentanyl and propofol are all classified by the Australian Drug Evaluation Committee (Australian Drug Evaluation Committees [ADECE], 1999) as part of category "C", as their pharmaceutical effects may cause potential harmful effects on the human fetus or neonate without causing malformations.

In regard to women who are breastfeeding and want sedation for endoscopic procedures, data are limited. It is recommended that patients who received Midazolam should not breastfeed for at least 4 hours after its administration. Breastfeeding restriction time after propofol administration is not well documented, although it is likely to be higher because the maximum concentration in breast milk occurs in 4 to 5 hours after administration. Hence, it is indicated to collect breast milk in a container and subsequently throw it a few hours before resuming breastfeeding. Fentanyl administration is not considered a contraindication for breastfeeding (Qureshi *et al*, 2005).

4. Conclusion

Sedation practices are extremely varied, having individual particularities throughout different regions of the world. Cultural, religious, ethical and procedural aspects come into play, dictating the use of a particular type of sedation, exclusion of different classes of agents, or even banning sedation altogether. Even though no or minimum sedation do provide higher safety and shorter follow-up periods, there is an increased tendency, especially in Western patients, to expect some level of sedation. As well as different levels of sedation, different levels of qualification of the individual providing the sedation are expected, depending on the location and the type of the medical unit and the complexity of the investigation.

In current practice, a various number of sedative agents are used, each with their respective indications and strengths, balanced by a series of unwelcome side-effects and inerrant shortcomings. Particularities such as age, gender, associated conditions, even weight and height, should be taken into consideration when choosing a particular type of sedation level or determining the use of a specific agent. Pediatric gastrointestinal endoscopies present particularities when considering sedation, given the distinctive morphological features of the young, developing body. Particular conditions, such as pregnancy or lactation, should come into play as well, restricting the use of particular agents with proven or suspected effects on the fetus or infant.

5. References

- Annequin, D.; Carbajal, R.; Chauvin, P.; Gall, O.; Tourniaire, B. & Murat, I. (2000). Fixed 50% nitrous oxide oxygen mixture for painful procedures: a French survey. *Pediatrics*, Vol.105, No.4, (April 2000), E 47, ISSN 1098-4275
- American Society of Anesthesiologists (2002). Task force on sedation and analgesia by non-anesthesiologists. Practice guidelines for sedation and analgesia by non-anesthesiologists. *Anesthesiology*, Vol.96, No.4 (April 2002), pp. 1004-1017, ISSN 0003-3022
- Amorós A, Aparicio JR, Garmendia M, Casellas JA, Martínez J, Jover R. Deep sedation with propofol does not precipitate hepatic encephalopathy during elective upper endoscopy. *Gastrointest. Endosc.* 2009; 70: 262-8.
- Arrowsmith, J.; Gerstman, B.; Fleischer, D. & Benjamin S.B. (1991). Results from the American Society for Gastrointestinal Endoscopy/U.S. Food and Drug Administration collaborative study on complication rates and drug use during gastrointestinal endoscopy. *Gastrointestinal Endoscopy*, Vol.37, No.4, (July-August 1991), pp. 421-427, ISSN 1097-6779

- Australian Drug Evaluation Committee. (1999). Prescribing Medicines in Pregnancy. In An Australian Categorisation of Risk of Drug Use in Pregnancy, 4th edn. 1999. Available from URL: <http://www.tga.gov.au/docs/pdf/medpreg.pdf>
- Bahal-O'Mara, N.; Nahata, M.C.; Murray, R.D.; Linscheid, T.R.; Fishbein, M.; Heitlinger, L.A.; Li, B.U.; McClung H.J.; Potter, C. & Lininger, B. (1994). Sedation with meperidine and midazolam in pediatric patients undergoing endoscopy. *European Journal of Clinical Pharmacology*, Vol. 47, No.4, pp. 319-323, ISSN 1432-1041
- Bailey, P.; Pace, N.; Ashburn, M.; Moll J. W.; East K.A. & Stanley T.H. (1990). Frequent hypoxemia and apnea after sedation with midazolam and fentanyl. *Anesthesiology*, Vol.73, No.5 (November 1990), pp. 826-830, ISSN 0003-3022
- Balsells, F.; Wyllie, R.; Kay, M. & Steffern R. (1997). Use of conscious sedation for lower and upper gastrointestinal endoscopic examinations in children, adolescents, and young adults: a twelve-year review. *Gastrointestinal Endoscopy*, Vol. 45, No.5, (May 1997), pp. 375-380, ISSN 1097-6779
- Barbi, E.; Petaros, P.; Badina, L.; Pahor, T.; Giuseppin, I.; Biasotto, E.; Martelossi, S.; Di Leo, G.; Sarti, A. & Ventura A. (2006). Deep sedation with propofol for upper gastrointestinal endoscopy in children, administered by specially trained pediatricians: a prospective case series with emphasis on side effects. *Endoscopy*, Vol. 38, No.4, (April 2006), pp. 368-375, ISSN 1438-8812
- Bell, G. D. (2004). Preparation, premedication, and surveillance. *Endoscopy*, Vol.36, No.1, (January 2004), pp. 23-31, ISSN 1438-8812
- Bonta PI, Kok MF, Bergman JJ *et al.* Conscious sedation for EUS of the esophagus and stomach: a double-blind, randomized, controlled trial comparing midazolam with placebo. *Gastrointest. Endosc.* 2003; 57: 842-7.
- Bouchut, J.C.; Godard, J.; Lachaux, A. & Diot, N. (2001). Deep sedation for upper gastrointestinal endoscopy in children. *Journal of Pediatric Gastroenterology and Nutrition*, Vol. 30, No.5, (May 2000), pp. 477-485, ISSN 1536-4801
- Brill JV. Endoscopic sedation: legislative update and implications for reimbursement. *Gastrointest. Endosc. Clin. North Am.* 2008; 18: 665-78.
- Buhren, M.; Maitre, P.O.; Crevoisier, C. & Stanski D.R. (1995). Pharmacodynamic modeling of the electroencephalographic effects of midazolam and diazepam. *Clinical Pharmacology & Therapeutics*, Vol.48, No.5, pp. 555-567, ISSN 1532-6535
- Bytzer, P. & Lindeberg, B. (2007). Impact of an information video before colonoscopy on patient satisfaction and anxiety – a randomized trial. *Endoscopy*, Vol. 39, No.8, (August 2007), pp. 710-714, ISSN 1438-8812
- Cappell, M.S.; Colon, V.J. & Sidhom, O.A. (1996). A study at 10 medical centers of the safety and efficacy of 48 flexible sigmoidoscopies and 8 colonoscopies during pregnancy with follow-up of fetal outcome and with comparison to control groups. *Digestive Diseases Sciences*, Vol.41, pp. 2353-2361, ISSN 1573-2568
- Cappell, M.S.; Colon, V.J.; & Sidhom, O.A. (1996). A study of eight medical centers of the safety and clinical efficacy of esophagogastroduodenoscopy in 83 pregnant females with follow-up of fetal outcome with comparison control groups. *The American Journal of Gastroenterology*, Vol.91, pp. 1963-1967, ISSN 1572-0241
- Casfeel, H.B.; Fiedorek, S.C. & Kiel, E.A (1992). Arterial blood oxygen desaturation in infants and children during upper gastrointestinal endoscopy. *Gastrointestinal Endoscopy*, Vol. 36, No.5, (September 1990), pp. 448-449, ISSN 1097-6779

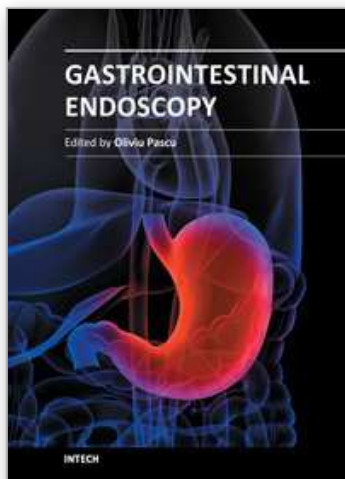
- Clarke AC, Chiragakis L, Hillman LC, Kaye GL. Sedation for endoscopy: the safe use of propofol by general practitioner sedationists. *Med. J. Aust.* 2002; 176: 158-61.
- Clarke, A.C. (2007). Consent for direct access endoscopy. *Journal of Gastroenterology and Hepatology*, Vol.22, No.12, (December 2007), pp. 2051-2052, ISSN 1440-1746
- Cohen, L.B.; Hightower, C.D.; Wood, D.A.; Miller, K.M. & Aisenberg, J.(2004) Moderate level sedation during endoscopy: a prospective study using low-dose propofol, meperidine/fentanyl, and midazolam. *Gastrointestinal Endoscopy*, Vol.59, No.7, (June 2004), pp. 795-803, ISSN 1097-6779
- Coté, C.J.; Karl, H.W.; Notterman, D.A.; Weinberg, J.A. & McCloskey, C.(2000). Adverse sedation events in pediatrics: analysis of medications used for sedation. *Pediatrics*, Vol.106, No.4, pp. 633-644, ISSN 1098-4275
- Conlong P, Rees W. The use of hypnosis in gastroscopy: a comparison with intravenous sedation. *Postgrad. Med. J.* 1999; 75: 223-5.
- Evans LT, Saberi S, Kim HM, Elta GH, Schoenfeld P. Pharyngeal anesthesia during sedated EGDs: is "the spray" beneficial? A meta-analysis and systematic review. *Gastrointest. Endosc.* 2006; 63: 761-6.
- Ertekin C, Kiylioglu N, Tarlaci S, Keskin A, Aydogdu I. Effect of mucosal anaesthesia on oropharyngeal swallowing. *Neurogastroenterol. Motil.* 2000; 12: 567-72.
- Faigel, D.O.; Baron, T.H.; Goldstein, J.L.; Hirota, W.K.; Jacobson, B.C.; Johanson, J.F.; Leighton, J.A.; Mallory, J.S.; Peterson, K.A.; Waring, J.P.; Fanelli, R.D. & Wheeler-Harbaugh, J. (2002). Guidelines for the use of deep sedation and anesthesia for GI endoscopy. *Gastrointestinal Endoscopy*, Vol.56, No.5, (November 2002), pp. 613-617, ISSN 1097-6779
- Faulx AL, Vela S, Das A *et al.* The changing landscape of practice patterns regarding unsedated endoscopy and propofol use: a national Web survey. *Gastrointest. Endosc.* 2005; 62: 9-15.
- Fechner J, Ihmsen H, Hatterscheid D, *et al.* Comparative pharmacokinetics and pharmacodynamics of the new propofol prodrug GPI 15715 and propofol emulsion. *Anesthesiology* 2004; 101: 626-39
- Gibiansky E, Struys MM, Gibiansky L, *et al.* AQUAVAN injection, a water-soluble prodrug of propofol, as a bolus injection: a phase I dose-escalation comparison with DIPRIVAN (part 1): pharmacokinetics. *Anesthesiology* 2005; 103: 718-29.
- Gourlay, G.K.; Kowalski, S.R.; Plummer, J.L.; Cousins, M.J. & Armstrong, P.J. (1988). Fentanyl blood concentration-analgesic response relationship in the treatment of postoperative pain. *Anesthesia & Analgesia*, Vol.67, No.4, (April 1988), pp. 329-337, ISSN 1526-7598
- Green, S.M.; Klooster, M.; Harris, T.; Lynch, E.L. & Rothrock, S.G. (2001). Ketamine sedation for pediatric gastroenterology procedures. *Journal of Pediatric Gastroenterology and Nutrition*, Vol. 32, No.1, (January 2001), pp. 26-33, ISSN 1536-4801
- Hayee B, Dunn J, Loganayagam A *et al.* Midazolam with meperidine or fentanyl for colonoscopy: results of a randomized trial. *Gastrointest. Endosc.* 2009; 69 (Suppl. 3): 681-7.
- Huang, R. & Eisen, G.M. (2004). Efficacy, safety, and limitations in current practice of sedation and analgesia, *Gastrointestinal Endoscopy Clinics of North America*, Vol.14, No.2 (April 2004), pp. 269-288

- Holm C, Christensen M, Schulze S, Rosenberg J. Effect of oxygen on tachycardia and arterial oxygen saturation during colonoscopy. *Eur. J. Surg.* 1999; 165: 755-8.
- Horn, E. & Nesbit, S.A. (2004). Pharmacology and pharmacokinetics of sedatives and analgesics. *Gastrointestinal Endoscopy Clinics of North America*, Vol.14, No.2 (April 2004), pp. 247-268
- Ionescu, D. (2005). Intravenous anesthetics, In: *Clinical anesthesia*, I. Acalovschi, (Ed.), 209-210, Clusium, ISBN 973-555-443-7, Cluj-Napoca, Romania
- Kaddu, R.; Bhattacharya, D.; Metriyakool, K.; Thomas, R. & Tolia, V. (2002). Propofol compared with general anesthesia for pediatric GI endoscopy: is propofol better? *Gastrointestinal Endoscopy*, Vol.55, No.1, (January 2002), pp. 27-32, ISSN 1097-6779
- Kane GC, Hoehn SM, Behrenbeck TR, Mulvagh SL. Benzocaine-induced methemoglobinemia based on the Mayo Clinic experience from 28 478 transesophageal echocardiograms: incidence, outcomes, and predisposing factors. *Arch. Int. Med.* 2007; 167: 1977-82.
- Kanto J, Gepts E. Pharmacokinetic implications for the clinical use of propofol. *Clin. Pharmacokinet.* 1989; 17: 308-26.
- Kulling D, Orlandi M, Inauen W. Propofol sedation during endoscopic procedures: how much staff and monitoring are necessary? *Gastrointest. Endosc.* 2007; 66: 443-9.
- Kern, S.E.; Xie, G.; White, J.L. & Egan, T.D. (2004). A response surface analysis of propofol-remifentanyl pharmacodynamic interaction in volunteers. *Anesthesiology*, Vol.100, No.6 (June 2004), pp. 1373-1381, ISSN 0003-3022
- Khoshoo, V.; Thoppil, D.; Landry, L.; Brown, S. & Ross, G. (2003). Propofol versus midazolam plus meperidine for sedation during ambulatory esophagogastroduodenoscopy. *Journal of Pediatric Gastroenterology and Nutrition*, Vol. 37, No.2, (August 2003), pp. 146-149, ISSN 1536-4801
- Lamireau, T.; Dubreuil, M. & Daconceicao, M. (1998). Oxygen saturation during esophagogastroduodenoscopy in children: general anesthesia versus intravenous sedation. *Journal of Pediatric Gastroenterology and Nutrition*, Vol. 27, No.2, (August 1998), pp. 172-175, ISSN 1536-4801
- Lazzaroni M, Bianchi Porro G. Preparation, premedication, and surveillance. *Endoscopy* 2001; 33: 103-8
- Levy, G. (1989). Impact of pharmacodynamic variability on drug delivery. *Advanced Drug Delivery Reviews*, Vol.33, No.3, (September 1998), pp. 201-206
- Liacouras, C.A.; Mascarenhas, M.; Poon, C. & Wenner, W.J. (1998). Placebo-controlled trial assessing the use of oral midazolam as a premedication to conscious sedation for pediatric endoscopy. *Gastrointestinal Endoscopy*, Vol.47, No.6, (June 1998), pp. 455-460, ISSN 1097-6779
- Lopez-Gil, M.; Brimacombe, J. & Diaz-Reganon, G. (2006). Anesthesia for pediatric gastroscopy: a study comparing the ProSeal laryngeal mask airway with nasal cannulae. *Pediatric Anesthesia*, Vol 16, No.10, (October 2006), pp. 1032-103, ISSN 1460-9592
- Louis S, Bassett M, Clarke A, Thomson A. Anaesthetic support for endoscopic retrograde cholangio pancreatograms in Australian teaching hospitals. *Int. Med. J.* 2004; 34: 368-9.
- Lytle, J. (2005). Anesthesia in ambulatory surgery, In: *Clinical anesthesia*, I. Acalovschi, (Ed.), 842-843, Clusium, ISBN 973-555-443-7, Cluj-Napoca, Romania

- Mahajan, L.; Wyllie, R.; Steffen, R.; Kay, M.; Kitaoka, G.; Dettorre, J.; Sarigol, S. & McCue, K. (1998). The effects of a psychological preparation program on anxiety in children and adolescents undergoing gastrointestinal endoscopy. *Journal of Pediatric Gastroenterology & Nutrition*, Vol.27, No.2, pp.161-165, ISSN 0277-2116
- Michaud L. (2005). Sedation for diagnostic upper gastrointestinal endoscopy: a survey of the Francophone Pediatric Hepatology, Gastroenterology, and Nutrition Group. *Endoscopy*, Vol.37, No.2, pp. 167-170, ISSN 1438-8812
- Montes, R.G. & Bohn, R.A. (2000). Deep sedation with inhaled sevoflurane for pediatric outpatient gastrointestinal endoscopy. *Journal of Pediatric Gastroenterology and Nutrition*, Vol. 31, No.1, (May 2000), pp. 41-46, ISSN 1536-4801
- Morrow JB, Zuccaro G Jr, Conwell DL, *et al.* Sedation for colonoscopy using a single bolus is safe, effective, and efficient: a prospective, randomized, double-blind trial. *Am J Gastroenterol* 2000; 95: 2242-7.
- Padmanabhan U, Leslie K. Australian anaesthetists' practice of sedation for gastrointestinal endoscopy in adult patients. *Anaesth. Intensive Care* 2008; 36: 436-41.
- Paspatis, G.; Manolaraki, M.; Xirouchakis, G. Papanikolaou, N.; Chlouverakis, G. & Gritzali, A. (2002). Synergistic sedation with midazolam and propofol versus midazolam and pethidine in colonoscopies: a prospective, randomized study. *The American Journal of Gastroenterology*, Vol.24, No.8, (August 2002), pp. 1963-1967, ISSN 1572-0241
- Pena LR, Mardini HE, Nickl NJ. Development of an instrument to assess and predict satisfaction and poor tolerance among patients undergoing endoscopic procedures. *Dig. Dis. Sci.* 2005; 50: 1860-71.
- Perera, C.; Strandvik, G.F.; Malik, M. & Sen, S. (2006). Propofol anesthesia is an effective and safe strategy for pediatric endoscopy. *Pediatric Anesthesia*, Vol.16, No.2, (February 2006), pp. 220-221, ISSN 1460-9592
- Pruitt R, Cohen LB, Gibiansky E, *et al.* A randomized, open-label, multicenter, dose-ranging study of sedation with Aquavan injection (GPI 15714) during colonoscopy. *Gastrointest Endosc* 2005; 61: AB111.
- Qadeer MA, Rocio Lopez A, Dumot JA, Vargo JJ. Risk factors for hypoxemia during ambulatory gastrointestinal endoscopy in ASA I-II patients. *Dig. Dis. Sci.* 2009; 54: 1035-40.
- Qureshi, W.A.; Rajan, E. & Adler, D.G. (2005). American Society for Gastrointestinal Endoscopy. ASGE Guideline: guidelines for endoscopy in pregnant and lactating women. *Gastrointestinal Endoscopy*, Vol.61, No.3, (March 2005), pp. 357-362, ISSN 1097-6779
- Rauch, R.Y. & Brener, C.E. (2003). Airway management for pediatric esophagogastroduodenoscopy using an endoscopy mask. *Anesthesia & Analgesia*, Vol. 96, No.1, (January 2003), pp. 303-304, ISSN 1526-7598
- Reimann, F., Samson, U., Derad, I.; Fuchs, M.; Schiefer, B. & Stange, E.F. (2000) Synergistic sedation with low-dose midazolam and propofol for colonoscopies *Endoscopy*, Vol. 32, No.3, (March 2000), pp. 239-244, ISSN 1438-8812
- Ristikankare M, Hartikainen J, Heikkinen M, Julkunen R. Is routine sedation or topical pharyngeal anesthesia beneficial during upper endoscopy? *Gastrointest. Endosc.* 2004; 60: 686-94.

- Rex, D.K. (2006). Moderate sedation for endoscopy: sedation regimens for non-anaesthesiologists. *Alimentary Pharmacology & Therapeutics*, Vol.24, No.2, (July 2006), pp.163-171, ISSN 1365-2036
- Rex DK, Deenadayalu VP, Eid E *et al.* Endoscopist-directed administration of propofol: a worldwide safety experience. *Gastroenterology* 2009 137: 1229-37.
- Rex, D.K.; Heuss, L.T.; Walker, J.A. & Qi, R. (2005). Trained registered nurses/endoscopy teams can administer propofol safely for endoscopy. *Gastroenterology*, Vol.129, No.5, (November 2005), pp.1384-139, ISSN 1528-0012
- Roseveare, C.; Seavell, C.; Patel, P.; Criswell, J.; Kimble, J.; Jones, C. & Shepherd H. (1998). Patient-controlled sedation and analgesia, using propofol and alfentanil, during colonoscopy: a prospective randomized controlled trial. *Endoscopy*, Vol. 30, No.9, (November 1998), pp. 768-773, ISSN 1438-8812
- Rudner, R.; Jalowiecki, P.; Kawecki, P.; Gonciarz, M.; Mularczyk, A. & Petelenz, M. (2003). Conscious analgesia/sedation with remifentanyl and propofol versus total intravenous anesthesia with fentanyl, midazolam, and propofol for outpatient colonoscopy. *Gastrointestinal Endoscopy*, Vol.57, No.6, (May 2003), pp. 657-663, ISSN 1097-6779
- Seifert, H.; Schmitt, T.; Gultekin, T.; Caspary, L. & Wehrmann, S. (2000). Sedation with propofol plus midazolam versus propofol alone for interventional endoscopic procedures: a prospective, randomized study. *Alimentary Pharmacology & Therapeutics*, Vol.14, No.9, (September 2000), pp.1207-1214, ISSN 1365-2036
- Sitcai, N. (2004). Outside hospital anesthesiology practice. *Guide for private medicine*, Callisto, ISBN 973-87261-0-7
- Snyder SH, Enna SJ, Young AB. Brain mechanisms associated with therapeutic actions of benzodiazepines: focus on neurotransmitters. *Am. J. Psychiatry* 1977; 134: 662-5
- Stark RD, Binks SM, Dutka VN, O'Connor KM, Arnstein MJ, Glen JB. A review of the safety and tolerance of propofol ('Diprivan'). *Postgrad. Med. J.* 1985; 61 (Suppl. 3): 152-6.
- Thomson, A.; Andrew, G. & Jones, D.B. (2010). Optimal sedation for gastrointestinal endoscopy: Review and recommendations. *Journal of Gastroenterology and Hepatology*, Vol.25, No.3, (March 2010), pp. 469-478, ISSN 1440-1746
- Tsai MS, Su YH, Liang JT, Lai HS, Lee PH. Patient factors predicting the completion of sedation-free colonoscopy. *Hepatogastroenterology* 2008; 55: 1606-8.
- Trapani G, Altomare C, Liso G, Sanna E, Biggio G. Propofol in anesthesia. Mechanism of action, structure-activity relationships, and drug delivery. *Curr. Med. Chem.* 2000; 7: 249-71.
- Tu RH, Grewall P, Leung JW, *et al.* Diphenhydramine as an adjunct to sedation for colonoscopy: a double-blind randomized, placebo-controlled study. *Gastrointest Endosc* 2006; 63: 87-94.
- VanNatta ME, Rex DK. Propofol alone titrated to deep sedation versus propofol in combination with opioids and/or benzodiazepines and titrated to moderate sedation for colonoscopy. *Am. J. Gastroenterol.* 2006; 101: 2209-17.
- Yi SY, Shin JE. Midazolam for patients undergoing upper gastrointestinal endoscopy: a prospective, single-blind and randomized study to determine the appropriate amount and time of initiation of endoscopy. *J. Gastroenterol. Hepatol.* 2005; 20: 1873-9.
- Zuccaro G Jr. Sedation and analgesia for GI endoscopy. *Gastrointest Endosc* 2006; 63: 95-96.

- Walker, J.A.; McIntyre, R.D.; Schleinitz, P.F.; Jacobson, K.N.; Haulk, A.A.; Adesman, P.; Tolleson, S.; Parent, R.; Donnelly, R. & Rex, D.K. (2003). Nurse-administered propofol sedation without anesthesia specialists in 9152 endoscopic cases in an ambulatory surgery center. *American Journal of Gastroenterology*, Vol. 98, No.8, (August 2003), pp. 1744-1750, ISSN 1572-0241
- Wang, T.H. & Lin, J.T. (1999). Worldwide use of sedation and analgesia for upper intestinal endoscopy. *Gastrointestinal Endoscopy* Vol.50, No.6, (December 1999), pp. 888-889, ISSN 1097-6779
- Wood, M. (1989). Variability of human drug response. *Anesthesiology*, Vol.71, No.5 (November 1989), pp. 631-634, ISSN 0003-3022



Gastrointestinal Endoscopy

Edited by Prof. Oliviu Pascu

ISBN 978-953-307-385-9

Hard cover, 272 pages

Publisher InTech

Published online 19, July, 2011

Published in print edition July, 2011

Endoscopy has had a major impact in the development of modern gastroenterology. By using different data it provided a better understanding of pathogenic mechanisms, described new entities and changed diagnostic and therapeutic strategies. Meanwhile, taking advantage of many technical advances, endoscopy has had a developed spectacularly. Video-endoscopes, magnification, confocal and narrow-band imaging endoscopes, endoscopic ultrasounds and enteroscopes emerged. Moreover, endoscopy has surpassed its function as an examination tool and it became a rapid and efficient therapeutic tool of low invasiveness. InTech Open Access Publisher selected several known names from all continents and countries with different levels of development. Multiple specific points of view, with respect to different origins of the authors were presented together with various topics regarding diagnostic or therapeutic endoscopy. This book represents a valuable tool for formation and continuous medical education in endoscopy considering the performances or technical possibilities in different parts of the world.

How to reference

In order to correctly reference this scholarly work, feel free to copy and paste the following:

Mitrut Paul, Mitrut Anca Oana, Streba Liliana, Calina Daniela and Salplahta Daniel (2011). Sedation Related to Gastrointestinal Endoscopy, *Gastrointestinal Endoscopy*, Prof. Oliviu Pascu (Ed.), ISBN: 978-953-307-385-9, InTech, Available from: <http://www.intechopen.com/books/gastrointestinal-endoscopy/sedation-related-to-gastrointestinal-endoscopy>

INTECH
open science | open minds

InTech Europe

University Campus STeP Ri
Slavka Krautzeka 83/A
51000 Rijeka, Croatia
Phone: +385 (51) 770 447
Fax: +385 (51) 686 166
www.intechopen.com

InTech China

Unit 405, Office Block, Hotel Equatorial Shanghai
No.65, Yan An Road (West), Shanghai, 200040, China
中国上海市延安西路65号上海国际贵都大饭店办公楼405单元
Phone: +86-21-62489820
Fax: +86-21-62489821

© 2011 The Author(s). Licensee IntechOpen. This is an open access article distributed under the terms of the [Creative Commons Attribution 3.0 License](https://creativecommons.org/licenses/by/3.0/), which permits unrestricted use, distribution, and reproduction in any medium, provided the original work is properly cited.

IntechOpen

IntechOpen