

We are IntechOpen, the world's leading publisher of Open Access books Built by scientists, for scientists

6,900

Open access books available

185,000

International authors and editors

200M

Downloads

Our authors are among the

154

Countries delivered to

TOP 1%

most cited scientists

12.2%

Contributors from top 500 universities



WEB OF SCIENCE™

Selection of our books indexed in the Book Citation Index
in Web of Science™ Core Collection (BKCI)

Interested in publishing with us?
Contact book.department@intechopen.com

Numbers displayed above are based on latest data collected.
For more information visit www.intechopen.com



Pseudohypoparathyroidism in Children

Benjamin U. Nwosu

*University of Massachusetts Medical School
Worcester, Massachusetts,
USA*

1. Introduction

Albright hereditary osteodystrophy (AHO) is a genetic syndrome characterized by a distinctive set of developmental and skeletal defects that may easily be misdiagnosed as exogenous obesity in children. There are very few publications detailing the comprehensive management of children and adolescents with this disorder. This chapter provides a comprehensive discussion of the various aspects of this disorder. At the end, the reader should be able to: (1) List the clinical features of Albright hereditary osteodystrophy, (2) Identify the genetic and molecular abnormalities of AHO, (3) List the clinical features of pseudohypoparathyroidism type 1a (PHP 1a), (4) Describe the management of children and adolescents with PHP 1a.

2. Genetics of Albright hereditary osteodystrophy

The molecular basis for AHO is a heterozygous mutation of the gene that encodes the G-stimulatory subunit ($G_s\alpha$) of guanine nucleotide-binding protein—the *GNAS* gene—that is located at chromosome 20q13.2. This type of mutation leads to a loss of expression or function of the $G_s\alpha$ which impairs the transmission of stimulatory signals to adenylate cyclase, limiting cyclic AMP generation necessary for hormone action (Lietman, 2008).

The *GNAS* gene is subject to imprinting. Patients with AHO who have *GNAS* mutations on maternally inherited alleles manifest resistance to multiple hormones, such as parathyroid hormone (PTH), thyroid stimulating hormone (TSH), gonadotropins, growth-hormone-releasing hormone (GHRH), and glucagon (Brickman, 1986; Weinstein, 2004). These defects lead to PHP 1a. On the other hand, patients with AHO who have *GNAS* mutations on paternally inherited alleles have only the phenotypic features of AHO without hormonal resistance, a condition termed pseudopseudohypoparathyroidism (PPHP) (Lietman, 2008). PHP 1b is an autosomal dominant disorder that is associated with the presence of hormone resistance that is limited to PTH target organs, normal $G_s\alpha$ activity, and the absence of features of AHO (Levine, 1983). PHP 1c is associated with features of AHO, resistance to multiple hormones, and normal *GNAS* activity while PHP type 2 is associated with renal resistance to PTH action and the absence of AHO phenotype (Levine, 2000).

More than 50 different loss-of-function mutations of *GNAS* have been reported in more than 70 affected individuals. Pohlenz *et al.* (Pohlenz, 2003) have reported a missense mutation, which results in the amino-acid substitution (Lys338Asn) in codon 338 of exon 12 of the *GNAS* gene associated with congenital hypothyroidism in AHO, though they did

not state the precise mechanism by which this mutation leads to hypothyroidism. A Q35X mutation in exon 1 has been associated with growth-hormone deficiency (Germain-Lee, 2003), whereas a *de novo*, missense mutation, W281R in exon 11, has been linked to progressive osseous heteroplasia, a rare, autosomal-dominant condition that presents in childhood as dermal ossification that progresses to involve deep skeletal muscles (Chan, 2004). Germain-Lee *et al.* (Germain-Lee, 2003) identified a patient with a Q29X mutation, and Nwosu *et al.* (Nwosu, 2009) reported the association of Q29X mutation with a phenotype that includes Albright hereditary osteodystrophy, morbid obesity, acanthosis nigricans, insulin resistance, growth-hormone deficiency, hypothyroidism, and subcutaneous calcification.

3. Clinical features

3.1 General appearance

The developmental and skeletal defects that characterize AHO include short stocky physique (Figure 1a), round face, mental deficiency, heterotopic ossification, and brachymetaphalangism (Weinstein, 1993) (Figure 1 b, c). AHO is present in types 1a and 1c and PPHP. Hormonal resistance is seen in PHP 1a, PHP 1c and PHP type 2.

3.2 Stature

The prevalence of short adult height in PHP 1a is reported to be as high as 80% (Nagant de Deuschaisnes, 2007). Although height during childhood may be normal, adult height is often subnormal. The reason for the short stature in PHP 1a is multifactorial and includes GHRH resistance and chondrocytic dysfunction as explained below in section 3.8.

3.3 Mental deficiency

Learning disabilities and psychomotor retardation have been described in PHP 1a (Chen, 2005). The mechanism of this mental deficiency is unknown and early institution of thyroid hormone replacement does not seem to prevent the development of mental deficiency (Weisman, 1985). There appears to be a correlation with reduced G_{α} since patients with PHP 1b do not present with mental deficiency in spite of equivalent serum calcium and phosphate abnormalities (Wilson, 1994). This mental deficiency is generally mild, but ranges from moderately severe delay to normal educational ability.

3.4 Ectopic calcification

In patients with PHP 1a, soft-tissue calcification has been reported in various body parts, especially in the subcutaneous tissues, and rarely in the brain and cardiac septum (Schuster, 1992). Persistent hyperparathyroidism is believed to have some causative role in this abnormal calcification. This situation is distinct from progressive osseous heteroplasia (Chan, 2004), a rare condition that causes dermal ossification.

3.5 Brachymetaphalangism

The hand abnormalities in the PHP and PPHP forms of AHO are indistinguishable (Poznanski, 1977). The malformations involve both the phalanges and metacarpals and are often symmetrical (Wilson, 1994) (Figure 1b). Shortening of the distal phalanx of the thumb is estimated to occur in 75% of AHO patients (Poznanski, 1977). Similar shortening occurs in the metacarpals. Metacarpal shortening often involves the fourth and the fifth

metacarpals(Poznanski, 1977; Steinbach, 1965). Shortening of the metatarsals (Figure 1c), especially the third and fourth, is seen in about 70% of persons with AHO(Steinbach, 1966).

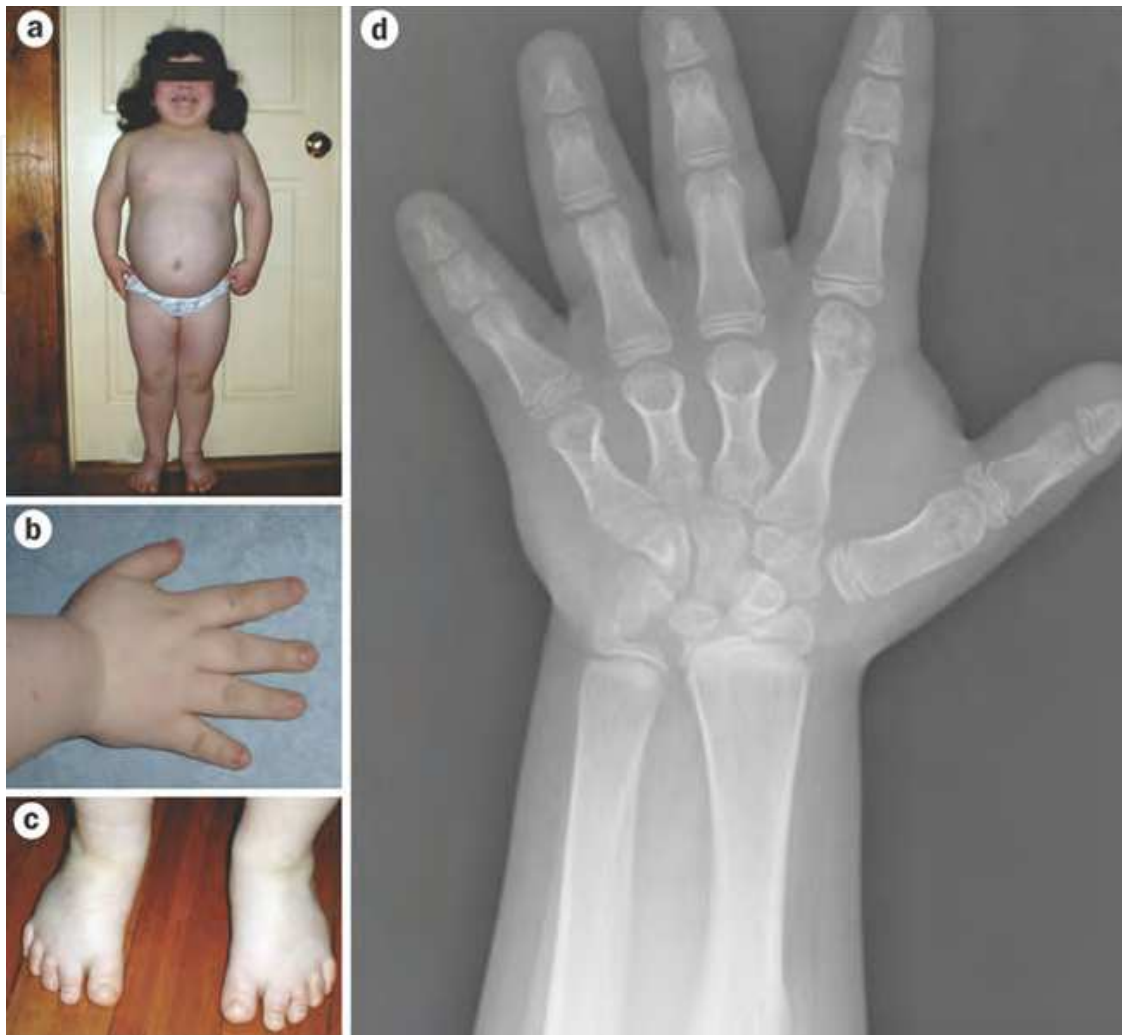

Fig. 1. a, b, c, d. Features suggestive of Albright hereditary osteodystrophy(Nwosu, 2009)
 Figure 1 | Features suggestive of Albright hereditary osteodystrophy in the patient. a | Photo of a patient at 5 years of age showing an obese phenotype, round face, broad chest, short neck and digits consistent with pseudohypoparathyroidism type 1a. b | Photo of the patient's hand at 5 years of age showing brachyphalangism of the fingers, especially the third through fifth digits. c | Photo of the patient's feet at 5 years of age showing brachyphalangism of the toes. d | Bone age radiograph of the patient at 7 years of age showing premature fusion of the epiphyses of the distal phalanges of the thumb, midphalanges of both the second and fifth fingers, and shortening of the third through fifth metacarpals. Her bone age was read as 13 years at a chronological age of 7 years and 8 months.

3.6 Obesity and insulin resistance

Insulin resistance has not been described in patients with PHP 1a, and acanthosis nigricans is not a typical finding in AHO. Germain-Lee et al(Germain-Lee, 2003) reported a patient with acanthosis nigricans in a cohort of 13 patients with PHP 1a who had normal

hemoglobin A1c and fasting insulin levels. Nwosu et al (Nwosu, 2009) described a child with PHP 1a with acanthosis nigricans and insulin resistance (Figure 2).

A patient with Albright hereditary osteodystrophy-like syndrome with a normal *GNAS* gene that was complicated by type 2 diabetes mellitus with severe insulin resistance, growth-hormone deficiency and diabetes insipidus has been described (Sakaguchi, 1998). Long *et al.* (Long, 2007) reported that obesity is a more prominent feature of PHP 1a than of PPHP, and that severe obesity is characteristic of PHP 1a. They postulated that paternal imprinting of *G_sα* occurs in the hypothalamus such that maternal, but not paternal, *G_sα* mutations lead to loss of the melanocortin signaling cascade, which is important for signaling satiety. This loss of satiety signaling then leads to greater alteration in energy balance and notably greater insulin resistance in individuals with PHP 1a (as shown in Figure 2) than in those with PPHP.

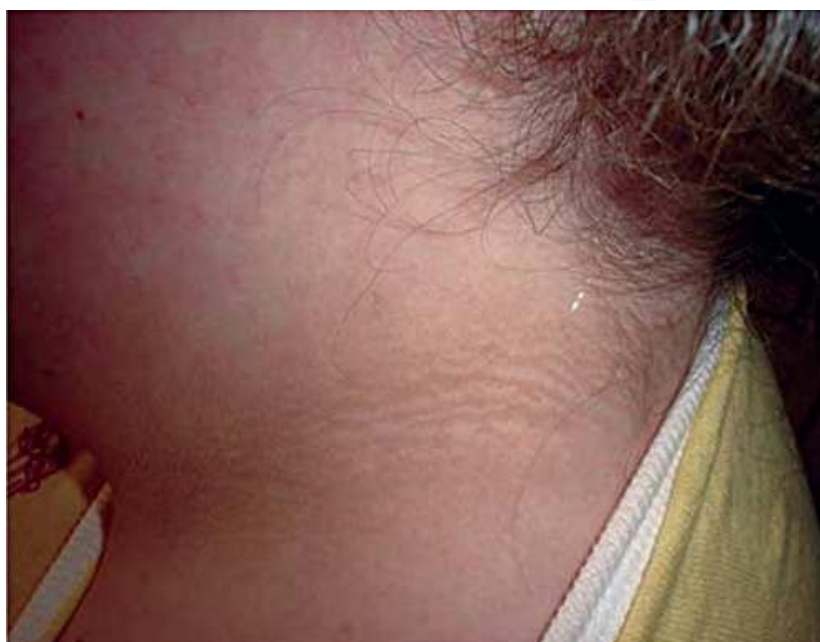

Fig. 2. Acanthosis nigricans of the neck folds in a patient with Albright Hereditary Osteodystrophy (Nwosu, 2009)

The insulin receptor belongs to a large class of tyrosine kinase receptors, and is structurally distinct from the heptahelical *G_s* receptors. The development of insulin resistance in the patient shown in Figure 2 most probably resulted from the combined effects of obesity, growth-hormone treatment, a family history of type 2 diabetes mellitus, and abnormal melanocortin signaling, as noted above. Obesity is the most common cause of insulin resistance in children (Caprio, 2002). It is postulated to represent a subclinical inflammatory state that promotes the production of proinflammatory factors, such as interleukin 6 and tumor necrosis factor, which are involved in the pathogenesis of insulin resistance (Bastard, 2006). Growth hormone antagonizes insulin's effects on glucose metabolism by inhibiting insulin-induced glucose uptake through the inhibition of insulin receptor substrate-2-associated phosphatidylinositol-3-kinase activity, without affecting glucose transporter 4 translocation (Sasaka-Suzuki N, 2009). A family history of type 2 diabetes mellitus conveys not only heritable genetic information, but also reveals familial behaviors and social norms that may exacerbate the individual's risk for insulin resistance and frank diabetes (Meigs, 2008).

3.7 Biochemical profile

The biochemical profile in patients with PHP 1a shows evidence of PTH resistance, with elevated serum concentrations of PTH and phosphate, and low or normal serum levels of ionized calcium. Serum TSH concentrations are elevated from infancy indicating TSH resistance at the receptor-complex level. Subnormal peak growth-hormone levels of $<7.5 \mu\text{g/l}$ are commonly found when growth-hormone stimulation tests are carried out (Scott, 1995). Serum gonadotropins are either normal or slightly elevated in women with AHO despite their hypoestrogenic status (Namnoum, 1998). This is believed to be due to partial resistance to gonadotropins in the granulosa and theca cells of the ovary (Namnoum, 1998).

3.8 Bone age and other skeletal and radiologic features

The bone ages of children with PHP 1a are more advanced than would be expected for their stage of sexual maturation. Premature epiphyseal fusion occurs selectively in the hands and feet of affected patients (de Wijn, 1982; Steinbach, 1966). Furthermore, the phalanges of patients either lack epiphyses or have epiphyses that are partially fused when they first develop, which makes accurate assessments of bone age very difficult (Steinbach, 1966). This abnormal epiphyseal fusion is postulated to result from the loss of $G_s\alpha$, which induces resistance to parathyroid-hormone-related protein which, in turn, promotes premature differentiation of proliferating chondrocytes into hypertrophic chondrocytes (Kobayashi, 2002; Tavella, 2004; van der Eerden, 2000). This series of events leads to early closure of the growth plate and limb-reduction defects. Despite early fusion of the epiphyses in the phalanges, the epiphyses of long bones may remain open, thus an increase in height with growth-hormone therapy is still possible.

Other radiological features of PHP 1a in children include rickets which results from low levels of 1,25-dihydroxyvitamin D as a result of PTH resistance (Wilson, 1994). Generalized osteoporosis and osteitis fibrosa cystica (Burnstein, 1985; Steinbach, 1966) can be seen, and these pathologies are suggestive of some preservation of the skeletal remodeling response to the raised levels of circulating PTH (Kerr, 1987). Some of the skeletal abnormalities associated with AHO include shortened ulna, radial and tibial bowing, coxa vara, coxa valga and caudal narrowing of interpedicular distance (Wilson, 1994).

3.9 Hormonal defects and manifestations

In addition to the AHO phenotype, biochemical and hormonal derangements in PHP 1a lead to characteristic patterns of presentation. PHP 1a is associated with resistance to multiple hormones, such as PTH, TSH, gonadotropins, growth-hormone-releasing hormone, and glucagon (Brickman, 1986; Weinstein, 2004).

PHP 1a accompanied by growth-hormone deficiency was first described in 1995 (Scott, 1995). The short stature of patients with PHP 1a results from a combination of several factors, such as epiphyseal defects and resistance to GHRH (Scott, 1995). This hormone resistance results in the inability of GHRH to stimulate pituitary somatotropes to produce growth hormone. Many patients with PHP 1a present with subclinical hypothyroidism in infancy (Pohlenz, 2003; Scott, 1995), as a result of resistance to TSH action. Resistance to PTH action could lead to hypocalcemia which could be complicated by hypocalcemic seizures, and/or muscle spasms. Resistance to the actions of the gonadotropins results in hypogonadism or menstrual irregularities in women with PHP 1a. The mechanism of this reproductive dysfunction is believed to be due to a partial resistance of the theca and granulosa cells of the ovary to gonadotropins due to deficient $G_s\alpha$ activity (Namnoum, 1998).

Whereas resistance to PTH, TSH, growth-hormone-releasing hormone, follicle-stimulating hormone, and luteinizing hormone may lead to clinical manifestations, the blunted cyclic AMP response to glucagon documented by Brickman *et al.* (Brickman, 1986) in patients with PHP 1a is apparently subclinical, as the glucose response is intact.

4. Differential diagnosis

The differential diagnoses of a child with this AHO phenotype include exogenous obesity, Cushing syndrome, severe hypoparathyroidism, Prader-Willi syndrome, and Laurence-Moon-Biedl-Bardet syndrome.

The generalized metacarpal and phalangeal shortening characteristics of acrodysostosis has been observed in cases of AHO (Ablow, 1977). Acrodysostosis presents with similar features as AHO including short stature, brachymetaphalangism, advanced bone age, mental deficiency and other radiologic features. However, cutaneous ossification does not occur in acrodysostosis, and pronounced nasal hypoplasia is a distinguishing feature of acrodysostosis, but has been described in PHP 1a (Ablow, 1977).

Turner syndrome and multiple familial exostoses are associated with short stature and metacarpal shortening but are easily distinguished from AHO (Wilson, 1994).

A diagnosis is usually reached by reviewing patient's family history, establishing the components of the AHO phenotype, such as short fourth metacarpals, and connecting these findings to the existing hormonal defects such as a history of subclinical hypothyroidism or parathyroid hormone resistance.

5. Treatment and management

The defect in PHP 1a leads to resistance to multiple hormones that mediate their actions through cyclic AMP (Spiegel, 1982). These include PTH, TSH, growth-hormone-releasing hormone, gonadotropins, glucagon, and possibly TSH-releasing hormone (Balavoine, 2008). Patients with $G_{s\alpha}$ deficiency could, therefore, develop hypothyroidism, hypogonadism, growth-hormone deficiency, and pseudohypoparathyroidism, depending on the degree of $G_{s\alpha}$ activity in specific tissues (Scott, 1995).

5.1 Hypoparathyroidism

The initial medical management of all patients with severe, symptomatic hypocalcemia should be with intravenous calcium. The recommended initial dose for newborn babies, infants and children is 0.5–1.0 ml/kg of 10% calcium gluconate administered over 5 min. Administration of oral calcium and 1α -hydroxylated vitamin D metabolites, such as calcitriol, is recommended for patients with symptomatic hypocalcemia. The goals of therapy are to maintain serum total and ionized calcium levels within the reference range and to reduce PTH levels to near normal. This normalization is important because elevated PTH levels in patients with PHP 1a could cause increased bone remodeling and lead to secondary hyperparathyroid bone disease (Abraham, 2007).

5.2 Growth-hormone deficiency

Some children with PHP 1a have hypothalamic growth-hormone deficiency and may benefit from therapy with recombinant human growth hormone to achieve optimal adult height. In those patients in whom defective growth-hormone secretion is suspected, the epiphyseal

defects, commonly mischaracterized as bone-age advancement, should not disqualify these children from being considered for growth-hormone therapy. In addition to its effect on statural growth, growth-hormone therapy also seems to improve body composition in patients with PHP 1a (Nwosu, 2009).

5.3 Hypothyroidism

Most patients with PHP 1a present with subclinical hypothyroidism before the onset of hypocalcemia. Hypothyroidism is treated with thyroid hormone replacement using levothyroxine at age-appropriate and weight-appropriate doses. The aim of management is to normalize serum concentrations of TSH and free T₄.

5.4 Hypogonadism

Common reproductive dysfunctions in persons with PHP 1a include delayed puberty, oligomenorrhea and infertility (Abraham, 2007). Each condition requires age-appropriate therapy; for example, low-dose estrogenic formulations are used to induce puberty in adolescent girls with delayed puberty.

5.5 Obesity and insulin resistance

Patients with PHP 1a who also have a family history of type 2 diabetes mellitus may have familial risk factors for development of insulin resistance, prediabetes and type 2 diabetes mellitus. Growth-hormone therapy improves body composition, but may worsen insulin resistance. Lifestyle modifications should be incorporated in the management of patients with PHP 1a phenotype who may be at risk of metabolic syndrome. Early introduction of oral insulin-sensitizing agents, such as metformin, may be necessary when lifestyle modification is ineffective, especially in patients with prediabetes.

6. Conclusion

Accurate understanding of the features of AHO will prevent its misdiagnosis as exogenous obesity. Children diagnosed with PHP 1a should be further evaluated for associated endocrinopathies, such as resistance to growth-hormone-releasing hormone, which may lead to growth-hormone deficiency. Preliminary data suggest that the short stature in patients with PHP 1a may be ameliorated with growth-hormone therapy in some cases (Scott, 1995). The advanced bone age seen in PHP 1a is due to a chondrocytic signaling defect, and not due to excess production of sex hormones; therefore, bone-age advancement should not preclude affected children from being considered for growth-hormone therapy. However, a combination of growth-hormone therapy, family history of type 2 diabetes mellitus, and obesity in these children might lead to metabolic complications, such as insulin resistance, prediabetes and type 2 diabetes mellitus.

7. Future directions

A comprehensive management of a child with PHP 1a must address the controversies surrounding authorization of growth hormone therapy for these patients. This is because most health insurance carriers decline authorization for GH therapy in these patients because of the apparent bone age advancement that affects the digital bones but not the long bones.

It is equally important to address increasing weight gain in these patients as they are at risk for obesity and its co-morbidities. Even though insulin resistance is not part of the syndrome, there are increasing reports of worsening insulin resistance in these patients which predisposes them to frank diabetes mellitus. This is due to the synergistic effects of prevalent obesity and the pre-existing AHO phenotype.

The presence of delayed puberty may indicate LH and FSH resistance in these patients. There is no clear protocol for initiating sex hormone therapy in these patients. Most pediatric endocrinologists address this problem by adopting similar therapeutic modalities for the induction of the development of secondary sexual characteristics as in patients with Turner syndrome.

Most patients with PHP 1a have variable levels of mental deficiency. It is important to address this problem very early in life by recommending additional classroom supervision, and in severe cases, instituting an individualized educational plan.

In summary, a comprehensive management of a patient with PHP 1a includes a thorough assessment for associated hormonal defects, the obese phenotype and its comorbidities, and the degree of intellectual deficiency.

8. Acknowledgement


We thank Ms. Jessica Kowaleski for her clerical assistance. This work was supported in part by a grant to Dr Nwosu by the Faculty Scholars Diversity Program, University of Massachusetts Medical School.

9. References

- Ablow, R. C., Hsia, Y. E., & Brandt, I. K. (1977). Acrodysostosis coinciding with pseudohypoparathyroidism and pseudo-pseudohypoparathyroidism. *AJR Am J Roentgenol*, 128(1), 95-99.
- Abraham, M. R., & Khadori, R. K. (2007). Pseudohypoparathyroidism. *eMedicine*, <http://www.emedicine.com/med/TOPIC1940.HTM>.
- Balavoine, A. S., Ladsous, M., Velayoudom, F. L., Vlaeminck, V., Cardot-Bauters, C., d'Herbomez, M., & Wemeau, J. L. (2008). Hypothyroidism in patients with pseudohypoparathyroidism type ia: Clinical evidence of resistance to tsh and trh. *Eur J Endocrinol*, 159(4), 431-437.
- Bastard, J. P., Maachi, M., Lagathu, C., Kim, M. J., Caron, M., Vidal, H., Capeau, J., & Feve, B. (2006). Recent advances in the relationship between obesity, inflammation, and insulin resistance. *Eur Cytokine Netw*, 17(1), 4-12.
- Brickman, A. S., Carlson, H. E., & Levin, S. R. (1986). Responses to glucagon infusion in pseudohypoparathyroidism. *J Clin Endocrinol Metab*, 63(6), 1354-1360.
- Burnstein, M. I., Kottamasu, S. R., Pettifor, J. M., Sochett, E., Ellis, B. I., & Frame, B. (1985). Metabolic bone disease in pseudohypoparathyroidism: Radiologic features. *Radiology*, 155(2), 351-356.
- Caprio, S. (2002). Insulin resistance in childhood obesity. *J Pediatr Endocrinol Metab*, 15 Suppl 1, 487-492.

- Chan, I., Hamada, T., Hardman, C., McGrath, J. A., & Child, F. J. (2004). Progressive osseous heteroplasia resulting from a new mutation in the *gnas1* gene. *Clin Exp Dermatol*, 29(1), 77-80.
- Chen, Y. J., Shu, S. G., & Chi, C. S. (2005). Pseudohypoparathyroidism: Report of seven cases. *Acta Paediatr Taiwan*, 46(6), 374-380.
- de Wijn, E. M., & Steendijk, R. (1982). Growth and maturation in pseudohypoparathyroidism: A longitudinal study in 5 patients. *Acta Endocrinol (Copenh)*, 101(2), 223-226.
- Germain-Lee, E. L., Groman, J., Crane, J. L., Jan de Beur, S. M., & Levine, M. A. (2003). Growth hormone deficiency in pseudohypoparathyroidism type 1a: Another manifestation of multihormone resistance. *J Clin Endocrinol Metab*, 88(9), 4059-4069.
- Kerr, D., & Hosking, D. J. (1987). Pseudohypoparathyroidism: Clinical expression of pth resistance. *Q J Med*, 65(247), 889-894.
- Kobayashi, T., Chung, U. I., Schipani, E., Starbuck, M., Karsenty, G., Katagiri, T., Goad, D. L., Lanske, B., & Kronenberg, H. M. (2002). Pthrp and indian hedgehog control differentiation of growth plate chondrocytes at multiple steps. *Development*, 129(12), 2977-2986.
- Levine, M. A. (2000). Clinical spectrum and pathogenesis of pseudohypoparathyroidism. *Rev Endocr Metab Disord*, 1(4), 265-274.
- Levine, M. A., Downs, R. W., Jr., Moses, A. M., Breslau, N. A., Marx, S. J., Lasker, R. D., Rizzoli, R. E., Aurbach, G. D., & Spiegel, A. M. (1983). Resistance to multiple hormones in patients with pseudohypoparathyroidism. Association with deficient activity of guanine nucleotide regulatory protein. *Am J Med*, 74(4), 545-556.
- Lietman, S. A., Goldfarb, J., Desai, N., & Levine, M. A. (2008). Preimplantation genetic diagnosis for severe albright hereditary osteodystrophy. *J Clin Endocrinol Metab*, 93(3), 901-904.
- Long, D. N., McGuire, S., Levine, M. A., Weinstein, L. S., & Germain-Lee, E. L. (2007). Body mass index differences in pseudohypoparathyroidism type 1a versus pseudopseudohypoparathyroidism may implicate paternal imprinting of *galpha(s)* in the development of human obesity. *J Clin Endocrinol Metab*, 92(3), 1073-1079.
- Meigs, J. B., Shrader, P., Sullivan, L. M., McAteer, J. B., Fox, C. S., Dupuis, J., Manning, A. K., Florez, J. C., Wilson, P. W., D'Agostino, R. B., Sr., & Cupples, L. A. (2008). Genotype score in addition to common risk factors for prediction of type 2 diabetes. *N Engl J Med*, 359(21), 2208-2219.
- Nagant de Deuschaisnes, C., Krane, SM. (2007). *Hypoparathyroidism* (3rd ed.). San Diego: Academic Press.
- Namnoum, A. B., Merriam, G. R., Moses, A. M., & Levine, M. A. (1998). Reproductive dysfunction in women with albright's hereditary osteodystrophy. *J Clin Endocrinol Metab*, 83(3), 824-829.
- Nwosu, B. U., & Lee, M. M. (2009). Pseudohypoparathyroidism type 1a and insulin resistance in a child. *Nat Rev Endocrinol*, 5(6), 345-350.
- Pohlenz, J., Ahrens, W., & Hiort, O. (2003). A new heterozygous mutation (I338N) in the human *galpha* (*gnas1*) gene as a cause for congenital hypothyroidism in albright's hereditary osteodystrophy. *Eur J Endocrinol*, 148(4), 463-468.

- Poznanski, A. K., Werder, E. A., Giedion, A., Martin, A., & Shaw, H. (1977). The pattern of shortening of the bones of the hand in php and pphp--a comparison with brachydactyly e, turner syndrome, and acrodysostosis. *Radiology*, 123(3), 707-718.
- Sakaguchi, H., Sanke, T., Ohagi, S., Iiri, T., & Nanjo, K. (1998). A case of albright's hereditary osteodystrophy-like syndrome complicated by several endocrinopathies: Normal α gene and chromosome 2q37. *J Clin Endocrinol Metab*, 83(5), 1563-1565.
- Sasaka-Suzuki N, A. K., Ogata T, Kasahara K. (2009). Gh inhibition of glucose uptake in adipocytes occurs without affecting glut-4 translocation thorough an irs-2pi 3-kinase-dependent pathway. *J. Biol. Chem.*
- Schuster, V., & Sandhage, K. (1992). Intracardiac calcifications in a case of pseudohypoparathyroidism type ia (php-ia). *Pediatr Cardiol*, 13(4), 237-239.
- Scott, D. C., & Hung, W. (1995). Pseudohypoparathyroidism type ia and growth hormone deficiency in two siblings. *J Pediatr Endocrinol Metab*, 8(3), 205-207.
- Spiegel, A. M., Levine, M. A., Aurbach, G. D., Downs, R. W., Jr., Marx, S. J., Lasker, R. D., Moses, A. M., & Breslau, N. A. (1982). Deficiency of hormone receptor-adenylate cyclase coupling protein: Basis for hormone resistance in pseudohypoparathyroidism. *Am J Physiol*, 243(1), E37-42.
- Steinbach, H. L., Rudhe, U., Jonsson, M., & Young, D. A. (1965). Evolution of skeletal lesions in pseudohypoparathyroidism. *Radiology*, 85(4), 670-676.
- Steinbach, H. L., & Young, D. A. (1966). The roentgen appearance of pseudohypoparathyroidism (ph) and pseudo-pseudohypoparathyroidism (pph). Differentiation from other syndromes associated with short metacarpals, metatarsals, and phalanges. *Am J Roentgenol Radium Ther Nucl Med*, 97(1), 49-66.
- Tavella, S., Biticchi, R., Schito, A., Minina, E., Di Martino, D., Pagano, A., Vortkamp, A., Horton, W. A., Cancedda, R., & Garofalo, S. (2004). Targeted expression of shh affects chondrocyte differentiation, growth plate organization, and sox9 expression. *J Bone Miner Res*, 19(10), 1678-1688.
- van der Eerden, B. C., Karperien, M., Gevers, E. F., Lowik, C. W., & Wit, J. M. (2000). Expression of indian hedgehog, parathyroid hormone-related protein, and their receptors in the postnatal growth plate of the rat: Evidence for a locally acting growth restraining feedback loop after birth. *J Bone Miner Res*, 15(6), 1045-1055.
- Weinstein, L. S., Liu, J., Sakamoto, A., Xie, T., & Chen, M. (2004). Minireview: Gnas: Normal and abnormal functions. *Endocrinology*, 145(12), 5459-5464.
- Weinstein, L. S., & Shenker, A. (1993). G protein mutations in human disease. *Clin Biochem*, 26(5), 333-338.
- Weisman, Y., Golander, A., Spirer, Z., & Farfel, Z. (1985). Pseudohypoparathyroidism type 1a presenting as congenital hypothyroidism. *J Pediatr*, 107(3), 413-415.
- Wilson, L. C., & Trembath, R. C. (1994). Albright's hereditary osteodystrophy. *J Med Genet*, 31(10), 779-784.



Contemporary Aspects of Endocrinology

Edited by Dr. Evanthia Diamanti-Kandarakis

ISBN 978-953-307-357-6

Hard cover, 454 pages

Publisher InTech

Published online 30, November, 2011

Published in print edition November, 2011

This book aims to provide readers with a general as well as an advanced overview of the key trends in endocrine disorders. While covering a variety of topics ranging from thyroid carcinogenesis and pituitary adenomas to adrenal tumors and metabolic bone disease, this book also focuses on more specific issues not yet fully elucidated (e.g. the molecular pathways involved in thyrotropin beta gene regulation or monogenic phosphate balance disorders). Readers of different fields and background will have the opportunity to update their knowledge and more importantly to clarify areas of uncertainty and controversies in several topics of endocrine disorders.

How to reference

In order to correctly reference this scholarly work, feel free to copy and paste the following:

Benjamin U. Nwosu (2011). Pseudohypoparathyroidism in Children, Contemporary Aspects of Endocrinology, Dr. Evanthia Diamanti-Kandarakis (Ed.), ISBN: 978-953-307-357-6, InTech, Available from: <http://www.intechopen.com/books/contemporary-aspects-of-endocrinology/pseudohypoparathyroidism-in-children>

INTECH
open science | open minds

InTech Europe

University Campus STeP Ri
Slavka Krautzeka 83/A
51000 Rijeka, Croatia
Phone: +385 (51) 770 447
Fax: +385 (51) 686 166
www.intechopen.com

InTech China

Unit 405, Office Block, Hotel Equatorial Shanghai
No.65, Yan An Road (West), Shanghai, 200040, China
中国上海市延安西路65号上海国际贵都大饭店办公楼405单元
Phone: +86-21-62489820
Fax: +86-21-62489821

© 2011 The Author(s). Licensee IntechOpen. This is an open access article distributed under the terms of the [Creative Commons Attribution 3.0 License](https://creativecommons.org/licenses/by/3.0/), which permits unrestricted use, distribution, and reproduction in any medium, provided the original work is properly cited.

IntechOpen

IntechOpen