

We are IntechOpen, the world's leading publisher of Open Access books Built by scientists, for scientists

6,900

Open access books available

185,000

International authors and editors

200M

Downloads

Our authors are among the

154

Countries delivered to

TOP 1%

most cited scientists

12.2%

Contributors from top 500 universities



WEB OF SCIENCE™

Selection of our books indexed in the Book Citation Index
in Web of Science™ Core Collection (BKCI)

Interested in publishing with us?
Contact book.department@intechopen.com

Numbers displayed above are based on latest data collected.
For more information visit www.intechopen.com



Monogenic Phosphate Balance Disorders

Helge Raeder, Silje Rafaelsen and Robert Bjerknes
*Department of Clinical Medicine, University of Bergen,
 Norway*

1. Introduction

The last decade has seen that several of the dominant and recessive forms of hypo- and hyperphosphatemic bone disease have received their molecular explanation. This has led to new insight into the pathophysiology of hypo- and hyperphosphatemic bone disease, as well as the understanding of a bone-kidney axis which operates integrated and in parallel with the classical parathyroid-kidney axis in the regulation of phosphorus content in the body. In addition, it has led to the recognition of a Janus face of some of the involved genes, showing both hyper- and hypofunction, dependent on the nature of the mutation. In this book chapter, we will present an update on the emerging insight of monogenic hypo- and hyperphosphatemic disorders.

2. Genetic mechanisms and pathophysiology

Hypophosphatemia may lead to bone or dental disease resulting from decreased mineralization (calcification) of bone or dental matrix or osteoid. The simultaneous blood calcium levels will also influence the degree of mineralization. Hypophosphatemia leads to rickets in children or to osteomalacia in adults. In many of the hypophosphatemic conditions, there is also an impairment of renal activation of vitamin D, further aggravating disease. The mineralization of teeth can also be affected, and there are clinical forms where bone affection is minimal and the dental disorders dominate.

Hyperphosphatemia may lead to increased mineralization of both bone and non-bone tissues (ectopic calcification) due to an increase in the body content of phosphorus. This results in tumoral calcinosis with calcification of muscles, skin and vessels. The monogenic forms affect the renal handling of phosphorus by various mechanisms resulting from inactivation or activation of the involved genes.

With the advancement of genetic insight and the subsequent possibility to study subjects with mutations and a wide range of phenotypes, a broader phenotypic pattern is recognized. Consequently, we suggest the more appropriate terms of monogenic hypophosphatemia and monogenic hyperphosphatemia for these disorders, and that the specific disorders should be classified according to the affected gene, e.g. *PHEX*-hypophosphatemia and *FGF23*-hyperphosphatemia (Table 1).

We will now provide an overview of the genes directly implicated in monogenic phosphate balance disorders. Please refer to textbooks for a discussion of genes indirectly affecting phosphate balance (i.e. genes leading to defective parathyroid gland development or disrupted PTH receptor function).

Gene	Classical disease name	Suggested new name
<i>PHEX</i>	X-linked dominant hypophosphatemic rickets	<i>PHEX</i> -hypophosphatemia
<i>DMP1</i>	AR hypophosphatemic rickets	<i>DMP1</i> -hypophosphatemia
<i>GALNT3</i>	Familial hyperphosphatemic tumoral calcinosis	<i>GALNT3</i> -hyperphosphatemia
	AD hypophosphatemic rickets	<i>FGF23</i> - hypophosphatemia
<i>FGF23</i>	Familial hyperphosphatemic tumoral calcinosis	<i>FGF23</i> - hyperphosphatemia
<i>FGFR1</i>	Osteogophonic dysplasia with hypophosphatemia	<i>FGFR1</i> - hypophosphatemia
	Hypophosphatemic rickets and hyperparathyroidism	<i>KL</i> -hypophosphatemia
<i>KL</i>	Hyperphosphatemic tumoral calcinosis	<i>KL</i> -hyperphosphatemia
<i>SLC34A1</i>	Hypophosphatemic nefrolithiasis/osteoporosis	<i>SLC34A1</i> -hypophosphatemia
<i>SLC34A3</i>	HHRH	<i>SLC34A1</i> -hypophosphatemia
<i>SLC9A3R1</i>	Hypophosphatemic nephrolithiasis/osteoporosis	<i>SLC9A3R1</i> -hypophosphatemia
<i>ENPP1</i>	AR hypophosphatemic rickets, type 2	<i>ENPP1</i> -hypophosphatemia

Table 1. Overview of genes directly implicated in monogenic phosphate balance disorders AR, autosomal recessive; AD autosomal dominant, HHRH, Hereditary hypophosphatemic rickets with hypercalciuria.

2.1 PHEX

The *PHEX* (Phosphate-regulating endopeptidase homolog, XB; MIM* 300550) gene consists of 22 exons (Sabbagh, Boileau et al. 2003) and was positionally cloned in 1995 (HYP Consortium 1995). This gene is encoding a transmembrane protein and belongs to the type II

integral membrane zinc-dependent endopeptidase family. The gene is expressed in a wide variety of tissues including the kidney with a higher expression in mature osteoblasts and odontoblasts. The substrate for the gene product is not known, but the pathogenesis seems to involve phosphate regulating humoral factors, phosphatonins, where the fibroblast growth factor-23 (FGFR-23) is central (Jonsson, Zahradnik et al. 2003; Juppner 2007; Bastepe and Juppner 2008). (See section 2.11 for a discussion on the physiological and pathophysiological mechanisms involved.) The protein is also believed to be involved in bone and dentin mineralization. Both the whole-body and bone-specific (osteocalcin-promoted inactivation) knockout mouse model of PHEX as well as the spontaneous Hyp mouse model display increased bone production, increased levels of serum FGF23, decreased kidney membrane NPT2 and osteomalacia (Yuan, Takaiwa et al. 2008). Cell studies indicate mechanistic defects both during protein processing in the endoplasmic reticulum and cell membrane (Sabbagh, Boileau et al. 2001) and as abrogated catalytic activity (Sabbagh, Boileau et al. 2003).

There are several mutations associated with PHEX-hypophosphatemia (see the PHEX mutation database: <http://www.phexdb.mcgill.ca/>) and most of the mutations are located in the region encoding the extracellular domain, but there are also examples of pathological mutations in the 5'UTR (Dixon, Christie et al. 1998) and 3'UTR (Ichikawa, Traxler et al. 2008) of the gene.

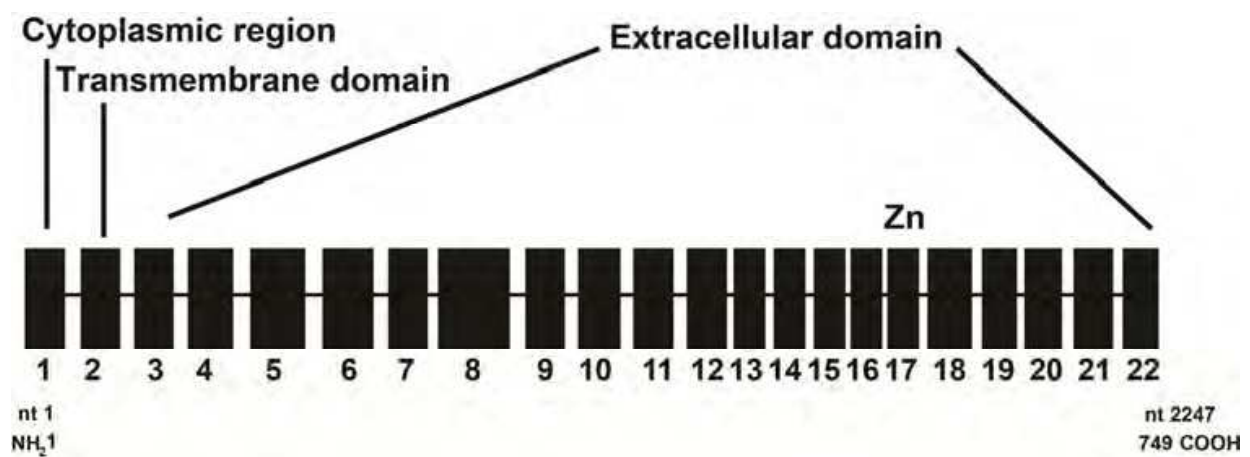


Fig. 1. *PHEX* gene structure and the corresponding encoded regions. Adapted from (Sabbagh, Boileau et al. 2003).

There is no clear genotype-phenotype correlation (Holm, Nelson et al. 2001). There is a slight dominance of familiar mutations (showing co-segregation with disease in a pedigree) to *de novo* mutations (sporadic) reported in literature (Holm, Nelson et al. 2001). The penetrance is high, although there are examples of non-penetrance (Gaucher, Walrant-Debray et al. 2009). The expressivity varies (Brame, White et al. 2004).

2.2 DMP1

The *DMP1* gene (dentin matrix acidic phosphoprotein 1; MIM* 600980) gene consists of 6 exons on chromosome 4q21, and was first implicated in a phosphate balance disorder in 2006 Lorenz-Depiereux, Bastepe et al. 2006). *DMP1* is highly expressed in osteocytes, and is a member of the 'SIBLING' (small integrin binding ligand n-linked glycoprotein) family of non-collagenous extracellular matrix proteins involved in bone mineralization (Huq, Cross

et al. 2005). The *DMP1* knockout model displays rickets and osteomalacia with isolated renal phosphate wasting associated with elevated FGF23 levels and normocalciuria (Feng, Ward et al. 2006). In humans, homozygous or compound heterozygous mutations in *DMP1* leads to hypophosphatemic rickets with elevated FGF23, isolated phosphate wasting, and no evidence of hypercalciuria. The exact relation between *DMP1* and FGF23 levels is not known, but in vitro studies have shown that vitamin D increases the expression of both (Farrow, Davis et al. 2009).

There are only a few reported mutations in the literature (Feng, Ward et al. 2006; Lorenz-Depiereux, Bastepe et al. 2006; Farrow, Davis et al. 2009; Koshida, Yamaguchi et al. 2010; Makitie, Pereira et al. 2010; Turan, Aydin et al. 2010), making *DMP1* mutations a rare cause of hypophosphatemic rickets (Gaucher, Walrant-Debray et al. 2009).

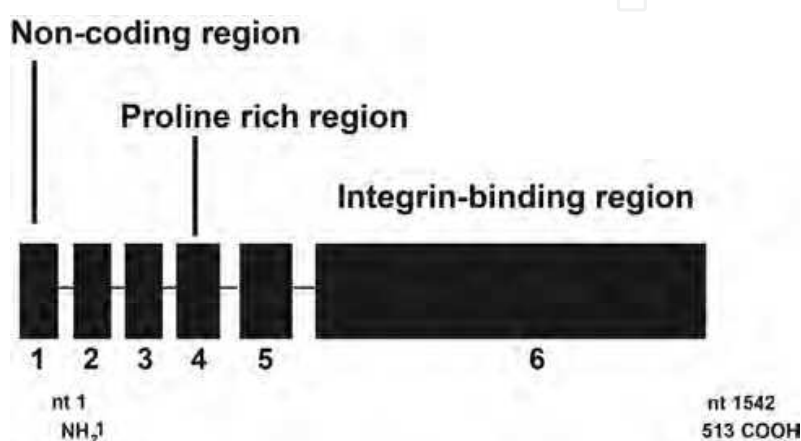


Fig. 2. *DMP1* gene structure and the corresponding encoded regions. Based on (Huq, Cross et al. 2005).

2.3 GALNT3

The O-glycosylation of serine and threonine residues on many glycoproteins depend on enzymatic catalyzation of the reaction UDP-GalNAc + polypeptide-(Ser/Thr)-OH to GalNAc- α -O-Ser/Thr-polypeptide + UDP. GalNAcT3 is one of 24 members in the UDP-GalNAc:polypeptide N-acetylgalactosaminyltransferase protein family involved in this process.

GalNAcT3 is encoded by the *GALNT3* gene (MIM *601756) on chromosome 2q24-q31, which contains 10 exons. GalNAcT3 is thought to protect FGF23 from proteolysis (Kato, Jeanneau et al. 2006) by O-glycosylation, and a deactivating mutation in *GALNT3* will thus lead to increased breakdown of FGF23. Mutations in *GALNT3* were the first to be associated with familial tumoral calcinosis (FTC) (Topaz, Shurman et al. 2004), and are also seen in the closely related disease, the hyperphosphatemic hyperostosis syndrome (HHS). These are the only diseases known to be caused by mutations in the family of UDP-GalNAc:polypeptide N-acetylgalactosaminyltransferases. Although the process of O-glycosylation is important in many tissues, mutations in *GALNT3* lead to a very restricted phenotype with hyperphosphatemia, periarticular calcifications and hyperostosis. This is thought to be explained by functional redundancy of this protein family. In addition to the effects on bone and renal phosphate handling caused by altered FGF23 metabolism, mutations in *GALNT3* are also thought to have direct effect in the process of ectopic calcification in extraosseous tissues (Chefet and Sprecher 2009).

2.4 FGF23

The *FGF23* gene (MIM*605380) on chromosome 12 is composed of 3 exons, and encodes a member of the fibroblast growth factor family. The protein product, FGF23, acts via its receptor FGFR1 (fibroblast growth factor receptor 1, see 2.5), but is also dependent on the co-receptor Klotho (α -Klotho) to exert its functions (see below). Furthermore, FGF23 belongs to the FGF19 family where the two other family members, FGF19 and FGF21, (also binding to FGFR1) are dependent on β -Klotho to exert their functions, illustrating the role of a co-receptor to ensure tissue specificity and function (Kurosu, Choi et al. 2007). FGF23 exerts its physiological effects on the kidney by the downregulation of the *CYP27B1* gene leading to a loss of compensatory increase in 1,25(OH)₂vitamin D levels, and by the endocytosis of the type IIa and IIc Na/phosphate (Pi) cotransporters (Npt2a and Npt2c) from the renal proximal tubular brush border membrane.

Heterozygous activating mutations in the cleavage site RXXR motif of exon 3 of *FGF23*, leads to stabilization and decreased degradation of the FGF23. The clinical phenotype is autosomal dominant hypophosphatemic rickets (Econs, McEnery et al. 1997; 2000).

Homozygous inactivating missense mutations in *FGF23* lead to hyperphosphatemic familial tumoral calcinosis, due to decreased renal excretion of phosphate and increased renal α -hydroxylation of vitamin D (Benet-Pages, Orlik et al. 2005; Ichikawa, Baujat et al. 2010).

2.5 FGFR1

The Fibroblast growth factor receptor 1 gene *FGFR1* (MIM*136315) located on chromosome 8p11 encodes a protein member of the FGFR (1-4) family, where the members are all receptor tyrosine kinases. FGFR1-3 are implicated in skeletal development, and various mutations in the corresponding genes are responsible for a number of skeletal dysplastic syndromes (Passos-Bueno, Wilcox et al. 1999). There are several subclasses of FGFRs, depending on the number of immunoglobulin-like loops and splicing differences in the third loop. FGFR1C combines with Klotho (*KL*) to become the functional receptor for FGF23 (Urakawa, Yamazaki et al. 2006).

Mutations in the *FGFR1C* lead to constitutive activation of the receptor and subsequent downregulation of the expression of the sodium-phosphate co-transporters NaPiIIa and NaPiIIc, as well as the downregulation of the *CYP27B1* gene leading to a loss of compensatory increase in 1,25(OH)₂vitamin D levels (Shimada, Hasegawa et al. 2004).

2.6 KL

Klotho (*KL*) (MIM*604824) is located to chromosome 13q12, comprises 5 exons, and encodes the protein Klotho (also known as α -Klotho), which in mice is considered a hormone with anti-aging properties (Kurosu, Yamamoto et al. 2005). *KL* knockout mice will go through a rapid aging process, and have decreased insulin secretion and increased insulin sensitivity (Kuro-o, Matsumura et al. 1997), while overexpression of *KL* leads to a prolonged life span in mice (Kurosu, Yamamoto et al. 2005). In addition, Klotho has been associated with disturbances of phosphate metabolism, as it is an obligate co-receptor for the binding of FGF23 to FGFR1C. In humans, there are two *KL* transcripts; one encoding a membrane bound protein and one encoding a secreted protein. Human *KL* is expressed mainly in the kidney, and the secreted variant seems to dominate (Matsumura, Aizawa et al. 1998). Recent findings from mouse studies suggest that Klotho has endocrine, paracrine and autocrine effects independent of FGF23 (Hu, Shi et al. 2010).

Inactivating mutations will lead to familial hyperphosphatemic tumoral calcinosis, similar to the phenotypes seen in *GALNT3*-hyperphosphatemia and *FGF23*-hyperphosphatemia (Ichikawa, Imel et al. 2007).

There is also one report of an activating translocation of the *KL* gene, leading to hypophosphatemic rickets with a phenotype similar to *PHEX*-hypophosphatemia but with additional distinctive dysmorphic features of the head (Brownstein, Adler et al. 2008).

2.7 SLC34A1

The solute carrier 34 (*SLC34*) gene family includes the three genes *SLC34A1*, *SLC34A2* and *SLC34A3*, all encoding sodium/phosphate cotransporters. *SLC34A2* encodes the intestinal NaPi-IIb, and will not be further discussed. *SLC34A1* and *SLC34A3* encode the two renal sodium/phosphate cotransporters, and the latter is described in 2.8 section.

The *SLC34A1* (MIM*182309) gene is expressed in the renal proximal tubule, and encodes the type IIa Na/Pi cotransporter (NaPi-IIa), which plays a central role in renal phosphate handling in various animal models. The expression of NaPi-IIa in the brush border membrane is regulated at the post translational level, by endocytosis and lysosomal degradation or microtubular recruitment (Tenenhouse 2005). Both PTH and FGF23 lead to increased endocytosis of NaPi-IIa, and thus decreased reabsorption of Pi from filtered urine, whereas hypophosphatemia and 1,25 dihydroxyvitamin D stimulate phosphate reabsorption (Tenenhouse 2005). There also seems to be a directly regulating effect of dietary Pi on Na/Pi cotransport in proximal tubules, and the existence of an intestinal-renal axis for phosphate regulation has been proposed [review: (Biber, Hernando et al. 2009)]. NaPi-IIa double knockout mice have hypophosphatemia, phosphaturia, elevated 1,25 dihydroxyvitamin D with resulting hypercalcemia, hypercalcuria and nephrocalcinosis/nephrolithiasis (Beck, Karaplis et al. 1998). This phenotype resembles hereditary hypophosphatemic rickets with hypercalcuria (HHRH) seen in humans, which interestingly is not caused by mutations in *SLC34A1*, but rather by mutations in *SLC34A3* (NaPi-IIc) (see 2.8).

In man, a few cases have been described of heterozygous mutations in *SLC34A1*, leading to a syndrome of hypophosphatemia, osteoporosis and nephrolithiasis (Prie, Huart et al. 2002).

2.8 SLC34A3

The human *SLC34A3* (MIM*609826) gene, consists of 13 exons on chromosome 9q34, and homozygous mutations in this gene lead to hereditary hypophosphatemic rickets with hypercalciuria (HHRH) (Bergwitz, Roslin et al. 2006; Lorenz-Depiereux, Benet-Pages et al. 2006). The phenotype of HHRH resembles that of NaPi-IIa knockout mice, but the patients also display rickets or osteomalacia. In animal models the type IIc Na/Pi cotransporter (NaPi-IIc) has been shown to play a more minor role in proximal tubular phosphate resorption than NaPi-IIa. The opposite might be the case in man (Amatschek, Haller et al. 2010).

2.9 SLC9A3R1

The *SLC9A3R1* (MIM*604990) gene on chromosome 17 encodes the protein NHERF1 (sodium/hydrogen exchanger regulatory factor 1), which plays a part in maintaining the cytoskeleton in polarized cells with microvilli, such as renal tubular cells. Three different mutations in *SLC9A3R1* have recently been identified in 7 subjects with hypophosphatemia due to phosphaturia, nephrolithiasis and osteoporosis (Karim, Gerard et al. 2008).

2.10 ENPP1

The *ENPP1* (ectonucleotide pyrophosphatase/phosphodiesterase 1) (MIM*173335) gene on chromosome 6q22-q23 comprises 23 exons and encodes a type II transmembrane glycoprotein ectoenzyme responsible for the generation of inorganic pyrophosphate (PPi). PPi is an inhibitor of hydroxyapatite crystal growth, and also suppress chondrogenesis. In mice, *ENPP1* is expressed in plasma cells, on hepatocytes, renal tubules, salivary duct epithelium, epididymis, capillary endothelium in the brain, and chondrocytes (Harahap and Goding 1988). In man it has been shown that *ENPP1* is expressed in liver, cartilage and bone, and is thought to regulate physiological mineralization processes and pathological chondrocalcinosis (Huang, Rosenbach et al. 1994).

Homozygous mutations in *ENPP1* are known to cause generalized arterial calcifications of infancy (GACI) (Rutsch, Vaingankar et al. 2001; Rutsch, Ruf et al. 2003). Recently, homozygous mutations in *ENPP1* have been shown to cause autosomal recessive hypophosphataemic rickets (Levy-Litan, HersHKovitz et al. 2010). In some families, identical mutations cause GACI in some family members and hypophosphatemic rickets in other family members (Lorenz-Depiereux, Schnabel et al. 2010). Prolonged survival in GACI has been observed in subjects who have simultaneously displayed renal phosphate loss (Rutsch, Boyer et al. 2008).

Mutations in *ENPP1* have also been associated with susceptibility to insulin resistance and obesity (Goldfine, Maddux et al. 2008).

2.11 An integrated model for the physiological and pathophysiological mechanisms in the renal phosphate regulation

Figure 3 shows the integrated physiological and pathophysiological mechanisms in the renal phosphate regulation. The parathyroid-renal axis has been the traditional model explaining how PTH stimulates the renal tubular cells to phosphaturia as a negative feedback loop response to elevated phosphate levels (Figure 3A). In this model PTH acts via its receptor to block the sodium-phosphate co-transporters NaPiIIa and NaPiIIc encoded by the *SLC34A1* and *SLC34A3* genes, respectively. In addition, PTH stimulates the *CYP27B1* gene leading to a compensatory increase in 1,25(OH)₂vitamin D levels as a negative feedback loop to reduced serum levels of 1,25(OH)₂vitamin D and calcium. There is, however, also a PTH-independent pathway where hormonal substances from bone, phosphatonins, stimulate the renal tubular cells to phosphaturia in a negative feedback response to elevated serum phosphate and 1,25(OH)₂vitamin D levels. Recent emerging insight has laid the foundation for this model of a bone-kidney axis (Quarles 2003), where fibroblast growth factor 23 (FGF23) seems to be the central phosphatonin inhibiting phosphate reabsorption and hence inducing phosphaturia (Figure 3B). In contrast to PTH, FGF23 inhibits *CYP27B1* gene leading to an absent compensatory increase in 1,25(OH)₂vitamin D levels, recognized by clinicians as inappropriate normal 1,25(OH)₂vitamin D levels. In the normal state *PHEX* and *DMP1* gene products seem to inhibit FGF23 production, whereas the *GALNT3* gene product seems to stimulate FGF23 production. By interfering with the bone-kidney axis, increased FGF23 levels seem to play a central role in the pathogenesis of *PHEX*-hypophosphatemia (Jonsson, Zahradnik et al. 2003) (Figure 3C) and potentially also *DMP1*-hypophosphatemia (Lorenz-Depiereux, Bastepe et al. 2006; Turan, Aydin et al. 2010) and *FGF23*-hypophosphatemia (Imel, Hui et al. 2007), but the mechanisms are still poorly known (Strom and Juppner 2008). It is also poorly known how increased FGF23 levels in *FGF23*-hyperphosphatemia and *GALNT3*-

hyperphosphatemia explain the opposite condition of hyperphosphatemia (Topaz, Shurman et al. 2004; Benet-Pages, Orlik et al. 2005). A current model postulates that mutations in *PHEX* lead to increased FGF23 production by cancelled *PHEX*-mediated inhibition of FGF23 production (Figure 3 C).

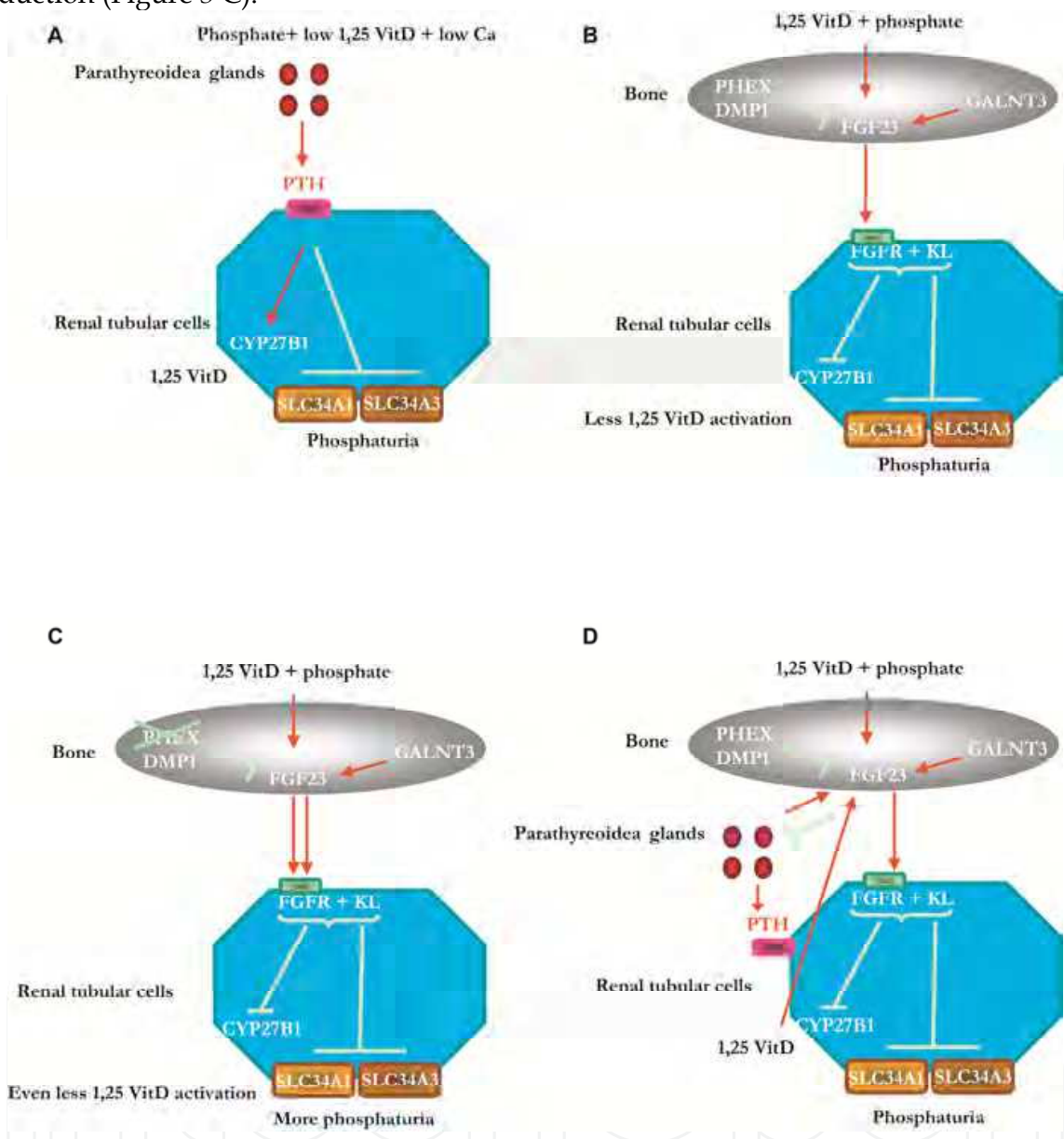


Fig. 3. Physiological and pathophysiological conditions in the phosphate regulation. For sake of clarity, only gene names are depicted and not the corresponding gene products. Adapted from (Bastepe and Juppner 2008; Strom and Juppner 2008).

Both the parathyroid-renal axis and the bone-kidney axis seem to be negative feedback loops where increased serum phosphate levels compared to a biological set value leads to phosphaturia. These two axes are different with respect to 1,25(OH)₂vitamin D: Whereas low 1,25(OH)₂vitamin D levels stimulating 1,25(OH)₂vitamin D activation is the major regulation in the parathyroid-renal axis, high 1,25(OH)₂vitamin D levels inhibiting 1,25(OH)₂vitamin D activation is the major regulation in the bone-kidney axis. Recent work also points to interactions between these feedback loops where FGF23 inhibits PTH,

whereas PTH possibly stimulates FGF23 (Figure 3D). Mutations in genes encoding the sodium-phosphate co-transporters such as *SLC34A1*, *SLC34A3* and *SLC9A3R1* lead to increased phosphaturia but since the $1,25(\text{OH})_2$ vitamin D activation is unaffected, there is a normal compensatory increase in $1,25(\text{OH})_2$ vitamin D levels. Whether gene mutations lead to hypophosphatemia or hyperphosphatemia is dependent on the location of the gene product in the pathways outlined above and whether the mutation is activating or inactivating the affected gene.

3. Diagnostic considerations

The diagnosis of monogenic hypo- or hyperphosphatemia requires the demonstration of affected phosphate balance in patients in which acquired causes of phosphate disturbance have been excluded. A family history of rickets, kidney stones, soft tissue calcification, bone deformities or recurrent fractures, as well as an indication of monogenic inheritance pattern is usually found, unless the patient seems to represent a sporadic case. In the case of hypophosphatemia, there is typically low plasma phosphate, low renal tubular reabsorption of phosphate (% TRP) and tubular threshold maximum for phosphate for glomerular filtration rate (TmP/GFR), raised alkaline phosphatase, normal PTH, and inappropriate and normal $25(\text{OH})$ and $1,25(\text{OH})_2$ vitamin D levels. Moreover, the urinary calcium excretion is normal, whereas X-ray changes may demonstrate rickets or osteomalacia. FGF23 levels are typically high, either due to overproduction or under-catabolism, and in children with rickets, the combined evaluation of FGF23 and PTH leads differential diagnosis in the direction of impaired phosphate homeostasis (high FGF23 and normal PTH) or altered metabolism of vitamin D, calcium or magnesium (low FGF23 and high PTH) (Alon 2010). In the case of hyperphosphatemia, there is usually high plasma phosphate, an inappropriate normal % TRP and TmP/GFR, a low or normal PTH and normal renal function. In some cases, the clinical picture and inheritance pattern will suggest a specific genetic diagnosis, and, in addition, the blood FGF23 levels and hypercalciuria may differentiate between different genetic disorders of phosphate balance, although the clinical role of blood FGF23 levels is at present not fully elucidated.

3.1 PHEX

PHEX-hypophosphatemia (X-linked dominant) is usually a progressive disorder with a typical onset at the age when the child starts to walk. The most common clinical manifestations include genu varus, radiological rickets, short stature, bone pain, dental abscesses and calcification of tendons, ligaments and joint capsules with boys being more severely affected than girls and a wide variation between families (Econs, Samsa et al. 1994; Carpenter 1997; Bastepe and Juppner 2008). Some patients may even have craniosynostosis and spinal stenosis. Many patients suffer from long lasting dental problems, particularly tooth decay and recurrent spontaneous dental abscesses that occur in the absence of a history of trauma or dental decay. Histological findings include high pulp horns, globular dentin, and defects of dentin and enamel. The primary teeth are most commonly affected, as the mineralization process starts in utero. Permanent teeth develop after birth, and adequate treatment improve development in some cases (Batra, Tejani et al. 2006). In children with rickets, a low serum phosphorus level, combined with high serum alkaline phosphatase and normal serum calcium is typical (Carpenter 1997). Urinary leakage of phosphate is demonstrated by low % TRP and TmP/GFR, whereas urinary calcium is normal. The PTH levels are usually normal or slightly

elevated, even before the onset of therapy. The 25(OH)vitamin D is normal, and there is no compensatory increase in 1,25(OH)₂vitamin D levels due to defective renal activation of vitamin D, and, hence, no hypercalciuria. The FGF23 levels are increased (Jonsson, Zahradnik et al. 2003), and since the lower extremities are more severely affected than the other parts of the skeleton, radiographs of the knees and ankles will demonstrate the extent of rickets. The diagnosis of *PHEX*-hypophosphatemia is confirmed by genetic analysis.

3.2 DMP1

DMP1-hypophosphatemia (autosomal recessive) is usually a progressive disorder with a typical onset at the age when the child starts to walk. The condition is rarer than *PHEX*-hypophosphatemia, but is phenotypically quite similar to *PHEX*- and *FGF23*-hypophosphatemia. There is no compensatory increase in 1,25(OH)₂vitamin D levels due to defective renal activation of vitamin D and hence no hypercalciuria. The circulation levels of FGF23 are increased (Feng, Ward et al. 2006). The degree of skeletal abnormalities varies between families (Makitie, Pereira et al. 2010). Some patients also have dental affection, with hypomineralization, enlarged pulp chambers, and decrease in the dentin and enamel layers, which can cause dental abscesses and loss of teeth (Koshida, Yamaguchi et al. 2010; Turan, Aydin et al. 2010).

3.3 GALNT3

GALNT3-hyperphosphatemia is the result of biallelic mutation in the *GALNT3*-gene, and leads to typical tumoral calcinosis (TC) (Topaz, Shurman et al. 2004) or hyperostosis-hyperphosphatemia syndrome (HHS). There are several mutations in the *GALNT3* gene, and the same mutation can lead to TC in some patients and HHS in other (Ichikawa, Baujat et al. 2010). TC is characterized by ectopic calcifications in soft tissues and around large joints, recognized clinically as palpable masses and/or on radiography. Calcifications may also be found in the retina, in blood vessels, as testicular microlithiasis, and there might be dental abnormalities. HHC is characterized by hyperostosis of long bones, seen radiographically as cortical hyperostosis, diaphysitis and periosteal apposition. The biochemical findings in TC and HHC are similar, with elevated serum phosphate levels, increased or normal 1,25(OH)₂vitamin D levels. The levels of serum calcium and parathyroid hormone are normal. Some authors suggest that TC and HHS are clinical variants of the same disease (Ichikawa, Baujat et al. 2010).

3.4 FGF23

FGF23-hypophosphatemia (autosomal dominant) shows a variable age at onset of disease.

The expression of disease varies, and some children may have fracture tendency without skeletal deformities, whereas other children may have only temporary renal phosphate loss (Econs and McEnery 1997). Tooth abscesses and loss also occurs (Imel, Hui et al. 2007).

FGF23-hyperphosphatemia (autosomal recessive) shows typical tumoral calcinosis, or more rarely the hyperostosis-hyperphosphatemia syndrome (Benet-Pages, Orlik et al. 2005).

3.5 FGFR1

FGFR1R-hypophosphatemia is characterized by osteoglophonic dysplasia and can be associated with hypophosphatemia (Farrow, Davis et al. 2006). Clinical features are skeletal

abnormalities leading to dwarfism and facial abnormalities similar to achondroplasia. There is often failure of tooth eruption, and mandibular malformations. Patients may also have various degrees of craniosynostosis (White, Cabral et al. 2005).

3.6 *KL*

To date only one case of *KL*-hypophosphatemia has been described in the literature (Brownstein, Adler et al. 2008). A 1-year old girl suffered from poor linear growth and increasing head size. She had clinical and radiological signs of rickets, hypophosphatemia, renal phosphate wasting and elevated levels of parathyroid hormone and alkaline phosphatase. A balanced translocation between chromosomes 9 and 13 was detected (t(9,13)(q21.13;q13.1)). This translocation had led to upregulation of *KL*-transcription. After a few years she demonstrated dysmorphic features of the face, and also an Arnold-Chiari 1 malformation (Brownstein, Adler et al. 2008). Dental affection has not been described.

KL-hyperphosphatemia has also been described in only one report (Ichikawa, Imel et al. 2007). A 13 year old girl presented with severe calcifications in soft tissues and in the vasculature, including the dura and the carotid arteries. In addition to hyperphosphatemia and hypercalcemia, she presented with hyperparathyroidism and elevated levels of FGF23. She had no signs of premature aging, which is seen in *KL* knockout mice. Dental affection has not been described.

3.7 *SLC34A1* and *SLC34A3*

In *SLC34A1*- and *SLC34A3*-hypophosphatemia, there is hypophosphatemic rickets with hypercalciuria without other tubular defects (Tieder, Modai et al. 1985). The inheritance pattern is autosomal recessive. Since there is normal renal activation of vitamin D (in contrast to *PHEX*-hypophosphatemia and *DMP1*-hypophosphatemia), hypophosphatemia leads to a normal compensatory increase in 1,25(OH)₂vitamin D levels and increased absorption of calcium and phosphate from the gut.

3.8 *SLC9A3R1*

A total of 7 cases of *SLC9A3R1*-hypophosphatemia (hypophosphatemia, nephrolithiasis/osteoporosis) have been described to date (Karim, Gerard et al. 2008). All patients were adults, and had either nephrolithiasis and/or bone demineralization combined with hypophosphatemia and hyperphosphaturia. 1,25 (OH)₂ vitamin D levels were either elevated or in the upper normal range. Dental affection has not been described.

3.9 *ENPP1*

ENPP1-hypophosphatemia (autosomal recessive) has a variable age at onset and a variable phenotype including Generalized Arterial Calcification of Infancy (GACI). Also there seems to be phenotypic variation within the same family among affected subjects carrying the same mutation. Whereas the classic presentation is that of severe arterial calcification leading to death in infancy, some patients have renal phosphate wasting and hypophosphatemia. This phosphate loss seems to attenuate the tendency of arterial calcifications, and is associated with prolonged survival (Lorenz-Depiereux, Schnabel et al. 2010).

4. Management principles

4.1 Hypophosphatemia

Hypophosphatemic rickets is in childhood usually treated with elementary phosphorus at doses preferentially between 30 and 60 (100) mg/kg bodyweight and 24 hours, usually divided by 4-6 doses, whereas the deficient 1,25(OH)₂vitamin D production is treated with active vitamin D, e.g. alphacalcidol or calcitriol in doses of 20 to 70 ng/kg bodyweight and 24 hours, usually divided by 2 doses. It should, however, be emphasized that the dosage ranges for both phosphate and active vitamin D are wide, dependent on the severity of the disease, the compliance and the occurrence of complications. In *SLC34A1*- and *SLC34A3*-hypophosphatemia, activation of vitamin D is normal, and, consequently, there is no need for treatment with vitamin D.

It is important to adjust the drug doses individually and bear in mind that insufficient doses of elementary phosphorus and vitamin D may fail to prevent or correct skeletal deformities (rickets, osteomalacia) and can lead to growth retardation. On the other hand, excessive doses may lead to nephrocalcinosis (high phosphate doses), as well as hypercalciuria and hypercalcemia (high vitamin D levels). Secondary (and even tertiary) hyperparathyroidism is seen in patients with insufficient doses of vitamin D or excessive doses of phosphorus. We recommend aiming at normal levels of PTH, which in severe cases may be obtained by adding the calcimimetic drug cinacalcet to the treatment (Raeder, Bjerknes et al. 2008).

Close monitoring is necessary to balance the effects of phosphorus supplement and active vitamin D. Growth, serum calcium, phosphorus, alkaline phosphatase, PTH, as well as urinary calcium/creatinine ratio should be determined every 3-6 months, and X-rays of ankles, knees and wrist should be taken yearly. Renal ultrasound should be obtained yearly to assess nephrocalcinosis.

Supplementary treatment with growth hormone is currently not recommended for the growth retardation caused by hypophosphatemia (Huiming and Chaomin 2005), but may be warranted in selected cases. Corrective osteotomies are seldom necessary in childhood, and it should always be deferred until the rickets has healed. Future therapeutic possibilities may include direct targeting of blood FGF23 levels.

4.2 Hyperphosphatemia

Patients with hyperphosphatemia due to monogenic phosphate balance disorders, i.e. *GALNT3*-hyperphosphatemia, *FGF23*-hyperphosphatemia and *KL*-hyperphosphatemia, develop ectopic and vascular calcifications. Combined use of intestinal phosphate binders and the carbonic anhydrase inhibitor acetazolamide has been reported to lower serum phosphorus levels and reduce tumoral masses in some patients (Garringer, Fisher et al. 2006). However, other reports suggest that neither medical nor surgical treatment seems to be effective in controlling ectopic calcifications in these conditions (Carmichael, Bynum et al. 2009). Future therapeutic possibilities may include direct targeting of blood FGF23 levels.

4.3 Genetic diagnostics and predictive testing

Identification of a specific mutation has important therapeutic and prognostic implications and tailored follow-up as outlined above. Distinction between *PHEX*-hypophosphatemia and *DMP1*-hypophosphatemia can be done clinically based on the inheritance pattern, but in some cases there is an ambiguous inheritance pattern (Figure 4) and a genetic test will resolve this ambiguity.

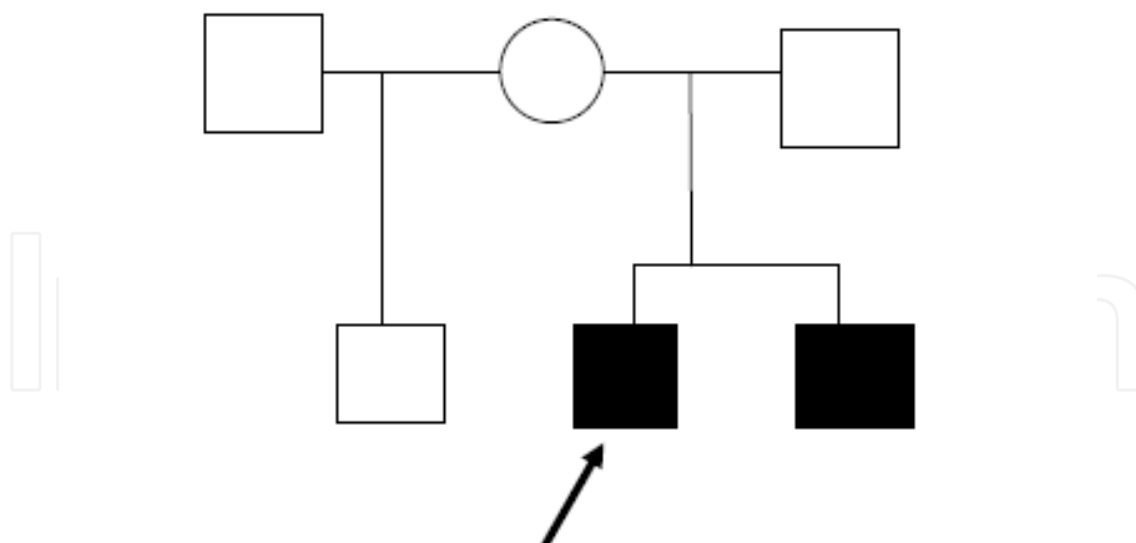


Fig. 4. An example of ambiguous inheritance pattern. Note that in this case, the pattern is compatible both with an X-linked disorder (i.e. *PHEX*-hypophosphatemia) and an AR disorder (i.e. *DMP1*-hypophosphatemia).

Monogenic phosphate balance disorders warrant genetic counseling, because of the known inheritance pattern and the high penetrance. This is also the case for novel gene variants where it is necessary to establish evidence for causality based on co-segregation studies and prediction tools (such as Polyphen <http://genetics.bwh.harvard.edu/pph/>). Predictive genetic testing is less straightforward, and the legal regulations vary in different countries. Communicating genetic information can be difficult and it is important to take into account how well the individual understands both genetics in general and the disorder itself and the consequences of potentially diagnosing other family subjects. The basic fact that there is a 25% or 50% probability for a child to carry the family's mutation should be conveyed to the parents. In addition, the probability for the development of the disorder in the presence of a mutation (i.e. the penetrance) is not always 100%. The variable and in some cases unpredictable age of onset of some of the disorders should also be discussed. By increasing knowledge of the clinical spectrum of mutations, novel expected manifestations need to be discussed with the patient. A system for follow-up is required for children without a phenotype but with affected family members and where parents still request that their child be tested. This follow-up may include periodic testing for hypophosphatemia, with a frequency dependent on age and the suspected condition.

5. Research perspectives

We have established a national database of patients with hypophosphatemic bone disorder in order to study phenotype-genotype correlation in this disease and to be able to explore novel pathophysiologic pathways based on insight obtained from studies of families with no previously known genetic cause of monogenic hypophosphatemic bone disorder. We believe that a new classification of disease based on genetic etiology instead of clinical criteria may facilitate the finding of new phenotypes since it will facilitate the study of unobserved phenotypes, both in the patients and in their presumably unaffected relatives carrying mutations. In addition, it is possible that emerging new treatment options may vary based on

the genetic diagnosis which warrants studies of associations between gene variants and therapeutic effects. Future studies of monogenic phosphate balance disorders will probably continue to include genomewide studies of families with genetically unexplained phosphate balance disorders. Animal and cell studies will probably also continue to contribute to the understanding of disease mechanism, and, in particular, the use of induced pluripotent stem cells (iPS) seems to be a promising new tool in the mechanistic and therapeutic studies (Rosenzweig 2010) as well as the use of small molecule screens in the search for new therapeutic options in monogenic disease (Shaw, Blodgett et al. 2011).

6. Conclusion

As we have discussed in this book chapter, several of the dominant and recessive forms of hypo- and hyperphosphatemic bone disease have received their molecular explanation leading to new insight into the pathophysiology of hypo- and hyperphosphatemic bone disease. The major advancement in pathophysiological understanding has come from the understanding of a bone-kidney axis where the central bone phosphatonin FGF23 acts on FGFR1-receptors in the kidneys to promote phosphaturia and from the understanding of all the factors converging on this axis. In fact, this axis ties together the known monogenic forms of renal phosphate disorders. In addition, the understanding of the genetics and pathophysiology of these disorders has led to the recognition of the two faces of some of the involved genes, showing both hyper- and hypofunction, dependent on the nature of the mutation, which is in particular the case for mutations affecting the *KL* and *FGF23* genes.

We recommend the use of a genetic-oriented classification instead of the traditional disease-oriented classification since we believe that this will facilitate a broader understanding of the phenotype of monogenic phosphate balance disorders. Whereas increased molecular understanding has led to a more precise diagnosis, it has not yet led to new established treatment. We believe, however, that the molecular understanding will indeed facilitate the development of new treatment options with the use of the powerful tools including iPS cells and small molecular screens.

7. References


- ADHR Consortium (2000). "Autosomal dominant hypophosphataemic rickets is associated with mutations in FGF23." *Nat Genet* 26(3): 345-348.
- Alon, U. S. (2010). "Clinical practice : Fibroblast growth factor (FGF)23: a new hormone." *European journal of pediatrics*.
- Amatschek, S., M. Haller, et al. (2010). "Renal phosphate handling in human--what can we learn from hereditary hypophosphataemias?" *Eur J Clin Invest* 40(6): 552-560.
- Bastepe, M. and H. Juppner (2008). "Inherited hypophosphatemic disorders in children and the evolving mechanisms of phosphate regulation." *Rev Endocr Metab Disord* 9(2): 171-180.
- Batra, P., Z. Tejani, et al. (2006). "X-linked hypophosphatemia: dental and histologic findings." *J Can Dent Assoc* 72(1): 69-72.
- Beck, L., A. C. Karaplis, et al. (1998). "Targeted inactivation of Npt2 in mice leads to severe renal phosphate wasting, hypercalciuria, and skeletal abnormalities." *Proc Natl Acad Sci U S A* 95(9): 5372-5377.

- Benet-Pages, A., P. Orlik, et al. (2005). "An FGF23 missense mutation causes familial tumoral calcinosis with hyperphosphatemia." *Hum Mol Genet* 14(3): 385-390.
- Bergwitz, C., N. M. Roslin, et al. (2006). "SLC34A3 mutations in patients with hereditary hypophosphatemic rickets with hypercalciuria predict a key role for the sodium-phosphate cotransporter NaPi-IIc in maintaining phosphate homeostasis." *Am J Hum Genet* 78(2): 179-192.
- Biber, J., N. Hernando, et al. (2009). "Regulation of phosphate transport in proximal tubules." *Pflügers Arch* 458(1): 39-52.
- Brame, L. A., K. E. White, et al. (2004). "Renal phosphate wasting disorders: clinical features and pathogenesis." *Seminars in nephrology* 24(1): 39-47.
- Brownstein, C. A., F. Adler, et al. (2008). "A translocation causing increased alpha-klotho level results in hypophosphatemic rickets and hyperparathyroidism." *Proc Natl Acad Sci U S A* 105(9): 3455-3460.
- Carmichael, K. D., J. A. Bynum, et al. (2009). "Familial tumoral calcinosis: a forty-year follow-up on one family." *The Journal of bone and joint surgery. American volume* 91(3): 664-671.
- Carpenter, T. O. (1997). "New perspectives on the biology and treatment of X-linked hypophosphatemic rickets." *Pediatric clinics of North America* 44(2): 443-466.
- Chefetz, I. and E. Sprecher (2009). "Familial tumoral calcinosis and the role of O-glycosylation in the maintenance of phosphate homeostasis." *Biochim Biophys Acta* 1792(9): 847-852.
- Dixon, P. H., P. T. Christie, et al. (1998). "Mutational analysis of PHEX gene in X-linked hypophosphatemia." *J Clin Endocrinol Metab* 83(10): 3615-3623.
- Econs, M. J. and P. T. McEnery (1997). "Autosomal dominant hypophosphatemic rickets/osteomalacia: clinical characterization of a novel renal phosphate-wasting disorder." *The Journal of clinical endocrinology and metabolism* 82(2): 674-681.
- Econs, M. J., P. T. McEnery, et al. (1997). "Autosomal dominant hypophosphatemic rickets is linked to chromosome 12p13." *J Clin Invest* 100(11): 2653-2657.
- Econs, M. J., G. P. Samsa, et al. (1994). "X-Linked hypophosphatemic rickets: a disease often unknown to affected patients." *Bone and mineral* 24(1): 17-24.
- Farrow, E. G., S. I. Davis, et al. (2006). "Extended mutational analyses of FGFR1 in osteoglophonic dysplasia." *American journal of medical genetics. Part A* 140(5): 537-539.
- Farrow, E. G., S. I. Davis, et al. (2009). "Molecular analysis of DMP1 mutants causing autosomal recessive hypophosphatemic rickets." *Bone* 44(2): 287-294.
- Feng, J. Q., L. M. Ward, et al. (2006). "Loss of DMP1 causes rickets and osteomalacia and identifies a role for osteocytes in mineral metabolism." *Nat Genet* 38(11): 1310-1315.
- Garringer, H. J., C. Fisher, et al. (2006). "The role of mutant UDP-N-acetyl-alpha-D-galactosamine-polypeptide N-acetylgalactosaminyltransferase 3 in regulating serum intact fibroblast growth factor 23 and matrix extracellular phosphoglycoprotein in heritable tumoral calcinosis." *The Journal of clinical endocrinology and metabolism* 91(10): 4037-4042.
- Gaucher, C., O. Walrant-Debray, et al. (2009). "PHEX analysis in 118 pedigrees reveals new genetic clues in hypophosphatemic rickets." *Hum Genet* 125(4): 401-411.
- Gaucher, C., O. Walrant-Debray, et al. (2009). "PHEX analysis in 118 pedigrees reveals new genetic clues in hypophosphatemic rickets." *Human genetics* 125(4): 401-411.

- Goldfine, I. D., B. A. Maddux, et al. (2008). "The role of membrane glycoprotein plasma cell antigen 1/ectonucleotide pyrophosphatase phosphodiesterase 1 in the pathogenesis of insulin resistance and related abnormalities." *Endocr Rev* 29(1): 62-75.
- Harahap, A. R. and J. W. Goding (1988). "Distribution of the murine plasma cell antigen PC-1 in non-lymphoid tissues." *J Immunol* 141(7): 2317-2320.
- Holm, I. A., A. E. Nelson, et al. (2001). "Mutational analysis and genotype-phenotype correlation of the PHEX gene in X-linked hypophosphatemic rickets." *The Journal of clinical endocrinology and metabolism* 86(8): 3889-3899.
- Hu, M. C., M. Shi, et al. (2010). "Klotho: a novel phosphaturic substance acting as an autocrine enzyme in the renal proximal tubule." *FASEB J* 24(9): 3438-3450.
- Huang, R., M. Rosenbach, et al. (1994). "Expression of the murine plasma cell nucleotide pyrophosphohydrolase PC-1 is shared by human liver, bone, and cartilage cells. Regulation of PC-1 expression in osteosarcoma cells by transforming growth factor-beta." *J Clin Invest* 94(2): 560-567.
- Huiming, Y. and W. Chaomin (2005). "Recombinant growth hormone therapy for X-linked hypophosphatemia in children." *Cochrane database of systematic reviews*(1): CD004447.
- Huq, N. L., K. J. Cross, et al. (2005). "A review of protein structure and gene organisation for proteins associated with mineralised tissue and calcium phosphate stabilisation encoded on human chromosome 4." *Archives of oral biology* 50(7): 599-609.
- HYP Consortium. A gene (PEX) with homologies to endopeptidases is mutated in patients with X-linked hypophosphatemic rickets. *Nature Genetics* 1995;11:130-6
- Ichikawa, S., G. Baujat, et al. (2010). "Clinical variability of familial tumoral calcinosis caused by novel GALNT3 mutations." *Am J Med Genet A* 152A(4): 896-903.
- Ichikawa, S., E. A. Imel, et al. (2007). "A homozygous missense mutation in human KLOTHO causes severe tumoral calcinosis." *J Clin Invest* 117(9): 2684-2691.
- Ichikawa, S., E. A. Imel, et al. (2007). "A homozygous missense mutation in human KLOTHO causes severe tumoral calcinosis." *J Musculoskelet Neuronal Interact* 7(4): 318-319.
- Ichikawa, S., E. A. Traxler, et al. (2008). "Mutational survey of the PHEX gene in patients with X-linked hypophosphatemic rickets." *Bone* 43(4): 663-666.
- Imel, E. A., S. L. Hui, et al. (2007). "FGF23 concentrations vary with disease status in autosomal dominant hypophosphatemic rickets." *J Bone Miner Res* 22(4): 520-526.
- Jonsson, K. B., R. Zahradnik, et al. (2003). "Fibroblast growth factor 23 in oncogenic osteomalacia and X-linked hypophosphatemia." *N Engl J Med* 348(17): 1656-1663.
- Juppner, H. (2007). "Novel regulators of phosphate homeostasis and bone metabolism." *Therapeutic apheresis and dialysis : official peer-reviewed journal of the International Society for Apheresis, the Japanese Society for Apheresis, the Japanese Society for Dialysis Therapy* 11 Suppl 1: S3-22.
- Karim, Z., B. Gerard, et al. (2008). "NHERF1 mutations and responsiveness of renal parathyroid hormone." *N Engl J Med* 359(11): 1128-1135.
- Kato, K., C. Jeanneau, et al. (2006). "Polypeptide GalNAc-transferase T3 and familial tumoral calcinosis. Secretion of fibroblast growth factor 23 requires O-glycosylation." *The Journal of biological chemistry* 281(27): 18370-18377.

- Koshida, R., H. Yamaguchi, et al. (2010). "A novel nonsense mutation in the DMP1 gene in a Japanese family with autosomal recessive hypophosphatemic rickets." *J Bone Miner Metab* 28(5): 585-590.
- Kuro-o, M., Y. Matsumura, et al. (1997). "Mutation of the mouse *klotho* gene leads to a syndrome resembling ageing." *Nature* 390(6655): 45-51.
- Kurosui, H., M. Choi, et al. (2007). "Tissue-specific expression of betaKlotho and fibroblast growth factor (FGF) receptor isoforms determines metabolic activity of FGF19 and FGF21." *The Journal of biological chemistry* 282(37): 26687-26695.
- Kurosui, H., M. Yamamoto, et al. (2005). "Suppression of aging in mice by the hormone Klotho." *Science* 309(5742): 1829-1833.
- Levy-Litan, V., E. HersHKovitz, et al. (2010). "Autosomal-recessive hypophosphatemic rickets is associated with an inactivation mutation in the ENPP1 gene." *Am J Hum Genet* 86(2): 273-278.
- Lorenz-Depiereux, B., M. Bastepe, et al. (2006). "DMP1 mutations in autosomal recessive hypophosphatemia implicate a bone matrix protein in the regulation of phosphate homeostasis." *Nat Genet* 38(11): 1248-1250.
- Lorenz-Depiereux, B., A. Benet-Pages, et al. (2006). "Hereditary hypophosphatemic rickets with hypercalciuria is caused by mutations in the sodium-phosphate cotransporter gene SLC34A3." *Am J Hum Genet* 78(2): 193-201.
- Lorenz-Depiereux, B., D. Schnabel, et al. (2010). "Loss-of-function ENPP1 mutations cause both generalized arterial calcification of infancy and autosomal-recessive hypophosphatemic rickets." *Am J Hum Genet* 86(2): 267-272.
- Makitie, O., R. C. Pereira, et al. (2010). "Long-term clinical outcome and carrier phenotype in autosomal recessive hypophosphatemia caused by a novel DMP1 mutation." *J Bone Miner Res* 25(10): 2165-2174.
- Matsumura, Y., H. Aizawa, et al. (1998). "Identification of the human *klotho* gene and its two transcripts encoding membrane and secreted *klotho* protein." *Biochem Biophys Res Commun* 242(3): 626-630.
- Passos-Bueno, M. R., W. R. Wilcox, et al. (1999). "Clinical spectrum of fibroblast growth factor receptor mutations." *Hum Mutat* 14(2): 115-125.
- Prie, D., V. Huart, et al. (2002). "Nephrolithiasis and osteoporosis associated with hypophosphatemia caused by mutations in the type 2a sodium-phosphate cotransporter." *N Engl J Med* 347(13): 983-991.
- Quarles, L. D. (2003). "Evidence for a bone-kidney axis regulating phosphate homeostasis." *J Clin Invest* 112(5): 642-646.
- Raeder, H., N. Shaw, et al. (2008). "A case of X-linked hypophosphatemic rickets (XLH): complications and the therapeutic use of cinacalcet." *Eur J Endocrinol.* 159 (Suppl. 1):101-105.
- Rosenzweig, A. (2010). "Illuminating the potential of pluripotent stem cells." *The New England journal of medicine* 363(15): 1471-1472.
- Rutsch, F., P. Boyer, et al. (2008). "Hypophosphatemia, hyperphosphaturia, and bisphosphonate treatment are associated with survival beyond infancy in generalized arterial calcification of infancy." *Circ Cardiovasc Genet* 1(2): 133-140.
- Rutsch, F., N. Ruf, et al. (2003). "Mutations in ENPP1 are associated with 'idiopathic' infantile arterial calcification." *Nat Genet* 34(4): 379-381.

- Rutsch, F., S. Vaingankar, et al. (2001). "PC-1 nucleoside triphosphate pyrophosphohydrolase deficiency in idiopathic infantile arterial calcification." *Am J Pathol* 158(2): 543-554.
- Sabbagh, Y., G. Boileau, et al. (2003). "Structure and function of disease-causing missense mutations in the PHEX gene." *The Journal of clinical endocrinology and metabolism* 88(5): 2213-2222.
- Sabbagh, Y., G. Boileau, et al. (2001). "Disease-causing missense mutations in the PHEX gene interfere with membrane targeting of the recombinant protein." *Human molecular genetics* 10(15): 1539-1546.
- Shaw, S. Y., D. M. Blodgett, et al. (2011). "Disease allele-dependent small-molecule sensitivities in blood cells from monogenic diabetes." *Proceedings of the National Academy of Sciences of the United States of America* 108(2): 492-497.
- Shimada, T., H. Hasegawa, et al. (2004). "FGF-23 is a potent regulator of vitamin D metabolism and phosphate homeostasis." *J Bone Miner Res* 19(3): 429-435.
- Strom, T. M. and H. Juppner (2008). "PHEX, FGF23, DMP1 and beyond." *Curr Opin Nephrol Hypertens* 17(4): 357-362.
- Tenenhause, H. S. (2005). "Regulation of phosphorus homeostasis by the type iia na/phosphate cotransporter." *Annu Rev Nutr* 25: 197-214.
- Tieder, M., D. Modai, et al. (1985). "Hereditary hypophosphatemic rickets with hypercalciuria." *The New England journal of medicine* 312(10): 611-617.
- Topaz, O., D. L. Shurman, et al. (2004). "Mutations in GALNT3, encoding a protein involved in O-linked glycosylation, cause familial tumoral calcinosis." *Nat Genet* 36(6): 579-581.
- Turan, S., C. Aydin, et al. (2010). "Identification of a novel dentin matrix protein-1 (DMP-1) mutation and dental anomalies in a kindred with autosomal recessive hypophosphatemia." *Bone* 46(2): 402-409.
- Urakawa, I., Y. Yamazaki, et al. (2006). "Klotho converts canonical FGF receptor into a specific receptor for FGF23." *Nature* 444(7120): 770-774.
- White, K. E., J. M. Cabral, et al. (2005). "Mutations that cause osteoglophonic dysplasia define novel roles for FGFR1 in bone elongation." *Am J Hum Genet* 76(2): 361-367.
- Yuan, B., M. Takaiwa, et al. (2008). "Aberrant Phex function in osteoblasts and osteocytes alone underlies murine X-linked hypophosphatemia." *The Journal of clinical investigation* 118(2): 722-734.



Contemporary Aspects of Endocrinology

Edited by Dr. Evanthia Diamanti-Kandarakis

ISBN 978-953-307-357-6

Hard cover, 454 pages

Publisher InTech

Published online 30, November, 2011

Published in print edition November, 2011

This book aims to provide readers with a general as well as an advanced overview of the key trends in endocrine disorders. While covering a variety of topics ranging from thyroid carcinogenesis and pituitary adenomas to adrenal tumors and metabolic bone disease, this book also focuses on more specific issues not yet fully elucidated (e.g. the molecular pathways involved in thyrotropin beta gene regulation or monogenic phosphate balance disorders). Readers of different fields and background will have the opportunity to update their knowledge and more importantly to clarify areas of uncertainty and controversies in several topics of endocrine disorders.

How to reference

In order to correctly reference this scholarly work, feel free to copy and paste the following:

Helge Raeder, Silje Rafaelsen and Robert Bjerknes (2011). Monogenic Phosphate Balance Disorders, Contemporary Aspects of Endocrinology, Dr. Evanthia Diamanti-Kandarakis (Ed.), ISBN: 978-953-307-357-6, InTech, Available from: <http://www.intechopen.com/books/contemporary-aspects-of-endocrinology/monogenic-phosphate-balance-disorders>

INTECH
open science | open minds

InTech Europe

University Campus STeP Ri
Slavka Krautzeka 83/A
51000 Rijeka, Croatia
Phone: +385 (51) 770 447
Fax: +385 (51) 686 166
www.intechopen.com

InTech China

Unit 405, Office Block, Hotel Equatorial Shanghai
No.65, Yan An Road (West), Shanghai, 200040, China
中国上海市延安西路65号上海国际贵都大饭店办公楼405单元
Phone: +86-21-62489820
Fax: +86-21-62489821

© 2011 The Author(s). Licensee IntechOpen. This is an open access article distributed under the terms of the [Creative Commons Attribution 3.0 License](https://creativecommons.org/licenses/by/3.0/), which permits unrestricted use, distribution, and reproduction in any medium, provided the original work is properly cited.

IntechOpen

IntechOpen