

We are IntechOpen, the world's leading publisher of Open Access books Built by scientists, for scientists

6,900

Open access books available

186,000

International authors and editors

200M

Downloads

Our authors are among the

154

Countries delivered to

TOP 1%

most cited scientists

12.2%

Contributors from top 500 universities



WEB OF SCIENCE™

Selection of our books indexed in the Book Citation Index
in Web of Science™ Core Collection (BKCI)

Interested in publishing with us?
Contact book.department@intechopen.com

Numbers displayed above are based on latest data collected.
For more information visit www.intechopen.com



Status for Congenital Hypothyroidism at Advanced Ages

Sevil Ari Yuca

Department of Pediatric Endocrinology, Selcuk University, Meram Medical Faculty, Turkey

1. Introduction

Congenital hypothyroidism is one of the most frequent causes of growth and developmental delay and preventable mental retardation. It's incidence of approximately 1 in 4,000 births (Fisher, 2008). Recently in some countries higher incidences were 1/1800, 1/2759 reported (Skordis *et al.*, 2005; Henry *et al.*, 2002).

2. Classification and etiology

Congenital hypothyroidism is usually classified as primary, secondary and tertiary or as permanently and transient hypothyroidism. Primary congenital hypothyroidism accounts for 90% of all cases. Approximately 85% of cases are sporadic, while 15% are hereditary. Besides dietary iodine deficiency, the causing reasons of permanently congenital hypothyroidism are embryologic and anatomical defect of the thyroid gland, biosynthetic defect in the production of thyroid hormones in sporadic cases. The most common causes are thyroid gland dysgenesis associated with ectopic, hypoplastic and absent gland (athyreosis). The next most common cause of permanent congenital hypothyroidism is dyshormonogenesis (MacGillivray, 2004). Affected patients have normally located and normally shaped thyroid gland but are enlarged due to thyroid-stimulating hormone chronic and hyperstimulation

The pathogenesis of dysgenesis is largely unknown, some cases are now discovered to be the result of mutations in the transcription factors PAX-8 and TTF-2. Loss of function mutations in the thyrotropin (TSH) receptor have been demonstrated to cause some familial forms of athyreosis. The most common hereditary etiology is the inborn errors of thyroxine (T₄) synthesis. Recent mutations have been described in the genes coding for the sodium/iodide symporter, thyroid peroxidase (TPO), and thyroglobulin. Transplacental passage of a maternal thyrotropin receptor blocking antibody (TRB-Ab) causes a transient form of familial congenital hypothyroidism (Brown, 2009).

3. Actions of thyroid hormone and clinical findings in congenital hypothyroid

Thyroid hormone has multiple effects in cells, including stimulation of thermogenesis, water and ion transport and acceleration of substrate turnover and amino acid and lipid metabolism. Thyroid hormone also potentiates the action of catecholamine's (Brown, 2009).

Whereas thyroid hormone-mediated effects in the pituitary, brain and bone can be detected prenatally, thyroid hormone-dependent action in brown adipose tissue, liver, heart, skin and carcass are apparent only postnatally.

The most prominent finding in view of the rough face of delayed diagnosis. In some cases, depending on the TSH stimulation can be found enlarged thyroid gland (fig 1a-1b). During the perinatal period, brown adipose tissue is essential for non-shivering thermogenesis. Thyroid hormone stimulates transcription of thermogenin that protein that uncouples nucleotide phosphorylation and the storage of energy as ATP. As the child matures, shivering thermogenesis assumes greater importance and brown adipose tissue disappears (Brown, 2009). In children with thyroid hormone deficiency is impaired temperature regulation. Thus the skin is rough and cold skin, and is evidence " cutis marmorata " signs. Hypertrichosis in children with delayed diagnosis and treatment of hypothyroidism can be seen in the back (fig 2).

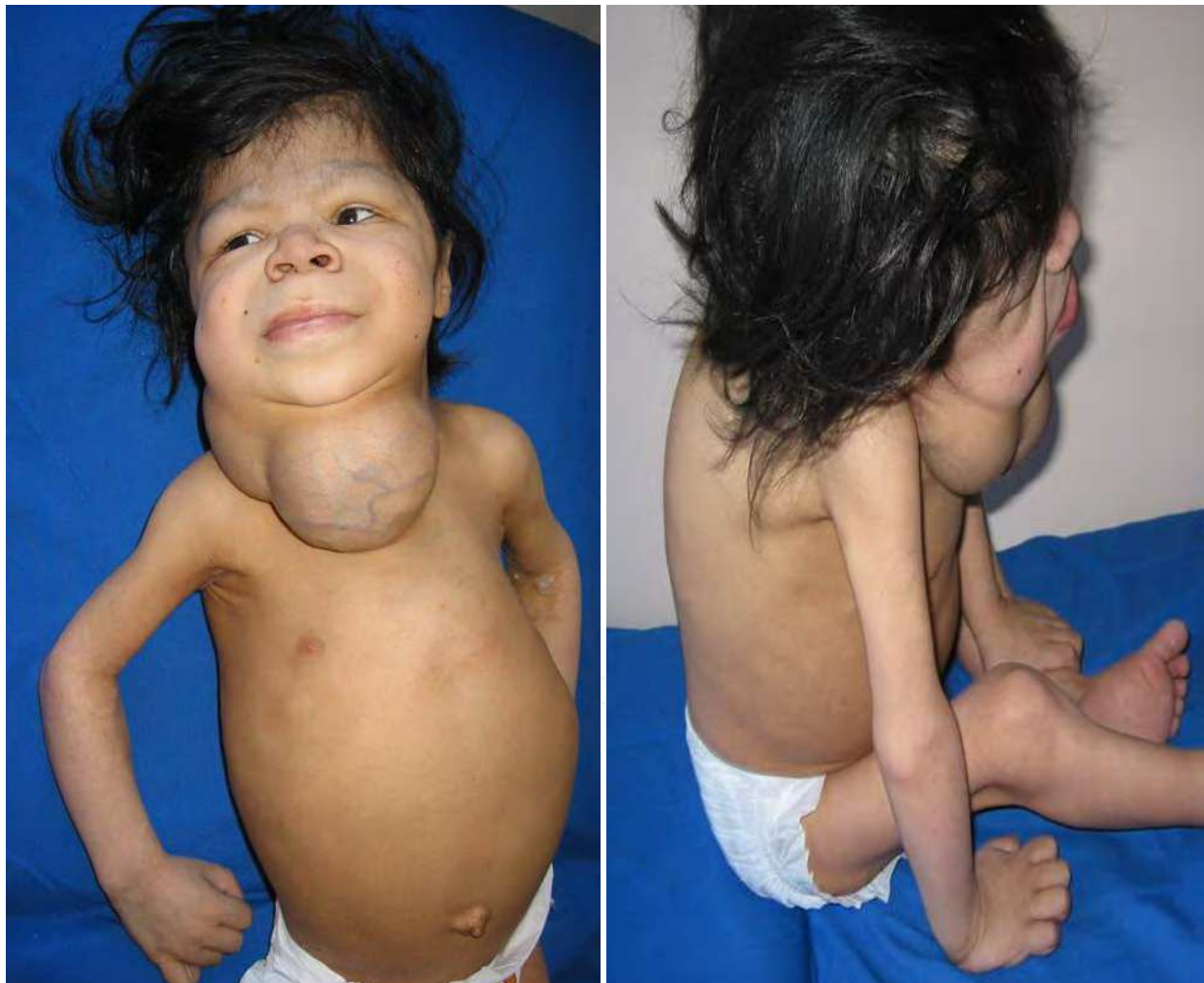

Fig. 1a, 1b. A 19-year-old girl with congenital primary hypothyroidism. Enlarged thyroid gland, coarse facial, umbilical hernia, thick hair, outpouring of the medial parts of the eyebrows, abdominal distention and delayed pubertal findings are seen (*Nobel Med*, 2010; 6(1):74-77).

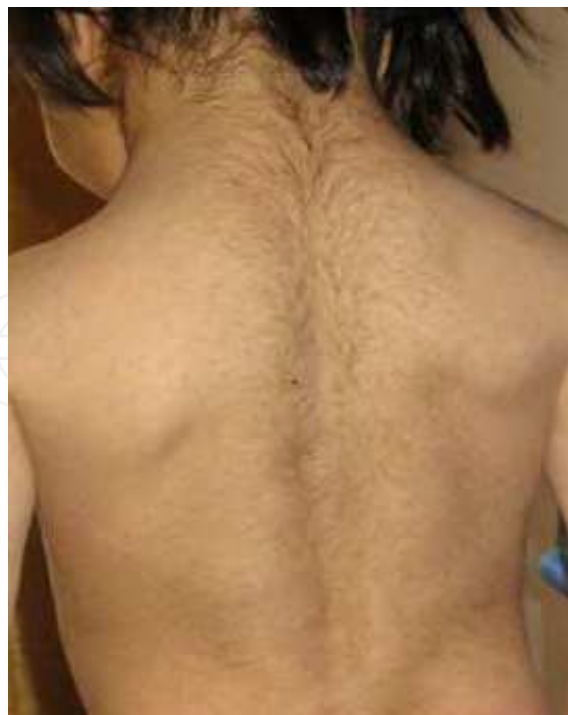

Fig. 2. A 6-year-old girl with congenital primary hypothyroidism. Dark and thick hairs on her back are seen.

Other important thyroid hormone target in the perinatal period is bone, as evidenced by the striking growth retardation, decreased growth velocity and delayed ossification of the epiphyseal growth plate characteristic of long-standing untreated hypothyroidism in infancy and childhood. Thyroid hormone-mediated bone maturation involves both direct and indirect actions. The indirect action mediated by regulation of growth hormone gene expression and the IGF system (Robson et al., 2000, 2002). T₃ regulates endochondral ossification and controls chondrocyte differentiation in the growth plate both in vitro and in vivo as a direct (Robson et al., 2000; Ball et al., 1997). Osteoblasts and growth plate chondrocytes both express TRs and several T₃-specific target genes have been identified in bone (Stevens et al., 2003). T₃ also stimulates closure of the skull sutures in vivo, the basis for the enlarged anterior and posterior fontanelle characteristic of infants with congenital hypothyroidism (Akita et al., 1994). Due to delayed bone maturation, there were skeletal deformed, kyphoscoliosis, on thoraco lumbar vertebrae in a 21 year old female with delayed diagnosis of hypothyroidism (fig 3). Bone age is retarded in hypothyroidism almost always exceeds the retardation in linear growth. Tooth eruption may be delayed, and in rare cases stippled epiphyses are evident radiographically.

In the brain, thyroid hormone provides the induction signal for the differentiation and maturation of neural system, and a critical window of brain development. These processes include neurogenesis and neural cell migration (occurring predominantly between 5 and 24 weeks), neuronal differentiation, dendritic and axonal growth, synaptogenesis, gliogenesis (late fetal to 6 months postpartum), myelination (second trimester to 24 months postpartum) and neurotransmitter enzyme synthesis. The thyroid hormone- deficient patient usually exhibits slowing of the deep tendon reflexes, with a delayed relaxation phase. (Brown, 2009). The sella turcica may be enlarged (Oatridge, 2002).

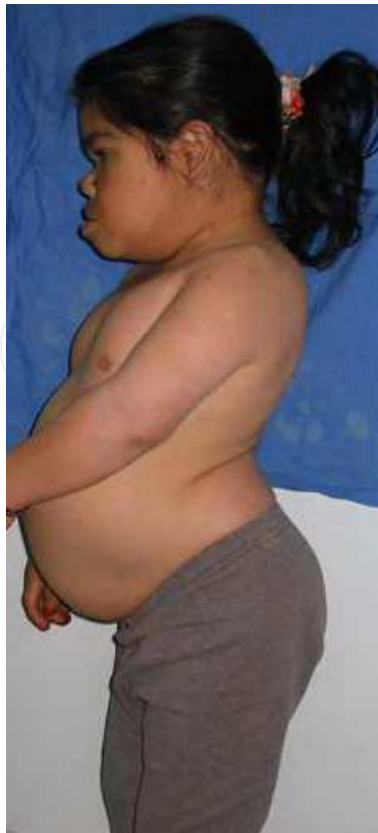

Fig. 3. A 21-year-old female with congenital primary hypothyroidism. Short stature, coarse facial, kyphoscoliosis on her back and absent of pubertal findings are seen (Nobel Med, 2010; 6(1):74-77).

The absence of thyroid hormone appears to delay rather than eliminate the timing of critical morphological events or gene products, resulting in a disorganization of intercellular communication. TRs are found in highest concentration in developing neurons and in multiple areas of the fetal brain, including the cerebrum, cerebellum, auditory and visual cortex. Consistent with a nuclear receptor-mediated mode of action, thyroid hormone stimulates numerous developmentally regulated genes, including genes for myelin, neurotrophins and their receptors, cytoskeletal components, transcription factors, extracellular matrix proteins and adhesion molecules, intracellular signaling molecules, as well as mitochondrial and cerebellar genes. In addition, thyroid hormones regulate some genes at the level of mRNA stability or mRNA splicing (Brown, 2009).

Sexual development of most hypothyroid children is delayed in approximate proportion to the retardation of skeletal maturation (fig 1a-3). However, rare children with severe hypothyroidism present with signs of precocious puberty, the Van Wyk-Grumbach syndrome, (Van Wyk & Grumbach, 1960; Hemady et al., 1978; Chattopadhyay et al., 2003). Girls manifest precocious menstruation, breast development, and galactorrhea. In boys, this syndrome is associated with excessive enlargement of the penis and testes. Most of these patients lack pubic hair, and bone age is retarded in keeping with the duration of the hypothyroid state. Serum prolactin and TSH levels are elevated in some children, but the molecular mechanism of precocious puberty is not clear. The increased serum prolactin levels are probably explained by the fact that TRH stimulates TSH and prolactin release from the pituitary. A paracrine action of the hyperstimulated thyrotropic cells on

gonadotrope cells may explain the increased gonadotropin secretion. It is also possible that these patients have genetic variants of the gonadotropin receptors that can be stimulated by the increased TSH levels (Anasti et al., 1995). Similar findings have been reported for TSH and FSH receptor variants stimulated by HCG (Rodien et al., 1998; Montanelli et al., 2004). When the hypothyroid state is alleviated, the manifestations of sexual precocity regress—and normal puberty ensues when the general level of maturity has progressed appropriately.

4. Newborn screening for congenital hypothyroidism

The morbidity of congenital hypothyroidism can be reduced to a minimum by early diagnosis and therapy. Thus mental retardation in affected infants is eliminated completely with treatment. Unfortunately, usually the disease may become evident after many symptoms of the condition leads to an irreversible brain damage. It was reported that, during the first month of birth, only 10% of the congenital hypothyroidism cases were diagnosed by clinical findings while 35% were diagnosed within 3 months after labor and 70% within a year and 100% only within 3-4 years of age, before screening for hypothyroid (Klein, 1972). Diagnosis of hypothyroidism has been delayed in the countries not applied national newborn screening yet (Malik & But, 2008; Tahirović & Toromanović, 2005).

The process involves measurement of T_4 and/or TSH on dried blood spots obtained from skin puncture done in first days after birth. In most center, only TSH is used to screen newborn infant, because of primary hypothyroidism is most common causes of congenital hypothyroidism. The cutoff for reporting an elevated TSH is a level above 20-25 U/L in most screening programs.

4.1 Diagnostic criteria

Diagnosis of congenital hypothyroidism has essentially based levels of serum TSH and free T_4 . In affected infants presenting with very low serum free T_4 and very high TSH levels. Rarely, some infants have only a moderate elevation of serum TSH and normal T_4 levels.

Congenital hypothyroidism is usually diagnosed during the neonatal period or early infancy. Sometimes, the diagnosis may be delayed in families with low level of socio-economic, and if the birth at home is frequent in population (Yuca et al. 2010). The newborn screening programs for early diagnosis and treatment is vital in congenital hypothyroidism.

5. Treatment

The primary aim of treatment for congenital hypothyroidism is begin adequate thyroid hormone replacement as early as possible to optimize the prognosis for intellectual development. L-thyroxin is preferred to triiodothyronine, because T_4 to T_3 convert locally in brain and peripheral tissues.

The starting oral dose of L-thyroxin is 10 to 12 $\mu\text{g}/\text{kg}/\text{day}$. The target range for serum is T_4 to 10-16 $\mu\text{g}/\text{dl}$. The clinical responses vary among infants even on the standardized dose regimen. Adjustment dose is based on the serum T_4 levels and the clinical examination. The patient should be follow at regular intervals.

6. Prognosis in delayed diagnosis and treatment

At 2-year-old and over children may refer to hospital due to uncertain growth and developmental retardation. Untreated congenital hypothyroidism cases may display different levels of mental retardation and delayed linear growth and bone maturation. Infants with delayed treatment may demonstrate neurological disorders such as spasticity and corrupted walking patterns, dysarthria or mutism and autistic behavior (DeLong, 1996).

Patients receiving treatment with delayed diagnosis is under an obvious target height, but can show some physical growth. These may gain the skill and awareness of their daily functions, and if they do not speak, will start talking or improve of talking. If they not walking, start walk, and have more active movements. It returns to the findings of thermogenesis and skin disorders. The findings of the skeleton will have been better by support therapies such as vitamin D₃ and calcium. In the patients had goiter with pressure symptoms, in fact the thyroid gland is nonfunctional, must be thyroidectomy.

Eventually, puberty is developed in the patients with congenital hypothyroid, and they may be fertile. But they cannot reach the mental development accordance with their own age, which is easy for patient with early diagnose and treatment (Oerbeck et al., 2003; Kempers et al., 2006; Josef et al., 2008).

7. Conclusion

Today, there is sensitive radioimmunoassay to measure serum T₄ and TSH using a blood spot made it possible to initiate newborn thyroid screening programs. Affected patients have get out of permanent mental retardation by early diagnosis and treatment with adequate dose of L-thyroxine.

Hypothyroidism not only the brain but also the other tissues affect and lead to functional and developmental abnormalities there. Some of these functions are recovered a small amount with long-term treatment. Unfortunately, in the patients diagnosed after the completion of the development of the brain, mental retardation is severe and irreversible despite appropriate therapy.


8. References

- Akita S, Nakamura T, Hirano A, Fujii T, Yamashita S (1994). Thyroid hormone action on rat calvarial sutures. *Thyroid*, 4, 99–106, 1050-7256.
- Anasti JN, Flack MR, Frochlich J, et al. (1995). A potential novel mechanism for precocious puberty in juvenile hypothyroidism. *J Clin Endocrinol Metab* 80:276, 0021-972X.
- Ball SG, Ikeda M, Chin WW (1997). Deletion of the thyroid hormone beta1 receptor increases basal and triiodothyronine-induced growth hormone messenger ribonucleic acid in GH3 cells. *Endocrinology*, 138, 3125–3132, 1355-008X.
- Brown GS (2009). The Thyroid. In: *Brook's Clinical Pediatric Endocrinology*, 6th ed. Brook C, Clayton C and Brown R, eds. 250-282. Willey-Blackwell, ISBN 978-1-4051-8080-1, Singapore.
- Chattopadhyay A, Kumar V, Marulaiah M (2003). Polycystic ovaries, precocious puberty and acquired hypothyroidism: The Van Wyk and Grumbach syndrome. *J Ped Surg*, 38,1390, 0022-3468.

- DeLong GR (1996). The neuromuscular system and brain in hypothyroidism. In: *Werner & Ingbar's the Thyroid: A Fundamental and Clinical Text* (7th Ed), 826–836. Lippincott Williams & Wilkins, Philadelphia, USA.
- Fisher DA (2008). Disorders of the thyroid in the newborn and infant. In: *Pediatric Endocrinology*, 3rd ed. Sperling MA, ed. 198–226. WB Saunders, ISBN: 978-1-4160-4090-3, Philadelphia, USA.
- Hemady ZS, Siler-Khodr TM, Najjar S (1978). Precocious puberty in juvenile hypothyroidism. *Pediatrics*, 92,55, 0031–4005.
- Henry G, Sobki SH, Othman JM. Screening for congenital hypothyroidism (2002). *Saudi Med* ; 23: 529–535, 0379–5284.
- Joseph R (2008). Neuro-developmental deficits in early-treated congenital hypothyroidism. *Ann Acad Med Singapore*, 37(12), 42–3, 0304–4602. Review.
- Kempers MJ, van der Sluijs Veer L, Nijhuis-van der Sanden MW, Kooistra L, Wiedijk BM, Faber I, Last BF, de Vijlder JJ, Grootenhuys MA, Vulsma T (2006). Intellectual and motor development of young adults with congenital hypothyroidism diagnosed by neonatal screening. *J Clin Endocrinol Metab*. 91(2), 418–24, 0021–972X.
- MacGillivray MH (2004). Congenital Hypothyroidism. In: *Pediatric Endocrinology*, Pescovitz OH and Eugster EA, eds., Lippincott Williams & Wilkins, 490–507, IBN 0-7817-4059-2, Philadelphia, USA.
- Malik BA, Butt MA (2008). Is delayed diagnosis of hypothyroidism still a problem in Faisalabad, Pakistan. *J Pak Med Assoc*, 58(10), 545–9, 0030–9982.
- Montanelli L, Delbaere A, Di Carlo C, Nappi C, Smits G, Vassart G, Costagliola S. (2004). A mutation in the follicle-stimulating hormone receptor as a cause of familial spontaneous ovarian hyperstimulation syndrome. *J Clin Endocrinol Metab* 89, 1255, 0021–972X.
- Oatridge A, Barnard ML, Puri BK, Taylor SD, Hajnal JV, Saeed N and Bydder GM (2002). Changes in Brain Size with Treatment in Patients with Hyper- or Hypothyroidism. *AJNR*, 23, 1539–1544, 0195–6108.
- Oerbeck B, Sundet K, Kase BF, Heyerdahl S (2003). Congenital hypothyroidism: influence of disease severity and L-thyroxine treatment on intellectual, motor, and school-associated outcomes in young adults. *Pediatrics*, 112(4), 923–30, 0031–4005.
- Robson H, Siebler T, Stevens DA, Shalet SM, Williams GR (2000). Thyroid hormone acts directly on growth plate chondrocytes to promote hypertrophic differentiation and inhibit clonal expansion and cell proliferation. *Endocrinology*, 141, 3887–3897, 1355–008X.
- Robson H, Siebler T, Shalet SM, Williams GR (2002). Interactions between GH, IGF-I, glucocorticoids and thyroid hormones during skeletal growth. *Pediatr Res*, 52, 137–147, 0031–3998.
- Rodien P, Brémont C, Sanson ML, Parma J, Van Sande J, Costagliola S, Luton JP, Vassart G, Duprez L (1998). Familial gestational hyperthyroidism caused by a mutant thyrotropin receptor hypersensitive to human chorionic gonadotropin. *N Engl J Med*, 17, 339, 0028–4793.
- Skordis N, Toumba M, Savva SC, Erakleous E, Topouzi M, Vogazianos M, Argyriou A. (2005). High prevalence of congenital hypothyroidism in the Greek Cypriot population: results of the neonatal screening program 1990–2000. *J Pediatr Endocrinol Metab*; 18, 453–461, 0021–972X.

- Stevens DA, Harvey CB, Scott AJ, O'Shea PJ, Barnard JC, Williams AJ, Brady G, Samarut J, Chassande O, Williams GR (2003). Thyroid hormone activates fibroblast growth factor receptor-1 in bone. *Mol Endocrinol*, 17(9):1751-66, 0888-8809.
- Tahirović H, Toromanović A (2005). Clinical presentation of primary congenital hypothyroidism: experience before mass screening. *Bosn J Basic Med Sci*, 5(4), 26-29, 1512-8601.
- Van Wyk JJ, Grumbach MM (1960). Syndrome of precocious menstruation and galactorrhea in juvenile hypothyroidism: An example of hormonal overlap in pituitary feedback. *J Pediatr*, 57, 416, 00223476 .
- Yuca SA, Cesur Y, Yilmaz C (2010). Congenital Primary Hypothyroidism Diagnosed at Advanced Ages. *Nobel Med*, 6(1), 74-77, .

IntechOpen



Contemporary Aspects of Endocrinology

Edited by Dr. Evanthia Diamanti-Kandarakis

ISBN 978-953-307-357-6

Hard cover, 454 pages

Publisher InTech

Published online 30, November, 2011

Published in print edition November, 2011

This book aims to provide readers with a general as well as an advanced overview of the key trends in endocrine disorders. While covering a variety of topics ranging from thyroid carcinogenesis and pituitary adenomas to adrenal tumors and metabolic bone disease, this book also focuses on more specific issues not yet fully elucidated (e.g. the molecular pathways involved in thyrotropin beta gene regulation or monogenic phosphate balance disorders). Readers of different fields and background will have the opportunity to update their knowledge and more importantly to clarify areas of uncertainty and controversies in several topics of endocrine disorders.

How to reference

In order to correctly reference this scholarly work, feel free to copy and paste the following:

Sevil Ari Yuca (2011). Status for Congenital Hypothyroidism at Advanced Ages, Contemporary Aspects of Endocrinology, Dr. Evanthia Diamanti-Kandarakis (Ed.), ISBN: 978-953-307-357-6, InTech, Available from: <http://www.intechopen.com/books/contemporary-aspects-of-endocrinology/status-for-congenital-hypothyroidism-at-advanced-ages>

INTECH
open science | open minds

InTech Europe

University Campus STeP Ri
Slavka Krautzeka 83/A
51000 Rijeka, Croatia
Phone: +385 (51) 770 447
Fax: +385 (51) 686 166
www.intechopen.com

InTech China

Unit 405, Office Block, Hotel Equatorial Shanghai
No.65, Yan An Road (West), Shanghai, 200040, China
中国上海市延安西路65号上海国际贵都大饭店办公楼405单元
Phone: +86-21-62489820
Fax: +86-21-62489821

© 2011 The Author(s). Licensee IntechOpen. This is an open access article distributed under the terms of the [Creative Commons Attribution 3.0 License](https://creativecommons.org/licenses/by/3.0/), which permits unrestricted use, distribution, and reproduction in any medium, provided the original work is properly cited.

IntechOpen

IntechOpen