

We are IntechOpen, the world's leading publisher of Open Access books Built by scientists, for scientists

6,900

Open access books available

186,000

International authors and editors

200M

Downloads

Our authors are among the

154

Countries delivered to

TOP 1%

most cited scientists

12.2%

Contributors from top 500 universities



WEB OF SCIENCE™

Selection of our books indexed in the Book Citation Index
in Web of Science™ Core Collection (BKCI)

Interested in publishing with us?
Contact book.department@intechopen.com

Numbers displayed above are based on latest data collected.
For more information visit www.intechopen.com



Oral Mucosa Graft: An Ideal Substitute for Urethroplasty

Maged Ragab and Hossam Haroun
*Tanta University, Tanta
EGYPT*

1. Introduction

Urethroplasty is both an art and science. The fact that over 200 different types of repair have been reported in the literatures confirms that it is a difficult surgery with many complications and frequently inadequate cosmetic and functional results. (1)

There are two main principles of urethroplasty:

- Anastomotic technique.
- Tissue transfer.

The use of vascularized local penile or preputial skin has been the mainstay of urethral reconstruction for a long time. Lacking of penile and preputial skin necessitated the search for new sources for tissue transfer. Resurgence of the use of free grafts for anterior urethral stricture reconstruction has renewed the search for the ideal urethral substitute. (1)

Since 1909, a large variety of free extra genital graft tissues had been described in the literature for substitution urethroplasty e.g. ureter (2), tunica vaginalis (3), full thickness extragenital skin (4), and bladder mucosa. (5)

For 100 years, oral mucosa had variously been utilized as a free graft in reconstructive plastic surgery. (6) The first report on the application of oral mucosa as a substitute for conjunctiva dated back to 1873 when Stellwag Von Carion used the lip mucosa to treat conjunctival defects. (6)

It is generally accepted that Humby, a plastic surgeon, first proposed and reported the use of buccal mucosa in urethral surgery for hypospadias repair in 1941. (7) Whether owing to lack of suitable antibiotic prophylaxis or technical factors, the technique did not gain acceptance or widespread use at that time until almost 50 years later. Current enthusiasm for the technique was promoted by Duckett 1986, (8) Burger and associates 1992 (9), Dessanti and colleagues 1992 (10) and Elkasaby et al. (11)

In the following years, numerous reports had described successful use of buccal mucosal graft in the repair of urethral defects associated with previously failed hypospadias surgery and those associated with urethral stricture. (12-19) Nowadays, buccal mucosa has become the mainstay of these tissue transfer techniques. (13)

In February 2006, Simonato et al. (20) described the results of the first pilot study on the use of the tongue as an alternative donor site for graft urethroplasty with good functional and aesthetic results. (20) One year later in a dog model, Song et al (21) investigated the feasibility of the LMG urethroplasty. Macroscopic examination of the graft showed no ulceration, calcification, strictures, diverticulae or fistula formation. The junction between

the graft and the normal urethra was discernible by its gross appearance, and the LMGs were tightly incorporated into the urethral walls. (21)

Since then, numerous reports for the use of the lingual mucosa for urethroplasty were published in the last 5 years (16, 21-30) emphasizing Simonato's conclusion that the mucosa of the tongue is a safe and effective graft material in the armamentarium for urethral reconstruction with potential minor risks of donor site complications. (27)

2. Histology of the Oral mucosa

The unique structure of the oral mucosa allows it to be an excellent graft material. (31) The location of the buccal mucosa is limited to the outer vestibule of the oral cavity, which is the space and structure from the teeth to the cheek inside the mouth. Buccal mucosa is freely mobile, loose and compliant. It is 500um thick and a nonkeratinized stratified squamous epithelium consisting of four layers; the stratum basale, stratum spinosum, stratum intermedium and stratum superficiale. (31)

The stratum basale or germinative layer is the basal layer of the epithelium that rests against the basement membrane and provides the progenitor cells for cellular division. It is two to three cells thick and includes melanocytes, antigen-presenting langerhans cells, sensory Merkel cells and lymphocytes. Its rapid mitotic division provides a fast turnover rate, with only 25 days required for all layers of the buccal mucosa to be replaced. (32)

The stratum spinosum is the next layer, which provides the intercellular bridges that give the buccal mucosa the prickly look under light microscopy. The outer two layers stratum intermedium and stratum superficiale are difficult to delineate from each other. These two layers, however, are unique in that they are more firmly attached to each other, providing excellent barrier protection. (32)

The lamina propria of the buccal mucosa is rich in collagen and elastin. Elastin fibers are more numerous in the buccal mucosa than in other tissues, allowing the buccal mucosa to recoil after stretching. The lamina propria further provides long, slender papillary invaginations into the epithelium and loose collagen fibers and loops of capillaries from which the epithelium gets its blood supply. The web like reticular layer of the lamina propria holds the vasculature and nerves of the buccal mucosa. The lamina propria is thin compared with bladder mucosa and skin, which facilitates inosculation and neovascularization. The line between the submucosa and the lamina propria is difficult to delineate. The submucosa, which is firmly attached to the underlying buccinator muscle, is also rich in collagen and elastin, which makes the tissue easy to handle and durable. There are also minor salivary and sebaceous glands. A major salivary gland duct (Stensen's duct) from the parotid gland pierces the buccinator muscle opposite the maxillary second molar bilaterally. (31)

The arterial blood supply to the buccal mucosa originates from the facial artery, the buccal artery, the posterior superior alveolar artery, and the anterior superior alveolar artery. These perforate the buccinator muscle to supply the buccal mucosa. Sensory input for the buccal mucosa is carried through the trigeminal nerve, and buccinator motor function is supplied by cranial nerve VII. (31)

The function of the buccal mucosa is a direct result of its structure. A tight spinosum layer and pump-functioning cells of the superficial layer provide protection from substances placed in the oral cavity. Elastin and collagen without bony attachment give the buccal mucosa flexibility and the ability to distend and compress. A rapid turnover rate and highly

vascularized lamina propria ensure quick healing after injury. The immune response is quickly aided by a lamina propria laden with lymphocytes and macrophages. (31)

The mucosa covering the lateral and under surface of the tongue is thin, smooth, and identical in structure with the lining of the rest of the oral cavity. Therefore it shares the same advantages such as easy harvesting, favorable immunologic properties (resistance to infection) and tissue characteristics (thick epithelium, high content of elastic fibers, thin lamina propria, rich vascularization) that are favorable properties for imbibition, inosculation, and revascularization of the graft. (27)

3. Harvesting the oral mucosa

Buccal mucosa may be harvested from the inner surface of the cheek or the inner surface of the upper or lower lip. For a single strip of buccal mucosa to be used as an onlay patch, the adult cheek provides up to 6 cm and the lip 4 cm length with 12 to 15 mm width. It is not advisable to continue the strip of buccal mucosa through the angle of the mouth to combine both cheek and lip segments in continuity for 10 cm. In the experience of Ransley, 1999 (12) the only buccal mucosa donor graft site complicated by a significant contracture was at the angle of the mouth. (12)

The mucosa of the cheek is preferable than that of the lip because the mucosa of the cheek is thicker and more robust than the mucosa of the lip. Also, the width of the lip limits the size of the graft. However in terms of outcomes, there is probably little difference between cheek and lip. (12)

General anesthesia via endotracheal intubation is the preferred method of airway control to facilitate access to the oral cavity. A surgical marking pen is used to outline the extent and shape of the graft away from the parotid papilla. The area should not encroach on the mental nerve, nor extend further back than the pterygomandibular raphe, and leave a cuff of mucosa 1 cm from the labial commissure. (14) The graft is better outlined as an elliptical shape, which eases closure of the anterior and posterior aspects of the donor site without compromising graft size or viability. A graft that is at least 10% longer and 10 - 20% wider than actually necessary is obtained to allow for shrinkage. (33)

Hydro-dissection of the oral mucosa from the underlying soft tissues using 1% lidocaine with 1:100,000 epinephrine and the use of a No. 15 blade is recommended so that the incision is limited to the full thickness of the mucosa only. (34) Dissection of the buccinator muscle can lead to damage of the buccal neurovascular bundle. Also, branches of the facial nerve lying deep within this muscle would not be damaged by this incision. (9)

Harvesting the graft is slightly painful but not disabling in the post-operative period. Pain appears to be worse in the immediate post-operative period after suturing the harvest site. There is no difference in long-term post-operative morbidity whether the graft site is closed or left open however, some authors recommended to leave the buccal mucosa harvest sites unsutured. (35) Post-operative discomfort can be lessened by a diet of soft meals and by cleansing of the wound daily with povidone iodine solution. Some difficulty with mouth opening might be experienced during the early postoperative period but it will return to the normal range even if complications of wound healing have occurred. (9)

Harvesting lingual mucosal grafts follows the basic principles as that of the buccal mucosa with few differences. Harvesting the tongue should be technically easier than from the inner cheek since the tongue can be pulled out of the mouth with a traction suture. (Fig. 1)

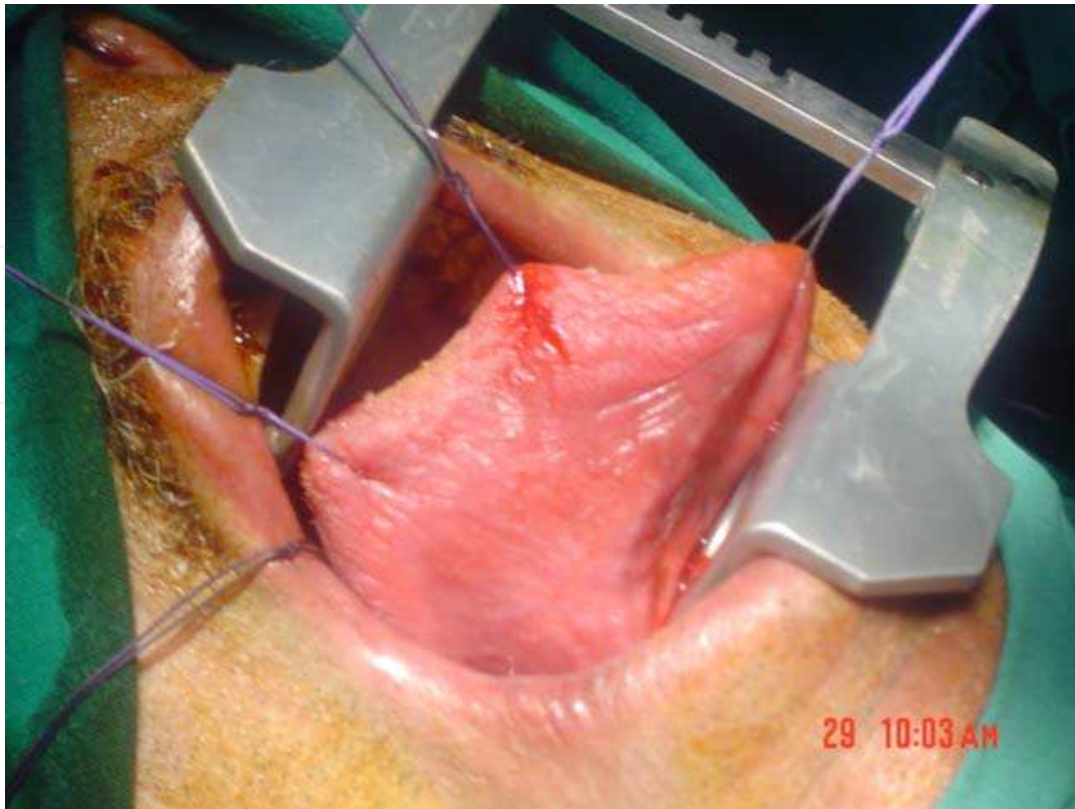


Fig. 1. Site of graft excision from lateral and undersurface of the tongue

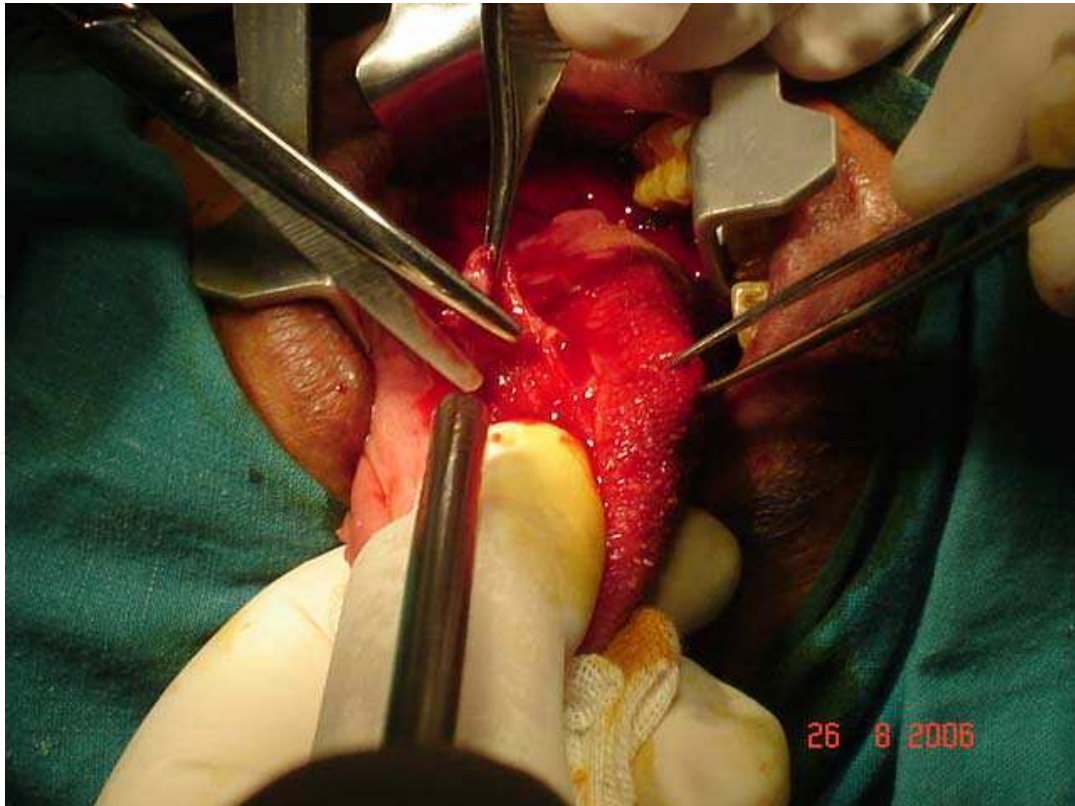


Fig. 2. Harvesting the graft

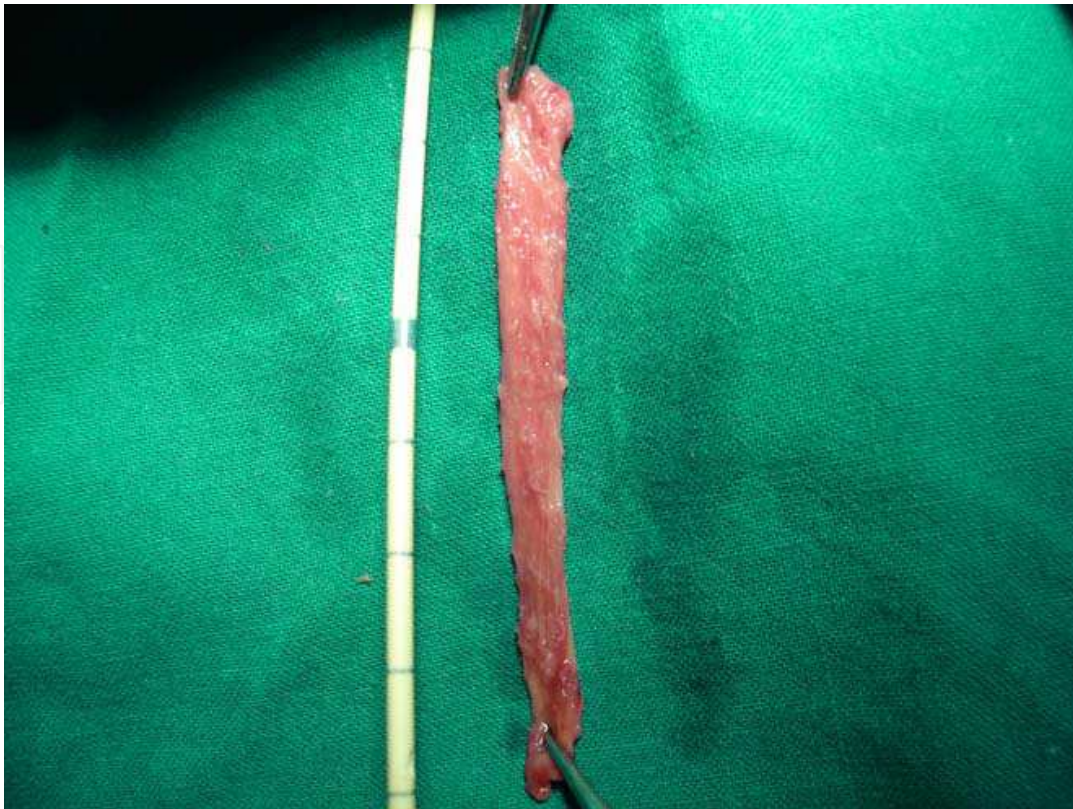

Fig. 3. Lingual graft excised

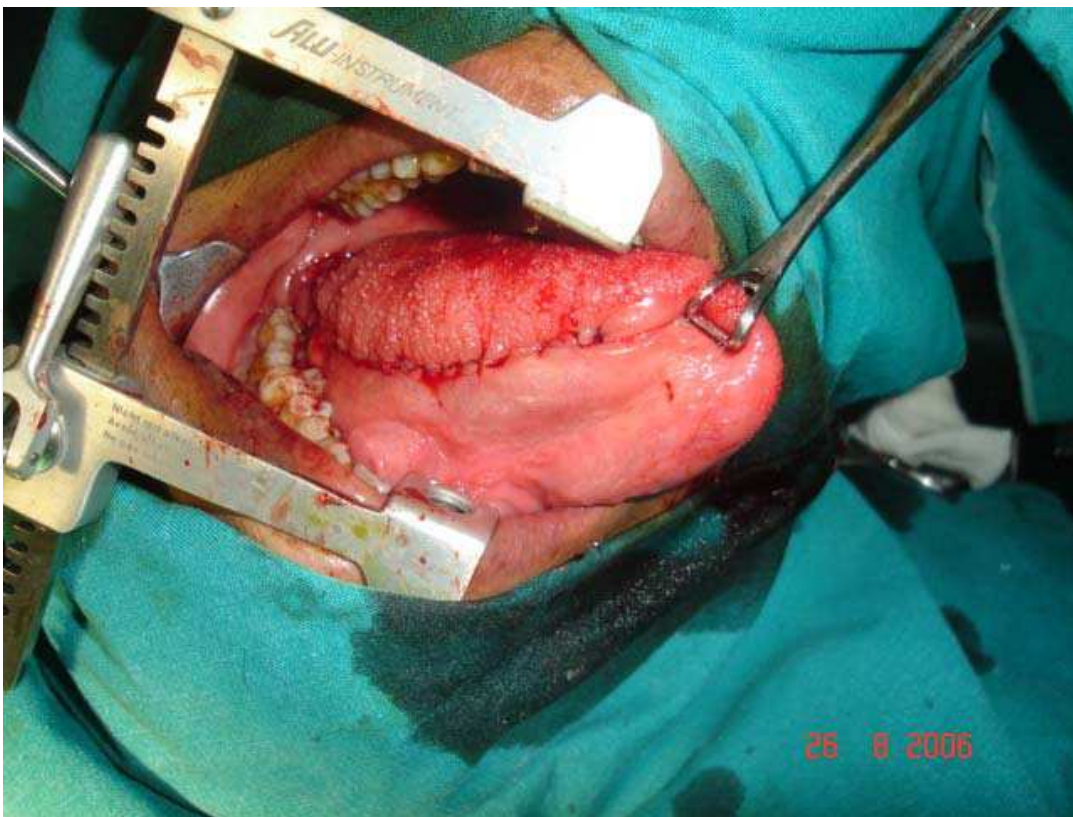


Fig. 4. Donor site closed

However, there is more bleeding associated with the lingual graft because the tongue is more vascular than the cheek. (25) During graft harvesting, care should be taken to the site of the opening of Wharton's duct and the underlying lingual nerve.

Simonato et al. (20) reported the lateral mucosal lining of the tongue as the harvest graft site since it is identical to the lining of the rest of the oral cavity and has no particular functional features. (20) Barbagli et al. (25) similarly described graft harvesting from the ventral surface of the tongue, suggesting that, when necessary, two grafts can be harvested from the same ventral tongue site. (25) In our description of the technique we suggested taking the graft from the lateral and undersurface of the tongue between the papillae situated on the dorsum and the sublingual mucosa. (29) (Fig. 2) Simonato, later admitted that the description of the surgical technique was inaccurate in his first report (36) and made clear that the site of the harvest graft is the ventrolateral mucosal surface of the tongue. (36)

In Barbagli's experience, the length of the lingual grafts was 4–6 cm (mean: 4.5 cm) with a width of 2.5 cm. (25) In our study, the length of the LMG used ranged from 4–10 cm and a width of 1.5 cm. (Fig. 3) Recently, Kumar et al. (26) reported harvesting a long (16.4 cm) and narrow (1–1.5 cm) lingual graft from the entire lateral mucosal lining of the tongue. (26)

In contrast to buccal mucosa the donor site must be closed with 4–0 polyglactin sutures at the end of the harvesting technique. (29) (Fig. 4)

4. Tips and tricks in the urethroplasty

Oral mucosa may be used as an onlay patch if the urethral plate is retained, as a complete tube if there is no available urethral plate or in various ways combined with other tissues. (30)

However, two main problems are faced using buccal mucosa as a tube graft. First, strips of oral mucosa should not be tubularized lengthwise to create 6 cm or 4cm tubes, because the width is insufficient. They can be folded lengthwise to provide shorter tubes of up to 3cm and 2cm, respectively or a second graft of similar dimensions can be applied to create a full-length cylinder of adequate diameter. (12)

Another problem with tube grafts in general is the inadequate graft take, as they are not circumferentially surrounded by vascularized tissue leading to increased incidence of contraction and anastomotic stricture that have led some to avoid tube grafts in favor of onlay procedure. (13, 37)

Traditionally, grafts have been placed on the ventral aspect of the urethra because it allows for easier access to the urethra and better visualization of the stricture. However, with a higher reported incidence of diverticula formation, due to poor support, and consequently postvoid dribbling and ejaculatory dysfunction. (38) Barbagli et al (39) introduced the dorsally placed graft and postulated that dorsal placement is advantageous as it allows better mechanical support for the graft with a richer vascular bed from the underlying corporeal bodies. (39) However, they recently compared the results of buccal mucosal urethroplasty in 50 patients with bulbar urethral strictures. Buccal mucosa grafts were placed on the ventral, dorsal and lateral bulbar urethral surface in 17, 27 and 6 cases, respectively. They reported that the placement of buccal mucosa grafts into the ventral, dorsal or lateral surface of the bulbar urethra showed the same success rates (83% to 85%) and the outcome was not affected by the surgical technique. Moreover, stricture recurrence was uniformly distributed in all patients. (40)

5. The process of take

The free graft initially adheres to its new bed by fibrin, and revascularization is achieved by the outgrowth of capillary buds from the recipient area to unite with those on the deep surface of the graft. This link up is usually well advanced by the third day. During this period (first 48 h.), the graft depends on imbibitions from the surrounding tissue. At the same time with the vascular link-up, the fibrin is infiltrated by fibroblasts, which gradually convert the initial weak adhesion provided by the fibrin clot into a definitive attachment by fibrous tissue. The strength of this attachment increases quickly, providing an anchorage within 4 days, which allows the graft to be handled safely if reasonable care is taken. More slowly a lymphatic link up is added and, even more slowly, nerve supply is re-established, although imperfectly and invariably. Of these various processes the ones most relevant in clinical practice are vascularization and fibrous tissue fixation. The speed with which this is accomplished, is determined by the characters of the bed on which the graft is laid, the characteristics of the graft itself, and the condition under which the graft is applied. (41)

The bed on which the graft is laid must have fibrinogen and the enzymes, which convert it into fibrin in sufficient quantities to provide the necessary adhesion. Sometimes the surface is harboring streptococcus pyogens, which destroys fibrin by its potent fibrinolysin action. Also, the bed should have enough blood supply to vascularize the graft. Rapid vascularization is important, and the distance to be traveled by the capillary buds in order to link-up clearly needs to be as short as possible. The graft has therefore to be in the closest possible contact with the bed. The most frequent cause of separation is bleeding from the bed; the resulting haematoma acts as a block to link-up of the outgrowing capillaries. (42)

The graft has also to lie immobile on the bed until it is firmly attached. In particular, shearing strains, which tend to make the graft slide to and fro and prevent capillary link-up, are to be avoided until the initial fibrin adhesion has been converted into a strong fibrous tissue anchorage. (42)

In summary, the graft take requires a bed that is capable of providing the necessary capillary outgrowth to vascularize a graft, free of pathogens inimical to graft take in addition to an immobile close contact between graft and bed. The most frequent cause of graft loss is the presence of a hematoma which separates the graft from its bed and or shearing movements which prevent adhesion between graft and bed, each in its own way preventing capillary link up and vascularization. (42)

6. Indications

In patients with congenital or acquired urethral defects, short or lengthy segments of the urethra need to be reconstructed. Vascularized preputial and penile shaft skin flaps are frequently used to achieve this. (43)

After repeated previous surgery there is lacking of penile and preputial skin and the blood supply of these skin flaps is disturbed so that free graft material is preferred. Free skin graft material from extragenital regions is less suitable due to the thickness, hair growth or tendency to contract. The use of bladder mucosal free graft includes the additional and not inconsiderable burden for the patient arising from graft harvesting, and is procedurally quite complicated. Furthermore, postoperative complications caused by cauliflower-like deformities in the meatus externus urethrae are frequent. These aspects have greatly reduced the potential of this operating technique. (5)

The first very good results of buccal mucosa as a free graft encourage its usage in these situations. El-Kassaby and associates, 1993 (11) recommended the use of buccal mucosal graft in the treatment of anterior urethral stricture. They used this technique for treatment of short strictures (1 to 2cm) that usually required a 2 to 4 cm repair, making excision and end-to-end anastomosis impractical. Buccal mucosa has also been used to replace urethra in epispadias repairs in exstrophy patients whose penile skin is insufficient. (44)

So, we can summarize the current indications for the use of buccal mucosal free grafts for substitution urethroplasty in:

- Anterior urethral strictures.
- Proximal hypospadias especially in circumcised patients.
- Crippled hypospadias where there is no sufficient genital skin.
- Epispadias when the penile skin is insufficient.

7. Advantages

- Easily accessible, non-hair bearing and the supply source is constant and adequate.
- The intraoral donor site guarantees an excellent cosmetic result.
- The graft is extremely elastic and shows only a slight tendency to contraction.
- The graft has been noted to retain the elasticity of the virgin tissue.
- The meatal problems of excoriation, encrustation and protuberance that encountered with bladder mucosa, have not been a problem with buccal mucosa.
- High resistance to infection and trauma and high regenerative power.
- Buccal mucosa is characterized by thick epithelial layer and thin lamina propria that make the graft mechanically stiff and easy handled and aid in rapid vascularization of the graft.

8. Disadvantages

- The oral mucosa cannot be tubularized to create long tubes because the width is insufficient. So, it can be folded lengthwise to provide shorter tubes or a second flap of similar dimensions can be applied to create a full-length cylinder of adequate diameter.
- It may lead to a significant contracture at the angle of the mouth if the buccal mucosal graft is taken through the angle.
- Liability of injury to superficial branches of the facial nerve.
- Stricture and fistula continue to be a problem with buccal mucosa as with any other free graft.

9. Results of oral mucosa urethroplasty

There is no doubt, both subjectively and objectively, that oral mucosa is proving very satisfactory as a material for urethral reconstruction. This may be due to growth factors within the mucosa that promote rapid healing, revascularization occurs quickly because of the thin lamina propria and the originally highly vascular bed from which the buccal mucosal graft was taken. (43)

In their early report of the use of buccal mucosa in hypospadias repair, Dessanti and associates, 1992 (10) reported only one case of urethral fistula out of 8 hypospadias patients

after 6-18 months of follow up. Another two patients required urethral dilatation during the initial 4 weeks because of mild anastomotic stenosis. No meatal problems such as stenosis or granulomatous reactions was observed. (10)

Similarly, Burger and associates (9) in the same year used buccal mucosa in 6 patients; failed hypospadias repair (3), severe stricture after hypospadias repair (1), short urethra (1) and epispadias in 1 patient. The results were 3 urethral fistulae and 1 meatal stenosis in 3 patients. No urethral stricture or diverticulum was noted, and the final outcome was good functionally and cosmetically in all patients. (9)

One year later El-Kasaby and associates (11) reported their experience with buccal mucosa patch graft in the management of 20 patients with anterior urethral strictures. Results were excellent in 18 patients while 2 required revision for recurrent stricture. (11)

The experience of Ransley and Manzoni, 1999 (12) with buccal mucosal graft extended to more than a 100 case. They reported a secondary operation rate of approximately 20%, which are mostly due to minor fistulae or the need for meatal revision. Radical reoperation with further urethral augmentation with an additional buccal mucosal graft had been necessary on some occasions. They recommended the use of preoperative testosterone treatment in difficult cases to improve the vascularity of the penile skin and thereby enhance the chances of success with a free graft technique. (12)

Barbagli and associates (39) have an extensive experience in the use of buccal mucosa for treatment of anterior urethral strictures. In 1998, they reported the use of buccal mucosa as a dorsal onlay graft in the management of 6 adult patients with bulbourethral strictures. The results were excellent with no stricture recurred in 6 patients. (39) In 2007, (45) they reported the results of 94 patients who underwent bulbar urethral reconstruction using two dorsal onlay techniques, namely augmented anastomotic urethroplasty and dorsal onlay graft urethroplasty. Forty-eight out of 94 patients received skin grafts and 46 buccal mucosal grafts. Twenty-eight (58.3%) out of 48 penile skin grafts were successful and 20 (41.7%) failed. Thirty-six (78.3%) out of 46 buccal mucosa grafts were successful and 10 (21.7%) failed. They concluded that buccal mucosa seems to be the best substitute graft material for bulbar urethroplasty using dorsal approach. (45)

More recently, Palminteri and associates, 2008 (15) used buccal mucosa as combined dorsal plus ventral graft in 48 patients with bulbar urethral stricture where 43(89.6%) patients were successful and 5(10.4%) patients showed failures in the form of recurrence of the stricture. (15)

In 2002, we reported our results of the use of three different types of free grafts (skin, bladder and buccal) in urethral reconstruction. The results showed that buccal mucosal graft had the highest success rate. Buccal mucosal graft was used in 25 patients, 10 hypospadias and 15 patients with urethral stricture. As regard the hypospadias patients (40%) were primary and (60%) were redo cases. The buccal mucosa was applied as patch graft in all patients. The length of the grafts ranged from 2.5-6 cm. The success rate was (70%) where 3 patients showed 4 complications in the form of 2 fistulae, one meatal stenosis and one breakdown. In urethral stricture patients, (26.7%) were primary and (73.3%) were secondary cases. The stricture was bulbar in all patients. The buccal mucosal graft was applied as patch graft in all patients. The length of the graft ranged from 3-5cm. Four patients showed 4 complications in the form of one urethrocutaneous fistula, one neourethral stenosis and 2 anastomotic strictures. The fistula was minute and closed spontaneously. The final success rate was (80%). (46)

At that time, we concluded that urethral reconstruction using buccal mucosa is a useful technique and the results appear to be acceptable given the difficulty of the cases in which buccal mucosa was used. The structure, function and ease of working with buccal mucosa make it the ideal extragenital source for reconstruction of the urethra in complex hypospadias and urethral stricture. Easiness of harvesting and rapid healing process also contributes to its superiority. As in all urethral reconstructions, the learning curve is long. However, as one becomes more familiar with urethral reconstruction using buccal mucosa, no doubt the complication rate will decrease measurably. (46)

Among the good results of the oral mucosa urethroplasty, the lingual mucosa is no exception. In their pioneering report, Simonato et al (20) reported seven successful cases out of the 8 cases included in his study achieving a success rate of 87.5%. (20) In a following report, they reported a series of 29 patients with anterior urethral strictures who underwent urethral reconstruction using LMG. The mean stricture length was 3.6 cm (range, 1.5–9.0 cm). The length of the LMG used ranged from 3 cm to 9 cm (mean, 5.3 cm), with a mean width of 1.5 cm. Mean follow-up time was 17.7 months (range, 6–71 months). The overall early stricture recurrence was 20.7%. (27)

Since then a number of groups have investigated the feasibility of lingual mucosa graft urethroplasty (16, 17, 21–23, 25, 26, 29, 30, 36, 47) whether experimentally (17, 21) or clinically, (16, 22, 23, 25, 26, 29, 30, 36, 47) alone or with buccal mucosa, (16, 17) and with different urethroplasty techniques. (23, 26, 47)

Barbagli et al (25) later described their early experience using LMG for urethral reconstruction in 10 patients with anterior urethral strictures. The length of urethral strictures was 2–6 cm and the length of the lingual grafts was 4–6 cm (mean, 4.5 cm) with a width of 2.5 cm. Mean follow-up time was 5 months (range, 3–12 months); nine cases (90%) were successful. (25)

We have also described our early results of lingual mucosa urethroplasty in 18 patients with long recurrent strictures of the anterior urethra. (29) Their mean age was 39.5 years (18–66 years), and the mean stricture length was 4.36 cm (3–9 cm). Of the 18 cases, 6 were penile, 8 bulbar, and 4 bulbopenile. The primary etiology was traumatic in 8 cases, iatrogenic in 6 cases, and inflammatory in 4 cases. Previous stricture treatments included dilations in all 18 patients, optical internal urethrotomy in 14, hypospadias repair in 2, and failed BMG urethroplasty in 2. The graft was placed dorsally in 12 cases and ventrally in 6 cases. The mean operative time was about 177 mins (140–210 mins) using a one-team approach. The length of the LMG used ranged from 4–10 cm and a width of 1.5 cm. The graft was harvested unilaterally in 15 (83%) cases and bilaterally in 3 (17%) cases. There was no need for intraoperative blood transfusions, and there were no major perioperative complications. (29)

There were 15 successful cases (83.3%), 2 patients had resticture at the anastomotic site, and 1 patient showed a urethrocutaneous fistula. In the successful cases, there were no residual strictures and no urethral diverticulae or sacculations in their urethrograms at 3 months. The peak flow rate improved from a mean of 4.98 ml/s (0.6–8.6 ml/s) to 27.28 ml/s (22.4–39.6 ml/s). Urethroscopy was done in 10 out of the 15 successful cases and revealed that LMGs were almost indistinguishable from the native urethra. (29)

In another prospective randomized controlled study, we compared outcomes as well as donor site complications of buccal mucosal graft (BMG) (20 patients) versus lingual mucosal graft (LMG) (20 patients) dorsal onlay urethroplasty in 40 patients with anterior urethral

strictures. Early and late complications, success rate and patient satisfaction were compared between the two groups.

The number of patients with pendulous, bulbar and bulbopendulous strictures as well as the mean stricture length and mean follow-up were comparable between the two groups. No significant difference between both groups in the operative time, hospital stay, early postoperative pain and time to resume fluid intake and normal diet. Late after surgery, the postoperative pain, perioral numbness and tightness of the mouth as well as changes in salivary function were significantly higher in the buccal mucosa (BMG) group versus the lingual mucosa (LMG) group ($p < 0.01$). The success rate in both groups was similar (90% in the BMG group and 85% in the LMG group) ($p > 0.05$). In the BMG group 80% and in the LMG group 85% said they would recommend this procedure to another patient ($p > 0.05$). (16)

Recently, Xu et al (47) published the biggest lingual mucosa urethroplasty series in 92 cases. After a mean follow-up of 17.2 months, complications reported in 8 patients, including urinary fistulas in 4 patients; recurrent strictures developed in 4 patients at 3–4 months post-operatively. (47)

10. Conclusion

Being easy to harvest and to handle, immune to infections and accustomed to a wet environment, the oral mucosa displays many inherent characteristics of an ideal graft substitute for urethroplasty.


11. References

- [1] Duckett JW. Transverse preputial island flap technique for repair of severe hypospadias. *Urol Clin North Am*. 1980;7:423-430.
- [2] Mitchell ME, Adams MC, Rink RC. Urethral replacement with ureter. *J Urol*. 1988;139:1282-1285.
- [3] Snow BW, Cartwright PC. Tunica vaginalis urethroplasty. *Urology*. 1992;40:442-445.
- [4] Hendren WH, Crooks KK. Tubed free skin graft for construction of male urethra. *J Urol*. 1980;123:858-861.
- [5] Ehrlich RM, Reda EF, Koyle MA, Kogan SJ, Levitt SB. Complications of bladder mucosal graft. *J Urol*. 1989;142:626-627.
- [6] Filipas D, Wahlmann U, Hohenfellner R. History of oral mucosa. *Eur Urol*. 1998;34:165-168.
- [7] Humby G, Higgins TT. A one stage operation for hypospadias. *British Journal of Surgery*. 1941;29:84-92.
- [8] editor. 1986; Southhampton, England: 1986.
- [9] Burger RA, Muller SC, el-Damanhoury H, Tschakaloff A, Riedmiller H, Hohenfellner R. The buccal mucosal graft for urethral reconstruction: a preliminary report. *J Urol*. 1992;147:662-664.
- [10] Dessanti A, Rigamonti W, Merulla V, Falchetti D, Caccia G. Autologous buccal mucosa graft for hypospadias repair: an initial report. *J Urol*. 1992; 147:1081-1083.

- [11] el-Kasaby AW, Fath-Alla M, Noweir AM, el-Halaby MR, Zakaria W, el-Beialy MH. The use of buccal mucosa patch graft in the management of anterior urethral strictures. *J Urol*. 1993;149:276.
- [12] Ransley PG, Manzoni GM. Buccal mucosa graft for hypospadias. In: Ehrlich RE, Alter GJ, editors. *Reconstructive and Plastic Surgery of the external Genitalia, Adult and Pediatric*. Philadelphia, PA: WB Saunders company; 1999. p. 121.
- [13] Bhargava S, Chapple CR. Buccal mucosal urethroplasty: Is it the new gold standard? *BJU Int*. 2004;93:1191-1193.
- [14] Fabbroni G, Loukota RA, Eardley I. Buccal mucosal grafts for urethroplasty: Surgical technique and morbidity. *Br J Oral Maxillofac Surg*. 2005;43:320-323.
- [15] Palminteri E, Manzoni G, Berdondini E et al. Combined dorsal plus ventral double buccal mucosa graft in bulbar urethral reconstruction. *Eur Urol*. 2008;53:81-89.
- [16] Elgamal S, Ragab MM, Farahat Y, Elnady M, Elsharaby M, Abo Farha O. A prospective randomized study comparing buccal and lingual mucosal dorsal onlay graft for management of anterior urethral strictures. *Tanta Medical Journal*. 2008;36:597-608.
- [17] Hu X, Xu Y, Song L, Zhang H. Combined Buccal and Lingual Mucosa Grafts for Urethroplasty: An Experimental Study in Dogs. *J Surg Res*. 2009
- [18] Kumar A, Das SK, Trivedi S, Dwivedi US, Singh PB. Substitution urethroplasty for anterior urethral strictures: buccal versus lingual mucosal graft. *Urol Int*. 2010;84:78-83.
- [19] Singh O, Gupta SS, Arvind NK. Anterior urethral strictures: a brief review of the current surgical treatment. *Urol Int*. 2011;86:1-10.
- [20] Simonato A, Gregori A, Lissiani A et al. The tongue as an alternative donor site for graft urethroplasty: a pilot study. *J Urol*. 2006;175:589-592.
- [21] Song LJ, Xu YM, Hu XY, Zhang HZ. Urethral substitution using autologous lingual mucosal grafts: an experimental study. *BJU Int*. 2008;101:739-743.
- [22] Simonato A, Gregori A. Oral complications after lingual mucosal graft harvest for urethroplasty. *ANZ J Surg*. 2008;78:933-934.
- [23] Singh PB, Das SK, Kumar A et al. Dorsal onlay lingual mucosal graft urethroplasty: Comparison of two techniques. *Int J Urol*. 2008;15:1002-1005.
- [24] Trivedi S, Kumar A, Goyal NK, Dwivedi US, Singh PB. Urethral reconstruction in balanitis xerotica obliterans. *Urol Int*. 2008;81:285-289.
- [25] Barbagli G, De Angelis M, Romano G, Ciabatti PG, Lazzeri M. The use of lingual mucosal graft in adult anterior urethroplasty: Surgical steps and short-term outcome. *Eur Urol*. 2008;54:671-676.
- [26] Kumar A, Das SK, Sharma GK et al. Lingual mucosal graft substitution urethroplasty for anterior urethral strictures: our technique of graft harvesting. *World J Urol*. 2008;26:275-280.
- [27] Simonato A, Gregori A, Ambruosi C et al. Lingual mucosal graft urethroplasty for anterior urethral reconstruction. *Eur Urol*. 2008;54:79-85.
- [28] Das SK, Kumar A, Sharma GK et al. Lingual mucosal graft urethroplasty for anterior urethral strictures. *Urology*. 2009;73:105-108.

- [29] Ragab MM, Elgamal S, Farahat Y, Saber W, Hawas M, Elsharaby M. Urethroplasty with lingual mucosal graft for management of long and recurrent strictures of the anterior urethra. *Urotoday Int J*. 2009;2
- [30] Xu YM, Sa YL, Fu Q, Zhang J, Si JM, Liu ZS. Oral mucosal grafts urethroplasty for the treatment of long segmented anterior urethral strictures. *World J Urol*. 2009;27:565-571.
- [31] Brock JW, Nelson E. Buccal mucosa reconstruction of the urethra. In: Ehrlich RE, Alter GJ, editors. *Reconstructive and Plastic Surgery of the External Genitalia, Adult and Pediatric*. WB Saunders company; 1999. p. 126.
- [32] Strachan DS, Avery JK. Histology of the oral mucosa and tonsils. In: Avery JK, editor. *Oral development and histology*. Thieme Medical Publishers; 2001. p. 243.
- [33] Wood DN, Allen SE, Andrich DE, Greenwell TJ, Mundy AR. The morbidity of buccal mucosa graft harvest for urethroplasty and the effect of nonclosure of the graft harvest site on postoperative pain. *J Urol*. 2004;172:580-583.
- [34] Markiewicz MR, Margarone JE, Barbagli G, Scannapieco FA. Oral mucosa harvest: An overview of anatomic and biologic considerations. *EAU-EBU update series*. 2007;5:179-187.
- [35] Muruganandam K, Dubey D, Gulia AK et al. Closure versus nonclosure of buccal mucosal graft harvest site: A prospective randomized study on postoperative morbidity. *Indian J Urol*. 2009;25:72-75.
- [36] Simonato A, Gregori A. Lingual mucosal grafts for anterior urethroplasty: a review. *BJU Int*. 2010;105:132-133.
- [37] Woodall JR, Gosalbez R, Barone J, Perez LM. Buccal mucosa: Free grafts in complicated urethral reconstruction. *Reconstructive Surgery of the Lower Urinary Tract in Children*. Oxford: Isis Medical Media; 1995. p. 29.
- [38] Wessels H, McAninch JW. Use of free grafts in urethral stricture reconstruction. *J Urol*. 1996;155:1912-1915.
- [39] Barbagli G, Palminteri E, Rizzo M. Dorsal onlay graft urethroplasty using penile skin or buccal mucosa in adult bulbourethral strictures. *J Urol*. 1998;160:1307-1309.
- [40] Barbagli G, Palminteri E, Guazzoni G, Montorsi F, Turini D, Lazzeri M. Bulbar urethroplasty using buccal mucosa grafts placed in the ventral, dorsal or lateral surface of the urethra: Are results affected by the surgical technique? *J Urol*. 2005;174:955-958.
- [41] Triana RJJ, Murakami CS, Larrabee WFJ. Skin grafts and local flaps. In: Papel ID, editor. *Facial Plastic and Reconstructive Surgery*. New York, NY: Thieme Medical Publishers; 2009. p. 41.
- [42] McGregor AD, McGregor IA. Free Skin Grafts. In: McGregor AD, McGregor IA, editors. *Fundamental Techniques of Plastic Surgery and their Surgical Applications*. Philadelphia, Pa.; Churchill Livingstone; 2000. p. 35-59.
- [43] Duckett JW, Coplen D, Ewalt D, Baskin LS. Buccal mucosal urethral replacement. *J Urol*. 1995;153:1660-1663.
- [44] Dessanti A, Iannuccelli M, Ginesu G, Feo C. Reconstruction of hypospadias and epispadias with buccal mucosa free graft as primary surgery: more than 10 years of experience. *J Urol*. 2003;170:1600.

- [45] Barbagli G, Lazzeri M. History and evolution of dorsal onlay urethroplasty for bulbar urethral stricture repair using skin or buccal mucosal grafts. *Urologia*. 2007;74:233.
- [46] Haroun H. Evaluation of three different free grafts in urethral reconstruction. [dissertation]. Tanta, Egypt: M.D Thesis in Urology, Tanta University; 2002.
- [47] Xu YM, Fu Q, Sa YL et al. Treatment of urethral strictures using lingual mucosae urethroplasty: experience of 92 cases. *Chin Med J (Engl)*. 2010;123:458-462.



Current Concepts of Urethroplasty

Edited by Dr Ivo Donkov

ISBN 978-953-307-392-7

Hard cover, 152 pages

Publisher InTech

Published online 19, July, 2011

Published in print edition July, 2011

Urethral reconstructive surgery has always been a challenging part for urologist since the dawn of our speciality. In this book leading experts in lower urinary reconstructions from all over the world present their views and experience in that field, together with practical tips and tricks. The book is an excellent source of information for those who are already dealing with urethral surgery, and also an invaluable companion for urologists in training or those who want to dedicate themselves to this great sub-specialty. This book is an excellent reference guide and companion on the way to operating and consulting room, or when writing an article and reviewing the current practices. The abundance of methods and continuing development of new approaches to the problem prove the complexity of it.

How to reference

In order to correctly reference this scholarly work, feel free to copy and paste the following:

Maged Ragab and Hossam Haroun (2011). Oral Mucosa Graft: An Ideal Substitute for Urethroplasty, Current Concepts of Urethroplasty, Dr Ivo Donkov (Ed.), ISBN: 978-953-307-392-7, InTech, Available from: <http://www.intechopen.com/books/current-concepts-of-urethroplasty/oral-mucosa-graft-an-ideal-substitute-for-urethroplasty>

INTeCH
open science | open minds

InTech Europe

University Campus STeP Ri
Slavka Krautzeka 83/A
51000 Rijeka, Croatia
Phone: +385 (51) 770 447
Fax: +385 (51) 686 166
www.intechopen.com

InTech China

Unit 405, Office Block, Hotel Equatorial Shanghai
No.65, Yan An Road (West), Shanghai, 200040, China
中国上海市延安西路65号上海国际贵都大饭店办公楼405单元
Phone: +86-21-62489820
Fax: +86-21-62489821

© 2011 The Author(s). Licensee IntechOpen. This is an open access article distributed under the terms of the [Creative Commons Attribution 3.0 License](https://creativecommons.org/licenses/by/3.0/), which permits unrestricted use, distribution, and reproduction in any medium, provided the original work is properly cited.

IntechOpen

IntechOpen