

We are IntechOpen, the world's leading publisher of Open Access books Built by scientists, for scientists

6,900

Open access books available

186,000

International authors and editors

200M

Downloads

Our authors are among the

154

Countries delivered to

TOP 1%

most cited scientists

12.2%

Contributors from top 500 universities



WEB OF SCIENCE™

Selection of our books indexed in the Book Citation Index
in Web of Science™ Core Collection (BKCI)

Interested in publishing with us?
Contact book.department@intechopen.com

Numbers displayed above are based on latest data collected.
For more information visit www.intechopen.com



Management of Post Hypospadias Urethral Fistula

Sherif Shehata and Mohamed Hashish

*Department of Pediatric Surgery, Tanta University Hospital, Tanta,
Egypt*

1. Introduction

Complications after any surgical procedures are normal consequences within the standard acceptable percentage among surgeons. Complications are higher in hypospadias surgery as compared to other reconstructive operations. Urethrocuteaneous fistula after hypospadias surgery repair is the most common complication and remains a frustrating problem for surgeons [21].

Generally fistula is defined as a tract connecting two epithelial surfaces. Furthermore, the problem is exacerbated because urethrocuteaneous fistula not only occurs but also recurs, sometimes with all the potential harmful physical and psychological consequences. However, with the improvement in suture material and surgical techniques, such complications are increasingly unacceptable. The occurrence of urethrocuteaneous fistulae precludes a goal of hypospadias surgery [6].

The reported incidence of urethrocuteaneous fistula ranged, from 0 to 30%, varying with the severity of hypospadias, surgical technique, and experience of the operating surgeon [5]. Unfortunately there is no one single perfect technique to repair any urethrocuteaneous fistula. The temptation to simply close the hole without understanding the failure mechanisms is dangerous and often leads to recurrence of the fistula or even worse [29].

Many factors influence the results of fistula repair such as the conditions of local tissue, time after hypospadias repair, the number, location and size of the fistula [29]. These factors can be preventable when considered, experience and surgical tips are needed to improve the outcomes in cases of hypospadias fistulae.

2. Incidence of fistula formation

Generally, the incidence of fistula varies from 0 to 30 %. It is less in urethral plate preservation procedures like tabularized incised plate (TIP) and onlay flap as compared to inner preputial flap and tube urethroplasty.

The incidence of fistula formation has decreased gradually in the past two decades. In 1973, Horton and Devine estimated the incidence of fistula following hypospadias surgery to range between 15 % and 45 % [18]. In 1984, Shapiro found a urethral fistula rate of 6.25 % in a series of 176 hypospadias repairs including various techniques of repair [32].

Nowadays, the incidence of fistula was varied among different techniques of repair as some procedures are more prone to fistula formation than others [15]. For example, Durham

Smith in 1981 noted that the fistula rate for the meatoplasty and glanuloplasty (MAGPI) procedure ranged from 0.5 % to 10 %, whereas the rate for flip-flap repairs varied from 2.2 % to 35 % and that for island pedicle tube repairs from 4 % to 33 % [37]. Free graft tube-repairs are encountered with higher fistula rates of 15-50 %. While using a two-stage repair, in more than 500 cases, Durham Smith in 1990 reduced his incidence of fistula formation to less than 3 % [36]. Similarly, Greenfield and colleagues reported a urethral fistula rate of 2.5 % with a two-stage repair [12].

3. Classification of fistula

The Beginning of fistula formation occurs early in the healing process after ventral urethral repair usually between the 7th-10th post operative days [3]. Post hypospadias urethral fistula could be classified according to many aspects into different classifications:

- 1. According to site or location into:
 - Anastomotic fistula
 - Non anastomotic fistula

The urethrocutaneous fistula may occur anywhere along the neourethra. However, the most common sites include the site of the original meatus, glans penis, at the coronal level in tubularization urethroplasty and at the site of anastomosis in flap urethroplasty [8].

- 2. According to the size into:
 - Pin point fistula
 - Small fistula
 - Mega fistula.

Small tiny fistulas may occur even with experienced surgeons using delicate techniques. Mega fistula with diameter more than 4-5 mm in its largest diameter represents a form of incomplete disruption of the repair [11].

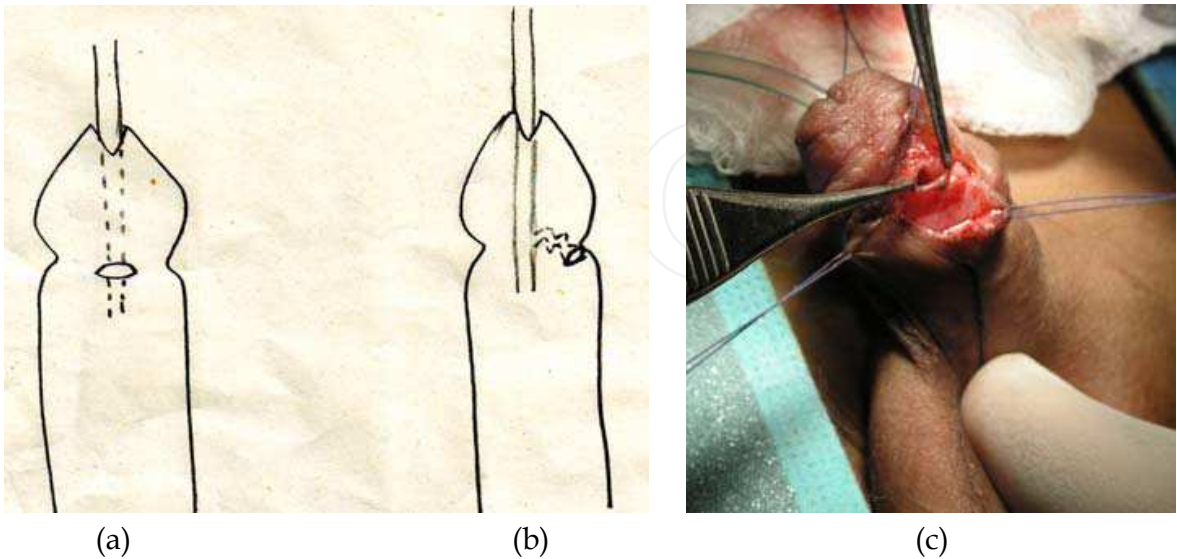


Fig. 1. Description of some types of fistula according to fistula track path: A) Graph of direct ventral fistula, B) Graph of serpentine long lateral fistula and C) Operative photograph of direct post anastomotic fistula. [Courtesy of Prof. Sherif Shehata]

3. According to its track path into:

- Direct
- Serpentine

Direct fistula where the tract pass straight in the same level of all repaired layers while serpentine fistula where the tract run in different pathway among the different layers and usually came lateral in position not in the mid line.

4. According to number into:

- Single
- Multiple

Single fistula are more common and may be presented in different size while the Multiple fistulae are less common; they may occur due to technical factors such as ischemia, infection and distal stenosis or in recurrent cases [11].

4. Mechanism of fistula formation

Infection and ischemia remain the two important factors in fistula production. Incorporation of urethral mucosa in the ventral repair is a substrate for fistula formation with rapid migration of urethral mucosa and skin epithelium into suture tracts. Whether the mucosal or dermal migration along suture tracts can be attenuated or prevented by changing the biochemical environment needs further investigation [7]. Some individuals have abnormal tissue reactivity to the sutures as foreign bodies, thus induce irritation and inflammatory reaction that initiates fistula formation [34].

5. Etiology and risk factors

The actual causes of fistulae formation remain unknown although the most common reasons are technical and avoidable; there are many factors that may cause a high incidence of fistula formation which include:

1. Local infection,
2. Local ischemia,
3. An inadequate procedure,
4. Poor tissue healing, and
5. Distal obstruction due to meatal stenosis/encrustation [24, 34].
6. The type of suture material.

The fistula formation rate was significantly higher in the group of patients where neourethra was constructed using 6/0 polyglactine (Vicryl) in a single layer, full-thickness, uninterrupted fashion (16.6 %) compared to group of patients in which 7/0 polydioxanone (PDS) was used in the urethral anastomosis performed in a subcuticular, uninterrupted fashion with fistula rate of 4.9 % [23, 24]. Use of a subcutaneous suture technique utilizing PDS suture material in urethroplasties is advocated [23, 24].

6. Tips for fistula prevention

The numerous factors that have accounted to lower incidence of fistula formation today are summarized below:

1. Technical points
 - Type of suture
 - Fine instruments

- Magnification
- 2. Protective intermediate layer
 - De-epithelialized skin
 - Tunica vaginalis
 - Dartos flap
 - Dorsal subcutaneous preputial flap
 - External spermatic fascia
- 3. Urethral stenting
- 4. Dressing
- 5. Tisseel (fibrin glue) [15]

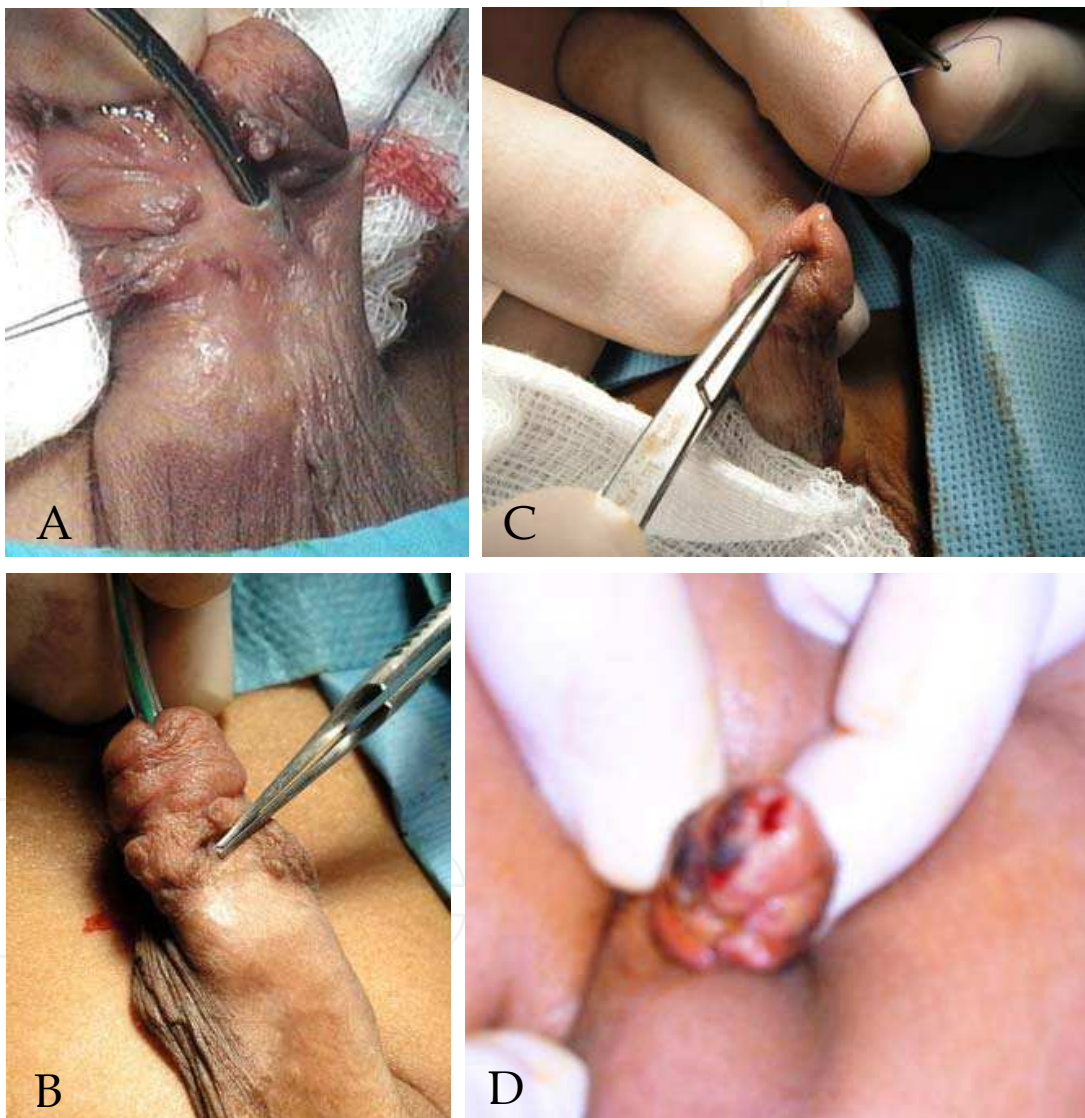


Fig. 2. Shape and Causes of post hypospadias fistulae: A) Preoperative photograph shows disrupted proximal hypospadias with multiple fistulae with operative calibration, B) Operative photograph of a case of direct coronal fistula, C) Photograph of the a case of meatal stenosis as a contributing factor to fistula development and D) Postoperative photograph of another case of distal hypospadias with early infection that predispose to fistula formation later. [Courtesy of Prof. Sherif Shehata]

6.1 Technical points

Better and finer suture materials are available today with greater tensile strength and less reactivity including 6-0 to 7-0 polyglactin (Vicryl) and polyglycolic acid (Dexon). These sutures can be used on the skin as well as internally. PDS should not be used in the urethra (subcuticular is satisfactory) because it may react with urine and fistula may result [9, 23]. Plastic surgical principles such as ophthalmic and microvascular instruments are advocated and delicate tissue handling are now should be used by most hypospadias surgeons. Also most surgeons use either the microscope or 2.5 - 3.5 X optical magnification [9, 30].

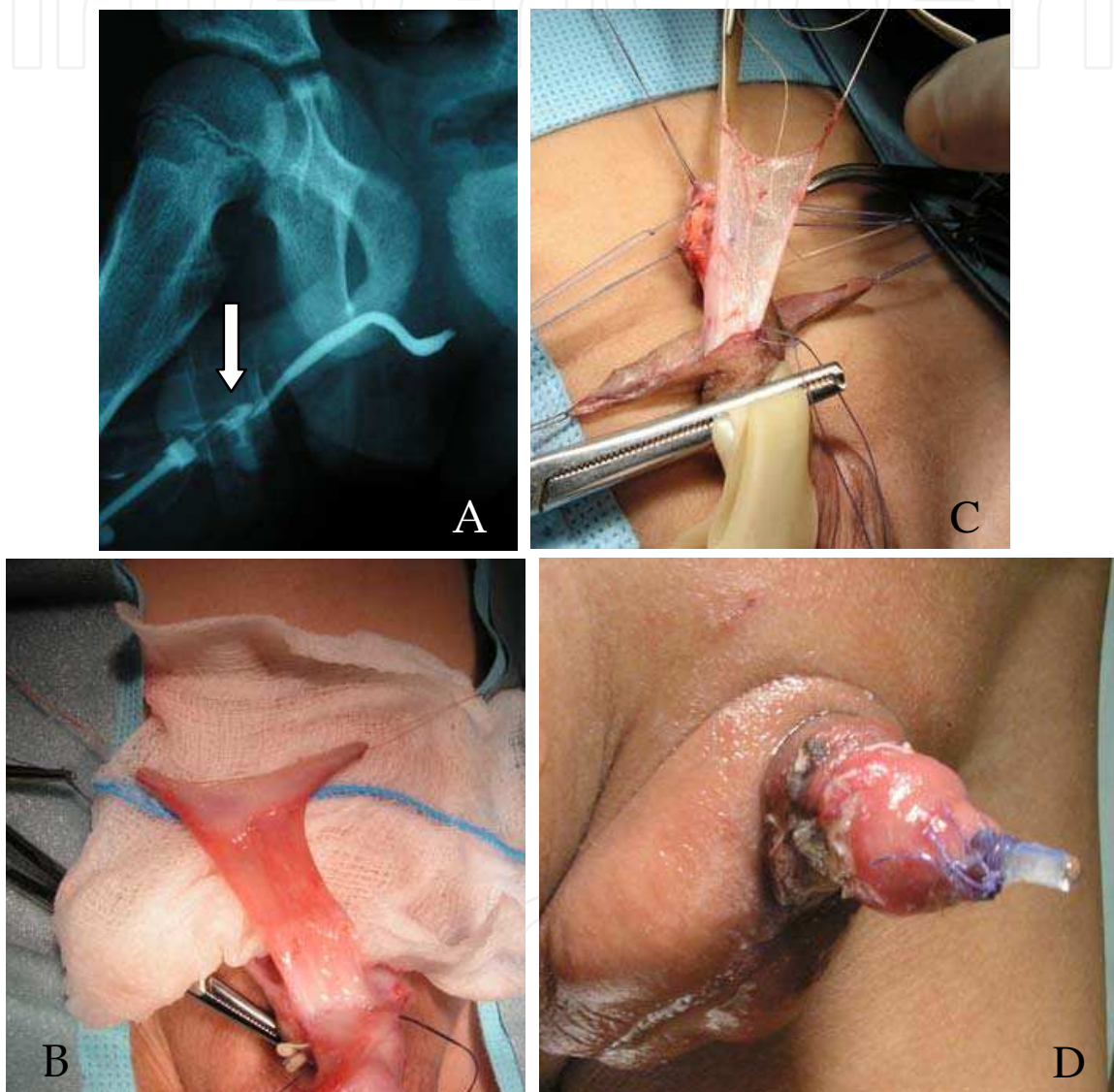


Fig. 3. Tips to minimize fistula development or recurrence: A) Preoperative contrast imaging photograph showing urethral stenosis (white arrow) and fistula after distal hypospadias repair, B) Operative photograph of the same case showing the prepared Retik's dorsal - subcutaneous preputial flap from the foreskin dorsal as a second protective layer with part of fore skin attached at tip of flap, C) Operative photograph of another case showing the dorsal dartos fascia flap prepared as a second covering layer for the urethroplasty and D) Operative photograph of a case showing the urethral stent at the time of recovery. [Courtesy of Prof. Sherif Shehata]

6.2 Protective intermediate layer

Multiple layer closure has a major role in lowering the incidence of fistula formation. The introduction of a protective intermediate layer is the most important single factor in reducing the incidence of fistula and other complications of hypospadias repair. One or more layers was essential as a protective intermediate layer between the neo urethra and the skin layer.

Types of protective intermediate layer including the following as summarized below:

- Buck's fascia,
- Smith's de-epithelialised skin,
- Snow's tunica vaginalis wrap from the testicular coverings,
- Retik's dorsal - subcutaneous preputial flap from the foreskin,
- Motiwala's dartos flap from the scrotum
- Dorsal dartos fascia flap, and
- The external spermatic fascia flap [16, 30].

Nowadays the use of spongioplasty is important to be added as an intermediate layer and is helpful to protect the urethroplasty. Another point is the two layers closure of the glans as additional support as proved statistically in hypospadias surgery whether primary or complicated case [33].

6.3 Urethral stenting

In a prospective comparative study in Cairo University, the role of stenting and catheterization has been evaluated. The study included 100 patients divided randomly into a silicone stent group and a no stenting group. Although the difference was not statistically significant, the incidence of complications and fistula formation was higher in the stented group [13, 16]. However, if the surgeon prefers to use catheters or stents, non-reactive silicone stents or catheters are better employed. A stent or catheter one size smaller than the urethra should be selected to permit voiding around the tube should it become plugged or should bladder spasms occur. Urethral stent is superior to catheterization in post operative period regarding the surgical outcome [13, 33, 34].

6.4 Dressing

Another major factor is the use of different types of dressings. In a comparative prospective study in Cairo University, the role of dressing has been evaluated. The study concluded that dressings in general statistically increase the incidence of complications and fistula formation in hypospadias repair [14, 33]. Our experiences with others advocate the non wetting or even dryness of wound by no dressing [13, 14, 22]. Other authors showed that dressings should be omitted from routine use after hypospadias repair [13, 14, 22, 40]. For those surgeons who still prefer to use dressings, modern hypospadias dressings with materials such as Duoderm or silicone foam have also aided in reducing the incidence of fistula [15].

6.5 Tisseel

A fibrin glue preparation is used to augment hypospadias repairs in children. When this adjunct was used, the fistula rate was lowered to 9% versus 28% as reported [28, 29]. Use of fibrin sealant reduces the overall complication rate in hypospadias repair [1, 22]. Recently, the use of butyl cyanoacrylate tissue glue for post hypospadias repair dressing is of many

advantages including dry sealant, transparent and protective water proof as a coated film cheaper sealant dressing from our current experience [1, Shehata, submitted].

7. Management of fistula

Every case of fistula especially if recurrent should be investigated thoroughly prior to surgery either to define possible associated anomalies or causes of recurrence such as presence of a urethral diverticulum or distal urethral stricture, as it may lead to recurrence of the fistula. The distal urethra must be examined for evidence of obstruction by cystoscopy, retrograde urethrography, ascending urethrography or urethral calibration. Intra operative calibration is of paramount importance especially with failure of tube passage. Meticulous penile examination is mandatory to assess the status of local tissue and design the management plan. Any obstruction found has to be corrected simultaneously with the fistula repair [8, 15].

Timing of the repair of post hypospadias fistula remains one of the most important issues in the outcome of repair. Once a fistula has formed, there may be inflammation and urine extravasation and urethral tissues quickly become edematous and friable. There is little point in attempting to close a newly formed fistula by means of secondary sutures, and in fact further inflammation will result in a larger fistulous opening [15, 26]. Once a fistula has formed, it is recommended that no surgical repair be considered for 6-12 months. Evermore, should all remnants of suture materials disappeared before any attempt for repair. This is the minimum time required for complete wound healing and to allow for full resolution of scar tissue. When we encountered with a recurrent fistula, the waiting time should be a minimum of one year lapse from the former repair. In some recurrent or mega fistulae the two - stage repair is advocated [35].

The classic management consist of small fistula which may heal spontaneously within 10 - 21 days of urinary diversion, with appropriate antibiotics until tissue induration and inflammation disappears when there is no meatal stenosis. Spontaneous closure of fistula has been reported in up to 30% cases. During this time, meatus can be dilated with an ophthalmic ointment tube tip to ensure an adequate meatal caliber. Dilation protocol is helpful in pin point cases of fistula provided that there is no distal or meatal stenosis [17, 20]. However, some hypospadias surgeons deny the importance of catheter as it is possible that fistulas which heal in this way would have healed in any case, without a catheter which may cause irritation that diminishes the chances of spontaneous healing [17, 28].

8. Surgical treatment

As common in hypospadias surgery, there are no perfect surgical techniques for repairing urethrocuteaneous fistulae. Many variable factors could influence the surgical management and outcome of urethrocuteaneous fistula repair as the time of occurrence after urethroplasty, the location (glanular, coronal, mid-shaft, etc.), size (pin-point, large), the number and the condition of local tissue [26].

During the last decade many principles of an ideal repair of fistulae have been clarified. We use the same principles that apply exactly to hypospadias repair in fistula closure and/or repair. Delicate tissue handling, delicate instruments, healthy tissue should be incorporated, a multilayer repair with well-vascularized tissues, avoiding overlapping sutures and non absorbable or thick suture materials, a tension-free closure, use of optical magnification and

needle-point cautery or bipolar cautery for coagulation are currently considered mandatory [28]. A pivotal factor is the operating surgeon that should have a fast experience in the field of hypospadiology not the surgeon who operate occasionally such cases [Warren Snodgrass, Personal Communication].

Before attempting any surgical repair of a fistula, it is important to identify the presence of a urethral diverticulum or distal urethral stricture, so the intra operative calibration of the distal urethra and distension of the repaired hypospadias to search for a diverticulum with meticulous penile examination is mandatory to assess the status of local tissues and design the management plan. Any obstruction found has to be corrected simultaneously with the fistula repair [28].

The next step is to identify the location of the fistula and to exclude any further fistulas by retrograde injection of a diluted povidone-iodine solution or methylene blue dye in to the meatus while the bulbous urethra is being compressed to prevent instillation into the bladder [13, 28].

Generally, the repair of post hypospadias fistulae depends on the size and location of the fistula. However there are many golden principles of the fistula repair which must be followed as the debridement, dissection of the fistula; elaborate excision of the fistulous tract – including the fistula cornu- down to healthy thin urethral tissue, closing by inverting suture, and protective layer closure with lastly coverage using small skin flap [8].

Many techniques advocated included; the trap door technique, simple closure, envelop like closure, using of any of the hypospadias repair techniques like TIP principle or Koff's urethral mobilization in special indications. No single technique is ideal, so the hypospadiologist should tailor the technique according to each case individually. The main two bases are tension free urethral closure and multi layer closure for protection. Also, the former technique employed in hypospadias repair is important with the status of the urethral plate to build up our technique of repair accordingly [34].

Some surgeons advised the use of purse string sutures as a simple method to close fistula which may be of value in small sized fistulae only. Although this principle carries the risk of tension at the edge of the fistula opening also its interrupted sutures; in spite of its simplicity it also had the possibility of impeded urethral epithelium in between the sutures [10].

For a small fistula, simple transverse approximation of healthy urethral tissue is often possible. Subcuticular continuous sutures of 7-0 Vicryl are used to close the urethral edges and had the benefits for preventing the leakage of the urine and passing the urethral epithelium through the sutures. Some surgeons prefer to irrigate the urethra with proximal compression intra operatively to ensure water - tight closure although it is not really necessary [19].

A protective intermediate layer plays an important part in avoiding recurrence as described before since many types of protective intermediate layer are available including; Buck's fascia, Smith's de-epithelialized skin, Snow's tunica vaginalis wrap from the testicular coverings, Retik's dorsal - subcutaneous flap from the foreskin, Motiwala's dartos flap from the scrotum, and the external spermatic fascia flap [16]. Even, the use of urethral mobilization without any suture line for distal fistulae is advocated to resolve the problem of distal fistula [17, 20, 28].

Many of the techniques used in primary repair of hypospadias are exactly used in the repair of post hypospadias urethral fistula especially if multiple or mega fistulae. In the large fistulae, the temptation to simply close the fistula is dangerous, as recurrent fistulae are quite common. Mega fistula should be managed as disrupted case of repair. Often it is advisable to repeat the whole urethroplasty [7, 34, 35].

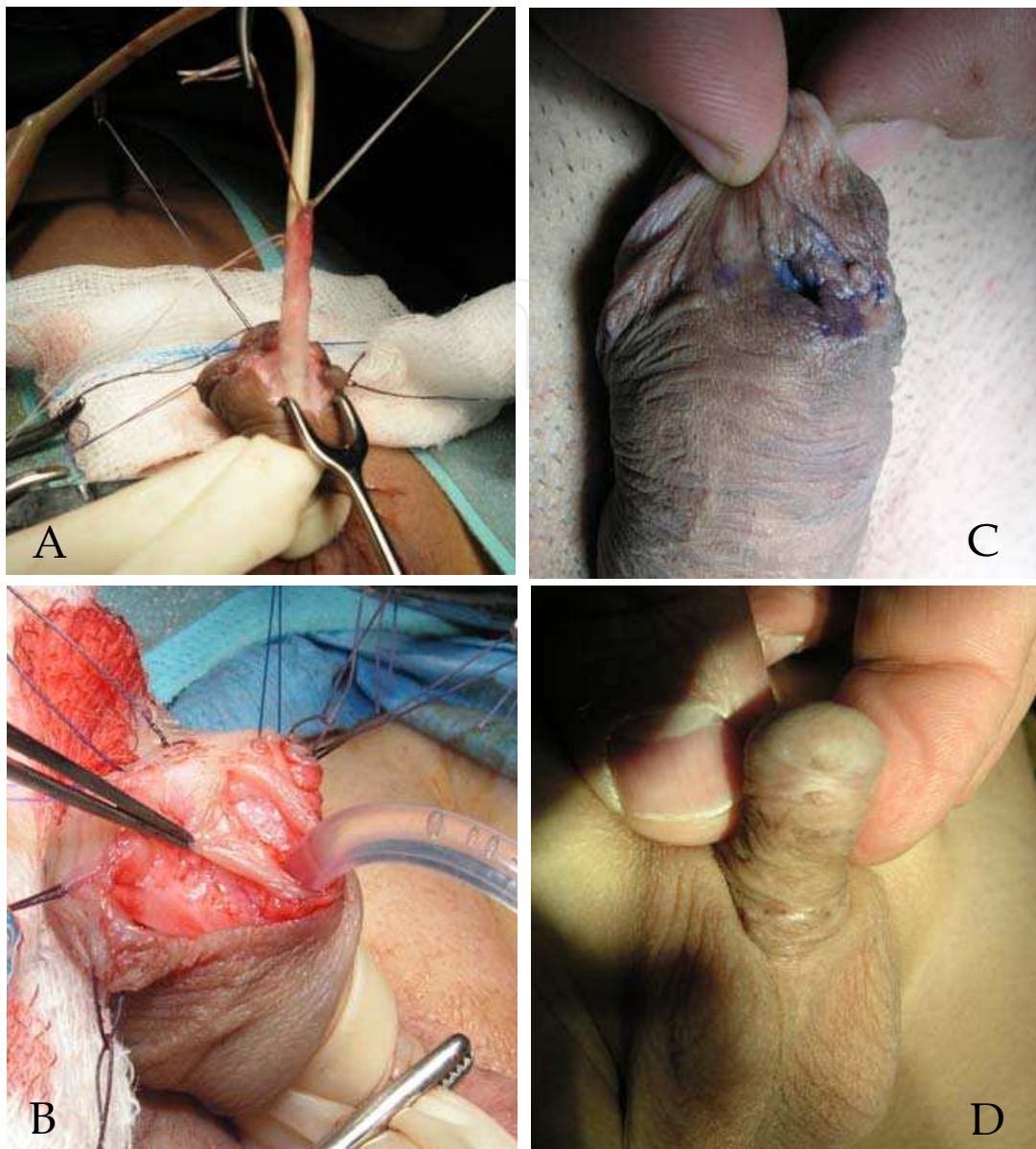


Fig. 4. Identification and techniques of fistula repair: A) Operative photograph of a case of coronal fistula treated by Koff's urethral mobilization, B) Operative photograph of a coronal fistula case converted into coronal type of hypospadias and repaired by TIP procedure, C) Preoperative photo of a coronal mega fistula with methylene blue come out of the fistula, and D) Post operative photo of small coronal fistula with skin bridge. [Courtesy of Prof. Sherif Shehata]

Most surgeons preferred converting large coronal fistulae developed after hypospadias repair, followed by tabularization of the urethral plate with or without a dorsal midline relaxing incision [2, 26, 35]. The Thiersch tube repair with or without the relaxing urethral plate incision, as described by Reddy [25], Rich et al [27] and Snodgrass [38] had a success rate of 92%. Secrest et al [31], reported on the successful urethrocutaneous fistula repair in 53 (91.4%) of the total 58 patients after hypospadias repair with converting the fistula in the primary hypospadias repair. We recently reported success rate of mega fistula by TIP principle of nearly 90 % [35].

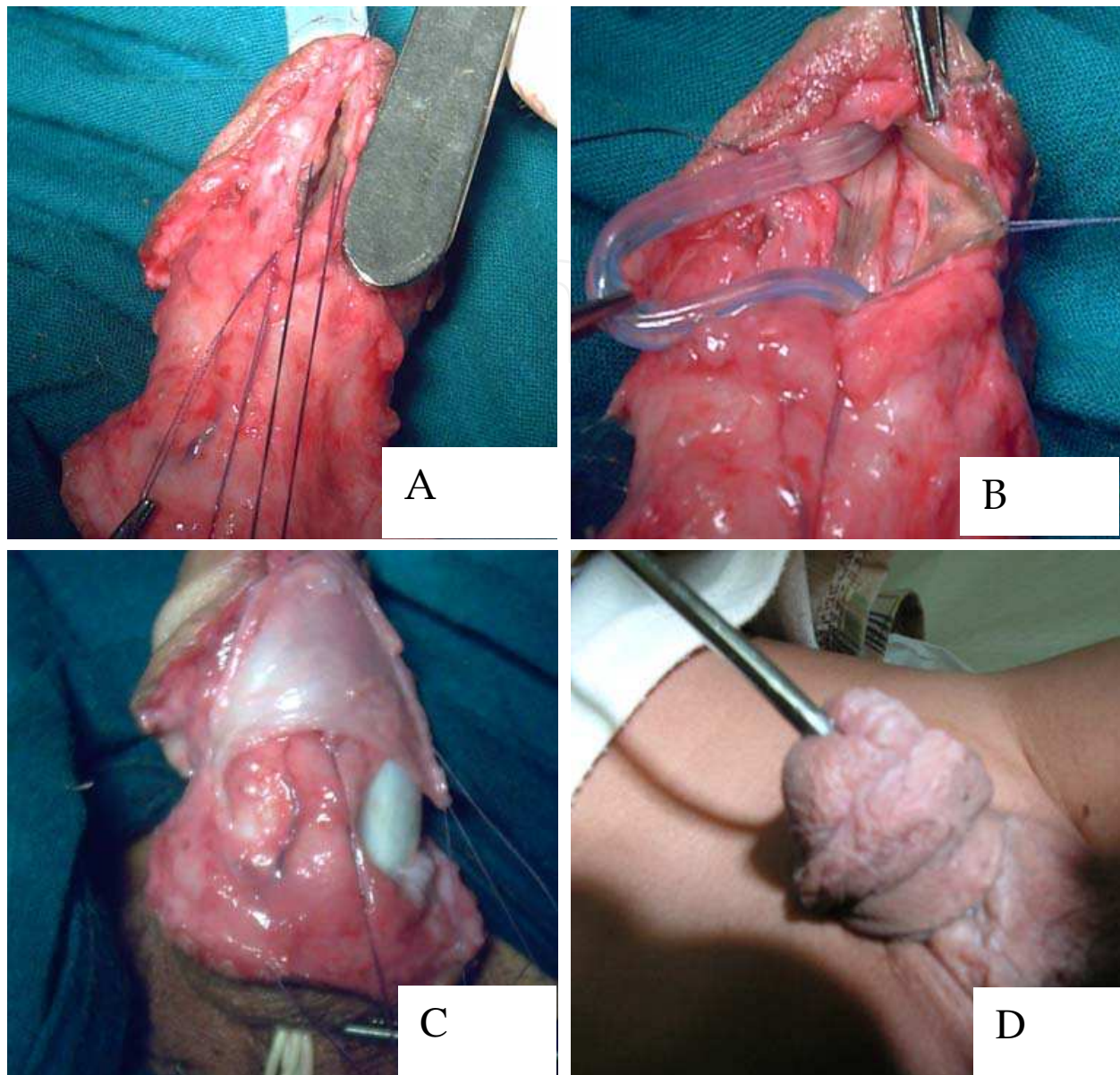


Fig. 5. Mega fistula repair by TIP principle: A) Operative photograph of penile mega fistula as compared to scalpel hand, B) Operative photograph of the same case after excision of fistula cornu and edge of healthy tissue with dorsal slit employing TIP principle, C) Operative photograph of the same case after fashioning lateral Buck's fascia protective layer and D) Post operative photograph of the same case after 3 months at calibration with complete healing. [Courtesy of Prof. Sherif Shehata]

A fistula near the glans with thin skin distally can be repaired by connecting the skin between the meatus and the fistula. The defect then is closed using the Mathieu technique to cover over the new subglanular meatus. In this technique, either a ventral or an oblique or lateral strip of skin can be used to cover over the meatus as in the classic Mathieu procedure [32].

Sometimes, the fistulous tract goes a long way before opening into the skin and there may be multiple tiny tracts that are not seen except during dissection. So it is very important to dissect and separate widely between the urethra and the overlying. Among these

techniques, the most common maneuver is to place some intervening layer of tissue between neo-urethra and the skin [4]. For multiple fistulae, a single-stage procedure is still a valid option. Two-stage procedures may be reserved for recurrent fistula where there is a deficiency of adequate healthy local tissue. In cases of serpentine, tortuous or long fistulae, it is advisable to make endoscopic treatment either by laser coagulation and fibrin glue as dissection between layers can destroy the original repair in cases of minute fistulae [16, 31]. Suture tracks (or sinuses) occur when epithelium grows along skin sutures before they dissolve or are removed postoperatively. These sinuses subsequently fill with desquamated keratin, producing unsightly marks. The likelihood that wound closure will leave suture tracks depends upon a variety of factors, including the size and composition of suture materials [39].

Recently, some surgeons have recommended the use of cyanoacrylate for repair of early fistula after hypospadias surgery and found effective. However the results are lacking the evidence yet. Endoscopic procedures even tried in some occasions [20].

Fistulae may recur because of technical errors. Contributing factors include inadequate layers of closure, ischemic tissue, and overlapping suture lines. Infection, tension such as is created by edema or hemorrhage, pressure of dressings and occlusion of catheters with urinary extravasation all contribute to fistula recurrence that should be prevented and revised step by step during repair [28]. Hence despite that some literature reports did not advocate the use of stents, our experience collected over 25 years in hypospadias field recommend the use of urethral stents for a minimum of 48 hours in distal cases following repair and suprapubic vesicostomy diversion in proximal cases.

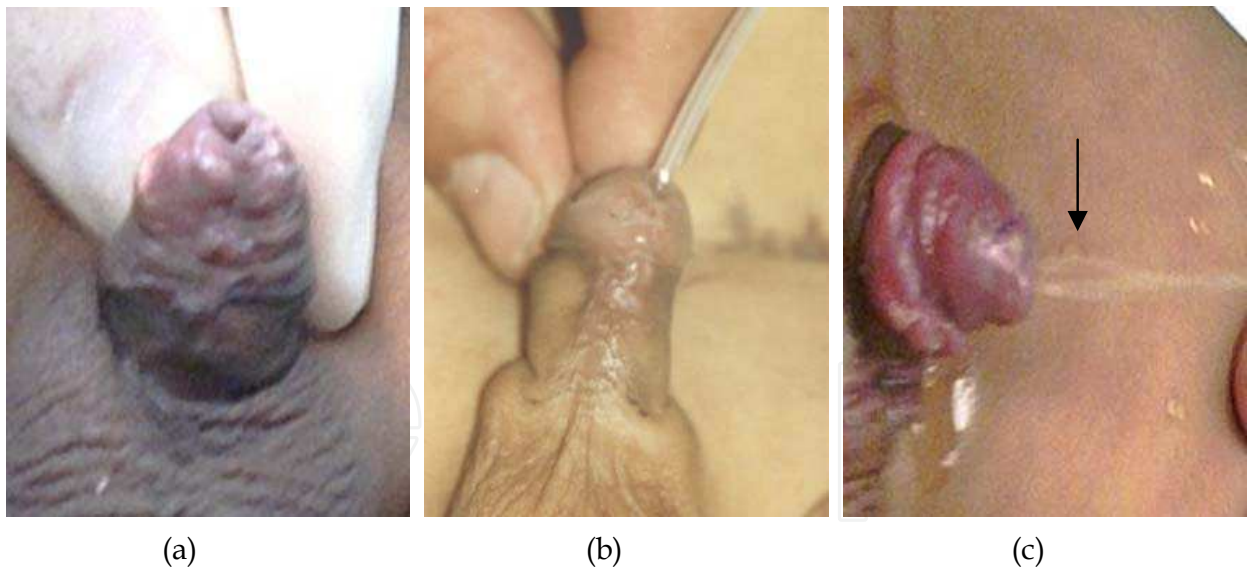


Fig. 6. Post operative results of fistula repair: A) Post operative photograph of a case after successful coronal fistula closure, B) Post operative photograph of another case after successful fistula closure at time of calibration, and C) Photograph of a third case at 3rd month post operative visit showing urine voiding in vertical stream (notice the black arrow) at tip of conical glans indicating the excellent result. [Courtesy of Prof. Sherif Shehata]

In conclusion, post hypospadias fistula repair need understanding of the theoretical basis and natural history of its development, technical expertise and considering the preventive

measures prior to its actual development plus the honest clarification of the condition to parents and patient to participate actively in the management plan are crucial to optimize the outcome and quality of life of the affected patients.

9. References


- [1] Ambriz-González, G., Velázquez-Ramírez, GA., García-González, JL., de León-Gómez, JM., Muciño-Hernández, MI., & González-Ojeda, A (2007). Use of fibrin sealant in hypospadias surgical repair reduces the frequency of postoperative complications. *Urol Int*, 78, 37- 41
- [2] Awad, MS (2006). Urethral advancement technique for repair of distal penile hypospadias: A revisit. *Indian J Plast Surg*, 39, 34-38
- [3] Barbagli, G., Palminteri, E., & Lazzeri, M (2001). Long-term outcome of urethroplasty after failed urethrotomy versus primary repair. *J Urol*, 165, 1918-1919
- [4] Djordjevic, ML., Perovic, SV., & Vukadinovic, VM (2005). Dorsal dartos flap for preventing fistula in the Snodgrass hypospadias repair. *BJU Int*, 95, 1303-1309
- [5] Dodson, L., Baird, D., Baker, L., Docimo, S., & Mathews, I (2007). Outcomes of delayed hypospadias repair: Implications for decision making. *Urology*, 11, 178, 278-281
- [6] Dubois, R., Pelizzo, G., Nasser, H., Valmalle, A., & Dodat, H (1998). Urethral fistulas after surgical treatment of hypospadias: A propose of a series of 74 cases. *Prog Uro*, 8, 1029-1034
- [7] Edney, MT., Lopes, JF., Schned, A., Ellsworth, PI., & Cendron, M (2004). Time course and histology of urethrocutaneous fistula formation in a porcine model of urethral healing. *Eur Urol*, 45, 806-810
- [8] ElBakry, A (2001). Management of urethrocutaneous fistula after hypospadias repair: 10 years' experience. *B J U Int*, 88, 590-595
- [9] El-Mahrouky, A., McElhaney, I., & Bartone, FF (1987). In vitro comparison of the properties of polydioxanone, polyglycolic acid and catgut sutures in sterile and infected urine. *J Uro*, 138, 913-915
- [10] Fatah, MF (1982). A method of closing urethral fistulae using a purse-string or interrupted silk sutures. *Br J Plast Surg*, 35, 102-103
- [11] Gardikis, S., Solutanidis, C., Deftereos, S., Kambouri, K., Limas, C., & Vaos, G (2004). Suprapubic catheter knotting: An unusual complication. *Int Urol Nephrol*, 36, 537-539
- [12] Greenfield, SP., Sadler, PT., & Wan, J (1994). Two stage repair for severe hypospadias. *J Uro*, 152, 498-501
- [13] Hadidi, A., Abdaal, N., & Kaddah, S (2003). Hypospadias repair: is stenting important? *Kasr El Ainy J Surg*, 4, 2, 3-8
- [14] Hadidi, A., Abdaal, N., & Kaddah, S (2003). Hypospadias repair: is dressing important? *Kasr El Ainy J Surg*, 4.1, 37-44.
- [15] Hadidi, AT (2004). Complications and Late Sequelae, in: *Hypospadias Surgery An Illustrated Guide*. Ahmed T. Hadidi and Amir F.Azmy, 23: 273-283, Springer-Verlag, Berlin Heidelberg, New York

- [16] Hadidi, AT., & Azmy, AF (2004). Editorial Overview of the Current Management of Hypospadias, In: *Hypospadias Surgery An Illustrated Guide*. Ahmed T. Hadidi and Amir F. Azmy, 35: 339-341, Springer-Verlag, Berlin, Heidelberg, New York
- [17] Hayashi, Y., Mogami, M., & Kojima, Y (1998). Results of closure of urethrocuteaneous fistulas after hypospadias repair. *Int J Urol*,5, 167-169
- [18] Horton, C E., & Devine, C J. (1973). Urethral fistula, In: *Plastic and reconstructive surgery of the genital area*. Horton CE, 397- 403, Little & Brown Co, 12567, Boston
- [19] Khan, U., Zic, R., & Boorman, J (2001). Water-proofing in hypospadias: A refinement of the two-stage reconstruction. *Br J Plast Surg*,54, 528-531
- [20] LaPointe, SP., N-Fékété, C., & Lortat-Jacob, S (2002). Early closure of fistula after hypospadias surgery using N-butyl cyanoacrylate: Preliminary results. *J Urol*,168, 1751-1753
- [21] Latifoglu, O., Yavuzer, R., Unal, S., Cavuonlu, T., & Atabay, K (2000). Surgical treatment of urethral fistulas following hypospadias repair. *Ann Plast Surg*,7, 44, 381- 386
- [22] McLorie, G., Joyner, B., & Herz, D (2001). A prospective randomized clinical trial to evaluate methods of postoperative care of hypospadias. *J Urol*, 2, 165, 1669- 1672
- [23] Mouriquand, PD., & Mure, PY(2004). Current concepts in hypospadiology. *B J U Int*, 93, 26, 120 -131
- [24] Ratan, SK., Sen, A., Pandey, RM., Hans, C., Roychaudhary, S., & Ratan J (2001). Lesser evaluated determinants of fistula formation in children with hypospadias. *Int J Clin Pract* ,55, 96-99
- [25] Reddy, LN (1975). One-stage repair of hypospadias. *Urology*,5, 475-478
- [26] Retik, AB., Keating, M., & Mandell, J (1988). Complications of hypospadias repair. *Urol Clin North Am*,15, 223-236
- [27] Rich, MA., Keating, MA., Snyder, HM., & Duckett, JW (1989). Hinging the urethral plate in hypospadias meatoplasty. *J Urol*,142, 1551-1553
- [28] Richter, F., Pinto, PA., Stock, JA., & Hanna, MK (2003). Management of recurrent urethral fistulas after hypospadias repair. *Urology*, 61, 448-451
- [29] Rickwood, A., & Fearn, C (1997). Pedicled penile skin for hypospadias 'rescue'. *Br J Urol*, 8, 80, 145-146
- [30] Saleh M., Mohamed, N., Esmael, T., & Khaled, S (2010). A simple procedure for management of urethrocuteaneous fistulas; post-hypospadias repair. *Afr J Paediatr Surg*,7, 124-128
- [31] Secrest CL, Jordan GH, Winslow BH, Horton CE, McCraw JB, & Gilbert DA (1993). Repair of the complications of hypospadias surgery. *J Urol*, 150: 1415-1418
- [32] Shapiro, SR (1984). Complications of hypospadias repair. *J Uro*, 11, 131, 5-18
- [33] Shehata, SMK, El-Heindey MH, & El-Bahnasy AM (2006). Glanular closure during the tubularized incised plate procedure: A prospective randomized study. *Ann Pediatr Surg*, 2, 1, 39-44
- [34] Shehata, SMK, Elian AA, Soliman SM, & Hassan HS (2007). Re-Operative mid penile hypospadias repair: Experience in 34 cases. *Ann Pediatr Surg*, 3, 3, 156-163
- [35] Shehata, SMK (2009). Use of TIP principle for the repair of non-glanular recurrent post hypospadias urethrocuteaneous mega fistula. *Eur J Ped Surg*, 19 (6), 395-398
- [36] Smith, ED (1990). Hypospadias, In: *Ashcraft Pediatric Urology*. Ashcraft K, 353-395, Saunders, Philadelphia.

- [37] Smith, ED (1981). Durham Smith repair of hypospadias. *Urol Clin North Am*, 8, 451-455
- [38] Snodgrass, W (1994). Tubularized incised plate urethroplasty for distal hypospadias. *J Urol*, 151, 464-465
- [39] Snodgrass W (1999). Suture tracts after hypospadias surgery. *BJU Int*. 84: 843-847
- [40] Van Savage, JG., Palanca, LG., & Slaughenhaupt, BL (2000). A prospective randomized trial of dressings versus no dressings for hypospadias repair. *J Urol*, 164, 981- 983

IntechOpen

IntechOpen



Current Concepts of Urethroplasty

Edited by Dr Ivo Donkov

ISBN 978-953-307-392-7

Hard cover, 152 pages

Publisher InTech

Published online 19, July, 2011

Published in print edition July, 2011

Urethral reconstructive surgery has always been a challenging part for urologist since the dawn of our speciality. In this book leading experts in lower urinary reconstructions from all over the world present their views and experience in that field, together with practical tips and tricks. The book is an excellent source of information for those who are already dealing with urethral surgery, and also an invaluable companion for urologists in training or those who want to dedicate themselves to this great sub-specialty. This book is an excellent reference guide and companion on the way to operating and consulting room, or when writing an article and reviewing the current practices. The abundance of methods and continuing development of new approaches to the problem prove the complexity of it.

How to reference

In order to correctly reference this scholarly work, feel free to copy and paste the following:

Sherif Shehata and Mohamed Hashish (2011). Management of Post Hypospadias Urethral Fistula, Current Concepts of Urethroplasty, Dr Ivo Donkov (Ed.), ISBN: 978-953-307-392-7, InTech, Available from: <http://www.intechopen.com/books/current-concepts-of-urethroplasty/management-of-post-hypospadias-urethral-fistula>

INTECH
open science | open minds

InTech Europe

University Campus STeP Ri
Slavka Krautzeka 83/A
51000 Rijeka, Croatia
Phone: +385 (51) 770 447
Fax: +385 (51) 686 166
www.intechopen.com

InTech China

Unit 405, Office Block, Hotel Equatorial Shanghai
No.65, Yan An Road (West), Shanghai, 200040, China
中国上海市延安西路65号上海国际贵都大饭店办公楼405单元
Phone: +86-21-62489820
Fax: +86-21-62489821

© 2011 The Author(s). Licensee IntechOpen. This is an open access article distributed under the terms of the [Creative Commons Attribution 3.0 License](https://creativecommons.org/licenses/by/3.0/), which permits unrestricted use, distribution, and reproduction in any medium, provided the original work is properly cited.

IntechOpen

IntechOpen