

# We are IntechOpen, the world's leading publisher of Open Access books Built by scientists, for scientists

6,900

Open access books available

185,000

International authors and editors

200M

Downloads

Our authors are among the

154

Countries delivered to

TOP 1%

most cited scientists

12.2%

Contributors from top 500 universities



WEB OF SCIENCE™

Selection of our books indexed in the Book Citation Index  
in Web of Science™ Core Collection (BKCI)

Interested in publishing with us?  
Contact [book.department@intechopen.com](mailto:book.department@intechopen.com)

Numbers displayed above are based on latest data collected.  
For more information visit [www.intechopen.com](http://www.intechopen.com)



# Urethroplasty; Wide Range of Therapeutic Indications and Surgical Techniques

Mahmoud Mustafa<sup>1</sup>, Dina Abugaber<sup>2</sup>, Sacit Nurigorgel<sup>3</sup>,  
Ertugrul Sefik<sup>3</sup>, Ozan Horsanali<sup>3</sup> and Wael Sadaqah<sup>2</sup>

<sup>1</sup>*An-Najah University, School of Medicine, Urology Department, Nablus-West-Bank,*

<sup>2</sup>*Rafidia State Hospital, Intensive Care Unit, Nablus-West-Bank,*

<sup>3</sup>*Izmir Ataturk Teaching Hospital, Urology Department, Izmir*

<sup>1,2</sup>*Palestine*

<sup>3</sup>*Turkey*

## 1. Introduction

Urethroplasty means plastic surgery of the urethra. Herein we are going to describe urethroplasty in terms of; diagnosis, indications, surgical techniques and definition of failure or success. A lot of issues related to urethroplasty remain to be defined, therefore we will clarify the debatable issues and highlight the last advances on urethroplasty.

There are two main causes which mandate urethroplasty; the first is the congenital anomalies with hypospadias being the most common, and the acquired anomalies with urethral stricture being the most common of them. Hypospadias is found commonly in newborn boys and it seen in approximately 8.2 per 1000 births. The goal of hypospadias reconstruction are to bring the meatus close to glans to allow the child to void standing, removing the chordee to allow for normal sexual intercourse and giving the phallus appearance of a normally circumcised penis when observed from distance. There are more than 200 named surgical procedure to correct hypospadias. Now a days tubularized incised plate (TIP) urethroplasty described by Snodgrass in 1994 is the most common procedure used for repair of hypospadias. The advantages of this technique include its simplicity, high success rate, low rate of complication and excellent cosmetic results. A lot of modifications were introduced on the TIP urethroplasty aiming to improve the success rate and to decrease fistula formation. We were from the firsts who published such modification regarding the use of double- layer dartos flap covering for urethra instead of the classic way of utilizing dorsal dartos flap (button hole maneuver).

The second cause of urethroplasty is the acquired anomalies. Strictures of urethra is of much clinical important than hypospadias, because it bothers the patients more, unfortunately the results of surgery is not promising as that of hypospadias. The term "urethral stricture" refer to anterior urethral disease or scaring process involving the spongy erectile tissue of the corpus spongiosum (spongiofibrosis). According to World Health Organization posterior urethral stricture are not included in the common definition of urethral stricture

and the term stricture is limited to the anterior urethra. Urethral disruption injuries typically occur in conjunction with multisystem trauma from vehicular accident, falls, or industrial accident. Because the posterior urethra is fixed at both the urogenital diaphragm and the puboprostatic ligaments, the bulbomembranous junction is more vulnerable to injury during pelvic fractures. When the fracture occurs the two separated ends fill with scar tissue, resulting in a complete lack of urethral continuity. The location of urethral strictures was classified as penile (including navicularis fossa), bulbar or posterior (excluding bladder neck contractures). While posterior urethral strictures were commonly caused by traumatic disruption distinctly different from etiology compared to that of anterior strictures disease, recurrence was monitored with the same procedure used for surveillance of anterior urethral reconstruction.

The Urethral disruption is heralded by the triad of blood at the meatus, inability to urinate, and palpably full bladder. When blood at the urethral meatus is discovered, an immediate retrograde urethrogram should be performed to rule out urethral injury. When urethral stricture is diagnosed immediate suprapubic tube placement remains the standard of care.

While the diagnosis of hypospadias needs no radiologic tests, diagnosis of urethral stricture is a matter of discussion. The most common primary diagnostic tests are uroflowmetry (56%), urethrography (51%) and cystourethroscopy (21%). Definition of recurrence of stricture or failure of surgery is also a questionable issue. In 75% of papers regarding urethroplasty, recurrence was defined as the need for additional surgical procedure and in 52% as the need for additional urethral dilation.

The treatment of urethral strictures is divided in two groups; endoscopic and open surgery. The endoscopic treatment such as direct-vision internal urethrotomy are the best reserved for selected short urethral stricture. However when the defects are 1 cm or longer or when a significant corpus spongiositis is present, endoscopic procedure such as cutting through the pelvic scare "cut-to-light" are ineffective. Despite the popularity of this procedure the failure rate after initial urethrotomy is reported to be at least 50%. The failure rate after the second urethrotomy is considered much higher and can be as high as 100%. Therefore there has been continuing discussion about the most appropriate use of urethrotomy, dilation, stenting, and intermittent self dilation. Question have also surfaced about the best technique for urethrotomy. There is no compelling evidence in the literature that any particular form of urethrotomy is more effective than another, whether using a cold knife or laser.

The second treatment option is open surgical reconstruction. There are two kinds of open surgical techniques used for urethroplasty; anastomotic urethroplasty and substitution urethroplasty. Anastomotic urethroplasty involves excision of the strictures and primary anastomosis of urethral ends. Open posterior urethroplasty through a perineal anastomotic approach is the treatment of choice for the most urethral distraction injuries because it definitely cures the patient without the need for multiple procedure. Care must be taken to carefully and meticulously excise all fibrotic tissue from the proximal urethra margin until at least a 28 french bougie passes without resistance. Free tension end to end anastomosis is the procedure of choice when the scar is 1.5-2 cm long and this is highly successful procedure in more than 95% of cases. Urethroplasty remains the gold standard for the management of urethral stricture offering the lowest rate of stricture recurrence and in some circumstance the most cost-effective compared to repeat dilation or endoscopic incision. The limiting factors with anastomotic urethroplasty is the strictures length, in particular the length of component distal to bulbopenile junction. Anastomatic procedure in the bulbar

urethra resulted in a significant impairment of erectile function initially which improved in the majority of cases with a low of long term erectile dysfunction.

The second kind of urethroplasty is substitution urethroplasty. Recent advances in tissue graft sources and the introduction of tissue sealants improve surgical outcomes and minimize patients morbidity by decreasing the number of surgical procedures and the potential disfigurement related to graft site morbidity. Substitution urethroplasty can be performed as a one-stage procedure via an augmented anastomotic procedure, patch substitution (onlay procedure) or a circumferential patch, or two-stage procedure which involves the formation of a roof strip followed by second stage tubularization. It has been shown that the efficacy of both grafts and flaps was identical, but there was a much higher morbidity with penile skin flaps which were also more complex with higher morbidity. The graft which has been used included scrotal skin, oral mucosa, extragenital skin, bladder mucosa, and colonic mucosa. The success rate at average follow-up of 53 months was reported to be 60% for augmented anastomotic repair and 80% for onlay procedure.

In conclusion urethroplasty especially in patients with urethral stricture required the urologist to be aware of the techniques which offer the patient the best success. Therefore different considerations have to be taken into account like length, location, anatomy and etiology of stricture. In comparison to reconstruction of urethral stricture, urethroplasty done due to hypospadias seems to be less complicated with high success rate at long term follow-up.

## 2. Urethral stricture

The bulbous urethra is eccentrically placed in relation to urethra to the corpus spongiosum and much closer to the dorsum of the penile structures. As one moves distally, the pendulous or penile urethra becomes more centrally placed within the corpus spongiosum. Any process that injures the urethral epithelium or the underlining corpus spongiosum to the point that healing results in a scar an anterior urethral stricture. Today, most urethral strictures are the results of trauma (usually straddle trauma). Inflammatory strictures associated with gonorrhea were the most commonly seen in the past and are less common now due to the effective antibiotic treatment. The place of Chlamydia and Ureaplasma urealyticum (non-specific urethritis) in the development of anterior urethral stricture is not clear. To date, no clear association between nonspecific urethritis and the development of anterior urethral stricture has been established. Congenital stricture is used by some to define a stricture for which there is no identifiable cause. We propose, however to define a stricture as congenital only if it is not an inflammatory stricture, it is a short-length stricture and it is not associated with history of or potential for urethral trauma. And it is the rarest encountered. The location of urethral stricture was classified as penile (including navicularis fossa), bulbar or posterior(excluding bladder neck contracture). According to world health organization posterior urethral stricture are not included in the common definition of urethral stricture and the term stricture is limited to the anterior urethra. Posterior urethral stricture commonly caused by traumatic disruption in contrast to that of anterior stricture.

Beside urethral stricture, congenital anomalies of urethra mandate reconstructive surgery for urethra. Hypospadias is the most common of these causes. Although the definite cause of hypospadias is still undefined, the management of these patients is the same regardless to etiologies or kinds of hypospadias. There are many classification systems for hypospadias depending on the location of the meatus; coronal, subcoronal, midshaft and penoscrotal hypospadias. Hypospadias is seen in approximately 8.2 per 1000 birth [1]. There are more



than 200 named surgical procedures for correction of hypospadias with a few common general concept. The aim of hypospadias reconstruction are to achieve an excellent cosmetic result of the penis and to remove chordee to allow for normal sexual intercourse. Tubularized incised plate (TIP) urethroplasty has gained widespread acceptance for repairing hypospadias and has become the therapy of choice for many kinds of hypospadias [2,3,4,5,6]. Tubularized incised urethroplasty was introduced by Snodgrass in 1994, for coronal and subcoronal (distal) cases of hypospadias [3]. Latter on a lot of papers tested the validity of this technique for more complicated hypospadias i.e midshaft and penoscrotal hypospadias and we were from those who claimed such validity [7]. The superiority of TIP urethroplasty technique comes from few key points, midline incision by which the urethral plate is widened to create tension free neourethra, subcutaneous flap which reinforced the neourethra and decrease incidence of fistula (Figure 1 a,b,c,d).

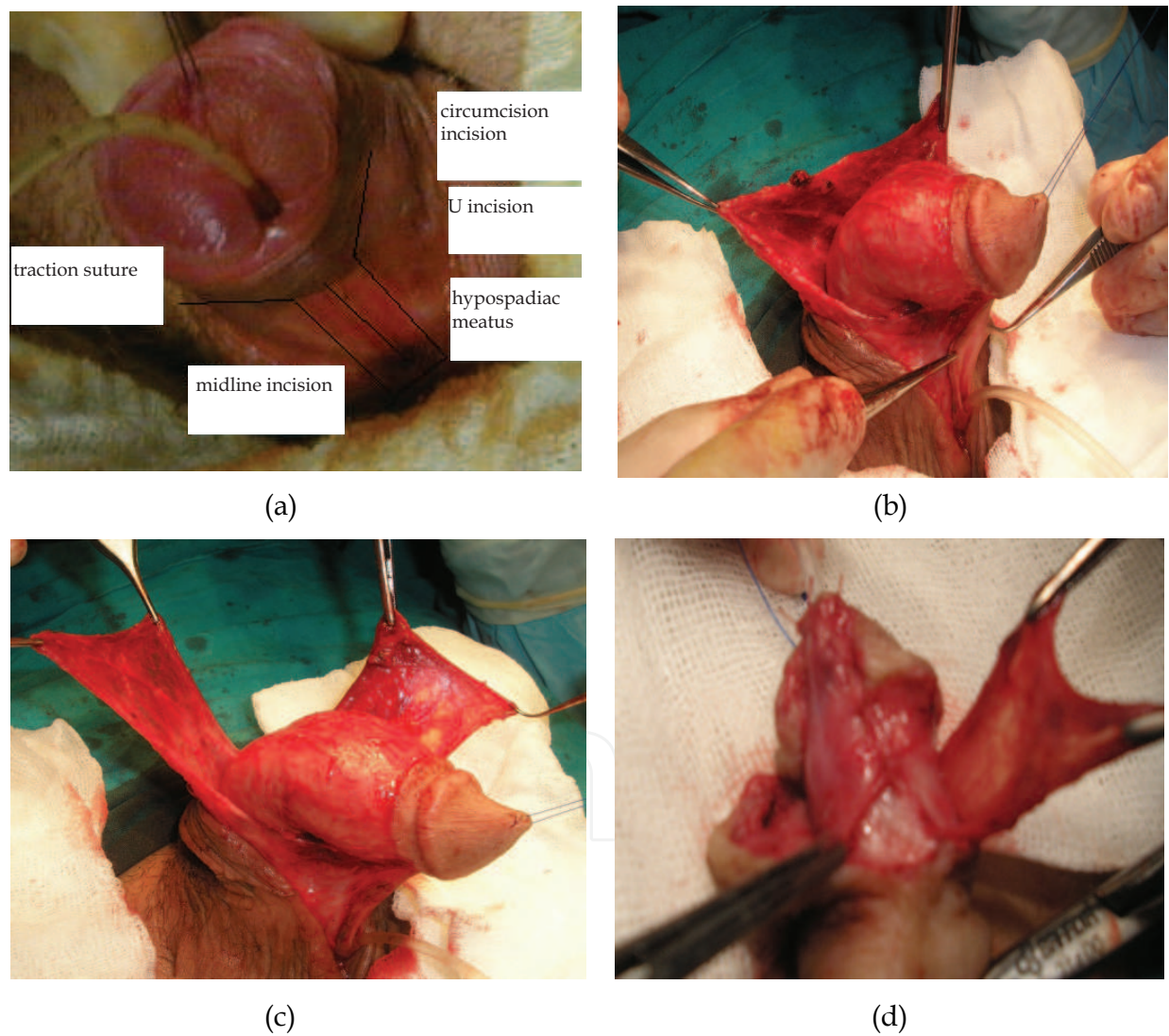


Fig. 1. (a) A 17-year-old patient with penoscrotal hypospadiac meatus where the the main key points of TIP urethroplasty are demonstrated; U-shaped incision, midline incision in urethroplate, (b) Posterior dartos flap prepared from subcutaneous tissue, (c) Dorsal dartos flap is incised from the middle thus both of layer can be rotated ventrally, (d) Shows how both of the layers of the flap covered the neourethra

The most common complication seen in hypospadias correction is urethrocutaneous fistula [8,9,10,11]. The rate of fistula was reported to be 3.5% in the present series [12,13]. Several modifications have been introduced on TIP urethroplasty to decrease the rate of fistula, especially regarding the usage of the dorsal dartos flap and we are from the first who applied this novel modification [6,14] (Figure 1). We introduced the usage of double layers dartos flap for the neourethra instead of one layer covering (Figure 1). There were different techniques concerning one layer covering. Retik and Borer described covering the neourethra with an asymmetric rotational subcutaneous dartos tissue flap [15], Yer-kes et al used a Y-to-I warp spongiosum for neourethra reinforcement [16]. Sozubir and Snodgrass [17] also used a dorsal dartos pedicle flap obtained from dorsal prepuce with buttonhole maneuver transposition of flap.

Urethral stricture differed from hypospadias in terms of; etiology, diagnosis, management, success rate and postoperative follow up. The etiology of hypospadias is congenital, however in urethral stricture, wide range of causes are present, traumatic, infectious and congenital cause as we mentioned before. While the physical examination is enough to diagnose hypospadias, the diagnosis of urethral stricture is not so much simple (we will discuss this issue in the coming sections). The surgical management of hypospadias is more simple and lead to more success in comparison to urethroplasty done due to urethral stricture. We will discuss in detail the surgical treatment of urethral stricture.

Urethral stricture refer to anterior urethral disease scarring process involving the spongy erectile tissue of the corpus spongiosum. According to world health organization posterior urethral stricture are not included in the common definition of urethral stricture and the term stricture is limited to the anterior urethra. Because the posterior urethra is fixed at both the urogenital diaphragm and the puboprostatic ligaments, the bulbomembranous junction is more vulnerable to injury during pelvic fracture. In children, injuries are more likely to extend proximally to the bladder because of the rudimentary nature of the prostate.

Diagnosis of urethral stricture begins by physical examination, the triad of blood at urethral meatus, inability to urinate, and palpably full bladder. Urethral disruption is often first detected when urethral catheter cannot be placed or when it is misplaced into pelvic hematoma. Females with urethral injuries presents with vulvar edema and blood at the vaginal introitus, thus indicating the need for careful vaginal examination in all female patients with pelvic fracture. Retrograde Urethrography (RGU) should be done when the blood at urethral meatus is discovered. Small-bore urethral catheter (16 French) is placed un lubricated 1 cm into the fossa navicularis and the balloon is filled with 1 cm of water or Brodney clamp or rolled gauze bandage can be used to provide penile traction. Regarding the usage of local anesthetic jel during retrograde urethrography, recently we published study regarding the usage lidocaine and we concluded that although usage of local anesthetic jel may lead to statistically significant dilatation of urethral diameter, clinically no false negative results in the diagnosis of urethral stricture were observed. [18]. Patients should be placed in an oblique or lateral decubitus position, and it is preferable to perform the study under fluorography, 28 ml of contrast material is injected gently by a 60-ml catheter-tip syringe and the film is taking during injection. The sensitivity and specificity to identify stricture by RGU are 67% to 100% and 93% to 97% with positive and negative predictive values of 50% and 97% to 100% respectively for anterior urethral stricture 3 to 5 cm long [19]. Limitation of RUG and VCUG include readily available fluoroscopic equipment and radiation exposure (1.1 mSV average for VCUG ie equivalent to approximately 11 chest x-rays [20]. Antegrade urethrography can be performed through suprapubic tube placed

after reconstruction. The initial management after the immediate diagnosis of urethral trauma is suprapubic catheter. The preoperative evaluation of urethral stricture before reconstructive procedure is planned, are imaging studies are necessary to delineate the characteristics of urethral stricture defect. A cystogram and retrograde urethrogram should be obtained simultaneously. Besides these main method of diagnosis a lot of methods can help in detecting urethral stricture; voiding symptoms and questionnaires described in the clinical history of the patient is the most basic and essential screening procedure to detect stricture. Multiple studies have evaluated the correlation between the AUA-SS and the presence of urethral stricture. The AUA-SS has been inversely correlated with urethral diameters by retrograde urethrogram and flow rates by uroflowmetry [21]. Morey et al demonstrated significant improvement in AUA-SS after successful urethroplasty that correlated with radiographic evidence of a patent urethra by retrograde urethrogram in 41 of 50 patients [22]. Urine culture/ urinary tract infection occurred due to increased post-void residual (PVR) and urinary stasis in patients with stricture. Urinary tract infection (UTI) is a common complication immediately after urethroplasty at reported rate of 6% [23]. To our knowledge no study has correlated postoperative UTI with stricture recurrence. Further studies are needed to determine the usefulness of urine culture as screening methods and the correlation between symptomatic UTI and stricture recurrence. Ultrasound PVR measurement is noninvasive technique that provide objective measurement of bladder emptying [24]. One may predict that high PVR volume would predict stricture. Unfortunately sonographic measurement are often user dependent with high interest variability [25] and up to two-third of patients may demonstrate daily variability in PVR of greater than 600ml [26]. Uroflowmetry is one of the most used measures to evaluate stricture. It is easily performed noninvasive and may allow quantitative data regarding voiding patterns [27]. Similar to ultrasound PVR, flow rates may be affected by operator error, benign prostate hyperplasia (BPH), lower urinary tract symptom, bladder dysfunction and variation in bladder capacity [28]. Further limitation of uroflowmetry include the needed for a minimum voided volume of 125 to 150 ml to reach a voided flow rate that reliably predicts an abnormality. Urethral ultrasound is relatively new technique for the evaluation of urethral stricture disease. First described by the McAninch et al in 1988 [29], urethral ultrasound (UU) to identify stricture has a reported sensitivity of 66% to 100%, specificity of 97% to 98%, and positive and negative predictive values of 50% to 80% and 96% to 98% respectively for anterior stricture 3 to 5 cm long. The usefulness of UU is limited by stricture location as it is more sensitive to stricture in the penile urethra than in bulbar portion [30]. It is also user dependency and the semi-invasive nature of the procedure often requiring local or general anesthesia for full urethra distention. It is benefit it can give three dimensional information about the stricture location and length. Magnetic resonance (MR) urethrography is a promising tool for defining male urethral strictures. It has comparable results with the combined RUG and SUG in diagnosing the anterior and posterior urethral strictures as regard the site and extension and degree of spongiositis but MR is superior in diagnosis of associated pathologies with stricture as it can provide extra-guidance for treatment planning that cannot be obtained with RUG [31,32].

In one of the most large systematic review for the diagnosis for recurrence stricture recurrence after urethroplasty conducted by Meeks et al [33] in their analysis of urethroplasty publication since 2000 found urethroplasty outcomes was determined by up to eight different diagnostics tests. The most common were uroflowmetry 56%, and retrograde urethrography 51%. Cystourethrography was used in 25% of patients. Recurrence of



stricture was defined as the need for an additional surgical procedure or dilatation in 75% and 52% of articles respectively. Clearly standardization is required and the methods used to determine stricture recurrence after urethroplasty remain widely variable. There are many objective and subjective procedures to evaluate for stricture recurrence. Standardization of A surveillance protocol after urethroplasty is needed to more effectively compare outcomes among institutions.

In our opinion both objective and subjective patients satisfaction outcomes should be evaluated. Objective measures should ideally involve urethrography or cystourethroscopy, flow rate is a poor indicator of urethral lumen diameters and a significant impact on flow rate is not observed until the urethral diameters is below 11F.

### **3. Treatment of urethral stricture; Endoscopic or open surgery?**

#### **3.1 Endoscopic management**

The management of urethral stricture disease in adult males has a wide range of possible therapeutics treatments. Urethral stricture are often treated with urethrotomy most commonly direct vision internal urethrotomy (DVIU) [34,35]. The popularity of this procedure has been attributed to the ease of performance, a perceived low complication rate and the fact that many north American urologists don not perform open urethroplasty so they may be forced to perform repeat urethrotomy[34,36]. The failure after initial urethrotomy is reported to be 50% [37,38]. The failure after second urethrotomy is considered much higher and can be as high as 100% [35,37,38]. Santucci R et al [39] performed retrospective review of more than 100 patients as a first study in north America, to evaluate the stricture free rate not only after single urethrotomy but after 2 through 5 procedure. He concluded that urethrotomy is a popular treatment for male urethral stricture. However the performance characteristics are poor. The Success rates after 1 urethrotomy was a mere 8% and after multiple urethrotomies was close to 0%. Because urethroplasty has long-term success rate ranging from 75-100, increased use of this more effective treatment may be warranted[40]. Urethrotomy should be reserved as a temporizing measure for poor surgical candidates until further reconstruction can be planned and executed. The majority of the base evidence base for the management of urethral strictures does not reach level 1 according to the oxford classification. With the rarity of significantly powered randomized controlled trials, we have to look to observational studies and expert opinion for guidance. In recent years there has been continuing discussion about the most appropriate use of urethrotomy, dilatation, stenting and intermittent self dilatation. We believe that self intermittent dilatation may be beneficial at least in prolonging the period between urethrotomies. There is no compelling evidence in literature that any particular form of urethrotomy is more effective than another, whether using a cold knife or laser. Heyns et al looked at whether repeated dilatation or urethrotomy was useful and noted that after single treatment 70% would be stricture free at three months, 35-40% would remain stricture free at 24 months, but not at 48 months. A third treatment was of no benefit at all [41].

Successful outcomes from urethrotomy or dilatation requires adequate vascularity within the under lining corpus spongiosum and is more likely to be successful in the bulbar urethra. Whilist et al [42] found up to two internal urethrotomy did not affect the outcomes or likelihood of subsequent anastomotic urethroplasty in patients with posterior injuries. For the anterior urethra using cox hazards regression analysis, failed internal urethrotomy



has been found to conform increased risk of failure for consequent urethroplasty [43]. Morey concluded that careful preoperative evaluation should be undertaken prior to internal urethrotomy and a patient should not need to have failed minimally invasive therapy prior to being considered for urethroplasty [44]. The current evidence suggests that the success is dependent upon stricture position, cause and length with success decline as the length of the stricture increases as clearly demonstrated by Heyns et al [41]. Altaf et al reported that one attempt at direct vision internal urethrotomy can be considered in the most bulbar stricture, unless they are complicated. For example by previous open surgery or fistulae, whilst a primary urethroplasty may be more appropriate in penile stricture [45]. This algorithm of considering an initial urethrotomy has been also been reiterated by Wessells to be the most cost effective [46]. Injection of triamcinolone (antifibroblast and anticollagen properties) was submucosally in 25 patients undergoing urethroplasty, reduced recurrence rates to 21.7% as compared to 50% in a control group at one year [47]. All the patients had stricture less than 1.5 cm and the author randomized the treatment with no mention of blinding.

Stents were introduced a number of years ago but unfortunately have not stayed the test of time since they have been clearly shown to be associated with complications [48]. Particularly if they are inserted as management of a failed urethroplasty following a urethral distraction injuries [49]. Failure of a permanently implanted urethral stent represents a significant therapeutic challenge which often leads to difficult substitution procedure with consequent limitation of the success of the procedure [49,50]. Therefore usage of stent should be limited to exceptional cases i.e difficult recalcitrant posterior urethral stenosis [51].

### 3.2 Open surgical techniques

The second treatment option is open surgical techniques or urethroplasty. Urethroplasty remains the most effective therapy for the management of most cases of anterior urethral stricture. Anastomatic urethroplasty involves excision of the stricture and the primary anastomosis of urethral ends. Traditionally strictures up to 3 cm have been considered as suitable for primary anastomosis. The limiting factors with anastomotic urethroplasty is the stricture length, in particular the length of the component distal to the bulbopenile junction. Open posterior urethroplasty through a perineal anastomotic approach is the treatment of choice for the most urethral distraction injuries because it definitely cures the patients without the need for multiple surgeries. One must be cautious of the risk of penile curvature and shortening, so mobilization of the urethra must not encroach upon the penile urethra. For bulbar stricture, by freeing up the urethra from the corpora and separating the two corpora another few centimeters may be gained in length depending on the individual circumstances. If the anastomotic urethroplasty is possible it is the procedure of choice having a success rate of approximately 90% at the intermediate follow-up [52,53]. In the patients with a 2-5 cm stricture undergoing an anastomotic procedure the risk of erectile dysfunction is increased [54]. A prospective study of erectile function post-urethroplasty showed anastomotic procedure in the bulbar urethra resulted in a significant impairment of erectile function initially which improved in the majority of cases. With low risk of long-term [55].

Substitution urethroplasty; this technique can be performed as one stage procedure via an augmented anastomotic procedure, (patch substitution onlay procedure) or a circumferential patch, or two stage procedure which involves the formation of a roof strip followed by second-stage tubularization. Balbagli and colleagues [56] reported their results in using

dorsal onlay graft urethroplasty and reported a series of 38 patients in which 65.8% were considered successful over a mean follow up of 111 months. The majority of the recurrence in this study occurred in the first year. Certainly in the long term follow up it is clear that the recurrence rate after a substitution is far worse than many would otherwise have considered likely based on the existing literature, with a reported rate of 42% at 15 years for substitution procedure and 14% for anastomotic procedure [57]. Barbagli et al [53] analyzed a cohort of 375 patients who underwent one of the three different one-stage procedure for bulbar strictures. He found that at an average follow up of 53 months the success rate for anastomotic urethroplasty was 90.9% and the augmented anastomotic repair was 60% and the onlay procedure was 80%. The Asopa technique, involving dorsal placement of a buccal mucosal graft via a ventral approach, has also been evaluated with 87% success rate at mean follow up of 42 months [58]. Another group found better success rate when applying a dorsal lingual mucosal graft via a ventral urethrotomy approach than a conventional barbagli approach of urethral mobilization [59]. However the preoperative characteristics of the patients in the group that underwent the barbagli approach include patients with higher proportion of patients with pan-urethral disease and balanitis Xerotica obliterans /infective causes potentially confounding interpretation of the results. Kulkarni et al have interestingly described better success rate with a one two stage oral mucosal urethroplasty 91 vs 73% respectively for penile stricture associated with lichen sclerosis [60]. However the number of the cases was low 8 and 15 respectively also the follow up period was short thus its difficult to draw any definite conclusion. Recently Kulkarni et al [61] have described the use of the one-sided anterior urethroplasty utilizing oral mucosa to preserve the lateral vascular supply to the urethra. Of 24 patients 92% had a successful outcomes at the mean of 22 months follow up. However the preservation of the lateral vascular supply of the urethra is of clinical values or not is still under debate. Barbagli et al [62] described a step to spare the bulbospongiosus nerves and muscles when gaining access for urethroplasty in series of sex patients. In all sex patients no evidence of stricture recurrence was noted at 12 months. Type of the grafts which have been used include scrotal skin [63], extragenital skin [64] and bladder mucosa [65]. In contemporary practice genital skin or oral mucosa are the most used, although there is interest in the future in the potential for tissue engineering [66]. Genital skin flaps are particularly useful when dealing with stricture in the penile urethra when an onlay flap of penile skin can be particularly helpful. Oral mucosa was first described in 1941 by Humby and Higgins [67]. This mucosa is used to being wet and is resilient to skin diseases such as lichen sclerosis and has a privileged immunology. Barbagli et al [68] in their retrospective review of 350 patients undergoing oral mucosa harvest from a single cheek showed the majority of patients had no pain 85.2% or major complication. Mathur et al [69] described the successful use of the tunica albuginea from the corpora for the urethroplasty with re-operation rate of 9.2% at 3 years in 206 patients. In 36 cases ranging between 10 and 20 cm in length, Xu et al [70] described success rates of 85.7% at a mean of 53.6 months using colonic mucosa. Similarly Munday and Andrich [71] described the use of grafts from the stomach, ileum and colon in complex patients with bulbomembranous strictures showing some success in otherwise unsalvageable cases. Tissue-engineering grafts of urethra offers a promising alternative to current grafts and minimize the risk of donor site morbidity [72]. A cellular grafts have undergone clinical assessment with mixed results [73,74]. Contemporary work is concentrated upon developing a cellular tissue engineered graft and Li et al [75] have shown a reduced inflammatory response and no recurrence of stricture up to 6 months in a rabbit model. Lu et al [76] have reported on the in-vitro success

of culturing urothelial cells on a cellular bladder matrix making the cellular graft histologically like urothelium.

In the future and in order to aid the decision-making process for the managements of stricture disease, randomized controlled studies (RCT) should be conducted [77,78]. Most of the current evidence comes from observational studies and due to the low qualities of cases available for RCT selection numbers are often increased by widening the inclusion criteria and thus comparing cases of different causes, locations and strictures size. It is clear that a more homogenous patients selection may guide clinical decisions better. Many factors have been found to affect urethroplasty outcomes and should thus be accounted for preoperatively [43,79]. Moreover, it must be noted that although evidence may support one technique over another, the situation during urethroplasty requires a dynamics assessment and adoption of an achievable procedure leading to patient-centered success.

#### 4. Conclusion

The plastic surgery of urethra include wide range of indications, operative techniques and outcomes. Urethroplasty done due to hypospadias is of more success rates in comparison to urethroplasty done due to urethral strictures. The surgeons have consensus on the preferable technique for hypospadias repair, however the situation is not similar regarding the management of urethral strictures. The contemporary evidence for the management of urethral strictures provides a practice-based algorithm which a reconstructive urologist may utilize when dealing with strictures based on location, length, anatomy and etiology. Moreover every case is unique and often different consideration have to be taken into account in carrying out surgery, with urologist being aware of the entire armamentarium of techniques and needing to use them to provide the best result for each patient. Therefore we believe that there is a need for a multi-center international database with outcomes standardization to adequately develop higher levels of comparative evidence. The development of validate patient-reported outcome measures is going to be very important in achieving this goal.

#### 5. References

- [1] Sweet RA, Schorrt HG, Kurland R et al. Study of incidence of hypospadias in Rochester, Minnesota 1940-1970 and a case control comparison of possible etiologic factors. *Mayo Clin Proc* 1974; 49: 52.
- [2] Snodgrass W, Koyle M, Manzoni G et al. Tubularized incised plate hypospadias repair for proximal hypospadias. *J Urol* 1998; 159:2129-2131.
- [3] Snodgrass W. Tubularized incised plate urethroplasty for distal hypospadias. *J Urol* 1994; 151:464-465.
- [4] Snodgrass W, Koyle M, Manzoni G et al. Tubularized incised plate for hypospadias repair: result of a multicenter experience. *J Urol* 1996; 156:839-841.
- [5] Snodgrass WT, Lorenzo A. Tubularized incised plate urethroplasty for hypospadias reoperation. *Br J Urol Int* 2002; 89:98-100.
- [6] Mustafa M, Wadie BS, Abol-Enein H. Standard Snodgrass technique in conjunction with double-layer covering of the neourethra with dorsal dartos flap is the therapy of first choice for hypospadias.. *Int Urol Nephrol*. 2008; 40(3):573-6.

- [7] Mustafa M. The concept of tubularized incised plate hypospadias repair for different types of hypospadias. *Int Urol Nephrol*. 2005; 37(1):89-91.
- [8] Sugarman ID, Trevett J, Malone PS. Tubularization of the incised plate (Snodgrass procedure) for the primary hypospadias surgery. *BJU Int* 1999; 83:88-90.
- [9] Jayanthi VR. The modified Snodgrass hypospadias repair: reducing the risk of fistula and meatal stenosis. *J Urol* 2003; 170:1603-1605.
- [10] Djordjevic ML, Perovic SV, Slavkovic Z, Djarovic N: longitudinal dorsal dartos flap for preventing of fistula after a Snodgrass hypospadias. *Eur Urol* 2006; 53-57.
- [11] Djordjevic ML, Perovic SV, Vukadinovic VM: Dorsal dartos flap for preventing fistula in the Snodgrass hypospadias repair. *BJU Int* 2005; 95:1303-1309.
- [12] Snodgrass W: Tubularized incised plate urethroplasty for distal hypospadias. *J Urol* 1994; 151:464-465.
- [13] Snodgrass W, Koyle M, Manzoni G, et al: Tubularized incised plate for hypospadias repair: result of a multicenter experience. *J Urol* 1996; 156:839-841.
- [14] Mustafa M, Wadie BS, Abol-Enein H. Dorsal dartos flap in Snodgrass hypospadias repair: how to use it?. *Urol Int*. 2008; 81(2):215-7.
- [15] Retik AB, Borer JG: Primary and reoperative hypospadias repair with the Snodgrass technique. *World J Urol* 1998; 16:186-191.
- [16] Yerkes EB, Adams MC, Miller DA, Pope JC, Rink RC, Brock JW 3<sup>rd</sup>: Y-to-I warp: use of the distal spongiosum for hypospadias repair. *J Urol* 2000; 163:1536-1539.
- [17] Sozubir S, Snodgrass W: A new algorithm for primary hypospadias repair based on TIP urethroplasty. *J Pediatr Surg* 2003; 38:1157-1161.
- [18] Mustafa M, Ali-El-Dein B, Mohsen T, Ibrahim el-HI. The use of local anesthetic gel during retrograde urethrography: does it cause a false negative result? *Int Urol Nephrol*. 2007; 39(2):513-6.
- [19] Choudhary S, Singh P, Sundar E et al: A comparison of sonourethrography and retrograde urethrography in evaluation of anterior urethral strictures. *Clin Radiol* 2004; 59: 736.
- [20] Arbique JM, Illeran JP, Buisson JB et al: Radiation exposure during standing voiding cystourethrography in women. *Urology* 2006; 67: 269.
- [21] Heyns CF and Marais DC: Prospective evaluation of the American Urological Association symptom index and peak urinary flow rate for the followup of men with known urethral stricture disease. *J Urol* 2002; 168: 2051.
- [22] Morey AF, McAninch JW, Duckett CP et al: American Urological Association symptom index in the assessment of urethroplasty outcomes. *J Urol* 1998; 159: 1192.
- [23] Navai N, Erickson BA, Zhao LC et al: Complications following urethral reconstructive surgery: a six year experience. *Int Braz J Urol* 2008; 34: 594.
- [24] Kaplan SA, Wein AJ, Staskin DR et al: Urinary retention and post-void residual urine in men: separating truth from tradition. *J Urol* 2008; 180: 47.
- [25] Rule AD, Jacobson DJ, McIvor ME et al: Longitudinal changes in post-void residual and voided volume among community dwelling men. *J Urol* 2005; 174: 1317.
- [26] Dunsmuir WD, Feneley M, Corry DA et al: The day-to-day variation (test-retest reliability) of residual urine measurement. *Br J Urol* 1996; 77: 192.
- [27] Feneley MR, Dunsmuir WD, Pearce J et al: Reproducibility of uroflow measurement: experience during a double-blind, placebo-controlled study of doxazosin in benign prostatic hyperplasia. *Urology* 1996; 47: 658.




- [28] Colomb J, Lindner A, Siegel Y et al: Variability and circadian changes in home uroflowmetry in patients with benign prostatic hyperplasia compared to normal controls. *J Urol* 1992; 147: 1044.
- [29] McAninch JW, Laing FC and Jeffrey RB Jr: Sonourethrography in the evaluation of urethral strictures: a preliminary report. *J Urol* 1988; 139: 294.
- [30] Nash PA, McAninch JW, Bruce JE et al: Sonourethrography in the evaluation of anterior urethral strictures. *J Urol* 1995; 154: 72.
- [31] Osman Y, El-Ghar MA, Mansour O, Refaie H, El-Diasty T. Magnetic resonance urethrography in comparison to retrograde urethrography in diagnosis of male urethral strictures: is it clinically relevant? *Eur Urol*. 2006; 50(3):587-93.
- [32] El-Ghar MA, Osman Y, Elbaz E, Refiaie H, El-Diasty T. MR urethrogram versus combined retrograde urethrogram and sonourethrography in diagnosis of urethral stricture. *Eur J Radiol*. 2010; 74(3):193-8.
- [33] Meeks JJ, Erickson BA, Granieri MA, Gonzalez CM. Stricture recurrence after urethroplasty: a systematic review. *J Urol* 2009; 182:1266-1270.
- [34] Greenwell TJ, Castle C, Andrich DE et al: Repeat urethrotomy and dilation for the treatment of urethral stricture are neither clinically effective nor cost-effective. *J Urol* 2004; 172: 275.
- [35] Naude AM and Heyns CF: What is the place of internal urethrotomy in the treatment of urethral stricture disease? *Nat Clin Pract Urol* 2005; 2: 538.
- [36] Bullock TL and Brandes SB: Adult anterior urethral strictures: a national practice patterns survey of board certified urologists in the United States. *J Urol* 2007; 177: 685.
- [37] Heyns CF, Steenkamp JW, De Kock ML et al: Treatment of male urethral strictures: is repeated dilation or internal urethrotomy useful? *J Urol* 1998; 160: 356.
- [38] Pansadoro V and Emiliozzi P: Internal urethrotomy in the management of anterior urethral strictures: long-term followup. *J Urol* 1996; 156: 73.
- [39] Santucci R., Eisenberg L: Urethrotomy has a much lower success rate than previously reported. *J Urol* 2010; 183:1859-1862.
- [40] Santucci RA: Male urethral stricture disease. In: *Urologic Diseases in America*. Edited by MS Litwin and CS Saigal. US Department of Health and Human Services, Public Health Service, National Institutes of Health, National Institute of Diabetes and Digestive and Kidney Diseases. Washington, D.C.: US Government Publishing Office 2007; NIH publication No. 07-5512, pp 531-552.
- [41] Heyns CF, Steenkamp JW, de Kock ML, Whitaker P. Treatment of male urethral strictures: is repeated dilation or internal urethrotomy useful? *J Urol* 1998; 160:356-358.
- [42] Singh BP, Andankar MG, Swain SK, et al. Impact of prior urethral manipulation on outcome of anastomotic urethroplasty for posttraumatic urethral stricture. *Urology* 2009; 75:179-182.
- [43] Breyer BN, McAninch JW, Whitson JM, et al. Multivariate analysis of risk factors for long-term urethroplasty outcome. *J Urol* 2009; 183:613-617.
- [44] Morey A. Urethral stricture is now an open surgical disease. *J Urol* 2009; 181 :953-954.
- [45] Mangera A, Christopher C. Management of anterior urethral stricture: an evidence-based approach. *Current opinion in urology* 2010; 20:453-458.

- [46] Wessells H. Cost-effective approach to short bulbar urethral strictures supports single internal urethrotomy before urethroplasty. *J Urol* 2009; 181:954– 955.
- [47] Mazdak H, Izadpanahi MH, Ghalamkari A, et al. Internal urethrotomy and intraurethral submucosal injection of triamcinolone in short bulbar urethral strictures. *Int Urol Nephrol* 2009.
- [48] Hussain M, Greenwell TJ, Shah J, Mundy A. Long-term results of a self-expanding wallstent in the treatment of urethral stricture. *BJU Int* 2004; 94:1037–1039.
- [49] Chapple CR, Bhargava S. Management of the failure of a permanently implanted urethral stent-a therapeutic challenge. *Eur Urol* 2008; 54:665– 670.
- [50] Palminteri E, Gacci M, Berdondini E, et al. Management of urethral stent failure for recurrent anterior urethral strictures. *Eur Urol* 2010; 57:615–21.
- [51] Eisenberg ML, Elliott SP, McAninch JW. Preservation of lower urinary tract function in posterior urethral stenosis: selection of appropriate patients for urethral stents. *J Urol* 2007; 178:2456–2460.
- [52] Lumen N, Piet H, Willem O. Urethroplasty for urethral strictures: quality assessment of an in-home algorithm. *Int J Urol* 2010; 17:167–174.
- [53] Barbagli G, Guazzoni G, Lazzeri M. One-stage bulbar urethroplasty: retrospective analysis of the results in 375 patients. *Eur Urol* 2008; 53:828–833.
- [54] Xie H, Xu YM, Xu XL, et al. Evaluation of erectile function after urethral reconstruction: a prospective study. *Asian J Androl* 2009; 11:209–214.
- [55] Erickson BA, Granieri MA, Meeks JJ, et al. Prospective analysis of erectile dysfunction after anterior urethroplasty: incidence and recovery of function. *J Urol* 2010; 183:657–661.
- [56] Barbagli G, Morgia G, Lazzeri M. Dorsal onlay skin graft bulbar urethroplasty: long-term follow-up. *Eur Urol* 2008; 53:628–633.
- [57] Andrich DE, Dunglison N, Greenwell TJ, Mundy AR. The long-term results of urethroplasty. *J Urol* 2003; 170:90–92.
- [58] Pisapati VL, Paturi S, Bethu S, et al. Dorsal buccal mucosal graft urethroplasty for anterior urethral stricture by Asopa technique. *Eur Urol* 2009; 56:201 – 205.
- [59] Singh PB, Das SK, Kumar A, et al. Dorsal onlay lingual mucosal graft urethroplasty: comparison of two techniques. *Int J Urol* 2008; 15:1002– 1005.
- [60] Barbagli G, De AM, Romano G, Lazzeri M. Clinical outcome and quality of life assessment in patients treated with perineal urethrostomy for anterior urethral stricture disease. *J Urol* 2009; 182:548–557.
- [61] Kulkarni S, Barbagli G, Sansalone S, Lazzeri M. One-sided anterior urethroplasty: a new dorsal onlay graft technique. *BJU Int* 2009; 104:1150–1155.
- [62] Barbagli G, De SS, Annino F, et al. Muscle- and nerve-sparing bulbar urethroplasty: a new technique. *Eur Urol* 2008; 54:335–343.
- [63] Jordan GH. Scrotal and perineal flaps for anterior urethral reconstruction. *Urol Clin North Am* 2002; 29:411–416.
- [64] Vyas PR, Roth DR, Perlmutter AD. Experience with free grafts in urethral reconstruction. *J Urol* 1987; 137:471 –474.
- [65] Xu YM, Qiao Y, Sa YL, et al. Urethral reconstruction using colonic mucosa graft for complex strictures. *J Urol* 2009; 182:1040–1043.
- [66] Bhargava S, Patterson JM, Inman RD, et al. Tissue-engineered buccal mucosa urethroplasty-clinical outcomes. *Eur Urol* 2008; 53:1263–1269.

- [67] Humby G, Higgins T. A one-stage operation for hypospadias. *Br J Surg* 2009; 29:84–92.
- [68] Barbagli G, Vallasciani S, Romano G, et al. Morbidity of oral mucosa graft • • harvesting from a single cheek. *Eur Urol* 2010; 58:33–41.
- [69] Mathur RK, Sharma AK, Odiya S. Tunica albuginea urethroplasty for anterior urethral strictures: a urethroscopic analysis. *Int J Urol* 2009; 16:751 –755.
- [70] Xu YM, Qiao Y, Sa YL, et al. Urethral reconstruction using colonic mucosa graft for complex strictures. *J Urol* 2009; 182:1040–1043.
- [71] Mundy AR, Andrich DE. Entero-urethroplasty for the salvage of bulbo-membranous stricture disease or trauma. *BJU Int* 2009; 105:1716–1720.
- [72] Jenkins BJ, Badenoch DF, Fowler CG, Blandy JP. Long-term results of treatment of urethral injuries in males caused by external trauma. *Br J Urol* 1992; 70:73–75.
- [73] El-Kassaby A, Aboushwareb T, Atala A. Randomized comparative study between buccal mucosal and acellular bladder matrix grafts in complex anterior urethral strictures. *J Urol* 2008; 179:1432–1436.
- [74] Ecke TH, Hallmann S, Gerullis H, Ruttloff J. Reconstruction of the urethra with a Surgisis onlay patch in urethral reconstructive surgery: two case reports. *J Med Case Reports* 2009; 3:7232.
- [75] Li C, Xu Y, Song L, et al. A preliminary experimental study on urethral reconstruction using tissue engineered oral mucosa. *Zhongguo Xiu Fu Chong Jian Wai Ke Za Zhi* 2008; 22:1 242–1 245.
- [76] Lu MJ, Wang Z, Zhou GD, et al. Construction of urethra mucosa structure in vitro by tissue engineering. *Zhonghua Nan Ke Xue* 2008; 14:1072–1076.
- [77] Barbagli G, Lazzeri M. Can reconstructive urethral surgery proceed without randomized controlled trials? *Eur Urol* 2008; 54:709–711.
- [78] Capizzi A. Urethral surgery in the evidence-based medicine (EBM) era: a never-ending story. *Urology* 2009; 73:1172–1174.
- [79] Breyer BN, McAninch JW, Whitson JM, et al. Effect of obesity on urethroplasty outcome. *Urology* 2009; 73:1352–1355.

IntechOpen



## **Current Concepts of Urethroplasty**

Edited by Dr Ivo Donkov

ISBN 978-953-307-392-7

Hard cover, 152 pages

**Publisher** InTech

**Published online** 19, July, 2011

**Published in print edition** July, 2011

Urethral reconstructive surgery has always been a challenging part for urologist since the dawn of our speciality. In this book leading experts in lower urinary reconstructions from all over the world present their views and experience in that field, together with practical tips and tricks. The book is an excellent source of information for those who are already dealing with urethral surgery, and also an invaluable companion for urologists in training or those who want to dedicate themselves to this great sub-specialty. This book is an excellent reference guide and companion on the way to operating and consulting room, or when writing an article and reviewing the current practices. The abundance of methods and continuing development of new approaches to the problem prove the complexity of it.

### **How to reference**

In order to correctly reference this scholarly work, feel free to copy and paste the following:

Mahmoud Mustafa, Dina Abugaber, Sacit Nurigorgel, Ertugrul Sefik, Ozan Horsanali and Wael Sadaqah (2011). Urethroplasty; Wide Range of Therapeutic Indications and Surgical Techniques, Current Concepts of Urethroplasty, Dr Ivo Donkov (Ed.), ISBN: 978-953-307-392-7, InTech, Available from:  
<http://www.intechopen.com/books/current-concepts-of-urethroplasty/urethroplasty-wide-range-of-therapeutic-indications-and-surgical-techniques>

**INTECH**  
open science | open minds

### **InTech Europe**

University Campus STeP Ri  
Slavka Krautzeka 83/A  
51000 Rijeka, Croatia  
Phone: +385 (51) 770 447  
Fax: +385 (51) 686 166  
[www.intechopen.com](http://www.intechopen.com)

### **InTech China**

Unit 405, Office Block, Hotel Equatorial Shanghai  
No.65, Yan An Road (West), Shanghai, 200040, China  
中国上海市延安西路65号上海国际贵都大饭店办公楼405单元  
Phone: +86-21-62489820  
Fax: +86-21-62489821



© 2011 The Author(s). Licensee IntechOpen. This is an open access article distributed under the terms of the [Creative Commons Attribution 3.0 License](https://creativecommons.org/licenses/by/3.0/), which permits unrestricted use, distribution, and reproduction in any medium, provided the original work is properly cited.

IntechOpen

IntechOpen