

# We are IntechOpen, the world's leading publisher of Open Access books Built by scientists, for scientists

6,900

Open access books available

186,000

International authors and editors

200M

Downloads

Our authors are among the

154

Countries delivered to

TOP 1%

most cited scientists

12.2%

Contributors from top 500 universities



WEB OF SCIENCE™

Selection of our books indexed in the Book Citation Index  
in Web of Science™ Core Collection (BKCI)

Interested in publishing with us?  
Contact [book.department@intechopen.com](mailto:book.department@intechopen.com)

Numbers displayed above are based on latest data collected.  
For more information visit [www.intechopen.com](http://www.intechopen.com)



# Tunica Albuginea Urethroplasty

RK Mathur

*Mahatma Gandhi Memorial Medical College & Maharaja Yashwantrao Hospital, Indore  
India*

## 1. Introduction

The male urethra can be divided into two different portions -The Posterior urethra and the Anterior urethra. The Posterior urethra consist of the membranous and the prostatic part and the Anterior urethra includes the navicularis, penile and bulbous region and is surrounded by corpus spongiosum.

Urethral strictures are an old affliction of mankind and can be defined as “a decrease in the caliber of the urethra due to a scar resulting from tissue injury or inflammation” Usually, fibrosis involves the corpus spongiosum also.

## 2. Etiological factors

Currently, trauma (accidental or iatrogenic) is the most common cause of urethral stricture. Anterior urethral strictures are caused mostly by the use of indwelling catheters especially the red rubber catheter. Traumatic incidence especially with transurethral resection of prostate has increased the incidence of pendulous and meatal strictures. In developing countries despite increasing awareness and education about sexually transmissible infections (STIs), urinary tract infections also continue to be an important cause and prognostic factor.

Traumatic strictures commonly involve the mucosa and submucosal layers whereas an inflammatory strictures may also extend into the erectile tissue of the corpus spongiosum or the surrounding layers.

## 3. Techniques available for urethral reconstruction

A wide array of techniques are used in the reconstructive surgery for anterior urethral stricture diseases, and modifications are continuously being made. Stricture excision and anastomotic repair is appropriate only for short and untreated lesions of traumatic origin. End-to-end urethroplasty for bulbar urethral stricture has greater than 95% durable cure rates and low complication rates. Long urethral strictures, which are not amenable to endoscopic correction, require anastomotic urethroplasty.

Urethroplasty of long strictures can be done either by standard two-staged procedures (marsupialization and creation of hypospadias in one stage and closing the lateral skin in midline in a second) or substitution of the strictured part by using genital skin, buccal mucosa and bladder mucosa graft, and so forth. Urethroplasty, with different grafts, usually requires technical expertise and restructure rates are high.

#### 4. Tunica albuginea urethroplasty: A novel technique

Presently buccal mucosal dorsal onlay grafting is considered the standard substitution urethroplasty procedure for anterior urethral strictures. We introduce a technique of anterior urethroplasty by using locally available tunica albuginea of the corpora cavernosa. In tunica albuginea urethroplasty (TAU), the ventral aspect of the tunica albuginea of the corpora cavernosa is used to form the roof of the neourethra.

The anatomical and histological similarity of the tunica albuginea of the corpora cavernosa to the covering of the urethra and its local availability prompted us to use it for urethroplasty. Furthermore, it has been observed that in other cases of urethroplasties with dorsal onlay grafts after necrosis, it is the tunica albuginea that maintains the urethral patency.

#### 5. Tunica albuginea urethroplasty - procedure

##### 5.1 Anatomical remarks

The anterior urethra includes the navicularis, penile and bulbous regions, and is surrounded by the corpus spongiosum. In the bulbar urethra, the relationship between the spongiosum tissue and the mucosal membrane is quite different from the relationship in the penile region: the corpus spongiosum is thick on the ventral urethral surface and thin on the dorsal urethral surface. Furthermore, the urethral lumen is located dorsally and not centrally.

##### 5.2 Operation

The patient is placed in the normal lithotomy position, and a midline penoscrotal incision was given. The bulbar or penile urethra, along with corpus spongiosum, was then freed and was dissected from the corpora cavernosa. The urethra was completely mobilized from the tunica albuginea of corpora cavernosa, which was then rotated and incised along its dorsal surface. The stricture was opened along its whole length.

Thus, the lumen of the strictured segment faced the ventral aspect of the tunica albuginea of corpora cavernosa. An all-silicone urethral catheter was passed through the meatus into the bladder and retained *in situ*. Then, the walls of the slit urethra, along with the tunica of the corpus spongiosum, were stitched to the tunica albuginea of the corpora cavernosa using interrupted vicryl 2-0 sutures at the 5 and 7 o'clock positions (Fig. d). Hemostasis was secured and fascia and skin were closed in layers (Fig. e). In this technique, the ventral aspect of tunica albuginea of corpora cavernosa forms the roof of neourethra and the floor is formed by a strictured portion of the urethra, along with corpus spongiosum which is cut dorsally.

##### 5.3 Postoperative course

After 21 days, the catheter was removed and a voiding cystourethrography was obtained. Urine culture was repeated every 4 months during the first year and yearly thereafter.

#### 6. Results

Results of the above technique was evaluated in the form of a large scale retrospective and prospective study conducted on 206 patients presenting with symptoms of urethral stricture during the period 1993–2008. After routine workup, in a detailed preoperative assessment, patients were evaluated by means of retrograde urethrogram, urethrosonogram, and uroflometry (preoperatively possible only in cases not having a supra pubic catheter).

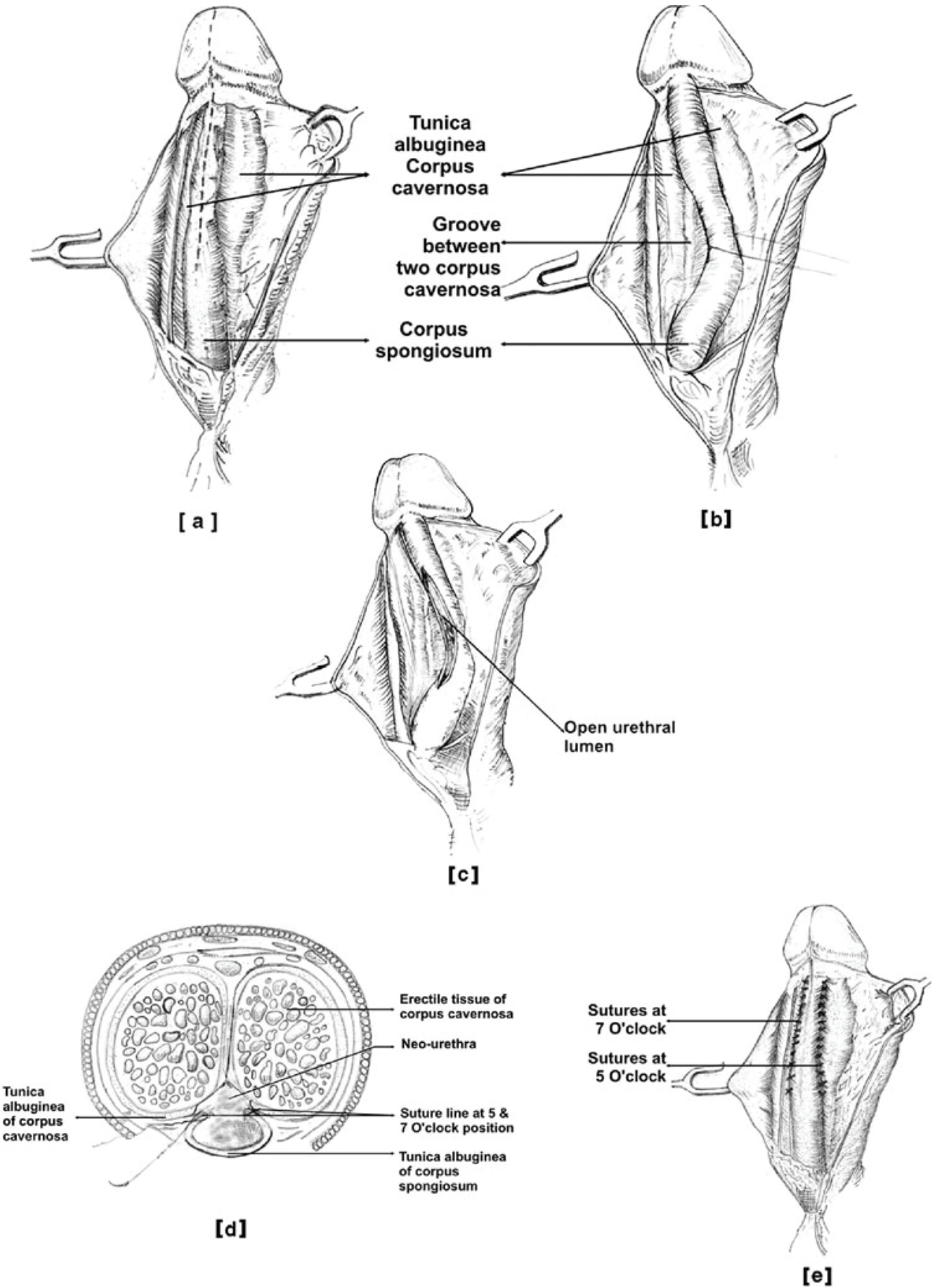


Fig. 1. Technique of Tunica Albuginea Urethroplasty

These patients were taken for TAU, the steps of which are illustrated in the above figure. Among 206 patients, 26 had membranous urethral strictures associated with anterior urethral strictures, which required a combined retrograde urethrogram and micturating cystourethrogram for preoperative evaluation, while in complex cases, magnetic resonance urethrogram was carried out. In all of these patients, U-shaped prostatobulbar anastomosis was carried out along with tunica albuginea urethroplasty.

After surgery, a perurethral 22 French silicon catheter was kept for 3 weeks in simple strictures and for 6 weeks in complex strictures. After catheter removal, patients were scheduled for postoperative assessment with contrast urethrogram, urethrosonogram, and uroflometry. Results were assessed by comparing pre and postoperative investigations and patient satisfaction.

Between July 2007 and September 2008, 30 patients were scheduled for postoperative urethroscopic evaluation. Urethroscopy was carried out only once in these selected patients (in which the outcome had already been assessed by our standard protocol mentioned in. The selection of patients to undergo urethroscopy was random from all groups, so as to allow us to assess both successful and failed cases.

Successful cases were scheduled for urethroscopy to understand how tunica albuginea maintained the urethral lumen without the help of any graft or flap, and also to confirm the growth of urothelium over the area of the roof formed by the tunica of the corpora cavernosa. Failed cases were evaluated to allow an understanding of the process of restricture after surgery.

criteria	good	fair	poor
retrograde urethrogram	Good caliber.	Partial narrowing at stricture site.	Persistent stricture.
urethro-sonogram	Patent and distensible lumen.	Patent lumen with decreased distensibility	Stricture present.
uroflowmetry	Qmax: >20 ml/sec	Qmax: 15-20 ml/sec	Qmax: <15ml/sec
patient's satisfaction	Satisfactory voiding, No instrumentation needed.	Satisfactory voiding but required few dilatations.	Not satisfied, not voiding or voiding with thin stream, need multiple dilatations or repeat surgery.

Table 1. Postoperative result assessment criteria

6.1 Outcome

In the study most of the stricture patients (63%) were young and middle-aged (20–45 years). Among all patients, traumatic and iatrogenic strictures were the most common, followed by



infective strictures. Almost 78% of patients had already undergone some previous intervention including multiple urethrotomies, dilations or some form of urethroplasty. Length of stricture (measured intraoperatively) ranged between 2.5 and 12.7 cm with median value 4.6 cm. Mean stricture length was 5.8 cm. It was noticeable that strictures shorter than 2.5 cm were rarely encountered. Probably late presentation for definitive corrective urethroplasty and continued inflammation may be the reason for this. Preoperative uroflowmetry was possible only in 98 patients as more than half of patients had suprapubic catheter for complete urinary retention. Preoperative maximum flow rates (Qmax) analysis showed a range of 3.0 to 12.5 mL/s, mean 7.6 mL/s, mode 5.0 mL/s, median 6.8 mL/s and standard deviation of 1.9 cm. Good and fair results were assumed to be successful, while poor results were considered failures. Postoperative and half yearly evaluation showed 96.6% (199) (good 85.9% [177] + fair 10.7% [22]) success rate which decreased to 94.7% (195) (good 84.5% [174] + fair 10.2% [21]) at 1 year and 93.2% (192) (good 84% [173] + fair 9.2% [19]) at 2 years. At the end of 3 years, the success rate was over 90% (good 84% [173] + fair 6.8% [14])

Most of the stricture recurrence (14 = 6.8%) occurred within the first 2 years of surgery, followed by 2.4% (five patients) between the 2nd and 3rd year of follow-up. A total of 19 cases (9.2%) were considered failures, requiring repeat urethroplasty. Out of the total 19 failed cases, six had lichen sclerosus et atrophicus associated with the stricture and another seven failed cases had combined anterior and posterior urethral strictures. About 10% of patients had minor superficial wound infection, which led to delayed healing. Two patients (<1%) developed urethrocutaneous fistula associated with cases of inflammatory etiology. Among 30 patients who were selected for urethroscopy, 18 were good results, seven were fair and five were failed cases.

As visualized on postoperative urethroscopy, in good results, the roof of the neourethra appears to have a similar lining as its base. Hence, it is expected that the urothelium regrows over the surface of the tunica albuginea. Beyond urethroscopy, the ultimate proof for this can only be a urethroscopic biopsy of the neourethral lining to confirm it is urothelium. In endoscopic evaluation, failed cases showed either circumferential scarring or extensive fibrotic narrowing at the site of reconstruction.

Also supported by studies, preoperative presence of a suprapubic catheter was shown to have a lesser incidence of circumferential scarring at the proximal urethra, as it relieves ballooning of the proximal urethra, drains urine well to relieve urinary stasis, thus ultimately decreasing inflammation in the proximal normal urinary tract.

This probably explains how continued inflammation leaves its mark in the form of fibrosis at expectedly normal ends of the proximal urethra and why there is circumferential scarring as the cause of stricture recurrence after TAU.

Similar fibrotic narrowing was also described by Barbagli *et al.* after bulbar onlay graft urethroplasty in the form of a ring stricture. Failed cases with inflammatory etiology showed diffuse fibrotic narrowing at the site of urethra reconstruction. The entire neourethra lumen was collapsed and replaced by fibrosis as a result of intense inflammation.

## 7. Advantages of tunica albuginea urethroplasty

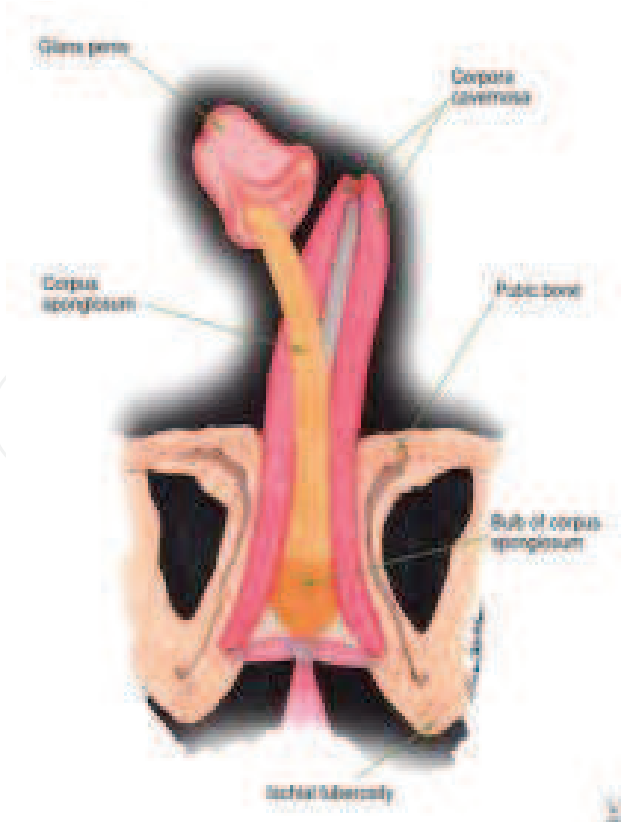
Success of free graft apposition depends on neovascularization from the surrounding structures, failure of which leads to necrosis of graft and formation of urethroperineal

fistula. Current techniques adopt graft (e.g. buccal mucosa, bladder mucosa) or flap apposition (e.g. pedicled skin flaps, skin island onlay flaps), but this often lacks the mechanical support of a fixed bed, which allows it to fold on itself, reducing the opportunity of neovascularization, and decreasing the caliber of the reconstructed urethra. Moreover, sacculation at the graft side or flap may occur, causing post-voiding dribbling and ejaculatory failure. Sequestration of semen and residual infected urine inside the pseudodiverticulum may further compromise the state of the adjacent urethra and facilitate recurrent stricture disease.

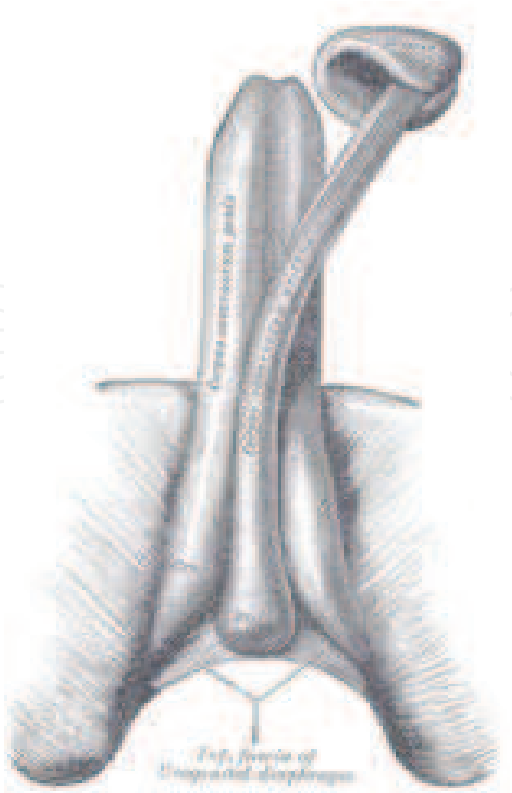
	Good results	Fair results	Poor results
Urethroscopy	Wide patent distensible lumen, regular mucosa	Patent lumen with decreased distensibility, some mucosal irregularities	Distal obliterated lumen, not possible to negotiate scope further

Table 2. Categorization of various urethroscopic findings

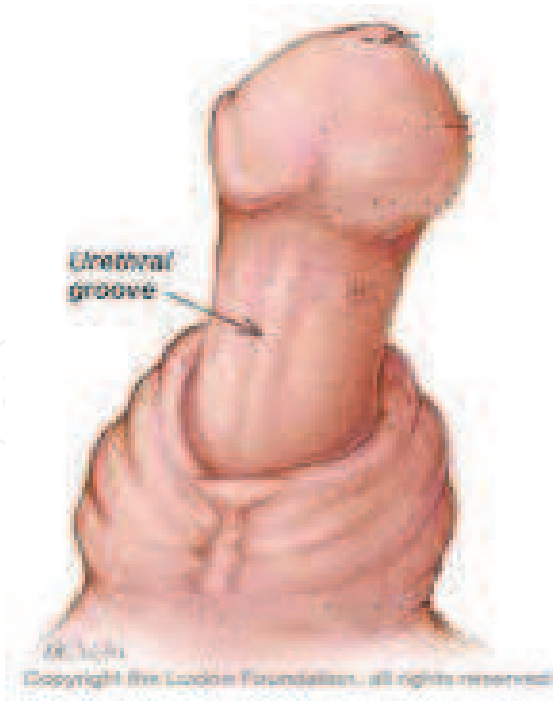
Some people recommend that dorsal onlay buccal mucosa graft can overcome these complications, but in a study by Barbagli *et al.* showed that the placement of buccal mucosa grafts into the ventral, dorsal or lateral surface of the bulbar urethra showed the same success rates (83–85%) and the outcome was not affected by the surgical technique.



(a)



(b)



(c)

Fig. 2. Figures showing the urethral groove



The urethroplasty of anterior urethral stricture by using locally available similar structures like tunica albuginea in a single-stage procedure is easy to perform, more feasible and, moreover, anatomically similar tissues are used for approximation as the fibers of the tunica albuginea of the corpora cavernosa and corpus spongiosum are histologically similar in composition and fiber orientation. Both have a circular inner layer that supports and contains the respective cavernous and spongiosal tissues. From these inner layers radiates intercavernosal and spongiosal pillars, respectively, that act as struts to augment the septum, which provides essential support, thus facilitating healing without the dangers of excessive fibrosis which could lead to reformation of the stricture.

The advantages of doing urethroplasty by using tunica albuginea of corpora cavernosa are:


1. Locally available tissue (tunica albuginea of corpora cavernosa) is used.
2. Postoperative restructure rates are very low.
3. The disadvantages of using hair-bearing skin are avoided.
4. It can be used for fairly long strictures (including pan-urethral stricture) without formation of chordae postoperatively.
5. Formation of urethroperineal fistula is not seen.
6. Doesn't require much technical expertise.
7. Cosmetically, the penis looks normal without any bending or curvatures.

## 8. Conclusion

Urethroplasty, by using anatomically far off and histologically dissimilar grafts, requires more expertise and the chances of restructure are high as well, especially in long strictures. Urethroplasty of anterior urethral stricture by using locally available similar tissue in a singlestage procedure is easy to perform and the postoperative results showed satisfactory results in 94.93% of the patients which is comparable to any other technique. Thus, we strongly recommend the use of tunica albuginea of corpora cavernosa, which is histologically similar and anatomically located near the stricture, rather than using distant and histologically dissimilar tissues such as buccal mucosa, skin and so forth, for anterior urethroplasty.

## 9. References

- [1] Mathur RK, Himanshu A, Sudarshan O. Technique of anterior urethra urethroplasty using tunica albuginea of corpora cavernosa. *Int. J Urol.* 2007 Mar; 14(3):209-13.
- [2] Mathur RK, Sharma Adittya K, Sudarshan O. Tunica Albuginea Urethroplasty for anterior urethral strictures. *International journal of Urology* september 2009; 16(9):751-5.
- [3] Mathur RK, Himanshu A, Sudarshan O. A technique of anterior urethroplasty using tunica albuginea of the corpora cavernosa. *Asian journal of Surgery* July 2008; 31(3):134-9
- [4] Mathur RK, Sharma Adittya K. Tunica Albuginea Urethroplasty for Panurethral strictures. *Urol J.* 2010; 7:120-4.



## **Current Concepts of Urethroplasty**

Edited by Dr Ivo Donkov

ISBN 978-953-307-392-7

Hard cover, 152 pages

**Publisher** InTech

**Published online** 19, July, 2011

**Published in print edition** July, 2011

Urethral reconstructive surgery has always been a challenging part for urologist since the dawn of our specialty. In this book leading experts in lower urinary reconstructions from all over the world present their views and experience in that field, together with practical tips and tricks. The book is an excellent source of information for those who are already dealing with urethral surgery, and also an invaluable companion for urologists in training or those who want to dedicate themselves to this great sub-specialty. This book is an excellent reference guide and companion on the way to operating and consulting room, or when writing an article and reviewing the current practices. The abundance of methods and continuing development of new approaches to the problem prove the complexity of it.

### **How to reference**

In order to correctly reference this scholarly work, feel free to copy and paste the following:

RK Mathur (2011). Tunica Albuginea Urethroplasty, Current Concepts of Urethroplasty, Dr Ivo Donkov (Ed.), ISBN: 978-953-307-392-7, InTech, Available from: <http://www.intechopen.com/books/current-concepts-of-urethroplasty/tunica-albuginea-urethroplasty>

**INTECH**  
open science | open minds

### **InTech Europe**

University Campus STeP Ri  
Slavka Krautzeka 83/A  
51000 Rijeka, Croatia  
Phone: +385 (51) 770 447  
Fax: +385 (51) 686 166  
[www.intechopen.com](http://www.intechopen.com)

### **InTech China**

Unit 405, Office Block, Hotel Equatorial Shanghai  
No.65, Yan An Road (West), Shanghai, 200040, China  
中国上海市延安西路65号上海国际贵都大饭店办公楼405单元  
Phone: +86-21-62489820  
Fax: +86-21-62489821

© 2011 The Author(s). Licensee IntechOpen. This is an open access article distributed under the terms of the [Creative Commons Attribution 3.0 License](https://creativecommons.org/licenses/by/3.0/), which permits unrestricted use, distribution, and reproduction in any medium, provided the original work is properly cited.

IntechOpen

IntechOpen