

# We are IntechOpen, the world's leading publisher of Open Access books Built by scientists, for scientists

6,900

Open access books available

185,000

International authors and editors

200M

Downloads

Our authors are among the

154

Countries delivered to

TOP 1%

most cited scientists

12.2%

Contributors from top 500 universities



WEB OF SCIENCE™

Selection of our books indexed in the Book Citation Index  
in Web of Science™ Core Collection (BKCI)

Interested in publishing with us?  
Contact [book.department@intechopen.com](mailto:book.department@intechopen.com)

Numbers displayed above are based on latest data collected.  
For more information visit [www.intechopen.com](http://www.intechopen.com)



## Plateau Iris

Yoshiaki Kiuchi, Hideki Mochizuki and Kiyoshi Kusanagi  
Hiroshima University  
Japan

### 1. Introduction

Primary angle-closure glaucoma (PACG) is a common form of glaucoma in Asia (Foster & Johnson, 2001). It is associated with a high risk of visual loss (Congdon et al., 1992; Foster et al., 1996). PACG was estimated to blind 5 times more people than primary open-angle glaucoma (Quigley et al. 2001). The original concept of primary angle closure glaucoma was a pupil- block angle-closure mechanism occurring in predisposed eyes with shallow anterior chamber angles. Peripheral iridectomy prevents the progression of primary angle closure glaucoma (Lowe, 1964). However, many patients experienced recurrent angle-closure glaucoma attacks after iridectomy (Wand et al., 1977). The occurrence of narrow angle in eyes with relatively normal depth in the anterior chamber and a relatively flat iris plane had been noted as early as 1940 (Gradle & Sugar, 1940). Chandler presented the case of a patient with repeated intermittent angle-closure glaucoma attacks despite a patent iridectomy, who was successfully treated with pilocarpine (Wand et al., 1977). Those cases were considered to be different from ordinary cases of narrow angle glaucoma. They were particularly found

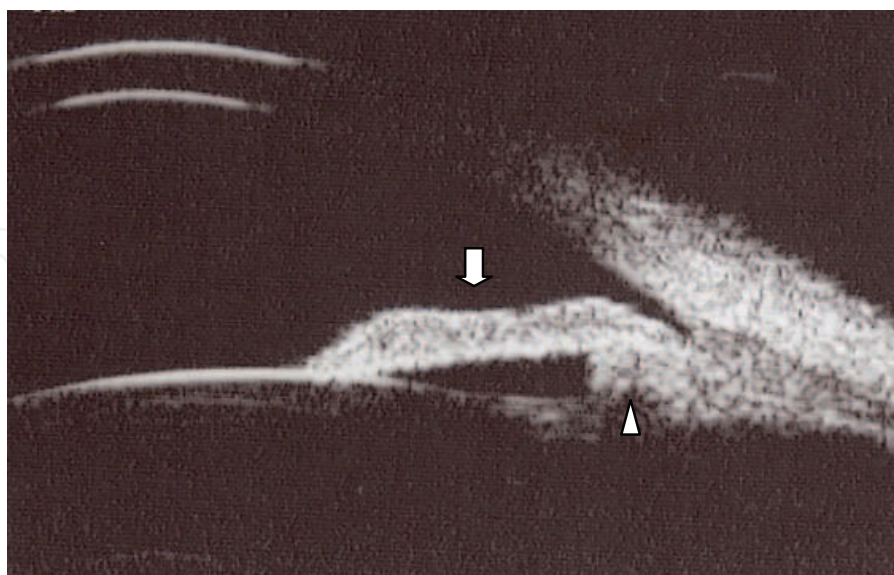


Fig. 1. Plateau iris configuration. Ultrasound biomicroscopy image shows a flat iris plane (⇩) accompanied by a narrow or closed anterior chamber angle. Plateau iris configuration is caused by anteriorly located ciliary processes (⇧), which close the ciliary sulcus and provide support to the peripheral iris

in younger patients in whom a peripheral iridectomy is often ineffective. These patients had a flat iris and a narrow angle secondary to an abrupt angulation at the root of the iris. This iris shape was called a plateau iris configuration.

The concept of the plateau iris was introduced in a publication by Shaffer (Shaffer, 1960). Primary angle closure includes those that are caused by a pupillary block and plateau iris configuration (Tarongoy et al., 2009).

## 2. Plateau iris configuration and plateau iris syndrome

Wand et al. reported that the plateau iris syndrome should be differentiated from the plateau iris configuration, to avoid confusion. Native plateau iris configuration refers to a preoperative (iridectomy or iridotomy) condition, in which angle-closure glaucoma is confirmed by gonioscopy, but the iris is flat and the anterior chamber is not shallow (Wand et al., 1977). One third of all patients demonstrating primary angle closure were estimated to have plateau iris configuration (Kumar et al., 2009, Mochizuki et al., 2010).

Plateau iris syndrome refers to the development of angle closure in an eye with plateau iris configuration. The intraocular pressure (IOP) increases because of angle closure after pupillary dilation. Plateau iris configuration can be diagnosed before iridotomy. However, plateau iris syndrome is normally diagnosed after laser iridotomy. Plateau iris syndrome is rare. Less than 10 % of all patients with primary angle closure are considered to have plateau iris syndrome.

The prevalence of angle closure attack in plateau iris syndrome is not known.

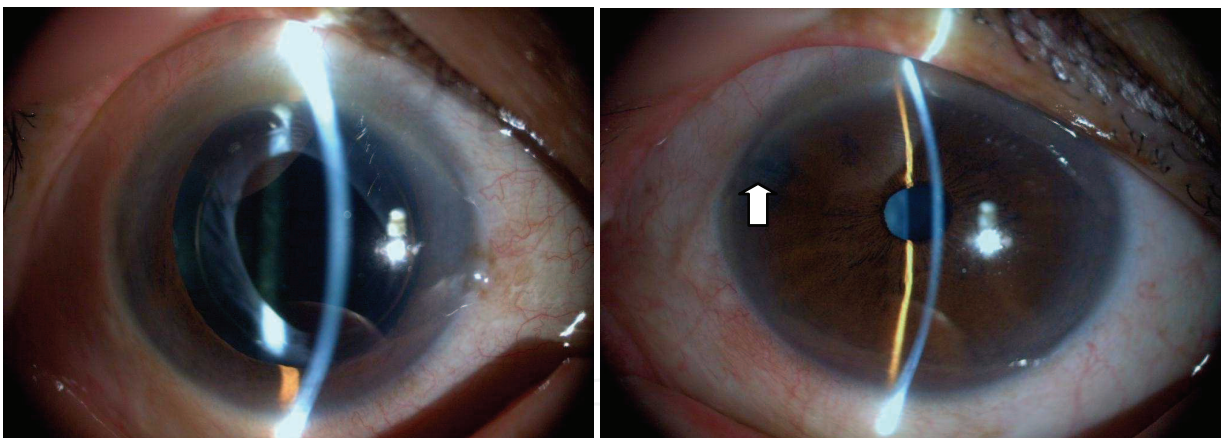


Fig. 2. Slit lamp photograph of an eye with a re-attack of acute closer attack and the patient's opposite eye. Right eye; Pupil is dilated after the second attack. Left eye; The laser iridotomy hole (↑) is observed at 10 o'clock

The right eye developed acute closed-angle attack on December 2005. After successful treatment by laser iridotomy patients had a re-attack on October 2006. This patient underwent cataract surgery for the relief of the angle closure attack. Cataract surgery stabilized the IOP in the right eye.

Plateau iris syndrome is classified into two groups. Complete syndrome has a high plateau and covers the chamber angle after dilation and causes elevation of the IOP. Incomplete Syndrome partially covers the chamber angle after dilation of the pupil. The IOP will not elevate after dilating the pupil. However, the peripheral anterior synechia (PAS) increases

over time (Wand et al., 1977). Many people tend to confuse incomplete plateau syndrome with plateau iris configuration.

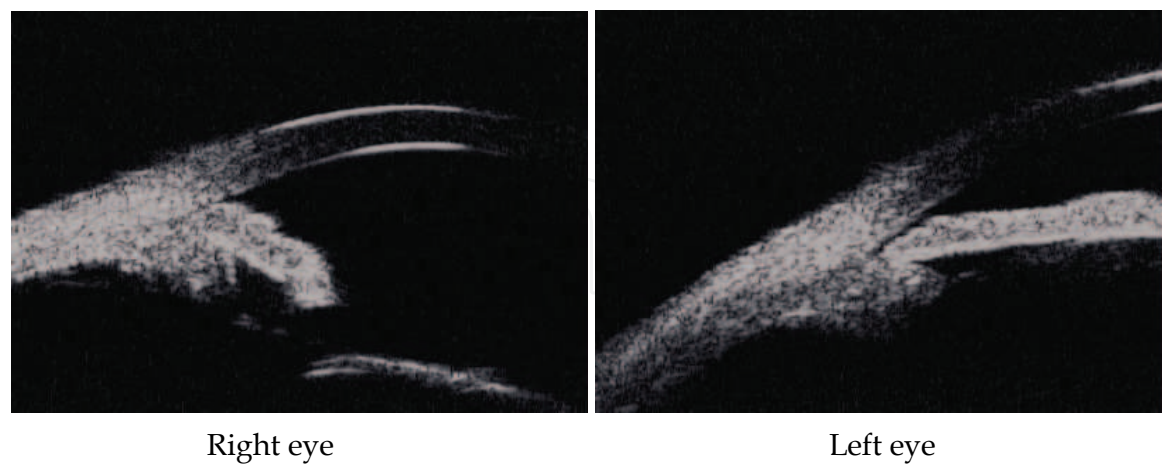


Fig. 3. Ultrasound biomicroscopy image of Figure 2

3. Diagnosis

3.1 Gonioscopic findings

Generally, the diagnosis of a plateau iris configuration is based on typical gonioscopic findings. A plateau iris configuration is defined as a flat iris plane accompanied by a narrow or closed anterior chamber angle. Some patients with a plateau iris configuration show an increased intraocular pressure after the pupils are dilated by angle closure even after laser iridotomy.

Indentation gonioscopy of eyes with a plateau iris configuration following patent iridotomy reveals a sine-shaped curve of the iris surface. Indentation presses the iris surface backward. The deepest point of indentation is not at the iris periphery, but at approximately two-thirds of the distance between the center of the pupil and the iris root. The iris rises again from this point to the site of appositional closure. This shape is called a double hump sign.




Fig. 4. Double hump sign after indentation



A double hump sign observed on indentation gonioscopy was strongly correlated with the presence of a plateau iris, and is, therefore a useful indicator of a plateau iris configuration. Therefore, a plateau iris configuration can be detected in many cases, without using a UBM (Kiuchi et al., 2009; Ritch, 1992).

### 3.2 Ultrasound biomicroscopy (UBM) findings

UBM provides detailed sub surface images of the angle region. This method showed that plateau iris configuration is caused by anteriorly located ciliary processes, which close the ciliary sulcus and provide support to the peripheral iris (Roberts et al., 2008). The ciliary processes were situated anteriorly in all the plateau iris configuration patients in comparison to the position in normal subjects and in patients with angle closure caused by pupillary block. The ciliary processes provide structural support beneath the peripheral iris, preventing the iris root from falling away from the trabecular meshwork after iridotomy (Pavlin et al., 1992).

Observation with a slit lamp causes miosis and thus the iris becomes thinner. An unintentional indentation and/or miosis induced by the slit-lamp light might prevent the identification of appositional angle closure during regular gonioscopic examination (Sakata et al., 2006). The importance of the diagnosis of plateau iris configuration by UBM resides in the fact that the plateau iris configuration can be detected without any interference from the effect of the lighting. Provocative tests were not usually helpful for detecting plateau iris syndrome (Ritch et al., 2009).

## 4. Gender and age

Women from Japan, Israel, Finland, and Thailand showed a consistently more frequent occurrence of PACG (Yamamoto et al., 2005). One study found no sexual predisposition for plateau iris configuration (Ritch, 1992). Others report that most patients with plateau iris were female and younger than those with pupillary block. The average age of the patients studied by Diniz et al. was 60.1 years old (Diniz et al., 2010). This is consistent with the results of the study by Mandell et al (Mandell et al., 2003), in which the plateau iris configuration patients averaged 57.5 years old.

Ritch, et al. evaluated the findings in patients 40 years of age or younger with angle closure. Sixty-seven patients (49 females, 18 males) met the entry criteria. Plateau iris configuration was found in 35 patients (52.2%) (Ritch et al., 2003).

On the other hand, the prevalence of PACG significantly increases with age in population based epidemiological studies (Yamamoto et al., 2005). Pupillary block angle closure is a disease of older persons, peaking in incidence between 55 and 70 years of age (Suzuki et al., 2008).

### 4.1 Prevalence of plateau iris configuration

Kumar et al. used standardized UBM criteria and found plateau iris in about one third of PACS eyes after laser iridotomy (Kumar et al., 2008, 2009). Mochizuki et al. conducted a study under the same criteria used by Kumar et al. to determine the prevalence of plateau iris configurations in acute angle-closure, chronic angle-closure glaucoma, and open-angle glaucoma eyes using ultrasound biomicroscopy. The study included fellow eyes from 27 acute angle-closure patients, 26 open-angle glaucoma patients, and 26 chronic angle-closure glaucoma patients with no history of acute angle-closure. Plateau iris configurations were

found in the opposite eyes of 10 (37.0%) of 27 patients with acute angle-closure, 9 (34.6%) of 26 patients with chronic angle-closure glaucoma, and 5 (19.2%) of 26 patients with open-angle glaucoma (Mochizuki et al., 2010). Filho also reported that plateau iris configuration in 10.2% of patients with open-angle glaucoma (Diniz Filho et al., 2010). The clinical significance of plateau iris configurations in open-angle glaucoma eyes is unclear. Open-angle glaucoma eyes do not have plateau iris configurations high enough to occlude the trabecular meshwork, which is associated with the elevation of IOP or other clinical events. However, lower plateau iris configuration may become higher over time due to increased thickness and anterior movement of the lens, which would consequently result in angle closure.

#### 4.2 Prevalence of plateau iris syndrome

Cases of recurrent angle-closure glaucoma after iridectomy, as a result of plateau iris syndrome are relatively rare. Plateau iris syndrome is believed to constitute a small percentage of eyes with plateau iris configuration. A study of eyes that had experienced angle-closure episodes was conducted to determine the relative frequency of plateau iris syndrome. All of the patients had undergone peripheral iridectomy. The IOP increased more than 8 mmHg after topical application of homatropine in 4 (6.2%) of the 65 eyes. Those 4 eyes were classified as the iris plateau type of angle -closure glaucoma (Godel et al., 1968). Saitoh reported that five of 50 iridectomized PACG eyes developed complete closure of the angle with an increase in the IOP exceeding 10 mmHg following the administration of homatropine which acts on the sphincter muscle located at the pupillary margin. However, those 5 subjects did not show IOP elevation after topical application of phenylephrine hydrochloride (alpha adrenergic stimulator). Phenylephrine acts on the iris dilator muscle which is located just above the iris pigment epithelium. Homatropine and phenylephrine act on different muscles in the iris, and the difference in the distribution of the dilator muscle and the sphincter muscle causes the different morphological changes in the iris after application of the midriatic agents. This may explain the difference in IOP response after dilation of pupil by midriatic agents (Saitoh, 1974).

#### 4.3 Biometrics of plateau iris configuration

Historically, plateau iris configuration is regarded as angle closure with normal anterior chamber depth and flat iris plane. Mandell et al. reported that all plateau iris configuration eyes showed biometric parameters that were completely different for those of normal eyes, except for the peripheral iris thickness at 500  $\mu$ m from the scleral spur. The eyes with plateau iris configuration showed a shallower anterior chamber depth than normal eyes (Mandell et al., 2003). The mean anterior chamber depth in patients with plateau iris syndrome ( $2.04 \pm 0.30$  mm) was significantly smaller than the hypothesized normal anterior chamber depth (3 mm). The mean anterior chamber depth in patients with pupillary block ( $2.17 \pm 0.30$  mm) was also significantly smaller than the hypothesized normal anterior chamber depth. Although a review of the literature suggested that patients with plateau iris had a normal or deeper axial anterior chamber depth in comparison to those with pupillary block, the mean anterior chamber depth in patients with plateau iris syndrome was significantly smaller than the anterior chamber depth in patients with pupillary block in the report by Mandell et al (Mandell et al., 2003).

There is one more report related to the biometrics of plateau iris configuration. Kiuchi et al. reported that patients with plateau iris configuration had deeper anterior chamber and

longer axial length than chronic angle closure patients without plateau iris configuration (Kiuchi et al., 2009). Further study is necessary to clarify this issue.

#### **4.4 Changes in the biometrics of plateau iris configuration after intervention**

Palvin et al. used ultrasound biomicroscopy to image angles in the dark, in the light, and following pilocarpine administration to clarify factors that produce angle opening changes in this syndrome. Changes in angle opening in dark and light were solely related to changes in iris thickness. Their results were consistent with the concept that the space between the ciliary processes and trabecular meshwork constitutes a passageway of fixed dimension. An increase in iris thickness resulted in a decrease in angle opening, and a decrease in iris thickness resulted in an increase in angle opening. Angle closure occurred if the iris thickness fills the space between the ciliary processes and the trabecular meshwork (Pavlin & Foster, 1999).

### **5. The cause of plateau iris configuration**

The cause of the plateau iris configuration is not known. The anomaly of the pars plicata position could be developmental or acquired. Ciliary processes develop during the 24<sup>th</sup> week of embryogenesis and initially overlap the trabecular meshwork but later recede to a position behind the scleral spur. This repositioning is thought to be due to a differential growth rate of the various tissue elements. The specific features of the ciliary processes in the eyes with plateau iris might be due to the failure of the ciliary processes to separate from the posterior iris surface. The displacement of the pars plicata from the peripheral iris to the iris root during embryogenesis may be incomplete in eyes with a shorter axial length. However, incomplete cleavage between the iris and ciliary body is unlikely (Razeghinejad & Kamali-Sarvestani, 2007; Tran et al., 2003).

Tran and associates (Tran et al., 2003) examined the anterior segments of 6 patients with plateau iris syndrome before and after cataract surgery. They found that irido-ciliary apposition persisted after extracapsular cataract extraction, thus indicating that the age related growth of the lens (i.e., acquired changes in the zonular fibers stretched by cataract formation) does not induce a reversible anterior pulling and or rotation of the ciliary body processes.

Etter investigated the prevalence of plateau iris syndrome in the first-degree relatives of patients affected with plateau iris syndrome. They found a high prevalence of plateau iris configuration in family members of patients with plateau iris syndrome. Five of the 10 participating patients (50%) were found to have at least 1 first-degree family member with plateau iris configuration. The presence of plateau iris configuration in successive generations, where there was not consanguineous marriage, therefore suggested that it might be inherited in an autosomal dominant manner with incomplete penetrance (Etter et al., 2006).

### **6. Differential diagnosis**

#### **6.1 Iris cyst**

Tanihara et al. reported a case of high, broad, peripheral anterior synechiae caused by multiple, bilateral iridociliary cysts. The peripheral anterior synechia extended to the corneal endothelium beyond Schwalbe's line. Ultrasound biomicroscopic imaging showed

that multiple, bilateral iridociliary cysts causes elevation of the iris structure (Tanihara et al., 1997). This report showed that an iris cyst could cause the pseudo-plateau configuration. The incidence and sector distribution of ciliary body cysts in normal subjects is not low. A UBM study conducted by Kunimatsu et al. showed that cysts were detected in 63 (54.3%) of the 116 subjects. The number and diameter of the cysts decreased with age. Gender and refractive error did not affect the incidence and distribution. A significant bilateral correlation was found in the number, incidence, and distribution of ciliary body cysts (Kunimatsu et al., 1999). There was a high prevalence of iris cysts in young subjects. Younger subjects with a bumpy peripheral iris have a higher likelihood of a diagnosis of pseudo-plateau iris (Shukla et al., 2008).

## 6.2 Others

Any disorder that causes swelling of the ciliary body or forward rotation of the ciliary body can create a pseudo-plateau iris configuration. Sulfa based compounds like hydrochlorothiazide, oral acetazolamide, supra ciliary effusions and ciliary body thickening after scleral buckling procedures can cause ciliary swelling and precipitate angle closure glaucoma. (Geason & Perkins, 1995; Palvin et al., 1997; Tripathi et al., 2003)

## 7. Management

### 7.1 Miotics

Miotic therapy is one option for plateau iris configuration. One drop of pilocarpine causes significant changes in the anterior eye segment morphology. This decreases the pupillary diameter and the iris thickness (Németh et al., 1996-1997). A single drop of 2% pilocarpine is an effective agent for thinning the iris and opening the angle in plateau iris syndrome. The ability to visualize the degree of angle opening produced by pilocarpine can be helpful in predicting the efficacy of this therapy (Pavlin and Foster, 1999). There are two problems associated with pilocarpine treatment for glaucoma associated with plateau iris configuration. Most patients are relatively young in age in comparison to the usual angle-closure glaucoma patients, and therefore, are unhappy with pilocarpine-induced myopia and miosis. These side effects may decrease the compliance (adherence) to the medical therapy.

Yasuda et al. examined the long-term effects of topical pilocarpine on IOP control in primary angle-closure glaucoma without iridectomy. Six (43%) out of 14 eyes with acute PACG under topical pilocarpine therapy had re-attacks while one eye (7%) developed increased IOP. Twelve of 47 fellow eyes of patients with acute PACG (26%) developed acute attacks while 3 eyes (6%) showed increased IOP. They concluded that long-term medical therapy for PACG is unsatisfactory. A single drop of pilocarpine works only for 6 hours. Short acting duration of pilocarpine and poor compliance (adherence) may play some role in this result. They included all types of angle closure glaucoma in their study. Patients with plateau iris configuration might yield the same results (Yasuda & Kageyama, 1988).

### 7.2 Laser treatment

#### 7.2.1 Laser iridotomy

Laser iridotomy (LI) is the appropriate treatment for angle closure glaucoma due to primary pupillary block. UBM studies in patients with pupillary block glaucoma post-LI



demonstrated substantial increases in the anterior chamber angle aperture following laser iridotomy. Previous studies have also shown that in eyes with an acute attack, the angle widened in the first 2 weeks after LI, but did not change thereafter over 1 year, and the amount of peripheral anterior synechia (PAS) remained stable throughout. The results indicate the effectiveness of LI in preventing progressive closure of the angle in the first year after the angle closure attack (Porikoff et al., 2005). However, laser iridotomy is insufficient to treat glaucoma associated with plateau iris. Many patients with a patent iridotomy hole experienced acute angle-closed attacks. Polikoff et al. also examined the effect of laser iridotomy on anterior segment anatomy of patients with plateau iris configuration. Iridotomy will remove any contribution from pupillary block in these patients, but the angle will remain narrow because the anteriorly positioned ciliary processes prevent the peripheral iris from moving posteriorly. This report also showed that pupil block and plateau iris configuration coexists in many cases (Polikoff et al., 2005). Approximately one of three of the eyes showed PAS progression during a 3-year follow-up period after LI. The probability of progression was found to be high in the eyes that exhibited plateau iris (Choi & Kim, 2005). These data show that laser iridotomy alone is not an effective treatment for glaucoma with plateau iris configuration.

### **7.2.2 Argon laser peripheral iridoplasty**

Argon laser peripheral iridoplasty can effectively eliminate residual appositional closure after laser iridotomy caused by plateau iris syndrome, and the effect is maintained for years. Argon laser iridoplasty may also prove valuable in the treatment of plateau-like iris configuration resulting from iridociliary cysts (Crowston et al., 2005). Rich et al. documented the long-term effect of argon laser iridoplasty in patients with plateau iris syndrome. A total of 26 argon laser iridoplasty procedures were performed in 23 eyes of 14 patients. The angle remained open in 20 of 23 (87.0%) eyes after only 1 treatment with Argon laser iridoplasty over a follow-up period of  $78.9 \pm 8.0$  months (range, 72–188 months). They concluded that Argon laser iridoplasty could effectively eliminate residual appositional closure after laser iridotomy caused by plateau iris syndrome (Ritch et al., 2004). However, there are no other reports that indicate the effectiveness of laser peripheral iridoplasty.

### **7.2.3 Cataract surgery**

Hayashi showed that the anterior chamber depth and angle width in angle closure glaucoma eyes approximates that of POAG eyes and control eyes without glaucoma after phaco-emulsification and posterior chamber intraocular lens implantation (Hayashi et al., 2000). They thought that these changes contribute to the significant IOP reduction seen in the postoperative follow-up period of 12 months. Tran et al. evaluated the ultrasound biomicroscopic appearance of the anterior segment before and after cataract extraction in eyes with plateau iris syndrome. None of the six eyes with plateau iris syndrome in their study showed a change in the configuration of the ciliary body after IOL implantation. However, the anterior chamber depth increased and the angle opened further after cataract surgery. The persistent iridociliary apposition after cataract surgery suggests that the iris and pars plicata appear to move together (Tran et al., 2003). Nonaka et al. reported cataract surgery for angle closure including plateau configuration opened the angle concomitant with attenuation of the anterior positioning of the ciliary processes. Cataract surgery would contribute to postoperative widening of the angle not only by completely removing the lens

volume and pupillary block, but also by attenuating the anterior positioning of the ciliary processes in eyes with primary angle closed eyes (Nonaka et al., 2006). There are currently no randomized controlled trials supporting the use of clear lens extraction as the treatment of choice for PACG. However, the potential of obtaining some benefit from this procedure is considered to be biologically plausible (Thomas et al., 2011).

Phacoemulsification and goniosynechialysis (PEGs) is also effective in managing acute and subacute primary angle closure including patients plateau iris (Harasymowycz et al., 2005). Topical application of miotic agents, laser peripheral iridoplasty and cataract surgery seem to be effective for glaucoma with plateau iris configuration. There is a lack of well-designed, randomized, controlled trials to assess the effect as a therapeutic modality for glaucoma with plateau iris configuration, because the occurrence of plateau iris is relatively rare.

## 8. Conclusions

A plateau iris configuration is defined as a flat iris plane accompanied by a narrow or closed anterior chamber angle. Pathological and physiological data of plateau iris configuration and plateau iris syndrome are increasing. However, we do not have enough information related to plateau iris configuration and syndrome to manage them. The prognosis of this disorder compared to pupillary block angle closure glaucoma also remains to be elucidated. There are no quantitative diagnosis criteria, yet. This condition confuse the interpretation of the data appeared at the journals. The best therapeutic protocol should be established in future. New imaging technology will help us to obtain the new information.

## 9. References

- Choi, JS. & Kim, YY. (2005). Progression of peripheral anterior synechiae after laser iridotomy., *American Journal of Ophthalmology*, Vol.140, No.6, (2005), pp.1125–1127
- Congdon, N., Wang, F., & Tielsch, JM. (1992). Issues in the epidemiology and population-based screening of primary angle-closure glaucoma, *Survey of Ophthalmology*, Vol.36, No.11, (1992), pp.411–423
- Crowston, JG., Medeiros, FA. Mosaed, S., & Weinreb, RN. (2005). Argon laser iridoplasty in the treatment of plateau-like iris configuration as result of numerous ciliary body cysts, *American Journal of Ophthalmology*, Vol.139, No.2, (2005), pp.381–383
- Diniz Filho, A., Cronemberger, S., Ferreira, DM., Mérula, RV., & Calixto, N. (2010). Plateau iris configuration in eyes with narrow-angle: an ultrasound biomicroscopic study, *Arquivos brasileiros de oftalmologia*, Vol.73, No.2, (2010), pp.155-160
- Etter, JR., Affel, EL., & Rhee, DJ. (2006). High prevalence of plateau iris configuration in family members of patients with plateau iris syndrome, *Journal of Glaucoma*, Vol.15, No.5 (2006), pp.394–398
- Foster, PJ., Baasanhu, J., Alsbirk, PH., Munkhbayar, D., Uranchimeg, D., & Johnson, J. (1996). Glaucoma in Mongolia: a population-based survey in Hovsgol province, northern Mongolia, *Archives of Ophthalmology*, Vol.114, No.10, (1996), pp.1235–1241
- Foster, PJ. & Johnson, GJ. (2001). Glaucoma in China: how big is the problem?, *British Journal of Ophthalmology*, Vol.85, No.11, (2001), pp.1277–1282
- Geanon, JD. & Perkins, TW.(1995). Bilateral acute angle-closure glaucoma associated with drug sensitivity to hydrochlorothiazide, *Archives of Ophthalmology*, Vol.113, No.10, (1995), pp.1231–1232


- Godel, V., Stein, R., & Feiler-Ofry, V. (1968). Angle-closure glaucoma: following peripheral iridectomy and mydriasis, *American Journal of Ophthalmology*, Vol.65, No.4, (1968), pp.555-560
- Gradle, HS. & Sugar, HS. (1940). Concerning the chamber angle. III. A clinical method of goniometry, *American Journal of Ophthalmology*, Vol.23, (1940), pp.1135-1139
- Harasymowycz, PJ., Papamatheakis, DG., Ahmed, I., Assalian, A., Lesk, M., Al-Zafiri, Y., Kranemann, C., & Hutnik, C. (2005). Phacoemulsification and goniosynechialysis in the management of unresponsive primary angle closure, *Journal of Glaucoma*, (2005), pp.186-189
- Hayashi, K., Hayashi, H., Nakao, F., & Hayashi, F. (2000). Changes in anterior chamber angle width and depth after intraocular lens implantation in eyes with glaucoma, *Ophthalmology*, Vol.107, No.4, (2000), pp.698-703
- Kiuchi, Y., Kanamoto, T., & Nakamura, T. (2009). Double hump sign in indentation gonioscopy is correlated with presence of plateau iris configuration regardless of patent iridotomy, *Journal of Glaucoma*, Vol.18, No.2, (2009), pp.161-164
- Kumar, RS., Baskaran, M., Chew, PT., Friedman, DS., Handa, S., Lavanya, R., Sakata, LM., Wong, HT., & Aung, T. (2008). Prevalence of plateau iris in primary angle closure suspects an ultrasound biomicroscopy study, *Ophthalmology*, Vol.115, No.3, (2008), pp.430-434
- Kumar, RS., Tantisevi, V., Wong, MH., Laohapojanart, K., Chansanti, O., Quek, DT., Koh, VT., MohanRam, LS., Lee, KY., Rojanapongpun, P., & Aung, T. (2009). Plateau iris in Asian subjects with primary angle closure glaucoma, *Archives of Ophthalmology*, Vol.127, No.10, (2009), pp.1269-1272
- Kunimatsu, S., Araie, M., Ohara, K., & Hamada, C. (1999). Ultrasound biomicroscopy of ciliary body cysts, *American Journal of Ophthalmology*, Vol.127, No.1, (1999), pp.48-55
- Lim, LS., Aung, T., Husain, R., Wu, YJ., Gazzard, G., & Seah, SK. (2004). Acute primary angle closure: configuration of the drainage angle in the first year after laser peripheral iridotomy, *Ophthalmology*, Vol.111, No.8, (2004), pp.1470-1474
- Lowe, RF. (1964). Primary angle-closure glaucoma. Investigation after surgery for pupil block, *American Journal of Ophthalmology*, Vol.57, (1964), pp.931-938
- Mandell, MA., Pavlin, CJ., Weisbrod, DJ., & Simpson, ER. (2003). Anterior Chamber Depth in Plateau Iris Syndrome and Pupillary Block as Measured by Ultrasound Biomicroscopy, *American Journal of Ophthalmology*, Vol.136, No.5, (2003), pp.900-903
- Mochizuki, H., Takenaka, J., Sugimoto, Y., Takamatsu, M., & Kiuchi, Y. (2010). Comparison of the Prevalence of Plateau Iris Configurations Between Angle-closure Glaucoma and Open-angle Glaucoma Using Ultrasound Biomicroscopy, *Journal of Glaucoma*, (2010)
- Németh, J., Csákány, B., & Pereg, T. (1996-1997). Ultrasound biomicroscopic morphometry of the anterior eye segment before and after one drop of pilocarpine, *International Ophthalmology*, Vol.20, No.1-3, (1996-1997), pp.39-42
- Nonaka, A., Kondo, T., Kikuchi, M., Yamashiro, K., Fujihara, M., Iwawaki, T., Yamamoto, K., & Kurimoto, Y. (2006). Angle widening and alteration of ciliary process configuration after cataract surgery for primary angle closure. *Ophthalmology*, Vol.113, No.3, (2006), pp.437-441

- Pavlin, CJ & Foster, FS. (1999). Plateau iris syndrome: changes in angle opening associated with dark, light, and pilocarpine administration, *American Journal of Ophthalmology*, Vol.128, No.3, (1999), pp.288-291
- Pavlin, CJ., Ritch R., & Foster, FS. (1992). Ultrasound biomicroscopy in plateau iris syndrome, *American Journal of Ophthalmology*, Vol.113, No. 4, (1992), pp.390-395
- Pavlin, CJ., Rutnin, SS., Deveny R., Wand, M. & Foster, FS. (1997). Supraciliary effusions and ciliary body thickening after scleral buckling procedures, *Ophthalmology*, Vol.104, No. 3, (1997), pp.433-438
- Polikoff, LA., Channis, RA., Toor, A., Ramos-Esteban, JC., Fahim, MM., Gagliuso, DJ., & Serle, JB. (2005). The effect of laser iridotomy on the anterior segment anatomy of patients with plateau iris configuration, *Journal of Glaucoma*, Vol.14, No.2, (2005), pp.109-113
- Quigley, HA., Congdon, NG., & Friedman, DG. (2001). Glaucoma in China (and worldwide): changes in established thinking will decrease preventable blindness, *British Journal of Ophthalmology*, Vol.85, No.11, (2001), pp.1271-1272
- Razeghinejad, MR. & Kamali-Sarvestani, E. (2007). The plateau iris component of primary angle closure glaucoma: developmental or acquired, *Medical Hypotheses*, Vol. 69, No.31, (2007), pp.95-98
- Ritch, R. (1992). Plateau iris is caused by abnormally positioned ciliary processes, *Journal of Glaucoma*, Vol.1, (1992), pp.23-26
- Ritch, R., Aung, T., & Lam, DS. (2009). Angle-closure Glaucoma, *Journal of Glaucoma*, Vol.18, No.7, (2009), pp.567-570
- Ritch, R., Chang, BM., & Liebmann, JM. (2003). Angle closure in younger patients, *Ophthalmology*, Vol.110, No.10, (2003), pp.1880-1889
- Ritch, R., Tham, CC., & Lam DS (2004). Long-term success of argon laser peripheral iridoplasty in the management of plateau iris syndrome, *Ophthalmology*, Vol.111, No.1, (2004), pp.104-108
- Roberts, DK., Ayyagari, R., & Moroi, SE. (2008). Possible association between long anterior lens zonules and plateau iris configuration, *Journal of Glaucoma*, Vol.17, No.5, (2008), pp.393-396
- Saitoh, S. (1974). Midriasis test in primary angle-closure glaucoma, *Nippon Ganka Gakkai Zasshi*, Vol.78, No.11, (1974), pp.1179-1185
- Sakata, LM., Sakata, K., & Susanna, R Jr. (2006). Long ciliary processes with no ciliary sulcus and appositional angle closure assessed by ultrasound biomicroscopy, *Journal of Glaucoma*, Vol. 15, No.5, (2006), pp.371-379
- Shaffer, RN. (1960). Primary Glaucomas. Gonioscopy, ophthalmoscopy and perimetry, *Transactions - American Academy of Ophthalmology and Otolaryngology*, Vol.64, (1960), pp.112-127
- Shukla, S., Damji, KF., Harasymowycz, P., Chialant, D., Kent, JS., Chevrier, R., Buhrmann, R., Marshall, D., Pan, Y., & Hodge, W. (2008). Clinical features distinguishing angle closure from pseudoplateau versus plateau iris, *British Journal of Ophthalmology*, Vol. 92, No.3, (2008), pp.340-344
- Suzuki, Y., Yamamoto, T., Araie, M., Iwase, A., Tomidokoro, A., Abe, H., Shirato, S., Kuwayama, Y., Mishima, HK., Shimizu, H., Tomita, G., Inoue, Y., & Kitazawa, Y. (2008). Tajimi Study review, *Nippon Ganka Gakkai Zasshi*, Vol.112, No.12, (2008), pp.1039-1058



- Tanihara, H., Akita, J., Honjo, M., & Honda, Y. (1997). Angle closure caused by multiple bilateral iridociliary cysts, *Acta ophthalmologica Scandinavica*, Vol. 75, No.2, (1997), pp.216-217
- Tarongoy, P., Ho, CL., & Walton, DS. (2009). Angle-closure glaucoma: the role of the lens in the pathogenesis, prevention, and treatment, *Survey of Ophthalmology*, Vol.54, No. 2, (2009), pp.211-225
- Tran, HV., Liebmann, JM., & Ritch, R. (2003). Iridociliary apposition in plateau iris syndrome persists after cataract extraction, *American Journal of Ophthalmology*, Vol.135, No.1, (2003), pp.40-43
- Tripathi, RC., Tripathi, BJ., Haggerty C. (2003). Drug-induced glaucomas: mechanism and management, *Drug safety*, Vol. 26, No.11, (2003), pp.749-767
- Wand, M., Grant, WM., Simmons, RJ., & Hutchinson, BT. (1977). Plateau iris syndrome, *Transactions. Section on Ophthalmology. American Academy of Ophthalmology and Otolaryngology*, Vol. 83, No. 1, (1977), pp.122-130
- Yamamoto, T., Iwase, A., Araie, M., Suzuki, Y., Abe, H., & Shirato, S. (2005). The Tajimi Study report 2: prevalence of primary angle closure and secondary glaucoma in a Japanese population, *Ophthalmology*, Vol. 112, No.10,(2005), pp.1661-1669
- Yasuda, N. & Kageyama, M. (1988). The long-term effects of local medication on intraocular pressure control in primary angle-closure glaucoma, *Nippon Ganka Gakkai Zasshi*, Vol.92, No.10, (1988), pp.1644-1649

IntechOpen



## **Glaucoma - Basic and Clinical Concepts**

Edited by Dr Shimon Rumelt

ISBN 978-953-307-591-4

Hard cover, 590 pages

**Publisher** InTech

**Published online** 11, November, 2011

**Published in print edition** November, 2011

This book addresses the basic and clinical science of glaucomas, a group of diseases that affect the optic nerve and visual fields and is usually accompanied by increased intraocular pressure. The book incorporates the latest development as well as future perspectives in glaucoma, since it has expedited publication. It is aimed for specialists in glaucoma, researchers, general ophthalmologists and trainees to increase knowledge and encourage further progress in understanding and managing these complicated diseases.

### **How to reference**

In order to correctly reference this scholarly work, feel free to copy and paste the following:

Yoshiaki Kiuchi, Hideki Mochizuki and Kiyoshi Kusanagi (2011). Plateau Iris, Glaucoma - Basic and Clinical Concepts, Dr Shimon Rumelt (Ed.), ISBN: 978-953-307-591-4, InTech, Available from:  
<http://www.intechopen.com/books/glaucoma-basic-and-clinical-concepts/plateau-iris>

**INTech**  
open science | open minds

### **InTech Europe**

University Campus STeP Ri  
Slavka Krautzeka 83/A  
51000 Rijeka, Croatia  
Phone: +385 (51) 770 447  
Fax: +385 (51) 686 166  
[www.intechopen.com](http://www.intechopen.com)

### **InTech China**

Unit 405, Office Block, Hotel Equatorial Shanghai  
No.65, Yan An Road (West), Shanghai, 200040, China  
中国上海市延安西路65号上海国际贵都大饭店办公楼405单元  
Phone: +86-21-62489820  
Fax: +86-21-62489821

© 2011 The Author(s). Licensee IntechOpen. This is an open access article distributed under the terms of the [Creative Commons Attribution 3.0 License](https://creativecommons.org/licenses/by/3.0/), which permits unrestricted use, distribution, and reproduction in any medium, provided the original work is properly cited.

IntechOpen

IntechOpen