

We are IntechOpen, the world's leading publisher of Open Access books Built by scientists, for scientists

6,900

Open access books available

186,000

International authors and editors

200M

Downloads

Our authors are among the

154

Countries delivered to

TOP 1%

most cited scientists

12.2%

Contributors from top 500 universities



WEB OF SCIENCE™

Selection of our books indexed in the Book Citation Index
in Web of Science™ Core Collection (BKCI)

Interested in publishing with us?
Contact book.department@intechopen.com

Numbers displayed above are based on latest data collected.
For more information visit www.intechopen.com



Primary Angle Closure Glaucoma

Michael B. Rumelt

*Washington University Department of Ophthalmology and Visual Sciences
St. Louis, Missouri
USA*

1. Introduction

Glaucoma, a leading cause of blindness world wide, may be classified into two main types based on the anatomy of the anterior chamber angle: open angle, which is generally a chronic disease and narrow angle glaucoma, which can be an acute medical emergency. An acute primary angle closure glaucoma attack presents with a painful, inflamed eye, cloudy cornea, fixed mid dilated pupil, reduced vision, high intraocular pressure, and possibly nausea and vomiting. If not diagnosed or untreated promptly and appropriately, the attack can result in severe damage and possibly blindness.

2. Epidemiology

It is estimated that by 2020 in the United States 3 million persons will have glaucoma, approximately 10% to 16% will have narrow angle glaucoma. World wide by 2020 it is estimated almost 80 million persons will have glaucoma. Angle closure glaucoma accounts for as much as half of blindness from glaucoma cases in other nations (particularly Asian countries). Four million are bilaterally blind. (1)

Risk is higher older individuals, individuals with high hyperopic refractive error (2), and diabetes.

The ethnic risks for acute angle closure glaucoma is approximately 1 in 1000 for Caucasians (3-11), 1 in 100 for Hispanics and Asians (12-20); 2-4 in 100 for Inuits (21-23). Primary narrow angle closure glaucoma is three times more frequent in Caucasian females over age fifty, less frequent in African Americans or native Americans, and is very common in India with intumescent lenses a frequent component.

3. Genetics

Genetics may play a role in the genesis of primary angle closure glaucoma in some situations. Autosomal dominant nanophthalmos (NNO1) with high hyperopia and angle closure glaucoma (51) maps to chromosome 11. An autosomal recessive form of nanophthalmos has been found in an Amish-Mennonite family (NNO2) and analysis found the mutation to be a frameshift insertion, 1143C in the membrane frizzled-related protein (MFRP) gene is located at cytogene location (11q23.3) and encodes a member of the frizzled related proteins family, some of which may play a role in eye development.

Axenfeld–Rieger ocular dysgenesis is associated with mutations of the Human Pituitary Homeobox 2 (PITX2) and forkhead box C1 (FOXC1) genes (52).

3.1 Classification of angle closure glaucoma

A new definition and classification of angle closure glaucoma based on population and epidemiologic studies has been developed to allow comparison between the studies. It has the following types: Primary Angle closure suspect; Primary angle closure; Primary Angle closure glaucoma; Primary Acute Angle Closure Glaucoma Crisis attack. The term glaucoma is not applied unless there is glaucomatous optic nerve damage, characteristic visual field changes, and specific gonioscopic criteria. The terms chronic, intermittent, and subacute are eliminated.

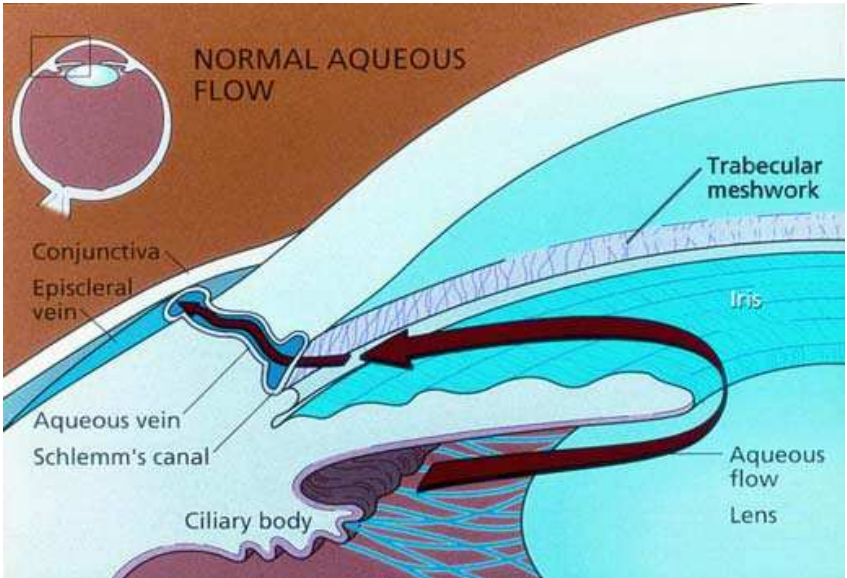


Fig. 1. Normal angle anatomy

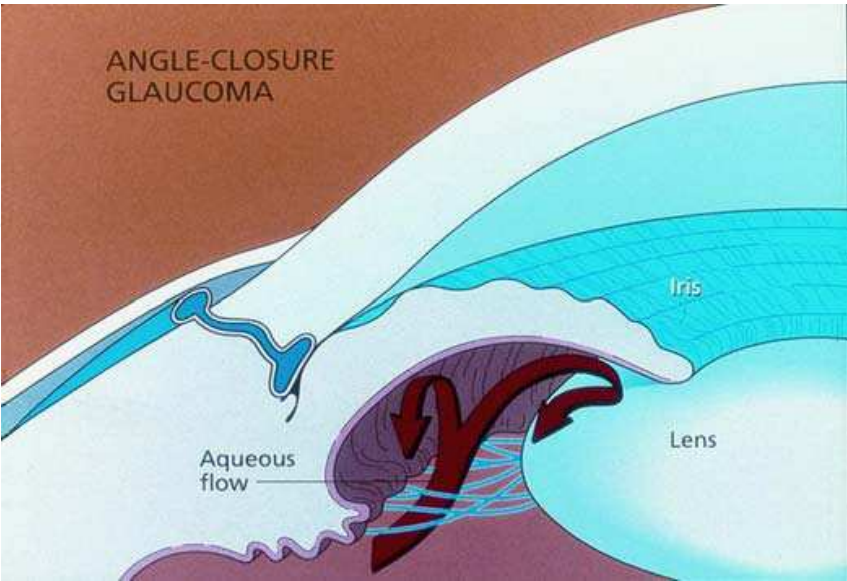


Fig. 2. Anatomy of primary angle closure glaucoma

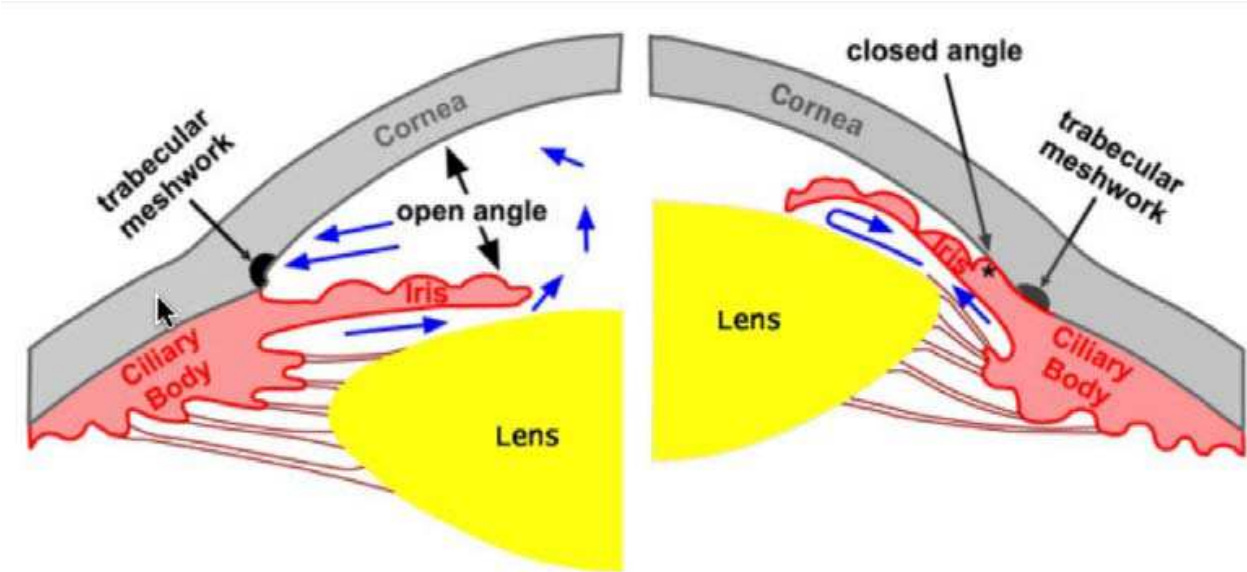


Fig. 3. The perheral iris in apposition to the trabecular meshwork blocking flow with an resultant increase intraocular pressure

3.2 Primary angle closure suspect

Anatomically narrow angles, normal IOP, absence of peripheral anterior synechiae, absence of glaucomatous optic neuropathy, and normal visual fields. (25) Patients should be warned of the symptoms of angle closure, drugs that may precipitate an attack, and the importance of a prompt evaluation by an ophthalmologist. They should be followed at appropriate intervals determined by the clinical expertise of the ophthalmologist, with gonioscopy and intraocular pressure monitoring performed at each visit, at least once a year. (56) If the patient is to be traveling to or living in a remote area where medical and/or ophthalmological may be unavailable for lengthy periods of time or transportaion may be delayed if an emergency arises, consideration of prophylactic laser peripheral iridotomies may be discussed with the patient (along with risks of the procedure).

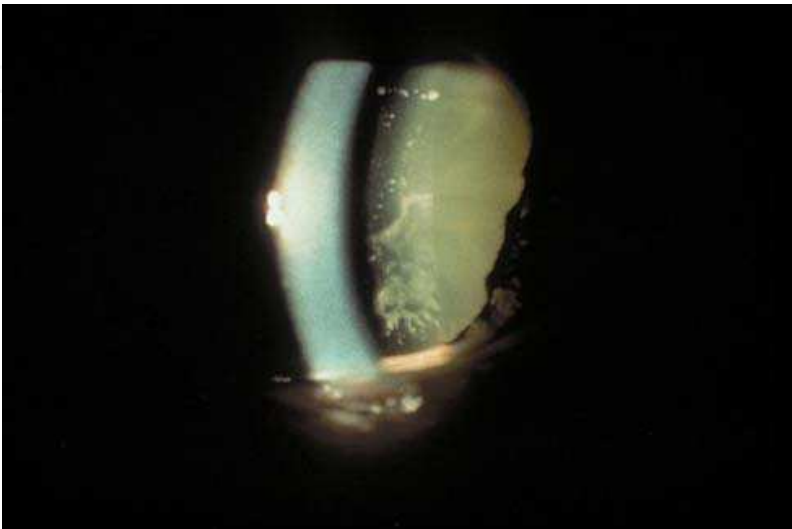


Fig. 4. Glauckomaflecken

Primary angle closure glaucoma: narrow angles, peripheral anterior synechiae, iris changes, glaucomaflecken, elevated intraocular pressure, excessive pigmentation in the trabeculum, no optic nerve damage, and normal visual fields. (26-28) They should be followed at least annually.

Primary angle closure glaucoma narrow angles, peripheral anterior synechiae, glaucomatous optic neuropathy, and characteristic visual findings. (29)

3.3 Primary acute angle closure glaucoma crisis attack presentation

About 10% of patients with closed angles present with acute angle closure crises characterized by sudden ocular pain, seeing halos around lights, red eye, very high intraocular pressure (>30 mmHg), nausea and vomiting, sudden decreased vision, and a fixed, mid-dilated pupil. Acute angle closure is an ocular emergency. Primary angle closure glaucoma occurs when the peripheral iris blocks the access of aqueous humor to the trabecular meshwork. Continued production of aqueous humor results in elevated intraocular pressure and damage to the nerve. In plateau iris, mild dilation of the pupil results in similar blockage of the angle. If not diagnosed promptly and treated appropriately, severe damage or blindness may result with either anatomical condition. (30)

An attack may present with headache and vomiting, and can be misdiagnosed as neurological or gastrointestinal in origin. If the attack occurs in a setting where either the patient can't communicate or an ophthalmologic consultation is unavailable or delayed, damage to the eye may be severe. Examples are demented patients in a nursing home, in post operative recovery, or the intensive care unit where the patient is sedated or receiving pain medication. Patients may choose self-diagnosis or treatment with over the counter medications to reduce healthcare costs and thus delay diagnosis and treatment.

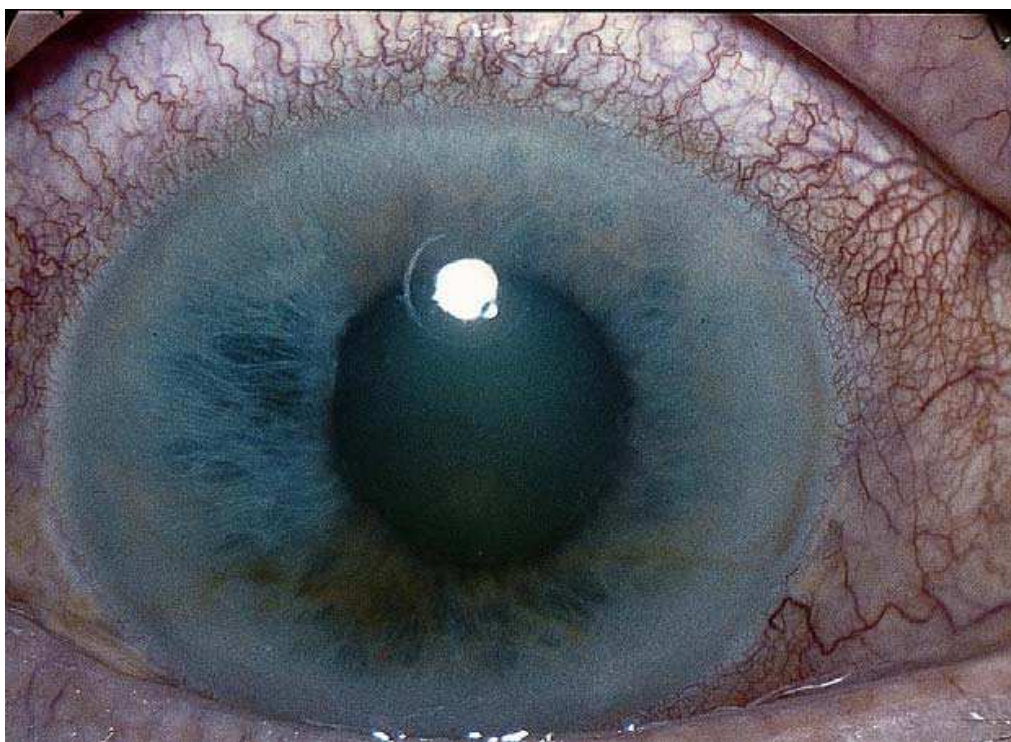


Fig. 5.

3.4 Example of a medical treatment regimen for acute primary angle closure glaucoma crisis attack

1. Topical brimonidine tartrate (Aphagan P®) x1 and timolol maleate-dorzolamidine HCL (Cosopt®) x1 (and an instruction for bid, unless there are contraindications).
2. IV acetazolamide (Diamox®) 500 mg (and an instruction for acetazolamide 250 mg tid).
3. PO glycerol 50% 100cc (1.5gr/kg) or isosorbide 25% for patients without diabetes mellitus.
4. In IOP below 60 mm Hg adding topical pilocarpine 2% x1.
5. IOP measurement after 30 min. If the IOP decreased, adding an instruction for pilocarpine 2% qid.
6. Massage with glass rod over the center of the cornea to force aqueous into the angle.
7. Analgesics and an antiemetic if necessary for pain and vomiting respectively up to every 4-6 hours.
8. Nd:YAG laser iridotomy in both eyes a day after. Adding topical apraclonidine (Iopidine®) 0.25% x1 and prednisolone acetate (Pred Forte®) qid for a week.
9. Indentation: it may be possible to break an attack by pressing with a four-mirror gonioscope lens, which may deepen the chamber angle and break peripheral anterior synechiae by hydraulic forces. Alternatively one may press firmly with a muscle hook or glass rod to accomplish the same goal: to flatten the cornea and compress aqueous humor into the anterior chamber angle to release fresh peripheral anterior synechiae. This may decrease the likelihood of developing chronic angle closure glaucoma.
10. Corneal edema may preclude gonioscopy and thus oral glycerin or topical glycerin may be useful in clearing the cornea.
11. The use of miotics like pilocarpine should be delayed until there is a drop in iop, generally less than 40 mm Hg so ischemia of the pupillary sphincter can resolve and the pupillary sphincter can function. Miotics may cause thickening of ciliary body and forward displacement of the ciliary body, thus worsening pupillary block but its use is still recommended.

If intervention is rapid enough, the attack may be broken and vision saved.

An attack that doesn't resolve may require filtering surgery, but operating on an inflamed eye with high intraocular pressure can be fraught with severe complications, including malignant glaucoma.

3.5 Etiology of angle closure

3.5.1 Primary angle closure

Pupillary block

Anatomically narrow angle: iris bombe, chronic progressive angle closure in which peripheral anterior synechiae gradually occlude the angle generally in an asymptomatic fashion and thus may be mis-diagnosed as open angle glaucoma if gonioscopy is omitted.

Ciliary block

Pan retinal photocoagulation can cause swelling of the ciliary body, scleral buckles, some drugs.

Plateau iris has a relatively deep mid anterior chamber with narrowing at the angle the severity of potential apposition or closure depending upon where the iris root inserts on the angle structures.

3.5.2 Secondary angle closure

Due to forces that pull the iris-lens diaphragm forward such as uveitis with iris bombe, diabetic neovascular glaucoma, forces pushing iris lens forward such as swollen lens, tumor, and malignant glaucoma following intraocular surgery. Malignant glaucoma first described by von Graefe (31) in 1869 in the classical form has elevated intraocular pressure, shallow or flat anterior chamber in the presence of a patent iridectomy. It occurs rarely after filtering surgery for angle closure glaucoma, with an incidence of 0.6 to 4%. The mechanism proposed is blockage of aqueous flow at the iris lens anterior vitreous face. Aqueous is misdirected into the vitreous cavity and displaces the iris-lens diaphragm forward resulting in shallow or flat anterior chamber. A newer theory (32) postulates that choroid expansion is involved. Many entities have been associated with malignant glaucoma: intraocular surgery, glaucoma drainage devices, various laser surgeries, (Neodymium-doped Yttrium Garnet) Nd:YAG cyclophotocoagulation, and other causes. Diagnosis is facilitated by Ultrasound BioMicroscopy). Treatment consists of phenylephrine to tighten zonules, topical beta-blockers, alpha agonists, and carbonic anhydrase inhibitors (topical and systemic) to reduce aqueous production. Prostaglandin analogues may be helpful by increasing uveoscleral outflow with reduction of intraocular pressure. If medical therapy fails, Nd:YAG laser might disrupt the vitreous face and allow normal flow of aqueous. If that fails, pars plana vitrectomy with or without lensectomy may disrupt the anterior vitreous face restoring normal flow. In pseudophakic patients, lens remnants should be removed and the vitreous face disrupted.

3.5.3 Secondary angle closure due to lens factors such as intumescent cataracts.

Drug induced angle closure glaucoma.

Anticholinergic are the most common for inducing "pupillary block" angle-closure glaucoma. Adrenergic agents, certain beta(2)-adrenergic agonists and anticholinergic agents may induce pupillary dilation and precipitate angle-closure glaucoma in susceptible patients: locally administered phenylephrine drops, nasal ephedrine, nebulized salbutamol or systemically administered (epinephrine for anaphylactic shock). Other drugs that can induce pupillary dilation and precipitate angle-closure glaucoma due to anticholinergic effects include tropicamide and atropine drops, tri and tetracyclic antidepressants, antihistamines, mydriatics, and phenothiazines. A novel anticholinergic form follows the use of periocular botulinum toxin diffusing back to the ciliary ganglion inhibiting the pupillary sphincter.

Sulfa based drugs (33) (acetazolamide, hydrochlorothiazide, cotrimoxazole, and topiramate (34)) induce "non-pupillary block" angle-closure glaucoma as an idiosyncratic reaction to the drug, cause swelling of the ciliary body with anterior rotation of the iris-lens diaphragm, and lead to the development of angle-closure glaucoma.

4. History of gonioscopy and concepts of angle closure glaucoma

In the modern eye clinic, the ease of use of the slit lamp microscope and various diagnostic contact lenses can lead one to take for granted the technological advance that each represents. Examination of the anterior chamber by gonioscopy, described in 1907, only became commonly used in the 1950's. It is instructive to learn about the history of gonioscopy and evolving understanding of the pathophysiology of angle closure. The work

of Dellaporta(36) provides an excellent review and source of much of the following information.

Until the middle of the twentieth century, glaucoma was classified into congestive and non-congestive. Treatment included bleeding, purging, leeches, counter-irritation and injecting mercury into an eye with chronic glaucoma to cause systemic inflammation, which would hopefully counteract the inflammation caused by glaucoma.

Herman von Helmholtz revolutionized the field of ophthalmology in 1851 with the invention of the ophthalmoscope.

Albrecht von Graefe noted in 1856 that scleral ectasias in glaucoma often became smaller after iridectomy. He deduced that IOP could be lowered by this procedure.

Examination of the anterior chamber angle dates back to 1875 when Alexios Trantas, a Greek ophthalmologist living in Istanbul until 1922 when he was forced to resettle in Athens due to political repression, was the first to examine the angle in a living person. In a 1907 presentation to the French Ophthalmological Society, he described his observations of the angle and his method, direct gonioscopy, that used digital pressure on the limbal area to indent the eye and allow visualization of the angle with a direct ophthalmoscope and a plus lens, power ranging from plus four to plus fourteen diopters. The term gonioscopy (which derives from the Greek and means observe the angle (36)) was first used by him, in the body of a paper (not the title) published in 1915 (35), but lost until after the end of the First World War.

Maximilian Salzmann's papers on gonioscopy and the angle, were published independently of Trantas in 1915. He tried direct ophthalmoscopy first but then found indirect ophthalmoscopy with a contact lens to be more satisfactory. He initially used Adolf Eugen Fick's scleral contact lens, first described in a paper published in 1888 (37). Salzmann later used a customized Zeiss scleral contact lens with a smaller diameter, that made gonioscopy easier.

In 1893 Theodor Leber (38-39) showed that the aqueous flows from the posterior chamber to the anterior chamber through the pupil. He and his collaborators injected various substances, including fine India ink, into the vitreous or anterior chamber of freshly enucleated eyes or those scheduled to undergo medically necessary enucleation and demonstrated the materials in the anterior chamber, iris, and Schlemm's canal.

The development of the slit lamp microscope by Zeiss in 1920 further advanced gonioscopy. Leonhard Koeppe examined patients sitting at the slit lamp with the contact lens he developed, held in position by a bandage, allowing viewing of the nasal and temporal aspects of the angle.

Later Karl Wolfgang Ascher examined patients in the supine position, and used the Koeppe lens, thus adding views of the superior and inferior angle. Ascher also identified episcleral veins near the limbus which carried clear fluid and when compressed with a small glass rod demonstrated the flow of aqueous from the anterior chamber into the blood vessels. He subsequently named them "aqueous veins".

In 1920, Edward James Curran described relative pupillary block and its treatment by peripheral iridectomy for the first time. Edward James Curran's observations were not accepted for many years.

Manuel Uribe Tronosco in 1925 invented a self illuminating monocular gonioscope (40), developed a version of the Koeppe lens made of polymethylmethacrylate rather than glass, and then a binocular microscope. In 1947 Edward James Curran published a book on gonioscopy.

Little progress was made until the 1936 publication of Otto Barkan's landmark paper, "On the Genesis of Glaucoma" (41), based on his observations made possible by modifications to the technique of gonioscopy, that allowed him to differentiate glaucoma into open angle and narrow angle glaucoma. His appreciation of the importance of pupillary block to angle closure glaucoma was a vital advance in gonioscopy and the understanding of the mechanism of glaucoma. Otto Barkan's ingenious innovation was to combine a handheld Zeiss binocular microscope suspended from the ceiling, an intensely bright source of illumination, the Koeppel lens, and finally the patient in a supine position. This process allowed great mobility, direct visualization of the entire angle, and manipulation of the eye. As important as Barkan's method of gonioscopy was, the widespread adoption by non glaucoma eye care specialists, was limited by the cumbersome details of the setup. Barkan also invented goniotomy for congenital glaucoma, facilitated by direct ophthalmoscopy using a special lens flattened on one edge to allow passage of a goniotomy knife

Because it was not efficient to apply direct gonioscopy to every patient, it became necessary to triage which patient would be examined. William van Herick (42) devised a method to identify patients with possibly narrow angles. He described positioning the slit beam at the temporal limbus angled sixty degrees to the side of the observer. If the space between the anterior iris stroma and the corneal endothelium was less than one fourth of the thickness of the cornea, those individuals would receive direct gonioscopy.

The development of the Goldmann indirect gonioscope lens (43), a contact lens incorporating one or more mirrors allowed examination of the entire angle with a patient seated before the slit lamp microscope. Two artifacts impact the utility of the lens: the requirement to use methylcellulose gel to eliminate air bubbles and if the lens was tilted, it could possibly indent the globe and falsely indicate a narrowing of the angle. The Koeppel lens won't indent the globe unless tilted and pressure applied, but with the patient in the supine position the chamber could deepen under the influence of gravity.

The development of the Zeiss 4-mirror and other similar lenses (44) which incorporated mirrors facilitated examination of the entire anterior chamber angle because these lenses were smaller in diameter than the cornea, used the tear film rather than methylcellulose to allow placement of the lens on the cornea, and had a handle which allowed indentation of the cornea to determine if apposition of the peripheral iris to the trabecular meshwork was permanent with synechiae or temporary and whether pressing with the contact lens could open the angle.

The technique of indenting the cornea was taught by Bernard Becker and Robert Moses at Washington University School of Medicine (45). Bernard Becker demonstrated the reduction of intraocular pressure by acetazolamide in 1954, a major advance in the treatment of glaucoma.

Glaucoma was officially divided into wide and narrow-angle types at the American Academy of Ophthalmology in 1948.

In the 1950s many advances in understanding angle closure glaucoma were made: Paul Chandler rediscovered Edward James Curran's work, and advanced the concept of pupillary block; Joseph Haas and Harold Scheie described angle opening after peripheral iridectomy and postulated resistance to the forward flow of aqueous lead to bowing of the peripheral iris; Otto Barkan supported Edward James Curran and Paul Chandler's concept; Chandler, Shaffer and Barkan described malignant glaucoma; and Tornquist described plateau iris.

Gerd Myer-Schwikerath in 1956 introduced Xenon photocoagulation of the iris but corneal and lens damage limited its use. It was replaced by laser iridotomies, first with the ruby, then with development of Argon and Neodymium-doped Yttrium aluminium garnet (ND:YAG) lasers. Iridectomy became noninvasive and moved from the operating room to the office.

The 1980's and 1990's saw the development of the concept of pupillary block, the concept of complete and incomplete plateau iris syndrome and the advent of laser iridoplasty, to shrink the peripheral iris to open the angle.

In the 2000's produced advances in instrumentation capable of non-contact anterior segment biometry: ultrasonic Biomicroscopy (UBM) (which does not require a clear cornea), ocular coherence tomography (OCT), and Pentascan using the Scheimpflug principle.

5. Examination of the angle to assess risk of closure

Gonioscopy

Because of total internal reflection of light, it is impossible to see angle structure and anatomy without other means. To overcome this problem, special contact lenses called gonioscopy lenses are utilized. The examiner must be careful not to incorrectly estimate angle depth when illumination passes through the pupil because miosis might deepen the angle.

Direct gonioscopy

One looks through a contact lens to the meridian of interest in the eye with a Koepple lens, requires methylcellulose, supine position, an assistant to hold lens in place with a q-tip, after the examination, vision may be blurred due to methylcellulose.

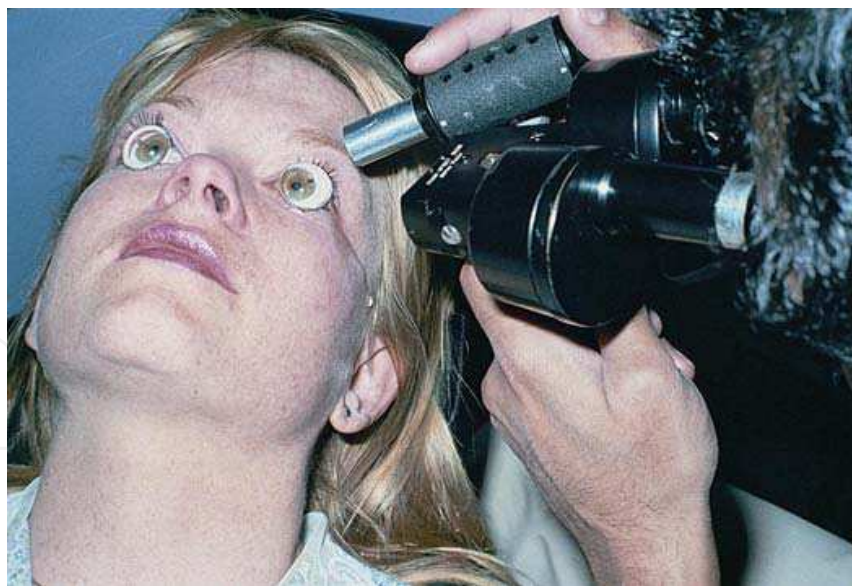

Fig. 6. Koepple lens, hand held illuminator, microscope, supine patient

Indirect gonioscopy

To see a particular meridian of the angle, a contact lens with a mirror or series of mirrors is used. Examination of the angle anatomy is done at the slit lamp with either a Zeiss four mirror gonioscopy lens or a Goldmann lens, which requires methylcellulose gel to eliminate air bubbles and can blur vision after the exam for a period of time. Goldmann lenses are

larger than the diameter of cornea and may be uncomfortable for the patient. Zeiss or Posner four mirror lenses do not require methylcellulose and rely on the tear film to allow placement of the lens without air bubbles. They have a smaller diameter compared to other type of contact lens and can be used to do indentation gonioscopy to determine if a narrowed angle can be opened or synechiae can be broken.

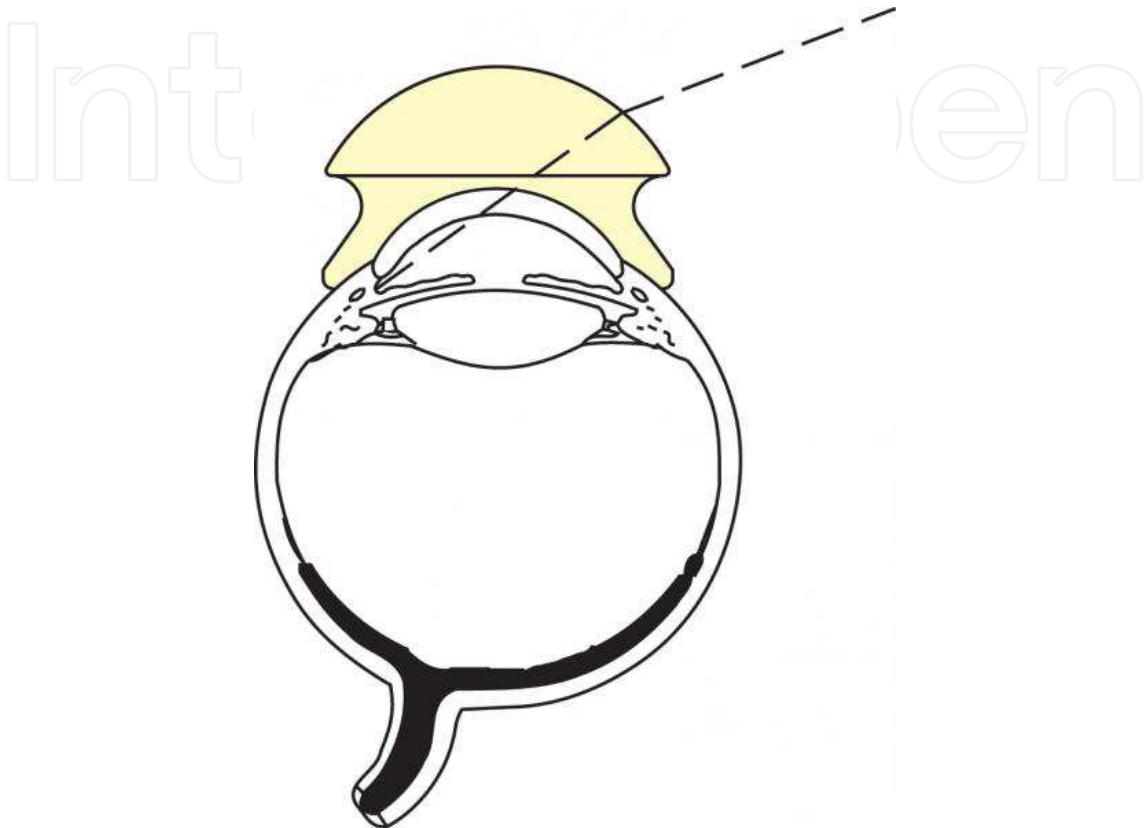


Fig. 7. Illustration of koeppe lens



Fig. 8. Mirror gonioscope lens

5.1 Grading the anterior chamber depth with gonioscopy

At the bedside with the flashlight test, a flashlight beam is directed parallel to the iris from the temporal side. If the crescentic iris shadow thus formed is less than half to one-third or no shadow the eye is considered to have a narrow angle and merit further examination.

At the slit lamp William van Herick’s (42) method of grading peripheral anterior chamber depth at the slit lamp consists of placing the slit beam at an angle of 60 degrees, just inside limbus, magnification 15, low to medium illumination, observe the space between corneal endothelium and front surface of iris. If the space (PAC) was less than one fourth of the thickness of the cornea (CT) the angle was considered possibly narrow and should be evaluated with gonioscopy.

Van Herick grading (42)

Grade 4 angle is wide open	PAC >CT
Grade 3 angle is narrow	PAC= 1/4 to 1/2 CT
Grade 2 angle dangerously narrow	PAC=1/4 CT
Grade 1 angle narrow or closed	PAC<CT

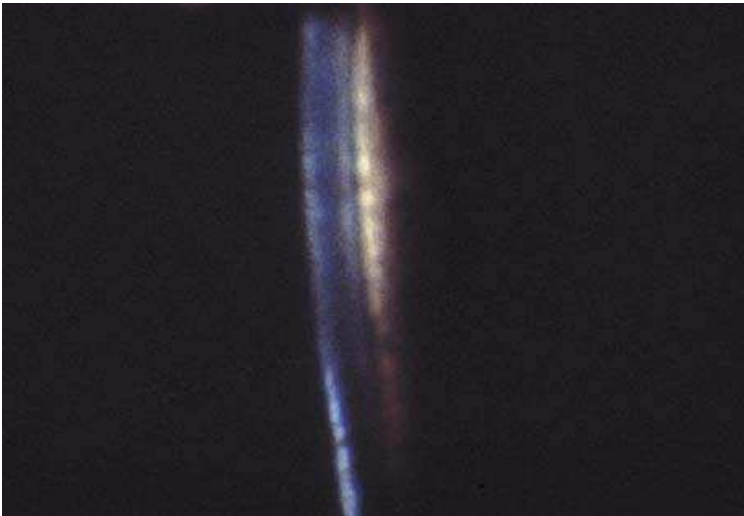


Fig. 9. Van Herick grade 1

Scheie grading (46)

Scheie proposed a grading system in which Roman numerals describe the degree of angle closure based upon the examiner’s visualization of the anterior chamber angle’s structures;

Grade I	all structures visible
Grade II	iris root visible
Grade III	posterior trabeculum obscured
Grade IV	only Schwalbe’s line visible

Shaffer grading (47)

Shaffer graded the angle of iris insertion with plane of trabecular meshwork:

Grade 4	45 to 35 degree angle	wide open
Grade 3	35 to 20 degree angle	wide open
Grade 2	20 degree angle	narrow
Grade 1	<10 degree angle	extremely narrow
Slit	0 degree angle	narrowed to slit

Shaffer grading system of depth of anterior chamber showing angle between iris and trabeculum

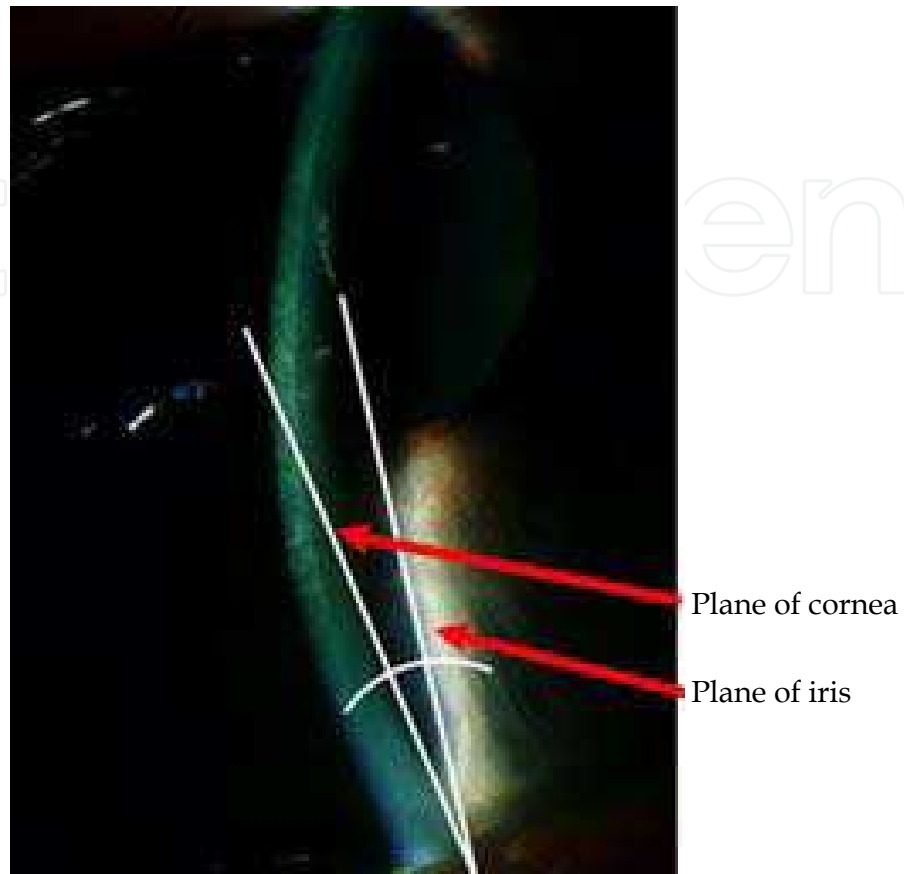


Fig. 10.

Spaeth's grading (48)

Spaeth's grading scheme is as follows

Iris insertion

- A anterior to Schwalbe's line
- B between Schwalbe's line and scleral spur
- C scleral spur visible
- D deep with ciliary body visible
- E very deep with >1 mm of ciliary body visible

Peripheral iris

- F flat
- B bowed anteriorly
- P plateau iris
- C concave

Pigmentation of trabecular meshwork

- 0 no pigment
- 1+ minimal
- 2+ mild
- 3+ moderate
- 4+ intense

Provocative testing such as dark room prone provocative testing is rarely utilized. A positive test is helpful, but a negative test does not guarantee that a particular individual with narrow angles will not suffer a future attack.

Optical coherence tomography of the anterior segment (OCT) is a non contact imaging system that can show detailed images of the anatomy including the anterior chamber angle. It can't acquire images behind the heavily pigmented posterior iris epithelium because the coherent light is absorbed by the iris pigment epithelium and thus may not be adequate for study of the ciliary body, zonules, posterior chamber, or anterior vitreous. The size of the pupil may be affected by ambient light and constrict falsely indicating a deeper chamber. The following illustration demonstrates crowding of the angle by peripheral iris with a dilated pupil.

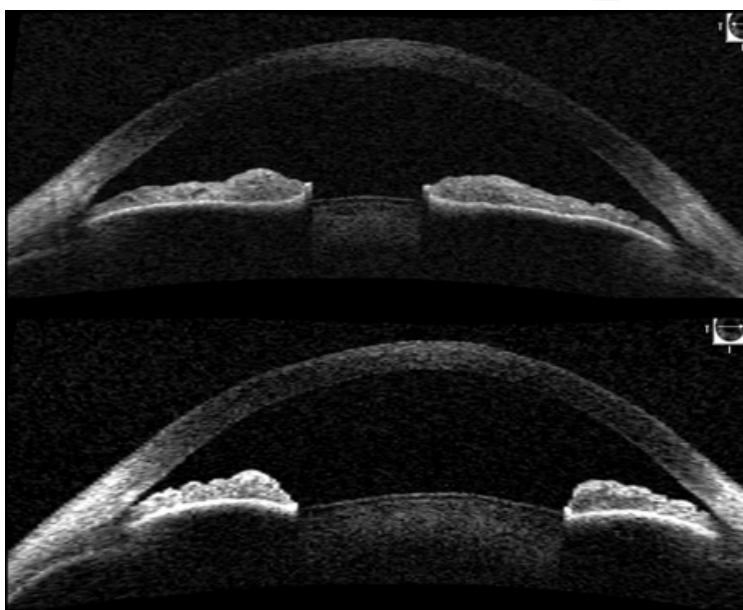


Fig. 11.

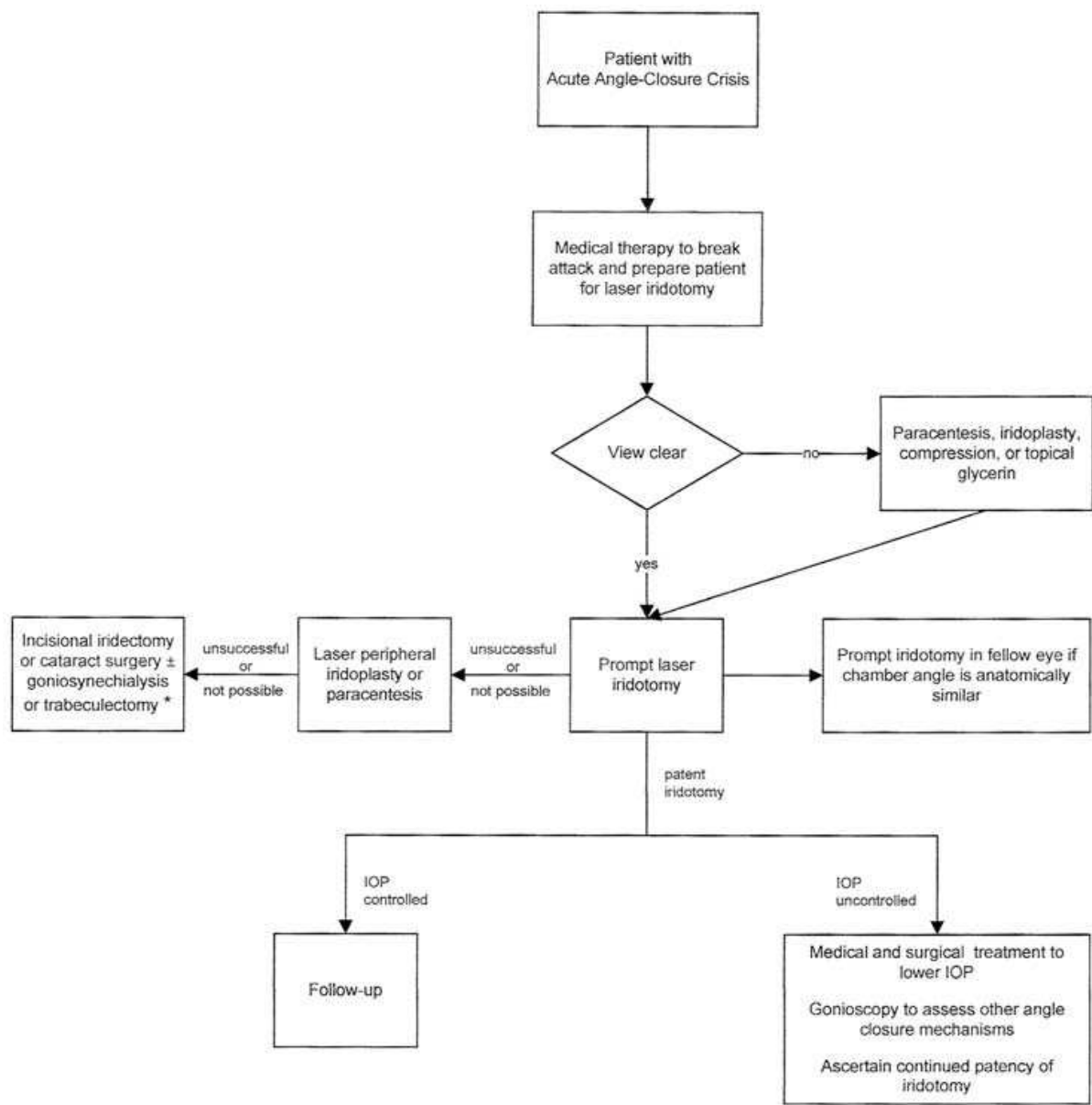
High resolution ultrasonography of the anterior segment, known as Ultrasound BioMicroscopy (UBM), is a contact imaging technique that can assess and display anterior chamber depth, configuration of the angle, lens position, iris thickness, and the ciliary body which may be thickened, rotated forward, have masses or cysts, or other anomalies presenting with angle closure in the presence of a cloudy cornea. UBM uses a higher frequency transducer (20-80 Mhz) than A-scan or B-scan (10 Mhz). Modifications in the system to apply the probe to the cornea eliminate the acoustic dead zone in front of the probe and allow the study to be performed sitting or supine.

Recent studies have suggested that increased iris thickness and cross-sectional area are associated with increased risk of angle closure glaucoma, there may be increased accumulation of proteins in iris in other cases. Another study comparing gonioscopy and UBM assessment of anterior chamber depth in Asian and Indian eyes found a very close correlation.

Central corneal thickness will affect Goldmann tonometry, since a thicker than “normal” cornea may be associated with a falsely higher pressure measurement and conversely measuring the intraocular pressure in a patient with a thinner cornea may underestimate the true intraocular pressure (49). A study comparing Pentacam Scheimpflug camera with

ultrasonic pachymetry and noncontact specular microscopy in measuring central corneal thickness showed the values obtained are similar but the methods are not interchangeable (50).

A-scan biometry of the axial length of the eye will reveal those eyes that are very short such as in nanophthalmos and at risk of angle closure glaucoma.



* Indicated for extensive synechial closure or optic nerve damage.

Fig. 12. Algorithm for the management of patients with acute angle-closure crisis American Academy of Ophthalmology preferred practice pattern 2010

6. Management of chronic angle-closure glaucoma (CACG)

The first step in the chronic angle-closure glaucoma (CACG) is often a surgical procedure to open up, as far as possible, those segments of the drainage angle that are appositionally

closed or narrow. Options may include laser peripheral iridotomy, argon laser peripheral iridoplasty, and lens extraction. Intraocular pressure (IOP) may, however, remain increased after these procedures, which may be the result of extensive residual synechial angle closure. IOP-lowering medications are indicated if a safe IOP level cannot be reached after angle-opening procedures. In the past, timolol and pilocarpine were extensively used in CACG. Once-daily prostaglandin analogue regimes are generally well tolerated by patients with CACG, and have become an important member in the medical arsenal against CACG. If the intraocular pressure remains elevated, or there is evidence of optic nerve damage, and/or significant visual field defects, then follow up intervals are similar to those when following an open angle glaucoma patient.

7. Medications available to treat elevated intraocular pressure

It is important to have a thorough knowledge of the patient's allergies, medical and surgical history, and a list of current medications to anticipate drug interactions or harmful side effects.

Alpha2-adrenergic receptor agonists: brimonidine tartrate 0.2%, 0.5%, 0.1% (Alphagan®, (Alphagan®P®), apraclonidine 0.5%, 1% (Iopidine®).

These medications may decrease IOP by reducing aqueous humor production and increase uveoscleral outflow.

The recommended dose is one drop of Alphagan®P® in the affected eye(s) twice daily, approximately 12 hours apart.

Use with precautions in coronary insufficiency, chronic renal failure, recent myocardial infarction, cerebrovascular disease, Raynaud disease, thromboangiitis obliterans, and patients with depression. A moderate risk of allergic response to this drug exists. Caution should be used in individuals who have developed an allergy to Iopidine. The brand Alphagan-P contains the preservative Purite and has been shown to be much better tolerated than its counterpart Alphagan. Coadministration with topical beta blockers may further decrease intraocular pressure; tricyclic antidepressants may decrease effects of brimonidine; CNS depressants such as barbiturates, opiates, and sedatives may potentiate effects of brimonidine. Contraindications if documented hypersensitivity and patients receiving Monoamine Oxidase Inhibitors inhibitors therapy.

Beta-adrenergic blocking agents: timolol maleate 0.25%, 0.5% (Timoptic® Timoptic-XE®, Betimol®, Istalol®), levobunolol 0.25%, 0.5% (Betagan®), carteolol 1% (Ocupress®).

Beta-adrenergic receptor antagonists decrease aqueous humor production by the ciliary body and possibly increased outflow.

Treatment can be initiated at one drop of 0.25% Timoptic® solution in each affected eye twice a day.

These medications may cause bradycardia, bronchospasm, obstructive pulmonary disease, cardiac failure, may contain sulfites and cause allergic reactions. Use with caution in patients with cerebrovascular insufficiency; in myasthenic syndromes, may potentiate muscle weakness; patients with an anaphylactic reaction may be unresponsive to usual dose of epinephrine. The product may cause depression, confusion, hallucinations, and psychosis, especially in the elderly. These effects may occur suddenly and are typically reversible upon discontinuation; some have sulfites, which may cause allergic-type reactions in susceptible patients. Punctal occlusion after dosing may reduce systemic absorption.

Topical carbonic anhydrase inhibitors: brinzolamide 1% (Azopt®) dorzolamide 2% (Trusopt®). Dosage is 1 drop in affected eye tid.

The mechanism of action is to reduce secretion of aqueous humor by inhibiting carbonic anhydrase in ciliary body, causing a decrease in intraocular pressure. May use concomitantly with other topical ophthalmic drug products to lower intraocular pressure. Local ocular adverse effects, primarily conjunctivitis and lid reactions may occur with chronic administration.

Systemic carbonic anhydrase inhibitors: acetazolamide 125mg, 250 mg tablet (Diamox®), 500mg extended release capsule (Diamox Sequels®); 25 mg, 50mg methazolamide (Neptazane®).

Dosage Acetazolamide tablet (Diamox®) dosage 250 mg tablet qDay/bid/tid/qid; (Diamox Sequels®) 500 mg po bid; 25, 50 mg Methazolamide (Neptazane®) dosage 50-100 mg po bid/tid.

Systemic absorption can affect carbonic anhydrase in the kidney, reducing hydrogen ion secretion at renal tubule, and increasing renal excretion of sodium, potassium bicarbonate, and water.

Systemic administration of carbonic anhydrase inhibitors may have potential serious side effects. They may decrease levels of lithium, alter excretion of amphetamines, quinidine, phenobarbital, and salicylates by alkalinizing urine. Derived chemically from sulfa drugs. Boxed warning: rare fatalities have occurred because of severe reactions to sulfonamides resulting in Stevens-Johnson syndrome, toxic epidermal necrolysis, fulminant hepatic necrosis, agranulocytosis, aplastic anemia, and other blood dyscrasias; reports of anorexia, tachypnea, lethargy, coma, and death with concomitant high-dose aspirin may cause substantial increase in blood glucose in some diabetic patients; may result in loss of potassium.

Miotic agents (parasympathomimetics): pilocarpine ophthalmic 0.5%, 1%, 2%, 4%, Gel; 4% (Isopto Carpine®, Pilopine HS Gel®).

Dosage is 1 gtt tid/qid, gel apply 0.5 inch ribbon in lower cul de sac q hs.

A naturally occurring alkaloid, pilocarpine mimics muscarinic effects of acetylcholine at postganglionic parasympathetic nerves, directly stimulate cholinergic receptors in the eye, decreasing resistance to aqueous humor outflow. Miotics cause the pupillary sphincter to contract, mechanically pulling the iris away from the trabecular meshwork and open the angle, and cause the ciliary muscle to contract increasing trabecular outflow. They may be ineffective when used concomitantly with nonsteroidal anti-inflammatory agents, are contraindicated with documented hypersensitivity and acute inflammatory disease of anterior chamber. In pregnancy, the risk to fetus not established or studied in humans but may be used if benefits outweigh risk to fetus. Use with caution in acute cardiac failure, peptic ulcer, hyperthyroidism, GI spasm, bronchial asthma, Parkinson disease, recent MI, urinary tract obstruction, and hypertension or hypotension.

Prostaglandin analogs: travoprost 0.004% (Travatan®, Travatan Z®), latanoprost 0.005% (Xalatan®), bimatoprost 0.01%, 0.03% (Lumigan®).

Dosage 1 gtt in affected eye a Day.

Exact mechanism of action unknown but believed to reduce IOP by increasing uveoscleral outflow. Another mechanism of action may be through induction of metalloproteinases in ciliary body, which breaks down extracellular matrix, thereby reducing resistance to outflow through ciliary body.

Commonly causes ocular hyperemia; may cause permanent increases in brown pigment in iris and eyelid; eyelash growth may increase; bacterial keratitis may occur; use with caution in uveitis or macular edema (Prostaglandins may aggravate or induce cystoid macular edema); do not instill if wearing contact lenses. Co-administration with eye drops, containing the preservative thimerosal, may reduce effects (administer at intervals of 5 min between applications. Contraindicated if there is documented hypersensitivity; signs of inflammation. Use with caution in pregnant patients.

Topical hyperosmotic agents: glycerin (Ophthalgan®) One or two drops of applied to the cornea prior to gonioscopy may facilitate gonioscopy by clearing corneal edema.

Systemic hyperosmotic agents: mannitol (Osmitol®), Ismotiv® (isosorbide) Solution 45% w/v, glycerin (Osmoglyn®)

Prior to intravenous administration, assess for adequate renal function in adults by administering a test dose of 200 mg/kg IV over 3-5 min. Should produce a urine flow of at least 30-50 mL/h of urine over 2-3 h. If safe to administer, then administer 1.5-2 g/kg body weight IV over 30-60 minutes;

Isosorbide 45% solution, (Ismotiv®) oral dosage 1-2 gm/kg body weight (55);

Glycerin (Osmoglyn®) oral dosage 1 ml/kg body weight (55).

Osmotic agents lower IOP by creating an osmotic gradient between ocular fluids and plasma.

Assess for adequate renal function in adults or children. Carefully evaluate cardiovascular status before rapid administration of mannitol since a sudden increase in extracellular fluid may lead to fulminating congestive heart failure; If blood is given simultaneously with mannitol, add at least 20 mEq of sodium chloride to each liter of mannitol solution to avoid pseudoagglutination. Consultation with specialists in internal medicine is strongly advised.

8. Neuroprotective agents

The use of neuroprotective agents may facilitate recovery of function or at least attenuation of damage. The results of studies of brimonidine and memantidine as potential neuroprotective agents are encouraging (54).

9. Surgical treatment

Surgical treatment may consist of laser iridotomies, laser iridoplasties to shrink the peripheral plateau iris, surgical iridectomies, and filtering procedures.

Argon laser peripheral iridotomy in eyes with light blue or green irides includes the following steps. After informed consent is obtained, Topical anesthetic (proparacaine 0.5%), topical alpha-agonist (apraclonidine or brimonidine), and pilocarpine 1% are placed on the eye. To perform laser peripheral iridotomy (LPI). Either the Abraham lens or equivalent lens, is placed on the cornea with the magnifying bubble rotated to an upper nasal position and the patient instructed to fixate with the opposite on an appropriate target. The lenses stabilize the eye, act as a speculum, reduce power due to the magnifying portion of the lens, and absorb heat to reduce the chances of burning of the cornea. The location of the treatment should be upper and nasal near the arcus sinelid in a spot where the iris appears thinner, such as an iris crypt. By placing the spot thusly, one may avoid annoying optical effects due to light entering the iridotomy, a rare occurrence requiring a large iridotomy opening or extremely observant patient. Suggested starting settings for the Argon laser are as follows:

Spot size - 50 mm Duration - 0.03-0.04 seconds Power - 900 mW. These may be adjusted depending on iris color and thickness of the iris stroma. Each surgeon should determine appropriate parameters for each clinical situation and adjust them accordingly. Prednisolone acetate 1% is started (4 times a day for 5-7 d). Follow up examination is in one hour to avoid missing any spike in intraocular pressure, which must be treated appropriately. The patient is seen in one week, one month, then at three to six months, then at least annually.

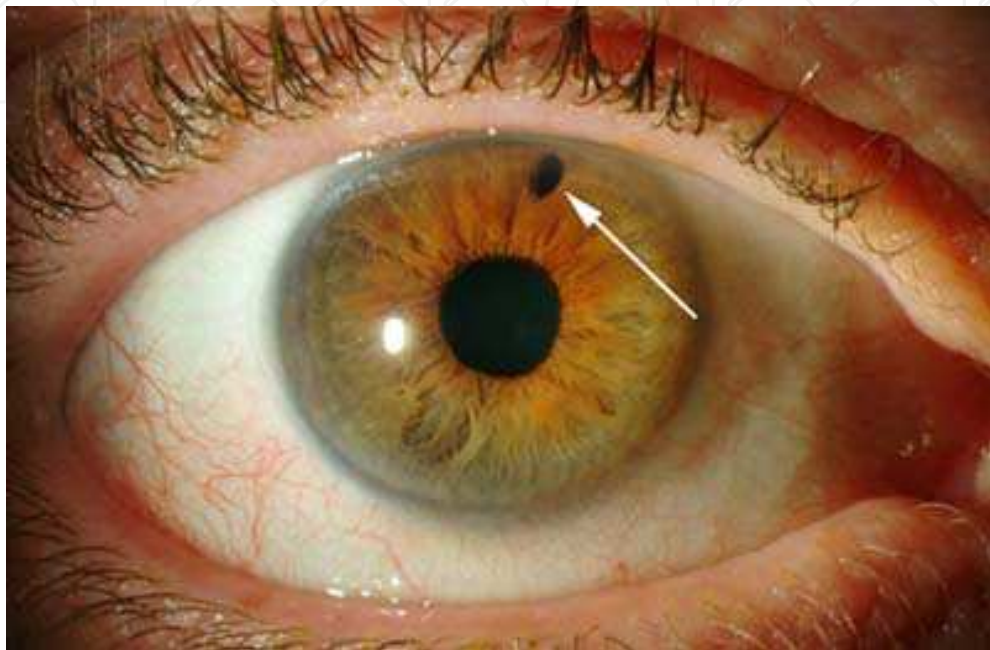


Fig. 13. Argon laser peripheral iridotomy is illustrated

ND: Yag laser peripheral iridotomy is indicated in eyes that have thick dark brown irides. After similar preparatory steps as above, the proposed treatment site is thinned with the Argon laser, and then the iris perforated with the ND:Yag with starting settings: power 1.7-3 mJ, pulses per burst 2. Follow up examination in one hour to avoid missing any spike in intraocular pressure, which must be treated appropriately. The patient is seen in one week, one month, then at three to six months.

The number of surgical iridectomies has declined dramatically with the introduction of laser procedures which are noninvasive and thus avoid the potential and real complications of intraocular surgery. Lensectomy with posterior chamber intraocular lenses for intumescent or dislocated cataracts has been reported to have good clinical results with deepening of the anterior chamber. However, results of clinical trials to determine the true value of this procedure are pending.

One type of patient with narrow angles deserves special attention: the rare individual with nanophthalmos. These highly hyperopic eyes with very short axial lengths and proportionally large lenses, are prone to very serious complications during and after intraocular surgery such as vitreous loss during surgery and post operative hypotony with effusions in the suprachoroidal space culminating in huge choroidal detachments that in extreme cases seem to fill the eye. Corrective surgery is difficult and may involve vitrectomy, removing sclera surrounding vortex veins, and drainage of the choroidals. Posterior sclerotomy prior to trabeculectomy has some but does not have widespread support. (58)

10. Financial cost of glaucoma

In the United States of America in 2006, approximately eighty five thousand laser iridotomies and three thousand laser iridoplasties were reimbursed by Medicare for payment (53).

The total financial burden of adult major visual disorders is estimated to be 25.4 billion, with more than \$2.9 billion due to glaucoma. Outpatient medical and pharmaceutical costs accounted for the bulk of glaucoma expenditure. In 1996 the cost of Social Security benefits, lost income tax revenues, and healthcare expenditures was considered to be 1.5 billion dollars (USD). In 2003 it was estimated that blindness and vision loss were responsible \$2.14 billion in non eye related costs.

There is also a cost to society in terms of quality of life and supportive care for the blind. Individuals with impaired vision are at risk of falls, auto accidents, require more care, and may have reduced life expectancy.

Should the fellow eye be treated if it has not suffered an attack? It is usually warranted since both angles usually have similar structures. In the United States of America, medical liability may be a risk for not treating the fellow eye for blinding condition. The management of patients who are anatomically at risk who have not suffered an attack presents a dilemma: should they be treated or should treatment be delayed until the attack occurs. The cost of treatment must be factored into the decision with the knowledge that failure to diagnose primary angle closure glaucoma carries a risk of harm to the patient and malpractice litigation.

11. Prognosis

11.1 Acute angle closure

After the the acute attack is over, eyes should be examined for degree of angle closure, presence of peripheral anterior synechiae (PAS), and optic disc and visual field damage. Intraocular pressure (IOP) should be checked often to detect asymptomatic rise in IOP. The second eye should be assessed and treated to prevent attack. (59)

The prognosis is favorable if the IOP can be controlled. IOP is reported to be controlled with laser peripheral iridotomy alone in 42% to 72%, in whites more often then in Asians. (60) (61)

11.2 Angle closure glaucoma

Progressive visual deterioration may be prevented if control of the IOP can be achieved. Whether or not peripheral iridotomy alone can control the IOP depends the underlying mechanism and the stage of the disease when diagnosed. (62)

If more PAS, a higher IOP, and a larger cup-to-disc ratio are found, there is a likelihood of poor pressure control following iridotomy. (63) Once glaucomatous optic neuropathy has developed most patients will require further treatment to control IOP. (64)

Clinical clues for non-ophthalmologists that an individual may be having an attack of angle closure glaucoma. If a patient, who may or may not be able to communicate, has an inflamed eye with oval pupil and hazy cornea with loss of clarity, the diagnosis of angle closure glaucoma should be entertained. If the patient wears thick glasses that magnify objects, the patient may be far sighted or hyperopic with a small eye at risk of angle closure glaucoma. The flashlight test may point to narrow angles if a bright light is positioned to shine on the eye from the ear side and only a temporal crescent is lit up and the rest of the

iris is in shadow, instead of the entire iris being illuminated. A detailed medical is important to learn of prior eye problems, a family history of glaucoma, prior eye surgery, and a complete list of all medications both prescription and over the counter.

12. Summary

A significant number of individuals world wide are at risk of blindness from angle closure glaucoma. Acute angle closure glaucoma crises attacks are relatively easy to diagnose. The challenge is identification and examination of patients at risk of angle closure glaucoma, those with anatomically narrow angles who have not suffered an acute attack, those with evidence of subclinical attacks, symptoms of headache, blurry vision, halos around lights, narrowed angles, peripheral anterior synechiae, and the fellow eye of one that has suffered an attack of acute angle closure. Signs of a prior attack to look for include glaukomaflecken, Iris atrophy, ovoid pupil, and peripheral anterior synechiae.

The methods of grading the depth of the anterior chamber at the slit lamp (van Herick), indirect gonioscopy (Shaffer, Spaeth), and new non contact methods (UBM, anterior segment OCT, Scheimpflug, Pentascan) can be helpful in identifying patients who may be at risk of angle closure glaucoma and treated before they progress to optic nerve damage, visual field defects, and blindness.

13. Future directions in diagnosis and management of patients at risk of or suffering from angle closure glaucoma

The large numbers of individuals at risk of developing or those with eyes already damaged demonstrate the need for early detection and treatment, particularly in underdeveloped countries. A hand held self contained UBM or OCT would greatly facilitate the identification of those at risk. Such a portable device could scan the eye and wirelessly transmit data to a smart phone to store and display the results. The information could then be uploaded to a central health agency's website for further action.

To facilitate iridotomies in the field a hand held self contained portable ND:Yag laser would be useful.

Current imaging methods analyze the optic nerve, nerve fiber layer, and other structures. Perhaps a future method could image nerve impulses traveling along the ganglion cell axons to provide information about their functional status, identify unhealthy ones, allow mapping, and help suggest when appropriate treatment should be started.

Study of the genetic machinery involved in the embryologic development of the eye might identify the genes and other process involved and enable restarting the genetic machinery in damaged or blind eyes to regenerate or rebuild damaged retina and optic nerves. This assumes that the genes involved are turned on for a period of time, then silenced, are not removed from the genome, but persist in all cells and could be restarted.

14. References

- [1] Quigley H. A. Number of people with glaucoma worldwide. *Br J Ophthalmol*. 1996, 80: 389-393.


- [2] Noecker, Robert J., and Lauri Graham. "Acute Angle-Closure Glaucoma." *eMedicine Consumer Health*. Eds. Richard W. Allinson, et al. 18 Nov. 2005. Medscape. 30 Oct. 2009.
- [3] Bonomi L., Marchini G., Marraffa M., et al. Prevalence of glaucoma and intraocular pressure distribution in a defined population. The Egna-Neumarkt Study. *Ophthalmology* 1998; 105:209-15.
- [4] Mitchell P., Smith W., Attebo K., Healey P. R. Prevalence of open-angle glaucoma in Australia. The Blue Mountains Eye Study. *Ophthalmology* 1996; 103:1661-9.
- [5] Bankes JL, Perkins ES, Tsoulas S, Wright JE. Bedford glaucoma survey. *Br Med J* 1968; 1:791-6.
- [6] Coffey M., Reidy A., Wormald R., et al. Prevalence of glaucoma in the west of Ireland. *Br J Ophthalmol* 1993; 77:17-21.
- [7] Hollows F. C., Graham P. A. Intra-ocular pressure, glaucoma, and glaucoma suspects in a defined population. *Br J Ophthalmol* 1966; 50:570-86.
- [8] Wensor M. D., McCarty C. A., Stanislavsky Y. L., et al. The prevalence of glaucoma in the Melbourne Visual Impairment Project. *Ophthalmology* 1998; 105:733-9.
- [9] Klein B. E., Klein R., Sponsel W. E., et al. Prevalence of glaucoma. The Beaver Dam Eye Study. *Ophthalmology* 1992; 99:1499-504.
- [10] Dielemans I., Vingerling J. R., Wolfs R. C., et al. The prevalence of primary open-angle glaucoma in a population-based study in The Netherlands. The Rotterdam Study. *Ophthalmology* 1994; 101:1851
- [11] Bengtsson B. The prevalence of glaucoma. *Br J Ophthalmol* 1981; 65:46-9.
- [12] Casson R. J., Newland H. S., Muecke J., et al. Prevalence of glaucoma in rural Myanmar: the Meiktila Eye Study. *Br J Ophthalmol* 2007; 91:710-4.
- [13] Salmon J. F., Mermoud A., Ivey A., et al. The prevalence of primary angle closure glaucoma and open angle glaucoma in Mamre, western Cape, South Africa. *Arch Ophthalmol* 1993; 111:1263-9.
- [14] Dandona L., Dandona R., Mandal P., et al. Angle-closure glaucoma in an urban population in southern India. The Andhra Pradesh eye disease study. *Ophthalmology* 2000; 107:1710-6.
- [15] Bourne R. R., Sukudom P., Foster P. J., et al. Prevalence of glaucoma in Thailand: a population based survey in Rom Klao District, Bangkok. *Br J Ophthalmol* 2003; 87:1069-74.
- [16] Vijaya L., George R., Arvind H., et al. Prevalence of angle-closure disease in a rural southern Indian population. *Arch Ophthalmol* 2006; 124:403-9.
- [17] Ramakrishnan R., Nirmalan P. K., Krishnadas R., et al. Glaucoma in a rural population of southern India: the Aravind comprehensive eye survey. *Ophthalmology* 2003; 110:1484-90.
- [18] Rahman M. M., Rahman N., Foster P. J., et al. The prevalence of glaucoma in Bangladesh: a population based survey in Dhaka division. *Br J Ophthalmol* 2004; 88:1493-7.
- [19] Shiose Y., Kitazawa Y., Tsukahara S., et al. Epidemiology of glaucoma in Japan--a nationwide glaucoma survey. *Jpn J Ophthalmol* 1991; 35:133-55.
- [20] Yamamoto T., Iwase A., Araie M., et al. The Tajimi Study report 2: prevalence of primary angle closure and secondary glaucoma in a Japanese population. *Ophthalmology* 2005; 112:1661-9.

- [21] Van Rens G. H., Arkell S. M., Charlton W., Doesburg W. Primary angle-closure glaucoma among Alaskan Eskimos. *Doc Ophthalmol* 1988; 70:265-76.
- [22] Arkell S. M., Lightman D. A., Sommer A., et al. The prevalence of glaucoma among Eskimos of northwest Alaska. *Arch Ophthalmol* 1987; 105:482-5.
- [23] Bourne R. R., Sorensen K. E., Klauber A., et al. Glaucoma in East Greenlandic Inuit--a population survey in Ittoqqortoormiit (Scoresbysund). *Acta Ophthalmol Scand* 2001; 79:462-7.
- [24] Seah S. K., Foster P. J., Chew P. T., et al. Incidence of acute primary angle-closure glaucoma in Singapore. An island-wide survey. *Arch Ophthalmol* 1997; 115:1436-40.
- [25] Weinreb R. N., Friedman D. S., eds. *Angle Closure and Angle Closure Glaucoma*. World Glaucoma Association Consensus Series-3. The Netherlands: Kugler Publications, 2006.
- [26] Anderson D. R., Jin J. C., Wright M. M. The physiologic characteristics of relative pupillary block. *Am J Ophthalmol* 1991;111:344-50. Tiedeman JS. A physical analysis of the factors that determine the contour of the iris. *Am J Ophthalmol* 1991; 111:338-43.
- [27] Jin J. C., Anderson D. R. The effect of iridotomy on iris contour. *Am J Ophthalmol* 1990; 110:260-3.
- [28] Seah S. K., Foster P. J., Chew P. T., et al. Incidence of acute primary angle-closure glaucoma in Singapore. An island-wide survey. *Arch Ophthalmol* 1997; 115:1436-40.
- [29] American Academy of Ophthalmology Glaucoma Panel. Preferred Practice Pattern® Guidelines. Primary Open-Angle Glaucoma. San Francisco, CA: American Academy of Ophthalmology; 2010. Available at: www.aao.org/ppp.
- [30] Aung T., Husain R., Gazzard G., et al. Changes in retinal nerve fiber layer thickness after acute primary angle closure. *Ophthalmology* 2004; 111:1475-9.
- [31] von Graefe, A., *Beitrage zur Pathol und Therapiedes Glaucoma*, *Arch. f. Ophth.*, 15:i 8, 1869.
- [32] Quigley H. A., Angle-Closure Glaucoma-Simpler Answers to Complex Mechanisms: LXVI Edward Jackson Memorial Lecture. *Am J Ophthalmol* 2009; 118:657-669. Panday V. A, Rhee D. J.
- [33] Review of sulfonamide-induced acute myopia and acute bilateral angle-closure glaucoma. *Compr Ophthalmol Update* 2007; 8:271-6.
- [34] Fraunfelder F. W., Fraunfelder F. T., Keates E. U. Topiramate-associated acute, bilateral, secondary angle-closure glaucoma. *Ophthalmology* 2004; 111:109-11.
- [35] A. Trantas: Sur la gonioscopie (Ophtal- moscopie de l'angle iridocorneen). *Arch Ophtalmol (Paris)* 45:616, 1928.
- [36] Dellaporta A. Historical notes on gonioscopy. *Surv Ophthalmol* 1975; 20:137-49.
- [37] Salzmann M. Nachtrag zu ophthalmoskopie der kammerbucht. *Z Augenheilk* 1915; 34: 160-2.
- [38] Blum, M., et al, Theodor Leber: a founder of ophthalmic research, *Surv Ophthalmol*, 1992: p. 83-8.
- [39] Jaeger, W. The foundation of experimental ophthalmology by Theodor Leber. *Doc Ophthal.* 1988 Jan-Feb; 68:71-7.
- [40] Troncoso M. U. *Gonioscopy with the Electric Ophthalmoscope*. New York, NY: New York Academy of Medicine; 1921.

- [41] Barkan O., Boyle S. F., Maisler S. On the genesis of glaucoma. An improved method based on slit lamp microscopy of the angle of the anterior chamber. *Am J Ophthalmol* 1936; 19:209-15.
- [42] Van Herick W., Shaffer R. N., Schwartz A. Estimation of width of angle of anterior chamber. Incidence and significance of the narrow angle. *Am J Ophthalmol* 1969; 68:626-9.
- [43] Goldmann H. Zur Technik der Spaltlampenmikroskopie. *Ophthalmologica* 1938; 96:90-7.
- [44] Allen L, Braley A. E, Thorpe H. E. An improved gonioscopic contact prism. *AMA Arch Ophthalmol* 1954; 51:451-5.
- [45] Forbes M. Gonioscopy with corneal indentation. A method for distinguishing between appositional closure and synechial closure. *Arch Ophthalmol* 1966; 76:488-92.
- [46] Scheie H. G. Width and pigmentation of the angle of the anterior chamber; a system of grading by gonioscopy. *AMA Arch Ophthalmol* 1957; 58:510-2.
- [47] Shaffer R. N. *Stereoscopic Manual of Gonioscopy*. St. Louis, MO: Mosby; 1962.
- [48] Spaeth G. L. The normal development of the human anterior chamber angle: a new system of grading. *Trans Ophthalmol Soc UK* 1971; 91:709-39.
- [49] James D. Brandt, M. D., 1 Julia A. Beiser, M. S., 2 Michael A. Kass, M. D., 2 Mae O. Gordon, PhD, 2 and the Ocular Hypertension Treatment Study (OHTS). Group Central Corneal Thickness in the Ocular Hypertension Treatment Study (OHTS). *Ophthalmology* 2001; 108: 1779-1788
- [50] Fujioka M., Nakamura M., Tatsumi Y., Kusuvara A., Maeda H., Negi A. Comparison of Pentacam. Scheimpflug camera with ultrasound pachymetry and noncontact specular microscopy in measuring central corneal thickness. *Curr Eye Res.* 2007 Feb; 32:89-94.
- [51] M. I. Othman, S. A. Sullivan, G. L. Skuta, D. A. Cockrell, H. M. Stringham, C. A. Downs, A. Forne, A. Mick M. Boehnke, 2 D. Vollrath, and J. E. Richards, Autosomal Dominant Nanophthalmos (*NNO1*) with High Hyperopia and Angle-Closure Glaucoma Maps to Chromosome 11. *Am. J. Hum. Genet.* 63:1411-1418, 1998.
- [52] Fred B. Berry, Matthew A. L., J. Martin, Tim Footz D. Alan Underhill, Philip J. Gage and Michael A. Walter, Functional interactions between FOXC1 and PITX2 underlie the sensitivity to FOXC1 gene dose in Axenfeld-Rieger syndrome and anterior segment dysgenesis. *Human Molecular Genetics*, 2006, Vol. 15, No. 6 doi: 10.1093/hmg/ddi008
- [53] Jordana K. Schmier, M. A; David W. Covert, M. B. A; Edmund C. Lau, M. S; Alan L. Robin, M. D. Trends in Annual Medicare Expenditures for Glaucoma Surgical Procedures From 1997 to 2006. *Arch Ophthalmol.* 2009; 127:900-905.
- [54] R H W Funk E-M Kniep and C Röhlecke. Detecting the effects of neuroprotection in living cells. *Eye* (2007) 21, S38-S41; doi:10.1038/sj.eye.6702887
- [55] Kolker, A. E. Symposium on glaucoma The Association for Research in Ophthalmology and the National Society for the Prevention of Blindness.
- [56] Hyperosmotic agents in glaucoma. *Investigative Ophthalmology* Volume 9 Number 6 June 1970 418-423.
- [57] Primary Angle Closure Preferred Practice Pattern October 2010.
- [58] Eibschitz-Tsimhoni M, Lichter P, Del Monte M, et al. Assessing the need for posterior sclerotomy at the time of filtering surgery in patients with Sturge-Weber syndrome. *Ophthalmology* 2003; 110:1361-1363.

- [59] Hollows F. C, Graham P. A. Intra-ocular pressure, glaucoma, and glaucoma suspects in a defined population. *Br J Ophthalmol.* 1966; 50:570-586.
- [60] Wishart P. K., Atkinson P. L. Extracapsular cataract extraction and posterior chamber lens implantation in patients with primary chronic angle-closure glaucoma: effect on intraocular pressure control. *Eye.* 1989; 3:706-712.
- [61] Gunning F. P., Greve E. L. Lens extraction for uncontrolled glaucoma. *J Cataract Refract Surg.* 1998; 24:1347-1356.
- [62] Ang L. P., Aung T., Chua W. H., et al. Visual field loss from primary angle-closure glaucoma: a comparative study of symptomatic and asymptomatic disease. *Ophthalmology.* 2004; 111:1636-1640.
- [63] Salmon J. F. Long-term intraocular pressure control after Nd:YAG laser iridotomy in chronic angle-closure glaucoma. *J Glaucoma.* 1993; 2:291-296.
- [64] Rosman M., Aung T., Ang L. P., et al. Chronic angle-closure with glaucomatous damage: longterm clinical course in a North American population and comparison with an Asian population. *Ophthalmology.* 2002; 109:2227-2231.

IntechOpen



Glaucoma - Basic and Clinical Concepts

Edited by Dr Shimon Rumelt

ISBN 978-953-307-591-4

Hard cover, 590 pages

Publisher InTech

Published online 11, November, 2011

Published in print edition November, 2011

This book addresses the basic and clinical science of glaucomas, a group of diseases that affect the optic nerve and visual fields and is usually accompanied by increased intraocular pressure. The book incorporates the latest development as well as future perspectives in glaucoma, since it has expedited publication. It is aimed for specialists in glaucoma, researchers, general ophthalmologists and trainees to increase knowledge and encourage further progress in understanding and managing these complicated diseases.

How to reference

In order to correctly reference this scholarly work, feel free to copy and paste the following:

Michael B. Rumelt (2011). Primary Angle Closure Glaucoma, Glaucoma - Basic and Clinical Concepts, Dr Shimon Rumelt (Ed.), ISBN: 978-953-307-591-4, InTech, Available from:
<http://www.intechopen.com/books/glaucoma-basic-and-clinical-concepts/primary-angle-closure-glaucoma>

INTech
open science | open minds

InTech Europe

University Campus STeP Ri
Slavka Krautzeka 83/A
51000 Rijeka, Croatia
Phone: +385 (51) 770 447
Fax: +385 (51) 686 166
www.intechopen.com

InTech China

Unit 405, Office Block, Hotel Equatorial Shanghai
No.65, Yan An Road (West), Shanghai, 200040, China
中国上海市延安西路65号上海国际贵都大饭店办公楼405单元
Phone: +86-21-62489820
Fax: +86-21-62489821

© 2011 The Author(s). Licensee IntechOpen. This is an open access article distributed under the terms of the [Creative Commons Attribution 3.0 License](https://creativecommons.org/licenses/by/3.0/), which permits unrestricted use, distribution, and reproduction in any medium, provided the original work is properly cited.

IntechOpen

IntechOpen