

We are IntechOpen, the world's leading publisher of Open Access books Built by scientists, for scientists

6,900

Open access books available

186,000

International authors and editors

200M

Downloads

Our authors are among the

154

Countries delivered to

TOP 1%

most cited scientists

12.2%

Contributors from top 500 universities



WEB OF SCIENCE™

Selection of our books indexed in the Book Citation Index
in Web of Science™ Core Collection (BKCI)

Interested in publishing with us?
Contact book.department@intechopen.com

Numbers displayed above are based on latest data collected.
For more information visit www.intechopen.com



A Surgical Technique for Difficult Glaucoma Cases: Combined Cyclectomy/Trabeculectomy

Kaya N. Engin¹ and Günay Engin²

¹Bagcilar Education and Research Hospital, Department of Ophthalmology, Istanbul

²Esenyurt Uğur Hospital, Department of Ophthalmology, Istanbul
Turkey

1. Introduction

Although glaucoma, known to be the most common cause of irreversible blindness, is characterized by progressive loss of retinal ganglion cells, it has long been perceived as a disease caused by “increased intra-ocular pressure (IOP)”. Although increased IOP has been recently removed from the definition of glaucoma and regarded as a major risk factor and glaucoma has been defined as an optical neuropathy, clinical practices are still predominantly oriented towards the reduction of IOP (Gupta & Yücel, 2007). Yet the neuroprotective strategies developed are of limited use due to both variety and receptors and ion channels and the severity of side effects. Moreover, clinical studies are not sufficient (Danesh-Meyer, 2011). Recently, we have many medical therapeutic agents that have reduced IOP via different mechanisms. When target IOP defined for particular patients cannot be reached using medical therapy, ophthalmologists still have different options. Trabeculectomy with or without antimetabolites remains the golden standard for most of the primary and secondary glaucomas when medical and laser therapy are insufficient. However, some eyes are unresponsive to this therapy as well (Coleman & Brigatti, 2001). In a study conducted on 709 eyes of 566 patients, the variability of the efficiency of standard trabeculectomy has been reported with the mean follow up of 27.9 months (Mietz et al, 1999). According to the study, success rates for complete surgical success ranged from 59% in the best group with pigmentary dispersion syndrome to 0% in the worst group with neovascular glaucoma. Success rates of patients with POAG, pseudoexfoliation, chronic angle closure, pigmentary dispersion syndrome, and dysgenetic glaucoma were similar. Failure rates ranged from 11% in the best group (pseudoexfoliation) to 80% in the worst group (neovascular glaucoma). Failure rates were high in complicated forms of glaucoma, such as traumatic (30%), buphthalmos (40%) and uveitic (50%). For repeat trabeculectomies, the failure rate was 49% (20 out of 41 eyes). The mean time until failure ranged from 2.7 months (traumatic) to 15.5 months (pigmentary dispersion syndrome) and was 4.9 months for repeat trabeculectomies.

2. Current strategies for refractory glaucoma

Neovascular glaucoma (NVG) is reported to be the worst type in terms of failure rates (Mietz et al, 1999). Recommendations for treatment of NVG include treatment of the

underlying disease, complete panretinal photocoagulation if retinal ischemia is a factor (Sivak-Callcott et al, 2001), and anterior retinal cryoablation (ARC), especially in eyes with media opacities and as a preliminary procedure for filtering surgery or drainage implant surgery (Sandramouli et al, 1993). Recently, intravitreal agents in the treatment of such patients have constantly increased in importance. Intravitreal bevacizumab administration does not directly cause reduction in IOP, but it provides support to medical and invasive treatments to be applied to such patients due to rapid control of anterior segment neovascularization and improved symptomatic relief (Ghosh et al, 2010; Kotecha et al, 2011). In general terms, with respect to the approaches for cases with refractory glaucoma, there are different surgical and laser techniques in the literature. Although the ideal surgical procedure is still controversial, currently, trabeculectomy with antimetabolite therapy, aqueous shunt implants (Yalvac et al, 2007), and diode laser cyclophotocoagulation (Pokroy et al, 2008) are the favored surgical treatment options. The most important cause of failure in glaucoma surgery is the fibrocellular scar tissue formation in the infiltration area. To date, many drugs have been tried and are being tried, which may control intra-cellular signal conduction pathways in order to prevent proliferation of fibroblasts in such areas. Among the drugs used for this purpose, the most popular one is, recently, Mitomycin and 5-FU. Side effects of those compounds seriously limit their clinical use (Sleep, 2010). Among all side effects, the most important ones include filtering bleb infections (Mac & Soltan, 2003) and endophthalmy (Lehmann et al, 2000), corneal endothelial damage (Mattox, 1995), hypotony and rare associated retinal bleeding (Suzuki et al, 1999).

Aqueous shunts are useful options in the management of complicated glaucoma, where conventional filtration surgery is considered to carry a high risk of failure. The Ahmed Glaucoma valve is an accepted device that has integrated mechanisms to sustain a residual intraocular pressure in order to avoid postoperative hypotony and related complications (Hille et al, 2004). According to a comparative retrospective study reported by Taglia et al, success rates – IOP below 15mmHg at 1 year – were 80% for the Molteno implant, 39% for the Krupin Eye Valve with Disc, and 35% for the Ahmed Glaucoma Valve. However, Ahmed Glaucoma Valve patients were less likely to experience complications requiring reoperations or loss of two or more lines of visual acuity than the others (Taglia et al, 2007). In one of the retrospective studies regarding the Ahmed Glaucoma valve, postoperatively, 15% of 159 eyes were reported to have intraocular pressure equal to or greater than 22 mmHg. According to that study, the complication rate was 47% and the most common complication was obstruction of the tube (11%) (Huang et al, 1999). In a study performed specifically on NVG patients, cumulative probabilities of success were 63.2% after one year in the Ahmed Glaucoma valve group (Yalvac et al, 2007). In literature, loss of light perception in NVG was encountered as 31% and 48% after Baerveldt (Sidoti et al, 1995) and Molteno (Mermoud et al, 1993) tube implantations, respectively.

Another important focus of interest in the fight against refractory glaucoma is the ciliary body and it has wide area practices, since it is generally targeted to reduce formation of aqueous. Now, the most commonly recognized method is the diode transscleral cyclophotocoagulation. In a new study conducted on 32 refractory eyes, which had the aqueous tube shunt previously applied, undergoing diode transscleral cyclophotocoagulation up to 360 degrees, 7.5 mmHg and 7.9 mmHg IOP reductions were found in 1-month and 1-year follow-up, respectively, and the complications were reported to be hypotony (n=4), hyphema (n=2), failed corneal

transplant (n=1), and loss of light perception (n=5) (Ness et al, 2011). In another study where diode laser cyclophotocoagulation was compared with another technique for the ciliary body, namely cyclocryotherapy (Tzamalidis et al, 2011), it was reported that both methods were efficacious and safe and it was concluded that the primary treatment option in refractory glaucomas should be diode laser cyclophotocoagulation.

Aside from diode laser cyclophotocoagulation, the ciliary body has been a focus of interest since Sautter's operation in the early 80's (Sautter & Demeler, 1984). More recent techniques targeting the ciliary body include Contact and Noncontact transscleral Neodymium: Yttrium Aluminium Garnet (Nd:YAG) cyclophotocoagulation, and are also useful in refractory glaucomas. A long-term follow-up of 500 patients treated with noncontact transscleral Nd:YAG cyclophotocoagulation was carried out. Satisfactory intraocular pressure reduction was achieved in 62% and 87% of the patients with single and repeated treatment sessions, respectively. However, visual loss remained a significant postoperative complication, with some degree of reduced vision occurring in 39% of the study population. Patients with neovascular glaucoma yielded the greatest rate of visual loss at 46%. Unsatisfactory intraocular pressure reduction and reduced vision rates for contact transscleral cyclophotocoagulation were reported as 50% and 27%, respectively (Shields & Shields, 1994).

A surgical technique on the ciliary body to reduce aqueous formation by partially excising the pars plicata was described by Sautter in 1980s. The technique was first applied to and published for 6 (5 narrow-angle and 1 primary open-angle glaucoma) aphacic eyes and it was referred to as the Sautter operation (Sautter & Demeler, 1976). With this technique, 60°-150° of the ciliary body was surgically removed. They reduced intraoperative complications, such as vitreous loss and vitreous haemorrhages from the ciliary body vessels to a minimum by the use of a Fleiringa-ring, a paracentesis and an extensive cauterisation of the ciliary body tissue. The postoperative complication of scleral wound dehiscence was also reduced by a double scleral wound closure. The same two surgeons reported the results of 106 ciliary body excisions in a total of 90 eyes, between 1974 and 1984 (Sautter & Demeler, 1984). According to the paper, after six months, intraocular pressure was 19 mm Hg or less in 60 eyes with no other treatment, although ten eyes required a second excision. Another five eyes had intraocular pressures of 19 mm Hg or less with medical therapy (one reoperation) and seven had intraocular pressures of 22 mm Hg or less without medical therapy (one reoperation). The ciliary body excision failed in 13 eyes. Four of these had persistent hypotony (intraocular pressures of less than 4 mm Hg) and nine had intraocular pressures above 40 mm Hg. Reasons for failure included rubeosis iridis (seven eyes), an overlarge excision (three eyes), and expulsive hemorrhage, siderosis bulbi, and Lowe's syndrome (one eye each). Postoperative visual acuity was unchanged in 45 eyes, somewhat improved in 15, and worse in 21. Although a series was also published where a success rate of almost 80% was reported (Demeler, 1986), this brutal surgery was quit over the course of time.

Cyclectomy/Trabeculectomy (C/T), a modified trabeculectomy operation described by Engin G in the early 90's, is particularly suggested for refractory glaucomas. When compared with the Sautter operation in which 60°-150° of the pars plicata were excised, the filtering effect of the C/T technique is more important than the decrease of aqueous formation. That difference also allowed the surgeon to avoid major haemorrhage complications, even in cases with neovascular glaucoma.

3. Cyclectomy/trabeculectomy procedure (engin operation)

3.1 Surgical technique

Unless a special condition is indicated, operations were performed under regional anesthesia. Heads of the patients were kept slightly elevated and they were monitored to secure safe and hypotensive surgery.

Globe fixation was ensured with saturation of superior rectus with 4.0 silk. Limbus based flap was brought down on the cornea by fairly peeling the anatomic limbus.

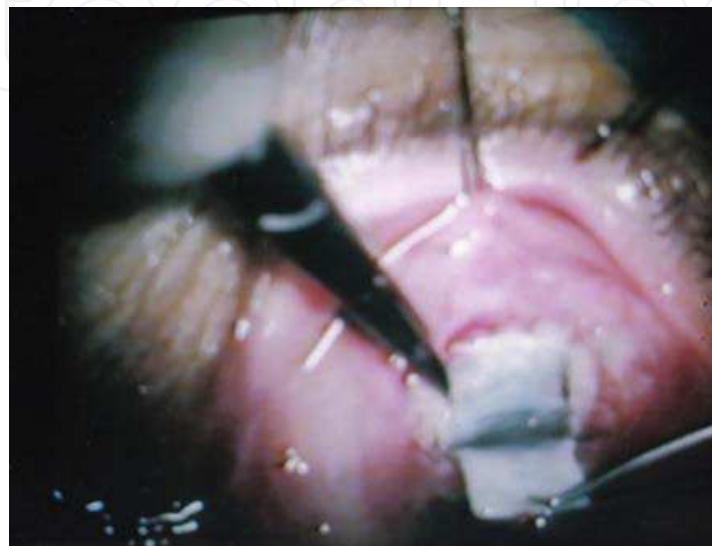

Fig. 1. A. A limbus based conjunctival flap was dissected. A half thickness scleral flap (4x6mm) was prepared. In order to prevent potential bleeding, the whole deep sclera and nearby was cauterized until a mild color change was achieved. This practice also decreases flap adhesion.

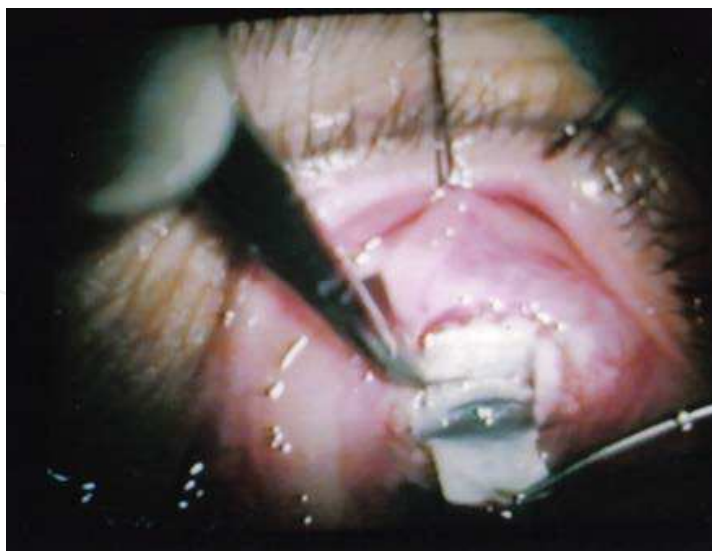

Fig. 1. B. Excision of a deep scleral piece of 2x4mm, posterior to the trabecular projection on the limbus grayline was performed. *In the C/T operation, deep sclerectomy incision was prepared even more posteriorly to visualize the processes of the ciliary body and to carry out a partial excision.*

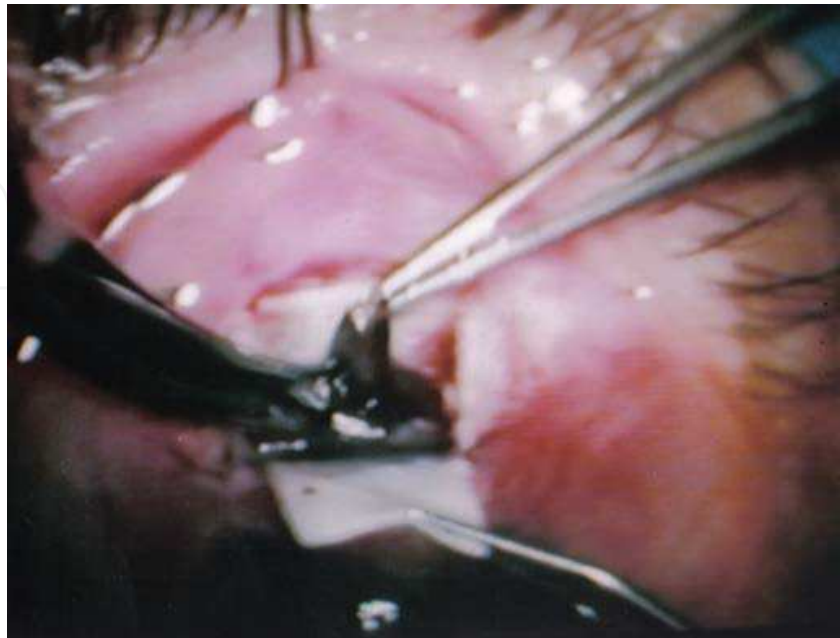


Fig. 1. C. A full thickness ciliary body fragment of the same dimensions of 2x4 mm was excised between 1 and 3 mm posterior to the clinical limbus. *Our experience has it that the iris root bleeds more than the ciliary process. The cyclectomy procedure feels like cutting out a piece from a sponge.*

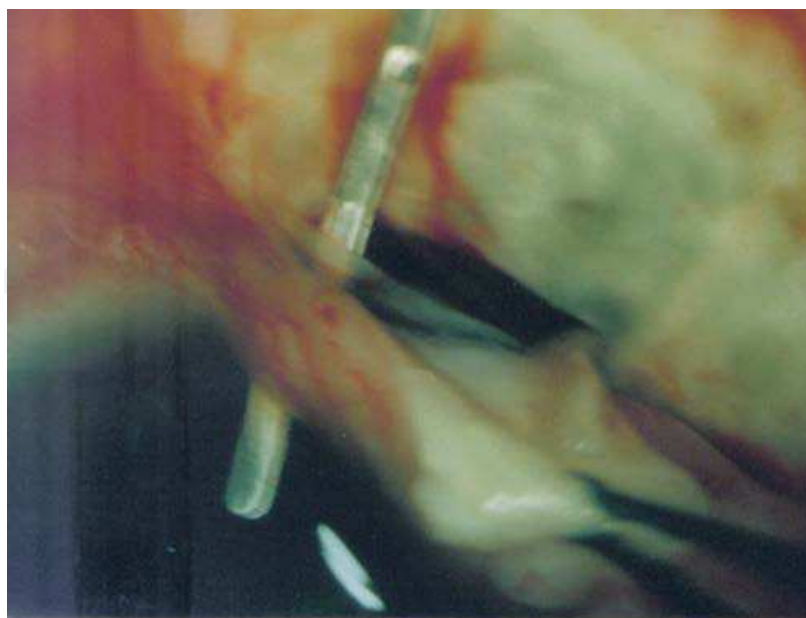


Fig. 1. D. The anterior chamber was entered just from the bottom of the cornea by separating it from the iridocorneal angle (4mm) with a spatula. *Afterwards, the majority of the iris and iris root was removed via partial cyclodialysis. Thus, although cyclodialysis and its full range of effects are not particularly designated, a limited dialysis takes effect as a side element of the procedure.*

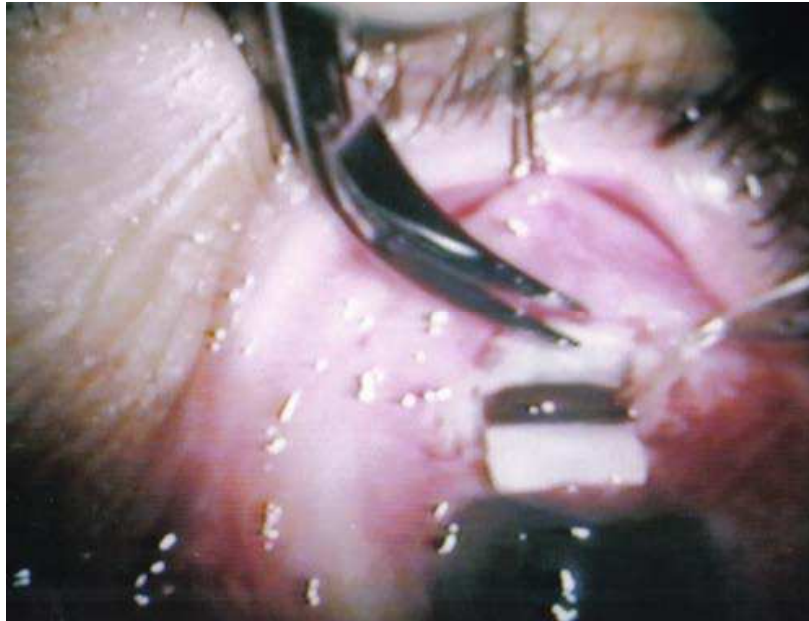


Fig. 1. E. The trabeculum of 2x3mm was excised with peripheral iridectomy. Thus, a wide passage from the anterior chamber to the posterior of the lens was completed.

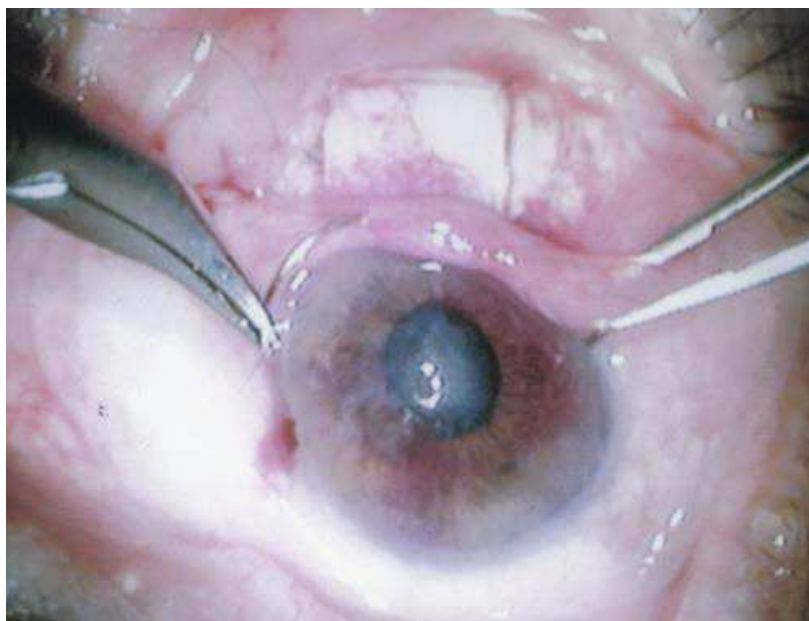


Fig. 1. F. The scleral flap was closed with 2 or 4 10.0 absorbable sutures. The operation was completed with the closing of the conjunctival flap by an 8.0 polyester running suture.

Neither an extra surgical device, nor antimetabolites were used. We currently regard the use of Mitomycin as an unnecessary risk in the C/T technique due to the wide filtration area (Figure 2).

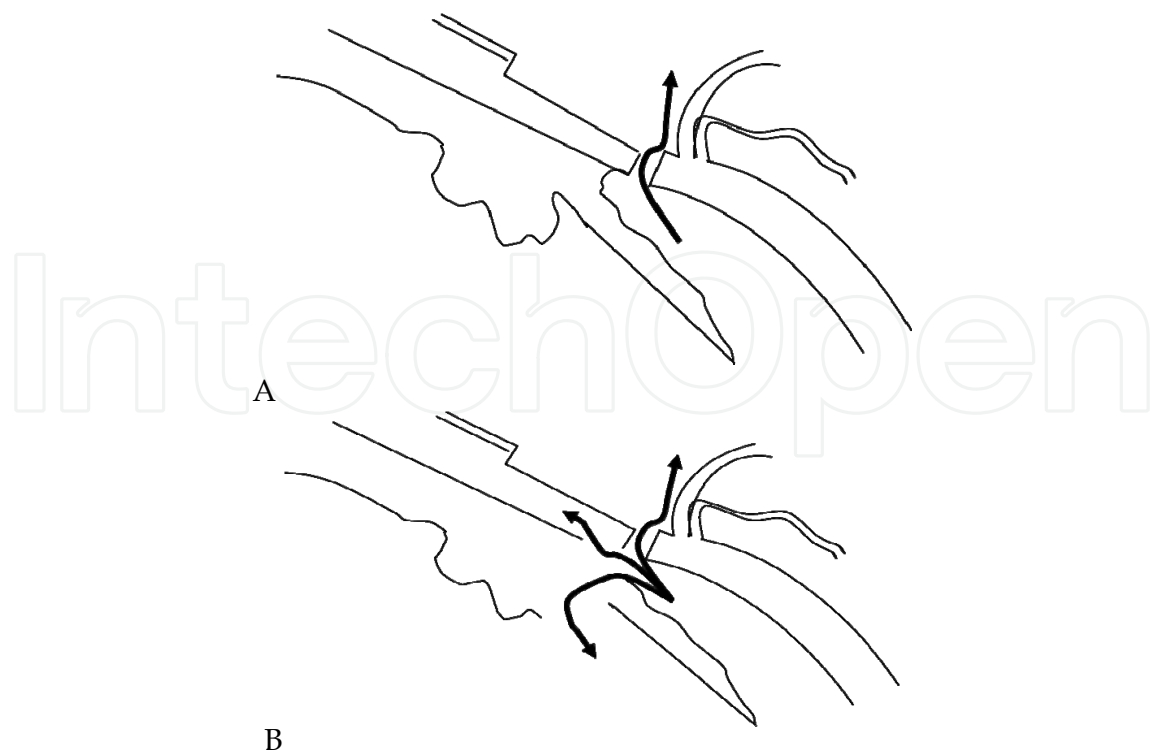


Fig. 2. Comparison of the filtration areas and probable routes of aqueous humor in standart trabeculectomy (A) and C/T operation (B).

3.2 Early and late results reported for C/T operation

Early results of the technique were reported on 55 desperate glaucomatous eyes of 52 patients -25 female and 27 male- with an average age of 52.4 years (in the range of 18-80 years) (Engin et al, 2007). The eyes with IOP remaining above 30 mmHg despite all medical therapies, and at least one glaucoma operation were selected for the operation. The etiological factors were 24 neovascular, 7 pseudophakic, 6 hereditary, 3 malignant, 3 postkeratoplasty, 3 postuveitic, 3 aphakic, 3 traumatic and 3 primary open angle glaucomas. All of the operated eyes were analyzed retrospectively. The IOPs, which varied between 32-80 (52.49 ± 12.94) mmHg preoperatively, decreased to 5-28 (13.85 ± 4.73) after the operation. IOPs were under 20 mmHg in 50 eyes without additional medical hypotensive therapy. A topical beta blocker was applied to the other five eyes. In 51 out of 55 eyes, the visual acuities increased or remained stable.

The complications were similar to those seen after trabeculectomy. No zonular damage or subluxation of the lens was observed, however, in three cases, the lens touch precipitated the cataract formation. No shallow anterior chamber after the operation was observed. The filtering bleb was always flat. Transient hyphema (27/55) was the most common complication and all of them resolved spontaneously in 2-5 days. The serious retinal detachments (2/55) that we observed were limited to the inferior part of the retina. It continued for two weeks, and then regressed spontaneously without any effect on visual acuity. Other postoperative complications observed were transient hypotony (8/55), anterior chamber inflammation (8/55) and intravitreal hemorrhage (5/55), conjunctival wound dehiscence (5/55), and choroidal detachment (6/55).

Peroperative problems were quite rare. Leaky hemorrhage from the iris base was seen in 11 patients. More insistent bleedings were observed in five neovascular glaucomas but they

were easily controlled by a simple cauterization. Vitreous loss was observed in six patients - two of them were aphakic - in which anterior vitreous and hyaloid integrity were broken. A vitreous excision was performed in order to prevent a blockage at the filtration site.

As for the late results, 42 eyes of 40 patients -22 female and 18 male- with an average age of 50.3 years (in a range of 18-86 years) were included in a retrospective study (Engin et al, 2004). All were difficult cases with glaucomas of various etiologies and 29 of them had at least one previous unsuccessful glaucoma operation. Four of the eyes were so desperate that they could represent an indication of enucleation. The etiologies were 21 neovascular, 5 hereditary, 4 pseudophakic, 3 aphakic, 3 malignant, 3 postkeratoplasty, and 3 postuveitic glaucomas. After a follow - up period of 2 to 5 years in 42 eyes, the IOPs which had varied between 34-80 mmHg preoperatively decreased after the operation and remained under 20 mmHg in 39 eyes. Only nine eyes needed topical therapy. In eight out of 42 eyes, the visual acuities improved while they remained the same in 32 eyes. The vision decreased in two eyes due to the development of secondary cataract. Complaints such as photophobia and ocular irritation disappeared in all patients. Complications were similar to those seen both after the trabeculectomy and our early results.

3.3 Results of combined C/T in neovascular glaucoma cases

Twenty-five eyes out of 23 cases with NVG have been included in this study. All the patients had been receiving triple medication consisting of Timolol, Dorzolamide and Bimatoprost. The gender distribution of this group was 14 female and 9 male and the average age was 62.7 years (in a range of 54-79 years). They were operated on with this technique from 1994 to 1999. The follow-up period was 12 months. The preop average IOP was 53.76 (38-80) mmHg and preop visions were from “no light perception” to 0.3. The main etiology was proliferative diabetic retinopathy. All the patients had been receiving triple medication consisting of Timolol, Dorzolamide and Bimatoprost and they were also undergoing treatment in our retina department. Written approval was obtained from each patient. None of the patients was perioperatively administered any antifibrotics or VEGF inhibitors.

Following all C/T operations undertaken in our clinic between 1994 and 2000, the excised specimens were photographed by an ophthalmic pathologist and confirmed as ciliary bodies. Postoperative comfort was evaluated with questionnaires regarding complaints, such as pain, photophobia and ocular irritation. Data regarding postoperative follow ups were analyzed retrospectively. Best corrected visual acuities with Snellen charts, IOPs taken by applanation tonometer and complications determined in routine examinations were recorded at the end of the first week and after six and 12 months. Cases with IOP between 5 to 20 mmHg, without additional medical therapy were considered as a complete success in terms of IOP lowering, whereas IOP less than 5 mmHg was recorded as hypotony. Prostaglandin analogues and/or aqueous suppressants were added to the therapy in eyes bearing IOP higher than 21 mmHg or complication.

At the end of the 1st year, vision preservations and success rates were found to be 92% and 72%, respectively. Complaints such as photophobia and ocular irritation disappeared in all patients. In five out of 25 eyes, the visual acuities increased while remained the same in 18 eyes. The vision decreased in two eyes (Figure 2A). In 23 out of 25 eyes, the IOPs postoperatively decreased and remained under 20 mmHg. Seven out of 25 eyes needed medical therapy (Figure 2B).

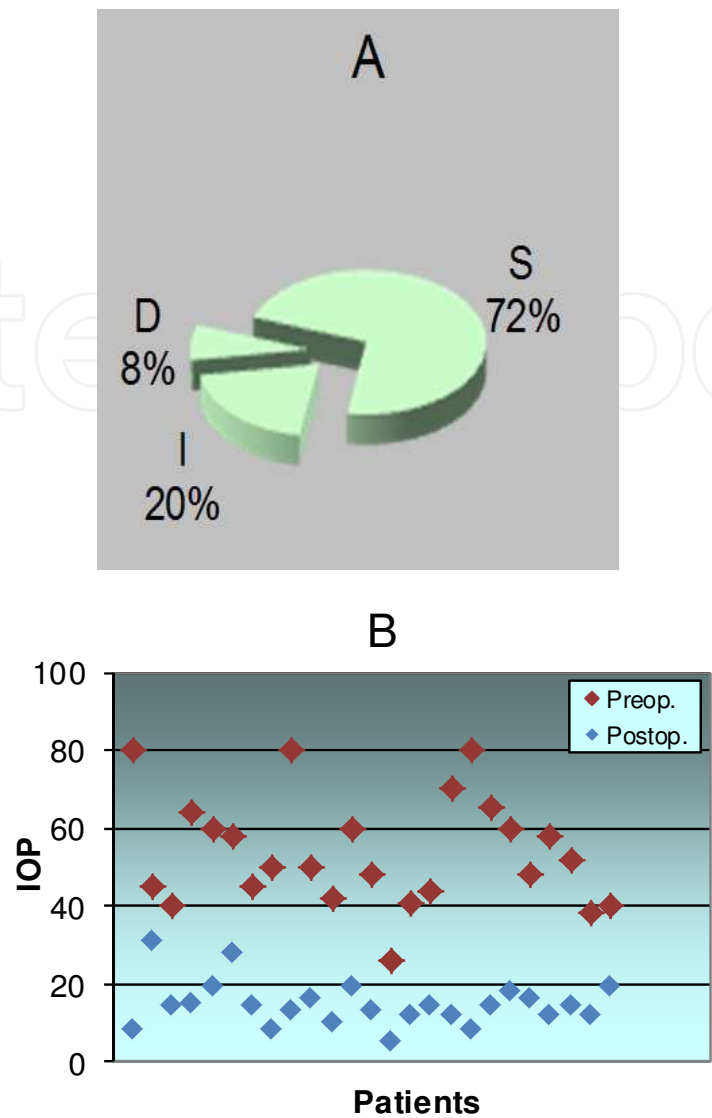


Fig. 2. Vision preservations (A) and success rates (B) S: Same, I: Increased, D: Decreased, IOP: Intraocular pressure.

Transient hyphema was the most frequent complication (40%) and resolved spontaneously in 2-5 days. No shallow anterior chamber after the operation was observed despite the occurrence of choroidal detachment (8%). The serious retinal detachments that we observed (4%) were limited to the inferior part of the retina. No zonular damage and subluxation of the lens were observed, however, in one case, lens touch precipitated cataract formation (4%). Hypotony was found to be 20% (Table 1).

In this study, vision preservations and success rates were found to be 92% and 72%, respectively, -which were both higher than the 76.4% and 63.2% of the Ahmed valve operations in NVG, respectively (Yalvac et al, 2007). Visual acuity reduced in two eyes due to cataract formation in the C/T group and this was not a specific complication of the C/T operation (Hylton et al, 2003).

The most common complication seen in the C/T group was hyphema. In a study reporting results after Trabeculectomy with MMC combined with direct cauterization of peripheral iris in patients with NVG, 20.8% hyphema was reported, in which irrigation of the anterior

chamber was required for three eyes (Elgin et al, 2006). We had a rate of 40% but all the hyphemas were resolved spontaneously in our series. That rate was also higher than 31% of our previous series with various etiologies (Engin et al, 2004; Engin et al, 2007). Consistent with the findings with the Ahmed Glaucoma valve in NVG, transient hyphema was the most common complication (Yalvac et al, 2007). It was reported between 8 and 20% with tube implantation in NVG (Sidoti et al, 1995 ; Mermoud et al, 1993). Hypotony was found to be 20% in our series, while the occurrence of these complications was reported both times previously as 5.3% with the Ahmed Glaucoma valve in NVG (Yalvac et al, 2007). Postoperative hypotony was reported between 8% (Huang et al, 1999) and 13% (Coleman et al, 1995) in other Ahmed Glaucoma valve series. Although that rate is higher than those previously reported in the literature, it was not a major problem clinically.

Complications	Ratios
Transient hyphema	10/25 (%40)
Transient hypotony	5/25 (%20)
Transient anterior chamber inflammation	4/25 (%16)
Transient intravitreal hemorrhage	2/25 (%8)
Choroidal detachment	2/25 (%8)
Serous retinal detachment	1/25 (%4)
Secondary cataract	1/25 (%4)
Mild vitreous loss	1/25 (%4)
Shallow anterior chamber	None
Conjunctival wound dehiscence	None
Corneal insufficiency	None

Table 1. Postoperative complications

4. Conclusions

When we compare the C/T procedure with the other known techniques above -as far as IOP reducing effect and vision preserving properties are concerned-, the superiority of the C/T technique is clearly seen. Clinical trials comparing the C/T technique with standard trabeculectomy, however, would be of great importance. On the other hand, the complications that we have observed were less frequent, and not worse than, standard trabeculectomy in incidence and severity. Since an external device is not used, it not only reduces the cost of surgery, but also removes from the surgeon’s agenda the possibility of complications arising from such devices. It is particularly remarkable that no endophthalmy or bleeding, which may pose a threat, was observed in almost 70 thousand surgeries published and/or presented to date.

Another advantage of the C/T technique over other alternatives is the ease of adaptation for a surgeon who is used to performing classical trabeculectomy. In this surgery, the aim is filtration, but not aqueous suppression, and the occurrence of large aqueous outflow by several routes including suprachoroidal and posterior chamber yields a huge circulation. As it is confirmed by the above comparative studies, obstruction of this passage is less possible than other filtrating surgeries.

The ongoing misfortune of the technique is that it is known and practiced by only a small group, and current trend is directed at minimizing trabeculectomy. However, even the

publications regarding current strategies against refractory glaucoma cases, clearly indicate the necessity for surgical treatment alternatives as effective as C/T. As we repetitively stated in our publications and oral, video presentations, C/T has identical complications to standard trabeculectomy. In fact, a far more efficient passage is opened and most of the anterior chambers do not disappear during operation, and in the post-operative period, the depth of anterior chamber remains adequate, even in narrow-angle eyes. We are positive that once an experienced glaucoma surgeon gets a hold of this technique in detail, he/she can use it successfully in indicated cases, yielding satisfactory results falling no shorter than other techniques.


5. Acknowledgments

Authors wish to thank to Prof Dr Levent Bilgiç (Istanbul University, Istanbul Faculty of Medicine, Dept of Pathology) for confirming each excised specimen as ciliary body, and to Prof Dr Gülgün Engin (Istanbul University, Istanbul Faculty of Medicine, Dept of Radiology) for employing her drawing skills for the artwork in this chapter.

6. References

- Coleman AL, Hill R, Wilson R, Choplin N, Kotas-Neumann R, Bacharach & J Panek WC. (1995). Initial clinical experience with Ahmed glaucoma valve implant. *Am J Ophthalmol* 120:23-31.
- Danesh-Meyer HV. (2011). Neuroprotection in glaucoma: recent and future directions. *Curr Opin Ophthalmol* 22(2):78-86.
- Demeler U. (1986). Ciliary surgery for glaucoma. *Trans Ophthalmol Soc U K* 105(Pt2):242-5.
- Elgin U, Berker N, Batman A, Simsek T & Cankaya B. (2006). Trabeculectomy with mitomycin C combined with direct cauterization of peripheral iris in the management of neovascular glaucoma. *J Glaucoma* 15:466-470.
- Engin G, Yilmazli C, Engin KN, Güllilik G & Bilgic L. (2004). Combined cyclectomy /trabeculectomy procedure for refractory glaucoma: methods and late results. *Ophthalmic Surg Lasers Imaging* 35:507-511.
- Engin G, Engin KN & Bilgic L. (2006). A modified surgical method for difficult glaucomas. *Tech Ophthalmol* 4:1-4.
- Ghosh S, Singh D, Ruddle JB, Shiu M, Coote MA & Crowston JG. (2010). Combined diode laser cyclophotocoagulation and intravitreal bevacizumab (Avastin) in neovascular glaucoma. *Clin Experiment Ophthalmol* 38(4):353-7.
- Gupta N & Yücel YH. (2007). Glaucoma as a neurodegenerative disease. *Curr Opin Ophthalmol* 18(2):110-4.
- Hille K, Moustafa B, Hille A & Ruprecht KW. (2004). Drainage devices in glaucoma surgery. *Klin Oczna* 106:670-681.
- Huang MC, Netland PA, Coleman AL, Siegner SW, Moster MR & Hill RA. (1999). Intermediate-term clinical experience with the Ahmed Glaucoma Valve implant. *Am J Ophthalmol* 127:27-33.
- Hylton C, Congdon N, Friedman D, Kempen J, Quigley H, Bass E & Jampel H. (2003). Cataract after glaucoma filtration surgery. *Am J Ophthalmol* 135:231-232.

- Kotecha A, Spratt A, Ogunbowale L, Dell'omo R, Kulkarni A, Bunce C & Franks WA. (2011). Intravitreal bevacizumab in refractory neovascular glaucoma: a prospective, observational case series. *Arch Ophthalmol* 129(2):145-50.
- Lehmann OJ, Bunce C, Matheson MM, Maurino V, Khaw PT, Wormald R & Barton K. (2000). Risk factors for development of post-trabeculectomy endophthalmitis. *Br J Ophthalmol* 84:1349-1353.
- Mac I & Soltau JB. (2003). Glaucoma-filtering bleb infections. *Curr Opin Ophthalmol* 14:91-94.
- Mattox C. (1995). Glaucoma filtration surgery ve antimetabolites. *Ophthalmic Surg Lasers* 26:473-480.
- Mermoud A, Salmon JF & Alexander P. (1993). Molteno tube implantation for neovascular glaucoma. Long-term results and factors influencing the outcome. *Ophthalmology* 100:897-902.
- Mietz H, Raschka B & Krieglstein GK. (1999). Risk factors for failures of trabeculectomies performed without antimetabolites. *Br J Ophthalmol* 83:814-821.
- Ness PJ, Khaimi MA, Feldman RM, Tabet R, Sarkisian SR, Skuta GL, Chuang AZ & Mankiewicz KA. (2011). Intermediate Term Safety and Efficacy of Transscleral cyclophotocoagulation After Tube Shunt Failure. *J Glaucoma* Feb 17. [Epub ahead of print]
- Pokroy R, Greenwald Y, Pollack A, Bukelman A & Zalish M. (2008). Visual loss after transscleral diode laser cyclophotocoagulation for primary open-angle and neovascular glaucoma. *Ophthalmic Surg Lasers Imaging* 39:22-29.
- Sandramouli S, Sihota R & Sood NN. (1993). Role of anterior retinal cryoablation in the management of neovascular glaucoma. *Doc Ophthalmol* 84:179-185.
- Sautter H & Demeler U. (1976). [Excision of the ciliary-body in cases of secondary closed-angle glaucoma (author's transl)]. *Klin Monbl Augenheilkd* 168(4):441-7.
- Sautter H & Demeler U. (1984). Antiglaucomatous ciliary body excision. *Am J Ophthalmol* 98:344-348.
- Shields MB & Shields SE. (1994). Noncontact transscleral Nd:YAG cyclophotocoagulation: a long-term follow-up of 500 patients. *Trans Am Ophthalmol Soc* 92:271-283.
- Sidoti PA, Dunphy TR, Baerveldt G, LaBree L, Minckler DS, Lee PP & Heuer DK. (1995). Experience with the Baerveldt glaucoma implant in treating neovascular glaucoma. *Ophthalmology* 102:1107-1118.
- Sivak-Callcott JA, O'Day DM, Gass JD & Tsai JC. (2001). Evidence-based recommendations for the diagnosis and treatment of neovascular glaucoma. *Ophthalmology* 108:1767-1776.
- Sleep T. (2010). Trabeculectomy and the use of antimetabolites. *Insight* 35(1):10-2.
- Suzuki R, Nakayama M & Satoh N. (1999). Three types of retinal bleeding as a complication of hypotony after trabeculectomy. *Ophthalmologica* 213:135-138.
- Taglia DP, Perkins TW, Gangnon R, Heatley GA & Kaufman PL. (2002). Comparison of the Ahmed Glaucoma Valve, the Krupin Eye Valve with Disk, and the double-plate Molteno implant. *J Glaucoma* 11:347-353.
- Tzamalīs A, Pham DT & Wirbelauer C. (2011). Diode laser cyclophotocoagulation versus cyclocryotherapy in the treatment of refractory glaucoma. *Eur J Ophthalmol* Feb 4. pii: 85784370-A31C-4F80-A7BC-2FC906898565. [Epub ahead of print]
- Yalvac IS, Eksioğlu U, Satana B & Duman S. (2007). Long-term results of Ahmed glaucoma valve and Molteno implant in neovascular glaucoma. *Eye* 21:65-70.



Glaucoma - Current Clinical and Research Aspects

Edited by Dr. Pinakin Gunvant

ISBN 978-953-307-263-0

Hard cover, 376 pages

Publisher InTech

Published online 27, June, 2011

Published in print edition June, 2011

This book summarizes current literature about research and clinical science in glaucoma and it is a synopsis and translation of the research conducted by individuals who are known in each of their respective areas. The book is divided into two broad sections: basic science and clinical science. The basic science section examines bench- and animal-modeling research in an attempt to understand the pathogenesis of glaucoma. The clinical science section addresses various diagnostic issues and the medical, laser and surgical techniques used in glaucoma management.

How to reference

In order to correctly reference this scholarly work, feel free to copy and paste the following:

Kaya N. Engin and Günay Engin (2011). A Surgical Technique for Difficult Glaucoma Cases: Combined Cyclectomy/Trabeculectomy, Glaucoma - Current Clinical and Research Aspects, Dr. Pinakin Gunvant (Ed.), ISBN: 978-953-307-263-0, InTech, Available from: <http://www.intechopen.com/books/glaucoma-current-clinical-and-research-aspects/a-surgical-technique-for-difficult-glaucoma-cases-combined-cyclectomy-trabeculectomy>

INTech
open science | open minds

InTech Europe

University Campus STeP Ri
Slavka Krautzeka 83/A
51000 Rijeka, Croatia
Phone: +385 (51) 770 447
Fax: +385 (51) 686 166
www.intechopen.com

InTech China

Unit 405, Office Block, Hotel Equatorial Shanghai
No.65, Yan An Road (West), Shanghai, 200040, China
中国上海市延安西路65号上海国际贵都大饭店办公楼405单元
Phone: +86-21-62489820
Fax: +86-21-62489821

© 2011 The Author(s). Licensee IntechOpen. This is an open access article distributed under the terms of the [Creative Commons Attribution 3.0 License](https://creativecommons.org/licenses/by/3.0/), which permits unrestricted use, distribution, and reproduction in any medium, provided the original work is properly cited.

IntechOpen

IntechOpen