

We are IntechOpen, the world's leading publisher of Open Access books Built by scientists, for scientists

6,900

Open access books available

186,000

International authors and editors

200M

Downloads

Our authors are among the

154

Countries delivered to

TOP 1%

most cited scientists

12.2%

Contributors from top 500 universities



WEB OF SCIENCE™

Selection of our books indexed in the Book Citation Index
in Web of Science™ Core Collection (BKCI)

Interested in publishing with us?
Contact book.department@intechopen.com

Numbers displayed above are based on latest data collected.
For more information visit www.intechopen.com



Dermatofibrosarcoma Protuberans – Special Challenges of Management in Resources Constrained Countries

Titus Osita Chukwuanukwu and Stanley Anyanwu
Nnamdi Azikiwe University
Teaching Hospital
Nigeria

1. Introduction

Dermatofibrosarcoma protuberans (DFSP) is best described as a fibroblastic neoplasm. It is a low to moderate grade type of soft tissue sarcoma (STS) arising from cells of mesenchymal origin in the dermal layer of the skin¹⁻⁴. This entity was first described in 1924 by Darier and Ferrand⁵. Though DFSP is a low grade malignancy, fibrosarcomatous variant can be very aggressive especially when provoked by inadequate excision. It is a rare type of skin cancer that can grow deeply into the skin to invade the fat, muscle, and bone. DFSP is a locally aggressive tumour and rarely metastasizes. This gives it a higher survival rate when adequately excised¹⁻⁷.

In developing countries however, late presentation to hospitals are very common. Patients here seek help first from unqualified persons and only come to the specialists late into their illness. This has led to poor outcomes in many cases.

2. Epidemiology

DFSP comprises 0.01% of all malignant tumours and 2 – 6% of all soft tissue sarcomas^{1,2,3}. STS constitute overall less than 1% of human adult solid malignant tumour⁷ but can be life threatening and sometimes difficult to diagnose and very challenging to treat. It has no sex predilection nor specified age incidence but is commoner between the ages of 20 and 50 years⁶⁻⁸. It is stated to be commoner in blacks with an estimated incidence of 0.8 to 5 per/million persons per year in America^{6,8}.

3. Aetiology

The exact cause of Soft Tissue Sarcomas and Dermatofibrosarcoma Protuberans is not well known. Predisposing factors include genetic mutation of the P 53 gene, exposure to ionising radiations, post burn and other scars and exposure to certain carcinogens have been documented. Of particular note is its recurrent nature especially following inadequate

excision either in margin or depth. High rate recurrence is noted in developing countries like Nigeria³.

4. Pathology

DFSP are skin cancers that arise from the dermal fibroblasts. Recent evidences by immunohistochemical tests however suggest that they may arise from the dendritic cells in the skin

It grows in a finger like manner into the surrounding tissues leading to uneven penetration. This is a major cause of recurrence as some malignant cells may have projected far beyond the macroscopic margin at the time of initial resection.

DFSP is highly cellular and comprises spindle cells arranged in a radial fashion most characteristic at the periphery of the tumor. It displays immunoreactivity to CD34. Haematogenous spread to the lungs is the commonest route of metastasis, regional lymph nodes are rarely involved⁷.

The variants of DFSP include the Bednar tumour, myxoid DFSP, atrophic type and the fibrosarcomatous variant which is very aggressive.

There is no staging system yet developed specific for DFSP but it is currently staged in accordance with the American Musculoskeletal Tumour society staging system taking into account tumour grade and compartmentalization⁶.

5. Clinical presentation

The usual pattern is an initial painless slow growing tumour. It may remain indolent for many years and sometimes grow to a very large size (more than 5cm in diameter over a few years). It may ulcerate but more commonly the patient intervenes one way or the other. Inadequate excision lead to recurrence of larger tumour and sometimes very slow healing ulcer. In the developing countries, they usually present with very large often fungating recurrent tumours. Other symptoms then depend on local effects and its site of location.

Metastasis is a late event and is commonest to the lung^{1,2,6,7,10}. Later to liver, lymph nodes, peritoneum (for abdominal wall tumours) and nearby structures. Progression depends on the histological variant, grade, stage, size, how deeply seated the tumour is and presence or absence of other tumours and patients genetic predisposition. The immune status may also play a role as a rare recurrence of the fibrosarcomatous variant has been reported to occur in pregnancy¹¹.

Rate of recurrence depends on the adequacy of resection margin and other management modalities employed. A DFSP has been reported to occur at the surgical scar of an earlier excised tumour after many years¹².

Pain is as a result of pressure. When infected, there may be fever, anorexia and Weight loss. Overall, patient presents with large tumours without much constitutional symptoms/sign.

6. Investigations

Biopsy of all suspicious lesions is mandatory. Histological and immunochemistry studies are done. The investigative tool of choice is the magnetic resonance imaging (MRI). This is

capable of delineating tissues planes thereby detecting extent of invasion of surrounding tissues including muscles and fat. This diagnostic tool is usually not available in developing countries. CT scan and contrast enhanced studies aid the diagnosis. X Rays of the affected parts and chest for metastasis to the lungs are also indicated in many cases. Biopsy of all suspicious tissues is recommended and for all lesions more than 5cm in diameter, an incision biopsy should precede definitive resection for adequate planning to avoid the danger of inadequate excision. Other investigations are done to determine the extent of local spread, distant metastasis and effects of the tumour on the patient generally.

7. Treatment

Surgery is the main stay of treatment. Wide local excision with histologically negative margins is the cornerstone of treatment^{3,6}. For tumour less than 5cm in diameter a 3cm margin is recommended and for lesions greater than 5cm and recurrent lesions resection margin should be 5cm. The underlying tissue is also excised beyond the normal plane. The margins are examined to ensure they are tumour-free. Adjuvant radiotherapy increases tumour clearance and decreases rate of recurrence. Resection of tumours close to neurovascular bundle, bone and other vital structures may not obey these rules and adjuvant radiotherapy and chemotherapy will then be absolutely indicated. It is usually difficult to identify the margin of the tumour macroscopically as the finger like projections into muscle, fascia, fat resemble normal tissue. Fibrosis from previous surgeries may also make adequate excision difficult. Radiotherapy and chemotherapy may be used pre-operatively to downsize the tumour and make it more resectable or post-operatively to manage residual tumours and metastasis.

Mohs micrographic surgery is presently employed (where available) and hold great promise for complete tumour excision⁷. Very large defects may be created after tumour excision which requires the services of a plastic reconstructive surgeon. When the limb is involved, limb sparing surgeries are first attempted where feasible otherwise amputation may be resorted to. Reconstructive procedures include local rotation and advancement flaps, regional flaps, pedicle and free tissue transfers. Prosthetic mesh has been used for reconstructing full thickness abdominal /chest wall defects^{3,31,14}.

A multidisciplinary approach by healthcare team with experience in management of STS is recommended for proper treatment of DFSP.

8. Follow up

Follow up of the patient is for life. Tumours have been known to recur many years after adequate excision. Any suspicious lesion around the area of an initial excision including the scars is subjected to full investigations and expert care.

9. Prognosis

Prognosis depends on both tumour and patient factors as well as availability of investigative and support services. Size is an important prognostic variable and so affects the quality of

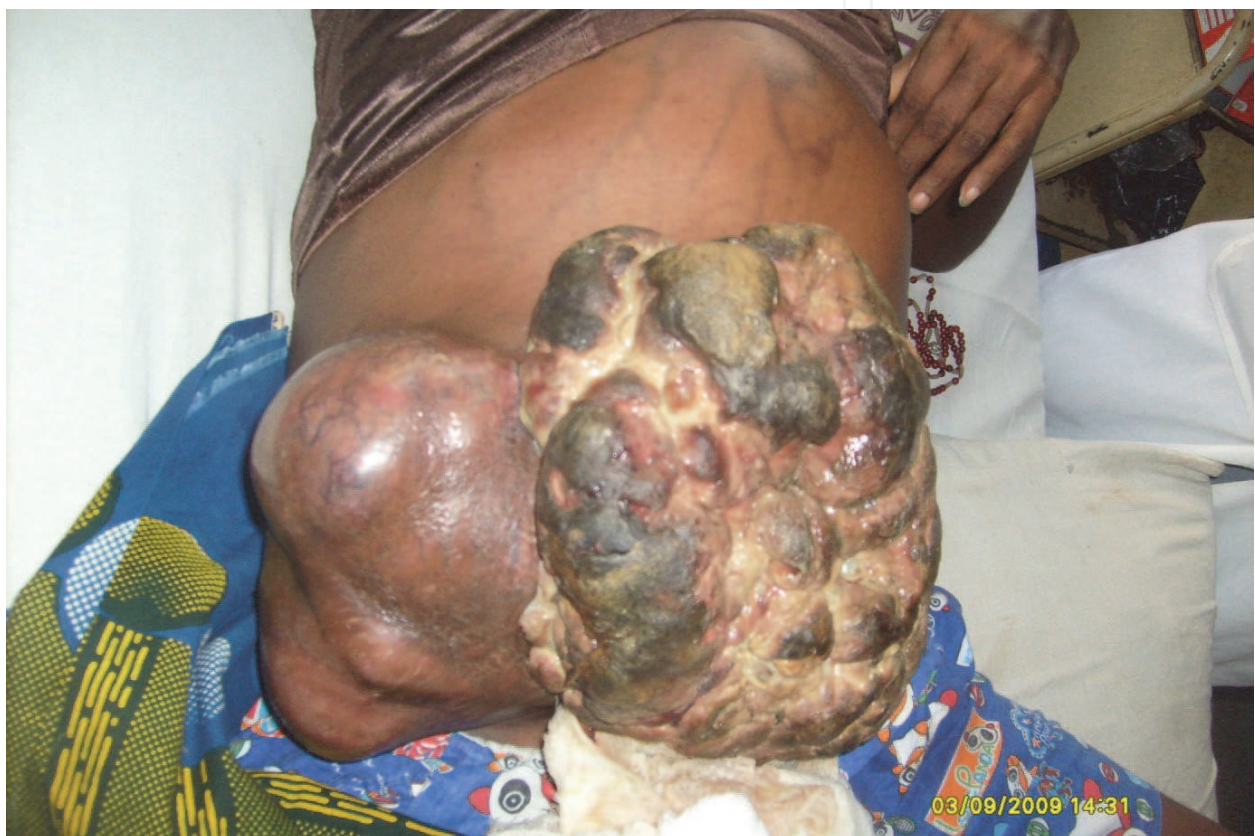

Fig. 1. Recurrence in pregnancy after 3rd excision, now very aggressive and fatal.resection.

In developed countries, the prognosis has improved remarkably but in the developing world however, prognosis remain poor due to a variety of factors. These include poverty, ignorance, late presentation with very large often fungating and metastatic lesions, low infrastructure and low availability of expertise.


10. References

- [1] LeBoit P.E., Burg G., Weedon D., Sarasin A. (9Eds): World Health Organisation Classification of tumours. Pathology and Genetics of Skin Tumour. IARC Press: Lyon 2006.
- [2] Fletcher C.D.M., Rydholm A., Singer S., Sundaram M., Coindre J.M: In Fletcher C.D.M., Unni K.K., Mertens F. (Eds): World Health Organisation classification of Tumours. Pathology and Genetics of Tumours of soft Tissue and Bone. IARC Press Lyon 2002. 13-18.
- [3] Chukwuanukwu T.O.G., Anyanwu S.N.C. Giant Fibrosarcoma Protuberans of Abdominal Wall Management Problems in Resources – Constrained Country. Nig. J. Clin Prac. Sept 2009 12 (3); 338-340.
- [4] Adigun I.A., Rahman G.A. A review of soft tissue sarcoma: Nig. J. Med. 16 (2); 94-101.
- [5] Darier J, Ferrand M: Dermatofibromes progressifs et recidivants ou fibrosarcomes de la peau. Ann Dermatol Syphiliga 1924; 5:545-562.
- [6] Kenny R.J, Cheney R., Stull M. A., Kraybill W. Soft Tissue Sarcomas; Current Management and Future Directions. Surg Clin N. AM 89 (2009) 235-247.
- [7] Burkhardt BR, Soule EH, Winkelmann RK, Ivans JC: Dermatofibrosarcoma protuberans: study of fifty-six cases. Am J Surg 1966;111:634-644.
- [8] Derek D, Vincent C, Lori I, Timothy M.J., Vernon K.S., Low recurrence rate after Surgery for Dermatofibrosarcoma protuberans. A multidisciplinary approach from a single institution. Cancer 2004; 100: 1008-16.
- [9] Stojanovic A, Hoos A, Karpoff HM, Leung DH, Antonescu CR, Brennan MF, Lewis JJ. Soft tissue tumours of the Abdominal wall; Analysis of disease patterns and treatment. Arch Surg. 2001; 136: 70-79.
- [10] Canale ST. Campbell's operative Orthopaedics. 10th ed. Philadelphia P.A: Mosby; 2003:864.
- [11] Cakir B., Misirlioglu A., Gideroglu K., Akoz T: Giant fibrosarcoma arising in dermatofibrosarcoma protuberance on the scalp during pregnancy. Dermatol Surg; 2003 Mar; 29 (3): 297-299.
- [12] Kshirsagar A.Y., Kanetkar S.R., Nikam Y.P., Vasisth G.O: Recurrent dermatofibrosarcoma protuberans over anterior abdominal wall. J. Cutan Aesthet Surg; 2010; 3(3): 167-169.
- [13] Kao CC, Rand RP, Stridde BC, Marchioro TL. Techniques in the composite reconstruction of extensive thoracoabdominal tumour resections. J. AM Coll. Surg. 1995. 180 (2).146-149.

- [14] Servant JM., Arnault E., Revol M., Damino A. Reconstruction of large thoraco-abdominal defects using two-stage free tissue transfers and prosthetic materials. J Plast Reconstr. Aesthet. Surg. 2006; 59(4): 360-365.

IntechOpen

IntechOpen



Soft Tissue Tumors

Edited by Prof. Fethi Derbel

ISBN 978-953-307-862-5

Hard cover, 270 pages

Publisher InTech

Published online 16, November, 2011

Published in print edition November, 2011

Soft tissue tumors include a heterogeneous group of diagnostic entities, most of them benign in nature and behavior. Malignant entities, soft tissue sarcomas, are rare tumors that account for 1% of all malignancies. These are predominantly tumors of adults, but 15% arise in children and adolescents. The wide biological diversity of soft tissue tumors, combined with their high incidence and potential morbidity and mortality represent challenges to contemporary researches, both at the level of basic and clinical science. Determining whether a soft tissue mass is benign or malignant is vital for appropriate management. This book is the result of collaboration between several authors, experts in their fields; they succeeded in translating the complexity of soft tissue tumors and the diversity in the diagnosis and management of these tumors.

How to reference

In order to correctly reference this scholarly work, feel free to copy and paste the following:

Titus Osita Chukwuanukwu and Stanley Anyanwu (2011). Dermatofibrosarcoma Protuberans – Special Challenges of Management in Resources Constrained Countries, *Soft Tissue Tumors*, Prof. Fethi Derbel (Ed.), ISBN: 978-953-307-862-5, InTech, Available from: <http://www.intechopen.com/books/soft-tissue-tumors/dermatofibrosarcoma-protuberans-special-challenges-of-management-in-resources-constrained-countries>

INTECH
open science | open minds

InTech Europe

University Campus STeP Ri
Slavka Krautzeka 83/A
51000 Rijeka, Croatia
Phone: +385 (51) 770 447
Fax: +385 (51) 686 166
www.intechopen.com

InTech China

Unit 405, Office Block, Hotel Equatorial Shanghai
No.65, Yan An Road (West), Shanghai, 200040, China
中国上海市延安西路65号上海国际贵都大饭店办公楼405单元
Phone: +86-21-62489820
Fax: +86-21-62489821

© 2011 The Author(s). Licensee IntechOpen. This is an open access article distributed under the terms of the [Creative Commons Attribution 3.0 License](https://creativecommons.org/licenses/by/3.0/), which permits unrestricted use, distribution, and reproduction in any medium, provided the original work is properly cited.

IntechOpen

IntechOpen