

We are IntechOpen, the world's leading publisher of Open Access books Built by scientists, for scientists

6,900

Open access books available

186,000

International authors and editors

200M

Downloads

Our authors are among the

154

Countries delivered to

TOP 1%

most cited scientists

12.2%

Contributors from top 500 universities



WEB OF SCIENCE™

Selection of our books indexed in the Book Citation Index
in Web of Science™ Core Collection (BKCI)

Interested in publishing with us?
Contact book.department@intechopen.com

Numbers displayed above are based on latest data collected.
For more information visit www.intechopen.com



Laparoscopic Approach to Abdominal Sepsis

José Sebastião Santos, Carlos A.M. Donadelli, Rafael Kemp,
Alberto Facury Gaspar and Wilson Salgado Jr.
*Medical School, University of São Paulo, Ribeirão Preto, São Paulo
Brazil*

1. Introduction

Diagnostic laparoscopy (DL) was introduced in surgical practice at the beginning of the 20th century but its use was limited for about 80 years. During the second half of the 20th century, laparoscopic access started to be used as a diagnostic resource in the traumatic and non-traumatic acute abdomen (Llanio & Sarle, 1956). Over the last decades, with the advent of new video systems, with the development of laparoscopic instruments and the improved visualization of the entire abdominal cavity, DL achieved an excellent level (Geis & Kim, 1995). Within this context of progress, DL started to be successfully used in critically ill patients in intensive care units, with a diagnostic accuracy of 96% and with no significant changes in hemodynamic parameters during the procedure (Brandt et al., 1993; Forde & Treat, 1992).

The easy identification of the types of organic fluids, the resources for the aspiration of pus, blood, bile and the intestinal content and the increased surgical experience have contributed to the therapeutic success of laparoscopy in an acute abdomen of surgical cause (Boyd & Nord, 1992; Cueto et al., 1997; Easter et al., 1992; Geis & Kim, 1995).

With growing reports of its therapeutic efficacy, laparoscopy quickly became the preferential route of access for the treatment of acute cholecystitis (Z'graggen et al., 1995; Colonval et al., 1997) and was also standardized for the treatment of acute appendicitis, adnexial diseases, and perforated gastric or duodenal ulcers (Branicki, 2002; Sauerland et al., 2006). It also represents an alternative access route for the exploration of the bile ducts (Tagorona et al., 1995), necrosectomy and drainage of collection in acute pancreatitis (Pamoukian & Gagner, 2001).

There is a growing use of laparoscopy in peritonitis secondary to the perforation of diverticular disease of the colons as an option for cavity washing and drainage, and for the resection of the segment involved, especially in elective procedures (Tonelli et al., 2009; Chatzimavroudis et al., 2009). Selected cases of intestinal obstruction or perforation with early intervention before the installation of sepsis or of circulatory shock can also benefit from a laparoscopic access (Branicki, 2002).

2. Laparoscopy in peritonitis

Although DL represents a standard procedure for critically ill patients with an acute abdomen (Pecoraro et al., 2001), there is controversy about its therapeutic use in the presence of sepsis and of hemodynamic repercussions. The insufflation of CO₂ into the

peritoneal cavity reduces the peritoneal immunity mediated by macrophages, with lower production of inflammatory cytokines (IL-1, IL-6, TNF- α). However, laparoscopic surgery is associated with a lower systemic inflammatory response compared to open surgery (Buunen et al., 2004). Studies of the effect of laparoscopy in an animal model of severe peritonitis have obtained conflicting results (Bloechle et al., 1998; Gurtner et al., 1995; Salgado Jr et al., 2008; Wichterman et al., 1979).

There is experimental evidence that pneumoperitoneum predisposes to bacterial translocation and increases the systemic inflammatory response (Bloechle et al., 1998), but other studies have not confirmed this finding (Gurtner et al., 1995; Wichterman et al., 1979).

In a model of peritonitis induced by bacterial inoculation in rats subjected to laparoscopy, elevation of the abdominal wall and laparotomy, the changes of the peritoneal immune system in response to the abdominal infection were lower in the group treated by laparoscopy (Targarona et al., 2006). In a similar study, the number of bacterial colonies obtained in the peritoneal fluid, the rates of positive blood cultures and the peritoneal levels of IL-1 and IL-6 were significantly lower after 24 and 72 hs in the groups subjected to laparoscopy. CO₂ did not appear to influence bacterial growth (Balague et al., 1999)

The incidence of bacteremia due to *B. fragilis* and *E. faecalis* was lower in secondary experimental bacterial peritonitis submitted to washing of the cavity by laparoscopy compared to laparotomy even when the duration of peritonitis exceeded 3 hs, suggesting that laparoscopy produces a lower local trauma and preserves the intra-abdominal conditions (Linhares et al., 2001)

In an experimental rat model of severe bacterial peritonitis (Figure 1) it was demonstrated that antibiotic therapy and an early approach to the abdominal cavity by laparotomy or laparoscopy had similar effects on survival. The approach to the abdominal cavity by laparoscopy induces a greater elevation of the pro-inflammatory cytokines TNF- α and IL-6 compared to laparotomy, but when the procedures are associated with the use of broad spectrum antibiotic therapy (gentamicin and metronidazole) there is no difference between them (Salgado Jr et al., 2008).

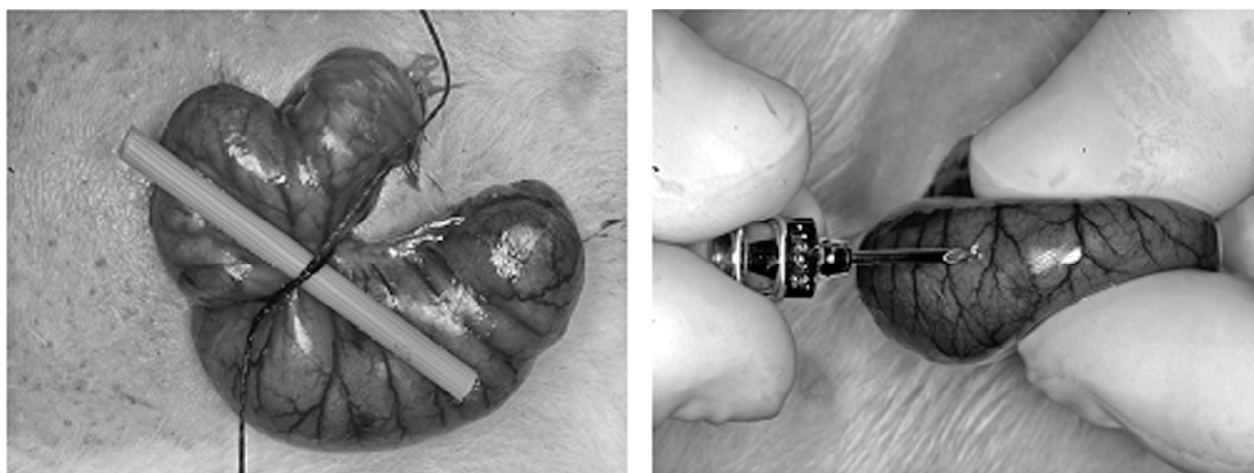


Fig. 1. Experimental model for bacterial peritonitis in rats. Cecal ligation against a rigid mold and 17 gauge needle puncture (Salgado Jr et al., 2008).

Pneumoperitoneum induces an increase in circulating endotoxin but the survival of animals treated by the laparoscopic route is greater than that of animals subjected to laparotomy,

indicating that the overall result of the laparoscopic method may be superior (Chatzimavroudis et al., 2009).

Today, hemodynamic instability is still a limiting factor regarding the use of laparoscopy. The lack of appropriate equipment and of a qualified team continues to be an absolute contraindication of the method. Abdominal distention poses additional risks and reduces the yield of this access route (Stefanidis et al., 2009).

The early use of laparoscopy in an acute abdomen is defended as an appropriate method to prevent a delay in obtaining a definitive diagnosis. Diagnostic laparoscopy within 48 h of hospital admission provided a definitive diagnosis in 90% of cases and modified the clinical diagnosis in 30% of them. A significant portion of patients (83%) were submitted to the laparoscopic procedure as the final treatment of their conditions, with a 7% rate of conversion to open surgery. Peritonitis was present in 180 patients and there was one postoperative death involving a patient with a perforated gastric neoplasia (Golash & Willson, 2005).

An etiologic diagnosis of a non-traumatic acute abdomen by laparoscopy was obtained in 98.6% of cases. The surgical treatment was performed by the laparoscopic route in 75% of the patients and by laparotomy directed by the laparoscopic diagnosis in 13%. Due to a diagnostic error in 2 cases of intestinal obstruction in patients with no abdominal surgery, in this situation the authors recommend laparotomy or investigation by means of other exams (Kirshtein et al., 2003).

The 2005 Consensus of the European Association of Endoscopic Surgery recommends the use of all non-surgical diagnostic means in order to obtain the etiologic diagnosis in patients with a non-traumatic acute abdomen. If the etiology is not detected, DL should be indicated. A perforated peptic ulcer, appendicitis, acute cholecystitis and pelvic inflammatory disease should be treated by the laparoscopic route. The benefits regarding other etiologies have not been sufficiently clarified (Sauerland et al., 2006).

3. Laparoscopy in nonspecific abdominal pain and abdominal sepsis

Nonspecific acute abdominal pain is characterized by a duration of less than 7 days and by diagnostic uncertainty after basic clinical and laboratory evaluation. Under these circumstances, DL is useful for establishing the etiology by means of direct inspection of large areas of the surface of abdominal organs and for obtaining material for biopsy, culture and aspirate, with complementation by laparoscopic ultrasonography. In most cases it is also possible to perform a therapeutic intervention by the same route of access (Stefanidis et al., 2009).

The accuracy of DL ranges from 70 to 99% and its use reduces the time of hospitalization without interfering with morbidity when compared to expectant management of nonspecific abdominal pain (Cueta et al., 1998; Cueto et al., 1997; Decadt et al., 1999; Fahel et al., 1999; Gaita et al., 2002; Golash & Willson, 2005; Majewski, 2000; Navez et al., 1995; Ou & Rowbotham, 2000; Poulin et al., 2000; Sanna et al., 2003; So`zu`er et al., 2000; Stefa`nson et al., 1997).

DL is also useful in intensive care when the abdomen is the suspected source of sepsis, of systemic inflammatory response syndrome (SIRS) or multiple organ failure. DL can be used in critically ill patients who present abdominal pain with peritonism accompanied by some signs and symptoms of an inflammatory process, but still without an indication of laparotomy (Stefanidis et al., 2009).

DL can be performed by the bedside, a fact that avoids the risk associated with the transportation of intensive care patients. The contraindications of DL are the same as those for any laparoscopic intervention: hypercapnia, clotting disorder with no possibility of correction, mutliple previous abdrominal surgeries with adhesions, and abdominal surgery in the last 30 days. The use of pneumoperitoneum pressure of 8 to 12 mmHg is recommended, although some authors have used pressures of up to 15 mm Hg with no adverse consequences under these circumstances (Stefanidis et al., 2009).

The diagnostic accuracy of DL in intensive care patients is 90 to 100% (Almeida et al., 1995; Brandt et al., 1993; Brandt et al., 1994; Gagne et al., 2002; Hackert et al., 2003; Jaramillo et al., 2006; Kelly et al., 2000; Orlando & Crowell, 1997; Pecoraro et al., 2001; Walsh & Hoadley, 1998). These success rates are due to the more frequent abdominal diseases occurring in this population (acalculous acute cholecystitis and mesenteric ischemia). The method may fail to detect retroperitoneal processes such as pancreatitis (Stefanidis et al., 2009).

Several studies which evaluated the resolutive capacity of laparoscopy in different clinical situations are summarized in Table 1.

Clinical Setting	Study	N	Study type	Laparoscopy Resolution (%)	Morbidity (%)	Mortality (%)
Acute abdomen	Cueto et al., 1997	107	Review	87,9	14	4,6
Acute abdomen	Perri et al., 2002	221	Review	87%	3	0,5
Acute Abdomen	Golash & Willson, 2005	1320	Retrospective	83	0,9	0,07
ICU	Brandt et al., 1993	25	Clinical series (retrospective)		8	0
Perforated duodenal ulcer	Druart et al., 1997	100	Prospective	92	9	5
Acute Cholecystitis	Z'Graggen et al., 1995	103	Prospective	95,1	10,7	0
Acute Cholecystitis	Colonval et al. , 1997	221	Retrospective	90	13,5	0,9
Small Bowel Obstruction	Kirshtein et al., 2003	44	Retrospective	52	6,4	4,5
Diverticular disease	Torenvliet et al., 2010	231	Review	95,7%	10,4	1,7

Table 1. Evidence for the use of laparoscopy for diagnosis and for some therapeutic purposes in clinical practice.

4. Laparoscopy in acute appendicitis

Appropriate clinical history and physical examination are sufficient for the correct diagnosis of acute appendicitis with typical clinical presentation, a context within which imaging exams are of little value. Computed tomography (CT) is the most valuable exam when there is a diagnostic doubt in acute appendicitis and its complications. CT has 94 to 98%

sensitivity, 83 to 100% specificity and 93 to 96% accuracy and can reduce the number of unnecessary laparoscopies and laparotomies (Spirit et al., 2010).

Appendectomy by the laparoscopic route yields better results than treatment by laparotomy, especially in patients with disease in the gangrenous phase or with perforation and localized peritonitis. There are isolated reports of the limitation of laparoscopic appendectomy in patients with diffuse peritonitis due to the difficulty in cleaning the peritoneal cavity, the debris and the infected secretion, whereas most reports emphasize the resources of laparoscopic surgery in terms of providing a view of the peritoneal cavity and its recesses, with similar or even more satisfactory conditions for washing the peritoneal cavity compared to laparotomy (Saeurland et al., 2006).

For acute appendicitis, the laparoscopic approach reduces the levels of infection of the surgical wound and favors a more rapid return to habitual activities for the patient compared to laparotomy. Women of reproductive age benefit more from laparoscopy, but other groups also experience this advantage. Laparoscopic treatment of acute appendicitis is also recommended in cases of perforation and contamination of the cavity (Saeurland et al., 2006).

A cohort study was conducted at various academic and private medical centers in the United States to compare laparoscopy and laparotomy for appendectomy. There was no difference in mortality between groups and the group subjected to laparoscopy had a lower incidence of infection of the surgical wound and of episodes of sepsis. The group subjected to laparotomy had a lower incidence of abdominal abscesses and, according to the authors, the approaches yielded similar results (Hemmila et al., 2010).

Among the advantages of the laparoscopic method are the possibility of complete inspection of the abdominal cavity, the preservation of the appendix when normal, and the opportunity to also treat by the laparoscopic route or by guided laparotomy other inflammatory processes or processes of varied characteristics detected on the occasion of inspection (Saeurland et al., 2006).

5. Laparoscopy in abdominal sepsis due to affections of the small bowel (mesenteric ischemia, intestinal obstruction and incarcerated hernias)

Peritonitis secondary to obstruction or ischemia of the small bowel is infrequent. According to the most recent consensus about obstructive intestinal processes, conservative treatment may be maintained for up to 72 hours as long as there is no evidence of strangulation or incarceration. After 3 days of expectant treatment, whether or not these signs are present, surgical exploration is obligatory (Catena et al., 2011).

Some evidence supports the use of the laparoscopic route in the lysis of abdominal adhesions and in the treatment of incarcerated hernias before the onset of necrosis and perforation of the intestinal loops. After the occurrence of these events, most authors recommend surgery by laparotomy (Saeurland et al., 2006).

The lysis of adhesions by laparotomy, the universally accepted route of access for this situation, leads to the later formation of new adhesions, to recurrent intestinal obstruction and to a new laparotomy in 10 to 30% of cases (Landercaasper et al., 1993).

In animal models, laparoscopy showed a lower incidence and a smaller number of adhesions, as well as a less severe obstructive situation compared to open surgery. Thus, the laparoscopic approach, when viable, can be considered to prevent obstruction due to adhesions (Tittel et al., 2001). Other clinical and experimental studies have also shown

evidence of a lesser formation of adhesions at the surgical site and on the abdominal wall when laparoscopy is used (Gadallah et al., 2001; Gamal et al., 2001).

The lysis of adhesions by the laparoscopic route has several theoretical advantages over open surgery: 1) less intense postoperative pain, 2) more rapid resolution of the ileum, 3) shorter hospitalization, 4) earlier return to daily activities, 5) lower incidence of complications of the surgical wound, and 6) a reduced formation of postoperative adhesions (Nagle et al., 2004). However, no randomized and controlled studies comparing adhesion lysis by the laparoscopic and open route were detected. Thus, the indications and the results of the less invasive procedure continue to be unclear (Catena et al., 2011).

Today laparoscopy should be reserved for well selected cases, with the use of an open technique for the initiation of pneumoperitoneum, preferentially in the upper left quadrant of the abdomen. It is preferable to use it in case of a first obstructive episode and also when a single or a few adhesions are predicted (for example, when the previous surgery was an appendectomy). A high rate of conversion is expected and the risk of damage to bowel is higher compared to surgery by laparotomy. Findings of a bowel segment larger than 4 cm, of multiple adhesions and of findings compatible with malignant neoplasias supports the option for conversion (Catena et al., 2011).

The extent of release of adhesions is a matter of debate and divides the opinion of authors between the option for lysis of all adhesions in the cavity in an attempt to prevent a new obstructive event or sufficient release for the resolution of obstruction (Scott-Coombes et al., 2003).

Treatment of abdominal wall hernias by laparoscopy has progressed considerably over the last decades and in general this is considered to be the access route of choice in an elective situation. However, it is not possible to transfer the knowledge acquired with this practice to urgency situations such as incarceration, strangulation and bowel injury with contamination of the cavity and infection. There are isolated reports of favorable results for properly selected cases treated by experienced surgeons (Saeurland et al., 2006).

The contribution of laparoscopy to mesenteric ischemia is small. For this situation, DL is less precise than angiography and CT and has not proved to be able to reduce the number of unnecessary laparotomies. DL can detect ischemia when present but cannot rule out this diagnosis when the intestinal loops have a normal appearance upon laparoscopy (Saeurland et al., 2006).

6. Laparoscopy in peritonitis due to gynecological causes

Gynecological affections should always be part of the clinical reasoning in the evaluation of abdominal pain in women. The more frequent causes of abdominal and pelvic pain are ectopic pregnancy, salpingo-oophoritis, pelvic adhesions, endometriosis, and ovarian cysts. In contrast to abdominal processes, CT is less valuable in these conditions. Transvaginal and conventional ultrasonography with a pregnancy test for women of reproductive age are part of the initial evaluation. DL is superior to all other tests and can correct the preoperative diagnosis in up to 40% of cases (Saeurland et al., 2006).

7. Laparoscopy in trauma

DL has been indicated for victims of trauma with suspected intra-abdominal injuries in order to reduce the rate of non-therapeutic laparotomies with their morbidity, mortality and

costs. The indications of DL include the suspicion of intra-abdominal injury maintained after an initial negative workup in closed traumas, stab wounds with proven or possible penetration of the cavity, gun-shot wounds with a possible intra-abdominal course, a diagnosis of diaphragm perforation in penetrating wounds of the thoraco-abdominal region, and the creation of a pericardiac transdiaphragmatic window to rule out heart injury (Stefanidis et al., 2009).

Absolute contraindications of DL are hemodynamic instability due to hemorrhagic shock or evisceration, and the relative contraindications include peritonitis, known or obvious intra-abdominal injury, posterior penetrating trauma with a high probability of intestinal injury and, of course, the lack of experienced professionals and of appropriate equipment (Stefanidis et al., 2009).

The accuracy of DL in defining the need for laparotomy ranges from 75 to 100%. In a review, DL prevented non-therapeutic laparotomy in 17 to 89% (median: 57%) of traumatized patients. The procedure involved a 6% rate of false-positive results (0-44%). In addition to providing an etiologic diagnosis, laparoscopy permits the appropriate treatment of intracavity injuries in up to 83% of cases (Hori, 2008).

A review of 37 studies including more than 1900 patients revealed a rate of DL complication of 1% (Villavicencio & Aucar, 1999). More recent reviews have revealed even lower rates close to zero. Intraoperative complications may occur during the creation of the pneumoperitoneum, the introduction of trochars, the occurrence of pneumothorax during inspection due to an unidentified diaphragmatic injury, during the perforation of hollow viscera, the laceration of solid viscera, during gas dissection in the subcutaneous layer of the peritoneum and vascular injuries (more frequently of the epigastric or epiploic arteries) (Hori, 2008).

8. Laparoscopy in the perforation of diverticular disease of the colon

Perforation of diverticular colon disease, generally in the sigmoid colon, with localized contamination of the abdominal cavity can be treated with antibiotics during the early stages, but abscesses larger than 5 cm must be approached surgically. Sigmoidectomy is indicated in patients who have suffered at least 2 crises of diverticulitis and in patients younger than 50 years who have suffered only one episode (Saeurland et al., 2006). Even within an urgency context, this surgery can be performed by the laparoscopic route with a surgical time and results comparable to those of laparotomy and has been performed with a conversion rate of 10% (Tonelli et al., 2009).

Over the last few years, there has been an increased use of peritoneal washing and drainage of the cavity by the laparoscopic route without resection, allied to antibiotic treatment during the episode of peritonitis secondary to diverticular perforation. Definite treatment by colectomy can be performed in an elective manner after the resolution of the inflammatory process (Saeurland et al., 2006; Tonelli et al., 2009).

In a systematic literature review of 231 cases of acute diverticulitis with purulent peritonitis treated in this manner, abdominal sepsis was effectively controlled in 95.7% of the patients. Mortality was 1.7%, morbidity was 10.4% and 1.7% of the patients required a stoma. A long recurrence-free period of time was observed in the patients not subjected to colon resection, and later elective resection of the segment involved by the laparoscopic route was possible in most cases (Toorenvliet et al., 2010).

Although most studies are retrospective, this conservative approach has a clear advantage. However, there is a consensus on the fact that laparoscopic washing and drainage is not recommended for cases of fecal peritonitis, and the results are unsatisfactory for cases of formation of an abscess in the pelvis. Several prospective and randomized studies are being conducted in order to better define in which clinical situations this approach should be indicated (Toorenvliet et al., 2010).

9. Conclusion

Access by laparoscopy seems to be of advantage over laparotomy as a diagnostic and therapeutic method in the approach to peritonitis and sepsis of abdominal origin by involving a lower surgical trauma, by providing a good field of view of the peritoneal cavity and by permitting to obtain tissue and fluid samples under direct vision. The rate of unnecessary laparotomies can be reduced when laparoscopy is used for a diagnostic and therapeutic approach in cases of acute abdomen, even in the presence of peritonitis or sepsis of abdominal origin.

In the management of peritonitis by laparoscopy, the inflammatory response is milder compared to management by laparotomy. The elevation of inflammatory cytokines is moderate and macrophages present a better basal immunologic performance. In contrast to what occurs with laparotomy, the acute phase of the inflammatory response associated with perioperative sepsis is attenuated during laparoscopy, and the immune function seems to be better preserved after the latter.

Despite the doubts about the feasibility and efficiency of laparoscopy compared to laparotomy for the approach to peritonitis, minimally invasive surgery is gaining acceptance among surgeons, especially regarding patients with abdominal sepsis.

10. Acknowledgments

Financial support: Fundação Waldemar Barnsley Pessoa

11. References

- Almeida J, Sleeman D, Sosa JL, Puente I, McKenney M & Martin L. (1995). Acalculous cholecystitis: the use of diagnostic laparoscopy. *J Laparoendosc Surg*, Vol. 5, pp. (227–231).
- Balague C, Targarona EM, Pujol M, Fillela X, Espert JJ & Trias M. (1999). Peritoneal response to a septic challenge comparison between open laparotomy, pneumoperitoneum laparoscopy, and wall lift laparoscopy. *Surg Endosc*, Vol.13, pp. (792–796).
- Bloechle C, Emmermann A, Strate T, Scheurlen UJ, Schneider C, Achilles E, Wolf M, Mack D, Zornig C & Broelsch CE (1998). Laparoscopic versus open repair of gastric perforation and abdominal lavage of associated peritonitis in pigs. *Surg Endosc*, Vol. 12, pp. (212–218).
- Boyd WP Jr & Nord HJ (2000). Diagnostic Laparoscopy. *Endoscopy*, Vol. 32, No.2, pp. (153–158)
- Brandt CP, Priebe PP & Eckhauser ML. (1993). Diagnostic laparoscopy in the intensive care patient. Avoiding the nontherapeutic laparotomy. *Surg Endosc*, Vol. 7, No.3, pp. (168–172).

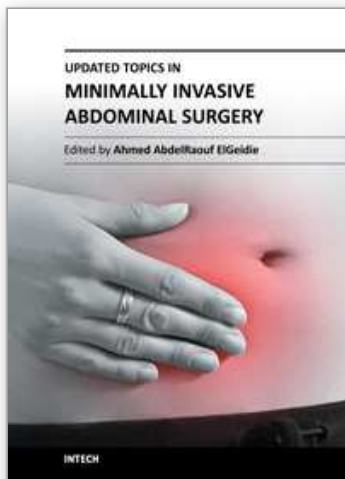
- Brandt CP, Priebe PP, & Jacobs DG. (1994). Value of laparoscopy in trauma ICU patients with suspected acute acalculous cholecystitis. *Surg Endosc*, Vol. 8, pp.(361–364).
- Branicki FJ. Abdominal Emergencies: Diagnostic and Therapeutic Laparoscopy (2002). *Surgical Infections*, Vol. 3, No.3, pp. (269-282).
- Buunen M, Gholghesaei M, ET, Veldkamp R, Meijer DW, Bonjer HJ & Bouvy ND. (2004). Stress response to laparoscopic surgery. *Surg Endosc*, Vol.18. pp. (1022-1028).
- Catena F, Di Saverio S, Kelly MD, Biffi WL, Ansaloni L, Mandalá V, Velmahos GC, Sartelli M, Tugnoli G, Lupo M, Mandalá S, Pinna AD, Sugarbaker PH, Van Goor H, Moore EE & Jeekel J. (2011). Bologna Guidelines for Diagnosis and Management of Adhesive Small Bowel Obstruction (ASBO): 2010 Evidence Based Guidelines of the World Society of Emergency Surgery. *World Journal of Emergency Surgery*, Vol. 21, pp. (6.5).
- Chatzimavroudis G, Pavlidis TE, Koutelidakis I, Giamarrellos-Borboulis EJ, Atmatzidis S, Kountopoulou U, Marikis G & Atmatzidis KI. (2009). CO₂ Pneumoperitoneum Prolongs survival in an animal model of peritonitis compared to laparotomy. *Journal of Surgical Research*, Vol. 152, pp. (69–75).
- Colonval P, Navez B, Cambier E, Richir C, de Pierpont B, Scohy JJ & Guiot P. (1997). Is laparoscopic cholecystectomy effective and reliable in acute cholecystitis? Results of a prospective study of 221 pathologically documented cases. *Arch Chir*, Vol. 51, No. 7, pp. (689-696).
- Cuesta MA, Eijsbouts QA, Gordijn RV, Borgstein PJ & De Jong D. (1998). Diagnostic laparoscopy in patients with an acute abdomen of uncertain etiology. *Surg Endosc*, Vol. 12, pp. (915-917).
- Cueto J, Díaz O, Garteiz D, Rodríguez M & Weber A. (1997). The efficacy of laparoscopic surgery in the diagnosis and treatment of peritonitis. *Surg Endosc*, Vol. 11, pp. (366-370).
- Decadt B, Sussman L, Lewis MP, Secker A, Cohen L, Rogers C, Patel A & Rhodes M. (1999). Randomized clinical trial of early laparoscopy in the management of acute nonspecific abdominal pain. *Br J Surg*, Vol. 86, pp. (1383–1386).
- Easter DW, Cuschieri A, Nathanson LK & Lavelle-Jones M. (1992). The utility of diagnostic laparoscopy for abdominal disorders. Audit of 120 patients. *Arch Surg*, Vol. 127, No. 4, pp. (379-383)
- Fahel E, Amaral PC, Filho EM, Ettinger JE, Souza EL, Fortes MF, Alcantara RS, Regis AB, Neto MP, Sousa MM, Fogagnoli WG, Cunha AG, Castro MM & Santana PA Jr. (1999). Nontraumatic acute abdomen: videolaparoscopic approach. *JSLs*, Vol. 3, pp. (187–192).
- Forde KA & Treat MR. (1992). The role of peritoneoscopy (laparoscopy) in the evaluation of the acute abdomen in critically ill patients. *Surg Endosc*, Vol. 6, No.5, pp. (219-221).
- Gadallah MF, Torres-Rivera C, Ramdeen G, Myrick S, Habashi S & Andrews G. (2001). Relationship between intraperitoneal bleeding, adhesions, and peritoneal dialysis catheter failure: a method of prevention. *Adv Perit Dial*, Vol. 17, pp.(127-129).
- Gagne´ DJ, Malay MB, Hogle NJ & Fowler DL. (2002). Bedside diagnostic minilaparoscopy in the intensive care patient. *Surgery*, Vol. 131, pp.(491–496).
- Gaita´n H, Angel E, Sa´nchez J, Go´mez I, Sa´nchez L & Agudelo C. (2002).Laparoscopic diagnosis of acute lower abdominal pain in women of reproductive age. *Int J Gynaecol Obstet*, Vol. 76, pp. (149-158).

- Gamal EM, Metzger P, Szabo G, Brath E, Peto K, Olah A, Kiss J, Furka I & Mikó I. (2001). The influence of intraoperative complications on adhesion formation during laparoscopic and conventional cholecystectomy in an animal model. *Surg Endosc*, Vol. 15, pp.(873-877).
- Geis WP & Kim HC. (1995). Use of laparoscopy in the diagnosis and treatment of patients with surgical abdominal sepsis. *Surg Endosc*, Vol.9, pp. (178-182).
- Golash V, Willson PD. Early laparoscopy as a routine procedure in the management of acute abdominal pain: a review of 1,320 patients. *Surg Endosc*. 2005;19(7):882-885
- Gurtner GC, Robertson CS, Chung SCS, Ling TKW, Ip SM & Li AKC (1995). Effect of carbon dioxide pneumoperitoneum on bacteraemia and endotoxaemia in an animal model of peritonitis. *Br J Surg*, Vol. 82, pp. (844-848).
- Hackert T, Kienle P, Weitz J, Werner J, Szabo G, Hagl S, Bu'chler MW & Schmidt J. (2003). Accuracy of diagnostic laparoscopy for early diagnosis of abdominal complications after cardiac surgery. *Surg Endosc*, Vol.17, pp. (1671-1674)
- Hemmila MR, Birkmeyer NJ, Arbabi S, Osborne NH, Wahl WL & Dimick JB. (2010). Introduction to Propensity Scores. A case study on the comparative effectiveness of laparoscopic vs open appendectomy. *Archives of Surgery*, Vol. 145, No. 10, pp. (939-945).
- Hori Y. (2008). SAGES Guidelines Committee. Diagnostic laparoscopy guidelines: This guideline was prepared by the SAGES Guidelines Committee and reviewed and approved by the Board of Governors of the Society of American Gastrointestinal and Endoscopic Surgeons (SAGES). *Surg Endosc*. Vol. 22, No. 5, pp. (1353-1383).
- Jaramillo EJ, Trevino JM, Berghoff KR & Franklin ME Jr. (2006). Bedside diagnostic laparoscopy in the intensive care unit: a 13-year experience. *JSLS*, Vol.10, pp. (155-159).
- Kelly JJ, Puyana JC, Callery MP, Yood SM, Sandor A & Litwin DE. (2000). The feasibility and accuracy of diagnostic laparoscopy in the septic ICU patient. *Surg Endosc*, Vol. 14, pp. (617-621).
- Kirshtein B, Roy-Shapira A, Lantsberg L, Mandel S, Avinoach E & Mizrahi S. (2003). The use of laparoscopy in abdominal emergencies. *Surg Endosc*, Vol. 17, pp. (1118-1124).
- Landercasper J, Cogbill TH, Merry WH, Stolle RT & Strutt PJ. (1993). Long-term outcome after hospitalization for small-bowel obstruction. *Arch Surg*, Vol. 128, pp.(765-770).
- Linhares L, Jeanpierre H, Borie F, Fingerhut A & Millat B. (2001). Lavage by laparoscopy fares better than lavage by laparotomy: experimental evidence. *Surg Endosc*, Vol. 15, No. 1, pp. (85-89).
- Llanio R & Sarle H. (1956). Interet de La peritoneoscope chez politraumatises. *Marseille Chirurg*, Vol. 8, pp. (82-86).
- M. L. Druart, R. Van Hee, J. Etienne, G. B. Cadie`re, J. F. Gigot, M. Legrand, J. M. Limbosch, B. Navez, M. Tugilimana, E. Van Vyve, L. Vereecken,3 E & Wubin, J. P. (1997). Yvergnaux Laparoscopic repair of perforated duodenal ulcer. A prospective multicenter clinical trial. *Surgical Endoscopy*, Vol. 11, pp. (1017-1020)
- Majewski W. (2000). Diagnostic laparoscopy for the acute abdomen and trauma. *Surg Endosc*, Vol. 14, pp. (930-937).
- Nagle A, Ujiki M, Denham W & Murayama K. (2004). Laparoscopic adhesiolysis for small bowel obstruction. *Am J Surg*, Vol. 187, No. 4, pp. (464-470).

- Navez B, d'Udekem Y, Cambier E, Richir C, de Pierpont B & Guiot P. (1995). Laparoscopy for management of nontraumatic acute abdomen. *World J Surg*, Vol. 19, (382–386).
- Orlando R III & Crowell KL. (1997). Laparoscopy in the critically ill. *Surg Endosc*, Vol. 11, pp. (1072–1074)
- Ou CS & Rowbotham R. (2000). Laparoscopic diagnosis and treatment of nontraumatic acute abdominal pain in women. *J Laparoendosc Adv Surg Tech A*, Vol.10, pp (41–45).
- Pamoukian VN & Gagner M. (2001). Laparoscopic necrosectomy for acute necrotizing pancreatitis. *J Hepatobiliary Pancreatic Surg*, Vol. 8, No. 3, pp. (221–223).
- Pecoraro AP, Cacchione RN, Sayad P, Williams ME & Ferzli GS. (2001). The routine use of diagnostic laparoscopy in the Intensive Care Unit. *Surg Endosc*, Vol. 15, pp. (638–641).
- Perri SG, Altilia F, Pietrangeli F, Dalla Torre A, Gabbrielli F, Amendolara M, Nicita A, Nardi M Jr, Lotti R & Citone G. (2002). Laparoscopy in abdominal emergencies. Indications and limitations. *Chir Ital*, Vol. 54, No. 2, pp. (165–178).
- Poulin EC, Schlachta CM & Mamazza J. (2000). Early laparoscopy to help diagnose acute nonspecific abdominal pain. *Lancet*, Vol. 355, pp. (861–863).
- Salgado Jr W, Santos JS & Cunha FQ (2008) The effect of laparoscopic Access and antibiotics on the outcome of severe bacterial peritonitis in rats. *Journal of Laparoscopy and Advanced Surgery Techniques*, Vol.18, No.1, pp.(5-12).
- Sanna A, Adani GL, Anania G & Donini A. (2003). The role of laparoscopy in patients with suspected peritonitis: experience of a single institution. *J Laparoendosc Adv Surg Tech A*, Vol.13, pp. (17–19).
- Sauerland S, Agresta F, Bergamaschi R, Borzelino Z, Budzynski A, Champault G, Fingerhut A, Isla A, Johansson M, Lundorff P, Navez B, Saad S & Neugebauer EA. (2006). Laparoscopy for abdominal emergencies: evidence-based guidelines of the European Association for Endoscopic Surgery (EAES). *Surg Endosc*, Vol. 20, pp.(14–29).
- Scott-Coombs Dm, Vinpond MN & Thompson JM. (1993). General surgeons attitudes to the treatment and prevention of abdominal adhesions. *Annals of the Royal College of Surgeons of England*, Vol. 75, pp. (123–128).
- So‘zu‘er EM, Bedirli A, Ulusal M, Kayhan E & Yilmaz Z. (2000). Laparoscopy for diagnosis and treatment of acute abdominal pain. *J Laparoendosc Adv Surg Tech A*, Vol. 10, pp. (203–207).
- Spirt MJ. (2010). Complicated intra-abdominal infections: a focus on appendicitis and diverticulitis. *Postgrad Med*, Vol. 122, No.1, pp. (39–51).
- Stefansson T, Nyman R, Nilsson S, Ekbom A & Pahlman L. (1997). Diverticulitis of the sigmoid colon: a comparison of CT, colonic enema, and laparoscopy. *Acta Radiologica*, Vol. 38, pp. (313–319).
- Stefanidis D, Richardson WS, Chang L, Earle DB & Fanelli RD. (2009). The role of diagnostic laparoscopy for acute abdominal conditions: an evidence based review. *Surg Endosc*, Vol. 23, pp. (16–23).
- Targarona EM, Balagué C, Espert JJ, Pérez Ayuso RM, Ros E, Navarro S, Bordas J, Téres J, & Trias M. (1995). Laparoscopic treatment of acute biliary pancreatitis. *Int Surg*, Vol. 80, No. 4, pp. (365–368).
- Targarona EM, Rodríguez M, Camacho M, Balagué C, Gich I, Vila L & Trias M. (2006). Immediate peritoneal response to bacterial contamination during laparoscopic surgery. *Surg Endosc*, Vol. 20, No. 2, pp. (316–321).

- Tittel A, Treutner KH, Titkova S, Ottinger A & Schumpelick V. (2001). Comparison of adhesion reformation after laparoscopic and conventional adhesiolysis in an animal model. Langenbeck's. *Arch Surg*, Vol. 386, pp. (141-145).
- Tonelli F, Di Carlo V, Liscia G & Serventi A. (2009) Diverticular disease of the colon: diagnosis and treatment. Consensus Conference, 5th National Congress of the Italian Society of Academic Surgeons. *Ann Ital Chir*, Vol. 80, No.1, pp. (3-8).
- Toorenvliet BR, Swank H, Schoones JW, Hamming JF & Bemelman WA. Laparoscopic peritoneal lavage for perforated colonic diverticulitis: a systematic review. *Colorectal disease*, Vol. 12, pp. (862-867).
- Villavicencio, RT & Aucar, JA. (1999). Analysis of Laparoscopy in Trauma. Review. *Journal of the American College of Surgeons*, Vol. 189, No.1, pp. (11-20).
- Walsh RM, Popovich MJ & Hoadley J. (1998). Bedside diagnostic laparoscopy and peritoneal lavage in the Intensive Care Unit. *Surg Endosc*, Vol. 12, pp.(1405-1409).
- Wichterman KA, Chaudry IH & Baue AE (1979). Studies of peripheral glucose uptake during sepsis. *Arch Surg*, Vol. 114, pp (740-750).
- Z'graggen K, Metzger A, Birrer S & Klaiber C (1995). Laparoscopic cholecystectomy as standard therapy in acute cholecystitis. A prospective study. *Chirurg*, Vol. 66, No.4, pp. (366-370).

IntechOpen



Updated Topics in Minimally Invasive Abdominal Surgery

Edited by Prof. Ahmed Elgeidie

ISBN 978-953-307-773-4

Hard cover, 246 pages

Publisher InTech

Published online 14, November, 2011

Published in print edition November, 2011

Updated topics in minimally invasive abdominal surgery provides surgeons interested in minimally invasive abdominal surgery with the most recent techniques and discussions in laparoscopic surgery. This book includes different topics covering a big variety of medical conditions with up-to-date information. It discusses many controversies in a clear and user-friendly manner. This book is made for young junior surgeons in training and also senior surgeons who need to know the most recent work in the field of laparoscopy. To make the material easily digestible, we provided the book with many figures and illustrations for different procedures and technical pearls.

How to reference

In order to correctly reference this scholarly work, feel free to copy and paste the following:

José Sebastião Santos, Carlos A.M. Donadelli, Rafael Kemp, Alberto Facury Gaspar and Wilson Salgado Jr. (2011). Laparoscopic Approach to Abdominal Sepsis, Updated Topics in Minimally Invasive Abdominal Surgery, Prof. Ahmed Elgeidie (Ed.), ISBN: 978-953-307-773-4, InTech, Available from: <http://www.intechopen.com/books/updated-topics-in-minimally-invasive-abdominal-surgery/laparoscopic-approach-to-abdominal-sepsis>

INTech
open science | open minds

InTech Europe

University Campus STeP Ri
Slavka Krautzeka 83/A
51000 Rijeka, Croatia
Phone: +385 (51) 770 447
Fax: +385 (51) 686 166
www.intechopen.com

InTech China

Unit 405, Office Block, Hotel Equatorial Shanghai
No.65, Yan An Road (West), Shanghai, 200040, China
中国上海市延安西路65号上海国际贵都大饭店办公楼405单元
Phone: +86-21-62489820
Fax: +86-21-62489821

© 2011 The Author(s). Licensee IntechOpen. This is an open access article distributed under the terms of the [Creative Commons Attribution 3.0 License](https://creativecommons.org/licenses/by/3.0/), which permits unrestricted use, distribution, and reproduction in any medium, provided the original work is properly cited.

IntechOpen

IntechOpen