

We are IntechOpen, the world's leading publisher of Open Access books Built by scientists, for scientists

6,900

Open access books available

186,000

International authors and editors

200M

Downloads

Our authors are among the

154

Countries delivered to

TOP 1%

most cited scientists

12.2%

Contributors from top 500 universities



WEB OF SCIENCE™

Selection of our books indexed in the Book Citation Index
in Web of Science™ Core Collection (BKCI)

Interested in publishing with us?
Contact book.department@intechopen.com

Numbers displayed above are based on latest data collected.
For more information visit www.intechopen.com



Encephalitis Due to Free Living Amoebae: An Emerging Issue in Human Health

Jacob Lorenzo-Morales, Carmen M^a Martín-Navarro,
Enrique Martínez-Carretero, José E. Piñero
and Basilio Valladares

*University Institute of Tropical Diseases and Public Health of the Canary Islands,
University of La Laguna, Tenerife, Canary Islands
Spain*

1. Introduction

Free-living amoebae (FLA) belonging to *Acanthamoeba* and *Sappinia* genera as well as *Balamuthia mandrillaris* and *Naegleria fowleri* species are aerobic, mitochondriate, eukaryotic protists that occur worldwide and can potentially cause infections in humans and other animals (Visvesvara and Maguire, 2006; Visvesvara et al., 2007). Due to the fact that these amoebae have the ability to exist as free-living organisms in nature and only occasionally invade a host and live as parasites within host tissue, they have also been called amphizoic amoebae (Page, 1988).

All four amoebae are known so far to cause infections of the central nervous system (CNS). Several species of *Acanthamoeba* (i.e. *A. castellanii*, *A. culbertsoni*, *A. hatchetti*, *A. polyphaga*, *A. rhysodes*), the only known species of *Balamuthia*, *B. mandrillaris*, two species of *Sappinia* genus, *S. diploidea* and *S. pedata*, and only one species of *Naegleria*, *N. fowleri*, are known to cause disease in humans and other animals (Khan, 2006; Visvesvara et al., 2007).

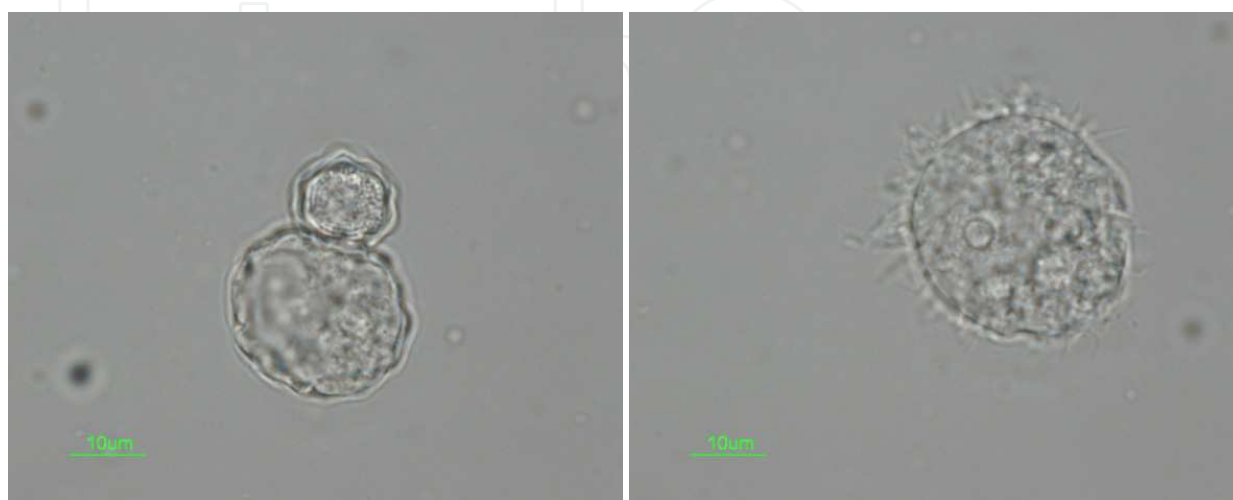

Fig. 1. Trophozoite (right) and Cyst stages (left) in *Acanthamoeba* sp.

2. Central nervous systems infections due to free living amoebae

The waterborne disease Primary Amoebic Meningoencephalitis (PAM) was discovered in Australia in the 1960s. Since then, it has been reported from about 15 other countries in Africa, Asia, Europe and North and South America. PAM is caused by *Naegleria fowleri*, and follows intranasal infection during swimming in warm, contaminated freshwater. Most victims have been children or young adults and the disease is almost invariably fatal. Infections have been linked with warm waters such as above-ground pipelines, tropical lakes, geothermal water, heated swimming pools or discharges of industrial cooling water. Until recent cases in the USA were identified, Australia was the only country where *Naegleria fowleri* has been associated with public water supplies (Visvesvara et al., 2007; Heggie, 2010). Recently, the causal agent of a PAM case in the US was diagnosed as *Paravahlkampfia francinae* n. sp., a new species of the free-living amoeba genus *Paravahlkampfia* that was isolated from the cerebrospinal fluid of a patient with headache, sore throat, and vomiting, presenting typical symptoms of PAM caused by *Naegleria fowleri*. Thus awareness of novel emerging amoebae as causative agents of PAM should also be considered (Visvesvara et al., 2009).

PAM should be suspected in young adults and children with acute neurological symptoms as described below and recent exposure to fresh water. The time from initial contact (swimming, diving, water skiing, or simply immersing head in water) to onset of illness is usually 5–7 days, and may even be as short at 24 h. Because there are no distinctive clinical features that differentiate PAM from acute pyogenic or bacterial meningoencephalitis it is imperative that the attending physician obtains information regarding the patient's contact with fresh water, including hot springs, during the past week. The earliest symptoms are sudden appearance of headaches, high temperature, nuchal rigidity, followed by nausea, vomiting, irritability and restlessness. Nuchal rigidity usually occurs with positive Kernig and Brudzinski signs. Photophobia may occur late in the clinical course, followed by neurological abnormalities, including lethargy, seizures, confusion, coma, diplopia or bizarre behaviour, leading to death within a week. Cranial nerve palsies (third, fourth, and sixth cranial nerves) may indicate brain edema and herniation. Intracranial pressure is usually raised to 600 mm H₂O or higher. Cardiac rhythm abnormalities and myocardial necrosis have been found in some cases (Martinez, 1980; Visvesvara et al., 2007).

CSF may vary in colour from greyish to yellowish-white, and may be tinged red with a few red cells (250 mm⁻³) in the early stages of disease. However, as the disease progresses the red blood cell number increases to as high as 24,600 mm⁻³. The white blood cell count, predominantly polymorphonuclear leukocytes (PMN), also may vary from 300 cells mm⁻³ to as high as 26,000 mm⁻³. No bacteria are seen. The CSF pressure is usually elevated (300–600 mm H₂O). The protein concentration may range from 100 mg per 100 ml to 1000 mg per 100 ml, and glucose may be 10 mg/100 mL or lower (Martinez, 1980; Visvesvara & Maguire, 2006; Visvesvara et al., 2007). The cause of death is usually increased intracranial pressure with brain herniation, leading to cardiopulmonary arrest and pulmonary edema (Martinez, 1980; Visvesvara & Maguire, 2006; Visvesvara et al., 2007).

Many species of *Acanthamoeba* can cause Granulomatous Amoebic Encephalitis (GAE) also known as *Acanthamoeba* Granulomatous Encephalitis (AGE) (Khan, 2006; da Rocha-Azevedo et al., 2009), is a rare, chronic, progressive infection of the CNS that may involve the lungs (da Rocha-Azevedo et al., 2009). AGE is usually associated with an underlying debilitating disease or immune suppressed individuals including HIV-AIDS patients, diabetics,

individuals undergoing organ transplants or cancer chemotherapy, and drug abusers (Khan, 2006; Visvesvara et al., 2007; da Rocha-Azevedo et al., 2009).

Therefore, the onset of AGE is slow and subtle and develops as a chronic disease from several weeks to months (Visvesvara & Maguire, 2006; Visvesvara et al. 2007). The usual features of AGE consist of headache, stiff neck, and mental-state abnormalities, as well as nausea, vomiting, low-grade fever, lethargy, cerebellar ataxia, visual disturbances, hemiparesis, seizures and coma. Facial palsy with numbness resulting in facial asymmetry is often seen. Cerebral hemispheres are usually the most heavily affected CNS tissue. They are often edematous, with extensive hemorrhagic necrosis involving the temporal, parietal, and occipital lobes. Computerized tomography (CT) scans of the brain show large, low-density abnormalities mimicking a single or multiple space-occupying mass. Magnetic resonance imaging (MRI) with enhancements shows multiple, ring-enhancing lesions in the brain (Seijo-Martínez et al., 2000; Shirwadkar et al. 2006; Visvesvara et al., 2007).

Acanthamoeba infecting the CNS are not readily found in the cerebrospinal fluid (CSF), although they have been isolated from the CSF in a few cases. *Acanthamoeba* that had apparently entered from the nasopharynx through a fistula have been detected in the CSF of a patient without CNS disease (Petry et al., 2006). CSF examination in general reveals lymphocytic pleocytosis with mild elevation of protein and normal or slightly depressed glucose. Examination of the autopsied brain reveals cerebral edema, areas of cortical and basal ganglia softening, and multiple necrotic and hemorrhagic areas of CNS tissues. The brainstem, cerebral hemispheres and cerebellum may show areas of hemorrhagic infarcts. Histological examination reveals the presence of multinucleated giant cells in the cerebral hemispheres, brain stem, mid-brain, cerebellum, and basal ganglion. Necrotic tissue with lipid-containing macrophages and neovascularization suggesting a tumour is often seen. Trophozoites and cysts of *acanthamoebae* are usually spread all over the infected tissue. Many blood vessels are thrombotic with fibrinoid necrosis and cuffed by polymorphonuclear leukocytes, amoebic trophozoites, and cysts. Multinucleated giant cells forming granulomas may be seen in immunocompetent patients but less often in immunocompromised patients.

Some infected individuals, mostly with HIV/AIDS, develop chronic ulcerative skin lesions, abscesses, or erythematous nodules (Seijo-Martínez et al., 2000; Visvesvara & Maguire, 2006; Visvesvara et al., 2007), especially of the chest and limbs. These nodules are usually solid but sometimes they become ulcerated and purulent. The prodromal period is unknown and several weeks or months may elapse following infection before the disease becomes apparent. Because of the time delay, the precise portal of entry is not clearly known, but the wide dissemination of these amoebae in the environment allows for many possible contacts and modes of infection. Trophic amoebae and/or cysts of *Acanthamoeba* have been isolated from the nasal mucosa of healthy individuals, suggesting a nasopharyngeal route as one means of invasion. Amoebae may also enter the body through ulcers in the skin, resulting in hematogenous dissemination to the lungs and brain, or by inhalation of amoebic cysts (Visvesvara & Maguire, 2006; Visvesvara et al 2007).

In addition to causing CNS infections, *Acanthamoeba* also causes a vision-threatening disease, *Acanthamoeba keratitis* (AK) which mostly affects contact lens wearers although many cases have been reported worldwide in non contact lens users mostly related to a previous corneal trauma [6, 7, 8]. The number of affected individuals is increasing worldwide. Moreover, recent outbreaks of *Acanthamoeba keratitis* have been recently reported in the United States and Australia (Verani et al., 2009; Tu and Joslin, 2010; Patel et al., 2010;

Joslin et al., 2010). AK is an acute, painful infection that can occur in immunocompetent individuals. When AK is not treated promptly, loss of visual acuity and blindness can occur [6, 7, 8]. Initial symptoms of AK are not specific and include disproportional eye pain, photophobia, eye redness, and tearing, usually affecting one eye. Using a slit-lamp, corneal inflammation leading to formation of a ring-like stromal infiltrate can be observed. Furthermore, corneal epithelial erosion, irregularities, and edema are present. The radial perineural distribution of the infiltrate (radial keratoneuritis) is characteristic for AK, similar to the type of infiltration observed in *Pseudomonas aeruginosa* keratitis. Later stages of infection can result in epithelial denudation and stromal necrosis. Contact lens usage and/or incidents of corneal trauma are strong indicators for AK. Despite the clinical picture, AK is often misdiagnosed as herpes or bacterial keratitides which present similar clinical symptomatology (Khan, 2006; Visvesvara et al., 2007; Martín-Navarro et al., 2008; da Rocha-Azevedo et al., 2009).

Both *Acanthamoeba* and *Balamuthia* cause infections of the lungs and skin (Khan, 2006; Maciver, 2007; Visvesvara et al., 2007; da Rocha-Azevedo et al., 2009). More recently, *Balamuthia mandrillaris*, has been discovered to cause a fatal encephalitis in humans (Maciver, 2007; Visvesvara et al., 2007; Matin et al., 2008). This encephalitis is known as *Balamuthia* amoebic encephalitis (BAE). There are worrying features of BAE that are emerging, even compared to AGE and PAM. PAM is restricted to bodies of warm freshwater, such as swimming pools and lakes, and so can be avoided after its presence has been identified.

AGE is mostly a disease of the immunocompromised, and so affects a small subpopulation of individuals who could conceivably be monitored for early signs of AGE; for example, by inspection of cerebrospinal fluid (CSF) (Deetz et al., 2003; Maciver, 2007). Present data indicate that BAE is more difficult to detect, as it is sporadic, affecting both immunocompromised and immunocompetent, otherwise healthy, individuals with little evidence of predisposing factors (i.e. working in farms or soil related environments. The unpredictable nature of the disease may mean that BAE is even less likely to be diagnosed in time for medical intervention and, like AGE and PAM, it is essential for BAE to be diagnosed early if it is to be treated successfully (Deetz et al., 2003; Petry et al., 2006; Maciver, 2007). Worryingly, BAE may be relatively a common type of amoebic encephalitis and some cases reported to be due to *Acanthamoeba* have subsequently been shown to be due to *B. mandrillaris* (Deetz et al., 2003; Maciver, 2007).

Recently, *Sappinia diploidea* and *Sappinia pedata* species, also belonging to the free-living amoeba group, that normally live in soil contaminated with faeces of elk, bison, and cattle, have been identified as causing encephalitis in otherwise healthy individuals (Gelman et al., 2001; Qvarstrom et al., 2009; Walochnik et al., 2010), indicating that there are probably other amoebae that are capable of causing encephalitis in humans.

A study looking at causes of encephalitis found at least 13,939 cases of acute encephalitis diagnosed between 1990 and 1999 in California [13, 26]. Amongst these cases, 0.1% was attributed to *Naegleria*, 0.63% to other protozoans, and 34.7% were from unspecified causes. The California Encephalitis Project (CEP) (reviewed in Maciver et al., 2007), identified three fatal cases caused by *Balamuthia* from the 334 patients who met the criteria for CEP. No cases of encephalitis caused by either *Acanthamoeba* or *Naegleria* were seen but immunocompromised patients were excluded from the study [30]. Thus, these data would suggest that in California in the 1990s *Balamuthia* and *Naegleria* each accounted for approximately 0.1% of total encephalitis cases in these studies (reviewed in Maciver et al., 2007).

3. Therapy and prognosis of *FLA* infections

3.1 *Acanthamoeba* spp.

Treatment of AGE is problematic because of the lack of clear-cut symptoms, the lack of a good reliable diagnostic test, and the fact that diagnosis is often made postmortem. However, several patients with GAE caused by *Acanthamoeba* spp., as well as some with *Acanthamoeba* cutaneous infection without CNS involvement, have been successfully treated with a combination of pentamidine isethionate, sulfadiazine, flucytosine, and fluconazole or itraconazole. For *Acanthamoeba* cutaneous infection without CNS involvement, topical applications of chlorhexidine gluconate and ketoconazole cream in addition to the above-noted antimicrobials have resulted in therapeutic success. In many cases, however, therapy had to be discontinued because of undesirable side effects of the medications Visvesvara et al., 2007. A combination of factors –late diagnosis, suboptimal efficacy of antimicrobial therapy, and problems inherent to the immunocompromised host –make for a poor prognosis for GAE patients.

Treatment of *Acanthamoeba* keratitis has been fairly successful. A variety of drugs have been used, including chlorhexidine, polyhexamethylene biguanide, propamidine isethionate, dibromopropamidine isethionate, neomycin, paromomycin, polymyxin B, clotrimazole, ketoconazole, miconazole, and itraconazole (Visvesvara et al., 2007; da Rocha-Azevedo, 2009). Brolene, a commercially available eye medication (in the UK, and other EU countries) containing propamidine isethionate and dibromopropamidine isethionate, was found to be effective in the treatment of *Acanthamoeba* infections but may be accompanied by drug toxicity and development of resistance.

A number of compounds, including a variety of diamidine compounds, synthetic maganins combined with silver nitrate, imidazole and triazole compounds, azithromycin, phenothiazines and povidone-iodine have been screened *in vitro* for efficacy against *Acanthamoeba* spp. Another drug, miltefosine, an alkylphospholipid, has also been shown to have amoebicidal potential. Significantly, medical cure has been achieved with the application of either polyhexamethylene biguanide (PHMB) or chlorhexidine gluconate with or without Brolene. When medical treatment failed, a combination of debridement and penetrating keratoplasty has been used with good results in some cases. Currently, the drugs of for AK are chlorhexidine gluconate, PHMB and Brolene, and they have greatly improved the prognosis for AK sufferers (reviewed in Visvesvara et al., 2007). However, it was recently demonstrated that clinical strains of *Acanthamoeba* are resistant to the concentrations of chlorhexidine gluconate or PHMB present in contact lens maintenance/disinfection solutions (Martín-Navarro et al., 2008). Thus, the latter together with the demonstrated toxicity of these molecules is supporting the need for novel therapies to treat AK worldwide.

3.2 *Balamuthia mandrillaris*

Balamuthia amoebic encephalitis (BAE) is a rare, subacute to chronic disease that is characterized by hemorrhagic necrotizing lesions or brain abscess (normally detected by neuroimaging scans) with severe meningeal irritation and encephalitis. The lesions are mainly detected in the basal ganglia, midbrain, brainstem and cerebral hemiparesis with characteristic lesions in the CNS parenchyma. Typically, encephalitis is of the granulomatous type composed of the amoebae, CD4 and CD8 T cells, B lymphocytes, few plasma cells, macrophages and multinucleate giant cells (Martinez and Visvesvara, 1997;

2001; Matin et al., 2008). However, in immunocompromised patients with an impaired cellular immune response, granuloma formation may be minimal or absent (Martinez and Visvesvara, 1997; 2001).

Post mortem examination often shows severe edema and hemorrhagic necrosis. The amoebae colonize the brain tissue and produce subacute necrotising hemorrhagic encephalitis leading to brain dysfunction. *Balamuthia mandrillaris* trophozoites and cysts are present within the perivascular spaces and within the necrotic CNS parenchyma (Martinez and Visvesvara, 1997). The disease is likely to take a cutaneous route before secondarily attacking the CNS. The time period of transition from the cutaneous form to the CNS ranges from 30 days to 2 years, with an average of 5–8 months (Bravo and Sanchez, 2003). The skin lesions may appear at the site of an abrasion of the skin surface of the patient, or lesions can appear as single or multiple plaques or nodules (Deetz et al., 2003). These plaques may appear on the face, the trunk or the limbs, with a rubbery to hard consistency (Bravo and Sanchez, 2003). Skin lesions indicate a site of entry and are frequently observed in BAE patients.

Because most of the cases of BAE have presented with no clear-cut clinical profile, they have been treated empirically with steroids as well as with antibacterial, antifungal and antiviral agents with almost no effect upon the course of the infection. Anti-inflammatory steroids that were administered may have actually facilitated spread of the infection by suppressing the inflammatory response. Two patients from California, a 60-year-old man, and a 6-year old girl, in addition to a 70-year-old woman from New York survived balamuthiasis after treatment with a combination of pentamidine isethionate, sulfadiazine, clarithromycin, fluconazole, and flucytosine (5-fluorocytosine) (Deetz et al., 2003).

In the case of the Peruvian balamuthiasis patients with cutaneous lesions (Martínez et al., 2010; Bravo et al., 2011), one recovered without any treatment and two others became well after prolonged therapy with albendazole and itraconazole. The use of multiple antimicrobials in treatment makes it difficult to single out one or more of the drugs that might be the basis for optimal therapy. Furthermore, drugs may show synergistic activities in vivo that are not seen in in vitro testing. In vitro studies have shown that pentamidine and propamidine isethionates were amoebastatic but not amoebicidal. Among other drugs tested with little or no activity were macrolide antibiotics, azole compounds, gramicidin, polymyxin B, trimethoprim, sulfamethoxazole, and a combination of trimethoprim-sulfamethoxazole as well as amphotericin B (Maciver, 2007; Visvesvara et al., 2007).

Recent information based on in vitro data has shown that miltefosine was able to lysed the amoebae. Voriconazole, however, had virtually no effect on *Balamuthia* (Maciver, 2007; Visvesvara et al., 2007). Given the problems with the diagnosis of infection and the lack of effective antimicrobial agents, the prognosis for patients is poor.

3.3 *Naegleria fowleri*

Few patients have survived PAM. One of these survivors, a Californian girl, was aggressively treated with intravenous and intrathecal amphotericin B, intravenous and intrathecal miconazole, and oral rifampin [2, 28]. Over a 4- year follow-up, she remained completely healthy and free of any neurological deficits. It was believed that amphotericin B and miconazole had a synergistic effect but that rifampin was without effect on the amoebae. Based on *in vitro* testing and *in vivo* mouse studies, amphotericin B was reported to be more effective against *Naegleria* than amphotericin B methyl ester, a water-soluble form of the drug. *In vitro* studies of phenothiazine compounds (chlorpromazine and trifluoperazine), which can accumulate in the CNS, were found to have inhibitory effects on

N. fowleri (Visvesvara et al., 2007; da Rocha-Azevedo et al., 2009). Azithromycin, a macrolide antimicrobial, has been shown to be effective against *Naegleria* both in vitro and in vivo (mouse model of disease). However, other macrolides (erythromycin, clarithromycin) are less effective. *Naegleria fowleri* is also sensitive to voriconazole (Marciano-Cabral and Cabral, 2003; Visvesvara et al., 2007; da Rocha-Azevedo et al., 2009).

3.4 *Sappinia* spp.

As it has been recently reported as pathogenic to humans and other animals, no studies have been carried out so far regarding therapy and prognosis of this amoeba.

	<i>Naegleria fowleri</i> (PAM)	<i>Acanthamoeba</i> (AGE)	<i>Balamuthia</i> <i>mandrillaris</i> (BAE)	<i>Sappinia</i> spp.
<i>Life cycle</i>	Three stages: amoeba, cyst and flagellate	Two stages: amoeba and cyst	Two stages: amoeba and cyst	Two stages: amoeba and cyst
<i>Distinctive morphological features</i>	Vesicular nucleus; limacine movement of amoebae; flagellate stage; cyst with pores flush at the surface	Vesicular nucleus; finger-like pseudopodia projecting from surface; cyst wall with two layers and with pores	Vesicular nucleus with single or multiple nucleoli; amoeboid and ‘spider-like’ movements in culture; cyst wall with three layers	Presence of two abutting nuclei in amoeba and cyst stages
<i>Prodromal period</i>	Days	Weeks to months	Weeks to months	Insufficient data
<i>Epidemiology</i>	Humans typically infected while recreating in warm fresh waters	Infection from soil, water, and air; present in hospital environment (water taps, hydrotherapy pools, air conditioning cooling towers)	Infection from soil, water, and air	Present in soil, water and in air; originally identified from herbivore faeces.
<i>Groups at risk</i>	Children and young adults in good health	Typically, immunocompromised individuals	Immunocompetent (children and elderly) or immunocompromised individuals; Hispanic Americans	Insufficient data
<i>Disease at presentation</i>	Headache, stiff neck, seizures, coma	Headache, stiff neck, behavioural changes, coma	Headache, nausea, seizures, stiff neck, hydrocephalus; sinus infection; nodule formation in cutaneous infections	Headache, vomiting, photophobia, loss of consciousness; preceded by sinus infection
<i>Clinical course</i>	Fulminant disease; death within 1–2 weeks without treatment	Indolent subacute course; acute stage fatal in weeks	Indolent subacute course; once in acute stage, fatal in weeks	Insufficient data

	<i>Naegleria fowleri</i> (PAM)	<i>Acanthamoeba</i> (AGE)	<i>Balamuthia</i> <i>mandrillaris</i> (BAE)	<i>Sappinia spp.</i>
<i>Prevention</i>	Public health monitoring of warm, fresh-water recreational sites	Widespread in soil and water; in hospital setting, monitoring of water supply, ventilators, air conditioning units	Found in soil and water; preventive measures not feasible	Insufficient data; organism found in soil; preventive measures not feasible
<i>Current therapy</i>	Intrathecal amphotericin B, miconazole	Pentamidine, azole compounds, flucytosine, sulfadiazine	Pentamidine, azithromycin, fluconazole, flucytosine	Azithromycin, pentamidine, itraconazole, flucytosine
<i>Prognosis</i>	Fair if diagnosed early (within days); otherwise poor—a few patients have survived	Poor; diagnosis is often postmortem—only a few patients have survived	Poor; diagnosis is often postmortem—three patients have survived	Insufficient data

Table 1. Characteristics of FLA as causal agents of encephalitis (adapted from Visvesvara et al., 2007).

3.5 Novel therapeutic approaches

Recently, the application of siRNA in *Acanthamoeba* species (Lorenzo-Morales et al., 2005; 2008; 2010) has opened a novel approach for the progress of future therapies based on siRNAs alone or in combination with chemical compounds. Also the use of RNAi molecules could be very powerful for the identification of novel drug targets and metabolic pathways in these pathogens that could be exploited for the development of new therapeutic agents. Recently, RNAi methodology has been successfully use in *Naegleria fowleri* (Jung et al., 2008) resulting in a reduced pathogenicity of the RNAi-treated amoebae. Therefore, RNAi molecules are currently presenting as very powerful tools that are waiting to be fully exploited in the development of new therapies against pathogenic FLA.


4. Conclusions

Regarding encephalitis caused by FLA, it is important to mention that because most of them are ultimately fatal, diagnosis of these infections is often made at autopsy, even in developed countries where sophisticated diagnostic facilities are readily available. However, in Sub-Saharan Africa and Southeast Asia, where HIV/ AIDS rates are increasing, it is quite possible that a large number of cases have gone undetected. A similar case occurs in South America, where skin infections due to *B. mandrillaris* are a common episode in countries like Peru but the lack of diagnostic and treatment facilities in most areas have caused that most of these cases have been unnoticed as well. This due to a number of reasons: (1) lack of expertise to identify these pathogenic amoebae; (2) cultural methods and expense that prevent autopsies; and (3) an abundance of more prominent diseases such as HIV/ AIDS, tuberculosis and malaria that consume national and international resources. Therefore, the actual incidence of the encephalitis caused by FLA is not really known although it seems that these pathogenic amoebae are emerging as causative agents of encephalitis worldwide.

5. References

- Bravo F, Sanchez MR. (2003) New and re-emerging cutaneous infectious diseases in Latin America and other geographic areas. *Dermatologic Clinics*. 2003 Oct;21(4):655-68, VIII. Review
- Bravo FG, Alvarez PJ, Gotuzzo E. (2011). Balamuthia mandrillaris infection of the skin and central nervous system: an emerging disease of concern to many specialties in medicine. *Current Opinion Infectious Diseases*. 2011 Apr;24(2):112-7. Review.
- da Rocha-Azevedo B, Tanowitz HB, Marciano-Cabral F. (2009). Diagnosis of infections caused by pathogenic free-living amoebae. *Interdisciplinary Perspectives Infectious Diseases*. 2009: 251406. Epub 2009 Aug 2.
- Deetz TR, Sawyer MH, Billman G, Schuster FL, Visvesvara GS. (2003). Successful treatment of Balamuthia amoebic encephalitis: presentation of 2 cases. *Clinical Infectious Diseases*. 15;37(10):1304-12.
- Gelman BB, Rauf SJ, Nader R, et al. (2001) Amoebic encephalitis due to Sappinia diploidea. *JAMA*. 16;285(19):2450-
- Heggie TW (2010) Swimming with death: Naegleria fowleri infections in recreational waters. *Travel Medicine and Infectious Diseases*. 2010 8(4):201-6
- Joslin CE, Tu EY, Shoff ME, Anderson RJ, Davis FG (2010). Shifting distribution of Chicago-area Acanthamoeba keratitis cases. *Arch Ophthalmol*. 2010 Jan;128(1):137-9.
- Jung SY, Kim JH, Song KJ, Lee YJ, Kwon MH, Kim K, Park S, Im KI, Shin HJ. (2009). Gene silencing of nfa1 affects the in vitro cytotoxicity of Naegleria fowleri in murine macrophages. *Molecular and Biochemical Parasitology*. 2009 May;165(1):87-93.
- Khan NA (2006), Acanthamoeba: biology and increasing importance in human health. *FEMS Microbiology Reviews*, 30:564-595.
- Lorenzo-Morales J, Ortega-Rivas A, Foronda P, Abreu-Acosta N, Ballart D, Martínez E, Valladares B. (2005). RNA interference (RNAi) for the silencing of extracellular serine proteases genes in Acanthamoeba: molecular analysis and effect on pathogenicity. *Molecular and Biochemical Parasitology*. 2005 Nov;144(1):10-5.
- Lorenzo-Morales J, Kliescikova J, Martinez-Carretero E, De Pablos LM, Profotova B, Nohynkova E, Osuna A, Valladares B. (2008) Glycogen phosphorylase in Acanthamoeba spp.: determining the role of the enzyme during the encystment process using RNA interference. *Eukaryotic Cell*. 2008 Mar; 7(3):509-17.
- Lorenzo-Morales J, Martín-Navarro CM, López-Arencibia A, Santana-Morales MA, Afonso-Lehmann RN, Maciver SK, Valladares B, Martínez-Carretero E. (2010). Therapeutic potential of a combination of two gene-specific small interfering RNAs against clinical strains of Acanthamoeba. *Antimicrobial Agents and Chemotherapy*. 2010 Dec;54(12):5151-5.
- Maciver SK.(2007). The threat from Balamuthia mandrillaris. *Journal of Medical Microbiology*. 56(Pt 1):1-3
- Marciano-Cabral F, Cabral G. (2003) Acanthamoeba spp. as agents of disease in humans. *Clinical Microbiology Reviews*. 2003 Apr;16(2):273-307. Review.
- Martínez AJ. (1980). Is Acanthamoeba encephalitis an opportunistic infection? *Neurology*. 1980 Jun;30(6):567-74.
- Martinez AJ, Visvesvara GS. (1997). Free-living, amphizoic and opportunistic amebas. *Brain Pathology*. 1997 Jan;7(1):583-98. Review.
- Martínez AJ, Visvesvara GS. (2001) Balamuthia mandrillaris infection. *Journal of Medical Microbiology*. 2001 Mar;50(3):205-7.

- Martínez DY, Seas C, Bravo F, Legua P, Ramos C, Cabello AM, Gotuzzo E. (2010). Successful treatment of *Balamuthia mandrillaris* amoebic infection with extensive neurological and cutaneous involvement. *Clinical Infectious Diseases*. 2010 Jul 15;51(2):e7-11.
- Martín-Navarro CM, Lorenzo-Morales J, Cabrera-Serra MG, Rancel F, Coronado-Alvarez NM, Piñero JE, Valladares B. (2008). The potential pathogenicity of chlorhexidine-sensitive *Acanthamoeba* strains isolated from contact lens cases from asymptomatic individuals in Tenerife, Canary Islands, Spain. *Journal of Medical Microbiology*. 57(Pt 11):1399-404.
- Matin A, Siddiqui R, Jayasekera S, Khan NA. (2008). Increasing importance of *Balamuthia mandrillaris*. *Clinical Microbiology Reviews*. 2008 Jul;21(3):435-48. Review.
- Page, F.C. (1988) A new key to freshwater and soil gymnamoebae. FBA NERC. P26.
- Patel DV, Rayner S, McGhee CN (2010). Resurgence of *Acanthamoeba* keratitis in Auckland, New Zealand: a 7-year review of presentation and outcomes. *Clinical Experimental Ophthalmology* 38(1):15-20.
- Petry F, Torzewski M, Bohl J, et al. (2006). Early diagnosis of *Acanthamoeba* infection during routine cytological examination of cerebrospinal fluid. *Journal of Clinical Microbiology*. 44(5):1903-4.
- Qvarnstrom Y, da Silva AJ, Schuster FL, Gelman BB, Visvesvara GS. (2009). Molecular confirmation of *Sappinia pedata* as a causative agent of amoebic encephalitis. *Journal of Infectious Diseases*. Apr 15;199(8):1139-42.
- Seijo Martinez M, Gonzalez-Mediero G, Santiago P, Rodriguez De Lope A, Diz J, Conde C, Visvesvara GS. (2000). Granulomatous amoebic encephalitis in a patient with AIDS: isolation of *acanthamoeba* sp. Group II from brain tissue and successful treatment with sulfadiazine and fluconazole. *Journal of Clinical Microbiology*. Oct; 38(10):3892-5.
- Shirwadkar CG, Samant R, Sankhe M, Deshpande R, Yagi S, Schuster FL, Sriram R, Visvesvara GS. (2006). *Acanthamoeba* encephalitis in patient with systemic lupus, India. *Emerging Infectious Diseases*. 2006 Jun;12(6):984-6.
- Tu EY and Joslin CE (2010). Recent outbreaks of atypical contact lens-related keratitis: what have we learned?. *American Journal of Ophthalmology*. 2010 Nov;150(5):602-608.e2.
- Verani JR, Lorick SA, Yoder JS, Beach MJ, et al. (2009). National outbreak of *Acanthamoeba* keratitis associated with use of a contact lens solution, United States. *Emerging Infectious Diseases*. 15(8):1236-42.
- Visvesvara GS and Maguire JH (2006) Pathogenic and opportunistic free-living amebas. *Acanthamoeba* spp., *Balamuthia mandrillaris*, *Naegleria fowleri*, and *Sappinia diploidea*. *Tropical Infectious Diseases*, Vol. 2 (Guerrant RL, Walker DH & Weller PF, eds), pp. 1114-1125. Churchill Livingstone.
- Visvesvara GS, Moura H and Schuster F L (2007), Pathogenic and opportunistic free-living amoebae: *Acanthamoeba* spp., *Balamuthia mandrillaris*, *Naegleria fowleri*, and *Sappinia diploidea*. *FEMS Immunology and Medical Microbiology*, 50:1-26.
- Visvesvara GS, Sriram R, Qvarnstrom Y, Bandyopadhyay K, Da Silva AJ, Pieniazek NJ, Cabral GA. (2009). *Paravahlkampfia francinae* n. sp. masquerading as an agent of primary amoebic meningoencephalitis. *Journal of Eukaryotic Microbiology*. Jul-Aug;56(4):357-66.
- Walochnik J, Wylezich C, Michel R. (2010) The genus *Sappinia*: history, phylogeny and medical relevance. *Experimental Parasitology*. 126(1):4-13.



Non-Flavivirus Encephalitis

Edited by Dr. Sergey Tkachev

ISBN 978-953-307-720-8

Hard cover, 360 pages

Publisher InTech

Published online 16, November, 2011

Published in print edition November, 2011

This book covers the different aspects of non-flavivirus encephalitis of different etiology. The first section of the book considers general problems of epidemiology such as study of zoonotic and animal vectors of encephalitis causative agents and methods and approaches for encephalitis zoonoses investigations. The members of different virus species are known to be the causative agents of encephalitis, so the second section of the book is devoted to these viral pathogens, their epidemiology, pathology, diagnostics and molecular mechanisms of encephalitis development by such viruses as HIV/SIV, herpes simplex virus type 1 and equine herpesvirus 9, measles virus, coronaviruses, alphaviruses and rabies virus. The next section of the book concerns the study of protozoan pathogens such as toxoplasma and amoebae. The last section of the book is devoted to multicellular pathogen as human *Filaria Loa Loa* - a filarial worm restricted to the West Africa.

How to reference

In order to correctly reference this scholarly work, feel free to copy and paste the following:

Jacob Lorenzo-Morales, Carmen Ma Martín-Navarro, Enrique Martínez-Carretero, José E. Piñero and Basilio Valladares (2011). Encephalitis Due to Free Living Amoebae: An Emerging Issue in Human Health, Non-Flavivirus Encephalitis, Dr. Sergey Tkachev (Ed.), ISBN: 978-953-307-720-8, InTech, Available from: <http://www.intechopen.com/books/non-flavivirus-encephalitis/encephalitis-due-to-free-living-amoebae-an-emerging-issue-in-human-health>

INTECH
open science | open minds

InTech Europe

University Campus STeP Ri
Slavka Krautzeka 83/A
51000 Rijeka, Croatia
Phone: +385 (51) 770 447
Fax: +385 (51) 686 166
www.intechopen.com

InTech China

Unit 405, Office Block, Hotel Equatorial Shanghai
No.65, Yan An Road (West), Shanghai, 200040, China
中国上海市延安西路65号上海国际贵都大饭店办公楼405单元
Phone: +86-21-62489820
Fax: +86-21-62489821

© 2011 The Author(s). Licensee IntechOpen. This is an open access article distributed under the terms of the [Creative Commons Attribution 3.0 License](https://creativecommons.org/licenses/by/3.0/), which permits unrestricted use, distribution, and reproduction in any medium, provided the original work is properly cited.

IntechOpen

IntechOpen