

We are IntechOpen, the world's leading publisher of Open Access books Built by scientists, for scientists

6,900

Open access books available

185,000

International authors and editors

200M

Downloads

Our authors are among the

154

Countries delivered to

TOP 1%

most cited scientists

12.2%

Contributors from top 500 universities



WEB OF SCIENCE™

Selection of our books indexed in the Book Citation Index
in Web of Science™ Core Collection (BKCI)

Interested in publishing with us?
Contact book.department@intechopen.com

Numbers displayed above are based on latest data collected.
For more information visit www.intechopen.com



Secondary Glaucoma After Vitreoretinal Procedures

Lizette Mowatt

*University of the West Indies, Mona, Kingston
Jamaica*

1. Introduction

Vitreoretinal surgery can be associated with transient or sustained elevated intraocular pressure (IOP) as a complication. This may occur in the immediate, early and late post operative phase. Secondary glaucoma is a complication of both external procedures (such as scleral buckling) and internal procedures (pars plana vitrectomy) including intravitreal steroids. Several internal tamponade agents are used in vitreoretinal surgery, such as expanding gases and silicone oils which can compromise the aqueous outflow in several ways, resulting in secondary glaucoma.

This chapter will look at the causes of secondary glaucoma complicating vitreoretinal procedures. Anderson et al, 2006, looked at 222 patients that underwent vitreoretinal procedures and noted that 8.4% had an IOP ≥ 30 mmHg at 5-12 hours and 14.9% had an IOP ≥ 30 mmHg on the first post operative day, despite all patients receiving topical brimonidine tds from 2 hours post operatively.

2. Intravitreal steroids

Intravitreal steroids have been used for uveitic and refractory diabetic cystoid macula oedema (CMO), CMO secondary to retinal vascular disease, as an adjuvant to laser treatment, choroidal neovascular membrane management and in macula hole surgery. The use of intravitreal steroids have increased exponentially over the past decade however, in the last few years with the advent of the anti VEGF drugs their use is decreasing.

A well known complication of intra vitreal steroids is secondary glaucoma. Most times it is transient; settling with anti glaucoma drugs and discontinuation of steroids. However, a few patients can develop intractable glaucoma requiring surgical intervention. The likelihood of glaucoma development depends on several factors; pre existing ocular status, family history of glaucoma, duration and dosage of steroids.

Steroid induced glaucoma is usually an open angle glaucoma. It occurs within weeks of commencing steroids and usually spontaneously reduces once the steroids are discontinued. Some patients are at higher risk of developing glaucoma on steroids, such as those with compromised outflow facility, diabetics, myopes and patients with family history of glaucoma. Primary open angle glaucoma is seen 4-12 times more commonly in eyes with retinal detachment than the normal population (Phelps and Burton, 1977).

RISK FACTORS FOR STEROID INDUCED GLAUCOMA
<ul style="list-style-type: none">• Pre existing primary open angle glaucoma (POAG)• Diabetes• Family history of glaucoma• High Myopia

Table 1. Risk Factors for Steroid Induced glaucoma

Intravitreal triamcinolone (IVTA) has been noted to cause an increase in intraocular pressure which in most cases is transient and responds to anti glaucoma medication. However in a small percentage of cases, treatment may require surgical intervention. A significant rise in IOP can occur within a week (Singh, 1994). One dose of 4mg intravitreal triamcinolone may increase the IOP >10mmHg in 28-30% of patients (Bakri, 2003; Karmar, 2007). In a double masked placebo controlled randomized controlled trial, 28% of patients had increased IOP requiring treatment (Gilles et al, 2004). 8% of eyes have ≥40mmHg IOP, with 0.9% requiring surgical intervention (Konstantopoulos et al, 2007). Jonas, 2005 had a 40% incidence of elevated IOP in patients post IVTA with 1-2% requiring glaucoma surgery. In another study 50% of diabetic patients developed elevated IOP within 2 months of IVTA (Yildirim et al, 2008)

Elevated IOP can occur with a single dose of intravitreal triamcinolone. For continued therapeutic level, patients may require repeat intravitreal injections. This increases the risk of secondary glaucoma. The fluocinolone acetonide intravitreal device has been designed for continuous delivery of low dose steroids (0.3-0.4ug/day) over 30 months and has been used effectively in chronic non infectious posterior segment uveitis. However, their clinical trials estimate that 77% of patients will require anti glaucoma drugs within 3 years of implantation and 37% requiring glaucoma surgical intervention (Retisert Bausch and Lomb, 2009).

2.1 Pathogenesis

Steroid induced glaucoma is a type of open angle glaucoma that occurs in patients with multiple doses/chronic use of steroids (topical, sub tenons, intra vitreal, nasally or systemic route) the exact pathophysiology has yet to be fully elucidated but it is theorized that the following may be the cause:

MECHANISM OF SECONDARY GLAUCOMA FOR INTRAVITREAL STEROIDS
<ul style="list-style-type: none">• Increased accumulation of glycoaminoglycans• Increased production of the Trabecular Meshwork Inducible Glucocorticoid Response (TIGR) protein• Corticosteroid induced cytoskeletal changes• Accumulation of extracellular material in the trabecular network• ?High levels of Tissue Inhibitor of Matrix Metalloproteinase (TIMP) in diabetics

Table 2. Mechanism of Secondary Glaucoma for Intravitreal Steroids

It is worthwhile to monitor these patients post intravitreal injection particularly patients with primary open angle, family history of POAG, pre existing trabecular dysfunction, elevated aqueous outflow or ocular hypertension (Jones et al, 2006) . It has the potential to

cause severe visual loss from intractable glaucoma. Argon laser trabeculoplasty has been attempted in 2 patients successfully reducing the IOP (Ricci et al, 2006). SLT has a temporary effect on lowering the IOP from steroid induced glaucoma and may need to be repeated in 4/7 cases (Rubin, 2008).

In the future gene therapy may have a role in steroid induced glaucoma, due to the interference with the glucocorticoid inducible MMP1 (matrix metalloproteinase) (Spriga et al, 2010)

3. Scleral buckling

Scleral buckling was introduced by Custodis and Schepens in the 1950s for the repair of uncomplicated retinal detachments. It involves suturing a silicone band or silicone sponge under the recti muscles against the sclera then covering with tenons and conjunctiva. This indents the sclera onto the retina, relieving the traction on the retinal tear, and closing the retinal break, thereby allowing the resolution of the subretinal fluid. It may be placed radially, segmentally or circumferentially depending on location of the retinal breaks. Very posterior or wide band may compress the vortex veins. Scleral buckles are usually permanent but may be removed in instances of extrusion or exposure.

Scleral buckles (especially encircling bands) can change the geometry of an eye (axial length and corneal topography) and the ocular rigidity. They cause indentation of the sclera decreasing the vitreal volume. Therefore, when the IOP increases, the pressure rise in an eye with a scleral buckle is less than a normal eye because the eye becomes less elliptical as the scleral sutures are stressed and the indentation reduces (Thompson, 2001). However once the eye resumes its more spherical shape the IOP will increase rapidly for increasing pressure change. Due to the change in the ocular rigidity, older methods of measuring IOP such as the Schiotz tonometer are not as accurate in eyes with scleral buckles.

3.1 Pathogenesis of secondary glaucoma (scleral buckles)

Secondary glaucoma occurs after scleral buckling because of angle closure glaucoma. In 1.4 - 4% of cases patients may have angle closure glaucoma (Kreiger et al, 1971 and Perez et al, 1976). This results in corneal oedema and shallowing of the peripheral angle. It may also be due to shallow detachment of the ciliary body, whose anterior displacement may occlude the angle, typically occurring 2-7 days post op. Angle narrowing has been detected in 50% of cases of non vitrectomized eyes in the first post op week (Hartley & Marsh 1973). However, in most cases these resolved spontaneously over several weeks.

The circumferential encircling band anterior to the equator may compress the vortex veins, impairing the venous drainage. This leads to the engorgement of the ciliary body and its resulting anterior rotation. This rotation leads to an anterior shift of the lens iris diaphragm resulting in secondary angle closure glaucoma.

Management of the angle closure glaucoma is with anti glaucoma therapy and topical corticosteroids. Cycloplegics relax the ciliary muscle and shift the lens-iris diaphragm posterior. Miotics are best avoided due their anterior movement of the lens-iris diaphragm which can worsen angle narrowing and also inflammation (Gedde, 2002). If it is not relieved then reassess the indenting buckle height. Excessive buckle height may be the cause and loosening the encircling band may relieve the IOP.

Glaucoma may also occur with anterior segment ischemia where the posterior ciliary arteries are compromised or obstruction of the venous drainage from the ciliary body by the

encircling band (Hayreh, 1973). This is usually seen with high buckles or in sickle cell patients. They will have corneal oedema, fibrin in the anterior chamber, raised IOP and the anterior chamber may be shallow. Mild cases may respond to topical anti glaucoma and steroids, however, if severe, releasing the buckle may be necessary.

MECHANISM OF SECONDARY GLAUCOMA FROM SCLERAL BUCKLING
Angle closure glaucoma
<ul style="list-style-type: none">• Shallow detachment of the ciliary body• Very high deep buckle (scleral indentation)• Compression of the vortex veins (especially with encircling band)<ul style="list-style-type: none">• Choroidal congestion• Engorgement of the ciliary body (leading to anterior rotation)• Anterior shift of the lens iris diaphragm
Anterior segment ischemia

Table 3. Mechanism of Secondary Glaucoma from Scleral Buckling

Anti glaucoma medical therapy is usually successful in controlling IOP. If glaucoma surgery is required because of intractable glaucoma, the management can be difficult due to conjunctival scarring and recession due to 360 degree or limited periotomies done to place the sclera buckle. This may affect the result of trabeculectomy surgery and bleb management due to the conjunctival scarring.

If tube shunts are to be used, the presence of the scleral bands can make surgical management challenging in refractory cases. Fran Smith et al, 1998, described 2 techniques of using a long Krupin Denver valved implant, where the distal end is placed superior to the encircling band but beneath the formed encapsulated fibrous capsule. The proximal end was place into the anterior chamber and covered with donor dura or pericardium. The other technique involved trimming 200-250mm³ Baerveldt implant wings and placing it under the encircling band, before the fibrous sheath forms. The distal lumen was occluded with an 8-0 supramid stent. Donor dura or pericardium was used to over the anterior episcleral area of the tube. 36.4% were complete success (IOP<21mmHg, not on glaucoma meds). The Krupin Denver valve was placed in patients 3 months after detachment repair, whereas the Baerveldt valve was placed within 3 months, prior to the formation of fibrous capsule around the band. However their success rate of IOP< 21mmHg, whether or not on meds was 82% and 73% at 1 and 2 years respectively (Fran Smith et al, 1998).

4. Pneumatic retinopexy

Intravitreal air was first used by Ohm in 1911 in the management of retinal detachments to flatten the retina. Initially air was used to provide internal tamponade for the retinal breaks, however, air is non expansible and quickly reabsorbed. Expanding gases are more commonly used and these include sulphur hexafluoride (SF₆), perfluoroethane (C₂F₆) and perfluoropropane (C₃F₈) (Table 4). The 2 most commonly used gases are SF₆ and C₃F₈, both are colourless, odourless and non toxic gas. SF₆ is x5 lighter than air and 100% concentration can double in size in 48 hours. It returns to its original size in 96 hours and can last 10-14 days in the eye (Abrams, 1974). Whereas C₃F₈ is x6 lighter than air and 100% concentration can quadruples in size in 3-4 days and can last 6-8 weeks in the eye. However, they may be

used in a mildly expansile format >20% (SF₆) and >12% (C₃F₈) to fill the vitreal cavity after pars plana vitrectomy (PPV).

Pneumatic Retinopexy is a technique in which an expansile gas is injected intravitreally to tamponade a retinal tear, to which retinopexy (cryotherapy or laser) has been applied. It is usually performed for simple retinal detachments with single small retinal tears in the upper quadrants of the retina. As 100% gas is used the IOP can significantly increase within hours (Table 4).

When intraocular gas is placed in the vitreal cavity, it reduces the ocular rigidity, as it is more compressible. (Thompson, 2001). With an intraocular gas filled eye the IOP should be measured with applanation tonometry as the change to the ocular rigidity makes the schiotz reading inaccurate.

Properties of Intraocular gases:

EXPANSILE PROPERTIES OF INTRAOCULAR GASES			
Gas	Expansibility Of 100% gas	Duration in the eye	Expanding concentration
Air	Non expansile	5-7 days	NA
SF6	X2 in volume @ 24-48 hours	10-14 days	>20%
C2F8	X3.3 in volume	4-5 weeks	>16%
C3F8	X4 in volume @ 72-96 hours	6-8 weeks	>14%

Table 4. Intraocular gas tamponade agents and their properties

Central retinal artery occlusion is a very serious complication which may occur in the acute case, whilst the gas is expanding. Patients may use topical anti glaucoma drops at the end of surgery or be placed on oral diuretics overnight in order to ensure that there is no pressure spikes. Patients with pre existing glaucoma or risk factors such as anterior synechiae or compromised angles (with reduced outflow) can experience higher IOP spikes. The IOP should be measured post operatively and appropriate anti glaucoma treatment instituted if required.

5. Pars Plana Vitrectomy

Pars plana vitrectomy (PPV) procedure can be done for several reasons including vitreous haemorrhage, macular holes, epiretinal membranes, retinal detachment repair and proliferative diabetic retinopathy. Adjuvants such as heavy liquid, (perfluorocarbon), intraocular gases, silicone oil (1000cs, 5000cs and heavy oil) may be used. Heavy liquid is usually removed at the time of the surgery; however other internal tamponade agents may be present for weeks to several months depending on the retinal status. Some patients with complex retinal detachment may require long term tamponade of the oil, in a few cases, because of the high risk of redetachment the VR surgeon may opt not to remove the silicone oil.

Pars plana vitrectomy can induce raised intraocular pressure within 2 hours (Desai, 1997), whether on its own or combined with lensectomy, scleral buckling and endolaser due to fibrin formation. When pars plana vitrectomy is done, for retinal detachments, intraocular gas may be injected to replace the vitreous. Its floatation force and volumetric displacement allows the retina to flatten.

Intraocular gases may be used in an expansile or non expansile concentration. Concentrations >20%, 16% and 14% mixture with of SF₆, C₂F₆ and C₃F₈ mixture with air are expansile respectively (Table 4). Tonometry on gas filled eyes is best done with applanation tonometry. Pneumatic tonometry and indentation tonometry underestimated the elevated IOP by 25% and 79% respectively (Poliner LS and Schoch LH, 1987)

5.1 Pathogenesis of Secondary Glaucoma (Intraocular Gases)

~35% of patients post pars plana vitrectomy develop IOPs>30mmHg within 48 hours (Han DP, 1989). It is postulated that the rise in IOP is mainly due to secondary open angle mechanisms (Han DP, 1989). Angle closure mechanisms causing raised IOP have been seen in 20% of patients. This occurs because of ciliary body oedema, iridocorneal apposition or pupillary block. However 26% of patients may develop late IOP rise which can be secondary to neovascular mechanism as seen in diabetics (Aaberg and Van Horn 1978) Other mechanisms include pupillary block, mediated by intraocular gas, fibrin or an intraocular lens, was the predominant angle-closure mechanism.

MECHANISM OF SECONDARY GLAUCOMA FROM VITREORETINAL PROCEDURES WITH INTRAOCULAR GAS
Secondary Open angle Secondary Angle closure <ul style="list-style-type: none">• due to posterior pressure of the gas on the iris narrowing the angle (this is well demonstrated in the aphakic patient, who can relieve the pupillary block by posturing face down so that the gas bubble moves to the posterior pole and aqueous collects in the anterior chamber)• ciliary body edema and iridocorneal apposition Pupillary block (aphake) <ul style="list-style-type: none">• Intraocular gas bulging through the pupil. (may be relieved by face down posturing)

Table 5. Mechanism of secondary glaucoma from Intraocular Gas

Face down post op posturing after macula hole surgery also has 2 roles; in addition to tamponading the retina, it keeps the gas bubble away from the lens, and thereby preventing a gas induced cataract and pupillary block in an aphakic patient. Interestingly acute angle closure glaucoma has been described in the fellow eye during prone posturing after a vitreoretinal procedure (Sutter et al, 2003). It was postulated that the lens moves anteriorly during prolonged prone posturing. The patients most at risk of angle closure include; the Asian, Chinese or Inuit origin, family history, hyperopia, short axial length or microphthalmos. Prone position narrow angle test was introduced in 1968. Lying prone in a dark room, causes angle closure secondary to pupillary block as the lens moves anteriorly in an extended prone position provocation test. However, this posture actually prevents pupillary block in the eye that has intraocular gas or oil as this floats to tamponade the posterior pole (away from the pupil) in prone posturing. Supine posturing must be avoided in patients with internal tamponade (gas or oil) as they float in the vitreal cavity and cause anterior displacement of the lens resulting in pupillary block. Even in the aphakic patient a bubble of gas occluding the pupillary area can produce pupillary block glaucoma and this may be relieved with face down posturing which moves the internal tamponade agent posterior, away from the pupil, hence aqueous humour can

flow in to the anterior chamber. Supine posturing can also cause intraocular gas/oil to affect the lens metabolism causing a gas cataract or increasing nuclear sclerosis/posterior capsular cataract with gas and oil respectively.

Air travel is contraindicated in the presence of intraocular gas (Table 6). Acute IOP rise can occur if air travel is undertaken or a mountainous climb with intraocular gas as the changes in the atmospheric pressure will result in a relatively rapid enlargement of the gas bubble which leads to a very high risk to closure of the Central Retinal Artery (CRA). Jackman et al, 1995 noted that eyes with intraocular gas that underwent hyperbaric oxygen therapy or scuba diving had elevated IOPs on return to normal atmospheric pressure.

SITUATIONS TO AVOID IN PATIENTS WITH INTRAOCULAR GAS	
SITUATION	MECHANISM of INCREASE IN IOP
<ul style="list-style-type: none">• Air travel• Mountainous climb• General Anaesthesia with Nitrous oxide• Supine posturing• Scuba diving	<ul style="list-style-type: none">• Gas expansion (on ascent)• Gas expansion (on ascent)• Gas expansion (as Nitrous oxide diffuses into the intraocular gas)• Pupillary block and ‘gas cataract’• Gas expansion on return to normal atmospheric pressure
<ul style="list-style-type: none">• Hyperbaric oxygen therapy	<ul style="list-style-type: none">• Gas expansion on return to normal atmospheric pressure

Table 6. Conditions to avoid in the presence of intraocular gas

Patients with intraocular gas should not undergo general anaesthesia with nitrous oxide as intraoperatively, this gas diffuses rapidly into the intraocular gas bubble and causes rapid expansion of the gas bubble, increasing the intraocular pressure. Central retinal artery occlusion has been reported in patients who have had general anaesthesia whilst having an intraocular gas bubble. There have been several reported cases of irreversible loss of vision from use of nitrous oxide during general anaesthesia (Hart, 2002, Kodjikian, 2003 and Silvanus et al, 2008)

In the acute case of elevated IOP, on the first post operative day, topical anti glaucoma medications (beta blockers, prostaglandin analogues, carbonic anhydrase inhibitors, alpha 2 agonists) and oral carbonic anhydrase inhibitors may be used. If the IOPs continue to increase, an anterior chamber paracentesis may be done or a small volume of gas may be aspirated from the vitreal cavity with a 27G needle and a 1ml syringe. Prophylactic treatment with intraoperative carbonic anhydrase may decrease the pressure in the post operative phase (Ruby et al, 1999) and may be routinely used by some VR surgeons.

6. Silicone oil

Since the 1960s, silicone oil has being used as a vitreous substitute for long term intraocular tamponade in retinal surgery, usually for a period of 2-6 months depending on the type of silicone oil, retinal detachment and surgeon’s choice. In some cases of complex retinal detachments that oil may be left in long term.

Silicone Oil is a viscous fluid with the cohesive forces due to the molecular structure and hence its resistance to flow. There are 2 main types of silicone oil; that ‘lighter than water’

and the other 'heavier than water' oil (Heavy oil). 'Lighter than water' oil, floats in the eye 'Heavier than water' oil e.g. Densiron® 68 and Oxane HD, provides long term tamponade for inferior retinal problems as this oil sinks in the vitreal cavity.

Glaucoma complicating vitreoretinal surgical procedures with silicone oil varies from 3-40% (Romano et al, 2010). The incidence of Silicone oil induced glaucoma from the silicone oil Study report was 8% (Henderer, 1999). The incidence of secondary glaucoma with intraocular silicone oil use ranges from 2.2% in 6 months to 56% in 8 months, so therefore, the longer that the oil is present in the eye, the more likely it is to cause secondary glaucoma.

6.1 Pathogenesis of secondary glaucoma (silicone oil)

The mechanism for secondary glaucoma includes pupillary block glaucoma, closure of peripheral iridectomy, trabecular block with emulsified oil or non emulsified oil, inflammation and peripheral synechial angle closure (Table 7).

Silicone oil can cause pupil block glaucoma in the aphakic patient. Migration of the silicone oil into the anterior chamber is a cause of secondary glaucoma (Figure 1). Infiltration into the trabecular meshwork of emulsified or non emulsified silicone oil or macrophage oil induced endocytosis can result in open angle glaucoma. In addition to a glaucomatous pressure dependent optic neuropathy silicone oil may also infiltrate the optic nerve, resulting in a granulomatous retrolaminar silicone oil reaction.

Honavar et al, 1997 studied the effect of silicone oil on 150 eyes with complicated retinal detachments. He found that glaucoma antedated the retinal surgery in 13.3% of eyes. Silicone oil was the etiologic factor in 70% with neovascular glaucoma being the causative factor in 11.7% of cases. Significant positive risk factors for developing glaucoma were; pre existing glaucoma, diabetes, trauma, aphakia, silicone oil in the anterior chamber, emulsified silicone oil and rubeosis. Myopia and anatomical failure were negative risk factors.

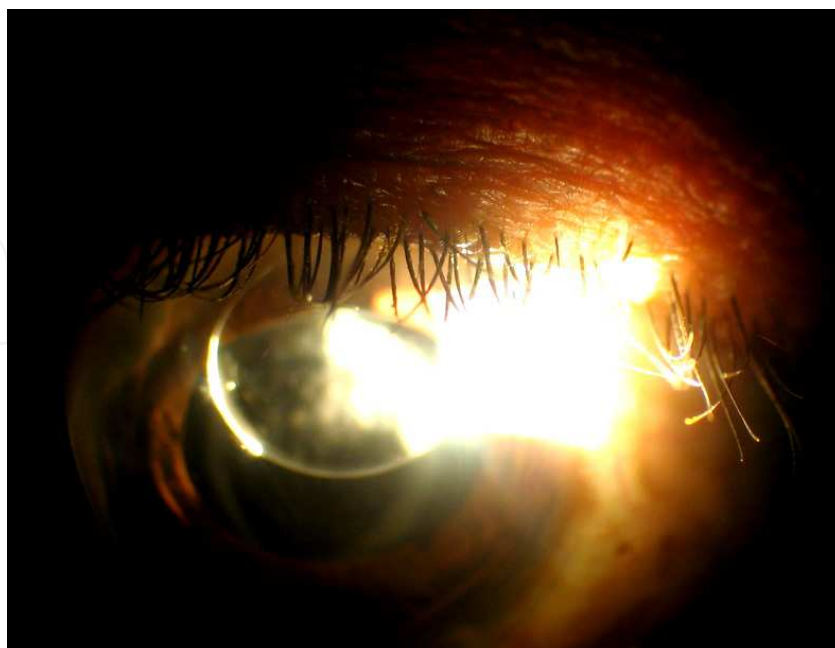


Fig. 1. A bubble of Silicone oil in the Anterior chamber

MECHANISMS OF SECONDARY GLAUCOMA FROM PROCEDURES WITH SILICONE OIL
<ul style="list-style-type: none">• Closure of Peripheral Iridotomy (by fibrin, blood or residual capsule)• Pupillary block (aphake,pseudophake, phakic (with subluxated lens))• Migration of emulsified and non emulsified oil into angle• Infiltration of trabecular meshwork (by oil droplets)• Inflammation, Trabeculitis (macrophage oil induced endocytosis)• Synechial angle closure• Overfill of vitreal cavity with silicone oil• Pre existing glaucoma/angle pathology• Rubeosis iridis

Table 7. Mechanism of Secondary Glaucoma from Silicone Oil

6.1.1 Pupillary block glaucoma

Pupillary block glaucoma occurs in 0.9% of all silicone oil filled eyes (Han DP et al, 1989). This condition is more likely to occur in aphakes, where the oil bubble may occlude the pupil, obstructing the flow of aqueous humour from the posterior chamber to the anterior chamber. Hence for aphakes, a peripheral iridectomy may be done using the vitrector. When ‘lighter than water’ oil is used the periphery iridotomy (PI) is done inferiorly (Ando’s peripheral iridectomy). ‘Lighter than water’ oil will float, so if it came into the anterior chamber obstructing the pupil, an inferior PI would be unobstructed and therefore, maintain the equalization of pressure between the anterior and posterior chamber. If ‘heavy oil’ is used the PI should be done superiorly as heavy oil remains inferiorly and can block an inferior PI. Pupillary block glaucoma may also occur in 6% of pseudophakic and phakic eyes where the anterior hyaloid face and zonules are disrupted (Riedel et al, 1990, Jackson T et al, 2001). The PI done at the time of the retinal surgery allows the aqueous humour to flow freely from the posterior to the anterior chamber thereby eliminating the raised IOP from pupillary block. Closure of the PI may occur within the short term because of blood or fibrin or long term contracture of the PI, resulting in pupillary block glaucoma if the silicone oil is adjacent to the pupil in the aphakic patient. Short term iridotomy failure occurred within 2 days in 31% and 85% within a month (Zalta et al, 2007). If the PI closes it may be reopened with the Nd YAG. However, Nd YAG laser PI can have a high rate of failure of 78% in reopening inferior PIs (Reddy, 1995). An iridotomy effectively reduced the mean IOP by 66% and peripheral anterior synechiae by 46% (Zalta et al, 2007). The YAG laser may be used where fibrin has occluded the PI. However, t-PA has been used successfully to reabsorb the fibrin occluding peripheral iridotomies (Jaffe, 1989). The use of intracameral tPA can improve long term patency of the PIs in 40% of cases post laser (Zalta et al, 2007). However, 11-33% of peripheral iridotomies will close in the post operative phase (Zalta et al, 2007) and this is moreso seen in diabetics or patients with PVR (Madreperla et al, 1995). If the patient is phakic the lens usually prevents pupillary block glaucoma and no PI is required.

6.1.2 Silicone oil and the anterior chamber

If the silicone oil enters the anterior chamber it will float on top of the aqueous humour and result in a hyperleon (‘inverted’ or ‘inverse’ hypopyon, if emulsified oil bubbles occur). This

can block the outflow from the angles in that area and the emulsified oil may block the trabecular meshwork causing an open angle glaucoma (Figure 2).

Oxane HD and Densiron “heavier than water” oil has a specific gravity of 1.02 g/cm³. When dispersed into droplets, one expects them to sink. There has been one reported case of emulsification of Oxane HD in an eye that unexpectedly manifested as an “inverted hypopyon”.

Oil in the anterior chamber should be removed early to prevent problems with glaucoma. If oil is present in the vitreal cavity, care must be taken to ensure that it doesn’t come forward during the removal of the oil in the anterior chamber. This can be done with the use of 2 anterior chamber paracentesis. In one opening viscoelastic is injected into the AC pushing the oil towards the other paracentesis site where it is removed. The patient would be placed on anti glaucoma drugs until the viscoelastic reabsorbed, which can sometimes be delayed in eyes with reduced aqueous outflow. If only one paracentesis is used to aspirate the oil from the AC, the oil in the vitreal cavity will come forward to replace it, resulting in more oil in the AC.



Fig. 2. ‘inverted hypopyon’ , emulsified oil in the Anterior chamber

6.1.3 Silicone Oil and the lens

Lensectomy may be done at the time of silicone oil surgery if the patient has a cataract which partially occludes the fundal view. If the patient is left pseudophakic, there will be a limited barrier to allow oil to float into the anterior chamber. However, in the event that the patient is left aphakic (whether or not a capsule is present), a peripheral iridotomy should be done. This prevents pupillary block glaucoma by oil. If the regular silicone oil is used an inferior peripheral iridotomy is done. If heavy oil is used then a superior peripheral iridotomy should be done, as the heavy oil remains in the inferior aspect of the anterior chamber and would block an inferior PI. The superior PI in this case allows aqueous humour to flow from the posterior chamber to the anterior chamber. This alleviates the secondary glaucoma from pupillary block.

6.1.4 Emulsification: Occlusion of the trabecular meshwork: Open angle glaucoma

Oil emulsification occurs at interfaces between the oil bubble and ocular tissues or aqueous forming small droplets (emulsified oil). These small droplets can pass through the zonules via the pupil into the anterior chamber. They may then block the trabecular meshwork, either physically or once ingested by macrophages. Silicone oil emulsification occurs in 0.7-

56% of cases (Valone J and Mc Carthy M, 1994)). It is a poor prognostic factor for control of IOP, odds ratio 15.3 (Honavar, 2001). The longer duration that silicone oil is in the eye, the more the likelihood of emulsification. Fibrinogen or fibrin can accelerate the emulsification process. Emulsified oil bubbles can be seen on the surface of the iris. If an 'inverted hypopyon' is not present, gonioscopy may reveal emulsified oil bubbles in the angle. Emulsified silicone oil in the anterior chamber must be removed at the time of removal of silicone oil (ROSO). If the patient has undergone ROSO already and there is residual emulsified oil in the anterior chamber, a single paracentesis site can be made and the emulsified oil bubbles removed with active aspiration with a simcoe.

6.1.5 Heavy oil

Heavy oil has a higher specific gravity and therefore, tamponade the inferior retinal better than conventional oil.

However shallow anterior chambers (AC) may occur in 1.9% of patients with silicone oil filled eyes compared with 5.3% with heavy oil filled eyes at day 1 post op (Romano et al, 2010). Romano et al, 2010, noted that elevated IOP occurred in 14% and 11.4% of eyes normal silicone oil at day 1 and 1 month respectively, compared to 20% and 16% for the same period in heavy oil filled eyes. However at 1 year the mean IOP was 16.7mmHg and 19.7mmHg in the silicone oil and heavy oil groups respectively. This difference was not statistically significant ($p=0.21$, chi-square test).

However, Wong et al, 2009, showed that Densiron (heavy oil) had a statistically significant higher IOP on the first day and 2 weeks post operatively than silicone oil ($P=0.05$ and 0.01 respectively). However, at 4 weeks post operatively there was no statistical difference in the IOP between the 2 groups. Heavy oil is removed earlier as it has a higher risk of inflammation. Small amounts of emulsification of Densiron induce macrophage activity (Hiscott et al, 2001) and increase the level of inflammation in the eye, inducing open angle glaucoma.

Zheng et al, 2010 found an 18.5% incidence of elevated IOP and emulsification each with Densiron. However after 3 months post oil removal the IOP returned to <20 mmHg. In that study 11.1% of eyes became hypotonous after removal of the silicone oil. This can occur because of redetachment, proliferation of PVR or because of extensive retinectomies done at the time of retinal detachment repair.

In the silicone oil study 18% of silicone oil eyes and 31% of C3F8 filled eyes had hypotony at 3 years (Barr CC Lai MY Jean JS, et al 1993). This may be due to extensive retinectomies (in order to repair complex detachment) and not the effect of the oil. Leaving the silicone oil in situ in these situations prevents phthisis bulb as it acts a barrier to the reabsorption of aqueous via the choroid.

6.1.6 Management options

Topical and systemic anti glaucoma medications controlled IOP in 30% of eyes (mean number of medications 1.5), with oral acetazolamide required in 7/18 cases. 50% of the eyes required chronic glaucoma treatment. Removal of silicone oil (ROSO) alone did not allow any of the eyes to achieve normal intraocular pressure. However with ROSO and medical therapy 25% achieved normal IOPs. Control of IOPs were achieved in 10/14 eyes that underwent surgical intervention. 5/14 that underwent Trabeculectomy + Mitomycin C had achieved normal IOP (2 cases with additional medical therapy and one with surgery alone,

post ROSO). One patient underwent an anterior chamber tube shunt to the encircling band (ACTSEB) and achieved normal IOPs with additional medical therapy. 3 patients underwent cyclocryotherapy, with 33% achieving normal IOP without and 33.3% with medical therapy. 4 patients underwent transcleral cyclophotocoagulation with a 75% success rate of controlling the IOP.

This contrast with Budenz 2001, who looked at the effect of 3 surgical procedures; ROSO alone, glaucoma surgery alone and combination of ROSO and Glaucoma surgery for the management of persistent raised IOPs. The mean IOP before surgical intervention was 41.4 +/- 15.1mmHg. 62% of patients that underwent silicone oil removal had their IOPs controlled. Of the 38% that failed (of the ROSO alone group), 92% had elevated IOP and 8% hypotony. Patients who underwent glaucoma surgery alone had a 50% failure (75% of those due to hypotony). However, patients that underwent ROSO and glaucoma surgery had a 33% failure rate with only 1/3 being from hypotony.

In patients with Silicone oil induced glaucoma, removal of the oil may reduce the intraocular pressure. If the oil is not removed before tube glaucoma surgery, migration of oil into tube can occur, even if it is placed inferiorly, with the hope that the oil will float and not occlude the tube (Kim and Bauman 2004)

Nguyen et al reported on intraocular pressure control in 50 eyes with PPV and silicone oil. Successful IOP control in 8 of 14 eyes that had ROSO alone and 3 of 5 that had Molteno valve implant alone. Only one case had Nd YAG transscleral cyclophotocoagulation which was successful. However one case underwent a modified Schocket procedure but didn't achieve normal IOPs.

Transscleral cyclophotocoagulation has shown successful IOP control in 74-82% of patients after 1 year although the visual function was poor in these patients (Bloom et al 1997 and Han et al, 1999). Early removal of silicone oil (6/12) has been noted to have reduced risk of secondary glaucoma and similar redetachment rates (Han et al 1998).

7. Conclusion

The underlying cause of secondary glaucoma after vitreoretinal surgery is often multifactorial in nature and may benefit from an exact analysis for an adequate and successful treatment regimen. Scleral buckling causes glaucoma that is transitory and settles well with topical anti glaucoma medication. Silicone oil related glaucoma can cause a refractory glaucoma.

Patients that underwent pars plana vitrectomy with silicone oil are the most refractory ones to treatment and present a surgical challenge. Intraocular pressure elevation is a common occurrence after intravitreal silicone oil injection. The underlying mechanism may often be multifactorial in nature. Patients in whom uncontrolled IOP develops may benefit from aggressive medical and/or surgical treatment with silicone oil removal, glaucoma implants, or cyclodestructive procedures.

8. References

- Aaberg TM, Van Horn D Br J Ophthalmol. (1978) Late complications of pars plana vitreous surgery. *Ophthalmology* Vol 85 pp 126-40 ISSN 0161-6420
- Abrams GW, Edelhauser HF, Aaberg TM, Hamilton LH. (1974) Dynamics of intravitreal sulphur hexafluoride gas. *Invest Ophthalmol.* Nov; Vol 13 No11 pp 863-8.

- Anderson N G, Finemad MS, Brown GC.(2006) Incidence of Intraocular pressure spike and other Adverse events after vitreoretinal surgery. *Ophthalmology* Vol 113 No1 pp 42-47 ISSN 0161-6420
- Barr CC, Lai MY, Lean JS, et al (1993) Post operative intraocular pressure abnormalities in the Silicone Study: Silicone study Report 4. *Ophthalmology* Vol 100 pp 1629-35 ISSN 0161-6420
- Bakri SJ, Beer PM. (2003) The effect of intravitreal triamcinolone acetonide on intraocular pressure. *Ophthalmic Surg Lasers Imaging*. Sep-Oct Vol 34 No5 pp 386-90.
- Bloom PA, Tsai JC, Sharma K, et al. (1997) "Cyclodiode". Transscleral diode laser cyclophotocoagulation in the treatment of advanced refractory glaucoma. *Ophthalmology* Vol 104 pp1508-19; discussion 1519-20. ISSN 0161-6420
- Budenz DL, Taba KE, Feur MS, Eliezer R, Cousins S, Henderer J, Flynn HW Jr. (2001). Surgical management of secondary glaucoma after pars plana vitrectomy and silicone oil injection for complex retinal detachment. *Ophthalmology*, September Vol 108 No 9 pp 1628-32 ISSN 0161-6420
- Desai UR, Alhalel AA, Schiffman RM, Campen TJ, Sunday G, Muhuch A (1997) Intraocular pressure elevation after simple pars plana vitrectomy. *Ophthalmology* Vol 104 pp781-6 ISSN 0161-6420
- Fran Smith M, Doyle W, Fanous M. (1998) Modified Aqueous Drainage Implants in the treatment of Complicated Glaucomas in Eyes with pre existing episcleral bands. *Ophthalmology* Vol 105 pp2237-2242 ISSN 0161-6420
- Gedde SJ (2002). Management of glaucoma after retinal detachment surgery. *Curr Opin Ophthalmol* Vol 13 pp103-109
- Gillies MC, Simpson JM, Billson FA, et al. (2004) Safety of an intravitreal injection of triamcinolone: results from a randomized clinical trial. *Arch Ophthalmol* Vol 122 No3 pp336- 40. ISSN 0003-9950
- Han DP, Lewis H, Lambrou FH, Mieler WF (1989) Mechanisms of intraocular pressure elevation after pars plana vitrectomy. *Ophthalmology* Vol 96 pp1357-62 ISSN 0161-6420
- Han L, Cairns JD, Campbell WG, et al. (1998) Use of silicone oil in the treatment of complicated retinal detachment: results from 1981-1994: *Aust N Z J Ophthalmol* Vol 26 pp299 -304
- Han SK, Park KH, Kim DM, Chang BL.(1999) Effect of diode laser trans-scleral cyclophotocoagulation in the management of glaucoma after intravitreal silicone oil injection for complicated retinal detachments. *Br J Ophthalmol* Vol 83 pp 713-7. ISSN 0007-1161
- Hart RH, Vote BJ, Borthwick JH, McGeorge AJ, Worsley DR (2002). Loss of vision caused by expansion of intraocular perfluoropropane (C3F8) during nitrous oxide anaesthesia. *Am J Ophthalmol* Nov;134(5):761-3
- Hartley RE, Marsh RJ. (1973). Anterior depth changes after retinal detachment. *Br J Ophthalmol* Vol 57 546- 50. ISSN 0007-1161
- Hayreh SS, Baines JAB (1973) Occlusion of the vortex veins: an experimental study. *Br J Ophthalmol* Vol 57 pp 17-238 ISSN 0007-1161


- Heiden HP, Kampik A, Thierfelder S. (1991) Emulsification of silicone oils with specific physiochemical Characteristics *Graefes Arch Clin Exp Ophthalmol* 229:88-94
- Henderer JD, Budenz DL, Flynn HW, et al. (1999) Elevated intraocular pressure and hypotony following silicone oil retinal tamponade for complex retinal detachment: incidence and risk factors. *Arch Ophthalmol*. Vol 117 pp 189–195. ISSN 0003-9950
- Hiscott P, Magee RM, Colthrust M, Lois N, Wong D. (2001) Clinicopathological correlation of epiretinal membranes and posterior lens opacification following perfluorohexyloctane (F₆H₈) tamponade. *Br J Ophthalmol* Vol 85 pp179-183 ISSN 0007-1161
- Kreiger AE, Hodgkinson BJ, Frederick AR, et al. (1971) The results of retinal detachment surgery. Analysis of 268 operations with a broad sclera buckle. *Arch Ophthalmol* Vol 86 pp385-394 ISSN 0003-9950
- Jackman SV and Thompson JT. (1995) Effects of hyperbaric exposure on eyes with intraocular gas bubbles. *Retina* 15:160-166
- Jackson TL, Thiagarajan M, Murthy R, Snead MP, Wong D, Williamson TH. (2001) Pupil block glaucoma in phakic And pseudophakic patients after vitrectomy with silicone oil injection. *Am J Ophthalmol* ;132(3):414-416
- Jaffe GJ, Lewis HA, Han DP, Williams GA and Abrams GW. (1989) Treatment of post vitrectomy fibrin pupillary Block with tissue plasminogen. *Am J Ophthalmol* Vol 108 pp 170-175
- Jones R 3rd, Rhee DJ. (2006) Corticosteroid induced ocular hypertension and glaucoma: a brief review and update of the literature. *Curr Opin Ophthalmol*. Apr Vol 17 No2 pp163-7. Review.
- Jonas JB (2005) Intravitreal triamcinolone acetate for the treatment of intraocular oedematous and neovascular disease. *Acta Ophthalmol* Vol 83No6 pp645-63
- Kim RW and Bauman C. (2004) Anterior segment complications related to vitreous substitutes. *Ophthalmol Clin North Am*. Vol 17 No4 pp569-76
- Kramar M, Vu L, Whitson JT, He YG. (2007) The effect of intravitreal triamcinolone on intraocular pressure. *Curr Med Res Opin*. Jun Vol23 No6 pp1253-8. Epub 2007 Apr 25.
- Konstantopoulos A, Williams CP, Newsom RS, Luff AJ. (2007) Ocular morbidity associated with intravitreal triamcinolone acetate. *Eye (Lond)*. 2007 Mar;21(3):317-20. Epub 2006 May 19. ISSN 0950-222X
- Li W, Zheng J, Zheng Q, Wu R, Wang X, Xu M. (2010) Clinical complications of Densiron 68 intraocular tamponade for complicated retinal detachment. *Eye Jan* Vol 24 No 1 pp21-8 ISSN 0950-222X
- Madreperla SA, Mc Cuen BW. (1995) Inferior peripheral iridectomy in patients receiving silicone oil. *Retina* Vol 15 pp87-90
- Nguyen QH, Lloyd MA, Heuer DK, et al. (1992) Incidence and management of glaucoma after intravitreal silicone oil Injection for complicated retinal detachments. *Ophthalmology* Vol 99 pp1520-6. ISSN 0161-6420
- Polinier Ls, Schoch LH, (1987) Intraocular pressure assessment in gas filled eyes following vitrectomy. *Arch Ophthalmol* Vol 105 No2 200-2

- Perez RN, Phelps CD, Burton TC (1976) Angle closure glaucoma following sclera buckling operations. *Trans Am Academy Ophthalmol Otolaryngol* Vol 81 pp 247-252
- Phelps CD, Burton TC. (1977) Glaucoma and retinal detachment. *Arch Ophthalmol* Vol 95 pp 418-422. ISSN 0003-9950
- Singh IP, Ahmad SI, Yeh D, Challa P, Herndon LW, Allingham RR, Lee PP.(2004) Early Rapid rise in Intraocular pressure after intravitreal triamcinolone injection *Am J Ophthalmol*. Aug Vol 138 No2 pp286-7.
- Spiga MG, Borrás T. (2010) Development of a gene therapy virus with a glucocorticoid-inducible MMP1 for the treatment of steroid glaucoma. *Invest Ophthalmol Vis Sci*. Jun Vol 51 No6 pp3029-41
- Sutter, F, Smorgon A, McClellan A (2003) Acute Angle Closure in the Fellow Eye as a complication of prone positioning after vitreoretinal surgery. *Arch Ophthalmol*, Vol 121 pp1057 ISSN 0003-9950
- Thompson TL (2001) The Effects and Action of Scleral Buckles in the Treatment of Retinal Detachment. *Retina 3rd edition*, Stephen Ryan (Editor in Chief) 1994-2009 Mosby Inc, ISBN 0-323-00804. St Louis , Missouri
- Reddy MA, Aylward GW. (1995) The efficacy of Nd:YAG laser iridotomy in the treatment of closed peripheral iridotomies In silicone-oil-filled aphakic eyes. *Eye*. Vol 9(pt 6) pp 757-759 ISSN 0950-222X
- Retisert® (fluocinolone acetonide intravitreal implant) 0.59 mg, package insert, Bausch and Lomb, revised Prescribing information March 2009
- Riedel KG, Gabel VP, Neuberger L, Kampik A, Lund OE. (1990) Intravitreal silicone oil injection: complications and treatment of 415 consecutive patients. *Graefes Arch Clin Exp Ophthalmol* Vol 228 No 1 pp 19-23
- Ricci F, Missiroli F, Parravano M. (2006) Argon laser trabeculoplasty in triamcinolone acetonide induced ocular hypertension refractory to maximal medical treatment *Eur J Ophthalmol*. Sep-Oct Vol 16 No5 pp 756-7.
- Ruby AJ, Grand MG, Williams D, Thomas MA. (1999), Intraoperative acetazolamide in the prevention of intraocular Pressure rise after pars plana vitrectomy with fluid gas exchange. *Retina*; Vol 19 pp185-7
- Rubin B, Taglienti A, Rothman RF, Marcus CH, Serle JB. (2008) The effect of selective laser trabeculoplasty on intraocular pressure in patients with intravitreal steroid-induced elevated intraocular pressure. *J Glaucoma*. Jun-Jul Vol 17 No4 pp287-92 ISSN 1057-0829
- Valone J Jr, McCarthy M. (1994) Emulsified anterior chamber silicone oil and glaucoma. *Ophthalmology* Vol 101 pp 1908 -12. ISSN 0161-6420
- Wong D, Kumar I, Quah SA, Ali H, Valldeperas X, Romano MR. (2009) Comparison of postoperative intraocular pressure in patients with Densiron 68 vs conventional silicone oil: a case control study. *Eye* Vol 23 no 1 (January 2009) pp190-194 ISSN 0950-222X
- Yildirim N, Sahin A, Erol N, Kara S, Uslu S, Topbas S. (2008) The relationship between plasma MMP-9 and TIMP-2 levels and intraocular pressure elevation in diabetic patients after intravitreal triamcinolone injection. *J Glaucoma* Vol 17 No4 pp253-6 ISSN 1057-0829

Zalta, A H, Boyle, N S and Zalta A K (2007) Silicone Oil Pupillary Block *Arch Ophthalmol*,
vol 125 no7 pp883-888 ISSN 0003-9950

IntechOpen

IntechOpen



Glaucoma - Current Clinical and Research Aspects

Edited by Dr. Pinakin Gunvant

ISBN 978-953-307-263-0

Hard cover, 376 pages

Publisher InTech

Published online 09, November, 2011

Published in print edition November, 2011

This book summarizes current literature about research and clinical science in glaucoma and it is a synopsis and translation of the research conducted by individuals who are known in each of their respective areas. The book is divided into two broad sections: basic science and clinical science. The basic science section examines bench- and animal-modeling research in an attempt to understand the pathogenesis of glaucoma. The clinical science section addresses various diagnostic issues and the medical, laser and surgical techniques used in glaucoma management.

How to reference

In order to correctly reference this scholarly work, feel free to copy and paste the following:

Lizette Mowatt (2011). Secondary Glaucoma After Vitreoretinal Procedures, Glaucoma - Current Clinical and Research Aspects, Dr. Pinakin Gunvant (Ed.), ISBN: 978-953-307-263-0, InTech, Available from: <http://www.intechopen.com/books/glaucoma-current-clinical-and-research-aspects/secondary-glaucoma-after-vitreoretinal-procedures>

INTECH
open science | open minds

InTech Europe

University Campus STeP Ri
Slavka Krautzeka 83/A
51000 Rijeka, Croatia
Phone: +385 (51) 770 447
Fax: +385 (51) 686 166
www.intechopen.com

InTech China

Unit 405, Office Block, Hotel Equatorial Shanghai
No.65, Yan An Road (West), Shanghai, 200040, China
中国上海市延安西路65号上海国际贵都大饭店办公楼405单元
Phone: +86-21-62489820
Fax: +86-21-62489821

© 2011 The Author(s). Licensee IntechOpen. This is an open access article distributed under the terms of the [Creative Commons Attribution 3.0 License](https://creativecommons.org/licenses/by/3.0/), which permits unrestricted use, distribution, and reproduction in any medium, provided the original work is properly cited.

IntechOpen

IntechOpen