

We are IntechOpen, the world's leading publisher of Open Access books Built by scientists, for scientists

6,900

Open access books available

185,000

International authors and editors

200M

Downloads

Our authors are among the

154

Countries delivered to

TOP 1%

most cited scientists

12.2%

Contributors from top 500 universities



WEB OF SCIENCE™

Selection of our books indexed in the Book Citation Index
in Web of Science™ Core Collection (BKCI)

Interested in publishing with us?
Contact book.department@intechopen.com

Numbers displayed above are based on latest data collected.
For more information visit www.intechopen.com



A Preliminary In Vivo Study on the Histocompatibility of Silk Fibroin

Lu Yan¹, Zhao Xia¹, Shao Zhengzhong², Cao Zhengbing² and Cai Lihui¹

¹Department of Otorhinolaryngology, Huashan Hospital, Fudan University, Shanghai

²Department of Macromolecule Science, Fudan University, Shanghai, China

1. Introduction

Biomaterials used for tissue engineering should have the property of good histocompatibility, superb plasticity and desired degradability, so that it can be extensively applied for defect tissue repairing with excellent clinical outcome. In the past decade, silk fibroin has become one of the most favored biomaterials for its wide availability, superb performance and readiness to be shaped for different purposes in tissue engineering^[1-14]. Porous scaffolds made by silk fibroin can be made into different pore size and porosity to serve for different needs of tissue repairing. The porous structure may contribute to the mass exchange in the scaffolds. However, the implanted protein scaffolds will degrade and can hardly be separated from host tissues. Therefore, little has been reported on histocompatibility experiment in vivo for silk fibroin^[15-22].

In this chapter, progress in study of silk fibroin scaffold in tissue engineering application and biocompatibility research will be introduced, then our histocompatibility experiment of porous scaffolds will be reported. In our experiment, porous scaffolds were made platy and buried in subcutaneous part of the back of SD rat. Tissue reaction was observed, and the value of silk fibroin as tissue engineering scaffold material was discussed.

2. The application of silk fibroin in tissue engineering

It is known to all that the application of silk production as un-absorb suture has many years of history. Along with the progress of tissue engineering techniques, scientists can extract natural polymeric materials- fibroin from silk and make it into different forms to fit various needs of tissue engineering^[1]. Vitro studies show silk fibroin is biodegradable. The speed and degree of degradation can be adjusted through changing physicochemical property^[2-4]. The product of degradation is mainly free amino acid and has no toxic side-effect on tissue.

Silk fibroin can be easily made into different forms to serve for various needs such as membrane, gelatum, knitting scaffold, porous scaffold and electrospinning scaffold. Therefore, it has been gradually utilized in various medical field such as drug delivery^[5,6], nerve regeneration^[7-9], dermis healing^[10], artificial ligament repair^[11,12], bone or cartilage healing^[13,14], vascular tissue engineering^[15,16], otology application^[17] and so on.

3. Biocompatibility research of silk fibroin

Silk fibroin has been utilized as natural biomaterial in tissue engineering applications. Many researches have been made in vitro to reveal its attractive properties such as slow-controllable degradation, mechanical robustness, and inherent biocompatibility^[18-21].

For the silk fibroin scaffolds are made up of proteins, those materials which have been implanted will degrade and could hardly be separated from host tissues, that made the study of histocompatibility difficult. Therefore, few report can be found about research on biocompatibility and degradation of porous fibroin scaffolds in vivo ^[4,22].

4. Our in vivo research on the histocompatibility of silk fibroin

4.1 Materials and methods

Laboratory animals: 8 healthy female Sprague-Dawley rat, body weight 220g~250g, get from department of laboratory animal medicine, Fudan University

Preparation method of porous silk fibroin scaffold: After degummed, the raw silk was dissolved into aqueous solution of LiBr (lithium bromide). The silk fibroin solution was adjusted to the concentration of 20% after filtration and concentration. Then n-butyl alcohol was added into the solution as volume ratio of 2: 1. Mixed solution was added into self-made mould after low-speed agitation, and white porous scaffold was obtained after freeze drying. The average pore size of the scaffold was between 10 and 20μm.

Material preparation: We cut the porous silk fibroin scaffolds to 1cm×1cm squares (about 1 mm thick), infused the material into 75% ethanol solution for 0.5 hour, then immersed the materials into 0.9% NaCl water for 24 hours.

Technique: After peritoneal injection anesthesia, we longitudinal incised the skin of back open, blunt dissected surrounding tissues, and buried the porous silk fibroin scaffolds subcutaneous. Then we sew up the incision and raised the animals in different captivities.

Histological examination The rats were executed 2,4,6,8 weeks after operation. General observation and hematoxylin and eosin stain histological examination was performed.

4.2 Result and discussion

General observation Animals recovered well after operation. Throughout the period of implantation, all scaffolds were well tolerated by the host animals and immune responses to the implants were mild. No obvious systemic reaction, abnormal eating and sleeping behaviors were found. The implant sample in animals' back hunched mildly. The wounds and surrounding skin healed well when drawing materials at different times (figure 1). No obvious hyperemia, seepage or purulent exudates signs were found in surrounding skin and muscular tissue. The surface of the scaffolds was wrapped up by the thin, semitransparent fibrous membranes. There was no obvious change in shape and appearance after implanting (figure 2). The inflammatory reaction surrounding the tissue was slight. And no obvious granulation was found. (table 1)

The second week: Fibroin scaffold is eosinophilic staining. The surface is not regular while there are big or small pores inside. Hematoxylin-eosin staining microscopic examination (table 2). Fibroblast grows adherently on the surface of the material. The surrounding tissue hyperplasticly changes, inflammatory cell infiltrate is visible, most of which are lymphocytes and macrophages. No signs of tissue necrosis are found. (figure 3,4)

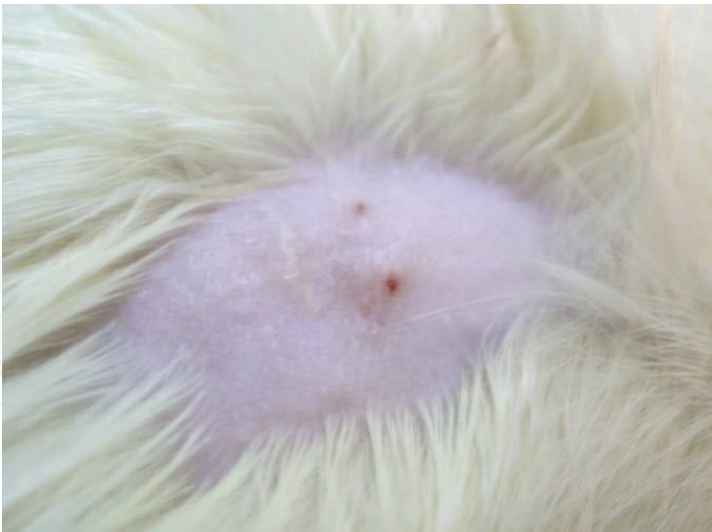

Fig. 1. The wound healed up well while taking samples

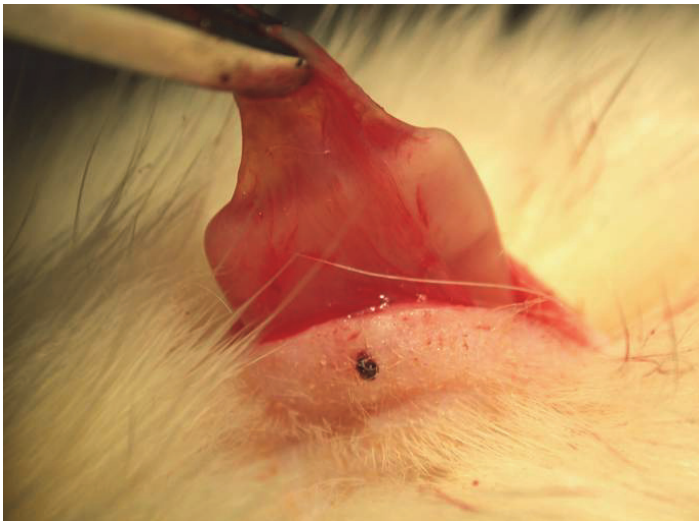


Fig. 2. Thin connective tissue wrap could be found on the scaffold, and the inflammatory reaction surrounding the tissue was slight.

Time(week)	Section number	inflammatory reaction	fibrous encapsulation	granulation formation
2	2	slight	yes	no
4	2	slight	yes	no
6	2	slight	yes	no
8	2	slight	yes	no

Table 1. general observation

The fourth week: There is few parts with eosinophilic staining inside the material disappears 4 weeks after operation, which shows crumbling phenomenon, while it’s general structure remains(figure 5). Fibroblasts grow along the surface of the scaffold or into the pores. There are lymphocytes and macrophages infiltrate. Vessel hyperplasia is visible,

while new capillary vessel inside the material is obvious. No signs of tissue necrosis are (figure 6).

The sixth week: There are a few parts with eosinophilic staining inside the material disappears 6 weeks after operation, which shows crumbling phenomenon, while it's general structure remains. Inflammatory cell infiltrate is visible 6 weeks after operation. Histocytes gradually grow deep into the scaffold. No signs of tissue necrosis are. (figure 7,8)

The eighth week: Histocytes grow more deeply into the scaffold. Inflammatory cell infiltrate is visible, most of which are macrophages. Vessel hyperplasia reduces inside the tissue, while hyperblastosis still obvious. No signs of tissue necrosis are. (figure 9,10)

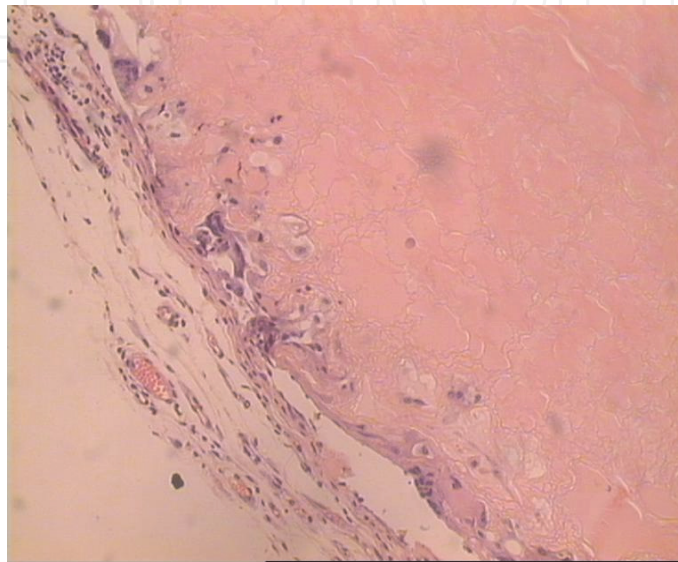


Fig. 3. Fibroblast grows adherently on the surface of the material two weeks after operation. The surrounding tissue hyperplasticly changes, inflammatory cell infiltrate is visible, most of which are lymphocytes and macrophages. No signs of tissue necrosis are found. ($\times 200$)

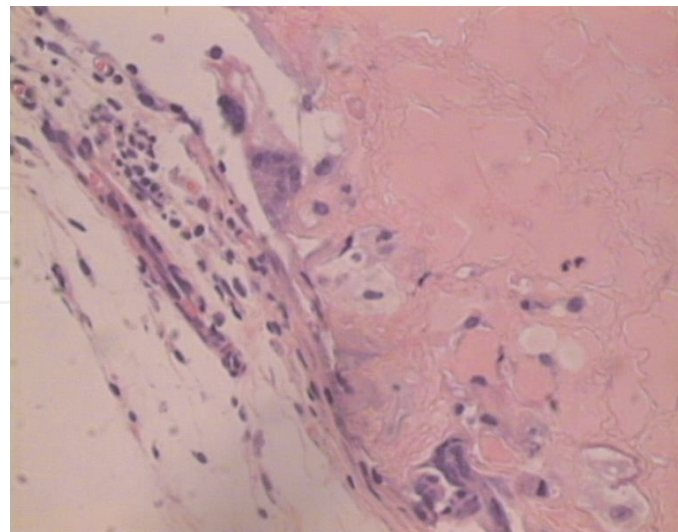


Fig. 4. Fibroin scaffold is eosinophilic staining. The surface is not regular while there are big or small pores inside. Fibroblasts grow adherently on the surface of the material. Inflammatory cell infiltrate is visible, most of which are lymphocytes and macrophages. ($\times 400$)

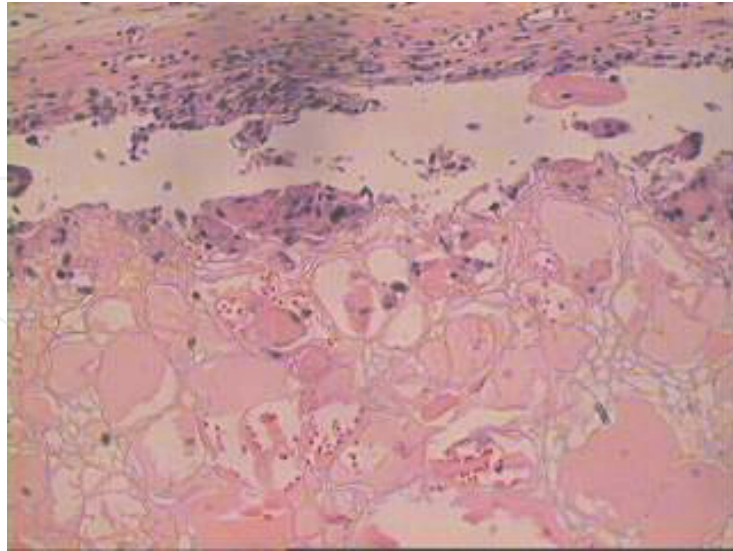


Fig. 5. There is few parts with eosinophilic staining inside the material disappears 4 weeks after operation, which shows disaggregation phenomenon, while it's general structure remains. ($\times 200$)

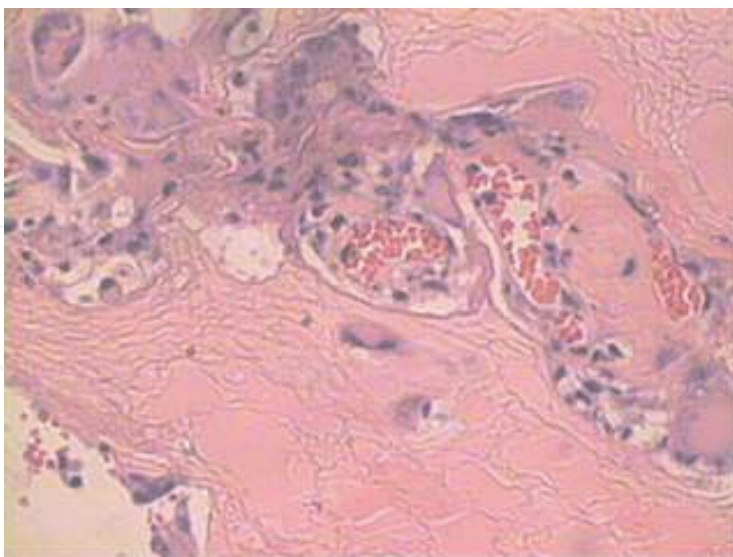


Fig. 6. Fibroblasts grow along the surface of the scaffold or into the pores. There are lymphocytes and macrophages infiltrate. Vessel hyperplasia is visible, while new capillary vessel inside the material is obvious. No signs of tissue necrosis are found. ($\times 400$)

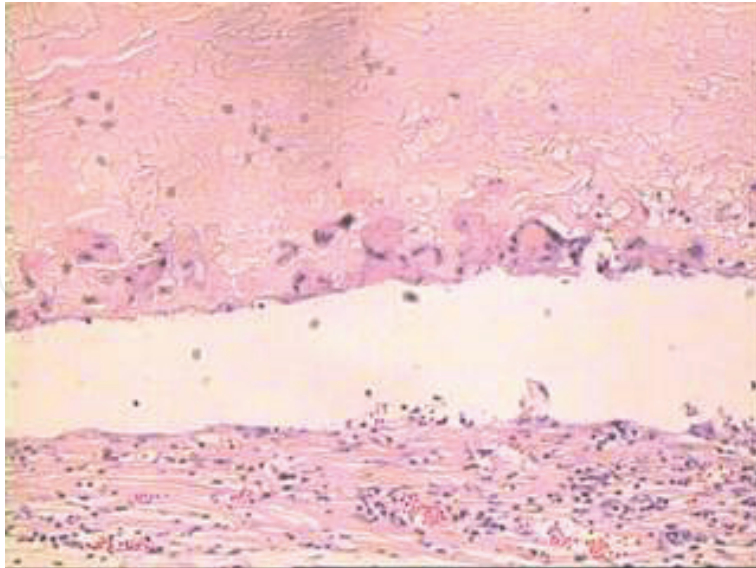


Fig. 7. Inflammatory cell infiltrate is visible 6 weeks after operation. Histocytes gradually grow deep into the scaffold. No signs of tissue necrosis are found. ($\times 200$)

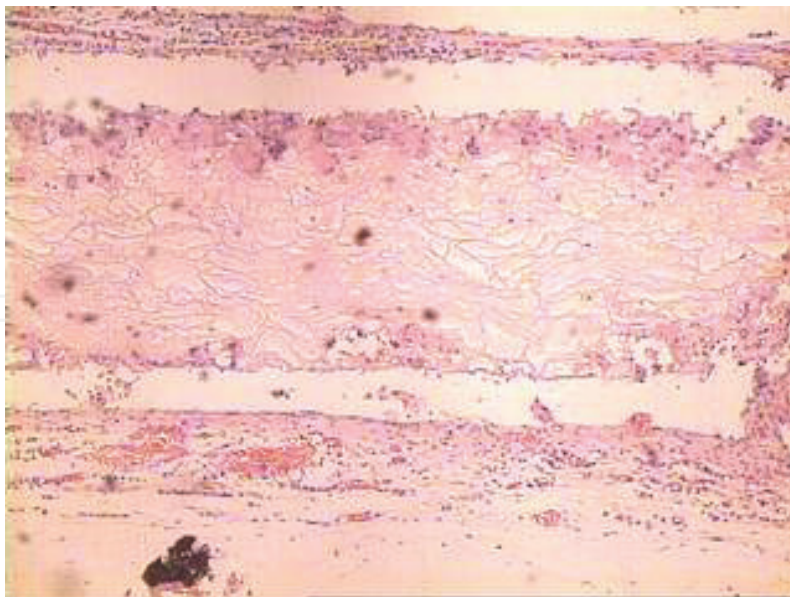


Fig. 8. There are a few parts with eosinophilic staining inside the material disappears 6 weeks postoperatively, which shows disaggregation phenomenon, while it's general structure remains. ($\times 200$)

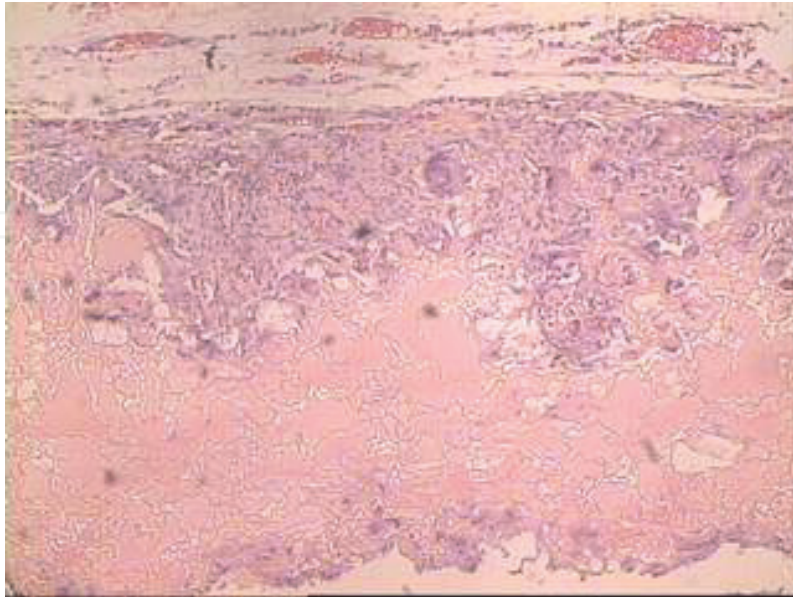


Fig. 9. Histocytes grow more deeply into the scaffold. Inflammatory cell infiltrate is visible, most of which are macrophages. Vessel hyperplasia reduces inside the tissue, while hyperblastosis still obvious. No sign of tissue necrosis is found. ($\times 200$)

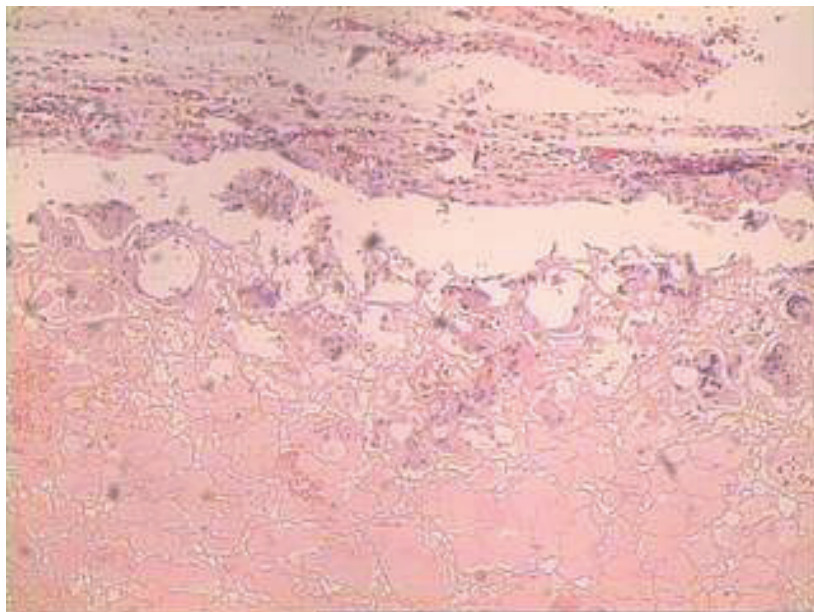


Fig. 10. The border of the scaffold break down at some part 8 weeks postoperatively, while the inside part remains as it was. ($\times 200$)

Time section (week)number	fibration	inflammatory cell type	Scaffold disaggregation	tissue necrosis	tissue ingrowth
2	2	yes	lymphocyte and macrophage	no	yes
4	2	yes	lymphocyte and macrophage	yes	no
6	2	yes	lymphocyte and macrophage	yes	no
8	2	yes	mosly macrophage	yes	no

Table 2. histopathology observation

Porous scaffolds made by silk fibroin can be formed into different pore size and porosity, which could meet the needs of different histocytes during repairing process. Porous structure is also helpful to the exchange of nutrient substance among different parts of scaffolds. So we choose the porous silk fibroin scaffold as the research object.

Biological material will be treated as foreign matter when implanted in the body, even if its biocompatibility is perfectly good. Therefore, foreign body reaction will be inevitable surrounding the material. The strength and extent of foreign body reaction are closely related to its biocompatibility and biodegradability. So, we evaluate the tissue reaction and material change after implantation by fibrous encapsulation, granulation formation , tissue fibrosis, type of inflammantary cells, tissue necrosis and tissue ingrowth, morphological changes and disaggregation of the scaffolds.

We found that wet porous fibroin scaffold was soft in texture, and could be easily cut into different forms to fit the need of implantation while the operation was performed. Tissue reaction around the materials was slight when we removed the scaffold, and the surface of the material was wrapped up by semitransparent fibrous membranes. The porous fibroin scaffolds were eosinophilic stained by HE. Its surface was irregular. And there are lacunes of different size inside the material. Chronic inflammation reaction occurred, mainly lymphocytes and macrophages could be found around the material. And fibrous capsule could be observed. After two weeks of implantation, blood capillary could be found proliferate into the lacuna of the material, and the fibroblasts also attached to the irregular surface of the material. These phenomena became more and more obvious as time went by, which showed that the surface texture of porous fibroin was favourable for interstitial cell to grow on. Moreover, the porous structure of the scaffold made the material permeable, which could probably cause the exchange of the nutrition and metabolite through the scaffold that lead to active tissue ingrowth. This may also be a plus factor for tissue regeneration.

Because the fibroin scaffolds were formed by protein and could hardly be separated from surrounding tissues, histopathology observation was performed after experiment instead of quantitative determination. During eight-weeks' observation, the scaffold disintegration started from the fourth week. But there was still no obvious change inside the scaffold structure until the eighth week, which indicated to us that we should set the observation period much longer to get more information about the degradation of fibroin porous scaffold in further research. We didn't make effective statistical analysis about the quantity and type of inflammatory cells surrounding the scaffold for the number of samples was too small. Moreover, according to the requirements of different tissue repair, the pore size and porosity of porous scaffolds should be different. And materials with different structure may cause different result in tissue reaction, tissue regeneration and material degradation. These are also challenging questions that need to be considered in further experiment.

5. Conclusion

To sum up, porous silk fibroin scaffold shows good histocyte attachment and has good histocompatibility. The Porous silk fibroin scaffold can degrade in vivo, but more study should be made on the mechanism and degradation products.

6. Acknowledgment

The chapter publication was funded by Shanghai Science and Technology Committee, 1052nm03801.

7. References

- Murphy AR, Kaplan DL. Biomedical applications of chemically-modified silk fibroin. *J Mater Chem.* 2009 Jun 23;19(36):6443-6450.
- Rebecca L. Horan, Kathryn Antle, Adam L. Collette, etc. In vitro degradation of silk fibroin. *Biomaterials*, Volume 26, Issue 17, June 2005, Pages 3385-3393
- Cao Y, Wang B. Biodegradation of silk biomaterials. *Int J Mol Sci.* 2009 Mar 31;10(4):1514-24.
- Wang Y, Rudym DD, Walsh A, etc. In vivo degradation of three-dimensional silk fibroin scaffolds. *Biomaterials.* 2008 Aug-Sep;29(24-25):3415-28.
- Lammel AS, Hu X, Park SH, etc. Controlling silk fibroin particle features for drug delivery. *Biomaterials.* 2010 Jun;31(16):4583-91.
- Wang X, Yucel T, Lu Q, etc. Silk nanospheres and microspheres from silk/pva blend films for drug delivery. *Biomaterials.* 2010 Feb;31(6):1025-35.
- Lu yan, Chi fang-lu, Zhao Xia, etc. Experimental study on facial nerve regeneration by porous silk fibroin conduit. *Zhonghua Er Bi Yan Hou Tou Jing Wai Ke Za Zhi.* 2006, 41(8),603-606.
- Yang Y, Ding F, Wu J, Development and evaluation of silk fibroin-based nerve grafts used for peripheral nerve regeneration. *Biomaterials.* 2007 Dec;28(36):5526-35.
- Tang X, Ding F, Yang Y, etc. Evaluation on in vitro biocompatibility of silk fibroin-based biomaterials with primarily cultured hippocampal neurons. *J Biomed Mater Res A.* 2009 Oct;91(1):166-74.
- Guan G, Bai L, Zuo B, etc. Promoted dermis healing from full-thickness skin defect by porous silk fibroin scaffolds (PSFSs). *Biomed Mater Eng.* 2010;20(5):295-308.
- Bosetti M, Boccafroschi F, Calarco A, etc. Behaviour of human mesenchymal stem cells on a polyelectrolyte-modified HEMA hydrogel for silk-based ligament tissue engineering. *J Biomater Sci Polym Ed.* 2008;19(9):1111-23.
- Altman GH, Horan RL, Lu HH, et al . Silk matrix for tissue engineered anterior cruciate ligaments. *Biomaterials*, 2002, 23(20): 4131-4141.
- Meinel L, Fajardo R, Hofmanna S, et al . Silk implants for the healing of critical size bone defects. *Bone*, 2005, 37(5): 688-698.
- Hofmann S, Hagenmuller H, Koch AM, et al . Control of in vitro tissue-engineered bone-like structures using human mesenchymal stem cells and porous silk scaffolds. *Biomaterials*, 2007, 28(6): 1152-1162.
- Zhou J, Cao C, Ma X, etc. Electrospinning of silk fibroin and collagen for vascular tissue engineering. *Int J Biol Macromol.* 2010 Nov 1;47(4):514-9.

- Tamada Y. Sulfation of silk fibroin by chlorosulfonic acid and the anticoagulant activity. *Biomaterials*, 2004, 25(3): 377-383.
- Levin B, Redmond SL, Rajkhowa R, etc. Preliminary results of the application of a silk fibroin scaffold to otology. *Otolaryngol Head Neck Surg*. 2010 Mar;142(3 Suppl 1):S33-5.
- Ghanaati S, Orth C, Unger RE, etc. Fine-tuning scaffolds for tissue regeneration: effects of formic acid processing on tissue reaction to silk fibroin. *J Tissue Eng Regen Med*. 2010 Aug;4(6):464-72.
- Mandal BB, Das T, Kundu SC. Non-bioengineered silk gland fibroin micromolded matrices to study cell-surface interactions. *Biomed Microdevices*. 2009 Apr;11(2):467-76.
- Acharya C, Ghosh SK, Kundu SC. Silk fibroin protein from mulberry and non-mulberry silkworms: cytotoxicity, biocompatibility and kinetics of L929 murine fibroblast adhesion. *J Mater Sci Mater Med*. 2008 Aug;19(8):2827-36.
- Yang Y, Chen X, Ding F, etc. Biocompatibility evaluation of silk fibroin with peripheral nerve tissues and cells in vitro. *Biomaterials*. 2007 Mar;28(9):1643-52.
- Etienne O, Schneider A, Kluge JA, etc. Soft tissue augmentation using silk gels: an in vitro and in vivo study. *J Periodontol*. 2009 Nov;80(11):1852-8.

© 2011 The Author(s). Licensee IntechOpen. This is an open access article distributed under the terms of the [Creative Commons Attribution 3.0 License](https://creativecommons.org/licenses/by/3.0/), which permits unrestricted use, distribution, and reproduction in any medium, provided the original work is properly cited.

IntechOpen

IntechOpen