

We are IntechOpen, the world's leading publisher of Open Access books Built by scientists, for scientists

6,900

Open access books available

186,000

International authors and editors

200M

Downloads

Our authors are among the

154

Countries delivered to

TOP 1%

most cited scientists

12.2%

Contributors from top 500 universities



WEB OF SCIENCE™

Selection of our books indexed in the Book Citation Index
in Web of Science™ Core Collection (BKCI)

Interested in publishing with us?
Contact book.department@intechopen.com

Numbers displayed above are based on latest data collected.
For more information visit www.intechopen.com



Surgical Treatment of Ulcerative Colitis

Gianluca Pellino¹, Guido Sciaudone¹, Gabriele Riegler²,
Silvestro Canonico¹ and Francesco Selvaggi¹

¹General Surgery Unit

²Division of Gastroenterology
Second University of Naples
Italy

1. Introduction

Ulcerative colitis (UC) is an ubiquitously distributed inflammatory bowel disease. Its incidence varies slightly between geographical areas, most likely because of either the different genetic patrimonies of the involved populations or several environmental factors. In socially evolved Countries UC incidence is of approximately 6 cases per 100.000 white adult individuals, with a prevalence of 40-100/100.000. This incidence notably decreases in Countries with lower socio-economic levels. Female gender is slightly more affected than male, with a gender ratio F/M of 1.5/1.

The aetiology of UC still remains mainly unknown, even if a multifactorial genesis is now widely accepted.

Unlike Crohn's disease, UC is a continuous disease involving mainly the rectum, suddenly expanding proximally to the colon, with no alternation of healthy or diseased mucosal area. Figure 1 depicts the possible localization of UC at the time of clinical presentation (Binder et al., 1982; Stonnington et al., 1987)

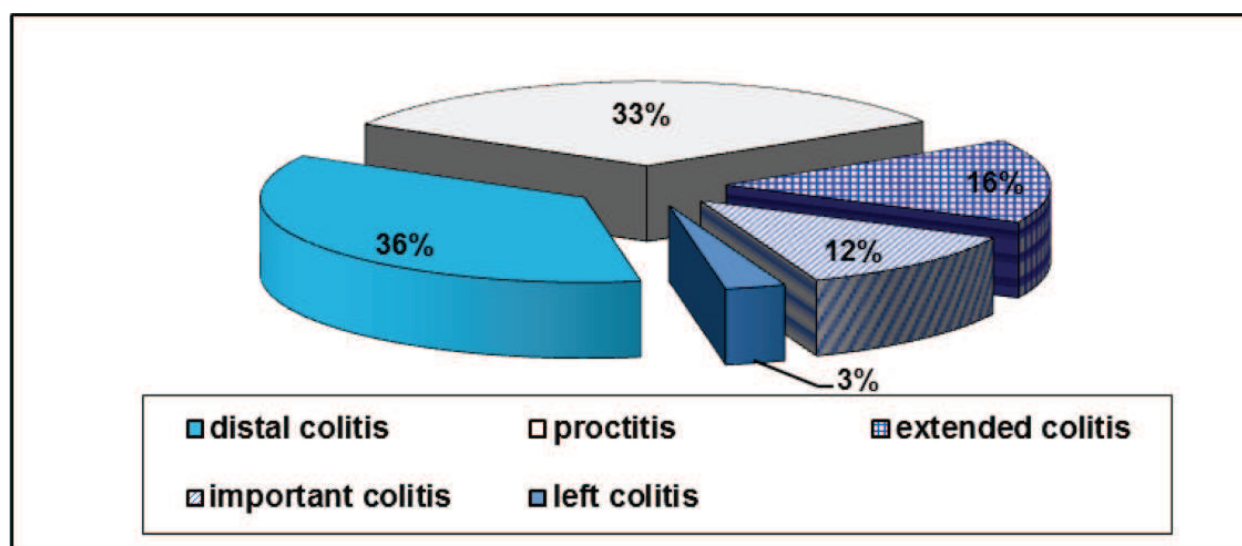


Fig. 1. Extension of ulcerative colitis at presentation

In case of pancolitis, in about 10-20% of patients also the last 5-15 cm of distal ileum can be involved, with ulcerated lesions of the mucosa, pathologically undistinguishable from colon lesions, picture defined as *backwash ileitis*. Disease usually presents with an acute attack or with a relapse in patients with an history of muco-haematic diarrhoea (Edwards & Truelove, 1963). Even if only the complete removal of involved organs – colon and rectum – ensures complete recovery, the treatment of UC is, initially, mainly medical, based on drugs such as corticosteroids, salicylates, immunomodulators, and, more recently, biologics. However, between 20 and 40% of patients will require surgery (Leijonmarck et al., 1990). Extension of the disease represents an important factor influencing treatment choice. In fact, only 2% of patients with a disease confined to the rectum require surgery during the 5 years after the diagnosis, whereas 35% of patients with pancolitis will be operated on (Richie, 1974). Indications to surgery consist of complications, such as toxic megacolon, perforation, hemorrhage, presence of intractable extra-intestinal manifestations, risk of carcinoma, and failure of medical treatment.

During years, surgical treatment of UC has dramatically changed, even if still ensuring disease eradication. In fact, giving an alternative to proctocolectomy with definitive ileostomy, option very humiliating for the patient, Parks and Nicholls (Parks & Nicholls, 1978) proposed in 1978 the *restorative proctocolectomy* (RP), fashioning an ileal reservoir (*pouch*) that offered patients a radical treatment of the disease but also a good anal function, preserving intestinal continuity and the anus in its natural site. This intervention, consisting of removal of the entire colon and rectum to the *linea dentata*, hence preserving the sphincters, followed by fashioning of a neo-rectum with the last ileal loops and ileo-anal anastomosis, represented a revolution in surgical treatment of UC, rapidly becoming the intervention of choice for UC in selected centres (Pemberton et al., 1987; Williams, 1989; Selvaggi et al., 1996)

2. Indications to surgery

Indications to surgical treatment of UC can be distinguished in indications to elective and emergency – relative or absolute – surgery (Table 1).

Elective surgery	Absolute emergency	Relative emergency
Failure of medical therapy Extraintestinal manifestations Preventing degeneration	Perforation Toxic megacolon	Hemorrhage Severe colitis

Table 1. Indications to surgical treatment of UC

The rate of patients at risk of experiencing an acute complication of UC (perforation, toxic megacolon, hemorrhage, severe colitis) ranges between 10 and 20% (Jewell, 1987; Truelove, 1988).

2.1 Perforation

It usually occurs in patients presenting with dilatation of the colon. It represents an absolute indication to surgical intervention in emergency settings and tends to occur soon during the course of the disease, before bowel thickening. Incidence of perforation is reported to be as high as 3% (Kirsner & Shorter, 1982)

2.2 Toxic megacolon

It occurs in 5-10% of patients (with perforation 0.9-1.6%) (Kirsner & Shorter, 1982). Bowel dilatation >6 cm represents an absolute indication to surgery. In such patients a subtotal colectomy with closure of the rectal stump and Brooke terminal ileostomy is recommended.

2.3 Hemorrhage

It is a rare complication (3%), that can usually be managed with medical treatment or with rectal washout with adrenaline in saline solution (1/200.000). If it is not possible, there is indication to surgery; it should be considered, however, that haemorrhage can continue in the residual rectum, if a subtotal colectomy is performed (12%) (Kirsner & Shorter, 1982).

2.4 Severe colitis

An acute episode of colitis is defined *severe* if bowel movements with blood are more than 6 in 24 hours, median afternoon temperature is >37.5°C or median entire day temperature is >37.7°C at least 2 out of 4 days, hearth rate is >90 bpm, ESR is >30, Hb is <10 g/dL. Such a condition, occurring in 10-15% of patients (Truelove & Jewell, 1974), requires intensive medical therapy with correction of hydro-electrolytic disturbances, albumin and corticosteroid infusion, plasma and/or blood infusion, total parenteral nutrition. Treatment should be tried for a maximum of 5 days; if there is no improvement of patient condition, emergency colectomy is required (Truelove & Witts, 1955; Turnbull et al., 1971). Most Authors believe, however, that if a plain abdominal radiograph documents colonic dilatation >6/7 cm or mucosal islands, surgical intervention should be performed after 24 hours of ineffective therapy at most (Bartram, 1987). In 1975 Lennard-Jones (Lennard-Jones et al., 1975) suggested some parameters predicting poor response to medical treatment (Table 2).

Factor	% Failure
Bowel movements > 9/24h	33
Bowel movements > 12/24h	55
Temperature > 38 °C	56
Albumin < 3 g/dl	42
Mucosal islands on plain adbominal rx	75

Table 2. Factors predicting poor response to medical treatment

2.5 Failure of medical therapy

It probably represents the most common indication to surgery. In patients with debilitating symptoms, a poor nutritional condition and an unsatisfactory quality of life despite adequate medical therapy, the eventuality of an elective surgical intervention should be considered. Some Authors (Mitchell et al., 1988) suggested that a prolonged medical treatment could increase the probability of surgery in emergency settings with consequential increase of morbidity, hospital stay and costs. Moreover, the prolonged medical treatment which UC patients often need, can have important secondary effects such as psychosis, hypertension, cataract, osteoporosis, insomuch as some Authors (Sagar et al., 1993) report a better quality of life in patients undergoing RP than in those receiving prolonged medical treatment.

2.6 Extraintestinal manifestations

About 30% of UC patients have at least one extraintestinal manifestation contributing to opt for surgery. Some manifestations, such as those involving skin, distal joints, eyes, or hematologic and vascular ones, can improve after surgery, whereas some other like pyoderma gangrenosum, ankylosing spondylitis, and rheumatoid arthritis do not seem to be modified by surgical intervention.

2.7 Prevention of neoplastic degeneration

Factors predisposing to colorectal cancer in UC patients consist of pancolitis, duration of disease, active disease and its severity. Early UC onset is another independent risk factor. Beside these factors, dysplasia represents the precancerous lesion from which colorectal cancer subsequently arise (Morson, 1962; Morson & Pang, 1967). In fact, > 70% of patients with colorectal cancer on UC have dysplasia on colorectal mucosa (Taylor et al., 1992; Connell et al., 1994). Severe dysplasia is reported to develop colorectal cancer in 45% of cases, whereas there are too few data in literature to do a similar valuation for mild-moderate dysplasia (Collins et al., 1987; Bernestein et al.,1994). Furthermore, the risk of colorectal cancer is due to the evidence that high grade dysplasia represents a marker of cancer in another colon site in 45% of patients (Provenzale et al.,1995). A review analyzing 116 studies pointed out that the global risk for colorectal cancer in UC patients is 8% after 20 years of disease, increasing gradually during years (Table 3), with a global rate of 3.7% (Van Heerden et al., 1980).

Risk (%)	Duration of disease (ys)
2	10
8	20
18	30

Table 3. Risk of colorectal cancer and duration of disease

This risk is approximately 8 times higher than normal population, increasing to 20 times if pancolitis is present; it is 4 times higher in case of left colitis (Gyde et al., 1988). For these reasons, some Authors advocated prophylactic colectomy in UC patients affected from more than 10 years, but this approach is still matter of debate (Provenzale et al.,1995).

3. Surgical options

The possible surgical strategies can be schematized in three types of intervention:

- total proctocolectomy with definitive ileostomy
- total colectomy with ileo-rectal anastomosis (IRA)
- restorative proctocolectomy with ileal pouch (RP)

In 1997 Little and Parks (Little & Parks, 1977) proposed proctocolectomy with definitive ileostomy for the treatment of UC. This intervention surely gives the advantage of being curative, ensuring complete disease removal with a single intervention. Moreover such intervention, if intersphincteric proctectomy is performed and perianal skin closed, allows to reduce morbidity of rectal excision with its major complications, such as urinary and sexual dysfunctions and leakage due to the presence of anal canal. Definitive ileostomy with lost anorectal function is the principal drawback of this procedure. Ileostomy, in fact, determines an important handicap for the patient who feels permanently ill, and can cause

alteration of body image leading to depression, isolation and impairment of social function in 45% of patients (Skarsgard et al., 1989; Druss et al., 1968).

Total colectomy with ileo-rectal anastomosis proposed by Devine (Devine, 1943) and Corbett (Corbett, 1952) seems to avoid this problem because it does not require ileostomy, restoring intestinal continuity with ileo-rectal anastomosis. Furthermore, this intervention is able to ensure good results with low incidence of mortality – especially if performed in elective settings – and low incidence of anastomotic leakage and pelvic sepsis (Jones et al., 1977). The main advantage is that the preservation of anorectal function is possible avoiding genito-urinary dysfunctions due to proctectomy, with 4/5 evacuation/day. However, in a study from the Mayo Clinic involving 63 patients with IRA only 55% of patients was satisfied with function in the long term (Farnell & Adson, 1985). Moreover, about 1/3 of patients still need enemas with corticosteroids or sulfasalazine (Khubchandani et al., 1978).

Colectomy with IRA does not remove the entire diseased organ, and the preservation of the rectum rises the risk of late carcinogenesis or of severe proctitis, which can affect long term results of the intervention and require subsequent proctectomy in 5-30% of patients (Parc et al., 1989). The presence of carcinoma, severe rectal disease and incompetence of the sphincters represent absolute contraindications to colectomy with IRA.

For these reasons, researchers felt the need of perform interventions that could not only be curative and radical, but able to preserve sphincters and, therefore, an acceptable anal function.

To fulfill these aims, Parks and Nicholls (Parks & Nicholls, 1978) first described RP with ileal pouch in 1978, consisting of total colectomy, proximal proctectomy, mucosectomy of the distal rectum and ileopouch-anal anastomosis. The intervention which they proposed implied fashioning of an S-shaped ileal reservoir with three folded ileal loops anastomized to the anal canal after mucosectomy of the rectal stump toward the *linea pettinata*.

Subsequently Utsonomiya (Utsonomiya et al., 1980) perfected this reservoir, as it had important emptying problems due to the often excessive length of the efferent limb (about 5 cm), responsible for failure of spontaneous evacuation. In 1980 the Author proposed a J-shaped reservoir fashioned with two loops of small bowel. J-pouch, easy to perform even with mechanical staplers, avoided problems of S-pouch but it still comported an high number of evacuations, particularly during the first years after ileostomy reversal, hence in 1984 Nicholls (Nicholls & Pezim, 1984) suggested a new type of reservoir, fashioned with four ileal loops, the W-pouch, which assumed an almost spherical shape and seemed to offer a better evacuating function than J-pouch even if technically more difficult to fashion (Figure 2).

A study from the St. Mark's Hospital (Nicholls & Pezim, 1985) comparing W-, S- and J-pouch for frequency of evacuations reported an inverse correlation between frequency and maximum volume of the pouch: reservoir capacity is thus one of the main factors affecting defecation frequency and volume seems to be more relevant than shape. A sufficiently capable J-pouch – fashioned with two loops of approximately 20 cm each – could hence have results similar to those of W- or S-pouch.

In a prospective randomized trial Selvaggi et al. (Selvaggi et al., 2000) found that patients with J-pouch had an higher number of defecations than W-pouch in the short term; it should be noted, however, that after this initial difference J-pouch allows a number of evacuations similar to that of W-pouch in the long term.

In the description of their original technique Parks and Nicholls (Parks & Nicholls, 1978) described mucosectomy of the rectal stump toward the *linea pettinata* and ileopouch-anal

anastomosis at that level. This was regarded as a fundamental time of the procedure, allowing complete removal of the diseased tissue and definitive disease healing.

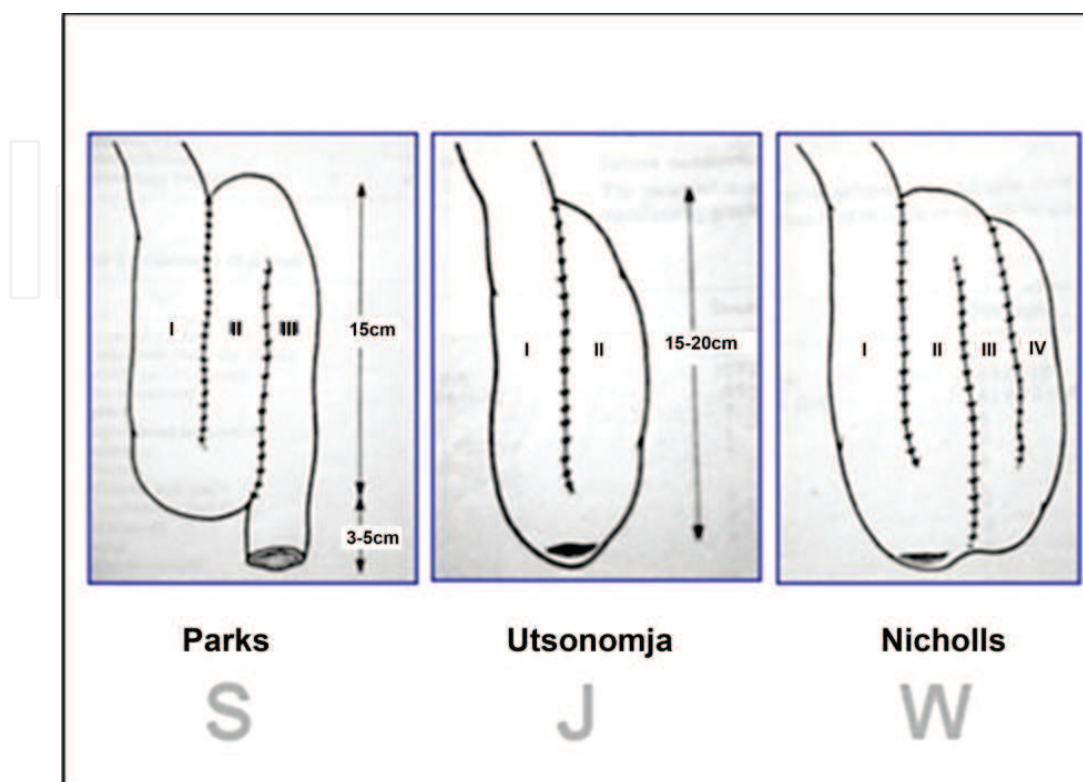


Fig. 2. Pouch configurations

Nowadays most Authors agree that preserving the rectum is useless, so it is sectioned at the level of anorectal junction. The preparation of the rectum toward anorectal junction is usually intramesorectal, which rises the risk of bleeding but also reduces the risk of nerve lesions. However mesorectal excision is mandatory in case of either severe dysplasia or cancer.

After pouch construction, ileopouch-anal anastomosis can be either manual or stapled. When mucosectomy is performed, it is necessary to fashion manual ileoanal anastomosis intra-anally by suturing the pouch to the anus with some stitches between it and the *linea dentata*. Mechanical anastomosis is performed with a circular stapler inserted trans-anally.

Mucosectomy guarantees complete eradication of the disease, avoiding both bleeding from persistent inflammation (Keighley et al., 1991), found in about 23% of cases (44%), and incidence of mucosal dysplasia and cancer development, but it is not routinely performed for several reasons: it is quite difficult to perform; it requires longer operative times; it brings about risks of sphincter lesions both direct and due to anal divaricator; it can be difficult to get the apex of the pouch to the perineal plane to effectuate the anastomosis without tension; there is the risk of pelvic septic complications. Moreover, mucosectomy also removes anal transitional zone (AZT) which has sensitive function and contributes to perfect continence.

To avoid such problems a technique was proposed, consisting of section of the rectum about 2 cm above the *linea dentata* and stapled pouch-anal anastomosis. Further resection of 1 cm

of rectum effectuated by the stapler poses the anastomosis just above the superior margin of the anal canal, with no need of mucosectomy.

As now, J- and W-pouch are the most used reservoirs, while S-pouch is not commonly performed due to the need of catheterization to facilitate evacuation in about 50% of patients.

Thus, RP represented a revolution in surgical treatment of UC, becoming in few years the intervention of choice in selected centers, as it allows a complete disease removal preserving intestinal continuity and the anus in its natural site, therefore ensuring good fecal continence and acceptable number of evacuation during one day. Moreover the simplification of the original procedure due to mechanical staplers to perform ileo-anal anastomosis significantly contributed to the diffusion of the technique.

The number of interventions necessary to perform RP can vary. In case of emergency settings, when patients usually are in severe general conditions, it is preferable to perform a total colectomy, postponing proctectomy and pouch construction. On the other hand, immunomodulators and, more recently, biologics demonstrated their effectiveness in controlling acute UC attack, allowing RP in elective settings when there is no absolute indication to surgery.

4. Patients selection

RP is nowadays the intervention of choice for surgical treatment of UC in so much that Dozois, already in 1988, stated that results with RP were so good that it should be preferred in the majority of patients.

Reliability of this intervention induced to extend surgical indication not only for patient with intractable UC but also for those in acceptable general conditions.

However, some factors should be considered before proposing to patients a RP.

First, diagnosis of UC must be histologically confirmed; if there is suspicion of Crohn's disease RP should be avoided, as Crohn's brings about a risk of perineal complications of about 50% with a 20-40% rate of pouch defunctioning/removal (Parker & Nicholls, 1991; Hyman et al., 1991).

Moreover a manometric examination of the sphincters must be carried out, because patients with poor sphincter function do not fit ileopouch-anal anastomosis.

Elderly represents a relative contraindication to RP: this is not due to patients' general health status, but to the more frequent incidence of fecal incontinence in the older population. In fact, anal contraction diminishes in over 70-year-old patients.

Patients already undergone anal surgery before RP have similar functional results than who did not (Selvaggi et al., 2010a).

RP is more difficult in patient with a small pelvis and in thin patients, as it could be difficult to get the pouch reach the anus without tension, even when all the techniques of mesenteric lengthening are performed. Obesity has represented another relative contraindication to RP, but the intervention is nowadays performed routinely also in obese patients.

Cancer of the colon or of the proximal rectum does not represent a contraindication to RP as it can be completely excised. When a locally invasive cancer with metastasis to regional nodes is diagnosed, total colectomy should be performed and adjuvant therapy should be given before proctectomy and pouch construction; in patients with metastatic disease RP is contraindicated and colectomy with IRA should be preferred.

5. Complications

Intraoperative mortality is reported to be lower than 1%, while global morbidity ranges between 13 and 54% after RP (Hosie et al., 1992; Metcalf et al., 1988; Nicholls & Pezim, 1984; Nicholls, 1993). Complications can occur early, after ileostomy closure or late.

5.1 Small bowel occlusion

It is an early complication occurring in 15% of patients before ileostomy closure. About 1/3 of these patients require surgical intervention. However, this rate is similar to that of other surgical interventions for UC. The rate of small bowel occlusion can reach 20-25% after ileostomy closure, so it is significantly higher than that after colectomy with terminal ileostomy (Marcello, 1993).

5.2 Pelvic sepsis

Manifestations of pelvic sepsis include abscess, flegmon and fistula. In the past this complication was reported to occur in 20-30% of patients, while nowadays its incidence dramatically reduced to 5-7% (Selvaggi et al., 2010b; Williams & Johnstone, 1985). Such a difference is probably due to both growing surgical experience and to complete rectal removal avoiding mucosectomy of a long rectal stump (Lohmuller et al., 1990). Some Authors reported that pelvic sepsis is a treating condition because, after its resolution, when the pouch is not excised, it determines pelvic fibrosis potentially affecting pouch compliance and, consequently, impair function.

5.3 Stenosis of ileopouch-anal anastomosis

Its incidence varies between 4 and 38%, being more frequent in case of stapled anastomosis. It is one of the most common causes of pouch malfunctioning due to the possibility of an outlet obstruction that can require several dilatations with Hegar dilators or, less frequently, redo-pouch (Nicholls, 1993).

5.4 Genito-urinary dysfunctions

They occur in approximately 11% of male and 12% of female (Nicholls, 1993). They are usually due to nerve lesions during rectal dissection and ligation of inferior mesenteric vessels and to post-surgical adhesions, that, in female gender, can cause infertility. However, pregnancy is possible after RP.

5.5 Pouchitis

It is a common complication of RP. Diagnosis consists of contemporaneous presence of abdominal pain, emission of liquid feces with blood, urgency, incontinence, general malaise, and fever. Pathological confirmation is required with histological evidence of the inflammation. When all these criteria are satisfied, it has an incidence of 10%.

The risk of developing pouchitis is higher during the first 6 months after intervention; cumulative risk at 4 years is 51%, but <10% of patients present with a severe pouchitis and only 1.3% will require pouch excision; in most cases (90%) pouchitis presents with sporadic episodes, easily managed with metronidazole and, sometimes, enemas with steroids or 5-ASA. In the rare eventuality of intractable pouchitis a temporary ileostomy or pouch removal can be necessary (Lohmuller et al., 1990; Patel et al., 1995).

An increase in bowel frequency or a *malfunctioning* pouch are not enough to define pouchitis, but this is a common mistake.
We have recently demonstrated that COX-2 and VEGF are overexpressed in ileal pouch mucosa, potentially playing a role in development of pouchitis (Romano et al., 2007).

5.6 Malfunctioning pouch

Reasons determining a poor pouch function are various and, often, due to surgeon's experience.
They are often due to fashioning of pouch either too small, unable to fulfill reservoir function, or too big, unable to empty completely.
Causes determining pouch dysfunction can be classified on the basis of anatomic site which they originate from (Table 4) (Selvaggi et al., 2002).

Proximal ileum	Pouch	Outlet
Chronic obstruction Gut infections Alimentation Small bowel motility	Crohn's disease Indetermined colitis Shape Volume Peri-pouch fibrosis	Stenosis of pouch-anal anastomosis Pouch angulation Pouch torsion Long rectal stump Pouch prolapse Anal sphincters spasms Paradox contraction of puborectalis m.

Table 4. Causes of dysfunction and anatomic site

6. Conclusions

Aim of surgical treatment of UC is the complete removal of the disease. Indications to surgery in election are not, as now, better defined than they were in the past, because of both better knowledge of clinical history and more accurate prevention of an eventual neoplastic transformation obtained with pancolonoscopy with multiple bioptic sampling.
On the other hand, nowadays more patients are operated on because recent procedures allow sphincters preservation and particularly to interposition of an ileal pouch that can offer a satisficing anal function in > 90% of patients with a good quality of life. This approach could be considered more aggressive, but it has surely determined a decrease in rate of patients needing surgery in emergency settings, consequently leading to lower incidence of perioperative mortality and morbidity. However some aspects still need to be analyzed in order to offer better functional results, with lower complication rates, such as ideal pouch shape, type of pouch-anal anastomosis, the need for mucosectomy, the role of ileostomy, and, of course, a better understanding of physio-pathological mechanisms determining pouchitis is needed, even if such complication does not seem to affect significantly overall functional results.

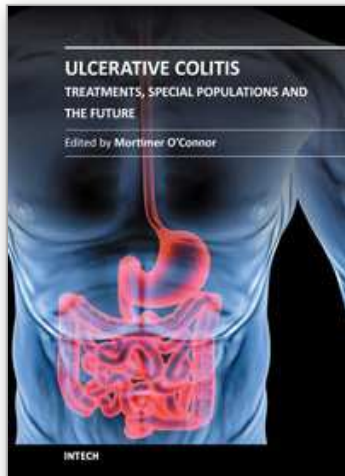
7. References

Bartram, C.I. (1994) Plain abdominal x-ray in acute colitis. *Proceddings of the Royal Society of Medicine* 69: 617-618
Bernstein, C.N.; Shanahan, F. & Weinstein, W.M. (1994) Are we telling patients the truth about surveillance colonoscopy in ulcerative colitis? *Lancet* 343: 71-74

- Binder, V.; Both, H.; Hansen, P.K.; Hendriksen, C.; Kreiner, S. & Trop-Pedersen, K. (1982) Incidence and prevalence of Ulcerative Colitis and Crohn's disease in the country of Copenhagen 1962-1978. *Gastroenterology*. 83:563-568
- Collins, R.H. Jr; Feldman, M. & Fordtran, J.S. (1987) Colon cancer, dysplasia, and surveillance in patients with ulcerative colitis. A critical review. *N Engl J Med* 316: 1654-1658
- Connell, W.R. ; Talbot, I.C. ; Harpaz, N. ; Britto, N. ; Wilkinson, K.H. ; Kamm, M.A. & Lennard-Jones, J.E. (1994) Clinicopathological characteristics of colorectal carcinoma complicating ulcerative colitis. *Gut* 35: 1419-1423
- Corbett, R.S. (1952) Recent advances in the surgical treatment of chronic ulcerative colitis. *Ann R Coll Surg Engl*. 10: 21-32
- Devine, H. (1943) A method of colectomy for desperate cases of ulcerative colitis. *Surg Gynecol Obstet* 76: 136-138
- Druss, R.G.; O'Connor, J.F.; Prudden, J.F. & Stern, O. (1968) Psychologic response to colectomy. *Arc Gen Psychiatry* 18: 53-59
- Edwards, F.C. & Truelove, S.C. (1963) The course and prognosis of ulcerative colitis : Parts I and II : short-term and long-term prognosis. *Gut* 4:299-315
- Farnell, M.B. & Adson, M.A. (1985) Ileorectostomy: current results: the Mayo Clinic Experience.. In: Dozois RR (ed): *Alternatives to Conventional Ileostomy*. Year Book Medical Publisher, Chicago, 100-121
- Gyde, S.N.; Prior, P.; Allan, R.N.; Stevens, A.; Jewell, D.P.; Truelove, S.C.; Lofberg, R.; Brostrom, O. & Hellers, G (1988) Colorectal cancer in ulcerative colitis: a cohort study of primary referrals from three centres. *Gut* 29: 206-217
- Hosie, H.B.; Grobler, S.P. & Keighley, M.R.B. (1992) Temporary loop ileostomy following restorative proctocolectomy. *Br J Surg*. 79: 33-34
- Hyman, N.H.; Fazio, V.W. & Lavery, I.C. (1991) Consequence of ileal pouch anal anastomosis for Crohn's colitis. *Dis Colon Rectum*. 34 :653
- Jewell, D.P. (1987) Ulcerative colitis.: indication for surgery. In: surgery of inflammatory bowel disorders. Lee ECG, Ed. Edinburgh. Churchill Livingstone, 33-38
- Jones, P.F.; Munro, A. & Even, S.W.B. (1977) Colectomy and ileorectal anastomosis for colitis: report on a personal series with a critical review. *Br J Surg* 64: 615-623
- Keighely, M.R.B.; Yoshioka, K. & Kmniot, W.A. (1991) Prospective randomized trial comparing anal function after hand sewn ileoanal anastomosis with mucosectomy versus stapled ileoanal anastomosis without mucosectomy in restorative proctocolectomy. *Br J Surg*. 78:430-434
- Khubchandani, I.T.; Turinvei, H.D.; Sheets, J.A.; Stasik, J.J. & Kleckner, F.S. (1978) Ileorectal anastomosis for ulcerative and Crohn's colitis. *Am J Surg* 135: 751-756
- Kirsner, J.B. & Shorter, R.G. (1982) Recent developments in "non specific" inflammatory bowel disease, Part I. *N Engl J Med* 306: 775-785
- Kirsner, J.B. & Shorter, R.G. (1982) Recent developments in "non specific" inflammatory bowel disease, Part II. *N Engl J Med* 306: 837-848
- Lavery, I.C.; Sirimarco, M.T.; Ziu, Y. & Fazio, V.W. Anal canal inflammation after ileal pouch-anal anastomosis. The need for treatment. *Dis Colon Rectum* 38:803-806
- Leijonmarck, C.E.; Persson, P.G. & Hellers, G. (1990) Factors affecting colectomy rate in ulcerative colitis: an epidemiological study. *Gut* 31: 329-333
- Lennard-Jones, J.E.; Ritchie, J.K.; Hilder, W. & Spicer, C.C. (1975) Assessment of severity in colitis. A preliminary study. *Gut* 16: 579-84

- Little, J.C. & Parks, A.G. (1977) Intersphincteric excision of the rectum. *Br J Surg* 64: 413-416
- Lohmuller, J.L.; Pemberton, J.H. & Dozois P.R. (1990) Pouchitis and extraintestinal manifestations of inflammatory bowel disease after ileal pouch-anal anastomosis. *Ann Surg*. 21: 622-629
- Marcello, P.W. (1993) Long-term results of the ileo-anal pouch procedure. *Arch Surg*. 128: 500-504
- Metcalf, A.M.; Dozois, R.R. & Beart, R.W. (1988) Temporary ileostomy for pouch anal anastomosis . function and complication. *Dis Colon Rectum*. 29: 300-303
- Mitchell, A.; Guyatt, G. & Singer, J. (1988) Quality of life in patients with inflammatory bowel disease. *J Clin Gastroenterol* 10: 306-310
- Morson, B.C. (1962) Some peculiarities in the histology of intestinal polyps. *Dis Colon Rectum* 5: 337
- Morson, B.C. & Pang, L.S.C. (1967) Rectal biopsy as aid to cancer control in ulcerative colitis. *Gut* 8: 423
- Nicholls, R.J. (1993) Controversies and practical problem solving. In : *Restorative Proctocolectomy*. Nicholls RJ, Bartolo DCC, Mortensen RJ. Oxford. Blackwell Scientific Publ, 53-82
- Nicholls, R.J. & Pezim, M.E. (1984) Restorative proctocolectomy with ileal reservoir for ulcerative colitis and familial adenomatous polyposis. *Ann Surg* 199: 383-388
- Nicholls, R.J. & Pezim, M.E. (1985) Restorative proctocolectomy with ileal reservoir for ulcerative colitis and familial adenomatous polyposis: a comparative of three reservoir designs. *Br J Surg* 72: 470-474
- Parc, R.; Legrand, M. & Frileux, P. (1989) Comparative clinical results of ileal pouch-anal anastomosis and ileal ileorectal anastomosis in ulcerative colitis. *Hepatogastroenterology* 36: 235-239
- Parker, M.C. & Nicholls, R.J. (1991) Restorative proctocolectomy in patients after previous intestinal or anal surgery. *Dis Colon Rectum* 35: 681
- Parks, A.G. & Nicholls, R.J. (1978) Proctocolectomy without ileostomy for ulcerative colitis. *Br Med J* 2: 85-88
- Patel, R.Y.; Barin, I.; Young, D. & Keighley, M.R.B. (1995) Cytokine production in pouchitis is similar to that in ulcerative colitis. *Dis Colon Rectum*. 38: 831-837
- Pemberton, J.H.; Kelly, K.A.; Beart, R.W. Jr.; Dozois, R.R.; Wolff, B.G. & Ilstrup, D.M. (1987) Ileal pouch-anal anastomosis for chronic ulcerative colitis. Long term results. *Ann Surg* 206: 504-513
- Pemberton, J.H. ; Kelly, K. ; Beart R.W. ; Dozois, R.R. ; Wolf, B.G. & Ilstrup D.M. (1988) Ileal pouch anal anastomosis for chronic ulcerative colitis. *Ann Surg*. 207 : 504
- Provenzale, D.; Kowdley, K.V.; Arora, S. & Wong, J.B. (1995) Prophylactic colectomy or surveillance for chronic ulcerative colitis? A decision analysis. *Gastroenterology* 109: 1188-1196
- Richie, J. (1974) Results of surgery for inflammatory bowel disease: a further study of one hospital region. *Br J Surg* 1:264-268
- Romano, M.; Cuomo, A. ; Tuccillo, C.; Salerno, R.; Rocco, A.; Staibano, S.; Mascolo, M.; Sciaudone, G.; Mucherino, C.; Giuliani, A.; Riegler, G.; Nardone, G.; Del Vecchio Blanco, C. & Selvaggi, F. (2007) Vascular endothelial growth factor and cyclooxygenase-2 are overexpressed in ileal pouch-anal anastomosis. *Dis Colon Rectum* 50 (5):650-9

- Sagar, P.M.; Lewis, W.; Holdsworth, P.J.; Johnston, D.; Mitchell, C. & MacFie, J. (1993) Quality of life after restorative proctocolectomy with a pelvic pouch compares favourably with that of patients with medically treated colitis. *Dis Colon Rectum*. 36: 584-592
- Selvaggi, F.; Giuliani, A.; Gallo, C.; Signoriello, G.; Riegler, G. & Canonico, S. (2000) Randomized, controlled trial to compare the J-pouch and W-pouch configurations for ulcerative colitis in the maturation period. *Dis Colon Rectum* 43:615-620
- Selvaggi, F.; Giuliani, A. & Sciaudone, G (2002) Le disfunzioni delle pouch ileali. *Archivio ed Atti della Soc.Ital. Chir.* 3: 144-160
- Selvaggi, F.; Sciaudone, G.; Guadagni, I. & Pellino, G. (2010a) Ileal pouch-anal anastomosis after stapled haemorrhoidopexy for unrecognized ulcerative colitis. *Colorectal Dis*. 12:e172
- Selvaggi, F.; Sciaudone, G.; Limongelli, P.; Di Stazio, C.; Guadagni, I.; Pellino, G.; De Rosa, M. & Riegler, G. (2010b) The effect of pelvic septic complications on function and quality of life after ileal pouch-anal anastomosis: a single center experience. *Am Surg*. 76:428-435
- Selvaggi, F.; Silvestri, A.; Scotto Di Carlo, E. & Sciaudone, G (1996) Il trattamento chirurgico della rettocolite ulcerosa. *Techniques in Coloproctol.* 4: 98-101
- Skarsgard, E.D.; Atkinson, K.G.; Bell, G.A.; Pezim, M.E.; Seal, A.M. & Sharo, F.R. (1989) Function and quality of life results after ileal pouch surgery for chronic ulcerative colitis and for polyposis. *Am J Surg* 157: 457-471
- Stonnington, C.M.; Phillips, S.F.; Melton, L.J. & Zinsmeister, A.R. (1987) Chronic ulcerative colitis: incidence and prevalence in a community. *Gut* 28: 402-409
- Taylor, B.A.; Pemberton, J.H.; Carpenter, H.A.; Levin, K.E.; Schroeder, K.W.; Welling, D.R.; Spencer, M.P. & Zinsmeister, A.R. (1992) Dysplasia in chronic ulcerative colitis: implications for colonoscopic surveillance. *Dis Colon Rectum* 35: 950-956
- Truelove, S.C. (1988) Medical management of ulcerative colitis and indication for colectomy. *World J Surg*. 12: 142-147
- Truelove, S.C. & Jewell, D.P. (1974) Intensive intravenous regimen for severe attack of ulcerative colitis. *Lancet* i: 1067-1074
- Truelove, S.C. & Witts, L.J. (1955) Cortisone in ulcerative colitis: final report on a therapeutic trial. *Br Med J* 2:1041-1048
- Turnbull, R.B.; Hawk, W.A. & Weakly, F.I. (1971) Surgical treatment of toxic megacolon: ileostomy and colostomy to prepare patients for colectomy. *Am J Surg* 122: 325-331
- Utsonomiya, A.J.; Iwama, T.; Iamjo, M.; Matsuo, S.; Sawai, S.; Yalgashi, K. & Hirayama, R. (1980) Total Colectomy, mucosal proctectomy and ileoanal anastomosis. *Dis Colon Rectum* 23: 459-466
- van Heerden, J.A. & Beart, R.W. Jr (1980) Carcinoma of the colon and rectum complicating chronic ulcerative colitis. *Dis Colon Rectum* 23: 155-159
- Williams, N.S. (1989) Restorative proctocolectomy is the first choice elective surgical treatment for ulcerative colitis. *Br J Surg* 76: 1109
- Williams, N.S. & Johnston, D (1985) The current state of mucosal proctectomy and ileo-anal anastomosis in the surgical treatment of ulcerative colitis and familial polyposis. *Br J Surg*. 72: 159-168
- Ziv, Y.; Fazio, V.W.; Church, J.M.; Milsom, J.W. & Schroeder, T.K. (1995) Safety of urgent restorative proctocolectomy with ileal pouch-anal anastomosis for fulminant colitis. *Dis Colon Rectum*, 38: 345-349



Ulcerative Colitis - Treatments, Special Populations and the Future

Edited by Dr Mortimer O'Connor

ISBN 978-953-307-739-0

Hard cover, 178 pages

Publisher InTech

Published online 02, November, 2011

Published in print edition November, 2011

This book is intended to act as an up to date reference point and knowledge developer for all readers interested in the area of gastroenterology and in particular Ulcerative Colitis. All of the chapter authors are experts in their fields of publication and deserve individual credit and praise for their contributions to the world of Ulcerative Colitis. We hope that you will find this publication informative, stimulating and a reference point for the area of Ulcerative colitis as we move forward in our understanding of the field of medicine.

How to reference

In order to correctly reference this scholarly work, feel free to copy and paste the following:

Gianluca Pellino, Guido Sciaudone, Gabriele Riegler, Silvestro Canonico and Francesco Selvaggi (2011). Surgical Treatment of Ulcerative Colitis, Ulcerative Colitis - Treatments, Special Populations and the Future, Dr Mortimer O'Connor (Ed.), ISBN: 978-953-307-739-0, InTech, Available from:
<http://www.intechopen.com/books/ulcerative-colitis-treatments-special-populations-and-the-future/surgical-treatment-of-ulcerative-colitis>

INTECH
open science | open minds

InTech Europe

University Campus STeP Ri
Slavka Krautzeka 83/A
51000 Rijeka, Croatia
Phone: +385 (51) 770 447
Fax: +385 (51) 686 166
www.intechopen.com

InTech China

Unit 405, Office Block, Hotel Equatorial Shanghai
No.65, Yan An Road (West), Shanghai, 200040, China
中国上海市延安西路65号上海国际贵都大饭店办公楼405单元
Phone: +86-21-62489820
Fax: +86-21-62489821

© 2011 The Author(s). Licensee IntechOpen. This is an open access article distributed under the terms of the [Creative Commons Attribution 3.0 License](https://creativecommons.org/licenses/by/3.0/), which permits unrestricted use, distribution, and reproduction in any medium, provided the original work is properly cited.

IntechOpen

IntechOpen