

We are IntechOpen, the world's leading publisher of Open Access books Built by scientists, for scientists

6,900

Open access books available

185,000

International authors and editors

200M

Downloads

Our authors are among the

154

Countries delivered to

TOP 1%

most cited scientists

12.2%

Contributors from top 500 universities



WEB OF SCIENCE™

Selection of our books indexed in the Book Citation Index
in Web of Science™ Core Collection (BKCI)

Interested in publishing with us?
Contact book.department@intechopen.com

Numbers displayed above are based on latest data collected.
For more information visit www.intechopen.com



Differential Diagnosis of the Pulmonary-Renal Syndrome

Martin Kimmel, Niko Braun and Mark Dominik Alscher
*Department of Internal Medicine, Division of Nephrology,
 Robert-Bosch-Hospital, Stuttgart
 Germany*

1. Introduction

The pulmonary-renal syndrome involves the combination of diffuse alveolar hemorrhage and a rapid progressive glomerulonephritis (RPGN). It is usually a systemic vasculitis that can lead through a vast vasculitic process to life-threatening injury to the involved organs lung and kidney [Niles 1996, Salant 1987, Boyce 1986, Gallagher 2002 & De Groot 2005].

In the differential diagnosis other diseases of acute renal and lung injury with alveolar hemorrhage without RPGN have to be discussed.

2. Pulmonary-renal syndrome

The *diffuse alveolar hemorrhage* is defined by the triad of hemoptysis, diffuse alveolar infiltrates and low hematocrit. However, the clinical presentation is variable (slight cough, progressive dyspnea, manifest hemoptysis) and these symptoms don't have to occur simultaneously [Hauber 2007]. Slowly protracted courses through to fulminant organ failure are described.

A *rapid-progressive glomerulonephritis (RPGN)* is manifested by a rapidly progressive renal function loss (a few days to few weeks) and the presence of a nephritic sediment with deformed erythrocytes of a glomerular origin and possibly red cell casts.

2.1 Pathophysiology

The underlying cause of a pulmonary-renal syndrome is usually a systemic vasculitis of the small pulmonary and renal vessels. These vasculitides have a heterogeneous pathogenesis - there are three different pathophysiological mechanisms of injury [Niles 1996, Salant 1987 & De Groot 2005]:

1. mediated by anti-neutrophil-cytoplasmic antibodies (ANCA),
2. immune-complex mediated vasculitis of small vessels or
3. by antibodies against the glomerular basement membrane (Goodpasture Syndrome).

In the kidney a *RPGN* is caused by damage of the capillaries and basal membranes with leakage of erythrocytes, followed by an influx of macrophages, fibrinogen and the formation of extracapillary cell proliferation (so called crescents) [Salant 1987].

In the lungs, a *diffuse alveolar hemorrhage* is caused by a pulmonary capillaritis [Hauber 2007]. In the case of ANCA-associated systemic vasculitis the detection of ANCA is possible in ~ 80% of patients. Besides the correlation of ANCA titers with disease activity, there is

evidence of a pathogenetic role of ANCA. Myeloperoxidase (MPO) and proteinase 3 (Pr3) are detected in the cytoplasm of non-stimulated neutrophils. It is assumed that cytokines (e.g. TNF, interleukins) raise the expression of Pr3 and MPO on the cell surface of granulocytes and thus a reaction of these antigens with ANCA is possible. This process leads to activation of granulocytes and release of adhesion molecules to the interaction of leukocytes with vascular endothelial cells. Finally cell necrosis and apoptosis contribute to vascular inflammation process [Bosch 2006].

2.2 Diagnosis

2.2.1 Basic steps

As with any systemic vasculitis the diagnosis of pulmonary-renal syndrome is made in three steps:

1. *Adequate evaluation and networking* of existing and past patient's symptoms.
2. *Establishing the diagnosis* by laboratory, technical and biopsy examinations.
3. Differential diagnosis of vasculitis.

2.2.2 Imaging

The value of imaging refers to the extent of pulmonary capillaritis resulting in *diffuse alveolar hemorrhage*: in a conventional X-ray or in a computer tomography of the chest confluent or mixed interstitial-alveolar infiltrates are found (Fig. 1).

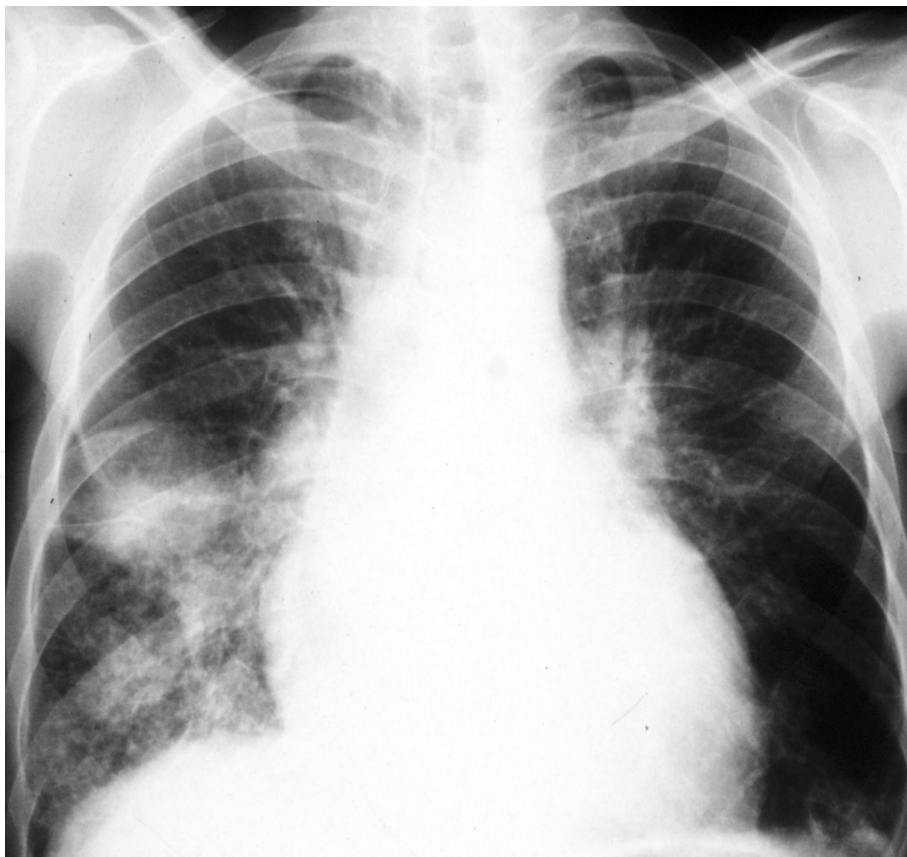


Fig. 1. Diffuse alveolar hemorrhage in chest x-ray in Wegener's granulomatosis.

In a RPGN sonographically enlarged kidneys presents with a wide parenchyma area.

2.2.3 Serology

Antibodies against the glomerular basement membrane (GBM) can be found typically in the rare Goodpasture's syndrome (Tab. 1).
The above briefly described heterogeneous pathogenesis of small vessels vasculitis results in the immunological classification considering serological / immunological parameters such as anti-neutrophil-cytoplasmic antibodies (ANCA) by immunfluorescence-optical findings (perinuclear or cytoplasmtic fluorescence) or ELISA against the target antigen proteinase 3 or myeloperoxidase (Tab. 1) [Bosch 2006]. In addition, the eosinophils, IgE and the extended autoimmunserology: anti-nuclear factor (ANA), anti-ds-DNA, C3, C4 and cryoglobulins can be determined.

Disease	Proteinase-3-Antibody	Myeloperoxidase (MPO-)-Antibody	ANCA negative	Anti-GBM-Ab
Wegener`s Granulomatosis	70 %	20 %	10 %	<10%
Microscopic Polyangiitis	30 %	60 %	10 %	<10%
Churg-Strauss-Syndrome	10 %	60 %	30 %	<10%
Goodpasture Syndrome	<10%	<30%	70%	95%

Table 1. ANCA-Sensitivity.

The rapid availability of these antibodies has improved the time to establish an early diagnosis, which is prognostically relevant [Saxena 1995].

2.2.4 Renal biopsy

The diagnosis of RPGN is done by renal biopsy: in light microscopy there is a glomerulonephritis with crescent formation in the Bowman's capsule compartment (extracapillary proliferation) in more than 50% of the glomeruli. The further work is carried out by immunohistochemistry and electron microscopy.
In immunohistology, the type of immunoglobulins and the deposition pattern (capillary, mesangial, granular, linear along the glomerular basement membrane) differ. Only in Goodpasture syndrome, linear deposits are found along the glomerular basement membrane. In case of an ANCA triggered form immune deposits are missing (pauci-immune RPGN). In contrast, in immune-complex vaculitis there can be found a different picture, usually with granular deposition of IgG, IgM, IgA or complement.

2.2.5 Bronchoscopy

The diagnosis of *diffuse alveolar hemorrhage* includes the clinical picture and a brochoscopy with a bronchoalveolar lavage and the microscopic detection of siderophages. Especially in the case of diffuse infiltrates in imaging without hemopytsis a bronchoscopy can be helpful and a definite diagnosis can be established [Hauber 2007].

3. Differential diagnosis of the pulmonary-renal syndrome

As already stated the pulmonary-renal syndrome is usually caused by a systemic small vessels vasculitis (Tab. 2), these can be categorized [Niles 1996, Salant 1987, De Groot 2005, Jennette 1994 & Falk 1997]:

- morphological criteria (size of the infesting vessels, presence or absence of granulomas),
- etiological criteria (idiopathic or secondary forms) and
- immunological criteria (ANCA-associated vasculitis, immune-complex vasculitis or caused by anti-basement antibodies).

3.1 ANCA-associated small vessel vasculitis

The Chapel Hill Consensus Conference classification defines [Jennette 1994]:

1. Wegener's granulomatosis,
2. microscopic polyangiitis and
3. Churg-Strauss syndrome.

Renal involvement is present in many systemic diseases, especially in the small vessel vasculitis – pointed out by Gallo in the New England Journal of Medicine: "The kidney is often a window on systemic disease" [Gallo 1991].

The suspicion of a pulmonary-renal syndrome in an ANCA-associated systemic vasculitis can often be taken from a careful history and thorough clinical examination with detection of other vasculitic signs (eye inflammation, intractable rhinitis / sinusitis, skin rashes, arthralgia, myalgia or polyneuropathy) (Fig. 2).

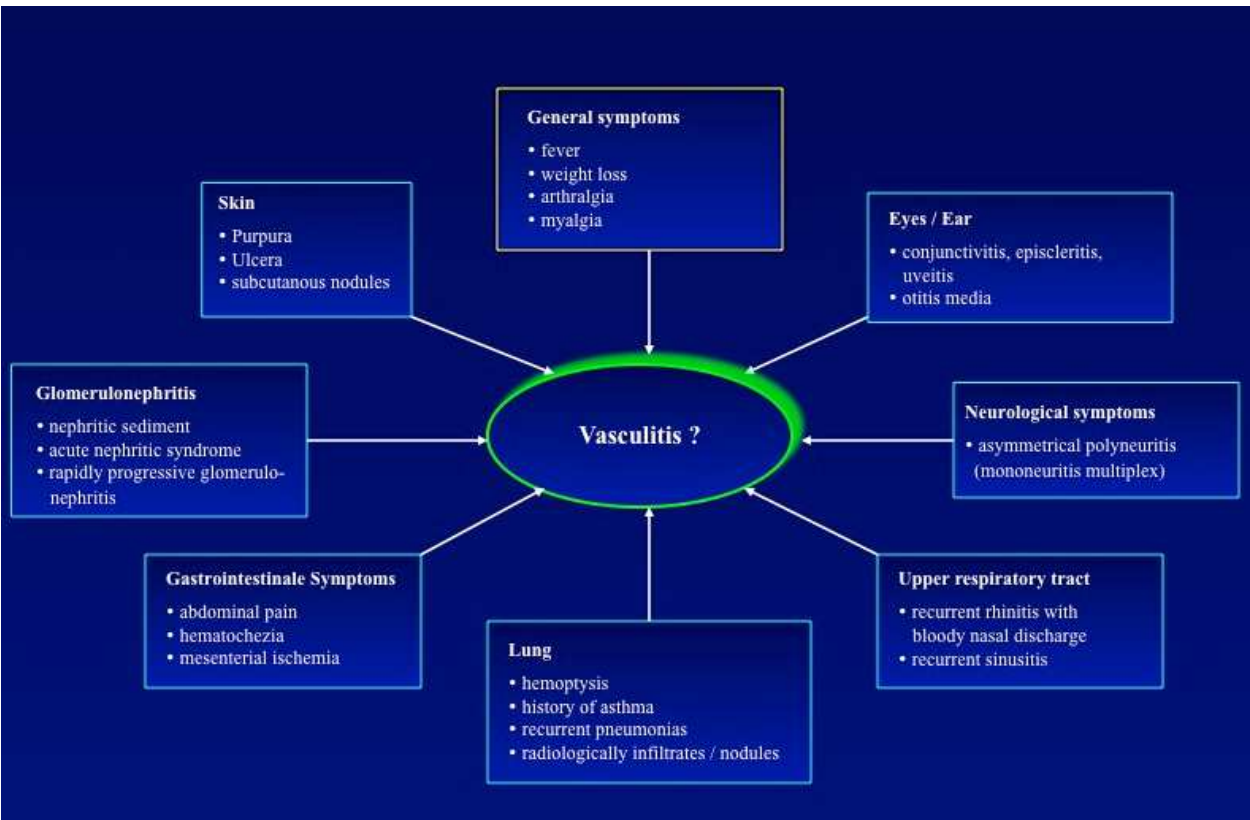


Fig. 2. General symptoms and signs of organ involvement in systemic small vessels vasculitis.

	ANCA-vasculitis				
	WG	MP	CSS	GP	SLE
Clinical presentation					
Vasculitic general symptoms	+	+	+	-	+
Granulomatous inflammation	+	-	+	-	-
Eye involvement	+	(+)	(+)	-	(+)
Recurrent asthma bronchiale	-	-	+	-	-
Pulmonary-renal syndrome possible	+	+	(+)	+	(+)
Skin (purpura, necrosis)	+	+	+	-	+
Gastrointestinal symptoms	(+)	(+)	(+)	-	(+)
	WG	MP	CSS	GP	SLE
Laboratory workup					
ANCA	80 - 90 %	80 - 90 %	50 - 70 %	< 30 %	-
Pr3-antibody	~ 70 %	~ 30 %	~ 10 %		
MPO-antibody	~ 20 %	~ 60 %	~ 60 %		
Eosinophilia	-	-	+	-	-
Reduced complement levels	-	-	-	-	+
Anti-ds-DNA	-	-	-	-	+
Anti-GBM-Ab	-	-	-	95%	-
Histology/Immunohistology					
Leucocytoclastic vasculitis	+	+	+	-	+
Granulomatous inflammation	+	-	+	-	-
Eosinophil granulomatous inflammation	-	-	+	-	-
Kidney Biopsy					
Light microscopy	necrotising intra- and extracapillary proliferative GN			necrotising intra- and extracapillary proliferative GN	Lupus-nephritis
Immunohistology	pauci-immune GN without immune-complex deposits			linear IgG-deposits in the glomerular basement membrane	granular deposits of IgG, IgM, IgA and complement factors

WG = Wegener's Granulomatosis. MP = microscopic polyangiitis. CSS = Churg-Strauss syndrome. GP = Goodpasture's Syndrome SLE = systemic lupus erythematosus. ANCA = antineutrophil cytoplasmic antibodies. PR-3 = proteinase-3. MPO = myeloperoxidase. IC = immune complex. GBM = Glomerular basement membrane. ds = double strand.

Table 2. The most important differential diagnoses of pulmonary-renal syndrome with clinical features, laboratory and histological findings.

3.1.1 Wegener's granulomatosis

Wegener's granulomatosis is a necrotizing vasculitis of the small and medium-sized vessels, associated with granulomas inflammation of the upper and lower respiratory tract and the frequent finding of glomerulonephritis. In active disease in about 90% of cases c-ANCA are directed against proteinase 3 (Tab. 1 and 2). Figure 3 shows the predominant symptoms in image and Figure 4 in number (at onset and during disease) [Hoffmann 1992].

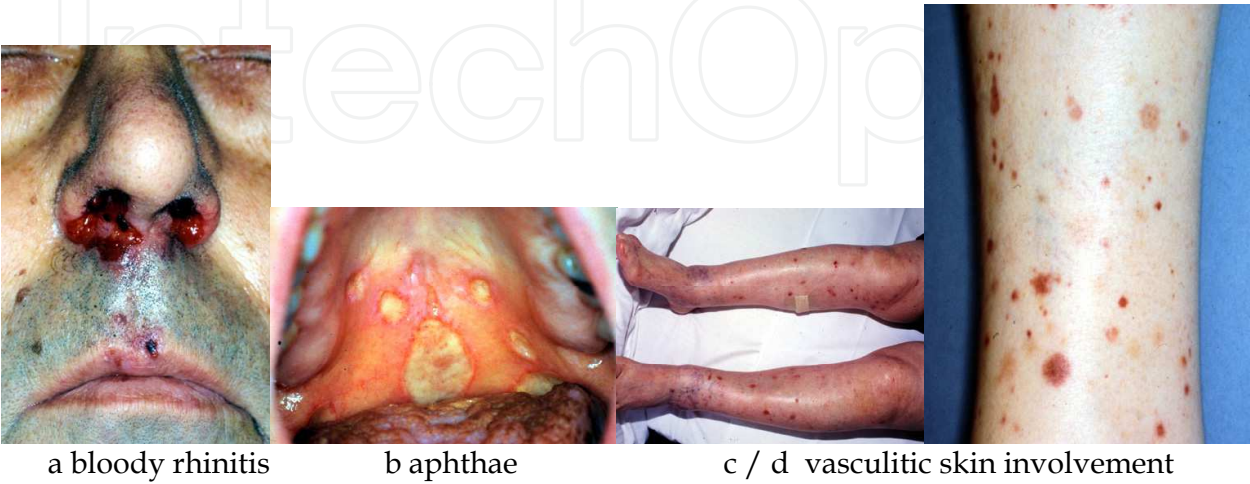


Fig. 3. Wegener's granulomatosis.

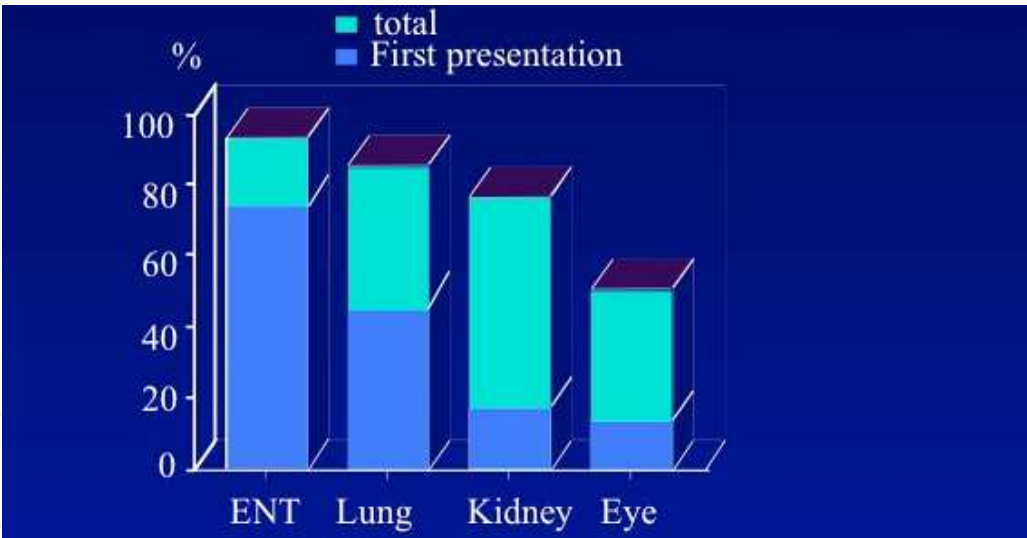


Fig. 4. Organ involvement in Wegener's granulomatosis.

3.1.2 Microscopic polyangiitis

Microscopic polyangiitis is characterized by a necrotizing vasculitis of small vessels with minimal or missing immune deposits and an inflammation of the pulmonary capillaries. Typically, there are p-ANCA directed against myeloperoxidase (Tab. 1 and 2) [Jennette 1994 & Falk 1997]. Wegener's granulomatosis and Microscopic polyangiitis shows comparable organ involvement, but the symptoms of the upper respiratory tract are usually milder in Microscopic polyangiitis, because there is no granulomatous inflammation. Compared to Wegener's granulomatosis disease recurrence is rare in patients with Microscopic polyangiitis.

3.1.3 Churg-Strauss syndrome

The Churg-Strauss syndrome is characterized by recurrent asthma attacks and allergic rhinitis, an intermittently or permanently detectable eosinophilia ($> 1500/\text{mm}^3$) and necrotizing granulomas and / or necrotizing arteritis with a Wegner's granulomatosis-like presentation. The serological diagnosis is less clear: c-ANCA or anti-PR3-Ab detected only rarely, p-ANCA and anti-MPO-Ab can be detected in up to 60% of cases (Tab. 1 and 2) [Hoffmann 1992].

The Churg-Strauss syndrome can be distinguished clinically (asthma attacks, eosinophilia) from Wegener's granulomatosis or Microscopic polyangiitis. Renal involvement is seen in approximately 25% of patients.

3.2 Goodpasture syndrome

The Goodpasture's syndrome is a rare disease with an incidence of 0.1-1 per million per year and affects mainly caucasian males. It is characterized by hemoptysis and / or radiological evidence of pulmonary infiltrates and a RPGN, which usually develops after hemoptysis. There is the very reliable detection of anti-GBM antibody, the identified antigen is the C-terminal end of the alpha-3-chain of type IV collagen. The immunohistological workup of the renal biopsy shows linear IgG deposits in the glomerular basement membranes (Tab. 1 and 2) [Goodpasture 1919, Salama 2001, Pusey 2003 & Hudson 2003].

Compared to the ANCA-associated small vessel vasculitides (Wegener's Granulomatosis, Microscopic polyangiitis and Churg-Strauss syndrome) there are no other, general vasculitic symptoms in patients with Goodpasture syndrome.

3.3 Immune-complex vasculitis of small vessels

Immune-complex vasculitides like

1. systemic lupus erythematosus,
2. cryoglobulinemic vasculitis and
3. Purpura Schoenlein-Hennoch [Markus 1989]

are important differential diagnostic considerations of the pulmonary-renal syndrome.

They can be distinguished by the previously described extended-serological diagnostic workup.

3.4 Further differential diagnoses

If this diagnostic workup is unremarkable, there are several more differential diagnosis:

1. antiphospholipid syndrome with vasculitis and / or pulmonary embolism
2. mixed connective tissue diseases (systemic sclerosis, polymyositis)
3. thrombotic thrombocytopenic purpura.
4. infectious diseases involving kidney and lung (e.g. Hanta-virus, cytomegalie-virus, Legionella, Mycoplasma, Leptospirosis, tuberculosis, sepsis)

Moreover, a primary renal disease can lead to a pulmonary disease and mimic the image of a pulmonary-renal syndrome:

1. acute renal failure with pulmonary edema and uremic hemoptysis
2. thromboembolism in nephrotic syndrome: renal vein thrombosis and/ or pulmonary embolism
3. immunosuppression in renal disease and a pneumonia.

Conversely, a primary pulmonary disease can lead to renal disease and can mimic the image of pulmonary-renal syndrome:

1. Infection of the respiratory tract with prerenal renal failure and / or postinfectious glomerulonephritis or hematuria in IgA nephropathy
2. Lung cancer with immune-complex nephritis.

4. Conclusions

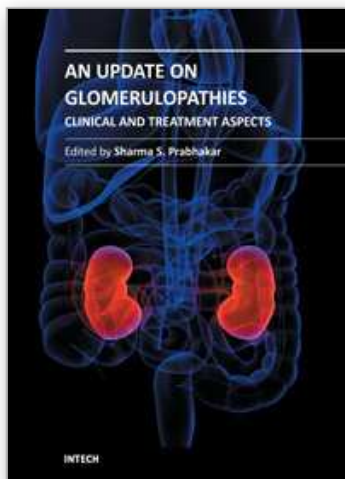
Since early treatment with the mentioned diseases is critical, the diagnosis has to be established quickly - the fast antibody-diagnostic and diagnostic imaging have a central role.

5. Acknowledgment

This work was supported by the Robert-Bosch Foundation.

6. References

- Niles JL et al. The syndrome of lung hemorrhage and nephritis is usually an ANCA-associated condition. *Arch Intern Med* 1996; 156: 440-445.
- Salant, DJ. Immunopathogenesis of crescentic glomerulonephritis and lung purpura. *Kidney Int* 1987; 32: 408-425.
- Boyce NW, Holdsworth SR. Pulmonary manifestations of the clinical syndrome of acute glomerulonephritis and lung hemorrhage. *Am J Kidney Dis* 1986; 8: 31-36.
- Gallagher H, Kwan JT, Jayne DR. Pulmonary renal syndrome: A 4-year, single-center experience. *Am J Kidney Dis* 2002; 39: 42-47.
- De Groot K, Schnabel A. *Internist (Berl)*. 2005; 46: 769-781.
- Hauber HP, Zabel P. Lunge und Autoimmunerkrankungen – Klinik und Diagnostik. *Dtsch Med Wochenschr* 2007; 132: 1633-1638.
- Bosch X, Guilabert A, Font J. Antineutrophil cytoplasmic antibodies. *Lancet* 2006; 368: 404-418.
- Saxena et al., Circulating autoantibodies as serological markers in the differential diagnosis of pulmonary renal syndrome. *J Intern Med* 1995; 238: 143-152.
- Jennette JC et al. Nomenclature of systemic vasculitides: Proposal of an international consensus conference. *Arthritis Rheum* 1994; 37, 187-192.
- Falk RJ, Jennette JC. ANCA small-vessel vasculitis. *J Am Soc Nephrol* 1997; 314-322.
- Gallo G. Renal complications of B-cell dyscrasias. *N Engl J Med* 1991; 324: 1889- 1990.
- Hoffmann GS et al. Wegener granulomatosis: an analysis of 158 patients. *Ann Intern Med*. 1992;116: 488-498.
- Masi AT et al. The American College of Rheumatology 1990 criteria for the classification of the Churg-Strauss syndrome (allergic granulomatosis and angiitis). *Arthritis Rheum* 1990; 33: 1094-1100.
- Goodpasture EW. The significance of certain pulmonary lesions in relation to the aetiology of pneumonia. *Am J Med Sci* 1919; 158: 863-870.
- Salama AD et al. Goodpasture's disease. *Lancet* 2001; 358: 917-920.
- Pusey CD. Anti-glomerular basement membrane disease. *Kidney Int* 2003; 64: 1535-1550.
- Hudson BG et al. Alport's syndrome, Goodpasture's syndrome, and type IV collagen. *N Engl J Med* 2003; 348: 2543-2556.
- Markus HS, Clark JV. Pulmonary hemorrhage in Henoch-Schönlein purpura. *Thorax* 1989; 44: 525-526.



An Update on Glomerulopathies - Clinical and Treatment Aspects

Edited by Prof. Sharma Prabhakar

ISBN 978-953-307-673-7

Hard cover, 468 pages

Publisher InTech

Published online 02, November, 2011

Published in print edition November, 2011

An Update on Glomerulopathies - Clinical and Treatment Aspects is a systemic overview of recent advances in clinical aspects and therapeutic options in major syndromes of glomerular pathology. The book contains twenty four chapters divided conveniently into five sections. The first section deals with primary glomerulopathies, and the second section is devoted to glomerulopathies complicating infectious conditions. The third section deals with systemic autoimmune disorders and vasculitides which constitute major causes of glomerular disease and often renal failure. The fourth section includes chapters discussing the glomerular involvement in some major metabolic and systemic conditions. The final section has chapters which relate to some general aspects of glomerular diseases. This book will form an excellent reference tool for practicing and academic nephrology community.

How to reference

In order to correctly reference this scholarly work, feel free to copy and paste the following:

Martin Kimmel, Niko Braun and Mark Dominik Alscher (2011). Differential Diagnosis of the Pulmonary-Renal Syndrome, An Update on Glomerulopathies - Clinical and Treatment Aspects, Prof. Sharma Prabhakar (Ed.), ISBN: 978-953-307-673-7, InTech, Available from: <http://www.intechopen.com/books/an-update-on-glomerulopathies-clinical-and-treatment-aspects/differential-diagnosis-of-the-pulmonary-renal-syndrome>

INTECH
open science | open minds

InTech Europe

University Campus STeP Ri
Slavka Krautzeka 83/A
51000 Rijeka, Croatia
Phone: +385 (51) 770 447
Fax: +385 (51) 686 166
www.intechopen.com

InTech China

Unit 405, Office Block, Hotel Equatorial Shanghai
No.65, Yan An Road (West), Shanghai, 200040, China
中国上海市延安西路65号上海国际贵都大饭店办公楼405单元
Phone: +86-21-62489820
Fax: +86-21-62489821

© 2011 The Author(s). Licensee IntechOpen. This is an open access article distributed under the terms of the [Creative Commons Attribution 3.0 License](https://creativecommons.org/licenses/by/3.0/), which permits unrestricted use, distribution, and reproduction in any medium, provided the original work is properly cited.

IntechOpen

IntechOpen