

We are IntechOpen, the world's leading publisher of Open Access books Built by scientists, for scientists

6,900

Open access books available

186,000

International authors and editors

200M

Downloads

Our authors are among the

154

Countries delivered to

TOP 1%

most cited scientists

12.2%

Contributors from top 500 universities



WEB OF SCIENCE™

Selection of our books indexed in the Book Citation Index
in Web of Science™ Core Collection (BKCI)

Interested in publishing with us?
Contact book.department@intechopen.com

Numbers displayed above are based on latest data collected.
For more information visit www.intechopen.com



Glomerular Pathology in Patients with HIV Infection

Enrique Morales, Elena Gutierrez-Solis,
Eduardo Gutierrez and Manuel Praga
*Nephrology Department, Hospital 12 Octubre, Madrid
Spain*

1. Introduction

The course and prognosis of patients infected with the human immunodeficiency virus (HIV) is changing dramatically following the introduction of highly active antiretroviral therapy (HAART), with increased patient survival and decreased morbidity (Mocroft et al, 1998).

Current therapy offers patients increased survival by making it more susceptible to certain comorbidities (Fang et al, 2007). Cardiovascular and renal diseases are the prototype of diseases whose prevalence increases progressively with the prolonged survival and aging (Braithwaite et al, 2005). On the other hand, besides specifically associated nephropathy or HIV coinfection with hepatitis C virus (HCV) with prolonged survival of the HIV-infected population, the spectrum of kidney disease in patients with HIV also reflects the growing burden of comorbid diabetes and hypertension and development chronic renal disease (Wyatt et al, 2007; Mocroft et al 2007; Szczech, 2004).

The prevalence of chronic kidney disease in HIV patients may be between 5 to 15% depending on the series. However, it has been manifested as albuminuria or proteinuria may be present up to 30% in some cohorts of HIV-infected patients (Szczech et al, 2002). The prevalence of renal histological involvement has ranged from 1-15% depending on the different autopsy series (Shahinian et al, 2000). Patients with HIV infection may develop different types of glomerular diseases, vascular lesions and tubulointerstitial nephritis related in some cases with the virus itself or other co-infections (Williams et al, 1998).

In this chapter we will review at different types of glomerular diseases found in patients with HIV infection, highlighting its etipopatogenia, clinical presentation, diagnosis and therapeutic alternatives.

2. Glomerular diseases in patients with HIV infection

Association between HIV infection and renal disease was first described in 1984, shortly after isolation of the virus (Rao et al, 1984). The glomerular diseases are relatively common complication in patients infected with HIV, with a wide range of clinical presentations and with a poor prognosis in most cases. Although HIV-associated nephropathy (HIVAN) has

been considered the most frequent and most representative glomerular disease, after the generalized treatment of HIV-infected patients with HAART therapy has allowed the emergence of other glomerular diseases with a higher incidence than the general population, see Table 1.

- HIVAN
- HIV-Associated glomerulonephritis. Immune complex glomerulonephritis
 - Membranoproliferative glomerulonephritis
 - Membranous nephropathy
 - Mesangial glomerulonephritis (IgA)
 - Focal segmental glomerulosclerosis non-collapsing
 - Lupus-like glomerulonephritis
 - Postinfectious glomerulonephritis
- Other nephropathies
 - Thrombotic Microangiopathy
 - Malignant hypertension
 - Amyloidosis

Table 1. Glomerular diseases in patients with HIV infection

2.1 HIV-associated nephropathy

This type of glomerular disease is HIV-associated nephropathy best described (Rao et al, 1987). The disease affects mostly males, intravenous drugs users and black patients (D’Agati & Appel, 1997). U.S. is the third leading cause of end-stage renal disease (ESRD) in African Americans between 20 and 64 years of age and the most common cause of ESRD in HIV-1 seropositive patients (Eggers & Kimmel, 2004; Shahinian et al, 2000). Prevalence is variable, ranging from 4% in clinical studies and 10% in autopsy (Mazbar et al, 1989). Although these renal findings can be seen in patients with asymptomatic or primary HIV infection, most of patients have low CD4 cells count and advanced disease. Among the specific mechanisms involved, in addition to genetic susceptibility (several polymorphisms that influence susceptibility to HIV infection), the virus can be seen in glomerular epithelial cells (Kimmel et al, 1993; Röling et al, 2006). Transgenic mice were crated with HIV-DNA construct inserted into the genome and developed a histological picture and clinical presentation very similar to that of humans (Bruggeman et al, 1997). The viral genome is detected in different renal structures (tubular cells, podocytes, glomerular parietal epithelial cells), even in cases without renal involvement, indicating that the presence in the renal tissue is not sufficient to cause nephropathy (Lu & Ross, 2005; Mikulak & Singhal, 2010). There are many mediators and the expression of nonstructural viral proteins, cytokines and growth factors can modulate and amplify renal injury. The mechanism of viral entry into renal epithelial cell is still unknown. CCR5 and CXCR4 are coreceptors to CD4 that mediate HIV-1 entry into lymphocytes. These receptors have not been demonstrated on renal epithelial cells in vivo (Eitner et al, 2000). Recently, have been described the DEC-205 receptor, which facilitates the entry of the virus in renal tubular cells (Hatsukari et al 2007). HIVAN is a characterized by a constellation of pathologic findings involving glomerular, tubular and interstitial compartments. Glomerular pathologic findings include a collapsing

focal segmental glomerulonephritis, with a marked retraction of glomerular capillary loops, and occlusion of the lumen (D'Agati & Appel, 1998). Podocytes show intense hypertrophy and hyperplasia, which is associated with decrease expression of podocyte maturity markers and accumulations of protein in their cytoplasm. On the other hand, there is a characteristic intense tubulointerstitial involvement, which gives it a matter of some exclusivity over other nephrotic syndromes. These changes consist of dilatation of the renal tubules, which sometimes are proliferative microcyst, and large proteinaceous cylinders in light, cell infiltrates and areas of fibrosis (D'Agati & Appel, 1998; Klotman, 1999). Immunofluorescence usually shows mesangial deposits of IgM and C3 and electron microscopy, are frequently observed tubuloreticular inclusions in the cytoplasm of endothelial cells. These structures are synthesized by the stimulation of alpha-interferon, as in the cases of patients with lupus nephritis. The histological differential diagnoses of focal segmental glomerulosclerosis are the collapsing nephropathy heroin abuse, caused by bisphosphonates, interferon or parvovirus (Klotman, 1999).

Main manifestation of HIV-associated nephropathy is a nephrotic syndrome (Herman & Klotman, 1998). However, although the proteinuric can be massive in many cases (more than 8-10 g/24 h), most patients with HIVAN do not have significant peripheral edema. Moreover, patients with HIVAN are usually not hypertensive, a remarkable finding considering that more than 90% of black patients with renal insufficiency of other causes exhibit hypertension. The kidneys are usually normal in size or larger. Most patients also have advanced renal failure at the time of diagnosis.

Evolution without HAART is poor, with rapid development of renal failure requiring dialysis within the first year of diagnosis, and with a high mortality (Winston et al, 1998). The beneficial effects of HAART on HIVAN have been shown in individual clinical observations. There are reports of resolution of renal disease with the administration of HAART, with a recurrence of renal disease after stopping treatment (Scialla et al, 2007).

Although no controlled clinical trials have demonstrated the effectiveness of any therapeutic measure in the HIVAN, it is recognized that HAART prevents or reduces the risk of developing HIVAN and if this occurs, the patients may have a slower course and lower mortality than in untreated patients (Lucas et al, 2004). Another treatment option is recommended in these patients using drugs that blocker renin-angiotensin-aldosterone system (BRAAS). These drugs are a part like any other chronic proteinuric nephropathy (Wei et al, 2003). Some studies have shown a decrease in proteinuria and a trend towards stabilization of renal damage in patients with HIVAN treated with corticosteroids. However, this treatment was not without significant side effects (Smith et al, 1994), so it should be limited to cases in which treatment with HAART have not produced any improvement and if we rule out opportunistic infections. Finally, we can find some curious case of spontaneous improvement of the glomerular pathology (Morales et al, 2002). The indications for renal replacement therapy with dialysis or transplantation in patients with HIVAN are similar to those followed in other chronic renal disease in the general population.

2.2 Immune-mediated glomerulonephritis

Patients with HIV infection have a higher incidence of other glomerulonephritis whose pathogenesis is generally attributed to glomerular deposition of immune complexes (Balow, 2005; Nochy et al, 1993), see **Table 2**.

	City/Country	Number of patients	Gender (M/F)	HCV (+)%	Race		Types of Glomerular diseases	Ref
Williams DI et al	London	17	13 M, 4 F		47% blacks	53% caucasians	HIVAN 41%, MN 23%, HUS 12%, others 24 %	9
Rao TKS et al.	Nueva York	55	49 M, 6 F		100% blacks		HIVAN 90%, Mesangial GN 10%	11
Mazbar SA et al.	San Francisco	27	26 M, 1 F		63% blacks	37% caucasians	HIVAN 27%, MPGN 27%, Interstitial nephritis 9%, immune complex GN with IgG-IgM 9%, 28 % others	15
NocheD et al.	Paris	60	51 M, 9 F		48% blacks	52% caucasians	43 % HIVAN, Immune complex GN 37%, lupus like nephritis 16%, HUS 11.5%	33
Casanova S et al.	Italy	26	21 M, 5 F		100% caucasians		Immune complex GN 65.5%, MPGN 15.5%, lupus like nephritis 11.5%, minimal change 7.5%	34
Connolly JO et al.	London	34	25 M, 9 F		55.8% blacks	41.1%caucasians	50 % HIVAN, 14.5 % MN, 6% MPGN, 12 % HUS, 3% Immune complex GN, 14.5 % others	53
Shahinian V et al.	Texas	389	362 M, 27 F		54 % blacks	35% caucasians	26% unknown, 7 % HIVAN, 7% immune complex GN, 17 % ATN, 25% crystal induced nephropathy	14
Szczech La et al.	EEUU	89	73 M, 16 F		88% blacks	12% others	47% HIVAN, 53 % non-HIVAN	6
Cheng JT et al.	EEUU	14	8 M, 6 F	100	93% blacks	7% caucasians	79% MPGN, 21% MN	36
Stokes MB et al.	EEUU	12	11 M, 1 F	100	58% blacks	42% caucasians	41% MPGN, 41 % mesangial GN, 8% MN, 8 % HIVAN	37
Gutiérrez et al.	Madrid, Spain	27	23 M, 4 F	77.8	11% blacks	89% caucasians	29.6% MPGN, 25.9% Non-collapsing FSGS, 22.2% mesangial GN, 14.8% HIVAN.	45

Table 2. Different studies with renal disease in HIV patients

In Europe, especially in Caucasians, glomerular immune complex glomerular diseases are more common than HIVAN and may take several forms. The immune-mediated glomerulonephritis would be the counterpart among the white population to what is represented by the HIVAN in the black (Casanova et al, 1995).

The pathogenesis of these types of glomerulonephritis remains largely unknown; there is a local formation or glomerular deposition of circulating immune complexes that may contain HIV antigens and polyclonal antibodies. We can not rule out the involvement of an immune response against associated viral infections. The clinical features are very striking (gross hematuria, edema, acute renal failure, and hypertension), although cases of more subtle presentation and are diagnosed incidentally, see **Table 3**. Hypergammaglobulinemia is common, reflecting a polyclonal B cell activation. However, the role of some viral co-infections very frequent among HIV patients, such hepatitis C (HCV) and hepatitis B virus (HBV), appears to be decisive, particularly in MPGN and NM.

Very limited information is presently available regarding treatment and clinical outcomes in patients with immune-mediated GN in patients with HIV infection. Until now we have not information about the therapeutic interventions used in patients without HIV infection (steroids, immunosuppressants, calcineurin inhibitors) can change the course of immune-complex glomerulonephritis.

	HIVAN	MPGN	IgAN	FSGS-NC	MN	PIGN	Lupus-like	Amyloidosis	MAT
Nephrotic syndrome	4	3	0	3	4	1	4	4	1
Macroscopic hematuria	0	2	4	0	0	3	2	0	2
Acute renal failure	1	1	2	1	1	3	1	1	4
Hypertension/ Malignant hypertension	1	1	3	1	1	1	1	0	3
Hypo-complementemia	0	3	0	0	0	4	1	0	0
Cryoglobulins (+)	0	3	0	0	0	1	1	0	0
Coinfection HCV/HBV	0	4	1	1	2	0	2	1	0
Treatment	HAART BSRAA S	BSRAA VHC (+) (INF+RBV) (S+PF+RTX)	BSRAA	BSRAA	BSRAA Several clinical (S+IMS)	BSRAA Several clinical (S)	HAART S	HAART Secondary aetiology	Plasma P

HIVAN: HIV-associated nephropathy; MPGN: membranoproliferative GN; IgAN: IgA nephropathy; FSGS-NC: Not collapsing forms of FSG; MN: membranous nephropathy; PIGN: Postinfectious GN; MAT: Thrombotic microangiopathy; HAART: Highly active antiretroviral therapy; BSRAA: Blockers of the system renin-angiotensin-aldosterone; S: steroids; INF: interferon; RBV: ribavirin; RTX: rituximab; P:Plasmapheresis. Degrees: (0-4): (Never-Always)

Table 3. Most common presentations and laboratory markers in glomerular diseases in patients with HIV infection

2.2.1 Membranoproliferative glomerulonephritis

The most common clinical presentation is nephrotic syndrome with macroscopic hematuria or microhematuria and normal renal function or mild renal function impairment. Up to 90% of cases there are co-infected with HCV (Morales et al, 1997; Cheng et al, 1999). Cryoglobulins are detected in most cases with elevated rheumatoid factor and decrease of complement, especially C4. The clinical and serological profile is very similar to the membranoproliferative GN associated with HCV patients without HIV infection. For all these reasons it is considered that this is a pathogenetically GN induced by HCV, without the concomitant presence of HIV play a prominent role (Stokes et al, 1997).

In some cases the extrarenal manifestations of cryoglobulinemia include clinical presentation, with vasculitis cutaneous, and even gastrointestinal manifestations alveolar hemorrhage. In these cases we can find an acute renal failure with hematuria and proteinuria, and characteristic histological finding of membranoproliferative GN with deposits of cryoglobulins in glomerular capillary lumens. Cryoglobulins are usually of a mixed IgG-IgM.

The safety and efficacy of HCV treatment with interferon and ribavirin in patients coinfecting with HIV has been evaluated in numerous series in the literature (Kadan & Talal, 2007). There are series of cases in which an effective antiviral treatment correlated with improvement in renal manifestations (Kamar et al, 2006). However, we find cases in which there is no negativity of cryoglobulins despite the negativity of HCV-RNA, and can even clinical manifestations (Morales et al, 2007). There are cases in which clinical aggressiveness may be amenable to immunosuppressive treatment. High-dose steroids and plasmapheresis may improve the clinical course, although has increased HCV replication and risk of worsening liver disease. Rituximab is an anti-CD20 monoclonal antibody that has produced a prolonged improvement of renal manifestations in cases that can not be eradicated HCV (Kamar et al, 2006).

In cases of membranoproliferative GN is not associated with HCV; the experience is limited and can recommend the use of drugs that block the RAAS, since its effect antiproteinuric, renoprotective and antihypertensive.

2.2.2 IgA nephropathy

Series have described several cases of IgA nephropathy in patients infected with HIV. The actual incidence is unknown, but in a study of 116 autopsies in patients with HIV infection were detected IgA glomerular deposits by 7.7% (Beaufils et al, 1995).

Patients infected with HIV develop IgA antibodies against specific HIV antigens and this seems to be the pathogenic basis of this nephropathy. On the other hand, can produce idiotype IgA antibodies against other antibodies IgG and IgM directed against viral antigens. Renal lesions may result from HIV antigen-specific immune complexes that are derived from the circulation and from in situ complex formation (Kimmel et al, 1992).

Clinical presentation is similar to that of idiopathic IgA nephropathy: microhematuria with occasional episode of gross hematuria after infection mainly located in the upper respiratory tract and different proteinuria degrees. The long-term prognosis depends mainly on the amount of the proteinuria. In addition to these developments chronic, slowly progressive, characteristic of IgA nephropathy, patients may also develop acute complications similar to those of the IgA idiopathic acute renal failure that is associated with macroscopic hematuria

is a widely known complication (Gutierrez et al, 2007) and development of hypertension malignant (MHT) (Chen et al, 2005). In episodes of gross hematuria may develop acute tubular necrosis, tubular abnormalities consist in a high proportion of tubules that are filled by red blood cells (RBC) casts and signs of tubular necrosis that are more evident in tubules that are occupied by RBC casts, see **Figure 1**.

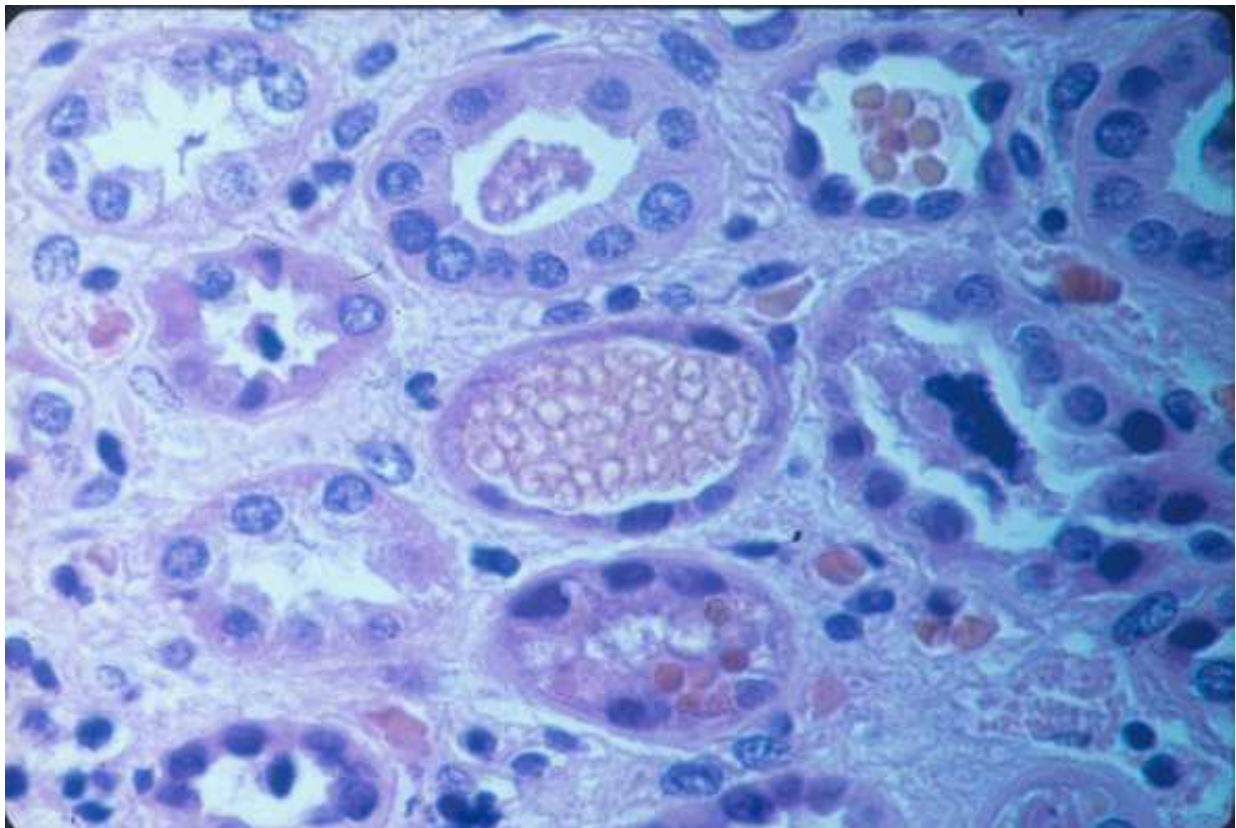


Fig. 1. Tubules filled by red blood cells, showing diminished number of lining epithelial cells and nuclear pyknosis.

Regarding the MHT, is observed in a significant percentage (5% -7%) of cases of idiopathic IgA, but some series indicate that its incidence may be even higher in HIV-associated IgA nephropathy. In our experience, most of the cases with HIV-infection and IgA nephropathy presented malignant hypertension (Gutierrez et al, 2007). The prognosis is poor and many cases progress to irreversible end-stage renal failure, see **Figure 2**. However, in some patients the effective control of blood pressure drug type inhibitors of angiotensin converting enzyme (ACE) inhibitors and / or antagonists of the angiotensin receptor (ARB) manages to partially reverse renal failure.

In some patients with HIV infection, as also in Idiopathic IgA renal manifestations may be associated with systemic manifestations of the type of vasculitis cutaneous, arthritis and various digestive disorders, all components of the Schönlein-Henoch syndrome.

At the present there is a little information about the treatment and outcomes of patients with HIV infection. Therefore, according to the recommendations in idiopathic IgA, it is recommended to treat all patients who develop significant proteinuria (>0.5 -1 g / day) or hypertension, with ACE inhibitors or ARB, since the antiproteinuric and renoprotective effect of these drugs, also tested with IgA nephropathy (Praga et al, 2003).

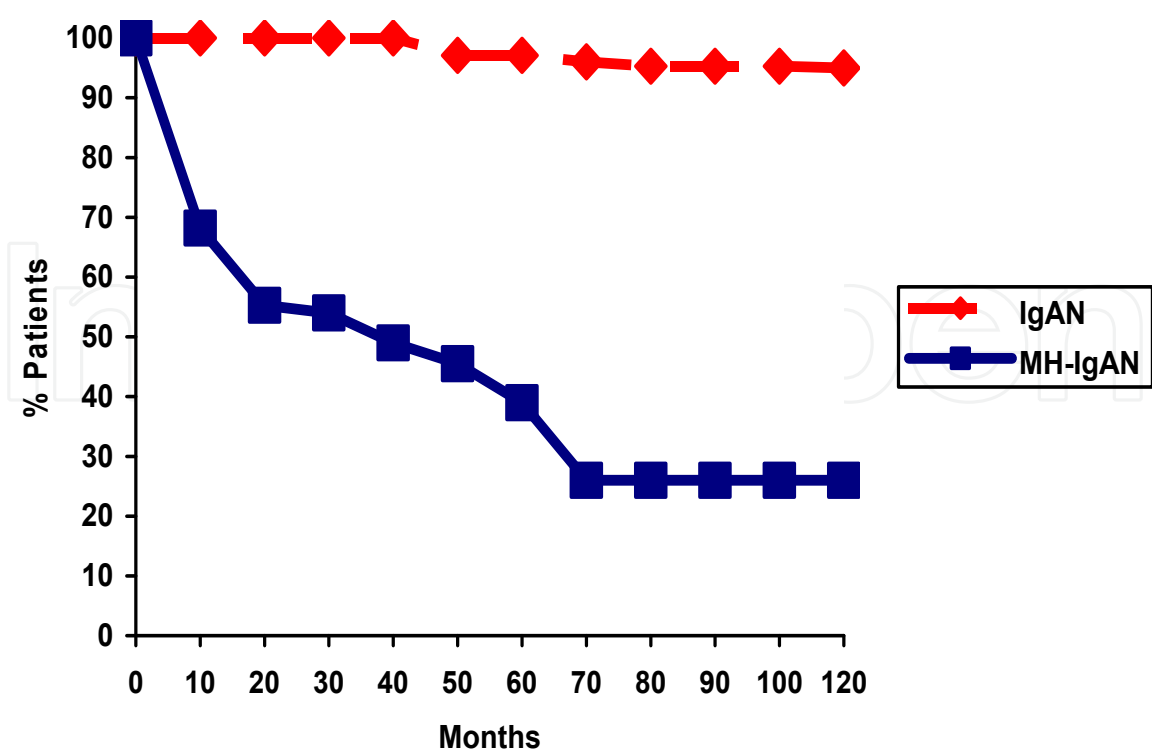


Fig. 2. Renal survival of patients with mesangial IgA nephropathy and MHT and mesangial nephropathy patients without MHT.

2.2.3 Focal segmental glomerulosclerosis non-collapsing

Among the different histological forms of focal glomerulosclerosis, have also been reported not collapsing glomerulosclerosis in patients with HIV (Haas et al, 2005). The pathogenesis and the exact relationship of these GN may have HIV or other pathogens have not been investigated.

Very limited information is available about the real incidence, clinical and developmental characteristics and therapeutic possibilities of this entity. In our experience, this type of glomerular disease is the second most common presentation in our HIV-infected patients (Gutierrez et al, 2007). The most common clinical presentation was proteinuria, and nephrotic syndrome was observed in 72% of cases. All patients were treated with HAART and BSRAA; at the end of treatment no patient need dialysis and 60% had renal insufficiency (Gutierrez et al, 2007).

In idiopathic forms, not associated with HIV, proteinuria and nephrotic syndrome are common manifestations. Some cases progress rapidly to ESRD. Corticosteroids administered for a long time for months and calcineurin inhibitors drugs are treatment options supported by experience. However, given the absence of data on HIV-infected patients and the susceptibility of these patients to infections, careful observational studies are needed before recommending these options. The optimization of antihypertensive and antiproteinuric drugs (ACEI/ARB) can exert a favorable effect, as in idiopathic less aggressive forms.

2.2.4 Membranous nephropathy

Membranous nephropathy (MN) is a typical example of glomerular disease mediated by deposition of immune complexes. MN is a recognized complication of renal malignancies

and infections. Among these, HBV and HCV have been associated with the development of MN and syphilis, and various parasitic diseases.

In this context, the frequent presence of HBV and HCV co-infection and the increasing incidence of syphilis and other infectious processes suggests that there may be a predisposition of patients with HIV infection to the development of MN, although not known actual incidence and its outcome.

The characteristic clinical presentation is nephrotic syndrome, although minorities of cases show no nephrotic range proteinuria. In forms idiopathic, there are two therapeutic strategies that have proven effective in controlled prospective studies, immunosuppression with steroids plus cyclophosphamide or chlorambucil, and calcineurin inhibitors drugs (cyclosporine, tacrolimus) (Praga, 2008). However, consider that a high percentage (up to 50% in some series) have spontaneous remission within the first years of the disease (Polanco et al, 2010) for this reason may be preferable initially attitude conservative in patients with HIV-infection. All chronic proteinuric nephropathies may be beneficial to use renin-angiotensin-aldosterone system blockers (ACEI/ARB). If we can identify an infectious agent as pathogenic factor, the treatment could potentially resolve the kidney problem.

2.2.5 Postinfectious glomerulonephritis

Although the descriptions are limited (Enriquez et al, 2004), patients with HIV infection could be theoretically exposed to the development of postinfectious GN due to its higher rate of infection. The clinical picture is generally abrupt, with hypertension difficult to control, often gross hematuria and mild and transient impairment of renal function frequently. There are typical red blood cell casts present in urinary sediment and hypocomplementemia. Renal biopsy shows a diffuse endocapillary GN with proliferation of mesangial and endothelial cells, Glomerular and interstitial infiltration of monocytes and lymphocytes is present. Glomerular accumulation of neutrophils is common and is termed "exudative". Ultrastructural studies demonstrate the subepithelial "humps" which are typical although not pathognomonic of postinfectious GN.

The history of an infection, usually 1-2 weeks, followed by a short asymptomatic period and the typical abrupt onset of nephritic syndrome for the diagnosis in many cases, along with the study of the sediment and the detection of hypocomplementemia. The majority of cases have benign course with conservative treatment of the infectious process and complications (hypertension, edema). The descriptions of acute postinfectious GN in patients with endocarditis or localized infections are characteristic, although they have published very few cases among HIV-infected patients.

2.2.6 Lupus-like glomerulonephritis

Lupus-like glomerulonephritis, defined by the presence of a "full house" of glomerular immunoglobulin and complement deposits on immunofluorescence in the absence of serologic evidence of systemic lupus erythematosus (SLE). There is presently little information known about the etiology, its treatment, or its long-term outcome.

Its main histological features are cell proliferation and mesangial matrix, the presence of hyaline thrombi and massive deposit of immune complexes in capillary walls, which reach mimic the "wire loops" typical of lupus nephritis and are the origin of name ("lupus-like") that has been proposed for these cases. In immunofluorescence, as occurs in lupus nephritis, deposit detects all types of immunoglobulins (IgG, IgA, IgM) and various fractions of

complement (Haas et al, 2005; Weiner et al, 2003). However, the term may be misleading, because the similarities end with lupus in the histological aspects of renal biopsy. There are no systemic symptoms similar to lupus flares and serology (ANA and anti-DNA, hypocomplementemia) is negative.

Most reported cases present with nephrotic syndrome and progressive deterioration of renal function. No information about the natural history of this process and whether or not modify therapeutic interventions. Regarding the pathogenesis, there are only speculations. It is proposed that, in addition to frequent infections with HBV, HCV and other infectious agents, HIV itself through several of its proteins (p24, gp41, gp120) can induce a systemic response of immunoglobulin, causing a large amount of circulating immune complexes that would be trapped nonspecifically in the glomerulus, alternatively, the HIV proteins could be initially deposited in the glomerulus (planted antigens) and subsequently be detected by the antibody in situ formation of immune complexes (Weiner et al, 2003).

Although we can be exceptionally patient with HIV infection and the coexistence of lupus with renal involvement, and it would be important to make a diagnosis difference between the two entities. In patients with both HIV infection and a diagnosis of SLE, three patterns of disease occurrence have been described: HIV following SLE diagnosis, SLE following HIV infection, and simultaneous diagnosis of HIV and SLE. Since the appearance of an autoimmune disorder in patients with a pre-existing immunodeficiency would not be expected, at least from a mechanistic standpoint, we will focus our review on patients with existing HIV who developed signs and symptoms consistent with a new diagnosis of lupus. SLE and HIV infection are two diseases whose clinical and serologic presentations may occasionally mimic one another, but with pathogenic mechanisms that theoretically are mutually exclusive. The seemingly paradoxical coexistence of these two immune disorders offers intriguing insights into the complex cellular and humoral immune networks that govern autoimmune phenomena and self tolerance.

Finally, the clinical management of the HIV positive lupus patient represents a therapeutic challenge for the physician due to the delicate equilibrium that needs to be achieved between SLE remission and HIV control (Gindea et al, 2010).

2.3 Other nephropathies in patients with HIV infection

2.3.1 Thrombotic microangiopathy

Thrombotic microangiopathy (TMA) is a known complication of HIV infection (Connolly et al, 1995; Alpers, 2003). Published reports of the incidence of TMA evaluated during the pre-HAART era vary considerably, depending on the type of study performed, diagnostic criteria used to evaluate patients, and stage of HIV disease (Connolly et al, 1995). It is likely that this under-diagnosed entity, as shown in autopsy studies (Gadallah et al, 1996) and patients with progressive deterioration of renal function, the presence of MAT in renal biopsy exceeded the incidence of HIVAN (Peraldi et al, 1999).

Endothelial cell injury appears to be the primary event causing platelet activation and deposition in the microvasculature. On these microthrombi mechanical destruction would occur, anemia, schistocytes, elevated LDH and Coombs test negative. Direct cytopathic roles of HIV as well as other factors such as malignancy, drugs, and infectious agents have been implicated in the pathogenesis of HIV-TMA. It is known that various HIV proteins can directly damage endothelial cells, inducing apoptosis therein (Alpers, 2003).

In experimental animals infected with HIV often develops MAT, so it is suspected that HIV itself plays a key role in endothelial damage (Eitner et al, 1999). It is also the possibility that anticardiolipin antibodies/antiphospholipid frequently detected in HIV patients (Boue et al, 1990) have pathogenic importance. In the primary antiphospholipid syndrome or lupus erythematosus associated with MAT may be triggered. Although not able to demonstrate that HIV-infected patients with anticardiolipin antibodies are at higher risk for MAT, it is an intriguing association. In idiopathic MAT has been achieved in many cases to elucidate the molecular basis of the disorder, especially those with family history: gaps ADAMS-13 and other enzymes that degrade the von Willebrand factor in type forms PTT and alterations of the complement system in the SHU. There is no evidence that these disorders occur in the MAT of patients infected with HIV. Although the majority of patients present in a more advanced stage of HIV disease, TMA can be the initial presenting symptom of HIV infection.

Clinical features are those of idiopathic TMA (Eitner et al, 1999), and the diagnosis should be suspected in any patient with new onset thrombocytopenia and microangiopathic haemolytic anaemia. Most patients are male and young and progressive deterioration of renal function is associated with the typical hematological findings MAT: schistocytes anemia with peripheral blood, thrombocytopenia, elevated LDH. Although most cases present a clear and rapidly progressive deterioration of renal function, similar to pictures of hemolytic uremic syndrome (HUS), others can have predominant neurologic manifestations, as in thrombotic thrombocytopenic purpura (TTP).

Kidney biopsy shows changes similar to idiopathic MAT: platelet-fibrin thrombi in preglomerular arterioles and the glomerular capillaries, arterioles with endothelial edema imaging in "onion skin" and mesangiolysis with widening of subendothelial space. When there are extrarenal manifestations (neurological, cardiac) vascular lesions are similar in the vessels of the affected organs.

Therapy with plasma exchange or infusion appears to be efficacious. A rapid diagnosis and institution of plasmapheresis is crucial for a favorable outcome. The long term prognosis of HIV-TMA is unfavorable and may depend on the stage of HIV infection. The recent data after the use of highly active retroviral treatment, however, are unavailable and current prognosis is therefore uncertain.

2.3.2 Malignant hypertension

Malignant hypertension is defined by the presence of unacceptably high blood pressure with grade III hypertensive retinopathy (hemorrhages and exudates) or IV (papilledema more vascular lesions). As we noted earlier, is a casual presentation of idiopathic IgA nephropathy, but its impact on the rest of idiopathic GN is rare. By contrast, preliminary studies indicate incidence of MHT special not only in IgA nephropathy patients with HIV, in which may be the most frequent presentation of this entity, but in other glomerular diseases associated with HIV (Morales et al, 2008). On the other hand, entities such as membranoproliferative GN, membranous and focal glomerulosclerosis, in which the MHT is a rare complication, there are a significant number of cases when associated with HIV infection. In our experience, malignant nephrosclerosis (arteriolar fibrinoid necrosis with intimal thickening and luminal narrowing; see **Figure 3**) was detected in six cases (three of them with IgAN, one with C-FSG, one with NC-FSG and one with MGN).

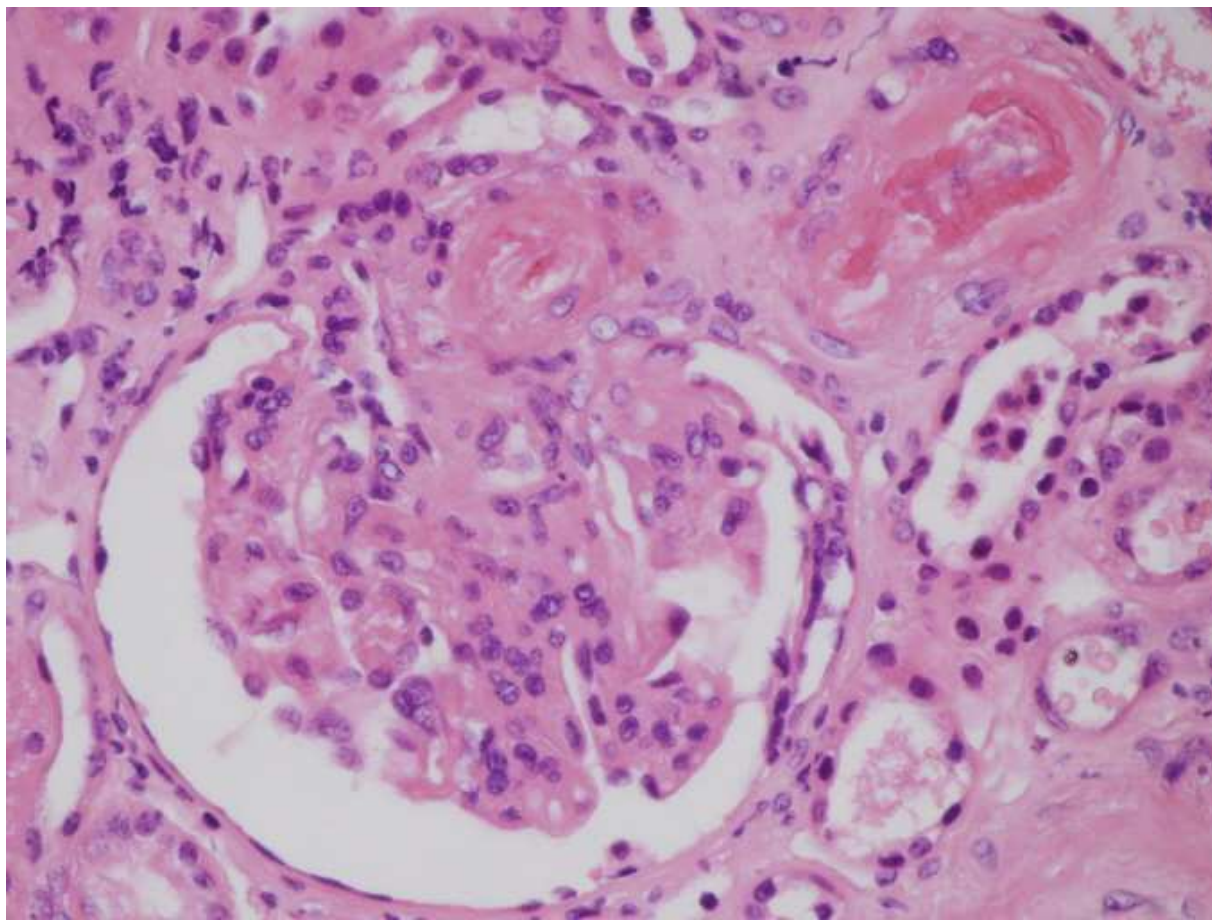


Fig. 3. Renal biopsy of patient 1 (Table 1), showing a glomerulus with mesangial proliferation (the immunofluorescence showed predominant deposits of IgA) and vascular lesions of malignant nephrosclerosis (fibrinoid necrosis) in the afferent arteriole. (hematoxylin;eosin; x400).

The typical symptoms of MHT (markedly increased BP, blurred vision due to retinal haemorrhages and severe headache). To interpret this catastrophic prognosis in HIV patients with GN and MHT, we speculate that the development of MHT has an irreversible detrimental influence on glomerular diseases already having a rather poor prognosis by themselves, see **Figure 4**.

On the other hand, the development of chronic renal failure could likely exacerbate the appearance of infectious and cardiovascular complications in these HIV-infected patients because both patients with chronic renal failure and HIV infection are particularly prone to the appearance of such complications (Grinspoon & Carr, 2005; Kamin & Grinspoon, 2005; Gupta et al, 2005). Other possible pathogenic pathways to explain this particular propensity of HIV patients with glomerular diseases to MHT could rely on the already known higher incidence of thrombotic microangiopathy (TMA) among HIV patients (Alpers, 2003). Both TMA and MHT could be interpreted as clinical manifestations of a systemic endothelial injury, due to a direct toxic effect of HIV, other infectious agents (particularly HCV and HBV) or other factors (such as drug addictions) linked to the environment of HIV infection. On the other hand, the presence of antiphospholipid antibodies is also more common among HIV patients, and these autoantibodies could play a role in endothelial vascular damage (Alpers, 2003; Galrao et al, 2007).

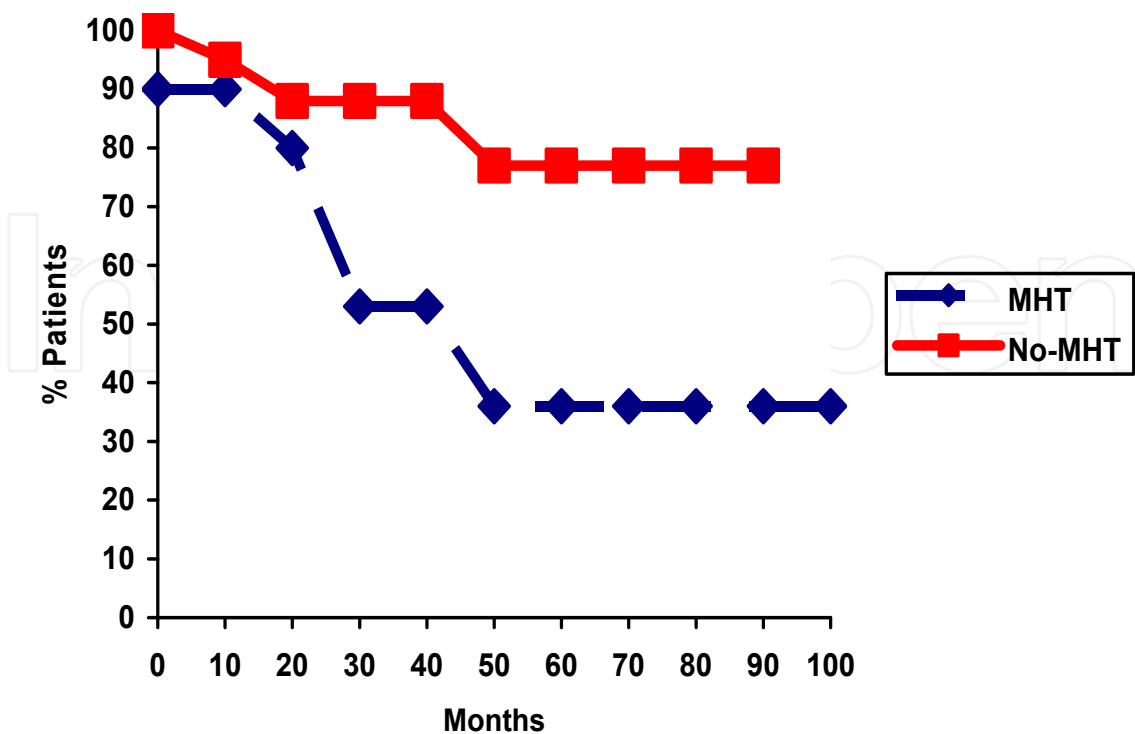


Fig. 4. Probability of renal survival (absence of chronic dialysis) in HIV patients with or without malignant hypertension.

In addition, considering the dismal prognosis of our patients in spite of HAART treatment and a satisfactory control of blood pressure, early detection and treatment of hypertension in HIV patients with glomerular diseases are mandatory.

2.3.3 Amyloidosis

In autopsy series of patients infected with HIV, as well as reviews of renal biopsies, amyloidosis is a relatively common finding (Lanjewar et al, 1999; Joseph et al, 2000). This is a secondary amyloidosis, type AA. Many studies have been suggested that frequent chronic infections may be responsible for this complication. However, it is possible that HIV infection itself plays a pathogenic role. Described a high level of SAA, acute phase reactant which is the precursor of AA amyloid in patients infected with HIV (Husebekk et al, 1986) and experimental models have shown that a significant proportion of animals infected develop amyloidosis (King et al, 1983).

As is common in amyloidosis, massive proteinuria and nephrotic syndrome were the most common renal manifestations in the cases described. There are no studies about specific therapeutic options in these patients, apart from trying to eradicate the underlying infectious process.

2.3.4 Hypertensive and diabetic nephropathy

Metabolic complications of HAART (dyslipidemia, changes in body fat, insulin resistance, diabetes mellitus) and the aging of the infected population suggest that kidney damage secondary to diabetes and hypertension may have increasing importance in patients infected HIV (Masia-Canuto et al, 2006).

In some series of renal biopsies of patients with HIV infection has been reported the presence of diabetic nephropathy in 6% of cases, hypertensive nephropathy in 4% (Szczech et al, 2004).The recommended treatment is similar to that used in the uninfected population and should include strict control of blood pressure and the early use of BSRAA to try to reduce proteinuria.

3. Tubular and interstitial renal disease

Patients infected with HIV can present a wide variety of tubular and interstitial renal disease secondary to drugs, infections and/or tumors; see Table 4 (GESIDA, 2010; Blok & Weening, 1999).

- Acute tubular necrosis
- Interstitial nephritis associated with drugs
 - Renal failure and Fanconi syndrome (certain reverse transcriptase inhibitors)
- Allergic interstitial nephritis
- Cristal-induced nephropathy (certain protease inhibitors)
- Interstitial nephritis associated with infections (cytomegalovirus, tuberculosis, hongos, Salmonella, Legionella, etc)
- Kaposi sarcoma and Lymphoma infiltrative
- Rhabdomyolysis

Table 4. Tubular and interstitial renal disease

The recommendations for the treatment of these nephropathies consist of drug withdrawal or correction of the precipitating cause, corrections, electrolyte, and in interstitial nephritis immunoallergic the administration of a short course of corticosteroids.

4. Conclusion

In conclusion, due to the wide range of kidney damage in people with HIV infection, it is difficult to predict the renal histology according to clinical criteria, so renal biopsy is mandatory for histologic diagnosis. In addition, the course and prognosis of these patients has changed radically since the introduction of antiretroviral therapy, with higher survival, so early diagnosis is essential and the establishment of an alternative therapy to prevent progression of renal disease.

5. References

Alpers CE (2003). Light at the end of the TUNEL. HIV-associated thrombotic microangiopathy. *Kidney Int* 2003; 63:385-396.

Alpers CE (2003). Light at the end of the TUNEL. HIV-associated thrombotic microangiopathy. *Kidney Int* 2003; 63:385-396.

Balow JE (2005). Nephropathy in the context of HIV infection. *Kidney Int* 2005; 67(4):1632-3.

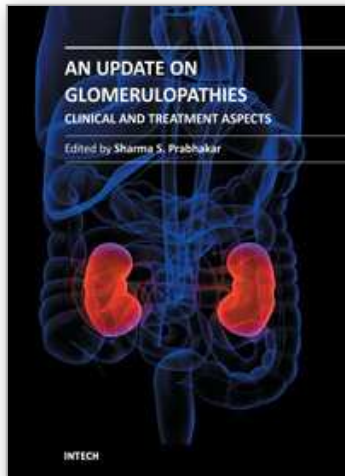
Beaufils H, Jouanneau C, Katlama C, Sazdovith V & Hauw JJ (1995). HIV-associated IgA nephropathy -A postmortem study. *Nephrol Dial Transplant* 1995; 10:35-38.

- Blok K & Weening JJ (1999). Interstitial nephritis and nephritic syndrome in patient from Zambia. *Nephrol Dial Transplant* 1999; 14:1016-1017.
- Boue F, Dreyfus M & Bridey F (1990). Lupus anticoagulant and HIV infection: a prospective study. *AIDS* 1990; 4:467-471.
- Braithwaite RS, Justice AC, Chang CC, Fusco JS, Raffanti SR & Wong JB et al (2005). Estimating the proportion of patients infected with HIV who will die of comorbid diseases. *Am J Med* 2005; 118: 890-898.
- Bruggeman LA, Dikman S, Meng C, Quaqqin SE, Coffman TM & Klotman PE (1997). Nephropathy in human immunodeficiency virus-1 transgenic mice is due to renal transgene expression. *J Clin Invest* 1997; 100:84-92.
- Casanova S, Mazzucco G, Barbiano di Belgiojoso G, Motta M, Boldorini R & Genderini A, et al (1995). Pattern of glomerular involvement in human immunodeficiency virus-infected patients: an Italian study. *Am J Kidney Dis* 1995; 26:446-453.
- Connolly JO, Weston CE & Hendry BM (1995). HIV associated renal disease in London hospitals. *Q J Med* 88: 627-34, 1995.
- Cheng JT, Anderson HL, Markowitz GS, Appel GB, Poque VA & D'Agati V (1999). Hepatitis C virus-associated glomerular disease in patients with human immunodeficiency virus coinfection. *J Am Soc Nephrol* 1999; 10:1566-1574.
- Chen Y, Tang Z, Yang G, Shen S, Yu Y & Zeng C et al (2005). Malignant hypertension in patients with IgA nephropathy. *Kidney Blood Press Res* 2005; 28:251-258.
- D'Agati V & Appel GB (1997). HIV infection and the kidney. *J Am Soc Nephrol* 1997; 8:138-152.
- D'Agati V & Appel GB (1998). Renal pathology of human immunodeficiency virus infection. *Semin Nephrol* 1998; 18: 406-421.
- Eitner F, Cui Y, Hudkins KL, Schmidt A, Birkebak T & Aqv MV et al (1999). Thrombotic microangiopathy in the HIV-2-infected macaque. *Am J Pathol* 1999; 155:649-661.
- Eitner F, Cui Y, Hudkins KL, Stokes MB, Segerer S & Mack M, et al (2000). Chemokine receptor CCR5 and CXCR4 expression in HIV-associated kidney disease. *J Am Soc Nephrol* 2000; May;11(5):856-67.
- Eggers PW & Kimmel PL (2004). Is there an epidemic of HIV infection in the US ESRD Program?. *J Am Soc Nephrol* 2004; 15:2477-2485.
- Enríquez R, Cabezuelo JB, Escolano C, Pérez M, Amorós F & Gutiérrez-Rodero F, et al (2004). Postinfectious diffuse proliferative glomerulonephritis and acute renal failure in an HIV patient. *Clin Nephrol* 2004; 61:278-281.
- Fang CT, Chang YY, Hsu HM, Twu SJ, Chen KT & Lin CC, et al (2007). Life expectancy of patients with newly-diagnosed HIV infection in the era of highly active antiretroviral therapy. *QJM* 2007; 100:97-105.
- Gadallah MF, El-Shahawy MA, Campese VM, Todd JR & King JW (1996). Disparate prognosis of thrombotic microangiopathy in HIV-infected patients with and without AIDS. *Am J Nephrol* 1996; 16:446-450.
- Galvão L, Brites C, Atta ML, Atta A, Lima I & Gonzalez F et al (2007). Antiphospholipid antibodies in HIV-positive patients. *Clin Rheumatol* 2007; 26: 1825-1830.
- Gindea S, Schwartzman J, Herlitz LC, Rosenberg M, Abadi J & Putterman C (2010). Proliferative Glomerulonephritis in Lupus Patients with Human Immunodeficiency Virus Infection: A Difficult Clinical Challenge. *Semin Arthritis Rheum* 2010 Dec; 40(3):201-9.

- Grinspoon S & Carr A (2005). Cardiovascular risk and body-fat abnormalities in HIV-infected adults. *N Engl J Med* 2005; 352: 1721–1722.
- Gupta SK, Eustace JA, Winston JA, Boydstun II, Ahuja TS & Rodriguez RA et al (2005). Guidelines for the management of chronic kidney disease in HIV-infected patients: recommendations of the HIV Medicine Association of the Infectious Diseases Society of America. *Clin Infect Dis* 2005; 40: 1559–1585.
- Gutiérrez E, González E, Hernández E, Morales E, Martínez MA & Usera G, et al (2007). Factors that determine an incomplete recovery of renal function in macrohematuria-induced acute renal failure of IgA nephropathy. *Clin J Am Soc Nephrol* 2007; 2:51-57.
- Gutiérrez E, Morales E, Gutiérrez Martínez E, Manzanares MJ, Rosello G & Mérida E et al (2007). Glomerulopatías asociadas a la infección por VIH: Una perspectiva española. *Nefrología* 2007; 27: 439-447.
- Haas M, Kaul S & Eustace JA (2005). HIV-associated immune complex glomerulonephritis with «lupus-like» features: a clinicopathologic study of 14 cases. *Kidney Int* 2005 67:1381-1390.
- Hatsukari I, Singh P, Hitosugi N, Messmer D, Valderrama E & Teichberg et al (2007). DEC-205-mediated internalization of HIV-1 results in the establishment of silent infection in renal tubular cells. *J Am Soc Nephrol* 2007; 18(3):780-787.
- Herman ES & Klotman PE (2003). HIV-associated nephropathy: Epidemiology, pathogenesis and treatment. *Semin Nephrol* 2003; 23:200-208.
- Husebekk A, Permin H & Husby G (1986). Serum amyloid protein (SAA): an indicator of inflammation in AIDS and AIDS-related complex. *Scand J Infect Dis* 1986; 18:389-394.
- Joseph A, Wali RK & Weinman EJ (2000). Renal Amyloidosis in AIDS. *Ann Intern Med* 2000;133(1):75
- Kadan JS & Talal AH (2007). Changing treatment paradigms: hepatitis C virus in HIV-infected patients. *AIDS* 2007; 21:154-168.
- Kamar N, Rostaing L, Alric L (2006). Treatment of hepatitis C-virusrelated glomerulonephritis. *Kidney Int* 2006; 69:436-439.
- Kamin DS & Grinspoon SK (2005). Cardiovascular disease in HIV-positive patients. *AIDS* 2005; 19: 641–652.
- Kimmel PL, Phillips TM, Ferreira-Centeno A, Farkas-Szallasi T, Abraham AA, Garret CT (1992). Idiopathic IgA nephropathy in patients with human immunodeficiency virus infection. *N Engl J Med* 1992; 327:729-730.
- Kimmel PL, Ferreira-Centeno A, Farkas-Szallasi T, Abraham AA & Garret CT (1993). Viral DNA in microdissected renal biopsy tissue from HIV infected patients with nephrotic syndrome. *Kidney Int* 1993; 43:1347-1352.
- King NW, Hunt RD & Letvin NL (1993). Histopathologic changes in macaques with an acquired immunodeficiency syndrome (AIDS). *Am J Pathol* 1983; 113:382-388.
- Klotman PE (1999). HIV-associated nephropathy. *Kidney Int* 1999; 56:1161-1176.
- Lanjewar DN, Ansari MA, Shetty CR, Maheshwari MB & Jain P (1999). Renal lesions associated with AIDS -an autopsy study. *Indian J Pathol Microbiol* 1999; 42:63-68.
- Lu TC & Ross M (2005). HIV-associated nephropathy. *Mt Sinai J Med* 2005; 72(3):193-9.
- Lucas GM, Eustace JA, Sozio S, Mentari EK, Appiah KA & Moore RD (2004). Highly active antiretroviral therapy and the incidence of HIV-1-associated nephropathy: a 12-year cohort study. *AIDS* 2004; 18:541-546.

- Masia-Canuto M, Bernal-Morell E & Gutierrez-Rodero F (2006). Lipid alterations and cardiovascular risk associated with antiretroviral therapy. *Enferm Infecc Microbiol Clin* 2006; 24:637-48.
- Mazbar SA, Schoenfeld PY & Humphreys MH (1989). Renal involvement in patients infected with HIV: Experience at San Francisco General Hospital. *Kidney Int* 37:1358-1370, 1989.
- Mikulak J & Singhal PC (2010). HIV-1 and kidney cells: better understanding of viral interaction. *Proc Natl Acad Sci U S A* 2010; 107(9):4281-6.
- Mocroft A, Vella S, Benfield TL, Chiesi A, Miller V & Gargalianos, P, et al (1998). Changing patterns of mortality across Europe in patients infected with HIV-1. EuroSIDA Study Group. *Lancet* 1998; 352:1725-1730.
- Mocroft A, Kirk O, Gatell J, Reiss P, Gargalinos P & Zilmer K, et al (2007). Chronic renal failure among HIV-1-infected patients. *AIDS* 2007; 21:1119-1127.
- Morales E, Alegre R, Herrero JC, Morales JM, Ortuño T & Praga M (1997). Hepatitis-C-Virus associated cryoglobulinaemic membranoproliferative glomerulonephritis in patients infected by HIV. *Nephrol Dial Transplant* 1997; 12:1980-1984.
- Morales E, Martinez A, Sánchez-Ayuso J, Gutierrez E, Mateo S, Martínez MA, Herrero JC & Praga M (2002). Spontaneous improvement of the renal function in a patient with HIV-associated focal glomerulosclerosis. *Am J Nephrol* 2002; 22(4):369-71.
- Morales E, Rosello G, Hernández E, Gutierrez E, González E & Praga M (2007). Persistence of symptomatic cryoglobulinemia after disappearance of HCV-RNA in patients with cryoglobulinemic membranoproliferative glomerulonephritis treated with interferon and ribavirin. *J Am Soc Nephrol* 2007; 18:787A.
- Morales E, Gutierrez-Solis E, Gutierrez E, González R, Martínez MA & Praga M (2008). Malignant hypertension in HIV-associated glomerulonephritis. *Nephrol Dial Transplant* 2008; 23(12):3901-7.
- Nochy D, Glotz D, Dosquet P, Pruna A, Guettier C & Weiss L et al (1993). Renal disease associated with HIV infection: A multicentric study of 60 patients from Paris Hospitals. *Nephrol Dial Transplant* 1993; 8:11-19.
- Panel de expertos del Grupo de Estudio de Sida (GESIDA) y del Plan Nacional sobre el Sida (PNS) (2010). Diagnosis, treatment and prevention of renal diseases in HIV infected patients. Recommendations of the Spanish AIDS Study Group/National AIDS Plan]. *Enferm Infecc Microbiol Clin* 2010; 28(8):520.e1-22.
- Peraldi MN, Maslo C, Akposso K, Mougenot B, Rondeau E & Sraer JD (1999). Acute renal failure in the course of HIV infection: A single-institution retrospective study of ninety-two patients and sixty renal biopsies. *Nephrol Dial Transplant* 1999; 14: 1578-1585.
- Polanco N, Gutiérrez E, Covarsí A, Ariza F, Carreño A & Vigil A, et al (2010). Grupo de Estudio de las Enfermedades Glomerulares de la Sociedad Española de Nefrología. Spontaneous remission of nephrotic syndrome in idiopathic membranous nephropathy. *J Am Soc Nephrol* 2010; 21(4):697-704.
- Praga M, Gutiérrez E, González E, Morales E & Hernández E (2003). Treatment of IgA nephropathy with ACE inhibitors: A randomized and controlled trial. *J Am Soc Nephrol* 2003; 14:1578-1583.
- Praga M (2008). Response to 'Tacrolimus in membranous nephropathy'. *Kidney Int* 2008; 74(6):824.

- Rao TK, Filippone FJ, Nicastri AD, Landesman SH, Frank E & Chen CK et al (1984). Associated focal and segmental glomerulosclerosis in the acquired immunodeficiency syndrome. *N Engl J Med* 310 (11):669-73, 1984.
- Rao TK, Friedman EA & Nicastri AD (1987). The types of renal disease in the acquired immunodeficiency syndrome. *N Engl J Med* 1987; 316:1062-1068.
- Röling J, Schmid H, Fischereder M, Draenert R & Goebel FD (2006). HIV-associated renal disease and highly active antiretroviral therapy-induced nephropathy. *Clin Infect Dis* 2006; 42:1488-1495.
- Scialla JJ, Atta MG & Fine DM (2007). Relapse of HIV-associated nephropathy after discontinuing highly active antiretroviral therapy. *AIDS* 2007; 21:263-264.
- Shahinian V, Rajaraman S, Borucki M, Grady J, Hollander M & Ahuja TS (2000). Prevalence of HIV-associated Nephropathy in Autopsies of HIV-Infected Patients. *Am J Kidney Dis* 35(5):884-888, 2000.
- Smith MC, Pawar R, Carey JT, Graham RC, Jacobs GH & Menon A, et al (1994). Effect of corticosteroid therapy on human-immunodeficiency virus-associated nephropathy. *Am J Med* 1994; 97:145-151.
- Stokes MB, Chawla H, Brody RI, Kumar A, Gertner R, Goldfarb DS & Gallo G (1997). Immune Complex Glomerulonephritis in Patients Coinfected With Human Immunodeficiency Virus and Hepatitis C Virus. *Am J Kidney Dis* 1997; Apr 29 (4):514-525.
- Szczech LA, Gange SJ, Van der Horst C, Bartlett JA, Young M & Cohen MH, et al (2002). Predictors of proteinuria and renal failure among women with HIV infection. *Kidney Int* 2002; 61: 195-202.
- Szczech LA, Gupta SK, Habash R, Guasch A, Kalayjian R & Appel R, et al (2004). The clinical epidemiology and course of the spectrum of renal diseases associated with HIV infection. *Kidney Int* 66:1145-1152, 2004.
- Wei A, Burns GC, Williams BA & Mohammed NB (2003). Long-term renal survival in HIV-associated nephropathy with angiotensin-converting enzyme inhibition. *Kidney Int* 2003; 64:1462-1471.
- Weiner NJ, Goodman JW & Kimmel PL (2003). The HIV-associated renal disease: Current insight into pathogenesis and treatment. *Kidney Int* 2003; 63:1618-1631.
- Williams DI, Williams DJ, Williams IG, Unwin RJ, Griffiths MH & Miller RF (1998). Presentation, pathology and outcome of HIV associated renal disease in a specialist centre for HIV/ AIDS. *Sex Transm Inf* 1998; 74:179-184.
- Winston JA, Burns GC & Klotman PE (1998). The human immunodeficiency virus (HIV) epidemic and HIV-associated nephropathy. *Semin Nephrol* 1998; 18:373-377.
- Wyatt CM, Winston JA, Malvestutto CD, Fishbein DA, Barash I & Cohen AJ, et al (2007). Chronic kidney disease in HIV infection: an urban epidemic. *AIDS* 2007; 21:2101-2110.



An Update on Glomerulopathies - Clinical and Treatment Aspects

Edited by Prof. Sharma Prabhakar

ISBN 978-953-307-673-7

Hard cover, 468 pages

Publisher InTech

Published online 02, November, 2011

Published in print edition November, 2011

An Update on Glomerulopathies - Clinical and Treatment Aspects is a systemic overview of recent advances in clinical aspects and therapeutic options in major syndromes of glomerular pathology. The book contains twenty four chapters divided conveniently into five sections. The first section deals with primary glomerulopathies, and the second section is devoted to glomerulopathies complicating infectious conditions. The third section deals with systemic autoimmune disorders and vasculitides which constitute major causes of glomerular disease and often renal failure. The fourth section includes chapters discussing the glomerular involvement in some major metabolic and systemic conditions. The final section has chapters which relate to some general aspects of glomerular diseases. This book will form an excellent reference tool for practicing and academic nephrology community.

How to reference

In order to correctly reference this scholarly work, feel free to copy and paste the following:

Enrique Morales, Elena Gutierrez-Solis, Eduardo Gutierrez and Manuel Praga (2011). Glomerular Pathology in Patients with HIV Infection, An Update on Glomerulopathies - Clinical and Treatment Aspects, Prof. Sharma Prabhakar (Ed.), ISBN: 978-953-307-673-7, InTech, Available from: <http://www.intechopen.com/books/an-update-on-glomerulopathies-clinical-and-treatment-aspects/glomerular-pathology-in-patients-with-hiv-infection>

INTECH
open science | open minds

InTech Europe

University Campus STeP Ri
Slavka Krautzeka 83/A
51000 Rijeka, Croatia
Phone: +385 (51) 770 447
Fax: +385 (51) 686 166
www.intechopen.com

InTech China

Unit 405, Office Block, Hotel Equatorial Shanghai
No.65, Yan An Road (West), Shanghai, 200040, China
中国上海市延安西路65号上海国际贵都大饭店办公楼405单元
Phone: +86-21-62489820
Fax: +86-21-62489821

© 2011 The Author(s). Licensee IntechOpen. This is an open access article distributed under the terms of the [Creative Commons Attribution 3.0 License](https://creativecommons.org/licenses/by/3.0/), which permits unrestricted use, distribution, and reproduction in any medium, provided the original work is properly cited.

IntechOpen

IntechOpen