

# We are IntechOpen, the world's leading publisher of Open Access books Built by scientists, for scientists

6,900

Open access books available

185,000

International authors and editors

200M

Downloads

Our authors are among the

154

Countries delivered to

TOP 1%

most cited scientists

12.2%

Contributors from top 500 universities



WEB OF SCIENCE™

Selection of our books indexed in the Book Citation Index  
in Web of Science™ Core Collection (BKCI)

Interested in publishing with us?  
Contact [book.department@intechopen.com](mailto:book.department@intechopen.com)

Numbers displayed above are based on latest data collected.  
For more information visit [www.intechopen.com](http://www.intechopen.com)



# Membranoproliferative Glomerulonephritis

Matthew C. Pickering<sup>1</sup> and Joshua M. Thurman<sup>2</sup>

<sup>1</sup>*Centre for Complement & Inflammation Research (CCIR), Imperial College, London,*

<sup>2</sup>*Division of Nephrology and Hypertension,  
University of Colorado Denver School of Medicine, Colorado*

<sup>1</sup>*United Kingdom*

<sup>2</sup>*United States of America*

## 1. Introduction

Membranoproliferative glomerulonephritis (MPGN) refers to glomerular pathology in which there is thickening of the capillary wall together with mesangial expansion. In this article we firstly review the pathological features of MPGN and discuss how advances in our understanding of the association between abnormalities in the regulation of complement and MPGN have revealed limitations in the historical pathological sub-division of MPGN. Secondly we review the clinical presentation of MPGN, its prognosis and therapeutic considerations.

## 2. Pathological features of MPGN

The name ‘membranoproliferative glomerulonephritis’ derives from the light microscopic glomerular histologic pattern. MPGN is synonymous with ‘mesangiocapillary glomerulonephritis’. The glomeruli are large and hypercellular. The hypercellularity is typically uniform though-out the glomeruli. Mesangial hypercellularity and expansion of the mesangial matrix can accentuate the appearance of discrete lobules within the glomeruli. In some cases the hypercellularity includes infiltration of the glomerulus with neutrophils [1] and in severe cases monocytes have been detected in the glomerulus [2]. The degree of leukocyte infiltration shows some correlation with the degree of C3d deposition, possibly due to the chemotactic effects of complement split products. In patients who have undergone two biopsies, for example, when the abundance of C3d decreased in the second biopsy fewer leukocytes were observed [3]. The basement membranes of glomerular capillaries in MPGN are thickened. A characteristic change in the capillary wall is splitting of the glomerular basement membrane (GBM), termed ‘tram-tracking’ or ‘double-contours’. This is due to the inter-position of the proliferated mesangial cells between the endothelial cells and the GBM. The inter-positioned mesangial cells generate new basement membrane material between the endothelial and mesangial cells, a process that is readily identifiable on electron microscopy.

Immunofluorescence studies of glomerular immunoglobulin and C3 in MPGN typically demonstrated granular deposition of these immune factors along the capillary loops. Staining for IgG is often fainter than it is for complement C3 and is sometimes absent [4 5].

An early study described three immunofluorescence patterns in MPGN: glomerular deposition of both immunoglobulin and C3 (66%), predominant deposition of C3 (21%) and deposition of C3 only (13%) [4]. The finding of immunoglobulin and complement is characteristic of immune complex-mediated glomerular inflammation and suggests that the MPGN is secondary to systemic disorders in which there is a propensity for immune-complexes to deposit or form within the kidney. The known conditions include diseases such as autoimmune disorders (e.g. systemic lupus erythematosus), malignancies and chronic infections. Hepatitis C, for example, is now recognized as a major cause of mixed cryoglobulinemia and MPGN [6]. Where a systemic disorder is identifiable the MPGN is referred to as secondary MPGN. In the absence of a clear aetiology MPGN is appropriately termed 'idiopathic or primary MPGN'.

The finding of glomerular complement deposition alone suggests activation of the complement system in the absence of immunoglobulin. This most commonly is a consequence of activation of the complement alternative pathway. Perhaps not surprisingly we now know that inherited and acquired disorders of the alternative pathway are associated with MPGN in which the histological features are characterized by predominant or isolated glomerular C3 deposition. The prototypic example of this is dense deposit disease. In the 1960s it was recognized that ribbon-like electron dense deposits are detectable within the lamina densa of the glomerular basement membrane in some patients with glomerulonephritis [7]. These intra-membranous deposits are the histological defining feature of dense deposit disease and this, rather than mesangial inter-positioning, produces thickening of the GBM. Dense deposit disease is rare: of children whose biopsies demonstrate an MPGN pattern by light microscopy, less than 20% have dense deposit disease [8 9]. Prominent C3 deposits are virtually always present in the glomeruli of patients with dense deposit disease. Granular C3 deposits are almost always present within the mesangium, although different patterns have also been observed [8], e.g. "ring-like" pattern of mesangial C3 staining. Glomerular C1q and/or immunoglobulins may be seen [10]. Our current understanding of dense deposit disease has recently been reviewed [11].

Since the MPGN in dense deposit disease was associated with distinct immunofluorescence studies (predominant or isolated glomerular C3 deposition) and GBM ultrastructural appearances (striking linear electron dense transformation of the lamina densa) an MPGN classification emerged which sub-divided MPGN initially into two groups: MPGN type I and MPGN type II. MPGN type I was characterized by immunoglobulin and C3 deposition and sub-endothelial electron dense GBM deposits [5]. MPGN type I contained both primary and secondary types. MPGN type II was used to describe dense deposit disease. Hence in the literature dense deposit disease was renamed MPGN type II. A further group, MPGN type III was subsequently added to describe MPGN where there were prominent subepithelial GBM deposits, possibly caused by immune-complexes similar to those found in membranous disease [12]. As in membranous disease, the deposits are associated with spikes along the GBM that can be detected by silver stain. A further MPGN type III variant was characterized by the presence of basement membrane ruptures on electron microscopy [13]. C3 deposition is invariably present in the glomeruli of patients with MPGN type III whilst immunoglobulin deposition is variable [13]. The traditional classification of MPGN is depicted in figure 1.

Subsequent studies have revealed limitations in this MPGN classification. Firstly, it is now recognized that patients with the dense deposit disease may present with many different patterns of glomerular injury by light microscopy. These patterns, in addition to MPGN,

include mesangial proliferative and crescentic lesions [10]. In fact more than half of the dense deposit disease biopsies did not show MPGN. The emerging consensus is that dense deposit disease is a distinct pathologic entity and should not be thought of as an MPGN variant [10 14]. Secondly, we now know that defects in complement regulation are strongly associated with glomerular inflammation in which there is isolated glomerular C3 deposition irrespective of whether the glomerular lesion is MPGN. We discuss the intimate association between complement and MPGN next.

MEMBRANOPROLIFERATIVE GLOMERULONEPHRITIS			
	type I	type II	type III
Immunofluorescence:	complement C3 and IgG	complement C3	complement C3 variable IgG
GBM deposits:	sub-endothelial	intra-membranous	sub-endothelial & sub-epithelial

Fig. 1. The traditional classification of MPGN. Dense deposit disease was renamed MPGN type II in this classification. Immunofluorescence refers to glomerular staining for complement C3 and IgG. GBM – glomerular basement membrane.

3. Complement and MPGN

The complement system is an integral component of immunity. Its principal role is concerned with host defence against pathogens and it forms an important component of innate immunity. Complement also acts as natural adjuvant enhancing the B cell response to antigen and more recent data implicates an important role for complement in T cell responses [15]. To understand the relationship between MPGN and complement it is important to understand how complement is activated. Binding of antibody to antigen forms an immune complex and immune complexes are the triggers of the complement classical pathway. In immune-complex associated MPGN the classical pathway is activated and contributes to glomerular inflammation. The complement alternative pathway is continuously activated i.e. requires no specific activating trigger. Unlike the classical pathway, the alternative pathway is antibody-independent and, through this pathway, the key effector molecules of the pathway (C3 and C5) can be deposited on surfaces in the absence of immunoglobulin. The key negative regulator of the alternative pathway is an abundant plasma protein called complement factor H (CFH). Early investigators studying MPGN hypothesized that MPGN lesions in which complement components such as C3 were present in the absence of immunoglobulin, were mediated by alternative pathway activation. We now know that both inherited and acquired causes of alternative pathway regulation are associated with this type of MPGN. Dense deposit disease, in which

glomerular C3 deposition is typically seen with little or no immunoglobulin, is associated with genetic and acquired factors that enhance alternative pathway activation (reviewed in [11]). C3 nephritic factor was associated with dense deposit disease decades ago [14] and the 'factor' is now known to be an immunoglobulin which targets an enzyme complex within the alternative pathway. This autoantibody stabilizes the enzyme complex and enhances alternative pathway activation. Hence C3 nephritic factor is associated with over-activation of the alternative pathway. Consequently, through consumption, plasma C3 levels are typically low in individuals with C3 nephritic factor. Genetic factors include genetic deficiency of the alternative pathway regulatory protein, CFH (reviewed in [16]) and 'gain of function' mutations in the alternative pathway activation protein, complement C3 [17]. Genetic deficiency of CFH in pigs and gene-targeted CFH-deficient mice also results in spontaneous MPGN [18–19]. Acquired dysregulation of the alternative pathway due to neutralizing autoantibodies against CFH [20] has also been described. Recently, an autoantibody to factor B, an activation protein within the alternative pathway, has also been associated with MPGN [21]. In summary factors that increase alternative pathway activation have been associated with MPGN in which there is glomerular C3 with little or no immunoglobulin. It is clearly important to distinguish MPGN driven by these factors from MPGN associated with systemic immune complex disease or MPGN due to other aetiologies. Consequently, there has been much discussion on how to develop our current classification of MPGN.

#### **4. C3 glomerulopathy – moving away from the traditional classification of MPGN**

In order to identify individuals with inherited or acquired defects in complement regulation we proposed a classification called C3 glomerulopathy (Figure 2) [22]. C3 glomerulopathy defines glomerular pathology characterized by isolated or predominant glomerular C3 deposition in the absence of immunoglobulin irrespective of both the glomerular light microscopic appearances and the ultrastructural appearance of the GBM [22]. Whilst many patients with isolated glomerular C3 deposition and complement abnormalities develop MPGN some do not [23–24]. For example, Servais and colleagues described 19 cases of primary glomerulonephritis cases with isolated deposition of C3 in the absence of morphological GBM changes of dense deposit disease [24]. Thirteen cases had an MPGN pattern by light microscopy whilst the remaining 6 did not [24]. They used the term 'C3 glomerulonephritis'. Recently a familial C3 glomerulopathy associated with a mutation in a complement protein called complement factor H-related protein 5 (CFHR5) was characterised [23]. Affected individuals have renal biopsies consistent with C3 glomerulonephritis. Biopsies show mesangial C3 deposition and variable degrees of mesangial hypercellularity. Mesangial and sub-endothelial GBM electron dense deposits are typical and some develop MPGN. These patients were identified and specifically investigated for complement disorders because renal biopsies demonstrated glomerular C3 deposition in the absence of immunoglobulin. The discovery of CFHR5 nephropathy is fascinating and we direct the interested reader to [25]. The impetus to propose the term C3 glomerulopathy was to enable the rapid identification of patients with glomerular disease who ought to be investigated for complement abnormalities and who may benefit from complement modulating therapeutic strategies. The relationship between C3 glomerulopathy and MPGN is discussed in detail in reference [26].



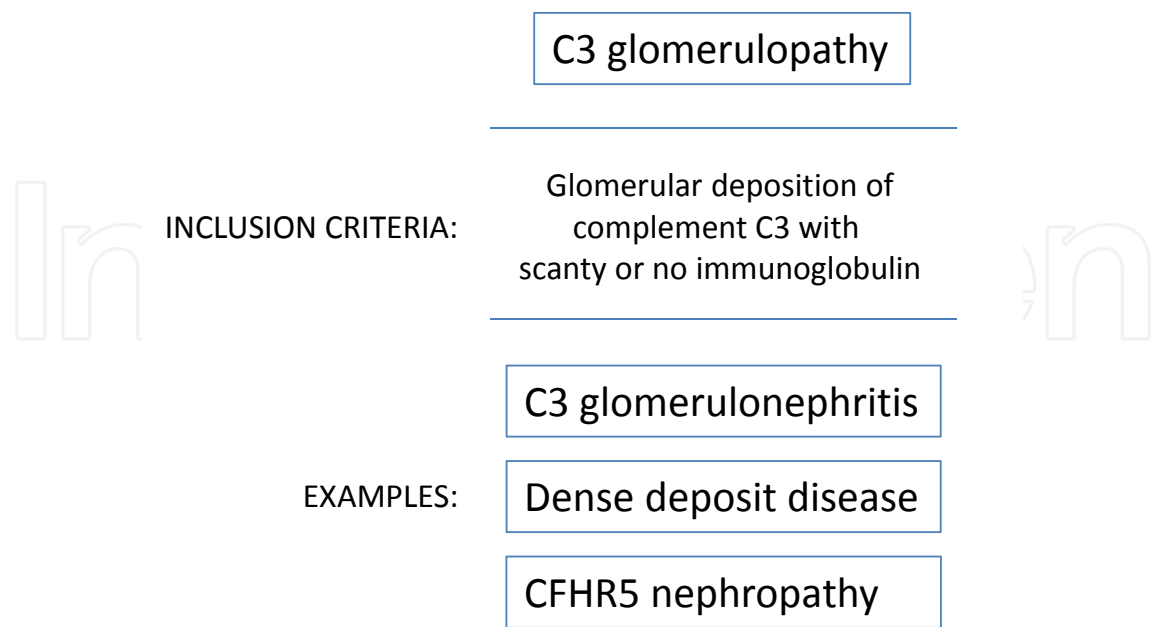


Fig. 2. Definition and examples of C3 glomerulopathy

In summary the traditional MPGN classification has become outdated due to advances in our understanding of complement-mediated glomerular inflammation and our knowledge of the histopathological spectrum of dense deposit disease. Nevertheless, in reviewing historical studies the use of the traditional MPGN sub-groups is unavoidable. In the next sections we have used the traditional sub-groups acknowledging that the reader will now be aware of the limitations of this classification. The recent descriptions of C3 glomerulonephritis and CFHR5 nephropathy are discussed separately.

5. Clinical features of MPGN

MPGN commonly presents with the nephritic syndrome (microscopic hematuria, non-nephrotic proteinuria, and renal insufficiency). However, up to one third of the patients present with relatively preserved renal function and the nephrotic syndrome [27]. The spectrum of clinical findings is generally the same for all of the subgroups considered in this review, but some differences exist and are discussed under individual headings below.

MPGN type I

MPGN type I may be more common in children than in adults [28]. It typically presents as a renal limited disease, although many patients have hypertension at the time of diagnosis [29]. Hypertension may be less common in children [29], particularly when the disease is detected early through screening of asymptomatic individuals. The majority of patients have microscopic hematuria, and some have macroscopic haematuria [29]. Cameron reported that 75% of their patients with MPGN type I had normal C3 levels at the time of disease onset [29]. In an analysis of 9 patients with MPGN type I, however, Ooi and colleagues reported depressed C3 levels for all of the patients on at least one occasion [30]. Approximately 30% of patients have a C3 nephritic factor [29 30]. C4 levels were low for some of the patients.

### **MPGN type II/Dense deposit disease**

Dense deposit disease usually presents in children between the ages of 5 and 15 [14], although a recent series included more patients diagnosed in adulthood than in childhood (12). There appears to be a slight female to male preponderance [31]. The clinical presentation is similar to that of MPGN type I. MPGN type II usually presents with the nephritic syndrome [28], but proteinuria is usually present and is in the nephrotic range in approximately 50% of patients [31]. Interestingly, the renal disease is often preceded by an infection [31]. More than 80% of patients with dense deposit disease have hypocomplementemia at some point [29], and 100% of children with the disease had depressed C3 levels in the report of Nasr *et al.* [31]. Approximately 80% of patients with dense deposit disease have detectable C3 nephritic factor [32]. As described above, dense deposit disease is strongly associated with defects in regulation of the alternative pathway of complement. This underlying defect probably explains the association of dense deposit disease with acquired partial lipodystrophy [33] and with retinal drusen (deposits within Bruch's membrane of the retina) [34]. In acquired partial lipodystrophy, uncontrolled complement activation causes the loss of subcutaneous fat. The drusen resemble those seen in patients with age related macular degeneration and presumably also form as a result of defective complement regulation. However, only one patient with each of these co-morbidities was described in a recent report of 32 patients with dense deposit disease [31].

### **MPGN type III**

MPGN type III usually presents with similar clinical findings to those seen in MPGN type I. The proportion of patients with hypocomplementaemia was comparable to that of MPGN type I [35].

### **C3 glomerulonephritis**

C3 glomerulonephritis is a recently described entity so the full spectrum of its clinical manifestations is not yet known. Servais *et al.* reported a series of 19 patients [24]. Men and women were represented nearly equally, and the patients ranged in age from 7 years old to 70. Sethi *et al.* recently reported three more cases of C3 glomerulopathy [36], all of whom were adult males (aged 38-73). Approximately 30% of the patients in the two reports had a creatinine clearance below 60 ml/min. Most of the patients had proteinuria (eight of the 22 patients described had nephrotic range proteinuria) and 15 patients had hematuria [24 36]. A comprehensive evaluation of the complement system was performed in both reports. Nine of the 22 total patients had depressed C3 levels. Six patients in the first series had C3 nephritic factor, and one of the patients reported by Sethi *et al.* had C3 nephritic factor. Mutations in complement regulatory proteins were identified in six of the patients reported by Servais *et al.* [24]. The three patients reported by Sethi *et al.* all carried the Tyr402His allele of CFH which has been identified as a risk allele for dense deposit disease [36].

### **CFHR5 nephropathy**

CFHR5 nephropathy is a familial form of C3 glomerulopathy that has to date only been described among individuals with Cypriot ancestry. It was characterized only recently [23 25]. Affected individuals all carry a mutation in CFHR5 and to date only heterozygous affected individuals have been identified. The biological role of CFHR5 is unknown although there is evidence that it interacts with complement deposited within the glomeruli in many different glomerular pathologies [37 38]. The mutation in CFHR5 nephropathy is an

internal duplication in exons 2 and 3 of the *CFHR5* gene. This results in a secreted abnormally large CFHR5 protein. The clinical course of CFHR5 nephropathy has been described in a comprehensive review of 91 patients from 16 pedigrees [39]. Affected patients have continuous microscopic haematuria and often develop macroscopic haematuria during periods of infection. Hypertension, proteinuria and end-stage renal failure are more common in men. In this report of affected individuals aged over 50 years, 80% of affected men developed chronic renal failure whilst 21% of affected women developed chronic renal failure [39]. The condition recurs in the transplanted kidney [40].

## 6. Prognostic considerations in MPGN

As highlighted in the above discussion, many of the patients who were previously identified simply as having MPGN are now recognized as having distinct disease processes. Consequently, older data regarding the prognosis of MPGN may have combined patients who would now be categorized differently. For example, early studies of MPGN may well have included patients with dense deposit disease due to defective complement regulation or patients with secondary MPGN caused by hepatitis C associated cryoglobulinemia.

### MPGN type I

Studies of patients with MPGN type I have reported fairly wide variation in the long-term prognosis of the disease. The 10-year renal survival for children has been reported to be 60-80% [41-42]. The patients included in these studies were treated with corticosteroids and other immunosuppression. The prognosis may be improved by early detection, such as that afforded by screening of school children [43]. This improvement could be due to lead-time bias, however. Adverse prognostic features include nephrotic syndrome [32-44], an elevated creatinine at presentation or within the first year, and structural injury on the renal biopsy [44].

### MPGN type II/Dense deposit disease

The prognosis of dense deposit disease may be worse than that for MPGN type I [8-9-29], although the small numbers of patients with each disease make it difficult to control for other variables. Spontaneous remissions of dense deposit disease are rare, and approximately 50% of patients will reach end-stage renal disease within 10 years [29]. Of the 27 patients in the report by Nasr *et al.* for whom follow-up was known, 25.9% had a complete response to therapy. There was no response in the remaining patients and 25.9% progressed to end-stage renal disease (duration of follow-up 2 months to 24 years) [31]. Age and the serum creatinine at biopsy were predictive of progression to end-stage renal disease. Only 7.1% of the adults had a complete response to therapy. Although uncontrolled complement activation is believed to be pathogenic in this disease, perturbations in C3 levels do not appear to correlate with clinical outcomes [29-31]. Recurrence in renal allografts is common [31-45].

### C3 glomerulonephritis

During the period of follow-up (ranging from 0.4 - 34 years) in the series reported by Servais *et al.* [24], most of the patients had a decline in renal function. Three patients reached end stage renal disease, and another two patients had creatinine clearances below 15 mL/min. The patients described by Sethi *et al.* did not show a decline in renal function during the short period of follow-up (6 months to 3 years) [36].



### **CFHR5 nephropathy**

As mentioned above the course of this condition is more severe in males. In affected individuals aged over 50 years the incidence of end-stage renal failure was 78% in men and 22% in women [39].

## **7. Therapeutic approaches to MPGN**

Given the distinct mechanisms of glomerular injury between immune-complex-mediated MPGN and the primary complement-mediated MPGN groups, evidence of treatment efficacy in one group may not be applicable to the other. However, for both groups non-specific therapies may be beneficial at slowing the progression of renal disease. The blood pressure should be rigorously controlled, and ACE inhibitors or angiotensin receptor blockers are probably agents of choice [46]. Complications of the nephrotic syndrome, such as hyperlipidemia, should be treated.

### **MPGN type I**

As this is a disease of immune-complex deposition, there is a rationale for treating this disease with immunosuppression. Unfortunately, there is not conclusive evidence that any of the common treatments are effective. Perhaps the best study to date was a randomized controlled trial of alternate day prednisone that included 41 children with MPGN type I [47]. The patients had high-grade proteinuria or renal impairment, and renal survival was better in the group that received steroids. Although this difference did not reach significance ( $P = 0.07$ ), the authors concluded that this was due to the small number of patients. Other uncontrolled studies further support the finding that long-term treatment with corticosteroids may be effective at inducing disease remission [9 48 49]. One of these studies included patients with diffuse lesions on their biopsies, but who were detected early through school-based screening [49]. These patients were treated with alternate day steroids, and all of the patients but one was treated for at least four years. Of 19 patients evaluated, four patients had persistent mild proteinuria but only one patient had a disease relapse (successfully treated with a second course of steroids). Other case series have not shown improved outcomes in patients who received steroids. In one such study, however, the authors determined that patients who received steroids were more likely to have had the nephrotic syndrome [44]. They concluded, therefore, that steroids may, in fact, have been beneficial. After analyzing the available data, Levin concluded that corticosteroids are indicated for children with nephrotic syndrome or with renal insufficiency [50], but the optimal criteria by which patients should be stratified for treatment are still under debate [44].

Similarly, some studies have suggested a benefit of treatment with anti-platelet agents [51 52]. A randomized, controlled trial of aspirin and dipyridamole, for example, indicated that treatment with these agents was effective at preserving renal function [51]. However, a long-term follow-up study that examined renal survival in these patients from the time of diagnosis (not from the start of treatment) did not see a sustained benefit [53]. Another randomized trial of patients demonstrated that aspirin plus dipyridamole was effective at reducing proteinuria at 36 months [54]. The serum creatinines in both groups were unchanged, however, so the effect of this treatment on the progression of renal disease remains uncertain.

Several case series and case reports have described patients treated with other immunosuppressive agents, such as cyclophosphamide or calcineurin inhibitors [29 44 55 56].

The patients treated with these agents are probably selected because they have concerning prognostic factors. Thus, it is difficult to determine the efficacy of these agents. Case reports have also described patients with steroid-resistant MPGN type I who responded to mycophenolate mofetil [57–58]. Certainly more data is needed, but given the relative safety of this medication it is a reasonable choice for patients who do not respond to steroids.

Approximately 30–60% of patients with MPGN type I who undergo renal transplantation have a recurrence of the disease, and disease recurrence adversely affects graft survival [59–60]. Although there are anecdotal reports that increasing immunosuppression may be beneficial, there is no well established therapy for recurrent disease [60].

### **MPGN type II/Dense deposit disease**

No clinical trials have been conducted in patients with dense deposit disease. Based upon what is known about the pathophysiology of the disease, the complement inhibitor eculizumab may be beneficial, and a clinical trial of this agent in dense deposit disease is currently underway. Eculizumab is a monoclonal antibody that blocks C5 activation and is currently licensed for treatment of anemia in paroxysmal nocturnal haemoglobinuria. It has been used successfully to treat atypical haemolytic uraemic syndrome and is likely to be licensed for this indication soon.

Plasma exchange may be effective at removing autoantibodies or dysfunctional complement components, while also enhancing CFH function through the infusion of plasma. Plasma exchange was reported to be effective in two affected sisters who had a factor H mutation and C3 nephritic factor [61].

The role of immunosuppressive agents in dense deposit disease is uncertain. Theoretically, immunosuppressive drugs may be beneficial in patients with evidence of autoantibodies, yet corticosteroids are not of clear benefit in this disease [14]. The patients reported by Nasr et al. included 18 patients who received immunosuppression [31]. The immunosuppression regimens included steroids in all patients. Two patients were also treated with mycophenolate mofetil and three received calcineurin inhibitors. A trend towards a benefit was seen in patients treated with immunosuppression but this did not reach significance. The greatest benefit was seen in those who received immunosuppression and a renin-angiotensin system inhibitor. Recently, a patient with fulminant disease was treated with high-dose corticosteroids, plasma exchange, and cyclophosphamide, and apparently responded to treatment [62]. This patient had a low C3 level, but did not have C3 nephritic factor or a complement mutation, so the mechanism by which the treatment benefited the patient is difficult to infer.

Based on existing data, the optimal treatment of patients with dense deposit disease is uncertain. A treatment algorithm incorporating complement testing and the above treatment options has been proposed [63]. Treatment may need to be initiated before genetic testing can be performed, however, and the presence or absence of C3 nephritic factor is probably not sufficiently accurate to guide therapy. Thus, the decision to use plasma exchange, standard immunosuppressive drugs, and/or eculizumab must ultimately be made based on the clinical severity of the disease.

Recurrence of MPGN type II is very common in patients who receive renal transplants, and some estimate the recurrence rate is 100% [60]. Graft survival at 5 years is approximately 50%, and the most common cause of graft loss is recurrent disease [64]. The impact of more aggressive (e.g. peri-transplant plasma exchange) or newer therapies (e.g. eculizumab) remain unknown.

### MPGN type III

Patients with MPGN type III do not seem to respond as well to corticosteroids as do those with type I disease as assessed by disease relapse and estimated GFR [35]. Thus, other than non-specific therapies there is scant evidence to guide the treatment of these patients.

### C3 glomerulonephritis

In the series by Servais et al., five of the patients were treated with steroids [24]. The authors reported that there was no clear effect of treatment on the disease outcomes. The patients reported by Sethi et al. were treated conservatively (no patients received immunosuppression), and no deterioration in renal function was seen during the period of follow-up [36]. Thus, based upon the available data there is little evidence to support immunosuppression in these patients.

### CFHR5 nephropathy

The optimum treatment for CFHR5 nephropathy presently remains unknown. There are theoretical grounds to investigate the utility of eculizumab in this condition e.g. during disease flares. The relationship between renal decline and infective episodes in CFHR5 nephropathy implies that immunosuppressive strategies may be a potentially harmful approach.

## 8. Conclusions

MPGN is a fascinating glomerular pathology. We have made significant progress in understanding the role of complement in MPGN. There are limitations to the traditional histological classification. Dense deposit disease should not be referred to as MPGN type II since many patients with dense deposit disease do not have MPGN. C3 glomerulopathy is a new term which encompasses glomerular pathologies in which there is isolated or predominant deposition of glomerular C3. C3 glomerulopathy includes dense deposit disease and C3 glomerulonephritis. The most recent addition is CFHR5 nephropathy. Individuals with C3 glomerulopathy should be investigated for complement dysregulation and represent logical patient populations in which to explore the efficacy of complement modulating therapies.

## 9. References

- [1] Jones DB. Membranoproliferative glomerulonephritis. One of many diseases? Arch Pathol Lab Med 1977; 101:457-461.
- [2] Laohapand T, Cattell V, Gabriel JR. Monocyte infiltration in human glomerulonephritis: alpha-1-antitrypsin as a marker for mononuclear phagocytes in renal biopsies. Clin Nephrol 1983; 19:309-316.
- [3] Soma J, Saito T, Sato H, et al. Intraglomerular immune cell infiltration and complement 3 deposits in membranoproliferative glomerulonephritis type I: a serial-biopsy study of 25 cases. Am J Kidney Dis 1994; 23:365-373.
- [4] Belgiojoso GB, Tarantino A, Bazzi C, et al. Immunofluorescence patterns in chronic membranoproliferative glomerulonephritis (MPGN). Clin Nephrol 1976; 6:303-310.
- [5] Zhou XJ, Silva FG. *Membranoproliferative Glomerulonephritis*. Philadelphia: Lippincott Williams & Wilkins, 2007.

- [6] Alpers CE, Smith KD. Cryoglobulinemia and renal disease. *Curr Opin Nephrol Hypertens* 2008; 17:243-249.
- [7] Berger J, Galle P. [Dense Deposits within the Basal Membranes of the Kidney. Optical and Electron Microscopic Study]. *Presse Med* 1963; 71:2351-2354.
- [8] Habib R, Gubler MC, Loirat C, *et al.* Dense deposit disease: a variant of membranoproliferative glomerulonephritis. *Kidney Int* 1975; 7:204-215.
- [9] Habib R, Kleinknecht C, Gubler MC, *et al.* Idiopathic membranoproliferative glomerulonephritis in children. Report of 105 cases. *Clin Nephrol* 1973; 1:194-214.
- [10] Walker PD, Ferrario F, Joh K, *et al.* Dense deposit disease is not a membranoproliferative glomerulonephritis. *Mod Pathol* 2007; 20:605-616.
- [11] Smith RJ, Harris CL, Pickering MC. Dense deposit disease. *Mol Immunol* 2011.
- [12] Burkholder PM, Marchand A, Krueger RP. Mixed membranous and proliferative glomerulonephritis. A correlative light, immunofluorescence, and electron microscopic study. *Lab Invest* 1970; 23:459-479.
- [13] Strife CF, McEnery PT, McAdams AJ, *et al.* Membranoproliferative glomerulonephritis with disruption of the glomerular basement membrane. *Clin Nephrol* 1977; 7:65-72.
- [14] Appel GB, Cook HT, Hageman G, *et al.* Membranoproliferative glomerulonephritis type II (dense deposit disease): an update. *J Am Soc Nephrol* 2005; 16:1392-1403.
- [15] Kemper C, Atkinson JP. T-cell regulation: with complements from innate immunity. *Nat Rev Immunol* 2007; 7:9-18.
- [16] Pickering MC, Cook HT. Translational mini-review series on complement factor H: renal diseases associated with complement factor H: novel insights from humans and animals. *Clin Exp Immunol* 2008; 151:210-230.
- [17] Martinez-Barricarte R, Heurich M, Valdes-Canedo F, *et al.* Human C3 mutation reveals a mechanism of dense deposit disease pathogenesis and provides insights into complement activation and regulation. *J Clin Invest* 2010; 120:3702-3712.
- [18] Hogasen K, Jansen JH, Mollnes TE, *et al.* Hereditary porcine membranoproliferative glomerulonephritis type II is caused by factor H deficiency. *J Clin Invest* 1995; 95:1054-1061.
- [19] Pickering MC, Cook HT, Warren J, *et al.* Uncontrolled C3 activation causes membranoproliferative glomerulonephritis in mice deficient in complement factor H. *Nat Genet* 2002; 31:424-428.
- [20] Meri S, Koistinen V, Miettinen A, *et al.* Activation of the alternative pathway of complement by monoclonal lambda light chains in membranoproliferative glomerulonephritis. *J Exp Med* 1992; 175:939-950.
- [21] Strobel S, Zimmering M, Papp K, *et al.* Anti-factor B autoantibody in dense deposit disease. *Mol Immunol* 2010; 47:1476-1483.
- [22] Fakhouri F, Fremeaux-Bacchi V, Noel LH, *et al.* C3 glomerulopathy: a new classification. *Nat Rev Nephrol* 2010; 6:494-499.
- [23] Gale DP, de Jorge EG, Cook HT, *et al.* Identification of a mutation in complement factor H-related protein 5 in patients of Cypriot origin with glomerulonephritis. *Lancet* 2010; 376:794-801.
- [24] Servais A, Fremeaux-Bacchi V, Lequintrec M, *et al.* Primary glomerulonephritis with isolated C3 deposits: a new entity which shares common genetic risk factors with haemolytic uraemic syndrome. *J Med Genet* 2007; 44:193-199.
- [25] Gale DP. The identification of CFHR5 nephropathy. *J R Soc Med* 2011; 104:186-190.



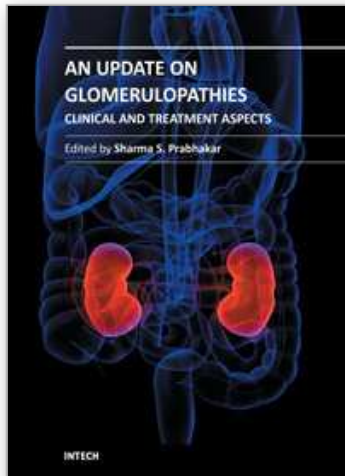
- [26] Pickering M, Cook HT. Complement and glomerular disease: new insights. *Curr Opin Nephrol Hypertens* 2011; 20:271-277.
- [27] Watson AR, Poucell S, Thorner P, *et al.* Membranoproliferative glomerulonephritis type I in children: correlation of clinical features with pathologic subtypes. *Am J Kidney Dis* 1984; 4:141-146.
- [28] Magil AB, Price JD, Bower G, *et al.* Membranoproliferative glomerulonephritis type 1: comparison of natural history in children and adults. *Clin Nephrol* 1979; 11:239-244.
- [29] Cameron JS, Turner DR, Heaton J, *et al.* Idiopathic mesangiocapillary glomerulonephritis. Comparison of types I and II in children and adults and long-term prognosis. *Am J Med* 1983; 74:175-192.
- [30] Ooi YM, Vallota EH, West CD. Classical complement pathway activation in membranoproliferative glomerulonephritis. *Kidney Int* 1976; 9:46-53.
- [31] Nasr SH, Valeri AM, Appel GB, *et al.* Dense deposit disease: clinicopathologic study of 32 pediatric and adult patients. *Clin J Am Soc Nephrol* 2009; 4:22-32.
- [32] Schwartz R, Rother U, Anders D, *et al.* Complement analysis in children with idiopathic membranoproliferative glomerulonephritis: a long-term follow-up. *Pediatr Allergy Immunol* 2001; 12:166-172.
- [33] Eisinger AJ, Shortland JR, Moorhead PJ. Renal disease in partial lipodystrophy. *Q J Med* 1972; 41:343-354.
- [34] Duvall-Young J, Short CD, Raines MF, *et al.* Fundus changes in mesangiocapillary glomerulonephritis type II: clinical and fluorescein angiographic findings. *Br J Ophthalmol* 1989; 73:900-906.
- [35] Braun MC, West CD, Strife CF. Differences between membranoproliferative glomerulonephritis types I and III in long-term response to an alternate-day prednisone regimen. *Am J Kidney Dis* 1999; 34:1022-1032.
- [36] Sethi S, Fervenza FC, Zhang Y, *et al.* Proliferative glomerulonephritis secondary to dysfunction of the alternative pathway of complement. *Clin J Am Soc Nephrol* 2011; 6:1009-1017.
- [37] McRae JL, Cowan PJ, Power DA, *et al.* Human factor H-related protein 5 (FHR-5). A new complement-associated protein. *J Biol Chem* 2001; 276:6747-6754.
- [38] McRae JL, Duthy TG, Griggs KM, *et al.* Human factor H-related protein 5 has cofactor activity, inhibits C3 convertase activity, binds heparin and C-reactive protein, and associates with lipoprotein. *J Immunol* 2005; 174:6250-6256.
- [39] Athanasiou Y, Voskarides K, Gale DP, *et al.* Familial C3 Glomerulopathy Associated with CFHR5 Mutations: Clinical Characteristics of 91 Patients in 16 Pedigrees. *Clin J Am Soc Nephrol* 2011; 6:1436-1446.
- [40] Vernon KA, Gale DP, de Jorge EG, *et al.* Recurrence of complement factor H-related protein 5 nephropathy in a renal transplant. *Am J Transplant* 2011; 11:152-155.
- [41] Arslan S, Saatci U, Ozen S, *et al.* Membranoproliferative glomerulonephritis in childhood: factors affecting prognosis. *Int Urol Nephrol* 1997; 29:711-716.
- [42] McEnery PT. Membranoproliferative glomerulonephritis: the Cincinnati experience--cumulative renal survival from 1957 to 1989. *J Pediatr* 1990; 116:S109-114.
- [43] Kawasaki Y, Suzuki J, Nozawa R, *et al.* Efficacy of school urinary screening for membranoproliferative glomerulonephritis type 1. *Arch Dis Child* 2002; 86:21-25.



- [44] Cansick JC, Lennon R, Cummins CL, *et al.* Prognosis, treatment and outcome of childhood mesangiocapillary (membranoproliferative) glomerulonephritis. *Nephrol Dial Transplant* 2004; 19:2769-2777.
- [45] Bennett WM, Fassett RG, Walker RG, *et al.* Mesangiocapillary glomerulonephritis type II (dense-deposit disease): clinical features of progressive disease. *Am J Kidney Dis* 1989; 13:469-476.
- [46] Kent DM, Jafar TH, Hayward RA, *et al.* Progression risk, urinary protein excretion, and treatment effects of angiotensin-converting enzyme inhibitors in nondiabetic kidney disease. *J Am Soc Nephrol* 2007; 18:1959-1965.
- [47] Tarshish P, Bernstein J, Tobin JN, *et al.* Treatment of mesangiocapillary glomerulonephritis with alternate-day prednisone--a report of the International Study of Kidney Disease in Children. *Pediatr Nephrol* 1992; 6:123-130.
- [48] Ford DM, Briscoe DM, Shanley PF, *et al.* Childhood membranoproliferative glomerulonephritis type I: limited steroid therapy. *Kidney Int* 1992; 41:1606-1612.
- [49] Yanagihara T, Hayakawa M, Yoshida J, *et al.* Long-term follow-up of diffuse membranoproliferative glomerulonephritis type I. *Pediatr Nephrol* 2005; 20:585-590.
- [50] Levin A. Management of membranoproliferative glomerulonephritis: evidence-based recommendations. *Kidney Int Suppl* 1999; 70:S41-46.
- [51] Donadio JV, Jr., Anderson CF, Mitchell JC, 3rd, *et al.* Membranoproliferative glomerulonephritis. A prospective clinical trial of platelet-inhibitor therapy. *N Engl J Med* 1984; 310:1421-1426.
- [52] Zimmerman SW, Moorthy AV, Dreher WH, *et al.* Prospective trial of warfarin and dipyridamole in patients with membranoproliferative glomerulonephritis. *Am J Med* 1983; 75:920-927.
- [53] Donadio JV, Jr., Offord KP. Reassessment of treatment results in membranoproliferative glomerulonephritis, with emphasis on life-table analysis. *Am J Kidney Dis* 1989; 14:445-451.
- [54] Zauner I, Bohler J, Braun N, *et al.* Effect of aspirin and dipyridamole on proteinuria in idiopathic membranoproliferative glomerulonephritis: a multicentre prospective clinical trial. Collaborative Glomerulonephritis Therapy Study Group (CGTS). *Nephrol Dial Transplant* 1994; 9:619-622.
- [55] Cattran DC, Cardella CJ, Roscoe JM, *et al.* Results of a controlled drug trial in membranoproliferative glomerulonephritis. *Kidney Int* 1985; 27:436-441.
- [56] Haddad M, Lau K, Butani L. Remission of membranoproliferative glomerulonephritis type I with the use of tacrolimus. *Pediatr Nephrol* 2007; 22:1787-1791.
- [57] De S, Al-Nabhani D, Thorner P, *et al.* Remission of resistant MPGN type I with mycophenolate mofetil and steroids. *Pediatr Nephrol* 2009; 24:597-600.
- [58] Ito S, Tsutsumi A, Inaba A, *et al.* Efficacy of mycophenolate mofetil for steroid and cyclosporine resistant membranoproliferative glomerulonephritis type I. *Pediatr Nephrol* 2009; 24:1593-1594.
- [59] Andresdottir MB, Assmann KJ, Hoitsma AJ, *et al.* Recurrence of type I membranoproliferative glomerulonephritis after renal transplantation: analysis of the incidence, risk factors, and impact on graft survival. *Transplantation* 1997; 63:1628-1633.

- [60] Ponticelli C, Glassock RJ. Posttransplant recurrence of primary glomerulonephritis. *Clin J Am Soc Nephrol* 2010; 5:2363-2372.
- [61] Licht C, Heinen S, Jozsi M, *et al.* Deletion of Lys224 in regulatory domain 4 of Factor H reveals a novel pathomechanism for dense deposit disease (MPGN II). *Kidney Int* 2006; 70:42-50.
- [62] Krmar RT, Holtback U, Linne T, *et al.* Acute renal failure in dense deposit disease: complete recovery after combination therapy with immunosuppressant and plasma exchange. *Clin Nephrol* 2011; 75 Suppl 1:4-10.
- [63] Smith RJ, Alexander J, Barlow PN, *et al.* New approaches to the treatment of dense deposit disease. *J Am Soc Nephrol* 2007; 18:2447-2456.
- [64] Braun MC, Stablein DM, Hamiwka LA, *et al.* Recurrence of membranoproliferative glomerulonephritis type II in renal allografts: The North American Pediatric Renal Transplant Cooperative Study experience. *J Am Soc Nephrol* 2005; 16:2225-2233.

IntechOpen



## **An Update on Glomerulopathies - Clinical and Treatment Aspects**

Edited by Prof. Sharma Prabhakar

ISBN 978-953-307-673-7

Hard cover, 468 pages

**Publisher** InTech

**Published online** 02, November, 2011

**Published in print edition** November, 2011

An Update on Glomerulopathies - Clinical and Treatment Aspects is a systemic overview of recent advances in clinical aspects and therapeutic options in major syndromes of glomerular pathology. The book contains twenty four chapters divided conveniently into five sections. The first section deals with primary glomerulopathies, and the second section is devoted to glomerulopathies complicating infectious conditions. The third section deals with systemic autoimmune disorders and vasculitides which constitute major causes of glomerular disease and often renal failure. The fourth section includes chapters discussing the glomerular involvement in some major metabolic and systemic conditions. The final section has chapters which relate to some general aspects of glomerular diseases. This book will form an excellent reference tool for practicing and academic nephrology community.

### **How to reference**

In order to correctly reference this scholarly work, feel free to copy and paste the following:

Matthew C. Pickering and Joshua M. Thurman (2011). Membranoproliferative Glomerulonephritis, An Update on Glomerulopathies - Clinical and Treatment Aspects, Prof. Sharma Prabhakar (Ed.), ISBN: 978-953-307-673-7, InTech, Available from: <http://www.intechopen.com/books/an-update-on-glomerulopathies-clinical-and-treatment-aspects/membranoproliferative-glomerulonephritis>

**INTech**  
open science | open minds

### **InTech Europe**

University Campus STeP Ri  
Slavka Krautzeka 83/A  
51000 Rijeka, Croatia  
Phone: +385 (51) 770 447  
Fax: +385 (51) 686 166  
[www.intechopen.com](http://www.intechopen.com)

### **InTech China**

Unit 405, Office Block, Hotel Equatorial Shanghai  
No.65, Yan An Road (West), Shanghai, 200040, China  
中国上海市延安西路65号上海国际贵都大饭店办公楼405单元  
Phone: +86-21-62489820  
Fax: +86-21-62489821

© 2011 The Author(s). Licensee IntechOpen. This is an open access article distributed under the terms of the [Creative Commons Attribution 3.0 License](https://creativecommons.org/licenses/by/3.0/), which permits unrestricted use, distribution, and reproduction in any medium, provided the original work is properly cited.

IntechOpen

IntechOpen