

We are IntechOpen, the world's leading publisher of Open Access books Built by scientists, for scientists

6,900

Open access books available

186,000

International authors and editors

200M

Downloads

Our authors are among the

154

Countries delivered to

TOP 1%

most cited scientists

12.2%

Contributors from top 500 universities



WEB OF SCIENCE™

Selection of our books indexed in the Book Citation Index
in Web of Science™ Core Collection (BKCI)

Interested in publishing with us?
Contact book.department@intechopen.com

Numbers displayed above are based on latest data collected.
For more information visit www.intechopen.com



Transanal Endoscopic Operation - A New Proposal¹

José Joaquim Ribeiro da Rocha² and Omar Féres²

¹*Division of Coloproctology of the Department of Surgery and Anatomy of Ribeirão Preto
Faculty of Medicine – University of São Paulo (FMRP-USP),*

²*Division of Coloproctology of the Department of Surgery and Anatomy, Ribeirão Preto
Faculty of Medicine – University of São Paulo (FMRP-USP),
Brazil*

1. Introduction

In general, local excision (LE) is one of the many techniques available for rectal cancer treatment. When this technique is used on a selective group of tumors, the survival rates are similar to those of patients submitted to abdominal surgery resections. In patients with high surgical risk, the LE shows smaller morbidity and mortality, with also less anorectal, urinary and sexual function alterations [1-3].

The most commonly used techniques for LE include the colonoscopy with polypectomy loops, conventional transanal excision (CTE), transanal endoscopic microsurgery (TEM) and the posterior access surgery [4-7].

For local rectal cancer surgical treatment, the TEM has been used since 1983 with positive results, low recurrence rates and less post-operation complications compared to conventional procedures. The posterior access surgery presents a high complication rate and offers no advantage for villous tumor resection that may be excised by transanal access techniques [8,9].

The pre-operative evaluation of candidates for a LE is of importance, since one must be certified that possible cure will be achieved by one of the proposed local surgical techniques. The rectal touch, rectoscopy, endorectal ultrasound and nuclear magnetic resonance are useful on the diagnosis and to determine the tumor stage on the pre- and post-operative times [10-14]. Selection criteria represent a relevant factor on the LE success. However, specific criteria for these tumors selection are still not universally accepted [2, 15-18]. Some parameters are indicated as requisites for determination of which tumors are theoretically adequate for transanal LE: smaller than 4 cm, mobile, restricted to only one quadrant, placed up to 10 cm of the anorectal line, well differentiated, with no lymphovascular or lymphonodal invasion, and endoscopic, tomographic and nuclear magnetic resonance evaluations that demonstrate that lesions are T1, T2 with no metastatic lesions [19].

The results of local treatment of rectal cancer are of difficult interpretation because the literature brings retrospective analysis of heterogeneous groups of patients, with different surgical indications and adjuvant therapies, while it lacks prospective homogeneous studies [1,20].

In our environment, the endoscopic transanal or surgical procedures for rectal tumors up to 15 cm of the anorectal line depend on the surgeon and/or endoscopist experience, on the equipment available and on the type of lesion. We use the CTE performed with anal retractors and basic surgical instruments for treatment of rectal lesions on the distal 1/3. The colonoscopy with polypectomy loops has allowed the resections of higher lesions, located on middle and superior rectum, on an appropriate manner.

The challenge comes when there is a benign, but of large volume and extension lesion, with or without carcinoma focuses, or on non invasive malignant neoplasms, located on middle or superior rectum, with no possibility for an endoscopic excision by colonoscopy and that can not be reached by CTE. In these circumstances, there is an indication for a transanal endoscopic surgery. In the absence of economic viability for the material acquisition, and surgical experience with complex methods like the TEM used by Buess [21,22] as also for the videoendoscopic transanal microsurgery (VETM) used by Swanstron [23] or the videoendoscopic transanal microsurgery without inflations [17,24-26] we have idealized, researched and executed a more simple technique, so called Transanal Endoscopic Operation (TEO).

In the present study, the main objective is to present the TEO as a method for local transanal excision of selected rectal lesions, and to present our clinical and surgical experience with this new method, comparing the results with those obtained with the well established endoscopic techniques available in the literature.

2. Casuistic and methods

We have designed a cylindrical rectoscope with 4 cm in diameter, with a 1 cm wide flap in one of the extremities, equidistantly perforated. In this flap, we attached a small (2 cm long) rectangular piece, of round contours, with a hole on the extremity and an aluminum screw on the base, used to fix it to the rectoscope flap (Fig. 1). This small piece is mobile and it is positioned in the way that its perforated extremity locates on the rectoscope lumen; in this position, the base screw is pressed and is used to hold the fiberlight cable, which will lighten the operative field (Fig. 2). The flap holes are used to fix the rectoscope with surgical thread to the anal border. In this way, with the rectoscope fixed to the anal border and the light correctly positioned, there is no need for an assistant surgeon for this task.



Fig. 1. Proctoscope presentation. Perforated flap and rectangular piece, of round contours, and the proctoscope guide

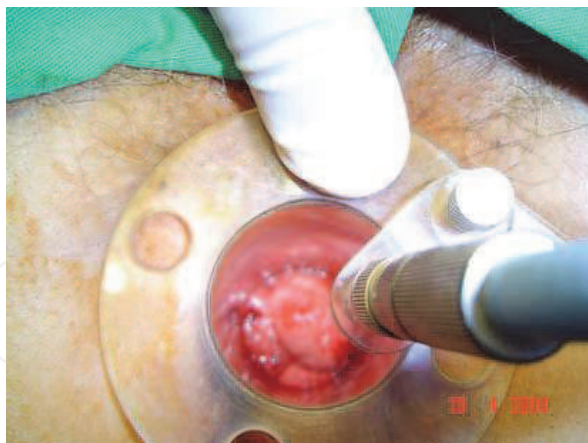


Fig. 2. Positioned proctoscope, together with the fixed fiberlight cable.

The equipment extremity which will be introduced has a beveled aspect and round borders (Fig 3). This format is very important for the essence of the procedure: since there is no inflations, this mechanical disposition allows the surgeon to position the rectoscope on the way that the longest part of this extremity holds the contra-lateral mucosa when the surgeon identifies the lesion, which will be now located on the center of the operative field.



Fig. 3. Distal proctoscope end, showing the beveled aspect and round borders.

It is also part of the equipment a guide which will be positioned inside the rectoscope on the moment of its anal insertion (Fig. 1-4). It is composed of an aluminum cable with a round tip, being its caliber obviously smaller than the rectoscope's one. On the tip of the guide there are two longitudinal ridges for air passage, avoiding the vacuum formation and the rectal mucosa aspiration during its removal from the rectoscope after its introduction.

Initially, only one 12 cm long rectoscope was built. After our experience with the equipment, another one, 20 cm long was built, once higher rectal lesions were also able to be removed with this method. Also, a smaller rectoscope (7 cm long) was built, which was ideal for excision of tumors located up to 5-6 cm from the anal border. Independently of the length, the rectoscopes contain all components described in this text.

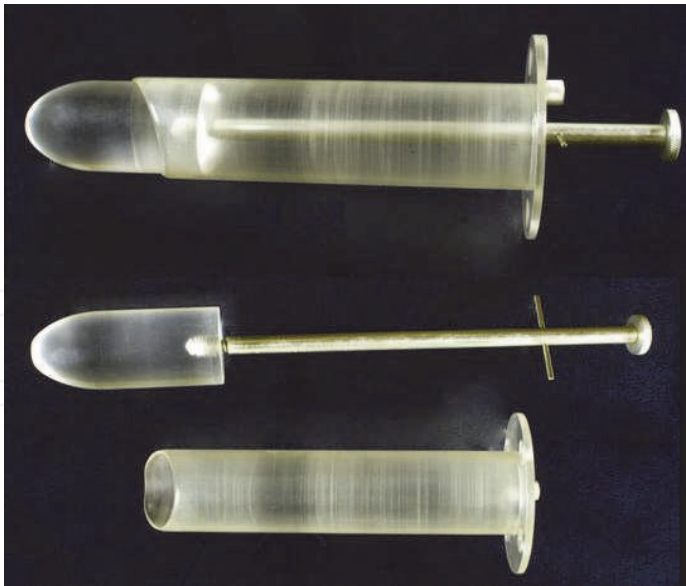

Fig. 4. Surgical proctoscopes (12 and 20 cm long) and respective guides.

Acrylic was chosen as the main equipment material, with small components in aluminum, for the following reasons: both these materials are easy to acquire, are of low costs, are easily manipulated by the staff who build the equipment in our facility and also because they are easy to be cleaned, disinfected and sterilized. More recently, a stainless steel rectoscope was built, more resistant and not transparent like the acrylic ones, with the advantage that the surgical field was lighter during its use (Fig. 5).




Fig. 5. Stainless steel rectoscopes

The accessories used for the TEO, together with the surgical rectoscope include a light source with a fiberlight cable (most of the times we used the light source from a videolaparoscopy equipment), an electrocautery with long pens and, when possible, also with thin tips to facilitate the lesion visualization, and forceps for holding and aspiration, used simultaneously. Other important components are: polypectomy loops, forceps for holding and presenting lesions (graspers), some of them from the videolaparoscopy equipment, long needle holders (conventional or from the videolaparoscopy equipment), long and thin aspiration tubes, syringes and suture threads.

2.1 Technical steps of the Transanal Endoscopic Operation (TEO)

Patients were prepared as for any other colorectal surgery: in the hospital, they receive clear liquid diet two days before the surgery, intestinal clearance with 10 % glycerin (retrograde preparation) or the oral use of osmotic laxatives (10 % manitol or sodium phosphate; anterograde preparation). Also, they are submitted to antibiotic therapy, beginning with i.v. metronidazole and ceftriaxona at the hospital and oral ciprofloxacin up to 7 days after surgery. All patients were regionally anaesthetized either by peridural (epidural) or spinal anesthesia, associated with i.v. sedation.

Operatory position was dependent on the rectal lesion location; posterior tumors were accessed through the litotomy position and anterior tumors were accessed through the "Jackknife" position.

After positioning the patient, antisepsis is done with topic PVP-I, surgical sheaths are placed, surgical tables and adequate surgical instruments are positioned, equipments such as light source, electrocautery and vacuum are checked and the anal dilation is carefully and manually performed, with topic lubricant, until we get permeability for two fingers (usually the index and the middle fingers). The anus and anal canal are lubricated again with xylocaine 2% jelly before the rectoscope introduction. Two or three Allis forceps holding out the sphincters muscles might help the guide and the rectoscope penetration.

With gentle movements, the complete equipment, guide and body, is completely introduced up to the flap (Fig. 6). The guide is removed and the light source is connected to its place next to the flap. With an adequate view of the rectal lumen, the endoscope is positioned the way that the best exposition and presentation of the lesion are achieved (Fig. 7). In this situation, the equipment is fixed with cotton thread to the anal border.

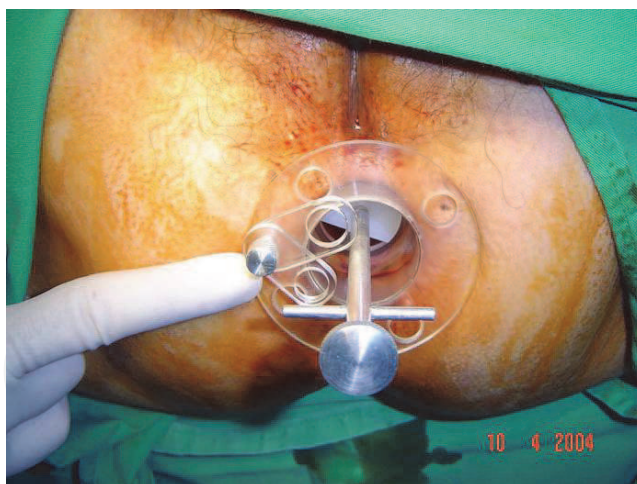


Fig. 6. Final aspect of the proctoscope and guide, after the correct introduction.

During the complete surgical procedure, saline irrigation and the electrocautery and vacuum are essential elements for the final result success. Observing the security limits (borders), adequate hemostasy and the resection deepness are also essential for a successful procedure.

After the lesion removal, which must be correctly oriented for the pathologist observation and diagnosis, a revision of the wound is performed. The last procedures of the TEO are saline and PVP-I irrigation, hemostasy and suture, before the rectoscope removal.

Vesical catheterization was performed only when there was post-operative urinary retention and only for patient relief. Patients were kept in the hospital until they could accept normal oral diet and present signs of normal intestinal function, usually for 24 to 48 hours after surgery.

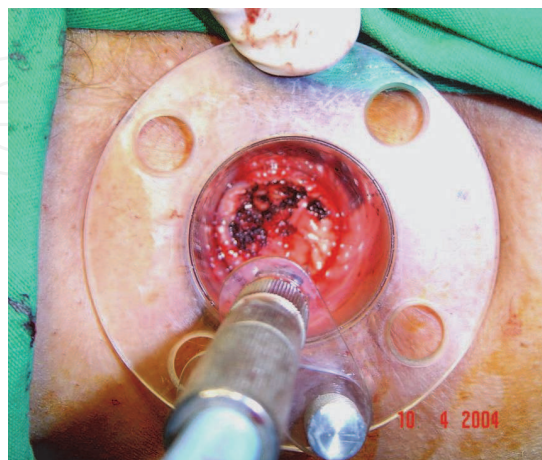


Fig. 7. Proctoscope surgically positioned and the correct presentation of the operatory field.

2.2 Evaluation of patients submitted to the Transanal Endoscopic Operation (TEO)

Eighty one patients submitted to the TEO, from August 2003 to February 2011 were included in the present study, being 36 patients from the Hospital São Paulo and 45 patients from the School of Medicine Hospital and Clinics, both in Ribeirão Preto City. The basic equipment and the surgeon was the same in all procedures.

A protocol with personal data, clinical history, previous history, physical, proctological and other exams, the indications for the TEO, performed procedures and clinical outcome was studied based on patients' hospital records. In this protocol, data on surgical time, lesion anal distance, hospitalization time, intra-and post-operative complications, follow up time, recurrence rates and posterior resections data were also studied.

Data obtained in this study was compared to data obtained by 39 different authors who used different techniques of TEO for transanal excision of rectal lesions. The metanalysis was used for the comparisons, a quantitative method whereby all data from all available studies of a determined subject are combined. Confidence intervals for proportions were obtained using the exact confidence interval for a proportion method [27]. Parameters analyzed by this method included the recurrence, complications and posterior resection rates. Recurrence rates were studied as total recurrence rate, adenoma recurrence rate and adenocarcinoma recurrence rate. For posterior resections, after the transanal excisions, the colorectal resection rates, so called rescue surgery, were quantified for all patients submitted to surgery and for patients with some kind of recurrence. Also, the rate for a new resection of local recurrence was evaluated.

Other data: lesion distance from the anorectal border, lesion size (on the widest diameter, in cm), operation time (in minutes), hospitalization time (in days), were described in scatter plot graphs, according to author and technique.

3. Results

3.1 Rectoscope idealized and built specifically for TEO

We consider successful the theoretical idea of building rectoscopes of 4 cm in diameter, with a fenestrated distal extremity and the proximal extremity with fixation and illumination supports. Because of the professional collaboration and support from our facility staff, associated with the financial support from the School of Medicine of Ribeirão Preto, there was no difficulty in projecting and building the ideal equipment for the TEO. In the time frame of 3 months, the ideal equipment was built and ready to use.

3.2 The Transanal Endoscopic Operation (TEO)

Eighty three patients were selected to be submitted to the TEO, with the described proctoscope. In two of these patients the TEO was not performed: one because of anal stenosis and the other because the lesion was more than 15 cm from the anal border, in an angulated area. The TEO, following the technical steps described previously, was successfully performed on the other 81 patients.

3.3 Evaluation of the patients submitted to the TEO

The table 1 shows the literature review of techniques used for local excision of rectal lesions, used for comparisons with the proposed TEO. Four studies were excluded from this analysis because there were not enough data for a comparative analysis. In this way, 35 different studies, being 26 of TEM, 4 of two or more techniques, 3 of VETM and 2 of CTE were compared. Because not all authors have cited all parameters compared in the present study, the scatter plots that illustrate the comparisons do not always present 35 points.

Number	Used techniques	Author(s)/year
1	CTE	Budhoo & Hancock, 2000
2	CTE	Aguilar, 2000
3	CTE-TEM- posterior access	Balani, 2000
4	CTE- posterior access	Graham, 1999
5	CTE-TEM	Morschell, 1998
6	TEM	Mentges, 1996
7	TEM	Mentges, 1996
8	TEM	Mentges, 1997
9	CTE-TEM	Stipa, 2005
10	TEM	Salm, 1994
11	TEM	Said, 1992
12	TEM	Steele, 1996
13	TEM	Lezoche, 1996

Number	Used techniques	Author(s)/year
14	TEM	Winde, 1998
15	TEM	Heintz, 1998
16	TEM	Doornebosch, 1998
17	TEM	Yamasaki, 1999
18	TEM	Ikeda, 2000
19	TEM	Lev-Chelouche, 2000
20	TEM	Arribas del Amo, 2000
21	TEM	Demartines, 2000
22	TEM	Ziprin, 2002
23	TEM	Farmer, 2002
24	TEM	Lloyd, 2002
25	TEM	Marks, 2003
26	TEM	Cocilovo, 2003
27	TEM	Lee, 2003
28	TEM	Neary, 2003
29	TEM	Kattri, 2004
30	TEM	Stipa, 2004
31	TEM	Meng, 2004
32	TEM	Palma, 2004
33	TEM	Endreseth, 2005
34	TEM	Duek, 2005
35	TEM	Rokke, 2005
36	VETM I	Swanstrom, 1997
37	VETM II	Nakagoe, 2003
38	VETM II	Araki, 2003
39	EMR	Hurlstone, 2005
40	TEO	Rocha, 2004

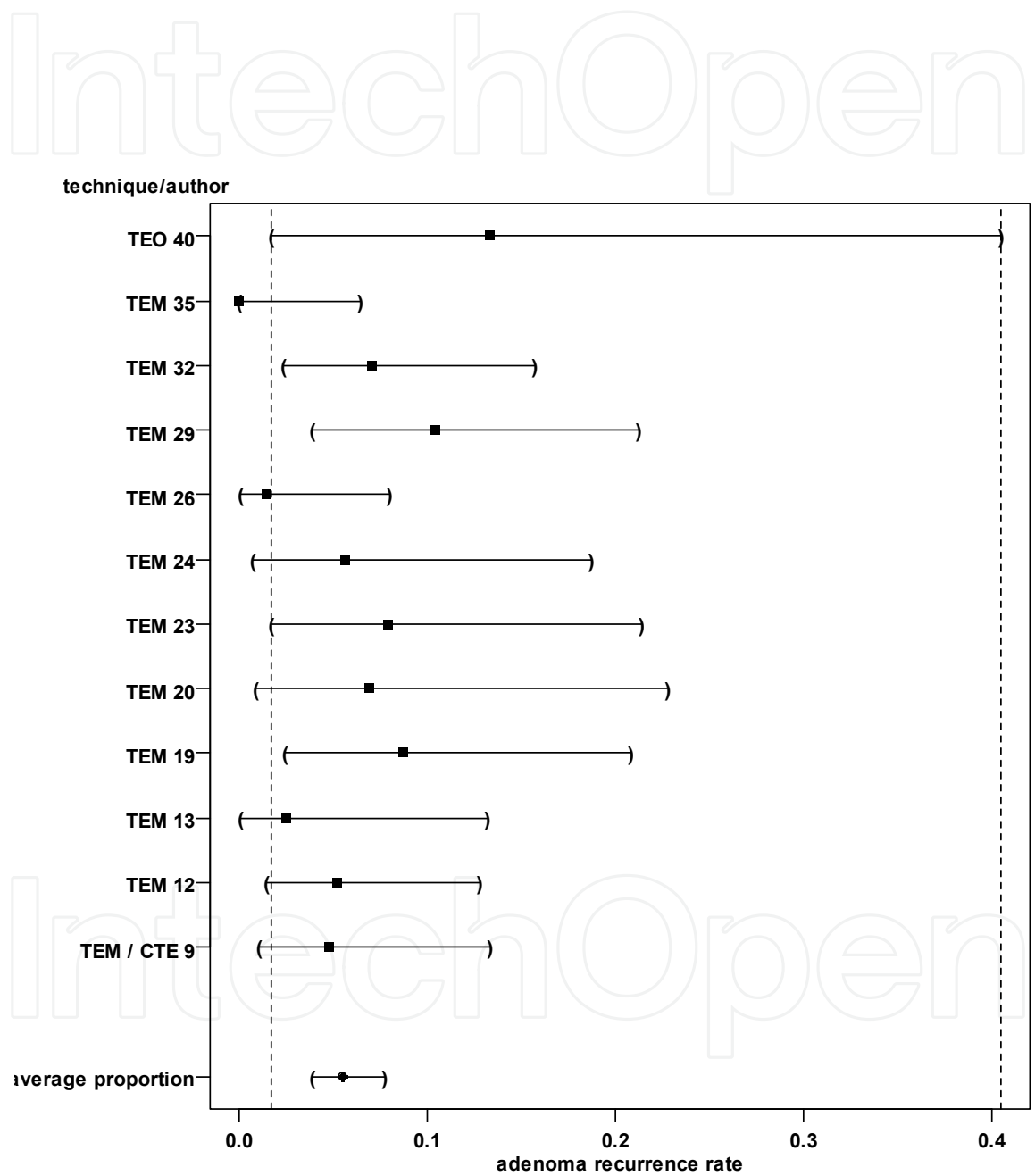
CTE: Conventional transanal excision
TEM: Transanal endoscopic microsurgery
VETM: Video endoscopic transanal microsurgery
EMR: Endoscopic mucosal resection
TEO: Transanal endoscopic operation

Table 1. Relation between most commonly used techniques and respective authors.

3.4 Recurrence rates evaluation (average proportions)

Adenoma recurrence rates

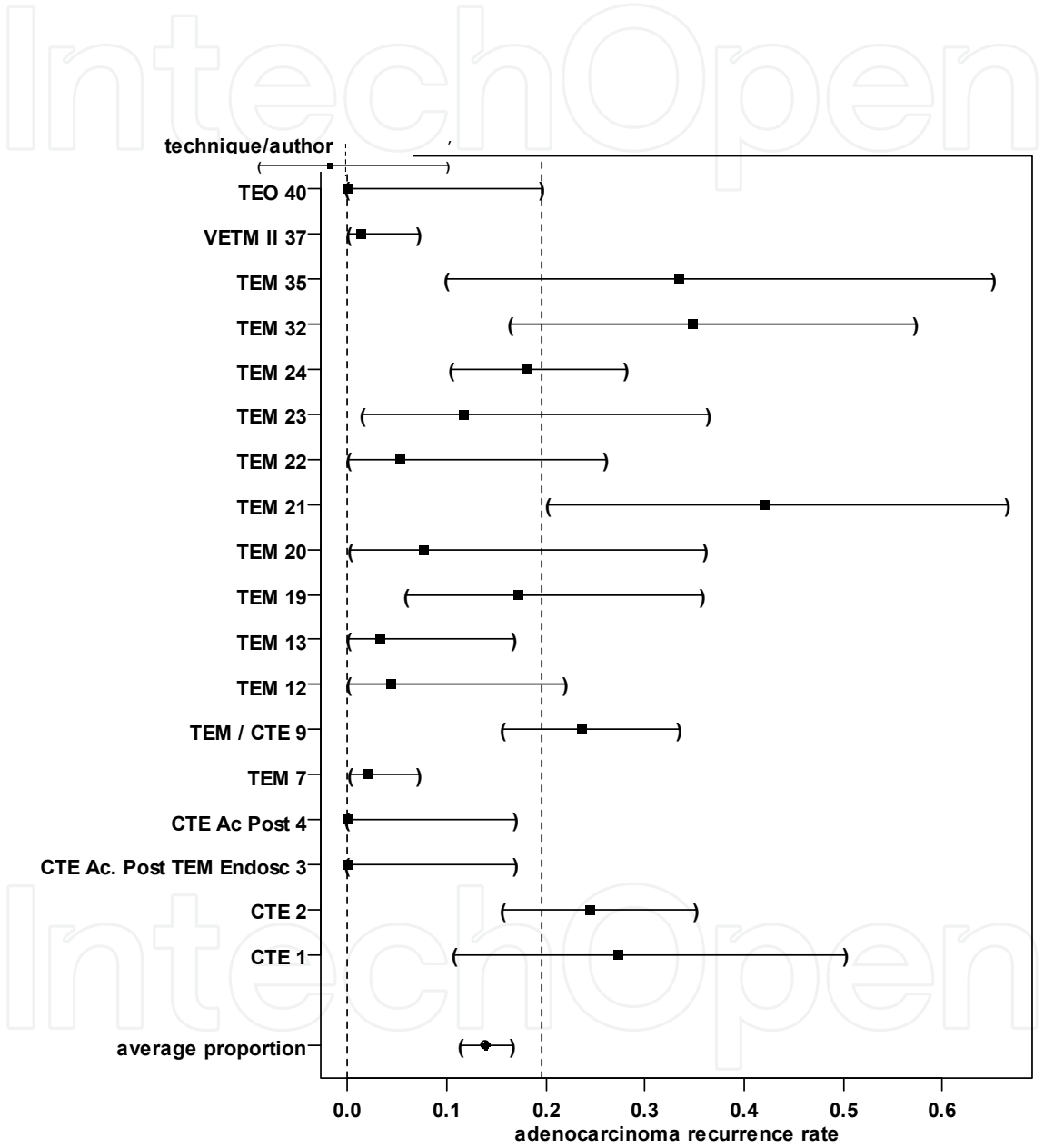
From 11 references compared, only one is out of the confidence interval for the TEO, showing a smaller recurrence rate for adenomas (Graph I).



Graph 1. Adenoma recurrence rates.

Adenocarcinoma recurrence rates

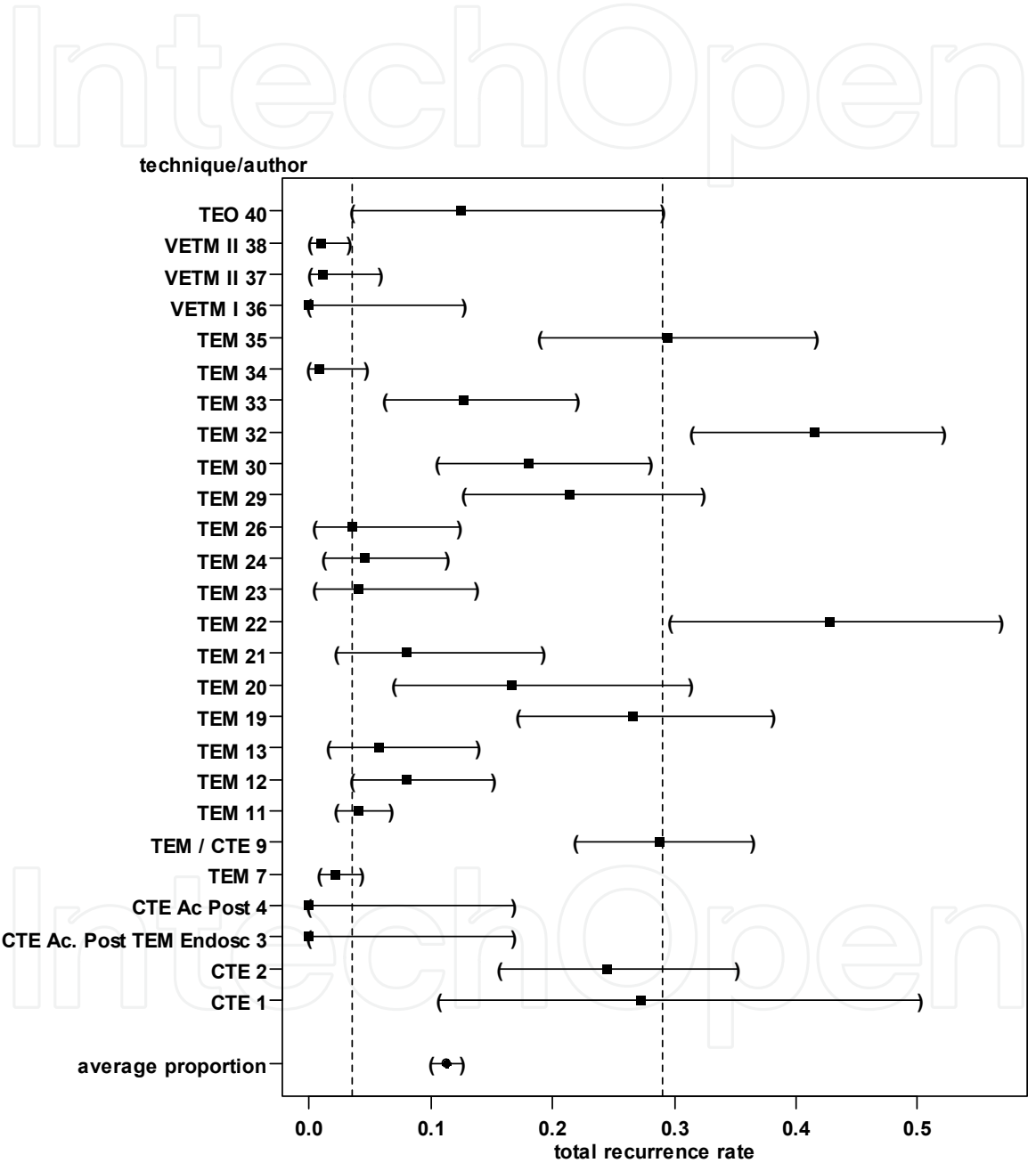
The TEO showed two adenocarcinoma recurrence and among 17 compared references, 6 present rates higher that the maximum confidence interval accepted (Graph II).



Graph 2. Adenocarcinoma recurrence rates

Total recurrence rates

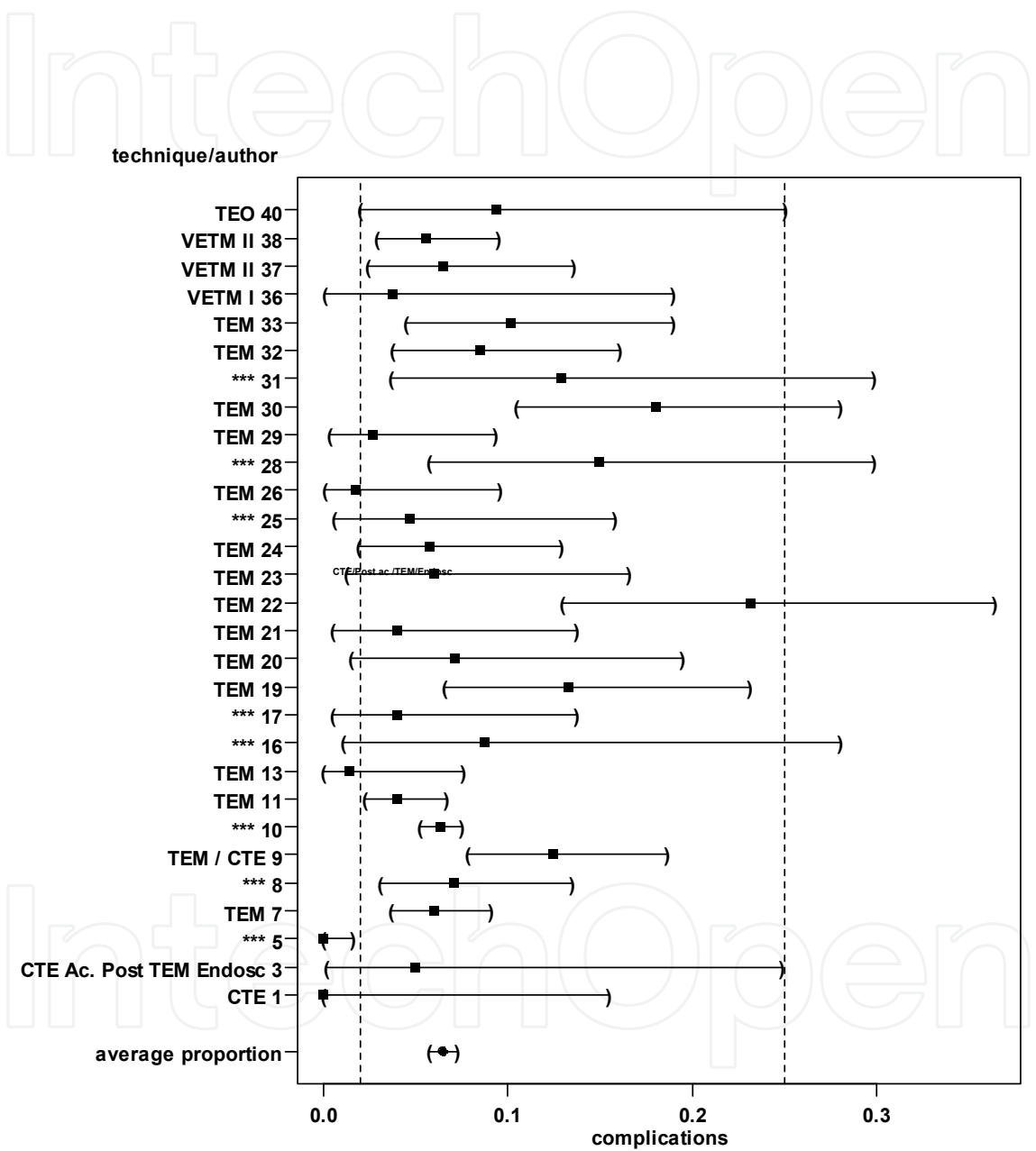
Twenty-five references were selected for this comparison with TEO. Seven of them presented smaller total recurrence rates, out of the TEO confidence interval while 3 presented higher rates. Most of them (15) are on the confidence intervals expected for the TEO (Graph III).



Graph 3. Total recurrence rates.

3.5 Complication rates evaluation (average proportions)

Only four in 28 references used for the analysis were out of the TEO confidence interval. Twenty-four of them present similar average proportions, and confidence intervals of the TEO (Graph IV).

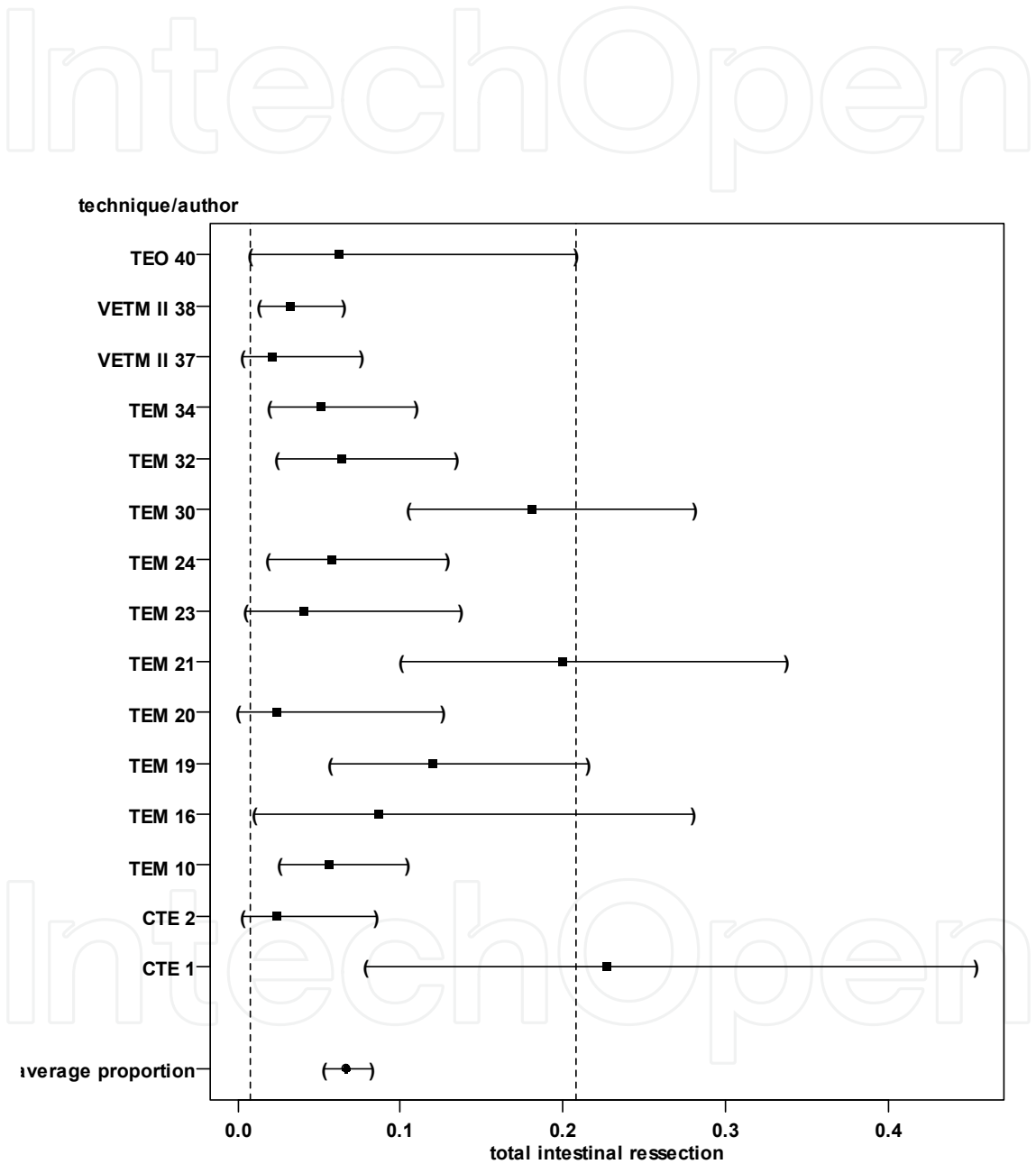


Graph 4. Complication rates.

3.6 Posterior colorectal resections rate evaluation (average proportions)

Colorectal resection rates in all patients

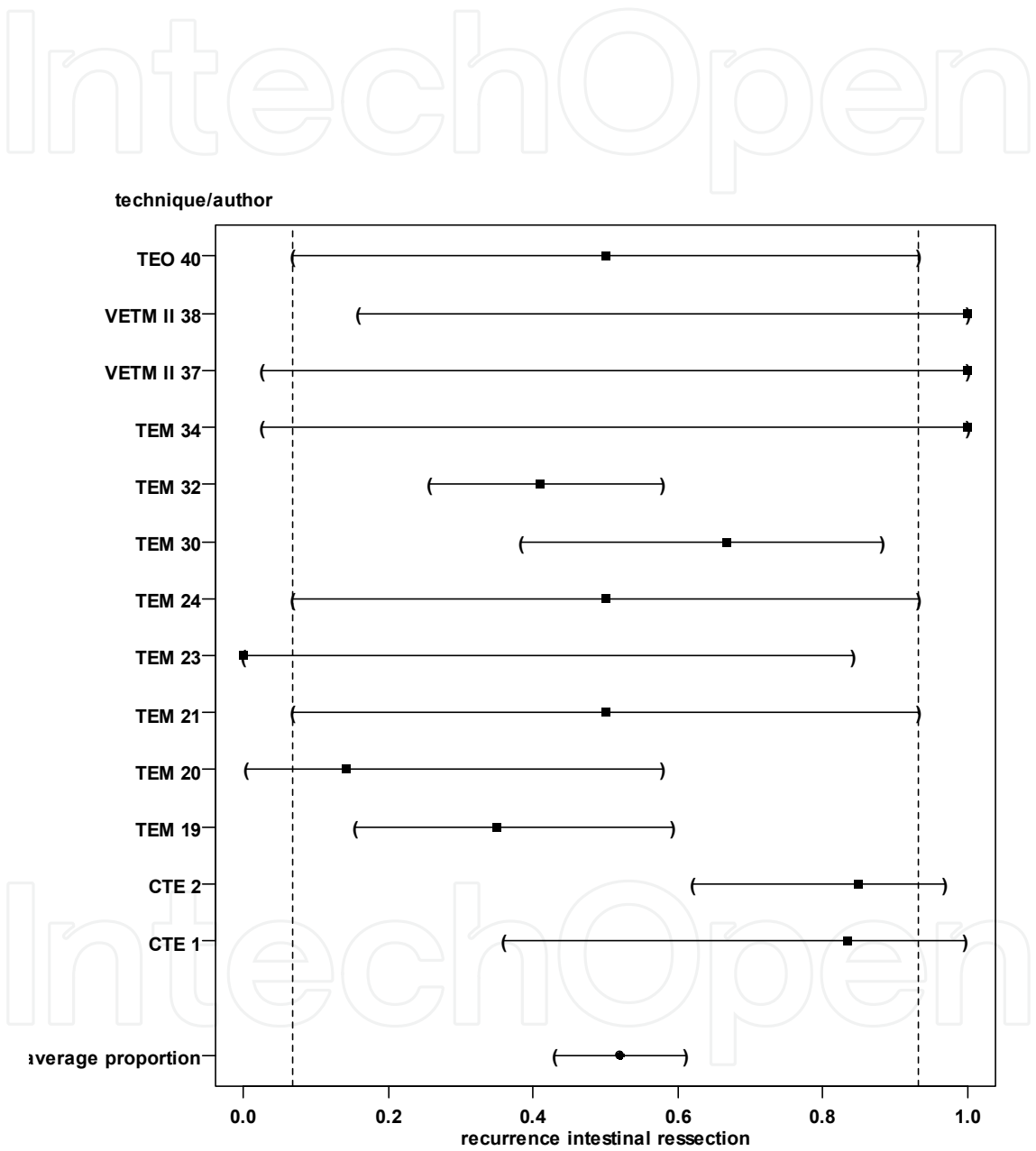
With the exception of one reference which is over the maximum confidence interval for the TEO, the other 13 evaluated show similar average proportions in the TEO confidence intervals. Average proportion of all references is 0.06 (Graph V).



Graph 5. Colorectal resection rates in all patients.

Recurrence colorectal resections rates

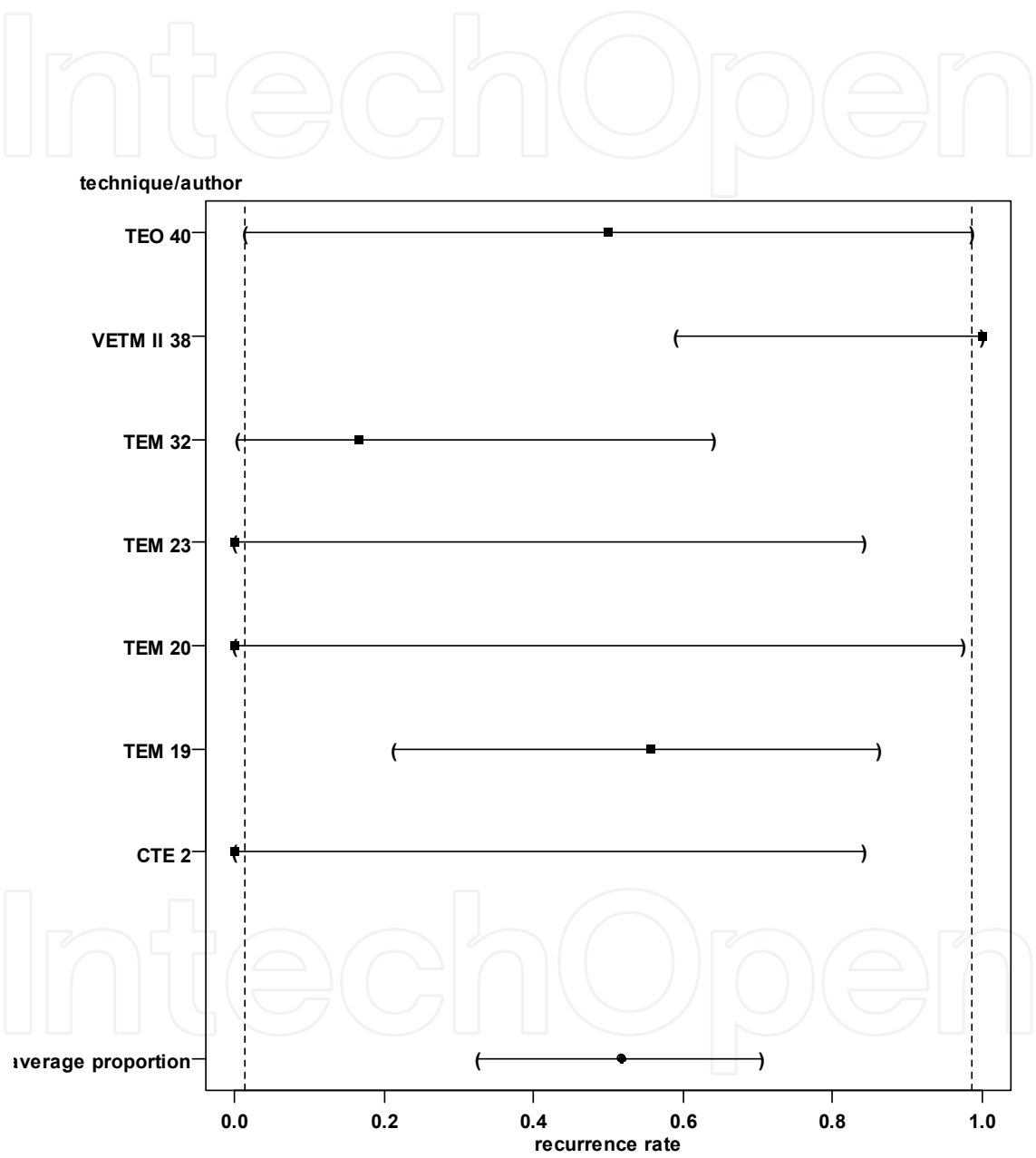
In this analysis, the average proportion of all cases is of 0.5. From the 12 evaluated references, only one showed a smaller rate than the minimum confidence interval for the TEO and other 3 showed average proportions higher than the maximum confidence interval (Graph VI).



Graph 6. Recurrence colorectal resections rates.

New resection of local recurrence rates

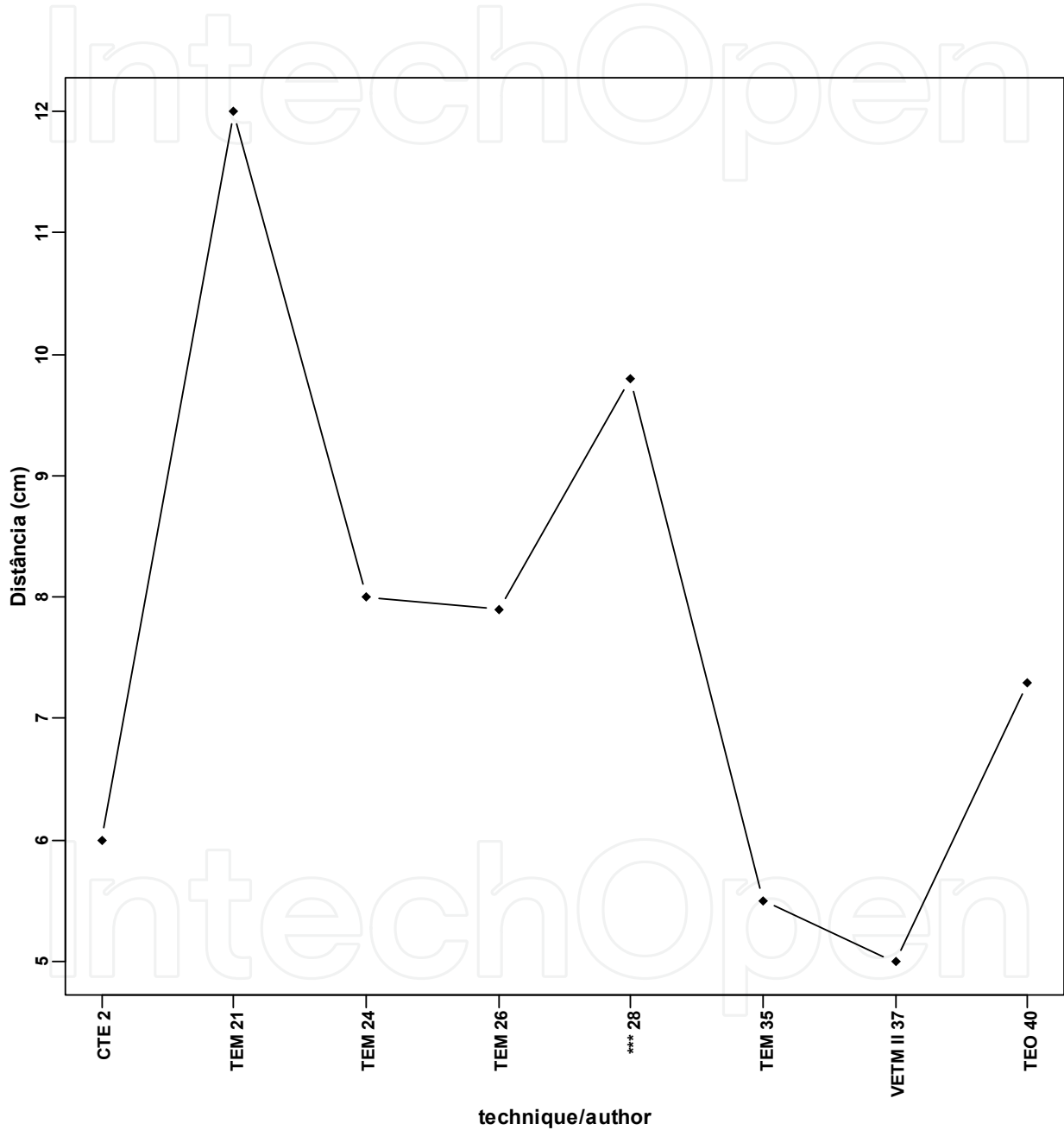
Only six references were available for this comparison. Half of them showed average proportions smaller than the TEO and only one showed a high value, larger than the maximum confidence interval of the TEO (Graph VII).



Graph 7. New resection of local recurrence rates.

3.7 Average distance from the anal border evaluation

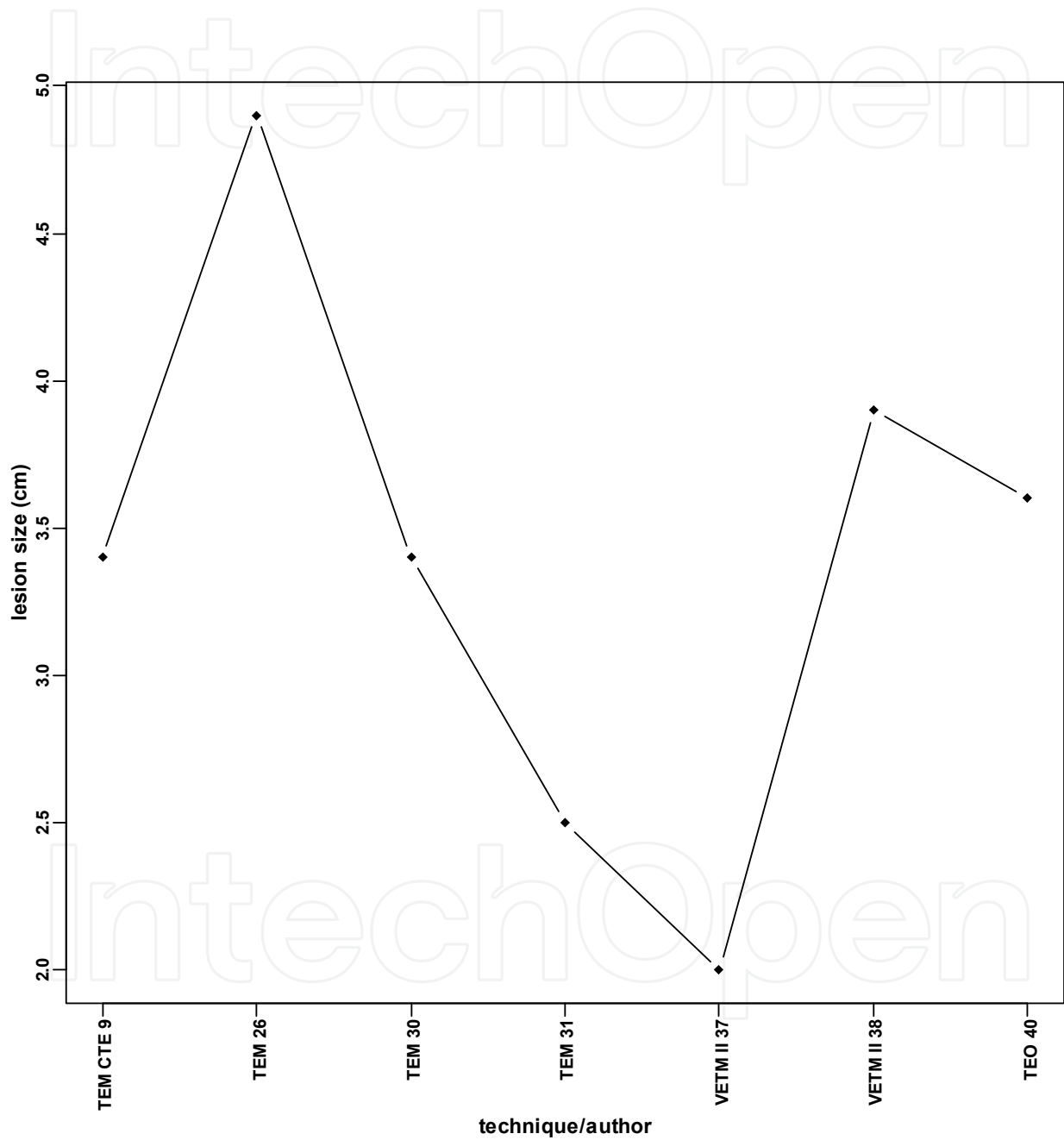
This data is presented on graph VIII. Seven references described these values, being the values between 12 and 5cm.The TEO values averaged 7.3cm.



Graph 8. Average distance from the anal border evaluation.

3.8 Average lesion size evaluation (wider diameter)

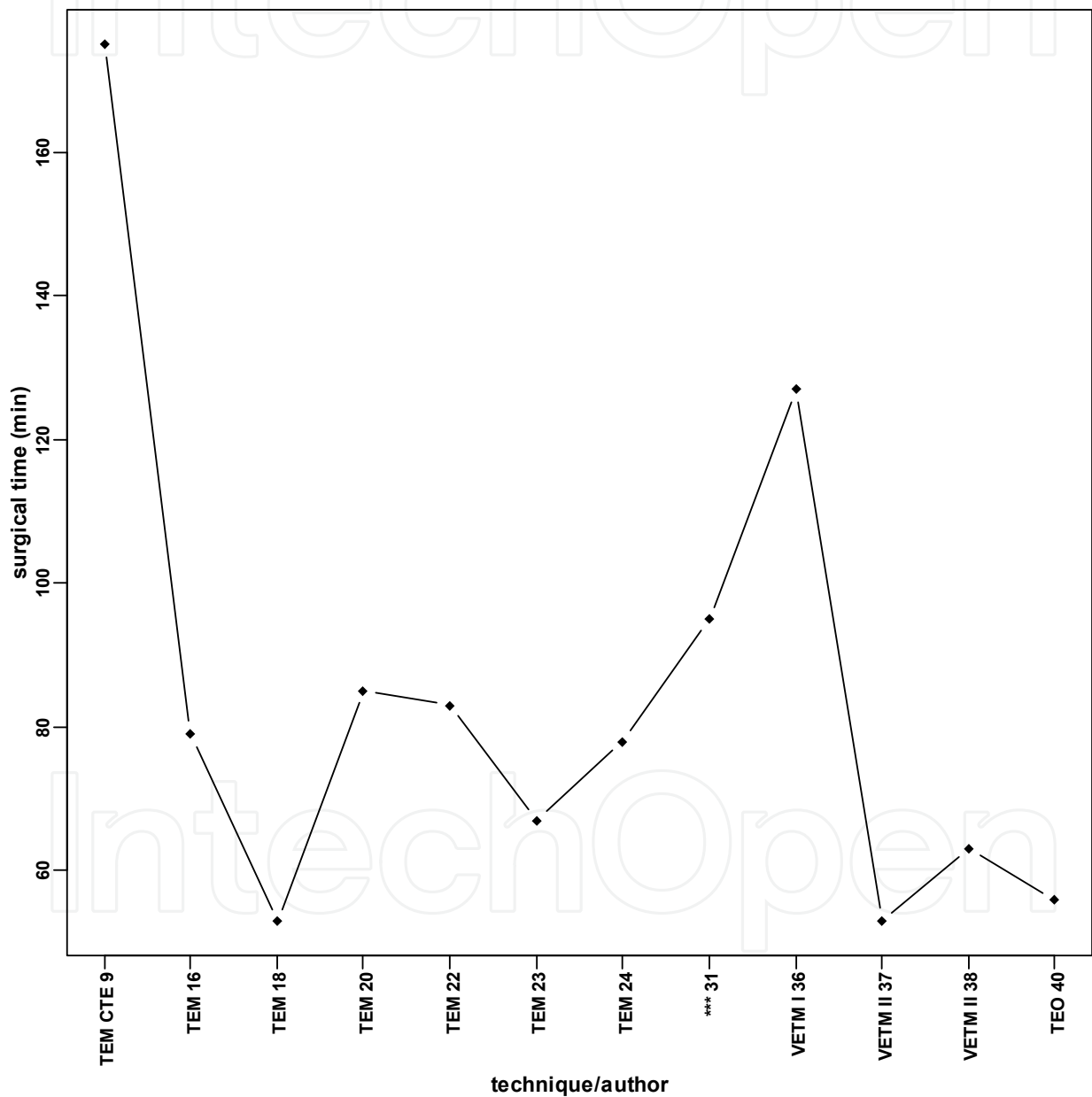
The average diameter of the excised lesions with TEO was 3.6 cm. Maximum size was 4.9 cm and minimum size was 2.0 cm in the literature compared (Graph IX).



Graph 9. Average lesion size evaluation (wider diameter).

3.9 Surgical time evaluation

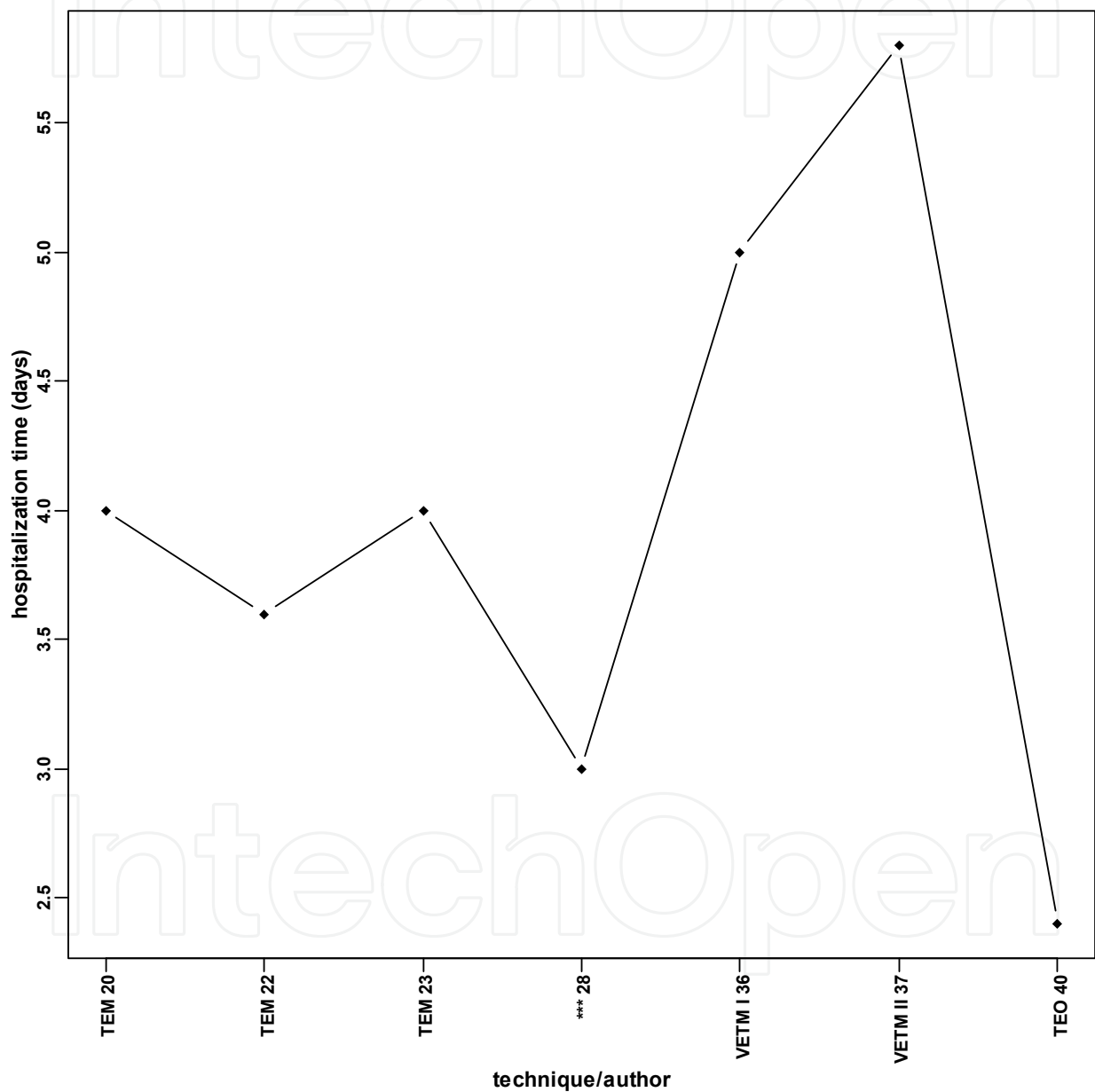
Eleven references were compared and the maximum average described was 175 minutes while the smaller average described was 53 minutes. The TEO average time was 56 minutes (Graph X).



Graph 10. Surgical time evaluation.

3.10 Average hospitalization time

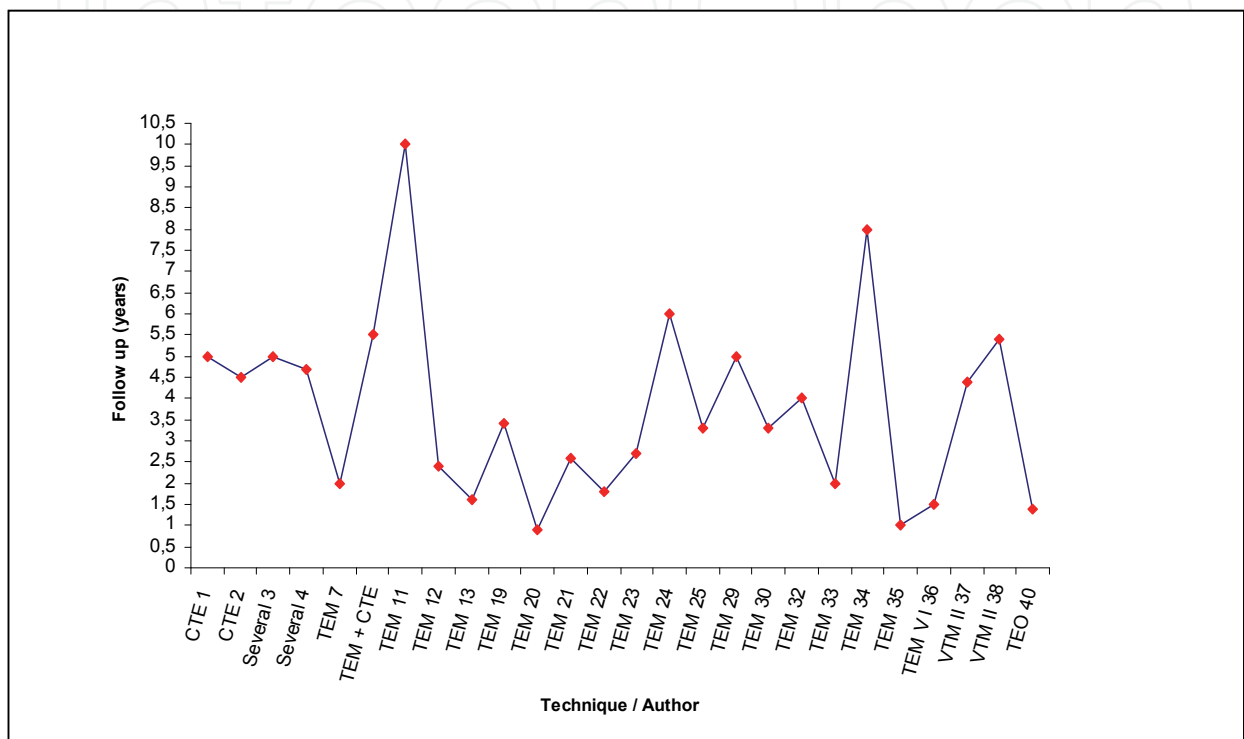
The smaller average presented in seven references was the TEO data of 2.4 days. The higher value was 5.8 days on average (Graph XI).



Graph 11. Average hospitalization time.

3.11 Follow up average time

The longest follow up period was 10 years. From the 26 references, 11 presented follow up times of 3 years or less our average varied from 2 months to 8 years (Graph XII).



Graph 12. Follow up average time.

4. Discussion

Local excision of rectal tumors is a well established procedure as a surgical method. It is a less invasive procedure that, according to its indication criteria, brings benefits in terms of rectal and canal anal functional preservation, morbid-mortality and costs [1,2]. Literature estimates reveal that 40 to 50 % of the primary rectal cancer will be presented without lymphonodal commitment (T1, T2, T3 - No) as soon as diagnosed [27,28] and that 15% of the patients considered cured show tumors limited to the rectal wall (T1 - T3 - No) [29]. Every year, more than 7000 patients with rectal cancer are potentially cured by local excision as the only therapeutic method [30]. Proctological exam (clinical and rectoscopy), the USER and MRI are important on the selection of patients to be submitted to transanal excision [3,7,13,14].

Classic and reasonable indications for rectal tumors local resection include T1, T2 mobile tumors, with adequate histological aspects (well or moderately differentiated, with no angiolymphatic invasion) [16-18].

Some references comparing transanal excision and radical resections demonstrated that low risk T1 lesions present similar survival and recurrence rates, with local excision, showing smaller hospitalization and surgical time, less analgesia and blood loss and less early and late morbidities. Data on T2 lesions are controversial [31-34]. Benign lesions are also included, especially the villous or tubulo-villous adenomas which resection was not possible by means of colonoscopy or conventional transanal excision.

We believe that, in diagnosing a rectal neoplasm lesion within or close to the transanal resection criteria, the complete resection is the logical conduct, which will allow a better histopathological evaluation than the regular biopsy.

It is not the tumor size or form but how deep it invades the wall and its malignant histological characteristics that will guide the final decision of a local excision. On the possibility of a complete lesion removal by local excision, this should be the first option. The decision for a large surgery depends on a good relation between the surgeon and the pathologist [35].

For the inferior or middle third rectal mobile tumors, technically accessible by the local excision, we suggest the excision to be done as "total biopsy", considering this method as the best one for their treatment. The "total biopsy" may constitute the definitive treatment for patients carefully selected.

On the presence of factors suggestive of bad prognosis, such as a deep lesion throughout the intestinal wall, incomplete surgical excision, presence of undifferentiated cells, venous or lymphatic invasion, and mucinous tumors, more aggressive and radical surgeries are indicated [36]. The final therapeutic decision must not be done before the complete examination of the tissue [9].

The advantage of having a tissue sample for the histopathological exam has been a stimulus for a complete local excision in selected patients. If we are sure that the cancer is not invasive, all efforts must be done in order to preserve the sphincter function.

In this way, the local excision of the complete lesion is the logical procedure, much better than just the biopsy because it allows: 1- the whole sample histopathological evaluation, 2- a chance for cure with a minimal invasive procedure, 3- on the necessity of a radical surgery, there was no prejudice for the patient, 4- the histopathological evaluation of this "total biopsy" will guide the further therapeutic proposal.

There are several procedures for local excision of rectal tumors. The conventional transanal excision (CTE), performed with anal retractors, is acceptable for lesions on the distal third of the rectum up to 4 cm in diameter. Posterior access, by means of transsacral or transsphincteric excisions do not offer advantages compared to the transanal techniques and have been less commonly used in the last decades [9].

Minimally invasive methods for rectal tumor resection with the use of rectoscopes are well accepted, widely used and improved in terms of technique in the last two decades. The transanal endoscopic microsurgery (TEM) idealized and preconized by Buess [37,38], is used in different countries: Germany, Italy, United Kingdom, Japan, Israel, Spain, Swiss, Australia, China, USA and others. Since its introduction into the clinical practice, some innovations were added to the technique, in order to improve the final performance of the

procedure. Among the TEM innovations are some different types (modalities) of the endoscopic access, mainly aimed in order to reduce the equipment costs.

The first modification of the original TEM was proposed by Swanström [23] where the authors propose the use of the videolaparoscopy equipment; this technique is known as video-endoscopic Transanal Microsurgery (VETM). In sequence, Japanese surgeons have modified the VETM performing it without gas inflation. These two main modifications of the original technique reduced the equipment price in approximately US\$ 50000.00 [24-26, 39].

Despite that the literature on the local excision of rectal tumors indicates high survival rates and good results about the local control of the disease, selection criteria for patient are restrict. Only about 3 to 8% of invasive rectal tumors are qualified for this kind of treatment, based on those criteria [36,40].

From all available techniques for local excision of rectal lesions, the endoscopic procedures (TEM and others) are the most internationally used. Nevertheless, these techniques demand experience and, in consequence, must be performed in reference centers where a larger number of patients are available, facing that the surgeon training is mandatory and the small frequency of the indications is a reality [41-44]. Because of the necessity of having specific instruments and also the particular technical aspects, this method demands good training for the obtention of satisfactory results [45-47]. It was described that in 11 tumors located up to 4 cm of the anorectal line, a surgical conversion was necessary because of technical difficulties [48]. Due to two important disadvantages: first the high costs, taking into account the limitation of the equipment use and second, technical difficulties to perform the technique with ability and efficiency, the procedure has not achieved wide acceptance and popularity [23,49].

In Brazil, very few surgeons use the TEM technique proposed by Buess.

Due to the explained circumstances and facing the reality of a growing consecutive series of the distal third rectal neoplasm, with most of them committing old patients, with relevant comorbidities and high surgical and anesthetic risks, we started thinking of a less invasive alternative procedure than the radical abdominal resections, which would be more efficient than the conventional transanal excision and less complicated than the posterior accesses.

In this way, we proposed the TEO: we idealized and built a surgical proctoscope of low costs, associated to conventional surgical instruments, a fiberlight source, polypectomy loops and videolaparoscopic forceps, without the necessity of inflation or video cameras. The equipment built in our precision tool facility (Oficina de Precisão da Faculdade de Medicina de Ribeirão Preto – Hospital das Clínicas) showed very good results. From the 83 proposed surgeries, in only two it was not possible to conclude the procedure, one due to a rectal stenosis and the other due to the distance of the lesion from the anal border (15 cm), with an accentuated rectal-sigmoidal angle.

On the opposite way from the other transanal endoscopic techniques, mainly the TEM, which are inefficient for the excision of the inferior third rectal tumors because it is not possible to keep the equipment on the rectal lumen under inflation [50], on the TEO, with the 7 cm rectoscope, these lesions were easily excised.

With the increasing surgeon experience, it was possible to modify the rectoscope making it easier to handle and the surgical steps efficient and fast. These modifications included the use of the stainless steel as the main component, the 0.5 cm enlargement in the rectoscope

diameter and the reduction of the electrocautery and vacuum tubes tips. This idealized proctoscope showed to be a very useful tool, with low cost, easy to handle and that allowed the obtaining of reliable results, similar to those already described for other transanal endoscopic techniques.

On the casuistic of the present study, six cases previously submitted to one or two endoscopic excision by means of colonoscopy (two superficial adenocarcinoma three villous-adenomas) were successfully submitted to the TEO. Another patient with villous-adenoma and high grade dysplasia, previously submitted to an CTE and presenting a recurrent lesion was also successfully submitted to the TEO. Eight patients were submitted to the TEO twice, or for the complete excision of the tumor or to the excision of residual or recurrent lesion suspect tissue.

The comparative results presented by the several local excision techniques are difficult to interpret since most of literature descriptions are based on retrospective analysis and on heterogeneous groups. Also, there is no randomized prospective studies and there is a lot of variation concerning the adjuvant therapy indication [1,2,16,17,20].

Another relevant aspect for literature data comparison is the biological characterization of the tumor, i.e., interaction tumor-host, which might be inferred by the morphology, histology, size, localization and invasive stage. This is essential for the therapeutic results comparison in patients with similar disease stages [51].

The lack of homogeneity in the literature is due to the difficulty in having a large number of patients for the study and also due to the necessity of classifying them according to the tumor stage (Tis, T1, T2, T3). Some authors use radiotherapy and others don't; while some authors exclude from the recurrence statistics those patients operated by local excision and, after diagnosing that the resection borders still had tumor, were right after submitted to a radical resection.

Despite recognizing the difficulties to find reports with the necessary severity for closer comparisons with the reality, 35 reviews were compared aiming the objectives of the present study.

We consider our recurrence rate very favorable since, to the moment only two recurrence were observed for the curative adenocarcinomas excised with TEO. For the adenomas, the average observed in our study is compatible with the literature revised, except one (Graphs I and II). If we group both rates on the total recurrence rate, the results are also similar to the literature (Graph III). These observations indicate that we should keep the surgery indication criteria, and continue to improve the technique and to observe the patients for a longer period of time.

The post-operative complications were observed in total since the literature available does not discriminate in mild or severe complications. Our complications rate is acceptable (Graph IV) and compatible with most of the literature revised. In two cases there was a severe complication (pneumoretroperitoneum) on the 5th and 3rd post-operative day. The first patient was operated on for a distal rectum opening on a patient with invasive, advanced and obstructed neoplasm and in this particular case a re-intervention was necessary, with a loop sigmoidostomy. The other case was treated conservatively and had good response. There was one pneumoperitoneum after a second TEO for a recurrent villous adenoma, when the peritoneal fold was opened, treated clinically, the patient had a good response. Other complications such as pain, evacuation bleeding, urinary difficulties, were treated clinically.

The average proportions of the intestinal resections after local excisions are small and equivalent to the literature (Graph V). The observations of the intestinal resections after neoplasm lesions recurrence were ten times larger but also comparable to the literature (Graph VI).

In our study, two patients were re-operated (intestinal resections) after the TEO: one with a resting villous-adenoma 15 cm above the anorectal border, not reached with the surgical rectoscope, and the other one with an adenocarcinoma on the rectal mid third, with angiolymphatic invasion and compromised border, who was submitted to a total proctocolectomy. Nevertheless, the following histopathological exam did not show the presence of neoplasm on the tissue.

The results of a second local excision due to a residual lesion or recurrence demonstrated that performing another local excision or an intestinal resection it is still controversial since half of the revised literature has shown average proportions inferior to the TEO (Graph VII). In the present study we performed four TEO re-operations being the indication based on the fibrosis and suspect granulation on the lesion border but in both cases, the histopathological analysis did not show resting neoplasm.

For some variables of interest, the correlation between our results and the literature were analyzed (Graphs VII to XII). These variables were the distance of the lesion from the anal border, lesion size represented by its maximum diameter, operation time and hospitalization time.

The evaluation of the anal border distance of the lesions allows us to infer that the local excision is safely performed on the mid and inferior thirds of the rectum. In the literature, there are reports of TEM excisions of 15 to 18 cm lesions. In the present study we reached tumors up to 12 cm. Only one case of a lesion located 15 cm from the anal border was not reached due to a rectal-sigmoidal angulation.

The lesion size analysis, expressed in cm in its maximum diameter, showed very good results since, in our study, lesions up to 7 cm were excised. Other authors refer the excision of 8-9 cm lesions but this situation is related to those giant villous-adenomas, in which the endoscopic resections might be done in more than one surgical time.

The analysis of Graph X indicates that TEO shows a very short operative time, which is probably due to the fact that the equipment is simple and easy to use and that the procedure itself is also simply performed.

In terms of hospitalization time, despite the fact that TEO has shown the smallest time, other authors also show very similar results. Some reports do not present this pattern because they described complicated cases, when long hospitalization was needed, and others because the follow up protocol demanded a longer hospitalization time.

The variable follow up after surgery, expressed in years (Graph XI) reflects the importance and the stability of the local excision surgeries. In several reports, the follow up time has been studied between 10 and 15 years. In our experience, the follow up time is in between 2 months and 8 years.

In this way, the challenge of idealizing, projecting and using a surgical endoscopic instrument of low costs, and adequate for its main purposes, i. e. appropriate for use in transanal endoscopic surgeries, was fully achieved.

The results of the TEO showed and discussed in the present study, compared to the international literature, demonstrated that the TEO is an adequate and feasible procedure for the local excision of rectal tumors.

5. Conclusions

1. The proctoscope specially designed and built for the TEO has shown appropriate, efficient and of low costs;
2. The TEO was easily performed on lesions of the mid and inferior third rectal tumors;
3. The results obtained with TEO were favorable and similar to those obtained with other available techniques for endoscopic transanal resection that are of high costs and of less availability.

6. References

- [1] Balani A, Turollo A, Braini A, Scaramucci M, Roseano M, Leggeri A. Local excision for rectal cancer. *J Surg Oncol* 2000; 74: 158-62.
- [2] Nastro P, Beral D, Hartley J, Monson JR. Local excision of rectal cancer: review of literature. *Dig Surg* 2005; 22 (1-2): 6-15.
- [3] Stipa S, Stipa F, Ziparo V. Tratamento cirúrgico de câncer de reto: Ressecção local. In: Rossi BM, Nakagawa WT, Ferreira FO, Aguiar Jr S, Lopes A. Câncer de Cólon, Reto e Anus. Ed. Tecmedd, 2005, p. 275.
- [4] Kraske P. Zur exstirpation hochsitzender Mastdarmkrebse. *Verh Dtsch Ges Chir* 1884, 14: 464.
- [5] Mason AY. Surgical access to the rectum: A transphincteric exposure. *Proc R Soc Med* 1970, 63(suppl): 91-4.
- [6] Rothenberger DA, Garcia-Agüilar J. Role of local excision in the treatment of rectal câncer. *Semin Surg Oncol* 2000 ; 19(4): 367-75.
- [7] Heintz A, Braunstein S, Menke H. Local excision of rectal tumors. Indications, preoperative diagnosis, surgical technique and results. *Med Klin* 1992; 87(5): 236-41.
- [8] Buess GF. Local surgical treatment of rectal cancer. *Eur J Cancer* 1995; 31 A (7-8): 1233-7.
- [9] Whitlow CB, Beck DE, Gathright JB. Surgical excision of large rectal villous adenomas. *Surg Oncol Clin N Am* 1996; 5(3): 723-34.
- [10] Reid AJ - Echocolonoscopy - an indispensable procedure before and after transanal endoscopic microsurgery. *Endosc Surg Allied Technol* 1993; 1(1): 47-8.
- [11] Graham RA, Hackford AW, Wazer DE. Local excision of rectal carcinoma: A safe alternative for more advanced tumors? *J Surg Oncol* 1999; 70: 235-8.
- [12] Guerrieri M, Paganini A, Feliciotti F, Zenobi P, Lugnani F, Lezoche E. Echography in minimally invasive surgery. *Ann Ital Chir* 1999; 70(2): 211-5.
- [13] Kneist W, Terzic A, Burghardt J, Heintz A, Junginger T. Selection of patients with rectal tumors for local excision based on preoperative diagnosis. Results of a consecutive evaluation study of 552 patients. *Chirurgie*, 2004 ; 75(2): 169-75.
- [14] Glancy DG, Pullyblank AM, Thomas MG. The role of colonoscopic endoanal ultrasound scanning (EUS) in selecting patients suitable for resection by transanal endoscopic microsurgery (TEM). *Colorectal Dis* 2005; 7(2): 148-50.
- [15] Biggers OR, Beart RW, Ilstrup DM. Local excision of rectal cancer. *Dis Colon Rectum* 1986; 29(6): 374-7.


- [16] Budhoo M R & Hancock B Transanal excision of early rectal carcinoma – review of a personal series. *Colorectal Dis* 2000; 2 (2): 73-6.
- [17] Koscinski T, Malinger S, Drews M. Local excision of rectal carcinoma not-exceeding the muscularis layer. *Colorectal Dis* 2003; 5 (2): 159-63.
- [18] Beral DL, Monson JR. Is local excision of T2/T3 rectal cancers adequate?. *Recent Results Cancer Res* 2005; 165: 120-35.
- [19] Guillem JG, Chessin DB, Jeong SY, Kim W, Fogarty JM. Contemporary applications of transanal endoscopic microsurgery: technical innovations and limitations. *Clin Colorectal Cancer* 2005; 5(4): 268-73.
- [20] Aguilar JG, Mellgren A, Sirivongs P, Buie D, Madoff RD, Rothenberger DA. Local excision of rectal cancer without adjuvant therapy. A word of caution. *Annals Surg.* 2000; 231(3): 345-51.
- [21] Buess G, Kipfmuller K, Naruhn M, Braunstein S, Junginger T. Endoscopic microsurgery of rectal tumors. *Endoscopy* 1987; 19 Suppl 1: 38-42.
- [22] Buess G, Kipfmuller K, Hack D, Grussner R, Heintz A, Junginger T. Technique of transanal endoscopic microsurgery. *Surg Endosc* 1988; 2(2): 71-5.
- [23] Swanstrom LL, Smiley P, Zelko J, Cagle L. Videoendoscopic transanal-rectal tumor excision. *Am J Surg* 1997; 173(5): 383-5.
- [24] Yamashita Y, Sakai T, Maekawa T, Shirakusa T. Clinical use of a front lifting hood rectoscope tube for transanal endoscopic microsurgery. *Surg Endosc* 1998; 12(2): 151-3.
- [25] Kakizoe S, Kakizoe K, Kakizoe Y, Kakizoe H, Kakizoe T, Kakizoe S. Rectal expander-assisted transanal endoscopic microsurgery in rectal tumors. *Surg Laparosc Endosc* 1998; 8(2): 117-9.
- [26] Ikeda Y, Koyanagi N, Mori M, Akahoshi K, Ueyama T, Sugimachi K. Transanal endoscopic microsurgery for T1 rectal cancer in patients with synchronous colorectal cancer. *Surg Endosc* 1999; 13(7): 710-2.
- [27] Hojo K, Koyama Y, Moriya Y. Lymphatic spread and its prognostic value in patients with rectal cancer. *Am J Surg* 1983; 144: 350-4.
- [27] Leemis LM & Trivedi KS. A comparison of approximate interval estimator for the Bernoulli parameter. *Am Statist.* 1996, 50(1): 63-8.
- [28] Jessup JM, Bothe A Jr, Stone MD. Preservation of sphincter function in rectal carcinoma by a multimodality treatment approach. *Sur Oncol Clin North Am* 1992; 1:137-45.
- [29] Enker WE, Paty PB, Minsky BD, Cohen AM. Restorative or preservative operations in the treatment of rectal cancer. *Surg Oncol Clin North Am* 1992; 1: 57-69.
- [30] Fortunato L, Ahmad NR, Yeung RS, Coia LR, Eisenberg BL, Sigurdson ER, Yeh K, Weese JL, Hoffman JP. Long-term follow-up of local excision and radiation therapy for invasive rectal cancer. *Dis Colon Rectum* 1995; 38:1193-1199.
- [31] Wind G, Nottberg H, Keller R, Schmid KW, Bunte H. Surgical cure for early rectal carcinomas (T1). Transanal endoscopic microsurgery vs anterior resection. *Dis Colon Rectum* 1996; 39 (9): 969-76.

- [32] Heintz A, Morschel M, Junginger T. Comparison of results after transanal endoscopic microsurgery and radical resection for T1 carcinoma of the rectum. *Surg Endosc* 1998; 12(9): 1145-8.
- [33] Lee W, Lee D, Choi S, Chun H. Transanal endoscopic microsurgery and radical surgery for T1 and T2 rectal cancer. *Surg Endosc* 2003; 17(8): 1283-7.
- [34] Whiteway J et al. The role of surgical local excision in the treatment of rectal cancer. *Br J Surg* 1985; 72: 694-7.
- [35] Morson BC, Bussey HJR, Samoorian S. Policy of local excision for early cancer of the colorectum. *Gut* 1977; 18: 1045-50.
- [36] Stearns MW, Sternberg SS, DeCosse JJ. Treatment alternatives: localized rectal cancer. *Cancer* 1984; 54: 2691-4.
- [37] Buess G. Review: transanal endoscopic microsurgery (TEM). *J R Coll Surg Edinb* 1983; 38 (4): 239-45.
- [38] Buess G, Kipfmüller K, Ibalá R, Heintz A, Hack D, Braunstein S, Gabbert H, Junginger T. Clinical results of transanal endoscopic microsurgery. *Surg Endosc* 1988; 2(4): 245-50.
- [39] Nakagoe T, Hishikawa H, Sawai T, Tsuji T, Tanaka K, Ayabe H. Surgical technique and outcome of gasless video endoscopic transanal rectal tumour excision. *Brit J Surg* 2002; 89, 769-74.
- [40] Coco C, Magistrelli P, Granone P, Roncolini G, Picciocchi A. Conservative surgery for early cancer of the distal rectum. *Dis Colon Rectum* 1992; 35: 131-6.
- [41] Buess G, Kayser J. Technique and indications for sphincter-saving transanal resection in rectal carcinoma. Buess G, Kayser J. *Chir* 1996; 67 (2): 121-8.
- [42] Said S, Stippel D. 10 years experiences with transanal endoscopic microsurgery. Histopathologic and clinical analysis. *Chirurg*. 1996; 67(2): 139-44.
- [43] Kipfmüller K, Buess G, Naruhn M, Junginger T. Training program for transanal endoscopic microsurgery. *Surg Endosc* 1988; 2(1): 24-7.
- [44] Spalinger R, Schlumpf R, Largiader F. Transanal endoscopic microsurgery – experiences at the Zurich University Hospital. *Schweiz Rundsch Med Prax* 1998; 87 (33): 1014-8.
- [45] Demartines N, von Flue MO, Harder FH. Transanal endoscopic microsurgical excision of rectal tumors: indications and results. *World J Surg* 2000; 25(7): 870-5.
- [46] Buess GF, Raestrup H. Transanal endoscopic microsurgery. *Surg Oncol Clin Am* 2001; 10(3): 709-31.
- [47] Lloyd GM, Sutton CD, Marshall LJ, Baragwanath P, Jameson JS, Scott AND. Transanal endoscopic microsurgery – lessons from a single UK centre series. *Col Dis* 2002; 4(6): 467-9.
- [48] von Flue M, Harder F. Transanal endoscopic microsurgery (TEM): indications and limitations. *Schweiz Med Wochenschr* 1994; 124(41): 1800-6.
- [49] Corman ML. *Colon & Rectal Surgery*. Fifth edition. Lippincott Williams & Wilkins, 2005.
- [50] Guillem JG, Paty PB, Cohen AM. *Surgical treatment of colorectal cancer*. *CA Cancer J Clin*. 1997; 47: 113.

- [51] Killingback M, Barron P, Dent OF . Local recurrence after curative resection of cancer of the rectum without total mesorectal excision. Dis Colon Rectum 2001; 44 (4): 473-86.

IntechOpen

IntechOpen



Endoscopic Procedures in Colon and Rectum

Edited by Prof. Jose Ribeiro Da Rocha

ISBN 978-953-307-677-5

Hard cover, 156 pages

Publisher InTech

Published online 07, November, 2011

Published in print edition November, 2011

Endoscopic procedures in colon and rectum presents nine chapters which start with introductory ones like screening by colonoscopy as the preparation and monitoring for this exam. In addition to these approaches the book aims in the last four chapters to explain endoscopic diagnostic and therapeutic aspects in the colon and rectum. The description of each text is very comprehensive, instructive and easy to understand and presents the most current practices on the topics described. This book is recommended for general and colorectal surgeons as it presents guidelines for diagnosis and treatment which are very well established.

How to reference

In order to correctly reference this scholarly work, feel free to copy and paste the following:

José Joaquim Ribeiro da Rocha and Omar Féres (2011). Transanal Endoscopic Operation - A New Proposal, Endoscopic Procedures in Colon and Rectum, Prof. Jose Ribeiro Da Rocha (Ed.), ISBN: 978-953-307-677-5, InTech, Available from: <http://www.intechopen.com/books/endoscopic-procedures-in-colon-and-rectum/transanal-endoscopic-operation-a-new-proposal>

INTECH
open science | open minds

InTech Europe

University Campus STeP Ri
Slavka Krautzeka 83/A
51000 Rijeka, Croatia
Phone: +385 (51) 770 447
Fax: +385 (51) 686 166
www.intechopen.com

InTech China

Unit 405, Office Block, Hotel Equatorial Shanghai
No.65, Yan An Road (West), Shanghai, 200040, China
中国上海市延安西路65号上海国际贵都大饭店办公楼405单元
Phone: +86-21-62489820
Fax: +86-21-62489821

© 2011 The Author(s). Licensee IntechOpen. This is an open access article distributed under the terms of the [Creative Commons Attribution 3.0 License](https://creativecommons.org/licenses/by/3.0/), which permits unrestricted use, distribution, and reproduction in any medium, provided the original work is properly cited.

IntechOpen

IntechOpen