

# We are IntechOpen, the world's leading publisher of Open Access books Built by scientists, for scientists

6,900

Open access books available

185,000

International authors and editors

200M

Downloads

Our authors are among the

154

Countries delivered to

TOP 1%

most cited scientists

12.2%

Contributors from top 500 universities



WEB OF SCIENCE™

Selection of our books indexed in the Book Citation Index  
in Web of Science™ Core Collection (BKCI)

Interested in publishing with us?  
Contact [book.department@intechopen.com](mailto:book.department@intechopen.com)

Numbers displayed above are based on latest data collected.  
For more information visit [www.intechopen.com](http://www.intechopen.com)



# Skin Biopsy Procedures: How and Where to Perform a Proper Biopsy

Seia Z., Musso L., Palazzini Stefania and Bertero M.  
*Ospedale S. Croce e Carle of Cuneo, SC Dermatologia  
Italy*

## 1. Introduction

### 1.1 Skin biopsy

The skin biopsy is a relatively simple, but essential procedure in the management of skin disorders. As a diagnostic method, skin biopsy is most commonly used in dermatology rather than in other medical specializations. The most common indication is to diagnose or exclude cutaneous malignancies. Properly performed, it may confirm a diagnosis, remove cosmetically unacceptable lesions, and provide definitive treatment for a number of skin conditions yielding a sample of skin for histopathological or other investigation. Before performing a skin biopsy it is necessary to take prior arrangements with a laboratory for sending specimens, particularly for specialised investigations such as direct immunofluorescence or molecular biology. Otherwise it would be better to send the biopsy to selected centers even far away because a wrong diagnosis is worse than a lack of diagnosis. It is also necessary a foolproof system for sending specimens, receiving and filing reports, documenting and executing action plans. Patients must give a well drafted, written consent form for invasive procedures.

Skin biopsy techniques should ideally be quick and easy to perform, yielding specimens of high quality and adequate size while leaving the smallest possible tissue defect and a good cosmetic result. Skin biopsies can be performed with minimal risk in critically ill patients, and a timely skin biopsy may avoid other, more invasive procedures. Skin biopsies are infrequently performed by internist. This may involve lack of proficiency, or uncertainty regarding indications, choice of procedure, specimen handling, or subsequent wound care. Nevertheless, many dermatoses have nonspecific histopathology and biopsy cannot substitute for good clinical skills.

There are few absolute contraindications to skin biopsy, but all patients should be told that biopsies leave scars. A biopsy should not be done at an infected site, although occasionally infection may be the indication for the procedure. Inquiry should be made regarding allergies to topical antibiotics, antiseptics, local anesthetics and reaction to tape. Patient should be asked about systemic diseases, bleeding disorders, bleeding with previous surgery, and use of drugs known to interfere with hemostasis.

There are several methods to perform biopsy: curettage, shave biopsy, punch biopsy, excisional biopsy.

#### 1.1.1 Surgical safety

Performing skin biopsies places the operator at risk of blood-borne infections. Universal precautions should be observed by wearing gloves and eye-guards. Shave and punch

biopsies are clean but not sterile procedures; mask, gown and sterile gloves are not always necessary. These are indicated for excisions, and are reasonable for any patient at increased risk of infection. Material that is contaminated with blood or other body fluids should be disposed in special „contaminated-materials“ plastic bags.

### 1.1.2 Preparing the site

To prepare the biopsy site common skin antiseptics can be used (such as isopropyl alcohol, providone-iodine, chlorhexidine gluconate). It is useful to mark the intended lesion with a surgical marker as the border may be temporarily obliterated by the anesthetic injection. For excision, a surgical fenestrated drape is placed over the biopsy site after cleansing and before anesthesia.

### 1.1.3 Anesthesia

The most commonly used anesthetic is 1% or 2% lidocaine. This is a vasodilator, and so small amounts of epinephrine are added to constrict blood vessels, decrease bleeding, and prolong anesthesia. It is better to avoid the use of epinephrine for acral lesions, tip of nose, or when large quantities are needed, especially in patients with cardiovascular disease. The onset of vasoconstriction is slower than that of anesthesia. The sting of injection can be minimized by mixing 1 mL of  $\text{NaHCO}_3$  with 9 mL of lidocaine, using a 30-gauge needle, and by making the initial injection perpendicular to the skin. Deep injections sting less than superficial injection, but prolong the time to adequate anesthesia. For small lesions the anesthetic can be injected directly into, or immediately adjacent to the lesion. For larger lesions it is better to perform a field block by placing a ring of anesthetic around the surgical site.

## 2. Biopsy procedure

### 2.1 Curettage

The curette is a spoon-like blade attached to a pencil-like handle ranging in diameter from 2 to 10 mm (fig 1)



Fig. 1. This is a Volkmann curette. In commerce there are also disposable curettes with a circular cutting top.

Curettage is performed by scraping the lesion with a curette. It can also be used to treat superficial nonmelanocytic skin cancers. Four mm diameter curettes are usually used for small lesions (less than 1 cm in diameter). Bigger curettes can give more tissue to make histological evaluation possible. Haemostasis is achieved by compression, cauterisation or laser.

## 2.2 Shave biopsy

Shave biopsies are quick, require little training, and do not require sutures for closure. The shave biopsy can be facilitated by raising the lesion with a wheal of injected anesthetic, allowing it to be propped up and stabilized between the thumb and forefinger. To shave a lesion, a blade is held parallel to the skin surface. The depth of the biopsy is controlled by the angle of the blade. Care should be taken to keep the blade parallel to the skin surface, avoiding irregular, deep penetration. A double-edge razor blade cut longitudinally can also be used for shave biopsies. The razor technique has several advantages; it is sharper than most blades, the razor can be bent concave or convex with the thumb and forefinger to better conform to the surface being cut, and depth is easily controlled by increasing the convexity of the curve. Curved scissors are an efficient means of removing skin tags and other small, exophytic growths. The lesion to be removed is stabilized with toothed forceps, then cut at the base.

Lesions that are most suitable for shave biopsies are either elevated above the skin, or have pathology confined to the epidermis (Fig 2).

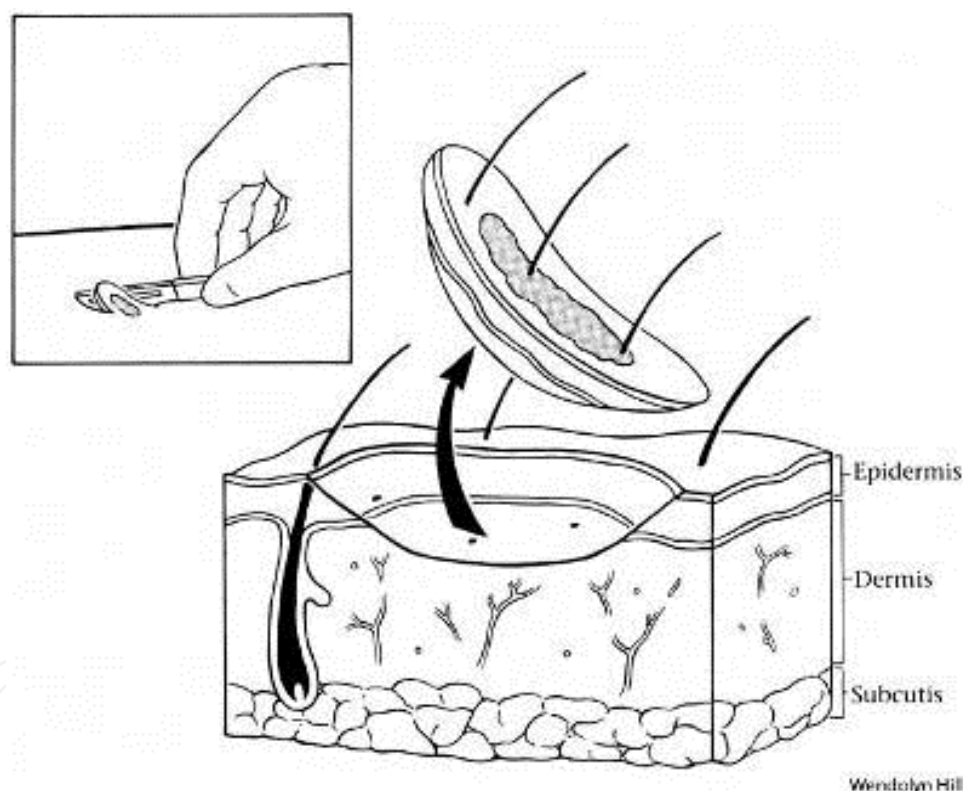


Fig. 2. An example of a shave biopsy. Note that the lesion depth was restricted only to the epidermis and the dermis.

It is acceptable if the lesion is small and the risk of malignancy is low. Common indications include seborrheic or actinic keratoses, skin tags, and warts. Shave biopsies should not be used for pigmented lesions. With shave biopsies, a small, depressed scar does occur.

## 2.3 Punch biopsy

Punch biopsy is considered the primary technique to obtain diagnostic, full-thickness skin specimen (Fig 3).

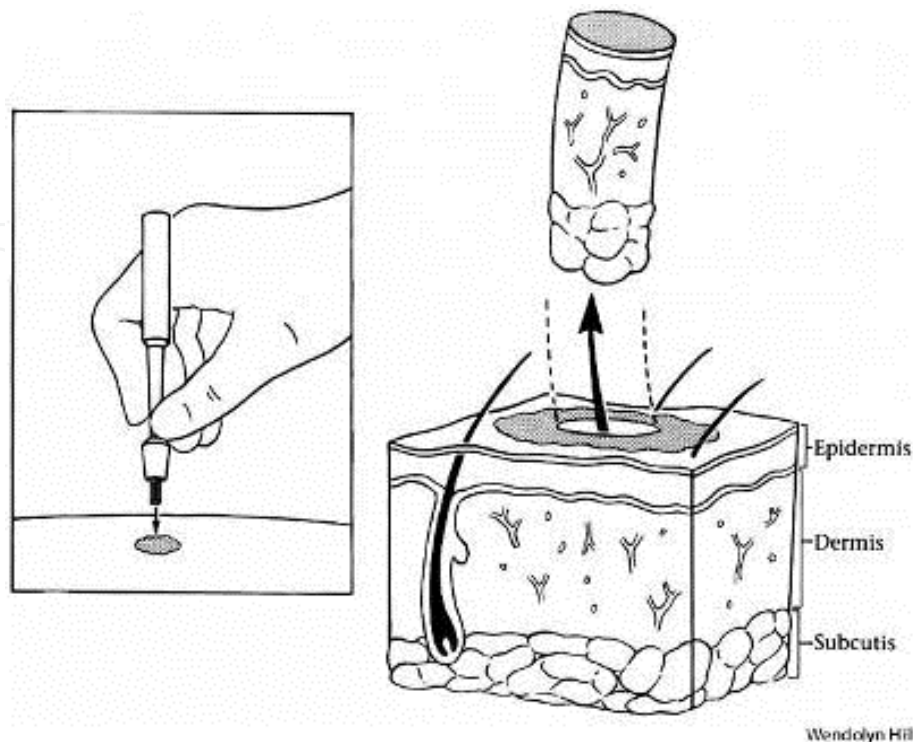


Fig. 3. An example of punch biopsy. The cylinder of tissue includes the epidermis, dermis and sometimes the subcutaneous fat.

It is performed using circular blade or trephine attached to a pencil-like handle ranging in diameter from 2 to 10 mm, but 3 mm is the smallest size likely to give sufficient tissue for consistent and accurate histologic diagnosis. The punch biopsy yields a cylindrical core of tissue that must be gently handled (usually with a needle) to prevent crush artifact at the pathological evaluation.

Large punch biopsy sites can be closed with a single suture and generally produce only minimal scarring. Because linear closure is performed on the circular-shaped defect, stretching the skin before performing the punch biopsy allows the relaxed skin defect to appear more elliptical and makes it easier to close. The skin is stretched perpendicular to the relaxed skin tension lines, so that the resulting elliptical-shaped wound and closure are parallel to these skin tension lines. The punch is then firmly introduced and rotated to obtain the specimen. This procedure is suitable when all skin layers are to be examined, or when the area of skin to be removed is unacceptably large for an excision.

Punch biopsy of inflammatory dermatoses can provide useful information when the differential diagnosis has been narrowed. The active edge of a dermatosis is usually chosen as the biopsy site. Cutaneous neoplasm can be evaluated by punch biopsy, and the discovery of malignancy may alter the planned surgical excision procedure (Fig 4).

A punch biopsy of a melanoma does not influence the prognosis of the neoplasm (Pflugfelder A et al 2010; Bong JI et al 2002), however it is currently recommended only for the histopathologic diagnosis of large tumors in facial, mucosal, and acral locations. Routine biopsy of skin rashes is not recommended because the commonly reported nonspecific pathology result rarely alters clinical management.



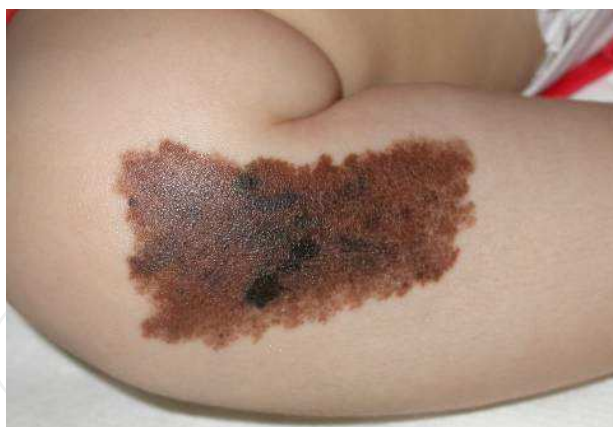

Fig. 4. In a case of giant congenital nevus a punch biopsy is useful to perform a histological evaluation of more atypical areas before deciding whether to remove the entire lesion.

## 2.4 Excisional biopsy

In an excision biopsy, the entire skin lesion is removed with an elliptical excision. The classical fusiform excision has a 3 to 1 length-to-width ratio and a 2-to-5 mm margin of normal skin around the lesion. This technique produces an angle of 30 degrees or less at the end of the wound. The long axis of the wound should be oriented parallel to the lines of least skin tension to improve the final scar outcome. Holding the scalpel with a number 15 blade like a pencil, the incision begins at one apex with the blade perpendicular to the skin. As the incision progresses, it should be made using more of the belly of the blade, raising it to the perpendicular again at the next apex. A number 11 blade can be also used instead of the 15 one. The incision must be deep enough to see subcutaneous fat when the sample is removed. Once the ellipse has been incised, the sample edge should be carefully lifted with fine forceps and completely undermined at the level of subcutaneous fat with scalpel or scissors. A properly designed fusiform excision can be closed primarily and should not result in the formation of raised tissue at the ends of the wound (known as „dog ears“). The skin should not be grasped with forceps, because the resulting skin damage can produce necrosis and scarring. Hematomas at the base of the excision inhibit wound healing, create excessive scarring and produce a depressed and more noticeable scar following normal scar retraction. Subcutaneous bleeding sites can be controlled with instrument clamps, electrocautery, or absorbable suture ligation. Interrupted, deep-buried absorbable sutures placed down to the level of the fascia eliminate dead space, provide excellent haemostasis, reduce tension on skin sutures and generally improve the cosmetic and functional result.

Excisions are reserved for lesions that cannot be removed with a punch owing to size, depth, or location. Their main advantage is the amount of tissue that can be excised, allowing for multiple studies (culture, histopathology, immunofluorescence, electron microscopy) from one biopsy site. Excisions are especially well suited for removal of large skin tumors or inflammatory disorders deep in the skin, involving the panniculus. Excision may be indicated for lipoma, dermatofibroma, keratoacanthoma, pyogenic granuloma, or epidermoid cysts. The wound is closed by suturing. This procedure can be curative for many lesions, but requires adequate time, expertise and suitable equipment. Excisional biopsy is also the procedure of choice for suspicious pigmented lesions (Tadiparthi S et al 2008) and for definitive treatment of skin cancer after diagnostic biopsy.

### 3.Choise of site

#### 3.1 Introduction

Skin biopses are unique because the lesion can be visualized, allowing for proper selection of biopsy site and technique. It is a common fact that more errors are made from failing to biopsy promptly than from performing unnecessary biopsies. Nevertheless, many dermatoses have nonspecific histopathology, and biopsy cannot substitute for good clinical skills. Biopsy is indicated in all suspected neoplastic lesions, in all bullous disorders, and to clarify a diagnosis when a limited number of entities are under consideration.

One of the more difficult initial decisions is selecting the biopsy site. Whenever possible, avoid important cosmetic areas, such as the face, areas with poor healing characteristics and areas where a nerve or an artery damage is possible. Hypertrophic scarring tends to occur over the deltoid and chest areas, and delayed healing can be a problem over the tibia, expecially in diabetic patients or in patients with arterial or venous insufficiency. The incidence of secondary infection in the groin and axillae is high; therefore biopsy these areas only if other sites are unavailable.

#### 3.2 Biopsy of the scalp

The biopsy of the scalp is usually performed to diagnose squamous carcinomas which are very frequent especially in an elderly patient. These tumors frequently derive from chronic actinic damage in a solar exposed area where the hair protection is lost. The scalp area is a highly vascular area and biopsy of the scalp should be performed in an aseptic surgical room by expert trained operators. The fusiform excision is to be preferred since in case of an artery damage (usually some branches of the superficial temporal artery) it is easier to stop bleeding with a suture of the artery. It is also important to not extend the incision deep to the galea capitis to lead a better and faster healing.

Considering inflammatory and cicatritial alopecias, it is nowadays considered more useful to have not just vertical but also horizontal histological sections in order to analyze the type of inflammatory infiltration and its localization around hair follicles. So in these cases, it is better to perform two punch biopsies of the scalp usually of 4-5 mm of diameter deep to the adipous layer. One tissue cylinder will then be cut vertically as usual leading to longitudinal sections, while the other will be cut horizontally leading to tangential sections Fig 5 and Fig 6).

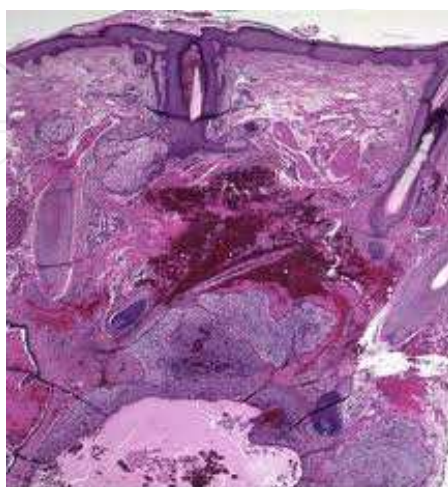


Fig. 5. Longitudinal classic histology of a biopsy of the scalp. It is possible to make a qualitative examination of the hair structures and it is possible to localize the inflammatory infiltrate.

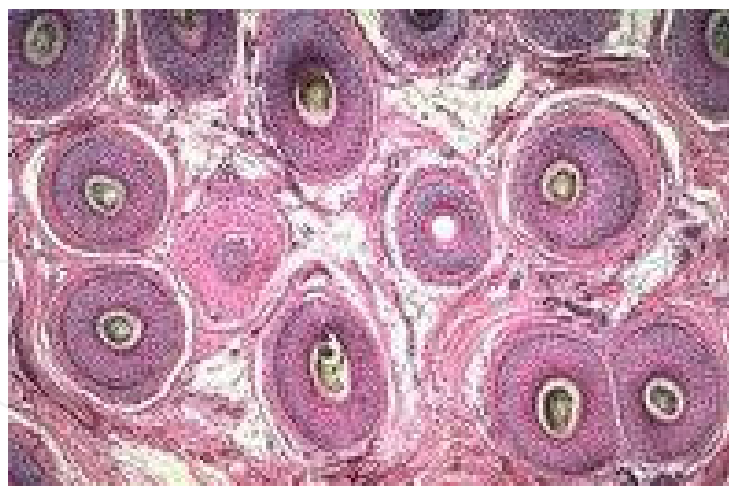


Fig. 6. A tangential histological evaluation of a scalp biopsy. With this section it is possible to localize the inflammatory infiltration, and to make a quantification of hair structures.

The timing of suture removal is usually 7-12 days.

A particular case of scalp biopsy is the biopsy of the Superficial Temporal Artery when there is a suspicion of Horton Temporal arteritis. Since the important risk is bleeding, this procedure must be done only by expert operators. For this particular biopsy it is better to obtain a sample of a Fronto-Temporal Artery branch. The artery can be recognized by the pulsations, but sometimes the vasculitic process could stop them. Before taking the biopsy it would be better to localize the exact biopsy site by Doppler marking with a skin-pen. Then the artery will be exposed with a scalpel cut paying attention not to damage it; with two hemostatic Klemmers the artery should be clamped proximally and distally in order to obtain the artery sample in the middle of the clamped area. Then both the edge of the cut artery must be accurately sutured in order to avoid the risk of post-operative bleeding (Fig 7).

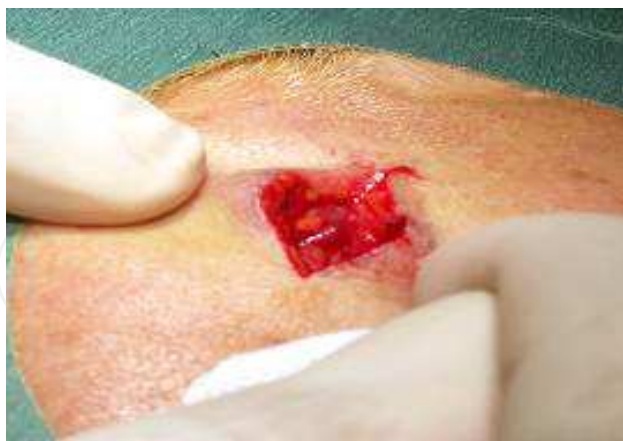

Fig. 7. The image shows the surgical preparation of the Temporal Artery before the biopsy.

### 3.3 Biopsy of the face

An incisional biopsy of the face can lead to a permanent cosmetic damage, so it should be performed only if necessary. The long axis of the wound should be oriented parallel to the lines of least skin tension lines (Kraissl lines in the living, Langers lines in anatomic studies) to improve the final scar outcome (Fig 8).



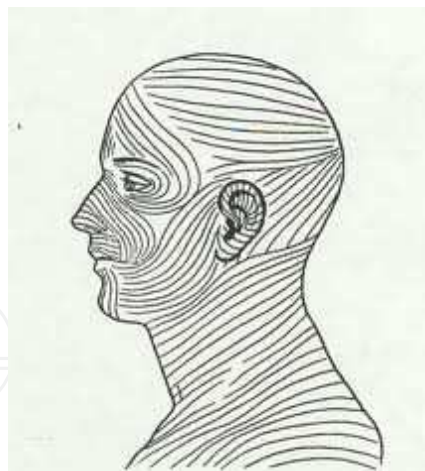


Fig. 8. The picture shows the orientation of Langers lines to follow while making an elliptical excision.

The face is a bleeding prone site and in some areas such as the nose, the anesthetic injection can be painful and difficult. The sting of injection can be minimized by using a 30-gauge needle with anesthetic cream applied two hours before. For cosmetic reason one should use the thinnest suture size (5-0 or 6-0) and suture in the face can be removed in 3 to 7 days eventually followed by the application of semipermanent adhesive strips to reduce wound tension. After the second or third day if there are some crusts on the suture, they should be washed away with wet gauze since they could cause depressed puntiform scars.

A particular attention has to be paid to the area above the zygomatic arch for the presence of the Fronto-Temporal Nerve and the preauricular area innervated by the Facial Nerve. A lesion of these two nerves can lead to a permanent functional and cosmetic damage. Placing a good volume of anesthetic beneath the lesion effectively increases the thickness of the skin and subcutaneous tissues, thereby keeping the incision more superficial.

### 3.4 Biopsy of the lip, of the tongue and of the oral mucosa

These sites are not particularly difficult to biopsy but they are easily bleeding. The dermatological competence for the oral cavity is limited to the anterior one-third of the entire area, the other part is usually let to Otorinolaringoiatry specialists.

### 3.5 Biopsy of the breast

Usually a biopsy in this area is performed to analyze a suspected naevus. In the areola is common Paget disease. The fusiform biopsy in this area should have a semilunar shape near or directly on the areola edge.

### 3.6 Biopsy of the finger

In the fingers it is better to use a ring block anesthesia in order to limit the pain. It has to be performed at the proximal lateral site of the finger with a 30 gauge needle, avoiding the use of epinephrine; the volume of anesthetic injected should be as less as possible in order to prevent compression ischemia.

Fingers are usually the site of pigmented lesions that are difficult to diagnose if they are located under the finger-nail. They require a biopsy of the nail matrix which has to be as small as possible in order to minimize aesthetic nail damage (Fig 9).

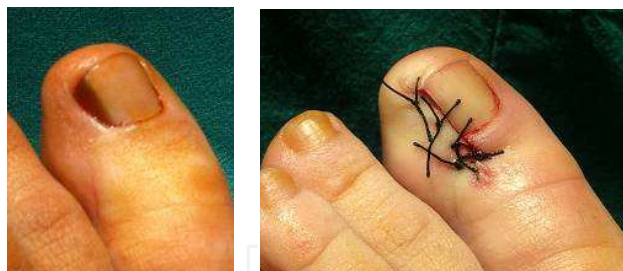


Fig. 9. Excisional biopsy of the medial edge of the thumb nail for the diagnosis of a suspected pigmented lesion.

### 3.7 Biopsy of the penis

A biopsy of the penis should be performed using anesthesia without epinephrine. If the lesion is on the shaft it is enough to make an injection under the lesion, while if the sample has to be taken on the glans it is better to perform a ring block anesthesia.

## 4. Choice of the lesion

A representative lesion at the height of its intensity, unmodified by trauma or treatment, will best show the more characteristic histological features; evolutionary changes may take several days and a too-early biopsy may reveal only nonspecific features. The major exceptions are blisters (and pustules), which should be preferably less than a day old when the specimen is taken. An old blister with secondary changes such as crusts, fissures, erosions, excoriations, infection and ulceration should be avoided since the primary pathological process may be obscured. For non bullous lesions, the biopsy should include maximal lesional skin and minimal normal skin. For lesions between 1 and 4 mm in diameter, biopsy the center or excise the entire lesion, for larger lesions, biopsy the edge, the thickest portion, or the area that is most abnormal in color, because these sites will most likely to contain the distinctive pathology. When the edge of the lesion is well demarcated it is usually best to take the specimen from the edge to include a small portion of normal skin. The edge is often the most active part of the lesion, and the normal skin serves as a built-in control. Whenever possible, remove vesicles intact, with adjacent normal-appearing skin, because disruption makes histological interpretation more difficult. Similarly, bullae should be biopsied at their edge, keeping the blister roof attached. If the differential diagnosis is broad, biopsy several sites to minimize sampling error or to assess the evolution of varied morphology of lesions.

### 4.1 Examples

- **Suspected melanoma.** A correctly performed biopsy is a crucial initial step in the management of malignant melanoma. Excision biopsy is the recommended method for suspected malignant melanoma as it enables diagnosis, staging of the tumour, and determines future investigation, treatment, and prognosis. The initial biopsy should be performed with a minimum lateral clearance of 2 mm and a cuff of subcutaneous fat deep to the tumour. This provides the pathologist with the maximum opportunity to diagnose a malignant melanoma in a given biopsy sample, as well as the depth of invasion. Breslow thickness, the most powerful prognostic parameter, together with the presence of ulceration and the mitosis number, subsequently provides a guide to the margin of clearance required for delayed wide excision and need for sentinel node

assessment and/or adjuvant therapy (Tadiparthi S et al 2008; Swanson NA et al 2002). To assess the thickness of a neoplasm, the base must be visualised; this can be done with confidence only if excision is done with a scalpel and is complete. An incisional biopsy is considered suboptimal because it does not provide the entire lesion for analysis. Incision biopsy is only acceptable for large lesions in cosmetically sensitive areas (facial, mucosal or acral locations) (Newton Bishop JA et al 2002) or when the suspicion for melanoma is low (Fig 10).

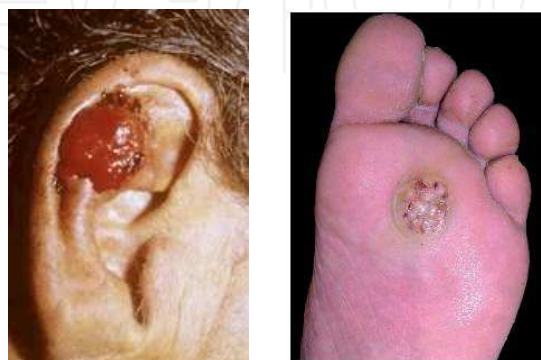

Fig. 10. An amelanotic melanoma is a lesion difficult to recognize. In this case a biopsy is required before making a complete excision.

Incision biopsy may also be warranted in an area of a recent change within a giant congenital naevus (Newton Bishop JA et al 2002). It is a controversial issue whether an incisional biopsy is associated with an unfavorable patient prognosis in melanocytic lesions. Evidence of one of the larger, prospective randomized controlled trial is that incisional biopsies were not associated with an unfavorable prognosis for melanoma patients (Pflugfeldern A et al 2008). Other methods of biopsy, such as punch and shave, are not recommended as they do not allow complete histological staging (Newton Bishop JA et al 2002).

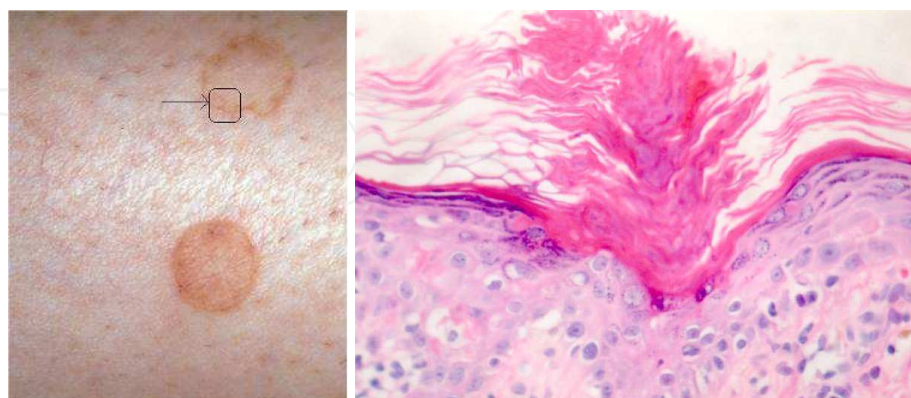


Fig. 11. In the clinical image on the left the arrow shows the exact area to be included in the biopsy. On the right a histological image of the cornoid lamella which arises from a small indentation in the epidermis while extends like a thin column through the entire stratum corneum, and the underlying granular cell layer is diminished.

- **Porokeratosis.** In porokeratosis the histopathologist can make a fast and correct diagnosis by recognizing in the histological slide the “cornoid lamella” which is the clue of this dermatitis. To obtain this clue in our sample it is necessary to biopsy one edge and a part of the internal area of the lesion (fig 11).

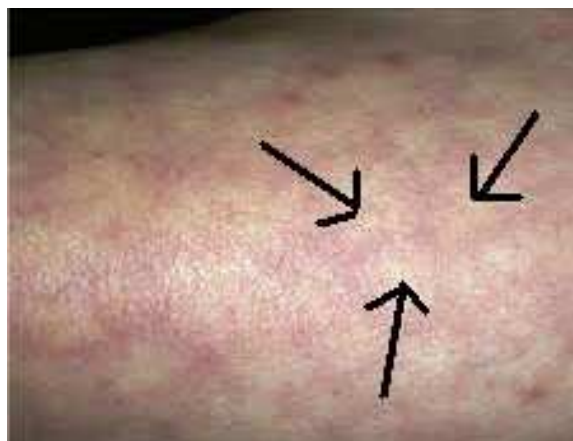
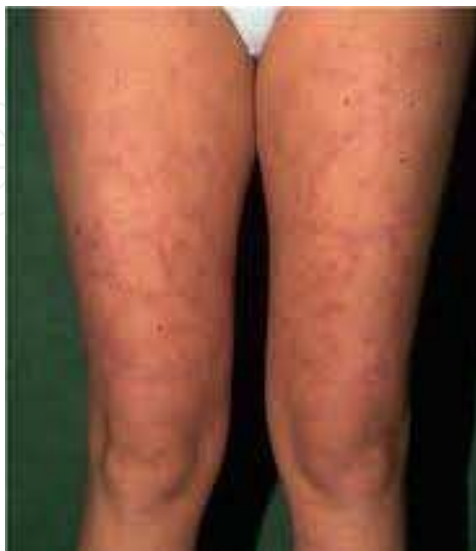
Fig. 12. A clinical example of reticulated dermatitis (livedo reticularis). The biopsy should be done on the center of the red ring in order to obtain evidence of the arteriolar damage.

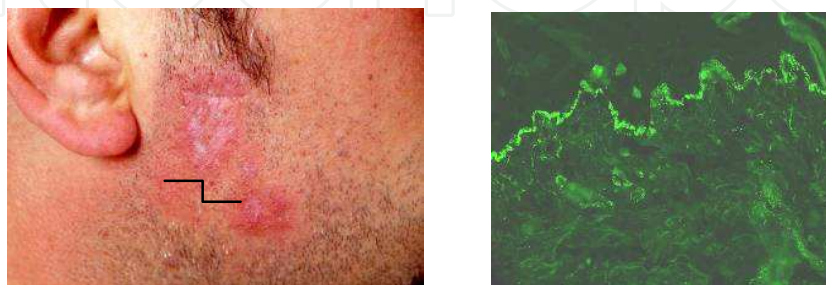


Fig. 13. In case of suspected lupus erythematosus the biopsy should be done in a non-scarring inflammatory area (see the arrow) in order to demonstrate at the direct immunofluorescence examination the specific lupus band.



- **Granuloma annulare.** Granuloma annulare should be biopsied on its elevated periferal edge where the biopsy sample should show the granulomatous infiltrate. Sampling a part of the center of the lesion or a part of the external normal skin would be useful to have a built-in negative control. A biopsy performed in the center of the lesion does not show the peculiar granulomatous infiltrate.
- **Reticulated dermatitis.** Livedo reticularis, erythema ab igne, livedo racemosa and other reticulated dermatitides should be biopsied in the center of a „red ring“. In fact only the white center of the vascular lesion can show the real arteriolar damage that leads to the reticular skin pattern (Fig 12).
- **Bullous dermatitis.** Blisters should be preferably less than a day old when the specimen is taken. An old blister with secondary changes such as crusts, fissures, erosions, excoriations, infection and ulceration should be avoided since the primary pathological process may be obscured. Perilesional skin is the best site for immunofluorescence, and should form the greater proportion of the specimen.
- **Lupus.** it is necessary to select early and mature lesions, avoiding those too recent or too late for finding the basal layer damage and still find immunofluorescence alterations (lupus band and perivascular deposits) (Fig 13).
- **Non-scarring alopecia** (androgenetic alopecia, telogen effluvium, alopecia areata, traction alopecia). The biopsy must be performed where the disease is mostly expressed.
- **Scarring alopecia** (peripilar lichen planus, lupus erythematosus, folliculitis decalvans). In this case the biopsy must be performed at the edge of the scarring area.
- **Pyoderma gangrenosum.** The biopsy should be done on a small early pustule and moreover it should be deep enough to reveal the suppurative folliculitis which is the main clue of the disease.
- **Lymphomas and erythrodermic diseases.** Since in these dermatitides there are usually different lesions in different clinical stages a good histological diagnosis is easily reached if more biopsies are performed in different areas from different lesions (Fig 14).

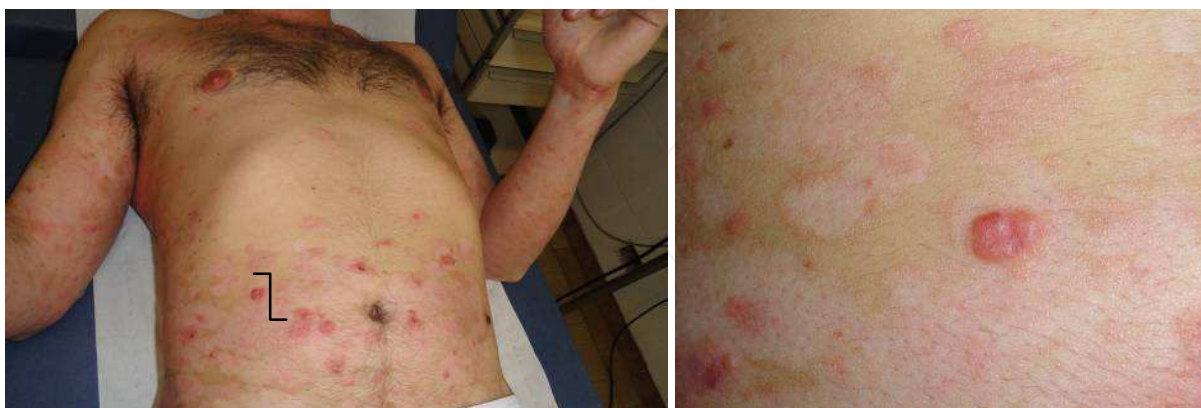

Fig. 14. A case of nodular mycosis fungoides. On the right a higher magnification of the clinical image where it is possible to see a nodular lesion and other flat lesions. In order to have a complete diagnosis, it is necessary to biopsy all the different lesions.

- **Vasculitis.** In suspecyted vasculitis a biopsy should be performed within 24 hours of appearance of the lesion, otherwise fibrinogen and immunoglobulin deposits may be difficult to find.



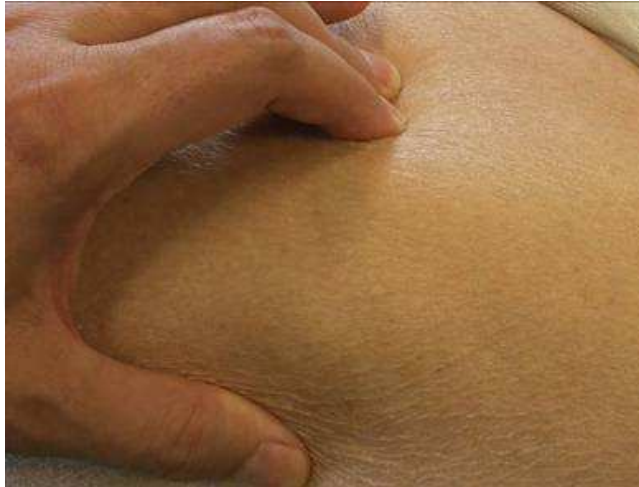

Fig. 15. A case of nephrogenic sclerosis (on the left). Since the dermatitis is a deep inflammatory process a deep biopsy is necessary to demonstrate the diagnostic clue.

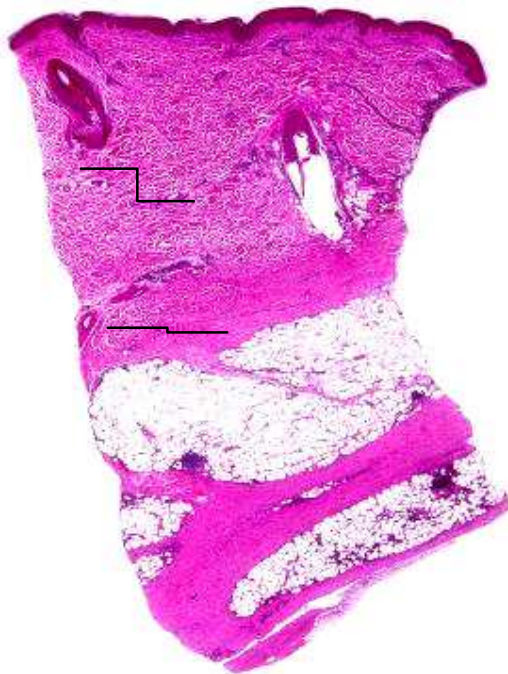

Fig. 16. The rows show the deep sclerosing process with fibrotic strands in the fat layer. A superficial biopsy would have given a false negative result.

- **Deep dermatitis.** In order to make an exact diagnosis of deep dermatitis such as panniculitis, necrobiosis lipoidica, cellulitis,...it is necessary to perform a deep biopsy which includes a thick layer of adipous tissue. This could help to differentiate different forms of cutaneous panniculitis that usually do not show peculiar alteration of superficial skin layers. The deep biopsy would lead to the differentiation between

lobular or septal panniculitis and should demonstrate the type of inflammatory infiltrate (Fig 15 and Fig 16).

- **Dermatomyositis.** While performing a biopsy in a muscle, a second anesthetic injection should be done when the muscle is reached to reduce pain.
- **Scabies (Acariasis).** Even if is not always possible to isolate the „Sarcoptes“ from the skin sample, it should be known that the acarus can not be found in the site of a cutaneous lesion (such as a crust or an excoriated lesion); it usually lies at a few millimeter distance away from the lesion.
- **Keratoacanthoma.** The specimen should include a segment of the shoulder of the lesion extending into the central crater, along with adjacent normal skin and subcutaneous fat (Fig 17).

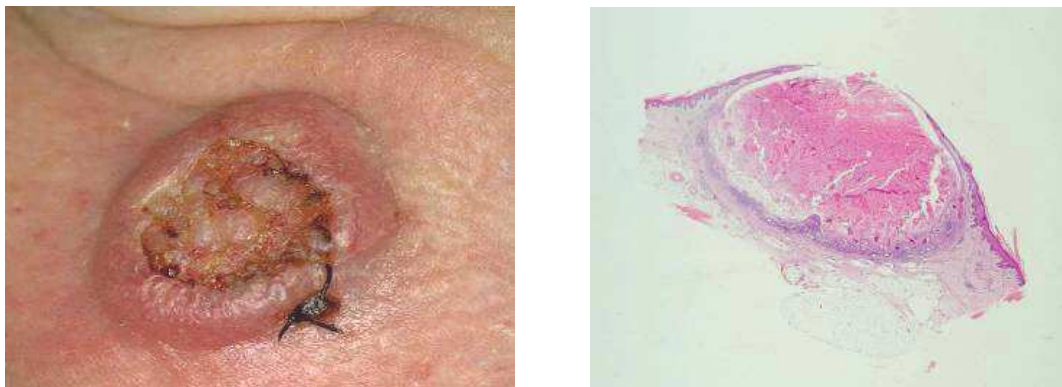


Fig. 17. A clinical image of a biopsied keratoacanthoma (image on the left). The biopsy of the elevated edge permits demonstration of the typical histological architecture of a depressed cup limited by two cutaneous collarettes (image on the right).

## 5. Procedure pitfalls/complications

Complications are usually related to inadequate operator experience or an insufficient knowledge of the anatomy or to underlying clinical conditions of the patient. Most frequent complications are:

Excessive bleeding during or after the procedure. A particular attention to patient in therapy with aspirin or coumarin and to special site such as the nose or the scalp.

If the wound only closes in the center with hard tugging on the tissue, it will be prone to **gaping**. It is a frequent complication in a lesion of the back especially if a patient does not respect a period of rest.

**Wound infection.** It is uncommon if proper aseptic technique is followed. The operative time should be as short as possible. Antibiotic ointment should be applied to the wound immediately following the surgery and then daily until the sutures are removed or the wound heals. Wound-edge redness not associated with pus or drainage is not infection but instead it represents reparative or inflammatory changes associated with healing. Care must be taken when performing procedures in certain areas at higher risk for infection such as the groins or lower legs. Particular attention must be paid to an immunodepressed patient.

**„Dog ears“ at the ends.** “Dog ears” are mounds of elevated tissue that occur at the ends of some linear wound after closure. Dog ears can occur with excisions on convex surfaces such as the arms and legs and most commonly develop from an improperly designed fusiform excision. The wound should be long enough to have at least a 3 to 1 length-to-width ratio. Dog ears can be removed by excising a fusiform island of skin in the direction of the original wound or by removing a lateral piece of redundant skin and extending the wound laterally.

**Damage to nerves or arteries.** Incisions that extend deep into tissues have the potential to cause permanent nerve and artery damage. An increased quantity of anesthetic beneath it can keep the lesion more superficial avoiding the deep structures damage.

**Discomfort during the procedure.** It is usually related to inadequate anesthetization before starting the procedure. Five to ten mL of anesthetic should be administered before most procedures.

**The final scar is thick and unsightly.** Properly designed incisions that follow the lines of least skin tension usually result in cosmetically acceptable scars. Wounds that cross flexion creases or perpendicular to the lines of least tension can thicken into hypertrophic scars.

**Keloids** are frequent on chest, chin, or ear lobules. African or asian patients are mostly involved in **keloids formation**.

## 6. Conclusions

Skin biopsy is an essential technique in the management of skin diseases, but it cannot replace clinical knowledge. Shave biopsy requires the least experience and time, but its use is limited to superficial lesions and should not be used for pigmented lesions. Punch biopsy is the primary diagnostic procedure in dermatology, is simple to perform, has few complications, and small biopsies can heal without suturing. Although closing with sutures improves the cosmetic result, it requires more expertise and time. Excisions are ideal for removing large or deep lesions, provide abundant tissue for multiple studies, and can be curative for a number conditions including cancer. However, excisions require the greatest amount of expertise, time, and office resources, and are associated with more complications, including bleeding and infection. Because of its complexity and complication potential, clinical training is highly recommended prior to attempting an excisional biopsy.


## 7. References

- Bong JI, Herd RM, Hunter JA. (2002). Incisional biopsy and melanoma prognosis. *J Am Acad Dermatol*, 46 (5):690-4.
- Newton Bishop JA, Corrie PG, Evans J, Gore ME, Hall PN, Kirsham N et al. (2002). UK guidelines for the management of cutaneous melanoma. *Br J Plastic Surg*, 55:46-54.
- Pflugfelder A, Weide B, Eigentler TK, Forschner A, Leiter U, Held L, Meier F, Garbe C. (2010). Incisional biopsy and melanoma prognosis: facts and controversies. *Clin Dermatol*, 28(3):316-8.
- Swanson NA, Lee KK, Gorman A, Lee HN. (2002). Biopsy techniques: diagnosis of melanoma. *Dermatol Clin*, 20:667-80.

Tadiparthi S, Panchani S, Iqbal A. (2008). Biopsy for malignant melanoma-are we following the guidelines?. *Ann R Coll Surg Engl*,90:322-325.

IntechOpen

IntechOpen



### **Skin Biopsy - Perspectives**

Edited by Dr. Uday Khopkar

ISBN 978-953-307-290-6

Hard cover, 336 pages

**Publisher** InTech

**Published online** 02, November, 2011

**Published in print edition** November, 2011

Skin Biopsy - Perspectives is a comprehensive compilation of articles that relate to the technique and applications of skin biopsy in diagnosing skin diseases. While there have been numerous treatises to date on the interpretation or description of skin biopsy findings in various skin diseases, books dedicated entirely to perfecting the technique of skin biopsy have been few and far between. This book is an attempt to bridge this gap. Though the emphasis of this book is on use of this technique in skin diseases in humans, a few articles on skin biopsy in animals have been included to acquaint the reader to the interrelationship of various scientific disciplines. All aspects of the procedure of skin biopsy have been adequately dealt with so as to improve biopsy outcomes for patients, which is the ultimate goal of this work.

### **How to reference**

In order to correctly reference this scholarly work, feel free to copy and paste the following:

Z. Seia, L. Musso, Stefania Palazzini and M. Bertero (2011). Skin Biopsy Procedures: How and Where to Perform a Proper Biopsy, Skin Biopsy - Perspectives, Dr. Uday Khopkar (Ed.), ISBN: 978-953-307-290-6, InTech, Available from: <http://www.intechopen.com/books/skin-biopsy-perspectives/skin-biopsy-procedures-how-and-where-to-perform-a-proper-biopsy>

**INTech**  
open science | open minds

### **InTech Europe**

University Campus STeP Ri  
Slavka Krautzeka 83/A  
51000 Rijeka, Croatia  
Phone: +385 (51) 770 447  
Fax: +385 (51) 686 166  
[www.intechopen.com](http://www.intechopen.com)

### **InTech China**

Unit 405, Office Block, Hotel Equatorial Shanghai  
No.65, Yan An Road (West), Shanghai, 200040, China  
中国上海市延安西路65号上海国际贵都大饭店办公楼405单元  
Phone: +86-21-62489820  
Fax: +86-21-62489821



© 2011 The Author(s). Licensee IntechOpen. This is an open access article distributed under the terms of the [Creative Commons Attribution 3.0 License](https://creativecommons.org/licenses/by/3.0/), which permits unrestricted use, distribution, and reproduction in any medium, provided the original work is properly cited.

IntechOpen

IntechOpen